frontiers | Research Topics

Surgical innovation and advancement in orthopedics

Edited by
Paphon Sa-ngasoongsong and Toshimi Aizawa

Published in
Frontiers in Surgery



FRONTIERS EBOOK COPYRIGHT STATEMENT

The copyright in the text of individual articles in this ebook is the property of their respective authors or their respective institutions or funders. The copyright in graphics and images within each article may be subject to copyright of other parties. In both cases this is subject to a license granted to Frontiers.

The compilation of articles constituting this ebook is the property of Frontiers.

Each article within this ebook, and the ebook itself, are published under the most recent version of the Creative Commons CC-BY licence. The version current at the date of publication of this ebook is CC-BY 4.0. If the CC-BY licence is updated, the licence granted by Frontiers is automatically updated to the new version.

When exercising any right under the CC-BY licence, Frontiers must be attributed as the original publisher of the article or ebook, as applicable.

Authors have the responsibility of ensuring that any graphics or other materials which are the property of others may be included in the CC-BY licence, but this should be checked before relying on the CC-BY licence to reproduce those materials. Any copyright notices relating to those materials must be complied with.

Copyright and source acknowledgement notices may not be removed and must be displayed in any copy, derivative work or partial copy which includes the elements in question.

All copyright, and all rights therein, are protected by national and international copyright laws. The above represents a summary only. For further information please read Frontiers' Conditions for Website Use and Copyright Statement, and the applicable CC-BY licence.

ISSN 1664-8714
ISBN 978-2-8325-4189-0
DOI 10.3389/978-2-8325-4189-0

About Frontiers

Frontiers is more than just an open access publisher of scholarly articles: it is a pioneering approach to the world of academia, radically improving the way scholarly research is managed. The grand vision of Frontiers is a world where all people have an equal opportunity to seek, share and generate knowledge. Frontiers provides immediate and permanent online open access to all its publications, but this alone is not enough to realize our grand goals.

Frontiers journal series

The Frontiers journal series is a multi-tier and interdisciplinary set of open-access, online journals, promising a paradigm shift from the current review, selection and dissemination processes in academic publishing. All Frontiers journals are driven by researchers for researchers; therefore, they constitute a service to the scholarly community. At the same time, the *Frontiers journal series* operates on a revolutionary invention, the tiered publishing system, initially addressing specific communities of scholars, and gradually climbing up to broader public understanding, thus serving the interests of the lay society, too.

Dedication to quality

Each Frontiers article is a landmark of the highest quality, thanks to genuinely collaborative interactions between authors and review editors, who include some of the world's best academicians. Research must be certified by peers before entering a stream of knowledge that may eventually reach the public - and shape society; therefore, Frontiers only applies the most rigorous and unbiased reviews. Frontiers revolutionizes research publishing by freely delivering the most outstanding research, evaluated with no bias from both the academic and social point of view. By applying the most advanced information technologies, Frontiers is catapulting scholarly publishing into a new generation.

What are Frontiers Research Topics?

Frontiers Research Topics are very popular trademarks of the *Frontiers journals series*: they are collections of at least ten articles, all centered on a particular subject. With their unique mix of varied contributions from Original Research to Review Articles, Frontiers Research Topics unify the most influential researchers, the latest key findings and historical advances in a hot research area.

Find out more on how to host your own Frontiers Research Topic or contribute to one as an author by contacting the Frontiers editorial office: frontiersin.org/about/contact

Surgical innovation and advancement in orthopedics

Topic editors

Paphon Sa-ngasoongsong — Mahidol University, Thailand

Toshimi Aizawa — Tohoku University, Japan

Citation

Sa-ngasoongsong, P., Aizawa, T., eds. (2024). *Surgical innovation and advancement in orthopedics*. Lausanne: Frontiers Media SA. doi: 10.3389/978-2-8325-4189-0

Table of contents

09 Polyostotic Fibrous Dysplasia Complicated by Pathological Fracture of Right Femoral Shaft with Nonunion: A Case Report
Qifan Yang, Jing Liu, Lei Tan, Ye Jiang and Dong Zhu

16 Arthroscopic Anterior Cruciate Ligament Repair Versus Autograft Anterior Cruciate Ligament Reconstruction: A Meta-Analysis of Comparative Studies
Long Pang, Pengcheng Li, Tao Li, Yinghao Li, Jing Zhu and Xin Tang

29 O-Arm-Navigated, Robot-Assisted Versus Conventional CT Guided Radiofrequency Ablation in Treatment of Osteoid Osteoma: A Retrospective Cohort Study
Tian-Long Wang, Yi-Ping Luo, Zi-Fei Zhou, Jun-Feng Liu, Xiao-Dong Hou, Shao-Hua Jia and Long-Po Zheng

37 Novel Retrograde Tibial Intramedullary Nailing for Distal Tibial Fractures
Bin Peng, Teng Wan, Wenfu Tan, Weiming Guo and Min He

43 A New Antirotation Strategy of K-Wire Tension Band Therapy for Patellar Fracture
Fengpo Sun, Yawen Zhang, Quan Ji, Tongyi Zhang, Yi Zhu, Ze Zhang, Ruining Han and Liangyuan Wen

50 A comparative Study of Novel Extramedullary Fixation and Dynamic Hip Screw in the Fixation of Intertrochanteric Fracture: A Finite-Element Analysis
Kai Ding, Yanbin Zhu, Haicheng Wang, Yonglong Li, Weijie Yang, Xiaodong Cheng, Yingze Zhang, Wei Chen and Qi Zhang

62 Case Report and Preliminary Exploration: Protection of Supraclavicular Nerve Branches during Internal Fixation of Clavicular Fractures through Preoperative Ultrasound Localization
Yulin Wang, Jiapeng Huang, Jianjun Li, Jinfeng Zhou, Qiang Zheng, Zhixue Chen, Penghui Wei and Wenxi Tang

68 Comparative Efficacy of Three Minimally Invasive Procedures for Kümmell's Disease: A Systematic Review and Network Meta-Analysis
Yajian Wang, Bo Liu, Zhenwei Sun, Yaning Zhang and Jiangping Su

78 Wide-Awake Local Anesthesia With no Tourniquet Versus General Anesthesia for the Plating of Distal Radius Fracture: A Systematic Review and Meta-Analysis
Ting-Yu Tu, Chih-Yang Hsu, Pei-Chin Lin and Chun-Yu Chen

92 A New Nomogram Model for Predicting 1-Year All-Cause Mortality After Hip Arthroplasty in Nonagenarians With Hip Fractures: A 20-Year Period Retrospective Cohort Study
Xingchen Lu, Ziming Wang, Feifei Chong, Yu Wang, Siyu Wu, Quanyin Du, Wenlong Gou, Keyun Peng and Yan Xiong

103 The Application of Platelet-Rich Plasma for Patients Following Total Joint Replacement: A Meta-Analysis of Randomized Controlled Trials and Systematic Review
Hongxin Shu, Zhenjun Huang, Xinyan Bai, Zhiyu Xia, Nanye Wang, Xiaoling Fu, Xigao Cheng and Bin Zhou

116 Unicompartmental Knee Arthroplasty for Knee Osteoarthritis With the Pellegrini–Stieda Lesion: A Case Report
Qiuyuan Wang, Wanshou Guo, Zhencai Shi, Weiguo Wang and Qidong Zhang

121 Biomechanical investigation of the hybrid modified cortical bone screw–pedicle screw fixation technique: Finite-element analysis
Alafate Kahaer, Xieraili Maimaiti, Julaiti Maitirouzi, Shuiquan Wang, Wenjie Shi, Nueraihemaiti Abuduwaili, Zhihao Zhou, Dongshan Liu, Abulikemu Maimaiti and Paerhati Rexiti

131 Clinical comparison of three-dimensional exoscope vs. operative microscope in transforaminal lumbar interbody fusion: A retrospective case-control study
Yu-jian Peng, Tian-bu Zhao, Jun Dai, Qian-liang Wang, Qian-zhong-yi Zhang, Jun-yin Cao and Xiao-feng Liu

143 The clinical outcomes of surgical treatment for chronic ankle instability by anatomical reconstruction of the anterior talofibular ligament with autologous half-bundle peroneal longus tendon: A retrospective study
Yeqiang Luo, Shanghui Lin, Lingchuang Kong, Yan Jin, Renkai Wang, Ying Zhang, Baofeng Li and Bei Chen

150 The ankle kinematic reference of normal gait pattern in Thai adults
Krongkaew Klaewkasikum, Tanyaporn Patathong, Chanika Angsanuntsukh, Thira Woratanarat, Jongsook Sanguantrakul and Patarawan Woratanarat

160 Elective transfemoral amputation and simultaneous implantation of a transcutaneous osseointegrated prosthesis stem as salvage treatment after knee joint arthrodesis with poor function: A case report
Katharina Krause, Katherina Richter, Thomas Beyer, Horst Heinrich Aschoff, Dagmar-Christiane Fischer and Thomas Mittlmeier

166 The hidden blood loss and its factors in patients undergoing minimally invasive knee arthroscopy
Sheng Li and Liang A

173 Arthroscopy-assisted partial trapeziectomy combined with ligament reconstruction for thumb carpometacarpal joint osteoarthritis: A different technique
Wan-Ling Zheng, Yang-Chun Wu, Yun-Dong Shen, Hua-Wei Yin and Wen-Dong Xu

182 The high resistance loop (H-loop) technique used for all-inside arthroscopic knotless suprapectoral biceps tenodesis: A case series
Min Zhou, Chuanhai Zhou, Dedong Cui, Yi Long, Jiang Guo, Zhenze Zheng, Ke Meng, Jinming Zhang, Jingyi Hou and Rui Yang

191 Application of allograft and absorbable screws in the reconstruction of a massive bone defect following resection of giant osteochondroma: A retrospective study
Zhihao Ma, Qiang Yang, Xinyu Liu and Zhenfeng Li

197 Different treatments for 3- or 4-part proximal humeral fractures in the elderly patients: A Bayesian network meta-analysis of randomized controlled trials
Jiale Guo, Caiju Peng, Ziyan Hu and Yehai Li

210 Factors for selective ultrasound screening in newborns with developmental dysplasia of the hip (DDH)
Chanika Angsanuntsukh, Tanyaporn Patathong, Krongkaew Klaewkasikum, Witoon Jungtheerapanich, Tanyawat Saisongcroh, Pornchai Mulpruek and Patarawan Woratanarat

217 Risk factors and new inflammatory indicators of deep vein thrombosis after adult patella fractures
Shuo Diao, Jingqiao Li, Jianyong Zhao, Dong Wang, Hanzhou Wang, Xiaopei Xu and Junlin Zhou

225 Biomechanical tests and finite element analyses of pelvic stability using bilateral single iliac screws with different channels in lumbo-iliac fixation
Yangyang Sun, Ying Fu, Fanxiao Liu, Wen Zhang, Huanzhi Ma, Qinghu Li, Dongsheng Zhou and Baisheng Fu

237 Four cases report: Treatment of knee joint cartilage defects using autologous chondrocyte patch implantation
Le Wang, Han Li, Yiguo Cao, Cheng Song, Qi Chen, Jun Hao, Weiguo Zhang and Kang Tian

246 A minimally invasive bipolar surgical approach for the treatment of patellar fracture using the tension-band wiring technique
Zhangxiong Lin, Yaoqing Chen, Hai Wang, Wenbin Lan, Yun Xie and Gui Wu

254 Case report of old anterior dislocation of the shoulder joint and review of the literature
Weiming Guo, Ming Hui, Yuan Yang, Teng Wan, Guang-Gui Zeng, Peiguan Huang, Xiaoxu Wang and Mingjun Qiu

260 First metatarsal single-screw minimally invasive chevron-akin osteotomy: A cost effective and clinically reliable technique
Xueqian Li, Jieyuan Zhang, Shaoling Fu, Cheng Wang, Fan Yang and Zhongmin Shi

267 Posterior ankle arthroscopic treatment of a talar chondroblastoma with allograft and a platelet-rich plasma-fibrin glue: A case report and literature review
Cheng Chen, ZhenDong Li, JianFeng Xue and ZhongMin Shi

276 Sacroiliac screws fixation navigated with three-dimensional printing personalized guide template for the treatment of posterior pelvic ring injury: A case report
Zhanyu Yang, Bin Sheng, Delong Liu, Yiwei Wang, Chao Liu and Rui Xiao

285 Total knee arthroplasty exhibits satisfactory long-term clinical efficacy in the treatment of hemophilia patients with stiff knees
Yi Liu, Yi-fan Liu, Hong-zheng Meng, Tao Sun, Ping Gao, Zhao-zhi Li and Wen-qiang Zhang

294 Clinical application of Kirschner wires combined with 5-Ethibond fixation for patella fractures
Yuan Liang, Jinlong Hu, Pei Zhang, Jiale Zhang, Lixun Yang, Wendong Zhang, Jiaxin Chen, Jinshan He, Yongchao Fang, Yuelai Zhou, Pengtao Chen and Jingcheng Wang

301 A brief review and clinical evidences of teriparatide therapy for atypical femoral fractures associated with long-term bisphosphonate treatment
Jianpeng Gao, Xiao Liu, Xiaoyong Wu, Xiaoya Li, Jianheng Liu and Ming Li

312 A comparison of different surgical approaches to hemiarthroplasty for the femoral neck fractures: A meta-analysis
Liang Shuai, Wu Huiwen, Deng Shihao, Wang Fangyuan, Jing Juehua and Li Jun

325 Treatment of avulsion fracture of posterior cruciate ligament tibial insertion by minimally invasive approach in posterior medial knee
Huihui Guo, Yao Zhao, Liang Gao, Chen Wang, Xianbo Shang, Haitao Fan, Wendan Cheng and Chang Liu

334 Liposclerosing myxofibrous tumor of the distal femur: A case report
Mingyang Zhang, Daguang Zhang, Wenjiang Yu and Chengxue Wang

340 Case report and literature review: Primary leiomyosarcoma of the bone in the trochanteric region of the femur
Zhonghan Wu, Li Cheng, Qiliang Cao, Shuming Ye, Shuisheng Yu, Min Sun and Juehua Jing

349 3D-printed patient-specific instrumentation decreases the variability of patellar height in total knee arthroplasty
Junfeng Wang, Xiaohua Wang, Bin Sun, Liang Yuan, Ke Zhang and Bin Yang

360 Ring-Pins combined with cable cerclage for the fixation of displaced inferior patellar pole fractures
Zhen Jian, Jianbo Jia, Langqing Zeng, Dejian Li, Xu Zhang, Jianhua Zhou, Chengqing Yi, Baoqing Yu and Rongguang Ao

366 The mid-term outcomes of mobile bearing unicompartmental knee arthroplasty versus total knee arthroplasty in the same patient
Jinlong Ma, Liang Zhang, Cui Wang, Kuishuai Xu, Zhongkai Ren, Tianrui Wang, Yingze Zhang, Xia Zhao and Tengbo Yu

374 The effect of hamstring donor-site block for functional outcomes and rehabilitation after anterior cruciate ligament reconstruction
Zijun Cai, Yuntao Yang, Di Liu, Wenhao Lu, Linyuan Pan, Miao He, Wenqing Xie, Dengjie Yu, Hengzhen Li, Hongfu Jin, Yusheng Li and Wenfeng Xiao

383 A retrospective case series of the treatment of spontaneous quadriceps tendon rupture in patients with uremia and secondary hyperparathyroidism
Shuang Wu, Huihui Wang, Yanlin Zhu and Weili Fu

392 Prediction of red blood cell transfusion after orthopedic surgery using an interpretable machine learning framework
Yifeng Chen, Xiaoyu Cai, Zicheng Cao, Jie Lin, Wenyu Huang, Yuan Zhuang, Lehan Xiao, Xiaozhen Guan, Ying Wang, Xingqiu Xia, Feng Jiao, Xiangjun Du, Guozhi Jiang and Deqing Wang

403 Clinical effect of limited posterior decompression and 13-mm titanium mesh implantation on severe thoracolumbar burst fractures: A case series
Liu Jingcheng and Lu Lei

411 Drain vs. no-drain for acetabular fractures after treatment *via* a modified stoppa approach: A retrospective study
Lin Jin, Zhongzheng Wang, Kuo Zhao, Xiaodong Lian, Wei Chen, Yingze Zhang and Zhiyong Hou

418 Outcomes following use of VersaWrap nerve protector in treatment of patients with recurrent compressive neuropathies
Keegan M. Hones, David Spencer Nichols, Haley Barker, Elizabeth Cox, Jaime A. Hones and Harvey Chim

423 Abductor muscle function after anterolateral approach in patients with unilateral end-stage hip osteoarthritis undergoing total hip arthroplasty: A prospective study
Siwadol Wongsak, Chavarat Jarungvittayakon, Kulapat Chulsomlee, Suphaneewan Jaovisidha and Paphon Sa-ngasoongsong

430 New technique for the treatment of fresh bony mallet finger: A retrospective case series study
Zhenshuang Yue, Yafeng Mo, Zhenfei Xiong and Yanghua Tang

435 Surgical treatment of patellar dislocation: A network meta-analysis of randomized control trials and cohort studies
Mingqing Fang, Zijun Cai, Linyuan Pan, Yilan Ding, Yueyao Zhang, Siyuan Cheng, Yifan Wang, Jialin Gao, Yusheng Li and Wenfeng Xiao

449 Deep vein thrombosis screening in pediatric orthopedic patients
Saowalak Tongta, Chanika Angsnuntsukh, Tanyawat Saisongcroh, Thira Woratanarat, Yaowaret Tangsopa and Patarawan Woratanarat

456 Anterior shift of the ventral dura mater: A novel concept of the posterior surgery for ossification of the posterior longitudinal ligament in thoracic spine
Kohei Takahashi, Ko Hashimoto, Takahiro Onoki, Haruo Kanno, Hiroshi Ozawa and Toshimi Aizawa

463 Surgical treatment and functional outcome of bilateral symmetrical hip dislocation and Pipkin type II femoral head fracture: a 5-year follow-up case report and literature review
Sujan Shakya, Jialei Chen, Fei Xing, Zhou Xiang and Xin Duan

470 Comparative study of halo-vest reduction and skull traction reduction in the treatment of cervical fracture dislocation in patients with ankylosing spondylitis
Liang Wang, Haibin Wang, Can Wang, Bangke Zhang, Haisong Yang and Xuhua Lu

477 A randomized controlled study of a psycho-behavioral intervention combined with a non-benzodiazepine to improve perioperative sleep quality in patients undergoing knee arthroplasty
Wang Jing, Zhao Chunlin, Yang Xue, He Tingting, Yuan Linyan, Chen Xiao and Li Lingli

486 Effectiveness of laser welding in cerclage wiring fixation: a biomechanical study
Nachapan Pengrung, Paphon Sa-ngasoongsong, Konlawat Sabsuantang, Nutchanat Thongchuea and Eakkachai Warinsiriruk

493 Investigating the effect of autograft diameter for quadriceps and patellar tendons use in anterior cruciate ligament reconstruction: a biomechanical analysis using a simulated Lachman test
Farid Amirouche, Giovanni Francesco Solitro, Brandon Zachary Gligor, Mark Hutchinson and Jason Koh

frontiers | Frontiers in Surgery

CASE REPORT
published: 12 April 2022
doi: 10.3389/fsurg.2022.879550

Polyostotic Fibrous Dysplasia Complicated by Pathological Fracture of Right Femoral Shaft with Nonunion: A Case Report

*Qifan Yang[1], Jing Liu[2], Lei Tan[1], Ye Jiang[1] and Dong Zhu[1]**

[1]Department of Orthopedics, The First Hospital of Jilin University, Changchun, China, [2]The First Clinical Medical College of Bin Zhou Medical College, Binzhou, China

OPEN ACCESS

Edited by:
Paphon Sa-ngasoongsong, Ramathibodi Hospital, Mahidol University, Thailand

Reviwed by:
Freeman Miller, Alfred I. duPont Hospital for Children, USA
Chanika Angsanuntsukh, Faculty of Medicine Ramathibodi Hospital, Mahidol University, Thailand

***Correspondence:**
Dong Zhu
zhu dong@mail.jlu.edu.cn

Speciality section:
This article was submitted to Orthopedic Surgery, a section of the journal Frontiers in Surgery

Received: *19 February 2022*
Accepted: *28 March 2022*
Published: *12 April 2022*

Citation:
Yang Q, Liu J, Tan L, Jiang Y and Zhu D (2022) Polyostotic Fibrous Dysplasia Complicated by Pathological Fracture of Right Femoral Shaft with Nonunion: A Case Report. Front. Surg. 9:879550. doi: 10.3389/fsurg.2022.879550

Introduction: Fibrous dysplasia is a benign fibrous bone tumor that accounts for 5% to 10% of benign bone tumors. It can manifest as simple fibrous dysplasia (70%–80%), polyostotic fibrous dysplasia (20%–30%), with approximately the same incidence in men and women. We report a patient with a rare case of multiple fibrous dysplasia combined with proximal femoral shepherd deformity with pathological fracture of the femoral shaft complicated by nonunion. It is necessary to understand the disease in more detail to avoid overtreatment of benign lesions or misdiagnosis of malignant tumors and other diseases.

Case presentation: A 58-year-old man with polyostotic fibrous dysplasia, bilateral proximal femur deformity, Shepherd's angle deformity, right femoral shaft pathological fracture complicated by nonunion, we under fluoroscopy, in the obvious proximal fracture, take osteotomy, and process the shape of the cut bone fragment to adapt it to the corrected force line, and then restore it back to its original position, using intramedullary nailing technology complete the operation. Three months after the operation, he came to the hospital for re-examination, and an X-ray of the right femur was taken. It was found that the fractured end had a tendency to heal. The patient was instructed to gradually bear weight. After six months of re-examination, the patient could walk with a walker. One year after the operation, the patient could walk without a walker and take care of himself at home. However, there was still stretch-like pain in the right lower back, but it was tolerable.

Conclusions: For patients with polyostotic fibrous dysplasia combined with proximal femoral shepherd deformity and pathological fracture of the femoral shaft with nonunion, osteotomy combined with intramedullary nailing is a simple and convenient way to correct the deformity and obtain correct fracture alignment.

Keywords: fibrous dysplasia, shepherd's crook deformity, nonunion, osteotomies, femoral shaft fracture

INTRODUCTION

The concept of "fibrous dysplasia" was introduced by Lichtenstein in 1938 (1, 2), which is a benign fibrous bone tumor in which fibrous tissue replaces normal bone tissue with metaplastic young woven bone. It accounts for about 5 to 10 percent of benign bone tumors. It can present as simple fibrous dysplasia (70%–80%), polyostotic fibrous dysplasia (20%–30%), Mccun-Albright syndrome (2%–3%), or Mazabraud syndrome(fibrous dysplasia with intramuscular myxoma) (3). In 1891, von Recklingosen first described that the proximal femur is one of the most common sites. Mechanical stress and repeated fractures result in progressive varus and bowing, typical of shepherd's curvature (4). Shepherd's deformity is a deformity that develops through osteoporosis and constant microfracture and fracture repair and is associated with limb pain, lameness, and femoral neck fractures (5).

A classification of proximal femoral deformities has previously been proposed based on the largest cohort of patients with fibrous dysplasia known to us. It is divided into six types according to the neck axis angle and the presence or absence of side axis bending. Types 1 and 2 deformities usually do not progress, while types 3–6 deformities have a higher recurrence rate even with treatment. Type 3 can be corrected with an intertrochanteric osteotomy; types 4 and 5 can be corrected with one or more osteotomies, and type 6 can be fixed with one or more femoral intertrochanteric osteotomies. Osteotomy to correct the deformity. Whenever possible, all associated deformities should be treated with appropriate osteotomy (4) It has also been suggested that polyostotic fibrous dysplasia imaging features at least one of the following: (a) a typical "ground glass" appearance, (b) radiographic Increased or decreased density, (c) bone cyst, or (d) enlarged and/or irregular femoral profile; the presence and extent of the axial cortex and medullary canal (6) consistent with the disease based on the patient's imaging profile Performance.

Regarding the treatment of fibrous dysplasia, there are many treatment options. Initially, there were simple curettage and bone grafting to treat related deformities. Later, related treatment methods such as osteotomy, plate fixation, and intramedullary nailing appeared (7, 8).

We report a rare case of multiple fibrous dysplasia combined with proximal femoral shepherd deformity in a patient with a pathological fracture of the femoral shaft with nonunion. As far as we know, this is a rare case in China. By providing this case and treatment, we can provide reference experience for medical workers to understand, diagnose and treat this disease in the future.

CASE REPORT

A 58-year-old man developed bilateral lower extremity deformities when he was young. He developed pain in his right thigh with no obvious cause 8 years ago. He was still able to farm daily and did not receive special treatment. The pain in the right thigh worsened 3 months ago and he was unable to stand immediately. He went to a local hospital and was diagnosed with a fractured right femoral shaft. No surgical treatment was performed, but conservative treatment was given at home. 2 months ago, consciously improved and walked down the ground, fell again, and the pain in the right thigh worsened. Conservative treatment was given at home again. Recently, he was admitted to our hospital because of worsening pain.

On admission, the clinical presentation was consistent with varus hip deformity, possibly with bilateral femoral neck deformities (**Figure 1**). In line with Tscherne type I closed fracture soft tissue injury, the remaining manifestations did not have any endocrine disturbance, pigmentation changes, or precocious puberty changes. Both lower extremities were deformed, and both knee joints were huge (**Figure 2**). In view of the abnormal bone quality of the patient, the imaging examination showed: multiple fibrous dysplasia combined with proximal femoral shepherd deformity, pathological fracture of the femoral shaft complicated by bone Nonunion (**Figure 3**), multiple fracture lines can be seen on the right femur, old fracture lines and new fracture lines coexist, and the original fractures are malunion. The fractured end of the new fracture was obviously displaced. The patient's hemoglobin, total number and classification of white blood cells, erythrocyte sedimentation rate, C-reactive protein, calcium, phosphorus, alkaline phosphatase and other blood and serum biochemical indicators and hormone levels were within the normal range. On the second day of hospitalization, the right femoral shaft fracture was treated with open reduction, intramedullary nailing, internal fixation and osteotomy under general anesthesia, and the deformity was corrected and the fracture was fixed in one stage.

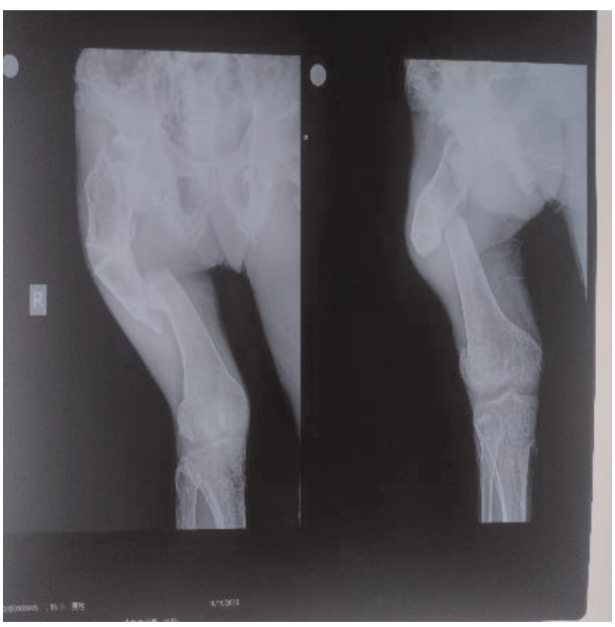

FIGURE 1 | X-ray of the patient on admission.



FIGURE 2 | Preoperative external image.

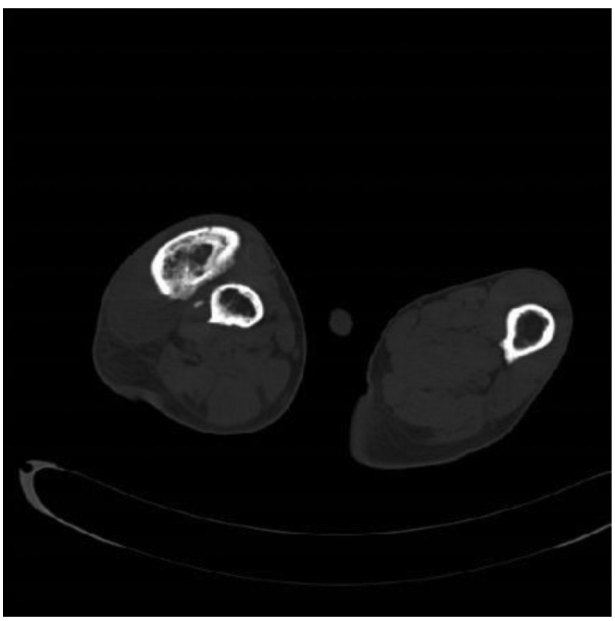

FIGURE 3 | Preoperative CT.

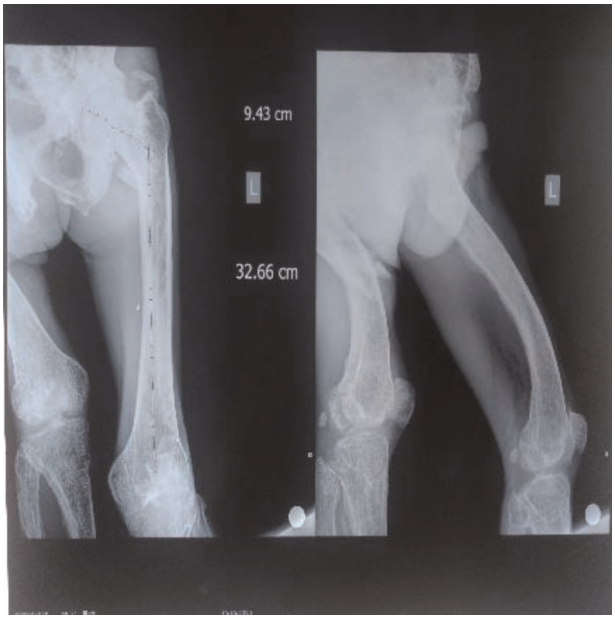

FIGURE 4 | Preoperative imaging of the unaffected femur.

According to the length of the unaffected limb (**Figure 4**), a special length of intramedullary nail is ordered. This operation is different from the conventional antegrade or retrograde intramedullary nailing. The feature of this case is that after the femoral deformity osteotomy is done, the bone drill is inserted retrogradely from the fracture end to ream the pulp, and the opening is retrograde from the greater trochanter. With the help of the golden finger, the guide pin was introduced retrogradely, and the ball end of the guide pin passed through the orthopedic bone fragment and the distal end of the fracture under direct vision. Postoperative fluoroscopy showed that the distal guide pin was not located in the middle of the medullary cavity, so a 4.0 Steiner wire was used as a block. The intramedullary nail is inserted anterogradely into the medullary cavity, and there is no special treatment for other operations. Because the patient refused to undergo pathological examination, the bone tissue was not taken for examination. This operation successfully completes the fracture fixation and deformity correction through the combination of intramedullary nailing technology and osteotomy. Because the two surgical techniques are mature and simple, the operation time can be greatly reduced and the fracture end can be stabilized. It can reduce the economic pressure of patients, and the central fixation with intramedullary nails has good mechanics, and the blood supply damage to the fracture end is less than that of the steel plate, which can restore the force line of the femur well; however, the femur of such patients is too short, and special reservation The length of intramedullary needles may take a long time and delay the operation date, resulting in complications such as thrombosis, fall off, and fracture pain of the lower extremities, increasing the risk of life and economic burden. The orthopedic bone block has a large resistance during the insertion of the intramedullary needle, so it is necessary to prevent stress fractures and implant fractures (**Figure 5**). On the third day after the operation, he reported that the right psoas muscle was tense, showing traction-like pain. After physical examination, it was found that the psoas

muscle was tense and tenderness was positive. He was given hot compress treatment, and the symptoms were relieved. After the operation, the deformity of the right thigh of the patient was relieved, but the knee valgus was still present (**Figure 6**).

Three months after the operation, he came to the hospital for re-examination. An X-ray of the right femur was taken. It was seen that the fracture end had a tendency to heal, and the patient was instructed to gradually bear weight (**Figure 7**); re-examination six months after the operation, the right femur was examined on the front and lateral sides, and the fracture was healed well. Now the patient can walk with the aid of a walker (**Figure 8**); One year after the operation, the X-ray of

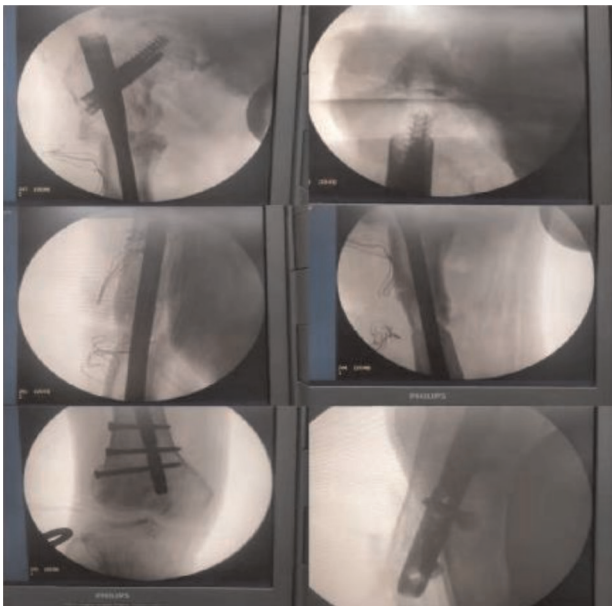

FIGURE 5 | Intraoperative fluoroscopic imaging.



FIGURE 7 | Follow-up 3 months after surgery.



FIGURE 6 | Postoperative external image.



FIGURE 8 | 6 months after the operation, the fracture line was further blurred.

the right femur was taken on the front and the lateral side (**Figure 9**): it was seen that the fractured end had healed. Now the patient can walk without the aid of a walker and can take care of himself at home (**Figure 10**). However, there was still stretch-like pain in the right lower back, but it was tolerable. This case report has been verbally agreed by the patient and his family (**Supplementary Video** attached at the end of the article).



FIGURE 9 | At 14 months postoperatively, the fracture was completely healed.



FIGURE 10 | One-year postoperative image.

DISCUSSION

The concept of "fibrous dysplasia" was introduced by Lichtenstein in 1938 (2), which is a benign fibrous bone tumor in which fibrous tissue replaces normal bone tissue with metaplastic young woven bone. It accounts for about 5 to 10 percent of benign bone tumors. It can present as simple fibrous dysplasia (70%–80%), polyostotic fibrous dysplasia (20%–30%), Mccun-Albright syndrome (2%–3%), or Mazabraud syndrome (fibrous dysplasia with intramuscular myxoma) (3). Of the affected sites, the proximal femur is one of the most common. As a rare skeletal disease, some scholars believe that its pathogenesis is that the mutation of somatic activation cam regulatory protein Gsa causes normal bone and bone marrow to be replaced by abnormally proliferated osteogenic precursors, resulting in deformity, fracture, dysfunction and pain. The disease can lead to a significant decrease in the patient's quality of life.

Nonunion is a rare disease in clinical practice. Once it occurs, it can cause huge living and economic burdens to patients and their families. At present, there is no consensus among countries on the definition of nonunion; the US Food and Drug Administration (FDA) defines the disease as: no healing on imaging for 9 months and no significant progress in healing in the past 3 months (9). The Danish Orthopedic Trauma Society defines nonunion as "a fracture that does not heal without further intervention" (10). By consulting relevant information, Protein antibodies, PTH and PTHrP have therapeutic effects on it, but there is no definite clinical trial to prove this conclusion (6); the most widely accepted treatment is still surgery. To strong fixation, restore the stability of the fracture-based.

Regarding the different manifestations and different stages of shepherd's flexion deformity, it is the most sensible choice to take a targeted treatment method. No matter which customized method is chosen, it is the most important to achieve the correct alignment.

Through reading the literature, the treatment of FD can be divided into conservative and surgical treatment. Conservative treatment includes the use of bisphosphonates to treat the disease, such as zoledronic acid, alendronate, and pamidronate. Long-term results show that it can reduce bone pain (11, 12); Surgical treatment is mostly for children: such as intramedullary nailing + corrective osteotomy, for those with small-sized femurs, the modified humeral intramedullary nail is used, and when the femur grows to a sufficient size, it is replaced with an adult. Femoral intramedullary nailing, there are also valgus osteotomy + lesion curettage + allogeneic bone graft + PHP fixation, and valgus osteotomy combined with growing rods and tension band construct (13–17); for adults, Including dynamic hip screw (DHS) or locking compression plate proximal screw (LCP) combined with

intramedullary cortical support allogeneic bone (fibula) fixation, curettage + bone graft + intramedullary nail fixation, some doctors also use "Angled blade plate", which considers that partially resorbed cortical bone is generally not suitable for locking the proximal screw of the intramedullary nail, and the angled blade plate can be inserted with relative ease, thus providing adequate mechanical support (18–20).

In conclusion, we report a rare case of an adult male with multiple fibrous dysplasia with proximal femoral Shepherd deformity with a pathological fracture of the femoral shaft with nonunion. In this patient's operation, we successfully reduced the fracture and achieved healing through osteotomy and intramedullary nailing, which effectively improved the patient's prognosis and saved the patient a lot of treatment costs. This will provide a reference for future clinical diagnosis and treatment of patients with similar conditions.

DATA AVAILABILITY STATEMENT

The original contributions presented in the study are included in the article/**Supplementary Material**, further inquiries can be directed to the corresponding author/s.

ETHICS STATEMENT

Informed consent was obtained from the patients in this case study.

AUTHOR CONTRIBUTIONS

DZ and LT are responsible for diagnosing diseases and reviewing articles, QY is responsible for editing articles, JL is responsible for contacting patients for review and collecting imaging data, and YJ is responsible for editing articles. All authors contributed to the article and approved the submitted version.

FUNDING

This study was supported by the National Natural Science Foundation of China (Grant No12072129).

SUPPLEMENTARY MATERIAL

The Supplementary Material for this article can be found online at: https://journal.frontiersin.org/article/10.3389/fsurg.2022.879550/full#supplementary-material.

REFERENCES

1. Nishiwaki T, Uchikawa S, Kusakabe H, Seki A, Eguchi Y, Takayama S, et al. Pronounced femur malunion after pathological bone fracture due to a simple bone cyst in the shaft of the femur, treated using Ilizarov fixation: a case report. *J Med Case Rep*. (2018) 12(1):173. doi: 10.1186/s13256-018-1710-3
2. Garlock JH. The differential diagnosis of hyperparathyroidism: with special reference to polyostotic fibrous dysplasia. *Ann Surg*. (1938) 108(3):347–61. doi: 10.1097/00000658-193809000-00002
3. Muthusamy S, Subhawong T, Conway SA, Temple HT. Locally aggressive fibrous dysplasia mimicking malignancy: a report of four cases and review of the literature. *Clin Orthop Relat Res*. (2015) 473(2):742–50. doi: 10.1007/s11999-014-3926-x
4. Ippolito E, Farsetti P, Boyce AM, Corsi A, De Maio F, Collins MT. Radiographic classification of coronal plane femoral deformities in polyostotic fibrous dysplasia. *Clin Orthop Relat Res*. (2014) 472(5):1558–67. doi: 10.1007/s11999-013-3380-1
5. Al-Mouazzen L, Rajakulendran K, Ahad N. Fibrous dysplasia, shepherd's crook deformity and an intra-capsular femoral neck fracture. *Strategies Trauma Limb Reconstr*. (2013) 8(3):187–91. doi: 10.1007/s11751-013-0174-7
6. Kostenuik P, Mirza FM. Fracture healing physiology and the quest for therapies for delayed healing and nonunion. *J Orthop Res*. (2017) 35(2):213–23. doi: 10.1002/jor.23460
7. Enneking W, Gearen P. Fibrous dysplasia of the femoral neck. Treatment by cortical bone-grafting. *J Bone Joint Surg Am*. (1986) 68(9):1415–22. doi: 10.2106/00004623-198668090-00015
8. Stephenson R, London M, Hankin F, Kaufer H. Fibrous dysplasia. An analysis of options for treatment. *J Bone Joint Surg Am*. (1987) 69(3):400–9. doi: 10.2106/00004623-198769030-00012
9. Ding ZC, Lin YK, Gan YK, Tang TT. Molecular pathogenesis of fracture nonunion. *J Orthop Translat*. (2018) 14:45–56. doi: 10.1016/j.jot.2018.05.002
10. Schmal H, Brix M, Bue M, Ekman A, Ferreira N, Gottlieb H, et al. Nonunion - consensus from the 4th annual meeting of the Danish Orthopaedic Trauma Society. *EFORT Open Rev*. (2020) 5(1):46–57. doi: 10.1302/2058-5241.5.190037
11. Boyce AM, Kelly MH, Brillante BA, Kushner H, Wientroub S, Riminucci M, et al. A randomized, double blind, placebo-controlled trial of alendronate treatment for fibrous dysplasia of bone. *J Clin Endocrinol Metab*. (2014) 99(11):4133–40. doi: 10.1530/boneabs.2.oc21
12. Chapurlat RD, Delmas PD, Liens D, Meunier PJ. Long-term effects of intravenous pamidronate in fibrous dysplasia of bone. *J Bone Miner Res*. (1997) 12(10):1746–52. doi: 10.1359/jbmr.1997.12.10.1746
13. Al Kaissi A, Kenis V, Chehida FB, Hofstaetter J, Grill F, Ganger R. Lower limbs deformities in patients with McCune-Albright syndrome: Tomography and treatment. *Afr J Paediatr Surg*. (2016) 13(3):125–30. doi: 10.4103/0189-6725.187808
14. Bian Z, Guo Y, Zhu Z, Lv X, Fu G, Yang Z. Preliminary results of surgical treatment of fibrous dysplasia of proximal femur in children. *Zhonghua wai ke za zhi*. (2021) 59(9):731–7. doi: 10.3760/cma.j.cn112139-20210307-00113
15. Chen F, Wei Y, Xia J, Wu J, Wang S, Huang G, et al. Double-level osteotomy and one-stage reconstruction with long intramedullary femoral nail to correct a severe proximal and diaphyseal femur deformity in a patient with polyostotic fibrous dysplasia: case report and literatures review. *Int J Clin Exp Med*. (2015) 8(8):14188–95. PMID: 26550394.
16. Benedetti Valentini M, Ippolito E, Catellani F, Farsetti P. Internal fixation after fracture or osteotomy of the femur in young children with polyostotic fibrous dysplasia. *J Pediatr Orthop B*. (2015) 24(4):291–5. doi: 10.1097/BPB.0000000000000192
17. Hampton MJ, Weston-Simmons S, Giles SN, Fernandes JA. Deformity correction, surgical stabilisation and limb length equalisation in patients with fibrous dysplasia: a 20-year experience. *Strategies Trauma Limb Reconstr*. (2021) 16(1):41–5. doi: 10.5005/jp-journals-10080-1523
18. Dheenadhayalan J, Avinash M, Lakhani A, Rajasekaran S. Shepherd's crook deformity: how to set it straight. A five-step surgical guide. *J Orthop Surg (Hong Kong)*. (2019) 27(1):2309499019834362. doi: 10.1177/2309499019834362
19. Fang X, Liu H, Lang Y, Xiong Y, Duan H. Fibrous dysplasia of bone: surgical management options and outcomes of 22 cases. *Mol Clin Oncol*. (2018) 9(1):98–103. doi: 10.3892/mco.2018.1636
20. Majoor BCJ, Leithner A, van de Sande MAJ, Appelman-Dijkstra NM, Hamdy NAT, Dijkstra PDS. Individualized approach to the surgical management of fibrous dysplasia of the proximal femur. *Orphanet J Rare Dis*. (2018) 13(1):72. doi: 10.1186/s13023-018-0805-7

Conflict of Interest: The authors declare that the research was conducted in the absence of any commercial or financial relationships that could be construed as a potential conflict of interest.

Publisher's Note: All claims expressed in this article are solely those of the authors and do not necessarily represent those of their affiliated organizations, or those of the publisher, the editors and the reviewers. Any product that may be evaluated in

this article, or claim that may be made by its manufacturer, is not guaranteed or endorsed by the publisher.

Copyright © 2022 Zhu, Yang, Liu, Lei and Jang. This is an open-access article distributed under the terms of the Creative Commons Attribution License (CC BY). The use, distribution or reproduction in other forums is permitted, provided the original author(s) and the copyright owner(s) are credited and that the original publication in this journal is cited, in accordance with accepted academic practice. No use, distribution or reproduction is permitted which does not comply with these terms.

frontiers | Frontiers in Surgery

SYSTEMATIC REVIEW
published: 20 April 2022
doi: 10.3389/fsurg.2022.887522

Arthroscopic Anterior Cruciate Ligament Repair Versus Autograft Anterior Cruciate Ligament Reconstruction: A Meta-Analysis of Comparative Studies

Long Pang[1†], Pengcheng Li[1†], Tao Li[1], Yinghao Li[1], Jing Zhu[2] and Xin Tang[1]**

[1]Department of Orthopedics, Orthopedic Research Institute, West China Hospital, Sichuan University, Chengdu, China, [2]Department of Respiratory and Critical Care Medicine, West China Hospital, Sichuan University, Chengdu, China

OPEN ACCESS

Edited by:
Paphon Sa-ngasoongsong, Ramathibodi Hospital, Mahidol University, Thailand

Reviewed by:
Jatupon Kongtharvonskul, Mahidol University, Thailand
Chaiyanun Vijittrakarnrung, Ramathibodi Hospital, Mahidol University, Thailand

***Correspondence:**
Jing Zhu
zhu-jing2008@163.com
Xin Tang
tangxin9388@163.com

†These authors have contributed equally to this work and share first authorship

Speciality section:
This article was submitted to Orthopedic Surgery, a section of the journal Frontiers in Surgery

Received: *01 March 2022*
Accepted: *05 April 2022*
Published: *20 April 2022*

Citation:
Pang L, Li P, Li T, Li Y, Zhu J and Tang X (2022) Arthroscopic Anterior Cruciate Ligament Repair Versus Autograft Anterior Cruciate Ligament Reconstruction: A Meta-Analysis of Comparative Studies. Front. Surg. 9:887522. doi: 10.3389/fsurg.2022.887522

Purpose: To compare the clinical outcomes of arthroscopic anterior cruciate ligament (ACL) repair and autograft ACL reconstruction for ACL ruptures.

Methods: PubMed, EMBASE, Scopus, Web of Science and The Cochrane Library were searched for relevant studies from 1 January 1990 to 21 March 2022. Two evaluators independently screened the literature, extracted data and assessed the methodological quality of the enrolled studies. Meta-analysis was conducted using RevMan 5.4 software.

Results: Ten studies with mean follow-up periods from 12 to 36 months were included. For 638 patients with ACL ruptures, arthroscopic ACL repair showed statistically comparable outcomes of failure ($p = 0.18$), complications ($p = 0.29$), reoperation other than revision ($p = 0.78$), Lysholm score ($p = 0.78$), Tegner score ($p = 0.70$), and satisfaction ($p = 0.45$) when compared with autograft ACL reconstruction. A significantly higher rate of hardware removal ($p = 0.0008$) but greater International Knee Documentation Committee (IKDC) score ($p = 0.009$) were found in the ACL repair group. The heterogeneity of the side-to-side difference of anterior tibial translation (ΔATT) was high ($I^2 = 80\%$). After the sensitivity analysis, the I^2 decreased dramatically ($I^2 = 32\%$), and the knees with ACL repair showed significantly greater ΔATT ($P = 0.04$).

Conclusion: For proximal ACL ruptures, arthroscopic ACL repair showed similar clinical outcomes, and even better functional performance when compared to autograft ACL reconstruction. ACL repair has a higher rate of hardware removal, and might be related to greater asymptomatic knee laxity. More high-quality prospective trials are needed to confirm our findings.

Keywords: ACL (anterior cruciate ligament), arthroscopic ACL repair, autograft ACL reconstruction, meta-analysis, arthroscope

INTRODUCTION

Primary open repair of the anterior cruciate ligament (ACL) was the standard surgical technique for ACL ruptures until the 1980s, when poor results at longer follow-up were reported (1–4). Thereafter, open ACL repair was gradually replaced by arthroscopic autograft ACL reconstruction for ACL ruptures.

However, autograft ACL reconstruction has several problems, such as anterior knee pain, thigh muscle weakness following harvesting, and an extensive rehabilitation period (5). In the past decade, renewed and increasing interest in ACL repair has arisen and various arthroscopic ACL repair techniques have been introduced, especially for proximal ACL ruptures (6, 7). Among these newly developed surgeries, four ACL repair techniques have been in the spotlight (5): suture anchor repair (SAR) of the ACL, repair with dynamic intraligamentary stabilization (DIS), internal brace ligament augmentation (IBLA) and bridge-enhanced ACL repair (BEAR). Moreover, previous published systematic reviews showed promising results following ACL repair. In 2017, Ahmad et al. (7) analyzed 23 articles related to DIS and concluded that ACL repair might be an effective modality for the treatment of acute proximal ACL tears. In another systematic review, van der List et al. (8) found that different techniques of primary ACL repair were safe with failure rates between 7 and 11%, and good functional outcome scores in 1,101 patients. However, subsequent two systematic reviews (9, 10) reported inconsistent results following ACL repair compared with ACL reconstruction.

On further review of the above literatures (7–10), we found most included studies in these systematic reviews were case series with relatively small sample sizes, and the number of high-quality trials comparing arthroscopic ACL repair with reconstruction was scarce, making it difficult to conduct a meta-analysis comparing arthroscopic ACL repair with autograft ACL reconstruction. Importantly, there are several high-quality comparative clinical trials (11–14) published in recent years reporting that arthroscopic ACL repair yields ideal results comparable to those of ACL reconstruction. Therefore, the purpose of this meta-analysis was to quantitatively compare the clinical outcomes of arthroscopic ACL repair and autograft ACL reconstruction for ACL ruptures. The study is to explore that whether arthroscopic ACL repair can be a viable alternative to ACL reconstruction for patients with ACL ruptures, providing an optional surgery for treating ACL tears in clinical practice.

METHODS

Literature Search

This study was conducted in strict accordance with the Preferred Reporting Items for Systematic Reviews and Meta-Analyses (PRISMA) guidelines (15). We searched PubMed, Embase, Scopus, Web of Science, and the Cochrane Library, using the combination of "anterior cruciate ligament", "ACL", "repair", "suture", "dynamic intraligamentary stabilization", "internal brace", "bridge-enhanced", "autograft" and "reconstruction". The search was performed by two independent researchers. All possible studies from 1 January 1990 to 21 March 2022, were manually retrieved. In addition, the reference lists of all retrieved articles were reviewed for potentially eligible studies. Any disagreement was debated and resolved with a third researcher.

Inclusion and Exclusion Criteria

Inclusion criteria: (1) the enrolled patients had a confirmed diagnosis of ACL rupture; (2) clinical studies comparing primary arthroscopic ACL repair to autograft ACL reconstruction; (3) a minimum of 12-month follow-up; (4) written in English.

Exclusion criteria: (1) presence of multiligamentous injuries or knee dislocations; (2) presence of concomitant lesions that would alter the rehabilitation; (3) presence of previous knee injuries on either the injured or contralateral knee; (4) long-term follow-up of historical studies; (5) focused on skeletally immature patients; (6) study with smallest cohort or shortest follow-up (different studies that report on the same group of patients); (7) data inadequate or unavailable.

Data Extraction

Two researchers independently extracted data from the included studies. Characteristics of the enrolled studies (authors, year, country, study design, level of evidence, sample size), and patients' baseline information (age, sex, time from injury to surgery, follow-up period, rupture location, autograft). The following clinical outcomes were extracted and pooled: (1) failure, complications, reoperation other than revision, hardware removal rates; (2) anteroposterior (AP) knee laxity assessed by the mean difference in anterior tibial translation (ΔATT) between the injured and contralateral knees; and (3) patient-reported outcomes including the International Knee Documentation Committee (IKDC) score (16), the Lysholm score (17), the Tegner score (18), and satisfaction.

Quality Assessment

Two authors made their own assessment of the risk of bias of enrolled randomized controlled trials (RCTs) according to the Risk of Bias Tool conferred by the Cochrane Handbook (19), and those of cohort and case–control studies by the Methodological Index for Non-Randomized Studies (MINORS) criteria (20). A third evaluator made the final decision when any disagreements appeared.

Statistical Analysis

Statistical analyses were performed with Manager V.5.4 (The Cochrane Collaboration, Software Update, Oxford, UK). We analyzed the outcomes by calculating the weighted mean difference (WMD) and pooled odds ratio (OR) with corresponding 95% confidence intervals (CIs). A P value <0.05 was considered to be statistically significant. We evaluated and characterized the heterogeneity of each eligible study with Cochrane's Q statistic and I^2 statistics. Statistical heterogeneity

between studies was assessed using the I^2 value, where less than 50% was considered to be within the acceptable range of heterogeneity and the fixed effect model was applied. Otherwise, the random effect model was adopted. In case of any heterogeneity, the following methods were applied to explain: (1) sensitivity analysis; (2) subgroup analysis. Sensitivity analyses were conducted to confirm the robustness of pooled outcomes by sequentially removing the included studies one-by-one. Subgroup analyses according to RCT design or non-RCT design were conducted for all outcomes. For the primary outcome failure rates, subgroup analyses according to the rupture location and ACL repair technique were performed. Publication bias was not assessed because the number of studies included in each study area was less than 10; therefore, the statistical power was low.

RESULTS

Literature Search

Two independent researchers searched PubMed, Embase, Scopus, Web of Science and the Cochrane Library according to the identified keywords, and a total of 2,318 articles were retrieved. After 909 duplicates were removed, the titles and abstracts of 1,409 remaining articles were screened, and 1,393 articles were removed according to the inclusion and exclusion criteria. The remaining full texts of 16 articles were screened independently by two researchers. The study by Gagliardi et al. (21) was excluded because this cohort enrolled skeletally immature patients (7–18 years old). The study by Jonkergouw et al. (22) was excluded because it compared outcomes following ACL repair with or without additional internal bracing. The study by Sporsheim et al. (23) was excluded because it was a 30-year follow-up of a history study, in which the contemporary arthroscopic ACL repair technique was not performed. The study by van der List et al. (24) was excluded because the follow-up period was less than 12 months. The study by Connolly et al. (25) excluded only reported postoperative pain and narcotic prescriptions at the first visit. Two studies (26, 27) by Murray et al. focused on the same group of patients, and the study with shorter follow-up (27) was excluded. Finally, 10 articles (11–14, 26, 28–32) were included in the meta-analysis, including 4 RCTs (11–14), 1 prospective cohort study (26), 3 retrospective cohort studies (28, 29, 31), and 2 case–control studies (30, 32) (**Figure 1**).

Quality Assessment

The quality of the included RCTs was assessed using Review Manager software, and they are summarized and visualized in **Figure 2**. The quality of the included cohort and case–control studies was evaluated by MINORS criteria, which are shown in **Table 1**.

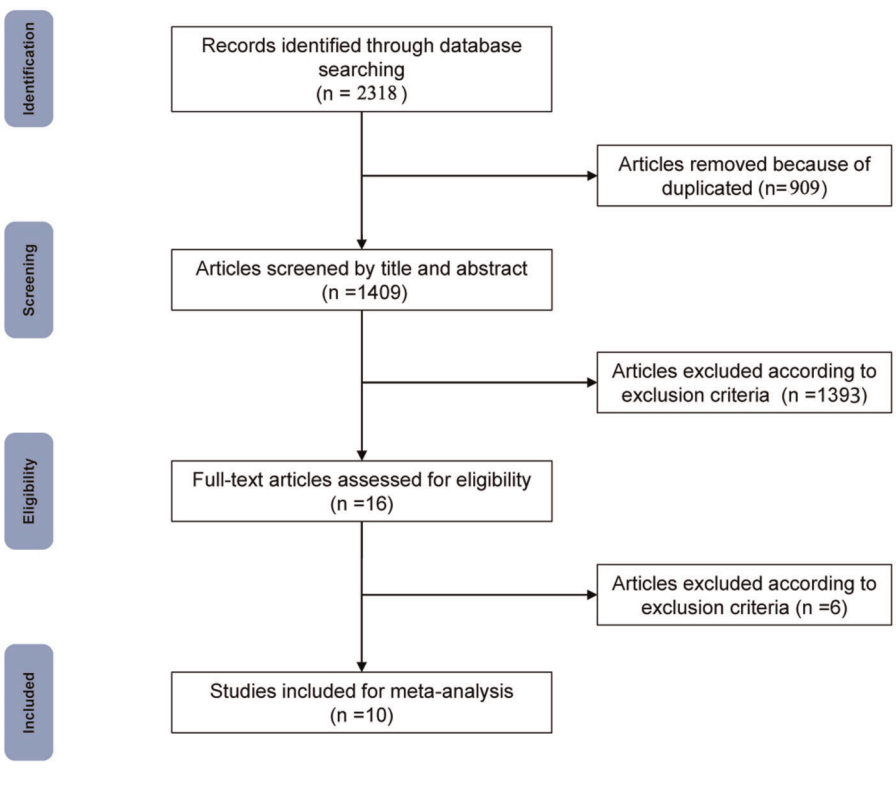

FIGURE 1 | PRISMA flow chart of literature retrieval.

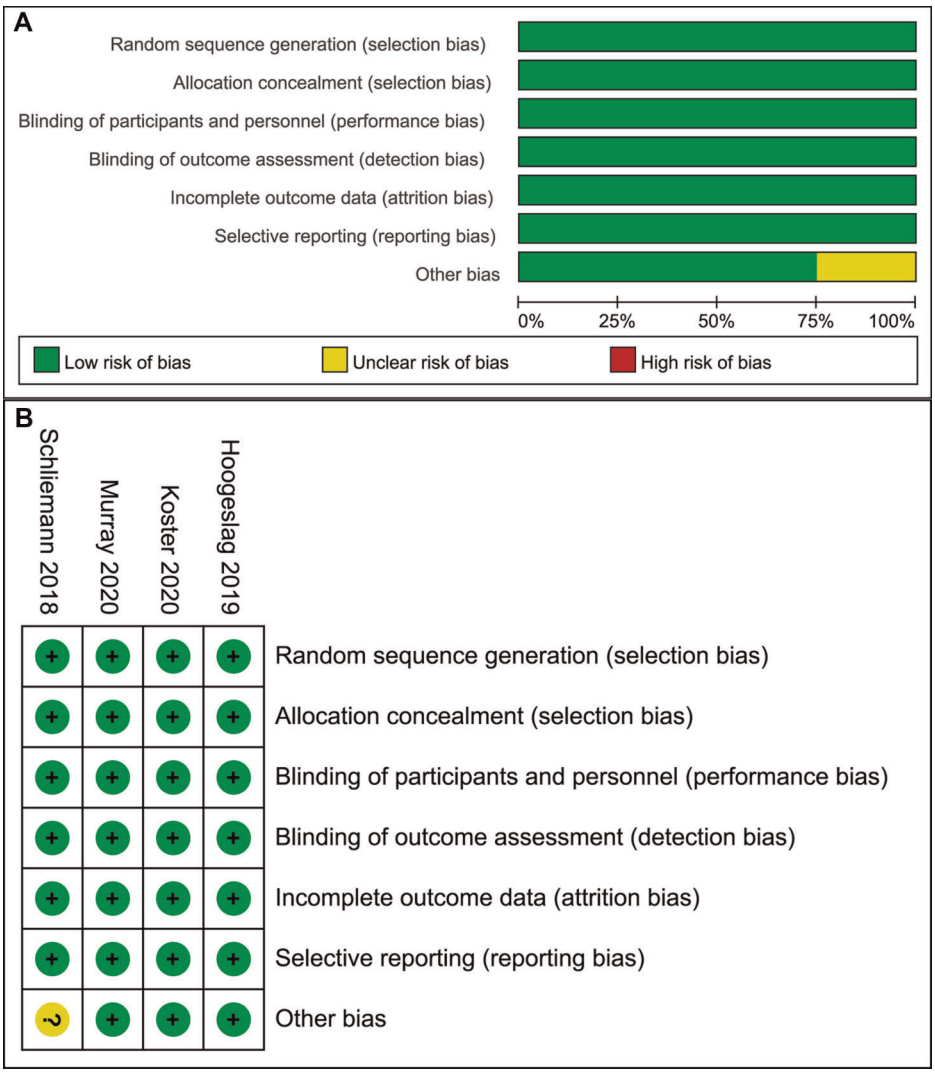

FIGURE 2 | Risk of bias graph (**A**) Graph of the risk of bias for the included RCTs; (**B**) graph of the risk of bias summary for the included RCTs.

TABLE 1 | Quality assessment of the non-RCT studies using the Methodological Index for Non-Randomized Studies (MINORS) criteria.

Author	Year	Journal	Study design	LOE	1	2	3	4	5	6	7	8	Total
Achtnich	2016	Arthroscopy	Case-control	III	2	2	1	2	1	2	2	0	12
Bieri	2017	Injury	Case-control	III	2	2	2	2	1	2	2	0	13
Murray	2019	OJSM	PCS	II	2	2	2	2	2	2	2	1	15
Vermeijden	2020	Arthroscopy	RCS	III	2	2	2	2	1	2	2	0	13
Ortmaier	2021	Sportverletz Sportschaden	RCS	III	2	2	1	2	1	2	1	0	11
Szwedowski	2021	J Clin Med	RCS	III	2	2	1	2	1	2	2	2	14

PCS, prospective cohort study; RCS, retrospective cohort study; LOE, level of evidence.
Only the non-comparative part of the MINORS criteria was used (i.e. first 8 questions). The criteria of MINORS with 0 points when not reported, 1 when reported but not adequate, and 2 when reported and adequate. Maximum score is 16.
1. A clearly stated aim; 2. Inclusion of consecutive patients; 3. Prospective collection of data; 4. End points appropriate to the aim of the study; 5. Unbiased assessment of the study end point; 6. Follow-up period appropriate to the aim of the study; 7. Loss to follow-up less than 5%; 8. Prospective calculation of the study size.

TABLE 2 | Characteristics of the included studies.

Author	Year	Country	Study design	LOE	Sample size, n		Age, y Mean ± SD (Range)		Sex (M/F)		Time from injury to surgery, d Mean ± SD (Range)		Follow-up period, m Mean ± SD (Range)	Rupture location		Autograft
					Repair	Recon	Repair	Recon	Repair	Recon	Repair	Recon		Repair	Recon	
Suture anchor repair (SAR)																
Achtnich	2016	Germany	Case-control	III	20	20	30 ± 8.9	33.6 ± 3.7	NA	NA	<42	<42	28 ± — (24–31)	Proximal rupture		Semitendinosus tendon
Dynamic intraligamentary stabilization (DIS)																
Bieri	2017	Switzerland	Case-control	III	53	53	30 ± 8.5	31 ± 7.6	43/10	43/10	14 ± 12.8	50 ± 27.3	24	Independent		Hamstring tendon (67%), patellar tendon (27%), quadriceps tendon (6%)
Schliemann	2018	Germany	RCT	I	30	30	28.2 ± 11.4	29.1 ± 12.0	15/15	8/22	15.2 ± 4.5	16.3 ± 5.0	12	Independent		Semitendinosus tendon
Hoogeslag	2019	Netherlands	RCT	I	24	24	21 ± — (10–27)	22 ± — (19.3–25)	19/5	18/6	13 ± — (12–16)	47 ± — (42–71)	24	Proximal:83.3% Central:12.5% Distal:4.2%	Proximal: — Central: — Distal: —	Semitendinosus tendon
Kosters	2020	Germany	RCT	I	43	42	28.7 ± 11.4	27.6 ± 10.6	25/18	31/11	14.5 ± 5.2	16.2 ± 7.3	24	Proximal:90.7% Midsubstance:9.3%	Proximal:76.2% Midsubstance:23.8%	Semitendinosus tendon
Bridge-enhanced ACL repair (BEAR)																
Murray	2019	USA	PCS	II	10	10	24.1 ± 4.9 (18.1–34.6)	24.6 ± 5.5 (18.6–33.8)	4/6	2/8	20.8 ± 4.8 (11.0–28.0)	24.6 ± 5.5 (24.0–80.0)	24	Length of tibial remnant, % 50–74: 90% 75–100:10%	Length of tibial remnant, % 50–74: 60% 75–100:40%	Semitendinosus-gracilis tendon
Murray	2020	USA	RCT	I	65	35	17 ± 1	17 ± 2	28/37	16/19	36 ± — (29–42)	39 ± — (33–43)	24	Length of tibial remnant, % 50–74: 88% 75–100:12%	Length of tibial remnant, % 50–74: 80% 75–100:20%	Semitendinosus-gracilis tendon (n = 33), bone–patellar tendon–bone autograft (n = 2)
Internal brace ligament augmentation (IBLA)																
Vermeijden	2020	USA	RCS	III	49	34	34.4 ± 10.7	29.4 ± 11.1	24/25	20/14	36 ± — (17–86)	74 ± — (34–186)	30 ± 9.6/36 ± 13.2	Proximal rupture		Soft-tissue allograft (n = 14), bone-patellar tendon-bone autograft (n = 9), hamstring autograft (n = 4), hybrid graft (n = 3)
Ortmaier	2021	Germany	RCS	III	24	45	NA	NA	8/16	16/29	<21	<21	21	Proximal rupture		Hamstring tendon (n = 25) quadriceps tendon (n = 20)
Szwedowski	2021	Poland	RCS	III	12	15	36 ± — (15–55)	NA	7/5	NA	30–60	30–60	14.8 ± — (5–24)/ 13.6 ± — (10–24)	Proximal rupture		Semitendinosus -gracilis tendon

RCT, randomized controlled trial; PCS, prospective cohort study; RCS, retrospective cohort study; LOE, level of evidence; Recon, reconstruction; M, male; F, female.

Baseline Data

Detailed baseline information for all included articles is summarized in **Table 2**, with a total of 638 patients assigned to the two groups (ACL repair/ACL reconstruction = 330/308). The mean age of patients ranged from 17 to 36 years old, and the percentage of male patients was from 30 to 81%. The mean time from injury to surgery ranged from 13 to 74 days, and the follow period ranged from 12 to 36 months.

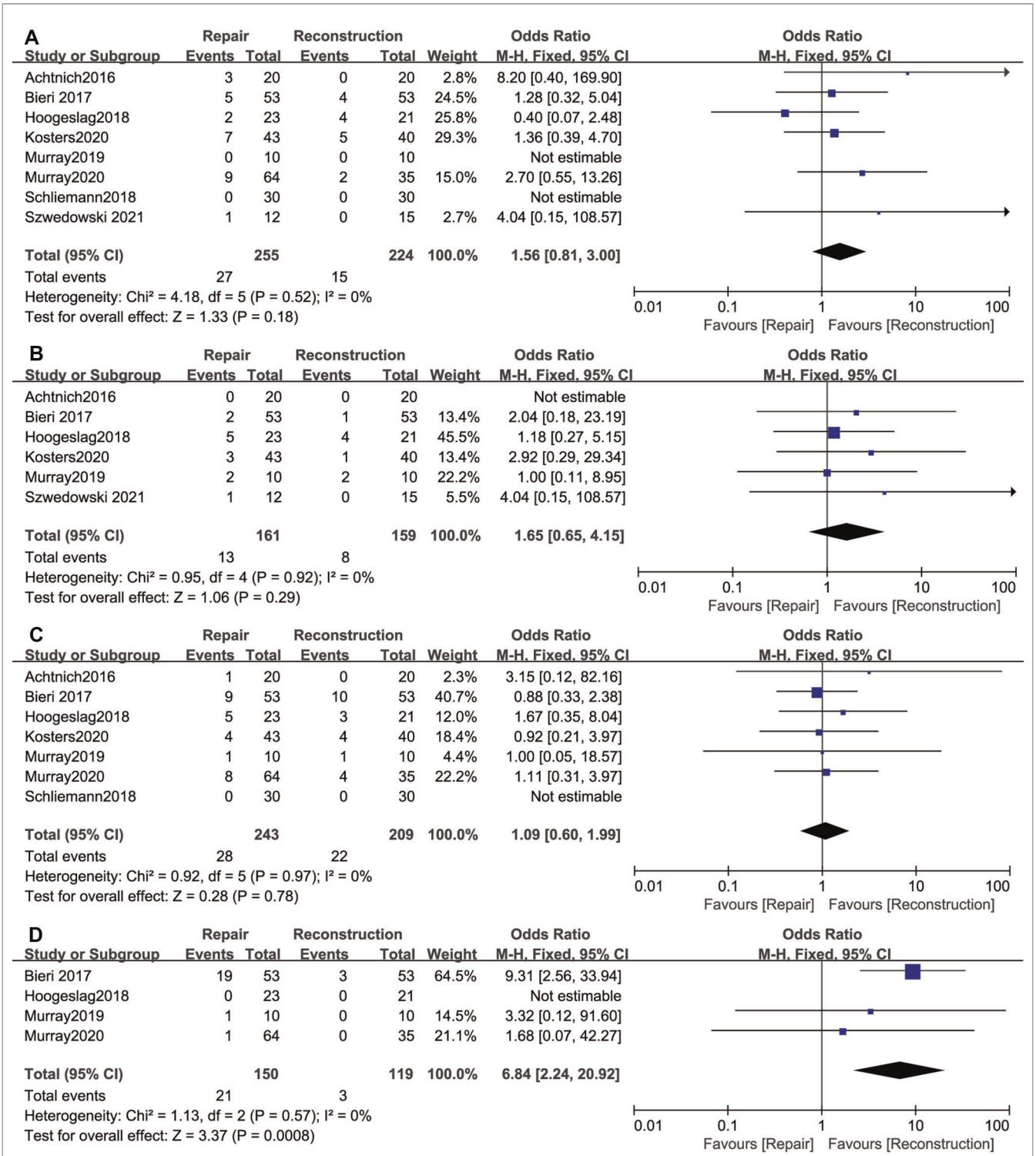

FIGURE 3 | Meta-analysis of the rates of (**A**) Failure; (**B**) Complications; (**C**) Reoperation rather than revision; (**D**) Hardware removal.

Two studies (14, 30) enrolled patients independent of the ACL rupture location, while other studies (11–13, 26, 28, 29, 31, 32) mainly included patients with ACL proximal rupture. As for the selection of autograft for ACL reconstruction, most studies (11–14, 26, 28, 32) used semitendinosus tendon, while the other studies (29–31) used hamstring tendon, patellar tendon, or quadriceps tendon. For the ACL repair techniques, primary SAR of the ACL was performed in 1 study (32), using one suture anchor to reattach the ACL remnant back to the femoral footprint. A total of 4 studies (11, 12, 14, 30) reported outcomes following primary ACL suture repair with DIS. After the remaining threads in the ACL stump were tensioned and the tibial stump was repositioned to the femoral footprint, an intraligamentary braid with cortical button fixation on the femoral side and an additional elastic link (a spring-in-screw mechanism) on the tibial side was introduced. A total of 2 studies (13, 26) by Murray et al. focused on patients treated with BEAR, involving suture repair of the ligament combined with a BEAR scaffold saturated with 5–10 ml autologous blood to bridge the gap between the ends of the torn ligament. In the other 3 studies (28, 29, 31), after completion of ACL suture repair, IBLA was achieved by adding FiberTape to the ACL substance, and fixed with a suture anchor perpendicular to the tibial cortex.

Failure, Complications, Reoperation Other than Revision, and Hardware Removal Rates

Failures were defined as postoperative recurrent instability of the ipsilateral knee joint regardless of the need for revision surgery. A total of 9 studies (11–14, 26, 28, 30, 32) reported failures after surgery, the result of which was 27/255 in the ACL repair group and 15/224 in the ACL reconstruction group (OR, 1.56; 95% CI, 0.81–3.00; $I^2 = 0\%$; $P = 0.18$) (**Figure 3A**).

A total of 6 studies (11, 12, 26, 28, 30, 32) reported postoperative complications, including superficial or deep infection, deep venous thrombosis (DVT), and pain at the tibial screw without the need for removal. There were 13/161 patients in the ACL repair group and 8/159 in the ACL reconstruction group (OR, 1.65; 95% CI, 0.65–4.15; $I^2 = 0\%$; $P = 0.29$) (**Figure 3B**).

Reoperations other than revision were defined as additional surgical interventions for ipsilateral knee disorders other than ACL retears, such as menisci lesions, synovitis, and arthrofibrosis. Reoperations were reported in 7 studies (11, 13, 14, 26, 30–32), and the result was 28/243 in the ACL repair group and 22/209 in the ACL reconstruction group (OR, 1.09; 95% CI, 0.60–1.99; $I^2 = 0\%$; $P = 0.78$) (**Figure 3C**).

Hardware removal rates were reported in 4 studies (11, 13, 26, 30), the result of which was 21/150 (19 in the DIS group, 2 in the BEAR group) in the ACL repair group and 3/119 (3 in the DIS group) in the ACL reconstruction group (OR, 6.84; 95% CI, 2.24–20.92; $I^2 = 0\%$; $P = 0.0008$) (**Figure 3D**).

AP Knee Laxity

A total of 6 studies (12–14, 26, 28, 32) reported ΔATT when stress was exerted on the knees, with a total of 170 cases in the ACL repair group and 144 cases in the ACL reconstruction group. The difference in postoperative ΔATT between the two groups was not statistically significant

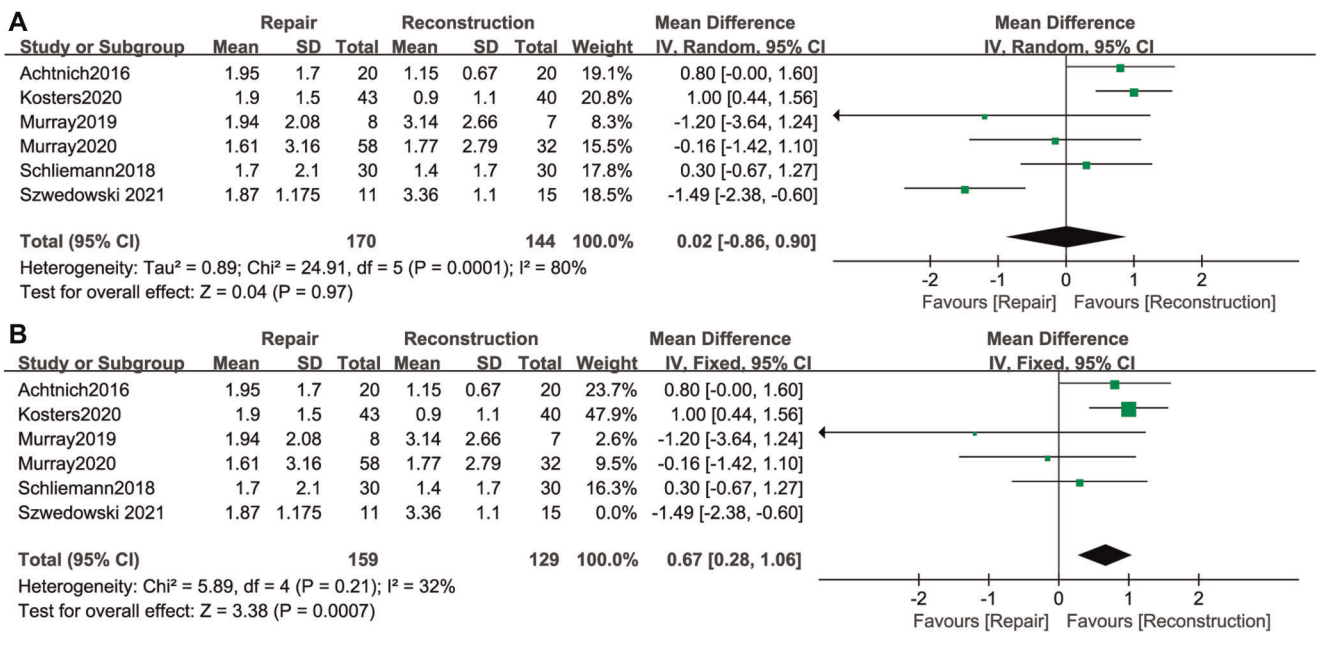

FIGURE 4 | Meta-analysis of AP knee laxity (**A**) ΔATT; (**B**) ΔATT (sensitivity analysis).

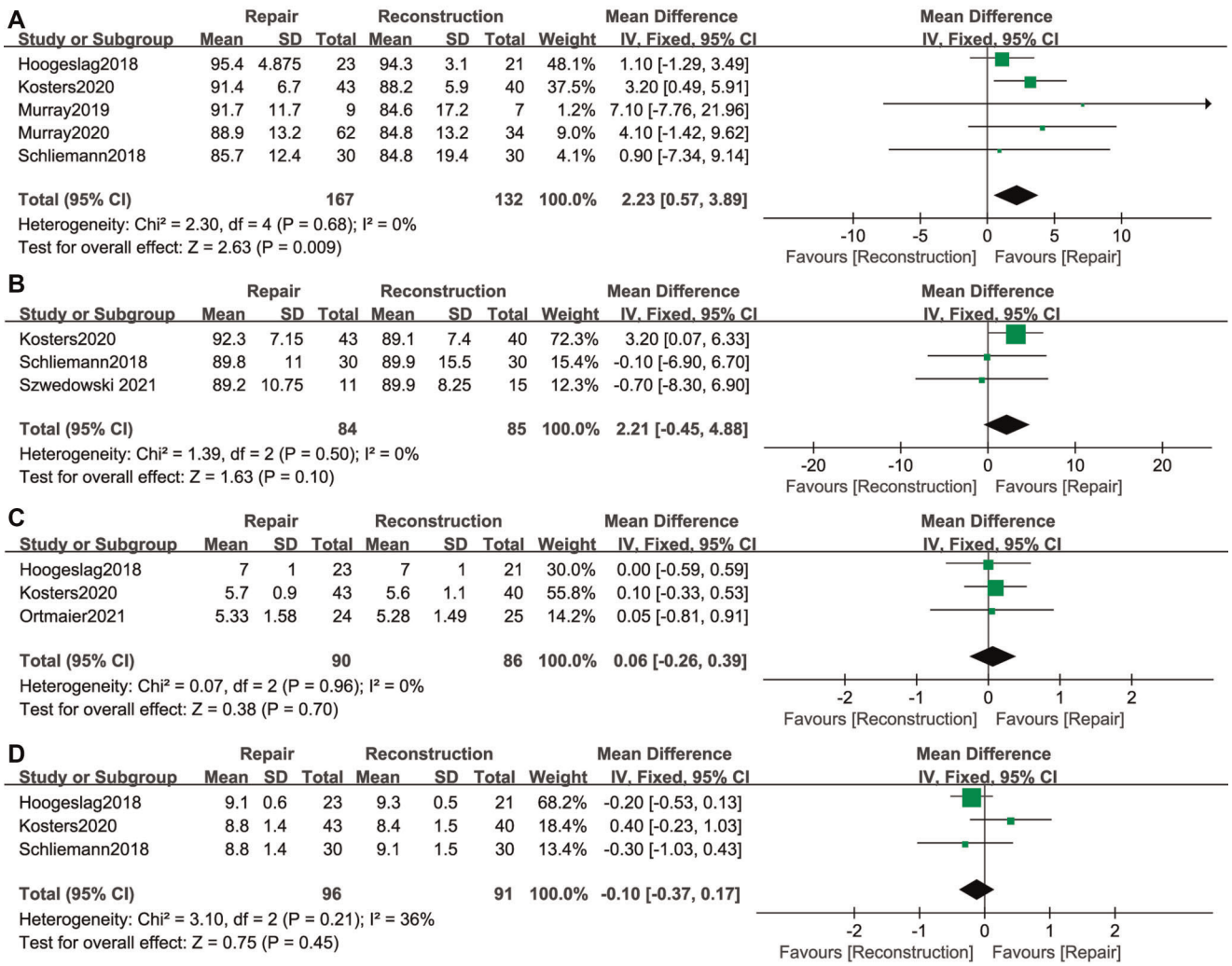

FIGURE 5 | Meta-analysis of patient-reported outcomes (**A**) IKDC score; (**B**) Lysholm score; (**C**) Tegner score; (**D**) Satisfaction.

(WMD, 0.02; 95% CI, −0.86–0.90; $I^2 = 80\%$; $P = 0.97$) (**Figure 4A**). Because the I^2 was relatively high, sensitivity analyses were performed by sequentially removing the included studies. After removing the study (28) by Szwedowski et al., the I^2 decreased dramatically, and knees with ACL repair showed significantly greater ΔATT (WMD, 0.56; 95% CI, 0.04–1.08; $I^2 = 32\%$; $P = 0.04$) (**Figure 4B**).

Patient-Reported Outcomes

The IKDC score was mentioned in 5 studies (11–14, 26), with 167 cases in the ACL repair group and 132 cases in the ACL reconstruction group. ACL repair showed an advantage in terms of the postoperative IKDC score over ACL reconstruction (WMD, 2.23; 95% CI, 0.57–3.89; $I^2 = 0\%$; $P = 0.009$) (**Figure 5A**).

The Lysholm score was reported in 3 studies (12, 14, 28), involving 84 patients in the ACL repair group and 85 patients in the ACL reconstruction group. There was no significant difference in the postoperative Lysholm score between the two groups (WMD, 2.21; 95% CI, −0.45–4.88; $I^2 = 0\%$; $P = 0.10$) (**Figure 5B**).

Tegner score was reported in 3 studies (11, 12, 31). There were 90 cases in the ACL repair group and 86 cases in the ACL reconstruction group. Compared to ACL reconstruction, ACL repair provided comparable improvements in the postoperative Tegner score (WMD, 0.06; 95% CI, −0.26–0.39; $I^2 = 0\%$; $P = 0.70$) (**Figure 5C**).

A total of 3 studies (11, 12, 14) reported satisfaction (range, 0–10; 0 representing unsatisfied and 10 representing very satisfied) after surgery. With 96 patients in the ACL repair group and 91 patients in the ACL reconstruction group, no significant difference regarding patient satisfaction after surgery was found between the two groups (WMD, −0.10; 95% CI, −0.37–0.17; $I^2 = 36\%$; $P = 0.45$) (**Figure 5D**).

Subgroup Analyses

Subgroup analyses for the primary outcome failure rates according to the rupture location and ACL repair technique were performed. No significant differences between different repair techniques and rupture locations were observed (**Table 3**). Subgroup analyses according to RCT design or non-RCT design were also conducted for all outcomes including failure, complications, reoperation other than revision, hardware removal rates, AP Knee laxity and patient-reported outcomes, but no significant differences or changes of outcomes were found according to the designs (**Table 4**). All the important outcomes are listed in **Table 5**.

DISCUSSION

This is the first meta-analysis to compare primary arthroscopic ACL repair to gold standard autograft ACL reconstruction. Different from previous results, this study revealed that, with a mean follow-up period from 12 to 36 months, patients who underwent arthroscopic ACL repair had statistically comparable outcomes of failure, complications, reoperation other than revision, Lysholm score, Tegner score, and satisfaction when compared with autograft ACL reconstruction. In addition, arthroscopic ACL repair showed subtle advantages in terms of the IKDC score but a higher rate of hardware removal and possibly greater ΔATT than ACL reconstruction.

ACL reconstruction has become the gold standard surgical treatment for ACL ruptures since the late 20th century. However, Van der List et al. (33) reviewed the evolutionary history of ACL surgical treatment modalities, and proposed that the paradigm shifting away from primary ACL repair was partly due to "unfortunate timing". Immature arthroscopic technology, a long period of immobilization after surgery (34, 35), and an unbefitting choice of patients (1) contributed to poor outcomes following open ACL repair. In 1991, Sherman et al. (1) reported an important finding that patients with proximal tears and good tissue quality tended to have significantly better clinical results than those with other types of tears. In 1993, Genelin et al. (36) performed open repair for patients with proximal ACL tears, and observed excellent outcomes at mid-term follow-up. Several studies (37–39) had already reported similar favorable outcomes in the early 1980s. A systematic review by Van der List et al. (40) found that open primary ACL repair yielded excellent outcomes in patients with proximal tears. These results suggested that primary arthroscopic ACL repair might play a role in treating proximal ACL tears. Previous systematic reviews (6, 7, 9, 10) revealed that ACL reconstruction led to better survivorship and improvement in postoperative function than arthroscopic ACL repair, but the use of internal bracing, biological augmentation, and dynamic stabilization had the potential to increase the success rate of repair. With some newly published studies enrolled, this is the first review to report that arthroscopic ACL repair is not inferior to autograft ACL reconstruction, and even has some advantages over reconstruction.

In theory, primary arthroscopic ACL repair techniques have some advantages over autograft ACL reconstruction. For example, proprioception should be maintained (41), less invasive, early range of motion (ROM) regain (24), native kinematics should be restored (42), donor site morbidity should be avoided, and osteoarthritis should be prevented (43). In addition, standard ACL reconstruction can be easily performed

TABLE 3 | Subgroup analysis of failure rates.

Variable	No. of studies	Failure rate		Risk ratio (95%CI)	*P* value
		Repair	Reconstruction		
ACL repair technique					
SAR	1	3/20	0/20	8.20 (0.40, 169.90)	0.17
BEAR	2	9/74	2/45	2.70 (0.55, 13.26)	0.22
IBLA	1	1/12	0/15	4.04 (0.15, 108.57)	0.41
DIS	4	14/149	13/144	1.02 (0.46, 2.29)	0.95
Main rupture location					
Independent	2	5/83	4/83	1.28 (0.32, 5.04)	0.73
Proximal	6	22/172	11/141	1.65 (0.78, 3.48)	0.19

SAR, suture anchor repair; BEAR, bridge-enhanced ACL repair; IBLA, internal brace ligament augmentation; DIS, dynamic intraligamentary stabilization.

TABLE 4 | Subgroup analyses according to study design for all outcomes.

Outcomes	No. of studies	Study design		OR/WMD, (95%CI), I^2		*P* value	
		RCT	Non-RCT	RCT	Non-RCT	RCT	Non-RCT
Failure	8	4	4	1.30, (0.57–2.92), 17%	2.17, (0.72–6.60), 0%	0.53	0.17
Complications	6	2	4	1.58, (0.47–5.33), 0%	1.75, (0.42–7.22), 0%	0.46	0.44
Reoperation other than revision	7	4	3	1.17, (0.52, 2.65), 0%	1.00, (0.41, 2.44), 0%	0.71	1.00
Hardware removal	4	2	2	1.68, (0.07, 42.27), NA	8.21, (2.48, 27.22), 0%	NA	0.0006
AP Knee laxity	6	3	3	0.55, (−0.13, 1.23), 43%	−0.54, (−2.34, 1.26), 86%	0.11	0.56
IKDC score	5	3	2	2.22, (0.51, 3.92), 0%	2.36, (−4.85, 9.56), 0%	0.01	0.52
Lysholm score	3	1	2	3.20, (0.07, 6.33), NA	−0.37, (−5.44, 4.70), 0%	NA	0.89
Tegner score	3	2	1	0.06, (−0.29, 0.42), 0%	0.05, (−0.81, 0.91), NA	0.72	NA
Satisfaction	3	3	0	−0.10, (−0.37, 0.17), 36%	NA	0.45	NA

OR, odds ratio; WMD, weighted mean difference; CI, confidence interval; RCT, randomized controlled trial; NA, not applicable; AP, anteroposterior; IKDC, International Knee Documentation Committee.

TABLE 5 | Summary of findings table.

Arthroscopic ACL repair for ACL ruptures
Patient or population: patients with ACL ruptures
Settings: in skeletally mature patients
Intervention: arthroscopic ACL repair
Comparison: autograft ACL reconstruction

Outcomes	Illustrative comparative risks[a] (95% CI)		Relative effect (95% CI)	No of Participants (studies)	Quality of the evidence (GRADE)	Comments
	Assumed risk Autograft ACL reconstruction	Corresponding risk Arthroscopic ACL repair				
Failure	**Study population** **67 per 1,000** **Moderate** **29 per 1,000**	**101 per 1,000** (55–177) **45 per 1,000** (24–82)	**OR 1.56** (0.81–3)	479 (8 studies)	⊕⊕⊕⊖ **moderate**	
Complication	**Study population** **50 per 1,000** **Moderate** **22 per 1,000**	**80 per 1,000** (33–180) **36 per 1,000** (14–85)	**OR 1.65** (0.65–4.15)	320 (6 studies)	⊕⊕⊕⊖ **moderate**	
Reoperation other than revision	**Study population** **105 per 1,000** **Moderate** **100 per 1,000**	**114 per 1,000** (66–190) **108 per 1,000** (62–181)	**OR 1.09** (0.6–1.99)	452 (7 studies)	⊕⊕⊕⊖ **moderate**	
Hardware removal	**Study population** **25 per 1,000** **Moderate** **0 per 1,000**	**150 per 1,000** (55–351) **0 per 1,000** (0 to 0)	**OR 6.84** (2.24–20.92)	269 (4 studies)	⊕⊕⊖⊖ **low**	
ΔATT		The mean ΔATT in the intervention groups was **0.02 higher** (0.86 lower to 0.9 higher)		314 (6 studies)	⊕⊖⊖⊖ **very low**	
IKDC score		The mean IKDC score in the intervention groups was **1.97 higher** (0.22–3.72 higher)		187 (3 studies)	⊕⊕⊖⊖ **low**	
Tegner score		The mean Tegner score in the intervention groups was **0.06 higher** (0.26 lower to 0.39 higher)		176 (3 studies)	⊕⊕⊖⊖ **low**	
Lysholm score		The mean Lysholm score in the intervention groups was **2.21 higher** (0.45 lower to 4.88 higher)		169 (3 studies)	⊕⊕⊖⊖ **low**	
Satisfaction		The mean satisfaction in the intervention groups was **0.1 lower** (0.37 lower to 0.17 higher)		187 (3 studies)	⊕⊕⊕⊕ **high**	

CI, *Confidence interval;* ***OR,*** *Odds ratio.*
GRADE Working Group grades of evidence.
High quality: *Further research is very unlikely to change our confidence in the estimate of effect.*
Moderate quality: *Further research is likely to have an important impact on our confidence in the estimate of effect and may change the estimate.*
Low quality: *Further research is very likely to have an important impact on our confidence in the estimate of effect and is likely to change the estimate.*
Very low quality: *We are very uncertain about the estimate.*
[a]*The basis for the* ***assumed risk*** *(e.g. the median control group risk across studies) is provided in footnotes. The* ***corresponding risk*** *(and its 95% confidence interval) is based on the assumed risk in the comparison group and the* ***relative effect*** *of the intervention (and its 95% CI).*

if primary ACL repair fails, while revision surgery for failed ACL reconstruction is much more complex. Studies included in our meta-analysis showed outcomes in favor of these advantages. Vermeijden et al. (29) observed that patients who underwent ACL repair had less awareness of their operated knees than those who underwent reconstruction at the 2- to 5- year follow-up, especially in patients older than 30 years, male patients and patients with a body mass index larger than 25. Schliemann et al. (14) reported that there were no significant differences between the two groups for knee kinematic and kinetic parameters at any time of the 6-month follow-up, but those in the DIS group had better early activity at weeks 2 and 3 after surgery. Ortmaier et al. (31) concluded that patients with IBLA had the same return-to-sports activity level as patients with classic ACL reconstruction at short-term follow-up. However, whether these advantages can be maintained at longer follow-up is unclear, and needs to be verified by further studies.

In this meta-analysis, potential disadvantages of ACL repair were also observed. ACL repair showed a significantly higher rate of hardware removal, mainly due to more requests for implant removal in patients with DIS repair. In the DIS procedure, the monobloc spring- screw is much bulkier than that used in ACL reconstruction, because it has to withstand a high tensile load. Although it is unnecessary to remove the spring- screw when ACL heals, Henle et al. (44) reported that nearly half of patients asked to remove it without any clinical need, while this procedure is uncommonly performed after ACL reconstruction (45, 46). This might be a disadvantage of DIS, but the hardware removal procedure is a minimally invasive operation under local anesthesia, yielding almost no negative effects on the recovery process.

Another potential disadvantage of ACL repair is AP knee laxity. Inconsistent results were reported in the included studies. The overall pooled outcome suggested no significant difference between ACL repair and reconstruction, but the heterogeneity was considered to be high ($I^2 = 80\%$). This heterogeneity might be caused by the differences in study design and ACL repair techniques. After removing the study by Szwedowski et al. (28), the I^2 decreased to 32%, and ACL repair showed significantly larger ΔATT than reconstruction. These results indicated that arthroscopic ACL repair might be related to greater AP knee laxity than reconstruction, but this asymptomatic laxity can only be observed when stress is exerted on the knees. Further studies should pay attention to long-term postoperative AP knee laxity in the two groups.

To further explore potential factors that would influence failure rates, we performed subgroup analyses. The rupture location and ACL repair technique are essential. Among the 10 included studies, 8 studies (11–13, 26, 28, 29, 31, 32) mainly enrolled patients with proximal ruptures, and the other 2 studies (14, 30) enrolled patients regardless of the rupture location. For ACL repair techniques, 1 study (32) used SAR, 2 studies (13, 26) used BEAR, 3 studies (28, 29, 31) used IBLA, and 4 studies (11, 12, 14, 30) used DIS. After subgroup analyses according to the rupture location and repair technique, no significant differences between different rupture locations and repair techniques were observed. However, these results should be interpreted with caution because the number of studies that enrolled patients regardless of the rupture location was only 2, and the number of studies using SAR and BEAR was also limited.

This study is not without limitation. First, although we enrolled more comparative studies than any other previous systematic review, the number of RCTs was only 4, and the majority of included studies were cohort and case–control studies. Second, due to a short history of arthroscopic ACL repair, the mean follow-up period of the included studies was not long enough (12–36 months). Third, the ACL repair techniques are varied, and differences in detailed surgical methods and the type of graft for ACL reconstruction were inevitable. However, the biomechanical effect of ACL reconstructions could be considered to be approximately equivalent. Fourth, we failed to conduct a meta-analysis of radiological results after surgery. Although good radiological results were observed, only 2 studies reported ACL healing examined by MRI and 1 study reported signs of osteoarthritis detected by X-rays at the 2-year follow up. Last, rehabilitation courses after surgery varied among studies, which could have influenced postoperative outcomes.

CONCLUSION

Compared to the autograft ACL reconstruction, arthroscopic ACL repair showed similar clinical outcomes, and even better functional performance in treating proximal ACL ruptures. ACL repair has a higher rate of hardware removal, and might be related to greater asymptomatic knee laxity. Arthroscopic ACL repair might be a viable option for patients with proximal ACL ruptures. However, limited by the amount of high-quality evidence (only 4 RCTs), we cannot draw a definite conclusion. More high-quality prospective trials comparing these two techniques are needed to confirm our findings.

DATA AVAILABILITY STATEMENT

The original contributions presented in the study are included in the article/supplementary material, further inquiries can be directed to the corresponding author/s.

AUTHOR CONTRIBUTIONS

JZ and XT conceived the idea; LP and TL: screened the literature, extracted data, assessed the methodological quality of the enrolled studies and performed the data analyses; TL and YL: prepared the tables and figures; all authors contributed to the writing and revisions. All authors contributed to the article and approved the submitted version.

FUNDING

This study was supported in part by grants from National Natural Science Foundation of China (82072514; Xin Tang) and Science & Technology Department of Sichuan Province (2021YFS0238; Xin Tang).

REFERENCES

1. Sherman MF, Lieber L, Bonamo JR, Podesta L, Reiter I. The long-term followup of primary anterior cruciate ligament repair. Defining a rationale for augmentation. *Am J Sports Med*. (1991) 19(3):243–55. doi: 10.1177/036354659101900307
2. Engebretsen L, Benum P, Fasting O, Mølster A, Strand T. A prospective, randomized study of three surgical techniques for treatment of acute ruptures of the anterior cruciate ligament. *Am J Sports Med*. (1990) 18 (6):585–90. doi: 10.1177/036354659001800605
3. Odensten M, Lysholm J, Gillquist J. Suture of fresh ruptures of the anterior cruciate ligament: a 5-year follow-up. *Acta Orthop Scand*. (1984) 55(3):270–2. doi: 10.3109/17453678408992354
4. Feagin Jr JA, Curl WW. Isolated tear of the anterior cruciate ligament: 5-year follow-up study. *Am J Sports Med*. (1976) 4(3):95–100. doi: 10.1177/036354657600400301
5. Heusdens CHW. ACL repair: a game changer or will history repeat itself? A critical appraisal. *J Clin Med*. (2021) 10(5):912. doi: 10.3390/jcm10050912
6. van Eck CF, Limpisvasti O, ElAttrache NS. Is there a role for internal bracing and repair of the anterior cruciate ligament? A systematic literature review. *Am J Sports Med*. (2018) 46(9):2291–8. doi: 10.1177/0363546517717956
7. Ahmad SS, Schreiner AJ, Hirschmann MT, Schröter S, Döbele S, Ahrend MD, et al. Dynamic intraligamentary stabilization for ACL repair: a systematic review. *Knee Surg Sports Traumatol Arthrosc*. (2019) 27(1):13–20. doi: 10.1007/s00167-018-5301-z
8. van der List JP, Vermeijden HD, Sierevelt IN, DiFelice GS, van Noort A, Kerkhoffs G. Arthroscopic primary repair of proximal anterior cruciate ligament tears seems safe but higher level of evidence is needed: a systematic review and meta-analysis of recent literature. *Knee Surg Sports Traumatol Arthrosc*. (2020) 28(6):1946–57. doi: 10.1007/s00167-019-05697-8
9. Nwachukwu BU, Patel BH, Lu Y, Allen AA, Williams 3rd. RJ, Anterior cruciate ligament repair outcomes: an updated systematic review of recent literature. *Arthroscopy*. (2019) 35(7):2233–47. doi: 10.1016/j.arthro.2019.04.005
10. Hoogeslag RAG, Brouwer RW, de Vries AJ, Boer BC, Huis In 't Veld R. Efficacy of nonaugmented, static augmented, and dynamic augmented suture repair of the ruptured anterior cruciate ligament: a systematic review of the literature. *Am J Sports Med*. (2020) 48(14):3626–37. doi: 10.1177/0363546520904690
11. Hoogeslag RAG, Brouwer RW, Boer BC, de Vries AJ, Huis In 't Veld R. Acute anterior cruciate ligament rupture: repair or reconstruction? Two-year results of a randomized controlled clinical trial. *Am J Sports Med*. (2019) 47(3):567–77. doi: 10.1177/0363546519825878
12. Kösters C, Glasbrenner J, Spickermann L, Kittl C, Domnick C, Herbort M, et al. Repair with dynamic intraligamentary stabilization versus primary reconstruction of acute anterior cruciate ligament tears: 2-year results from a prospective randomized study. *Am J Sports Med*. (2020) 48(5):1108–16. doi: 10.1177/0363546520905863
13. Murray MM, Fleming BC, Badger GJ, Freiberger C, Henderson R, Barnett S, et al. Bridge-enhanced anterior cruciate ligament repair is not inferior to autograft anterior cruciate ligament reconstruction at 2 years: results of a prospective randomized clinical trial. *Am J Sports Med*. (2020) 48(6):1305–15. doi: 10.1177/0363546520913532
14. Schliemann B, Glasbrenner J, Rosenbaum D, Lammers K, Herbort M, Domnick C, et al. Changes in gait pattern and early functional results after ACL repair are comparable to those of ACL reconstruction. *Knee Surg Sports Traumatol Arthrosc*. (2018) 26(2):374–80. doi: 10.1007/s00167-017-4618-3
15. Liberati A, Altman DG, Tetzlaff J, Mulrow C, Gøtzsche PC, Ioannidis JP, et al. The PRISMA statement for reporting systematic reviews and meta-analyses of studies that evaluate healthcare interventions: explanation and elaboration. *BMJ (Clin Res)*. (2009) 339:b2700. doi: 10.1136/bmj.b2700
16. Higgins LD, Taylor MK, Park D, Ghodadra N, Marchant M, Pietrobon R, et al. Reliability and validity of the international knee documentation committee (IKDC) subjective knee form. *Joint Bone Spine*. (2007) 74(6):594–9. doi: 10.1016/j.jbspin.2007.01.036
17. Lysholm J, Gillquist J. Evaluation of knee ligament surgery results with special emphasis on use of a scoring scale. *Am J Sports Med*. (1982) 10(3):150–4. doi: 10.1177/036354658201000306
18. Briggs KK, Lysholm J, Tegner Y, Rodkey WG, Kocher MS, Steadman JR. The reliability, validity, and responsiveness of the Lysholm score and Tegner activity scale for anterior cruciate ligament injuries of the knee: 25 years later. *Am J Sports Med*. (2009) 37(5):890–7. doi: 10.1177/0363546508330143
19. Higgins JP, Altman DG, Gøtzsche PC, Jüni P, Moher D, Oxman AD, et al. The Cochrane Collaboration's tool for assessing risk of bias in randomised trials. *BMJ (Clin Res)*. (2011) 343:d5928. doi: 10.1136/bmj.d5928
20. Slim K, Nini E, Forestier D, Kwiatkowski F, Panis Y, Chipponi J. Methodological index for non-randomized studies (minors): development and validation of a new instrument. *ANZ J Surg*. (2003) 73(9):712–6. doi: 10.1046/j.1445-2197.2003.02748.x
21. Gagliardi AG, Carry PM, Parikh HB, Traver JL, Howell DR, Albright JC. ACL repair with suture ligament augmentation is associated with a high failure rate among adolescent patients. *Am J Sports Med*. (2019) 47(3):560–6. doi: 10.1177/0363546518825255
22. Jonkergouw A, van der List JP, DiFelice GS. Arthroscopic primary repair of proximal anterior cruciate ligament tears: outcomes of the first 56 consecutive patients and the role of additional internal bracing. *Knee Surg Sports Traumatol Arthrosc*. (2019) 27(1):21–8. doi: 10.1007/s00167-018-5338-z
23. Sporsheim AN, Gifstad T, Lundemo TO, Engebretsen L, Strand T, Mølster A, et al. Autologous BPTB ACL reconstruction results in lower failure rates than ACL repair with and without synthetic augmentation at 30 years of follow-up: a prospective randomized study. *J Bone Joint Surg Am Vol*. (2019) 101(23):2074–81. doi: 10.2106/JBJS.19.00098
24. van der List JP, DiFelice GS. Range of motion and complications following primary repair versus reconstruction of the anterior cruciate ligament. *Knee*. (2017) 24(4):798–807. doi: 10.1016/j.knee.2017.04.007
25. Connolly PT, Zittel KW, Panish BJ, Rigor PD, Argintar EH. A comparison of postoperative pain between anterior cruciate ligament reconstruction and repair. *European J Orthop Surg Traumatol*. (2021) 31(7):1403–9. doi: 10.1007/s00590-020-02859-0
26. Murray MM, Kalish LA, Fleming BC, Flutie B, Freiberger C, Henderson RN, et al. Bridge-enhanced anterior cruciate ligament repair: two-year results of a first-in-human study. *Orthop J Sports Med*. (2019) 7(3):2325967118824356. doi: 10.1177/2325967118824356
27. Murray MM, Flutie BM, Kalish LA, Ecklund K, Fleming BC, Proffen BL, et al. The bridge-enhanced anterior cruciate ligament repair (BEAR) procedure: an early feasibility cohort study. *Orthop J Sports Med*. (2016) 4(11):2325967116672176. doi: 10.1177/2325967116672176
28. Szwedowski D, Paczesny Ł, Zabrzyński J, Gagat M, Domżalski M, Huri G, et al. The Comparison of clinical result between primary repair of the anterior cruciate ligament with additional internal bracing and anatomic single bundle reconstruction-A retrospective study. *J Clin Med*. (2021) 10(17):3948. doi: 10.3390/jcm10173948
29. Vermeijden HD, van der List JP, O'Brien R, DiFelice GS. Patients forget about their operated knee more following arthroscopic primary repair of the anterior cruciate ligament than following reconstruction. *Arthroscopy*. (2020) 36(3):797–804. doi: 10.1016/j.arthro.2019.09.041
30. Bieri KS, Scholz SM, Kohl S, Aghayev E, Staub LP. Dynamic intraligamentary stabilization versus conventional ACL reconstruction: a matched study on return to work. *Injury*. (2017) 48(6):1243–8. doi: 10.1016/j.injury.2017.03.004
31. Ortmaier R, Fink C, Schobersberger W, Kindermann H, Leister I, Runer A, et al. Return to sports after anterior cruciate ligament injury: a matched-pair analysis of repair with internal brace and reconstruction using hamstring or quadriceps tendons. *Sportverletz Sportschaden*. (2021) 35(1):36–44. doi: 10.1055/a-1019-0949
32. Achtnich A, Herbst E, Forkel P, Metzlaff S, Sprenker F, Imhoff AB, et al. Acute proximal anterior cruciate ligament tears: outcomes after arthroscopic suture anchor repair versus anatomic single-bundle reconstruction. *Arthroscopy*. (2016) 32(12):2562–9. doi: 10.1016/j.arthro.2016.04.031
33. van der List JP, DiFelice GS. Primary repair of the anterior cruciate ligament: a paradigm shift. *Surgeon*. (2017) 15(3):161–8. doi: 10.1016/j.surge.2016.09.006
34. Enneking WF, Horowitz M. The intra-articular effects of immobilization on the human knee. *J Bone Joint Surg Am*. (1972) 54(5):973–85. doi: 10.2106/00004623-197254050-00003

35. Millett PJ, Wickiewicz TL, Warren RF. Motion loss after ligament injuries to the knee. part I: causes. *Am J Sports Med*. (2001) 29(5):664–75. doi: 10.1177/03635465010290052401
36. Genelin F, Trost A, Primavesi C, Knoll P. Late results following proximal reinsertion of isolated ruptured ACL ligaments. *Knee Surg Sports Traumatol Arthrosc*. (1993) 1(1):17–9. doi: 10.1007/BF01552153
37. Strand T, Engesaeter LB, Mølster AO, Raugstad TS, Stangeland L, Stray O, et al. Knee function following suture of fresh tear of the anterior cruciate ligament. *Acta Orthop Scand*. (1984) 55(2):181–4. doi: 10.3109/17453678408992333
38. Marshall JL, Warren RF, Wickiewicz TL. Primary surgical treatment of anterior cruciate ligament lesions. *Am J Sports Med*. (1982) 10(2):103–7. doi: 10.1177/036354658201000208
39. Weaver JK, Derkash RS, Freeman JR, Kirk RE, Oden RR, Matyas J. Primary knee ligament repair–revisited. *Clin Orthop Relat Res*. (1985) 199:185–91. doi: 10.1097/00003086-198510000-00026
40. van der List JP, DiFelice GS. Role of tear location on outcomes of open primary repair of the anterior cruciate ligament: a systematic review of historical studies. *Knee*. (2017) 24(5):898–908. doi: 10.1016/j.knee.2017.05.009
41. Halinen J, Lindahl J, Hirvensalo E, Santavirta S. Operative and nonoperative treatments of medial collateral ligament rupture with early anterior cruciate ligament reconstruction: a prospective randomized study. *Am J Sports Med*. (2006) 34(7):1134–40. doi: 10.1177/0363546505284889
42. Fleming BC, Carey JL, Spindler KP, Murray MM. Can suture repair of ACL transection restore normal anteroposterior laxity of the knee? An ex vivo study. *J Orthop Res*. (2008) 26(11):1500–5. doi: 10.1002/jor.20690
43. Murray MM, Fleming BC. Use of a bioactive scaffold to stimulate anterior cruciate ligament healing also minimizes posttraumatic osteoarthritis after surgery. *Am J Sports Med*. (2013) 41(8):1762–70. doi: 10.1177/0363546513483446
44. Henle P, Röder C, Perler G, Heitkemper S, Eggli S. Dynamic Intraligamentary Stabilization (DIS) for treatment of acute anterior cruciate ligament ruptures: case series experience of the first three years. *BMC Musculoskelet Disord*. (2015) 16:27. doi: 10.1186/s12891-015-0484-7
45. Laxdal G, Kartus J, Ejerhed L, Sernert N, Magnusson L, Faxén E, et al. Outcome and risk factors after anterior cruciate ligament reconstruction: a follow-up study of 948 patients. *Arthroscopy*. (2005) 21(8):958–64. doi: 10.1016/j.arthro.2005.05.007
46. Fithian DC, Paxton EW, Stone ML, Luetzow WF, Csintalan RP, Phelan D, et al. Prospective trial of a treatment algorithm for the management of the anterior cruciate ligament-injured knee. *Am J Sports Med*. (2005) 33(3):335–46. doi: 10.1177/0363546504269590

Conflict of Interest: The authors declare that the research was conducted in the absence of any commercial or financial relationships that could be construed as a potential conflict of interest.

Publisher's Note: All claims expressed in this article are solely those of the authors and do not necessarily represent those of their affiliated organizations, or those of the publisher, the editors and the reviewers. Any product that may be evaluated in this article, or claim that may be made by its manufacturer, is not guaranteed or endorsed by the publisher.

Copyright © 2022 Pang, Li, Li, Li, Zhu, and Tang. This is an open-access article distributed under the terms of the Creative Commons Attribution License (CC BY). The use, distribution or reproduction in other forums is permitted, provided the original author(s) and the copyright owner(s) are credited and that the original publication in this journal is cited, in accordance with accepted academic practice. No use, distribution or reproduction is permitted which does not comply with these terms.

frontiers | Frontiers in Surgery

ORIGINAL RESEARCH
published: 02 May 2022
doi: 10.3389/fsurg.2022.881852

O-Arm-Navigated, Robot-Assisted Versus Conventional CT Guided Radiofrequency Ablation in Treatment of Osteoid Osteoma: A Retrospective Cohort Study

*Tian-Long Wang, Yi-Ping Luo, Zi-Fei Zhou, Jun-Feng Liu, Xiao-Dong Hou, Shao-Hua Jia and Long-Po Zheng**

Department of Orthopedics, Shanghai Tenth People's Hospital, School of Medicine, Tongji University, Shanghai, China

OPEN ACCESS

Edited by:
Paphon Sa-Ngasoongsong, Mahidol University, Thailand

Reviewed by:
Pramod P. Rao, Hôpital Pasteur, France
Kunal Bharat Gala, Tata Memorial Hospital, India

***Correspondence:**
Long-Po Zheng
dr.zheng@tongji.edu.cn

Specialty section:
This article was submitted to Orthopedic Surgery, a section of the journal Frontiers in Surgery

Received: *23 February 2022*
Accepted: *28 March 2022*
Published: *02 May 2022*

Citation:
Wang T-L, Luo Y-P, Zhou Z-F, Liu J-F, Hou X-D, Jia S-H and Zheng L-P (2022) O-Arm-Navigated, Robot-Assisted Versus Conventional CT Guided Radiofrequency Ablation in Treatment of Osteoid Osteoma: A Retrospective Cohort Study. Front. Surg. 9:881852. doi: 10.3389/fsurg.2022.881852

Background: Osteoid osteoma is a common benign bone tumor, and clinically there is severe local pain that typically worsens at night. The conventional CT-guided radiofrequency ablation (RFA) was widely used in the treatment of osteoid osteoma (OO), which could result in some radiation-related and imprecise complications due to the overdose of radiation exposure. This study aimed to compare the surgical effect of robot-assisted RFA with O-arm navigation and conventional CT-guided RFA in the treatment of OO.

Methods: Sixty-two patients who underwent robot-assisted RFA with O-arm navigation (Robot-RFA, $n = 24$) or CT-guided RFA (CT-RFA, $n = 38$) were included in this retrospective cohort study. The mean follow-up time was 23.3 months. The intra-operative data, primary technical success rate, visual analog scale (VAS), and post-operative complications were analyzed.

Results: Primary technical success was obtained in 23 patients who had robot-assisted RFA, and 35 patients who had conventional CT-guided RFA. One patient in Robot-RFA group and three patients in CT-RFA group with pain recurrence received repeat-RFA and had a secondary success. Mean operation time and dose of radiation exposure were lower in Robot-RFA group than that in CT-RFA group. The Robot-RFA group took fewer K-wire adjustment times for each patient than the CT-RFA group. There was a statistically significant difference in the mean operation time, dose of radiation exposure, and K-wire adjustment times between the groups ($p < 0.05$). No complications associated with the procedure were reported in the two groups during the follow-up period.

Conclusion: Robot-assisted RFA with O-arm navigation is a safer and more precise strategy in the treatment of osteoid osteoma with less operation time and radiation exposure compared with the conventional CT-guided radiofrequency ablation.

Keywords: osteoma, osteoid, imaging, three-dimensional, robotic surgical procedures, radiofrequency ablation, minimally invasion

INTRODUCTION

Osteoid osteoma (OO) is a common benign bone tumor accounting for approximately 5 % of all bone tumors (1). Adolescents and young adults are the most common groups diagnosed with this tumor. Clinically there is severe local pain that typically worsens at night. Though some patients have pain relief, most of them require surgical intervention for faster pain relief and to reduce the recurrence rate.

TABLE 1 | General information of the two groups.

Characteristics	Robot-RFA ($n = 24$)	CT-RFA ($n = 38$)	p-value
Age (years)	13.83 ± 7.23	16.58 ± 8.20	0.18
Gender (male/female)	11/13	17/21	0.60
Lesion localization			0.39
Femur	11	21	
Tibia	6	12	
Fibula	3	2	
Humerus	2	3	
iliac	2	0	
Lesion size (mm)	5.30 ± 1.23	5.14 ± 1.00	0.59
Preoperative VAS	7.17 ± 0.92	7.05 ± 0.98	0.63
Follow-up time (months)	22.00 ± 7.11	24.10 ± 6.40	0.23

Robot-RFA, Robot-assisted, O-arm-navigated radiofrequency ablation; CT-RFA, CT-guided radiofrequency ablation; VAS, visual analog scale.

Open surgery involves excessive removal of large portions of cortical bone, resulting in post-operative complications. As a thermal tissue destruction technique, radiofrequency ablation (RFA) has been applied to the treatment of OO with satisfactory results (2). Currently, percutaneous RFA with CT guidance for the treatment of OO has been widely applied (3). However, since OO is common among children, the multiple instances of radiation exposure in the CT-guided RFA process might put them at risk for future radiation-related complications (4).

Three-dimensional imaging system (O-arm) has been used for a wide variety of cases for its three-dimensional intra-operative imaging property (5). Besides, minimally invasive treatment technology represented by surgical robots has also become one of the main directions of surgical development (6). With precise, minimally invasive, and efficient properties, robot-assisted surgery has shown great potential in clinical applications (7).

The purpose of this study is to compare the clinical effects of robot-assisted RFA with O-arm navigation with the conventional CT-guided RFA.

MATERIALS AND METHODS

Patients

The retrospective analysis was approved by the ethics committee of our hospital. Patients who underwent robot-assisted RFA or CT-guided RFA treatment for OO between 2005 and 2018 were included. The inclusion criteria for this study were as follows: (1) Intra-operative pathological specimens were confirmed to be

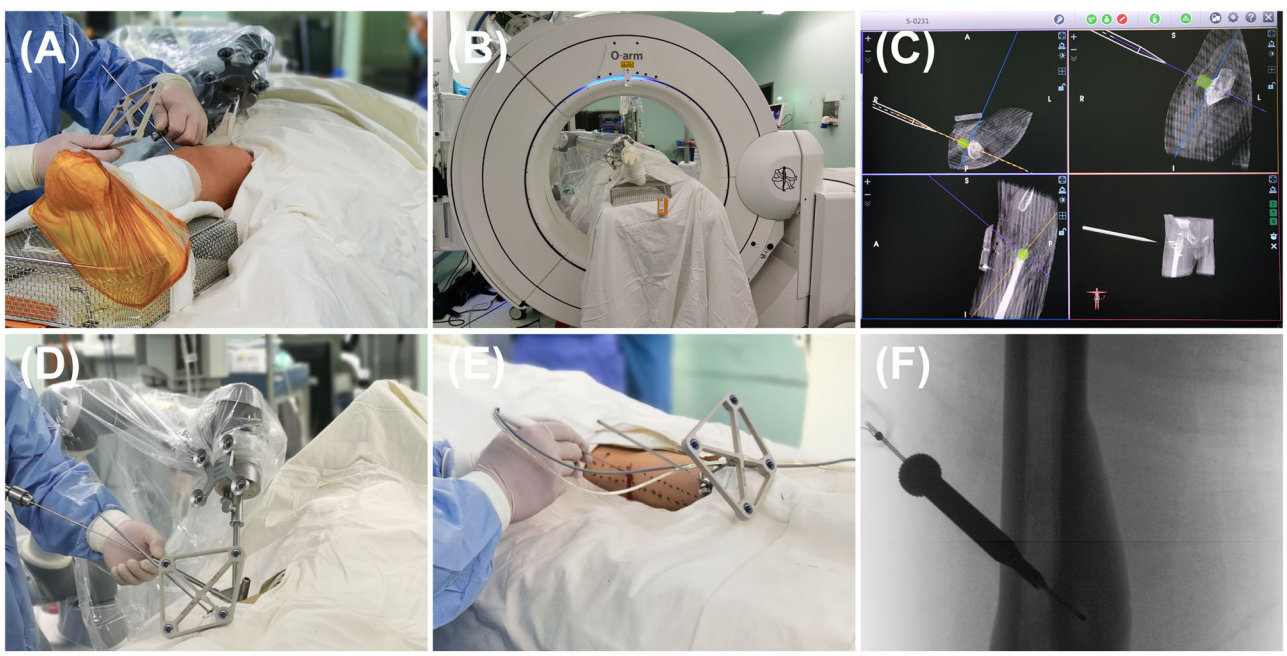

FIGURE 1 | The process of robot-assisted, O-arm-navigated radiofrequency ablation (RFA) of osteoid osteoma (OO). **(A)** Tracer installation for the real-time capture of patient's spatial location. **(B)** Collecting the preoperative three-dimensional (3D) radiographs data and uploading it to the robot system. **(C)** 3D reconstructions and surgical path planning in the robot system. **(D)** The movement of robot's arm and director following the planned path, followed by the penetration of K-wire into the nidus with the assistance of robot's director. **(E)** The placement of RF needle into the nidus following the path of K-wire. **(F)** The radiographs of the RF needle localization.

TABLE 2 | Comparative analysis of postoperative outcomes between the two groups.

Variables	Robot-RFA ($n = 24$)	CT-RFA ($n = 38$)	*p* value
Operation time (min)	40.29 ± 9.05	58.18 ± 12.47	<0 0.01*
DLP (mGy-cm^2)	436.25 ± 327.66	776.05 ± 474.58	<0 0.01*
K-wire adjustment times	0.21 ± 0.41	1.45 ± 0.80	<0 0.01*
Primary technical success rate	95.8 (23/24)	92.1% (35/38)	0.56
VAS (24 h)	1.29 ± 1.12	1.18 ± 1.18	0.52
Lesion size (6th month, mm)	3.40 ± 1.01	2.68 ± 0.75	0.43

Robot-RFA, Robot-assisted, O-arm-navigated radiofrequency ablation; CT-RFA, CT-guided radiofrequency ablation; DLP, dose-length product; VAS, visual analog scale.
**Statistically significant.*

OO; (2) all patients were diagnosed with OO based on clinical findings and radiology studies; (3) following time >12 months; and (4) no prior surgical treatment. Finally, a total of 62 patients with pain as the most distinct symptom were involved in this study (Robot-RFA group, $n = 24$; CT-RFA group, $n = 38$). The mean follow-up time was 22.00 ± 7.11 months (range, 12–36) for the Robot-RFA group and 24.10 ± 6.40 months (range, 12–39) for the CT-RFA group. The general information of the two groups is displayed in **Table 1**.

Surgical Intervention

In the Robot-RFA group, patients were placed in a prone or supine position on a carbon-fiber bed under general anesthesia. Before the surgery, the skin was sterilized based on the standard process, and machines including an O-arm (Medtronic, USA) and a robot (TINAVI Medical Technologies, China) were wrapped with sterile sleeves. According to the anatomical location of the lesion, the optical tracer was fixed at a proper position on the patient (**Figure 1A**). The patient was then scanned by the O-arm to locate the lesion (**Figure 1B**). The obtained three-dimensional (3D) images were then created and uploaded to the robot imaging system. The needle path was then designed according to the 3D images.

Next, the surgeon simulated the movement of the manipulator's arm in the robot operating system based on the designed path and confirmed that the angle and direction were correct (**Figure 1C**). According to the designed path, a very small skin incision of about 3 mm was made to avoid damage of soft tissue caused by tissue entanglement when the K-wire was inserted, and then a K-wire penetrated through the guide sleeve of the director into the nidus (**Figure 1D**). The position of the needle was then adjusted according to the repeat O-arm scan images. An RF needle (RITA Angiodynamics Inc., USA) was then advanced following the path of the K-wire (**Figure 1E**). When the needle came into the lesion as planned, a repeat scan was performed to confirm the location of the RF needle (**Figure 1F**), after which the RFA was performed. At last, the incision was sutured with nylon sutures, and the patient's skin was examined for burns or other superficial complications.

In the CT-guided percutaneous excision, the localization of the nidus was first determined by the preoperative 3D CT scan at a thickness of 1 mm, and then a K-wire was advanced to the nidus according to the experience of the operator. The K-wire could be adjusted several times to achieve an appropriate angle and direction in order to place the tip of K-wire in the center of the nidus under the guidance of CT sweep (15, 16). All lesions in the two groups were treated with RFA at 90° for 6–8 min with gradual increase of heat.

Data Collection and Assessment

Intra-operative data included operation time, dose-length product (DLP), and mean K-wire adjustment times. Operative time was defined as the time from skin sterilization to skin suture. DLP was defined as the total absorbed dose of radiation exposure, which is useful and easily acquired for comparing exam doses and measured in milligray-centimeter (mGy-cm^2) (17). Mean K-wire adjustment times represent the accuracy of surgery.

Post-operative data included primary technical success rate, visual analog scale (VAS), lesion size, post-operative complications, and radiological outcomes. VAS was applied to assess the pain relief before and after surgery at 24 h. The lesion size was measured according to the radiological images during the follow-up time. Nerve palsy and infection were recorded as the complications. The cortical changes were also noted.

Statistical Analysis

The collected data were analyzed by the SPSS 25.0 software (SPSS Inc., Chicago, USA). Continuous variables are expressed as Mean ± standard deviation (SD) and categorical variables are expressed as the frequency with percentages. Student *t*-test was performed to compare the data of the two independent groups. A Chi-square test was performed to analyze the categorical variables from the independent groups. Fisher's exact test was performed if an expected number was <5. A *p*-value of < 0.05 was considered statistically significant.

RESULTS

General Information of the Two Groups

Data of 62 patients with OO (24 patients received the robot-assisted RFA and 38 patients received the CT-guided RFA) were collected in this study. The mean age was 13.83 ± 7.23 years in the Robot-RFA group and 16.58 ± 8.20 years in the CT-RFA group. The Robot-RFA group comprised 11 males and 13 females, and the CT-RFA group comprised 17 males and 21 females.

Most of the lesions were located at the femur and tibia, while the other localizations included the fibula, the humerus, the iliac, and the calcaneus. The pre-operative mean lesion size was 5.30 ± 1.23 mm in the Robot-RFA group and 5.14 ± 1.00 mm in the CT-RFA group. The mean pre-operative VAS was 7.17 ± 0.92 in the Robot-RFA group and 7.05 ± 0.98 in the CT-RFA group. All patients in the two groups were followed up for at least 12 months.

In conclusion, there was no statistically significant difference in the age, gender, localization of lesion, pre-operative lesion size, pre-operative VAS score, and follow-up time between the two groups (**Table 1**).

TABLE 3 | Summary of some reported studies on using of O-arm or CT-guided RFA for the treatment of OO.

Authors	Patients	Type of guidance	Mean DLP (mGy-cm2)	Recurrence	Complications	References
Wang et al. (this study)	24	O-arm	436.25	1	0	
Kadar et al.	52	O-arm	544.7	3	1	(8)
Cheng et al.	23	O-arm	446.6	2	0	(9)
Cheng et al.	36	CT	1058.8	3	1	(9)
Tsalafoutas et al.	14	CT	1976	/	/	(10)
Renhitz et al.	102	CT	751.55	1	0	(11)
Cuesta et al.	200	CT	/	4	3	(12)
Lassalle et al.	126	CT	/	4	4	(13)
Rimondi et al.	557	CT	/	24	5	(14)

RFA, radiofrequency ablation; CT, computer tomography; DLP, dose-length product; OO, osteoid osteoma.

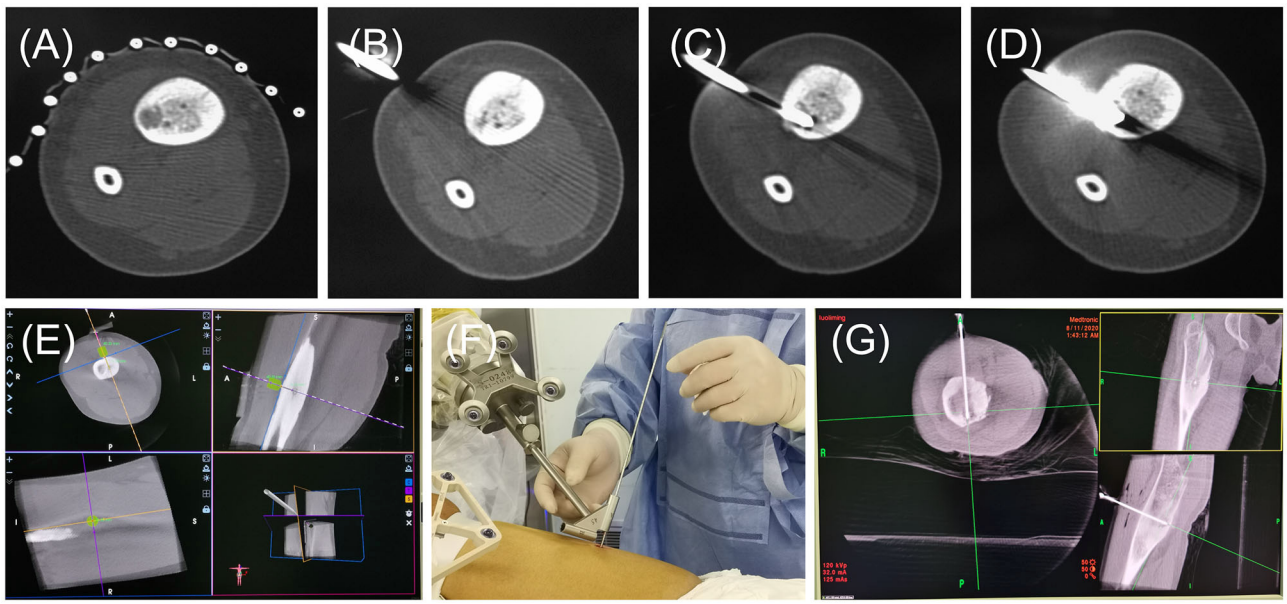

FIGURE 2 | The radiographs of general operative procedures of the CT-RFA group and Robot-RFA group. **(A)** Pre-operative CT scan. **(B–D)** Radiographs of CT scan for the K-wire localization and confirmation. **(E)** Guide pin path planning. **(F)** K-wire insertion follows the path of sleeve of the robot. **(G)** Location confirmation of the K-wire.

Intra-Operative and Post-operative Measurements

The operation time was 40.29 ± 9.05 min in the Robot-RFA group, while it was 58.18 ± 12.47 min in the CT-RFA group. The operation time was shorter in the Robot-RFA group ($p < 0.05$). Meanwhile, less radiation exposure was observed in the Robot-RFA group. The DLP was 436.25 ± 327.66 mGy-cm^2 in the Robot-RFA group and 776.05 ± 474.58 mGy-cm^2 in the CT-RFA group ($p < 0.05$). In addition, the K-wire adjustment times was were only 0.21 ± 0.41 times in the Robot-RFA group, while 1.45 ± 0.80 times in the CT-RFA group ($p < 0.05$).

The primary technical success rate was 95.8% (23/24) in the Robot-RFA group and 92.1% (35/38) in the CT-RFA group. Patients with pain recurrence received repeat-RFA and had a secondary success rate of 100%. The VAS score at 24 h after surgery was 1.29 ± 1.12 in the Robot-RFA group and 1.18 ± 1.18 in the CT-RFA group. The mean lesion size of OO was 3.40 ± 1.01 mm in the Robot-RFA group and 2.68 ± 0.75 mm in the CT-RFA group at 6 months. However, the primary technical success rate, VAS score at 24 h, and lesion size at 6 months after surgery showed no statistical significance between the two groups ($p > 0.05$). No complications associated with the procedure were reported in the two groups during the follow-up period.

In conclusion, there was a statistically significant difference in the operation time, dose of radiation exposure, and mean K-wire adjustment times between the two groups. No significant difference was observed in the primary technical success rate, VAS score at 24 h, and lesion size at 6 months after surgery (**Table 2**).

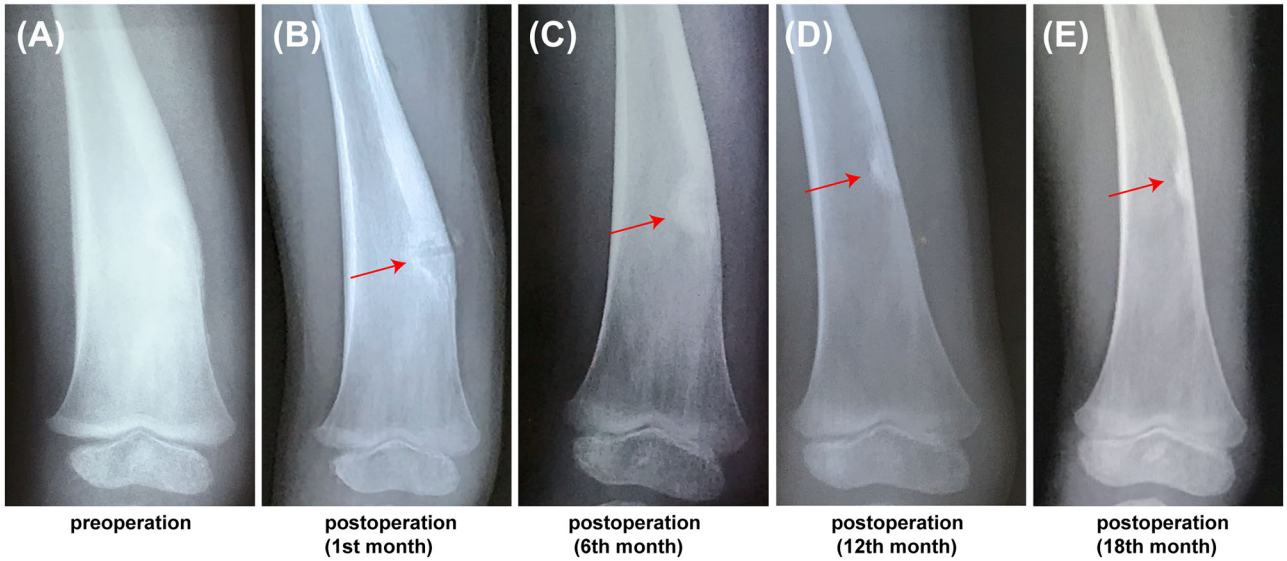

FIGURE 3 | The follow-up radiographs of a 3-year-old child confirmed with OO using the robot-assisted surgery. **(A)** Pre-operative X-ray image showed showing the thickening of cortex. **(B)** PostoperativePost-operative X-ray image at 1st month, **(C)** Post-operative X-ray image at 6th month. **(D)** Post-operative X-ray image at 12th month. **(E)** Post-operative X-ray image at 18th month (red arrow, the nidus).

DISCUSSION

Radiofrequency ablation with CT-guided navigation represented the most popular minimally invasive technique for the treatment of OO, and has been performed for several years. Much attention has also been paid to robot-assisted surgery and 3D navigation as novel techniques in clinical treatment. In this retrospective study, we compared the surgical effect of robot-assisted RFA with O-arm navigation with the conventional CT-guided RFA in the treatment of OO. Though the primary technical success rate, post-operative VAS score, and post-operative lesion size showed no significant difference between the two groups, the operation time, dose of radiation exposure, and accuracy of surgery showed that robot-assisted RFA is superior to conventional CT-guided RFA.

The most recommended and effective treatment for OO is surgical excision, which could completely remove the lesion and surrounding bone (18). However, the excessive removal of large portions of cortical bone in open surgery destroys the stability of the bone, resulting in a higher incidence of avascular necrosis and post-operative fractures (19). High post-operative complications have also taken place in open excision surgery for OO because of the inaccurate localization of the nidus (20). Over the decades, minimally invasive surgery represented by the CT-guided surgery and percutaneous RFA has become the trend worldwide in the treatment of OO (21). Many studies have demonstrated that CT-guided RFA is an acceptable strategy with minimal damage and fewer complications in the treatment of OO compared with open excision surgery (12). However, with the increasing usage of such CT guidance, radiation exposure has become a main concern, especially for young children, who are most susceptible to this disease. Some studies also highlighted the importance of minimizing radiation exposure in the adolescent population (22, 23). Nowadays, more attention is being paid to robot-assisted surgery and 3D navigation for their great potential in clinical application (24). Compared with the CT scan, O-arm can decrease the radiation exposure to both surgical staff and patients (25, 26). Kadar et al. (8) reported their experience in 52 O-arm-guided RFA procedures and measured a mean DLP of 544.7 mGy-cm^2, which was significantly lower than previously reported data regarding DLP of ablations with conventional CT guidance. Cheng et al. (9) have compared the use of an O-arm navigated system with conventional CT guidance for OO ablation in a case-control study, and a significant difference in DLP also existed between the two groups. Tsalafoutas et al. (10) performed CT-guided RFA in 14 cases with a mean DLP of 1976 mGy-cm^2. Renhitz et al. (11) performed CT-guided RFA in 102 cases with a mean DLP of 751.55 mGy-cm^2. All the CT-guided RFA showed a much higher radiation exposure than that of the reported O-arm navigated RFA (**Table 3**). Most of these reported studies showed a low recurrence and complication rate with variations (12, 13), which may be explained by the difference in localization of the lesion and the surgeon's experience in operation. Rimondi et al. (14) retrospectively studied 557 patients who received CT-guided RFA, and found that the clinical results were greatly improved *via* regulating the temperature and time of RFA. In recent years, robot-assisted surgery is also an evolving technology that has been given more attention in orthopedics. Due to the advantages of precise operation and greater reduction of radiation exposure, robot-assisted surgery in orthopedics has been performed in our institution, including spinal fractures, limb fractures, pelvic fractures, and OO, which have received excellent clinical results as reported (27).

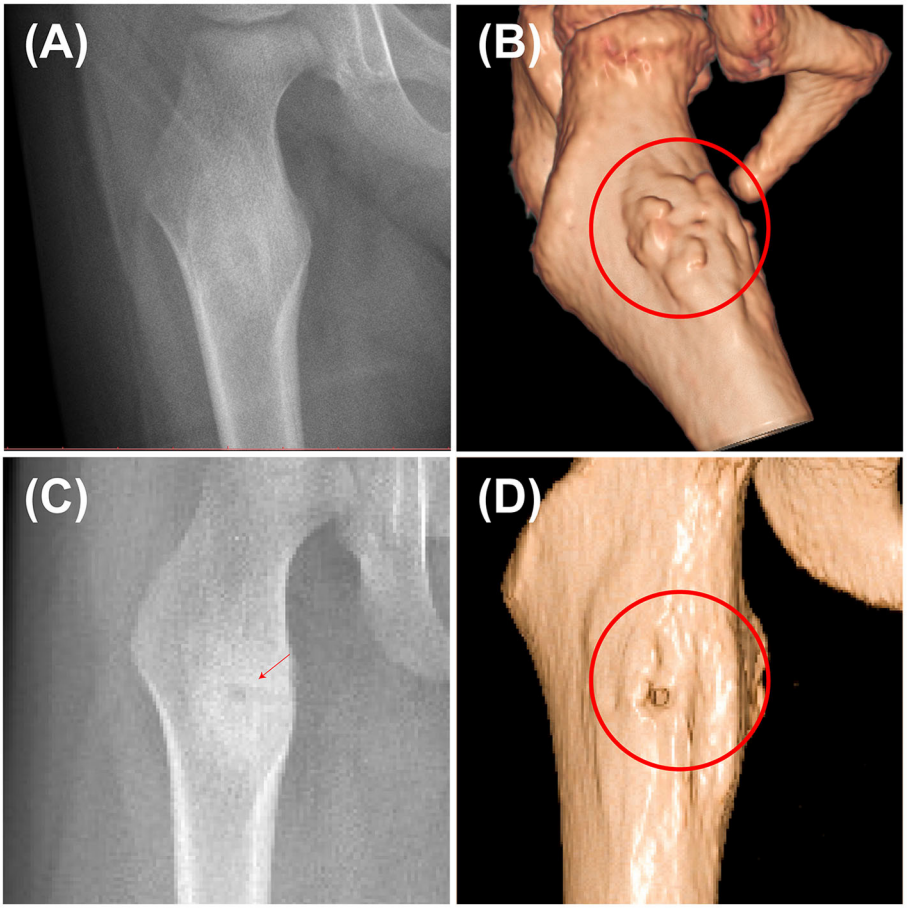

FIGURE 4 | Pre-operative and post-operative radiographs of a 3-year-old child confirmed with OO using the robot-assisted surgery. **(A)** Pre-operative X-ray image of the nidus. **(B)** Pre-operative 3D reconstruction image showing the thickening of the nidus. **(C)** Post-operative X-ray image at 3rd month. **(D)** Post-operative 3D reconstruction at 3rd month showing that the nidus greatly shrank (red arrow and cycle, the nidus).

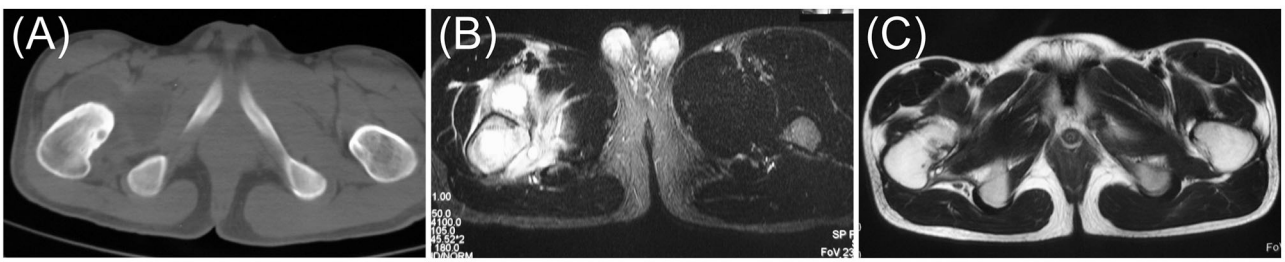

FIGURE 5 | Pre-operative and post-operative radiographs of a 17-year-old male confirmed with OO using the robot-assisted surgery. **(A)** Pre-operative axial CT image. **(B)** Pre-operative axial MR image. **(C)** Post-operative axial MR image at 12th month (red arrow, the nidus).

In this study, the accuracy and safety of robot-assisted RFA with O-arm navigation in the treatment of OO have been confirmed. The operation time was shorter in the Robot-RFA group compared with the CT-guided RFA group, which was mainly due to the assistance of the robot system. In the CT-guided RFA group, the operator could only insert the K-wire and sleeve based on the pre-operative CT scan (**Figure 2A**), which could result in the requirement to adjust the path several times during the operation with the navigation of CT scan (**Figures 2B–D**). The time of navigation will be much more for less experienced operators. However, with the assistance of robot system in the robot-assisted group to

design the needle path according to the 3D images (**Figure 2E**), multiple adjustments of K-wire were unnecessary, and the K-wire could be inserted to a perfect region (**Figures 2F,G**). Compared with CT-guided RFA, the robot-assisted surgery was more efficient and accurate in the treatment of OO, which could further reduce the dose of radiation exposure. As a result, mean radiation exposure in 24 procedures of robot-assisted RFA was 436.25 $mGycms^2$, which was much lower than conventional CT-guided RFA and also lower than the data reported using O-arm guided RFA without robot assistance (8). Meanwhile, this technique could provide excellent clinical results with significant pain relief, and no complications were observed as in conventional CT-guided RFA. Shown in **Figure 3**, is a representative case of a 3-year-old child confirmed with OO and treated with robot-assisted RFA with O-arm navigation. Pain relief was observed to a great extent after operation, and radiographs showed that the nidus gradually shrank and achieved advanced bone healing during the follow-up period (**Figures 3B–E**). A recent case who received robot-assisted RFA with O-arm navigation is shown in **Figure 4**. The pre-operative radiographs and 3D reconstruction showed a small nidus with cortical thickening (**Figures 4A,B**). Specifically, at a follow-up of 3 months, excellent pain relief was achieved and the size decreased markedly according to the post-operative X-ray and 3D reconstruction (**Figures 4C,D**). Another case confirmed with OO showed increased contrast enhancement of the nidus and the surrounding tissue edema in the MR image (**Figures 5A,B**). The accompanying tissue edema was greatly decreased (**Figure 5C**) after treatment with robot-assisted surgery on follow-up examination.

Finally, a few limitations existed in this study. Firstly, the investigation was performed at one single center with a small group of patients. Secondly, the patients in the two groups were retrospectively collected during different time intervals. Third, it is a retrospective analysis without similar lesion locations in these patients. Finally, a cost analysis was not performed, although the cost was higher when the robot surgery was applied.

CONCLUSIONS

This study favors the results that robot-assisted RFA with O-arm navigation is a more accurate and safer technique with less operation time and radiation exposure compared with the conventional CT-guided RFA. The K-wire adjustment times that represent the accuracy of surgery in this present investigation demonstrated that robot-assisted RFA is a much more efficient and safe technique. To our knowledge, we also believe that this technique has a great potential to further increase the accuracy of surgery and also reduce the expenses of patients by increasing the operator's proficiency in this technique.

DATA AVAILABILITY STATEMENT

The original contributions presented in the study are included in the article/supplementary material, further inquiries can be directed to the corresponding author.

ETHICS STATEMENT

The study was approved by the Ethics Committee of the Shanghai Tenth People's Hospital, No. SHSY-IEC-4.1/21-47/01. All the methods were performed in accordance with the relevant guidelines and regulations, such as the Declaration of Helsinki. Due to the retrospective design of the study, the written informed consent was waived by the Ethics Committee of Shanghai Tenth People's Hospital and all data were anonymized.

AUTHOR CONTRIBUTIONS

T-LW designed the study and wrote the article. All authors contributed to the article and approved the submitted version.

FUNDING

This research was funded by the Science and Technology Commission of Shanghai Municipality, grant number: 21ZR1450000.

REFERENCES

1. Boscainos PJ, Cousins GR, Kulshreshtha R, Oliver TB, Papagelopoulos PJ. Osteoid osteoma. *Orthopedics*. (2013) 36:792–800. doi: 10.3928/01477447-20130920-10
2. Motamedi D, Learch TJ, Ishimitsu DN, Motamedi K, Katz MD, Brien EW, et al. Thermal ablation of osteoid osteoma: overview and step-by-step guide. *Radiographics*. (2009) 29:2127–41. doi: 10.1148/rg.297095081
3. Yang WT, Chen WM, Wang NH, Chen TH. Surgical treatment for osteoid osteoma—experience in both conventional open excision and CT-guided mini-incision surgery. *J Chin Med Assoc*. (2007) 70:545–50. doi: 10.1016/S1726-4901(08)70058-3
4. Brody AS, Frush DP, Huda W, Brent RL. Radiation risk to children from computed tomography. *Pediatrics*. (2007) 120:677–82. doi: 10.1542/peds.2007-1910
5. Costa F, Ortolina A, Attuati L, Cardia A, Tomei M, Riva M, et al. Management of C1-2 traumatic fractures using an intraoperative 3D imaging-based navigation system. *J Neurosurg Spine*. (2015) 22,128-33. doi: 10.3171/2014.10.SPINE14122
6. Leung KS, Tang N, Cheung LW, Ng E. Image-guided navigation in orthopaedic trauma. *J Bone Joint Surg Br*. (2010) 92:1332–7. doi: 10.1302/0301-620X.92B10.24594
7. Yongqi L, Dehua Z, Hongzi W, Ke Z, Rui Y, Zhou F, et al. Minimally invasive versus conventional fixation of tracer in robot-assisted pedicle screw insertion surgery: a randomized control trial. *BMC Musculoskelet Disord*. (2020) 21:208. doi: 10.1186/s12891-020-03239-9
8. Kadar A, Netzer D, Schermann H, Gortzak Y, Dadia S, Kollander Y, et al. 3D imaging and stealth navigation instead of CT guidance for radiofrequency ablation of osteoid osteomas: a series of 52 patients. *BMC Musculoskelet Disord*. (2019) 20:579. doi: 10.1186/s12891-019-2963-8
9. Cheng EY, Naranje SM, Ritenour ER. Radiation dosimetry of intraoperative cone-beam compared with conventional CT for radiofrequency ablation of osteoid osteoma. *J Bone Joint Surg Am*. (2014) 96:735–42. doi: 10.2106/JBJS.M.00874

10. Tsalafoutas IA, Tsapaki V, Triantopoulou C, Gorantonaki A, Papailiou J. CT-Guided interventional procedures without CT fluoroscopy assistance: patient effective dose and absorbed dose considerations. *Am J Roentgenol*. (2007) 188:1479–84. doi: 10.2214/AJR.06.0705
11. Rehnitz C, Sprengel SD, Lehner B, Ludwig K, Omlor G, Merle C. CT-guided radiofrequency ablation of osteoid osteoma: correlation of clinical outcome and imaging features. *Diagn Interv Radiol*. (2013) 19:330–9. doi: 10.5152/dir.2013.096
12. Esteban Cuesta H, Martel Villagran J, Bueno Horcajadas A, Kassarjian A, Rodriguez Caravaca G. Percutaneous radiofrequency ablation in osteoid osteoma: tips and tricks in special scenarios. *Eur J Radiol*. (2018) 102:169–75. doi: 10.1016/j.ejrad.2018.03.008
13. Lassalle L, Campagna R, Corcos G, Babinet A, Larousserie F, Stephanazzi J, et al. Therapeutic outcome of CT-guided radiofrequency ablation in patients with osteoid osteoma. *Skeletal Radiol*. (2017) 46:949–56. doi: 10.1007/s00256-017-2658-x
14. Rimondi E, Mavrogenis AF, Rossi G, Ciminari R, Malaguti C, Tranfaglia C, et al. Radiofrequency ablation for non-spinal osteoid osteomas in 557 patients. *Eur Radiol*. (2012) 22:181–8. doi: 10.1007/s00330-011-2240-1
15. Daniilidis K, Martinelli N, Gosheger G, Hoell S, Henrichs M, Vogt B, et al. Percutaneous CT-guided radio-frequency ablation of osteoid osteoma of the foot and ankle. *Arch Orthop Trauma Surg*. (2012) 132:1707–10. doi: 10.1007/s00402-012-1614-4
16. Alemdar C, Çaçan MA, Dusak A, Özkul E, Atiç R, Kapukaya A. A comparison of percutaneous trephine excision and open surgery in the treatment of osteoid osteoma. *Int Orthop*. (2016) 40:1481–7. doi: 10.1007/s00264-015-3044-8
17. Huda W, Mettler FA. Volume CT dose index and dose-length product displayed during CT: what good are they? *Radiology*. (2011) 258:236–42. doi: 10.1148/radiol.10100297
18. Rosenthal DI, Hornicek FJ, Wolfe MW, Jennings LC, Gebhardt MC, Mankin HJ. Percutaneous radiofrequency coagulation of osteoid osteoma compared with operative treatment. *J Bone Joint Surg Am*. (1998) 80,815–21. doi: 10.2106/00004623-199806000-00005
19. Marwan YA, Abatzoglou S, Esmaeel AA, Alqahtani SM, Alsulaimani SA, Tanzer M, Turcotte RE. Hip arthroscopy for the management of osteoid osteoma of the acetabulum: a systematic review of the literature and case report. *BMC Musculoskelet Disord*. (2015) 16:318. doi: 10.1186/s12891-015-0779-8
20. Campanacci M, Ruggieri P, Gasbarrini A, Ferraro A, Campanacci L. Osteoid osteoma. Direct visual identification and intralesional excision of the nidus with minimal removal of bone. *J Bone Joint Surg Br*. (1999) 81:814–20. doi: 10.1302/0301-620X.81B5.0810814
21. Neumann D, Berka H, Dorn U, Neureiter D, Thaler C. Follow-up of thirty-three computed-tomography-guided percutaneous radiofrequency thermoablations of osteoid osteoma. *Int Orthop*. (2012) 36:811–5. doi: 10.1007/s00264-011-1402-8
22. Preston DL, Cullings H, Suyama A, Funamoto S, Nishi N, Soda M, et al. Solid cancer incidence in atomic bomb survivors exposed in utero or as young children. *J Natl Cancer Inst*. (2008) 100:428–36. doi: 10.1093/jnci/djn045
23. Redpath JL. Nonlinear response for neoplastic transformation following low doses of low let radiation. *Nonlinearity Biol Toxicol Med*. (2005) 3:113–24. doi: 10.2201/nonlin.003.01.007
24. Fujiwara T, Kunisada T, Takeda K, Hasei J, Nakata E, Mochizuki Y, et al. Mini-open excision of osteoid osteoma using intraoperative O-arm/Stealth navigation. *J Orthop Sci*. (2019) 24:337–41. doi: 10.1016/j.jos.2018.09.017
25. Rampersaud YR, Foley KT, Shen AC, Williams S, Solomito M. Radiation exposure to the spine surgeon during fluoroscopically assisted pedicle screw insertion. *Spine*. (2000) 25:2637–45. doi: 10.1097/00007632-200010150-00016
26. Zhang J, Weir V, Fajardo L, Lin J, Hsiung H, Ritenour ER. Dosimetric characterization of a cone-beam O-arm imaging system. *J Xray Sci Technol*. (2009) 17:305–17. doi: 10.3233/XST-2009-0231
27. Bai L, Yang J, Chen X, Sun Y, Li X. Medical robotics in bone fracture reduction surgery: a review. *Sensors (Basel, Switzerland)*. (2019) 19:3593). doi: 10.3390/s19163593

Conflict of Interest: The authors declare that the research was conducted in the absence of any commercial or financial relationships that could be construed as a potential conflict of interest.

Publisher's Note: All claims expressed in this article are solely those of the authors and do not necessarily represent those of their affiliated organizations, or those of the publisher, the editors and the reviewers. Any product that may be evaluated in this article, or claim that may be made by its manufacturer, is not guaranteed or endorsed by the publisher.

Copyright © 2022 Wang, Luo, Zhou, Liu, Hou, Jia and Zheng. This is an open-access article distributed under the terms of the Creative Commons Attribution License (CC BY). The use, distribution or reproduction in other forums is permitted, provided the original author(s) and the copyright owner(s) are credited and that the original publication in this journal is cited, in accordance with accepted academic practice. No use, distribution or reproduction is permitted which does not comply with these terms.

frontiers | Frontiers in Surgery

ORIGINAL RESEARCH
published: 10 May 2022
doi: 10.3389/fsurg.2022.899483

Novel Retrograde Tibial Intramedullary Nailing for Distal Tibial Fractures

Bin Peng[1], Teng Wan[2], Wenfu Tan[1], Weiming Guo[3] and Min He[1]**

[1]The Second Affiliated Hospital, Department of Orthopaedic Surgery, Hengyang Medical College, University of South China, Hengyang, Hunan, China, [2]Hengyang Medical College, University of South China, Hengyang, Hunan, China, [3]Sports medicine department, Huazhong University of Science and Technology Union Shenzhen Hospital; the 6th Affiliated Hospital of Shenzhen University Health Science CenterShenzhen, China

OPEN ACCESS

Edited by:
Paphon Sa-ngasoongsong, Ramathibodi Hospital, Mahidol University, Thailand

Reviewed by:
Junlin Zhou, Beijing Chaoyang Hospital, Capital Medical University, China
Holly Tyler-Paris Pilson, Wake Forest Baptist Medical Center, United States
Sebastian Kuhn, Bielefeld University, Germany

***Correspondence:**
Weiming Guo
253779211@qq.com
Min He
376900271@qq.com

Specialty section:
This article was submitted to Orthopedic Surgery, a section of the journal Frontiers in Surgery

Received: *18 March 2022*
Accepted: *21 April 2022*
Published: *10 May 2022*

Citation:
Peng B, Wan T, Tan W, Guo W and He M (2022) Novel Retrograde Tibial Intramedullary Nailing for Distal Tibial Fractures. Front. Surg. 9:899483. doi: 10.3389/fsurg.2022.899483

Purpose: Postoperative distal tibial fractures are often associated with complications such as difficulties in fracture healing and surgical incision infection. The purpose of this study is to evaluate the fracture healing time and functional recovery after a retrograde tibial intramedullary nail treatment for distal tibial fractures.

Methods: We retrospectively studied 9 cases of patients with distal tibial fractures treated with retrograde intramedullary nailing (IMN). Fracture healing time was based on monthly postoperative x-ray imaging results, and functional outcomes were defined according to the American Orthopaedic Foot and Ankle Society (AOFAS) ankle-hindfoot score.

Results: Among the 9 patients with distal tibial fractures from July 2020 to April 2021, the mean age was 51.8 ± 13.8 years. The classification of distal tibial fractures in the 9 patients according to OTA (Orthopaedic Trauma Association) includes 6 extra-articular fractures (3 of type A1, 2 of type A2, and 1 of type A3) and 3 intra-articular fractures (1 of type C1 and 2 of type C2). Among them, there were 5 closed fracture cases and 4 open fracture cases (according to Gustilo classification: 2 of type I, 2 of type II). We treated the fractures surgically with new retrograde tibial intramedullary nailing. The mean follow-up time for this group was 7.9 months (5–12 months). According to monthly postoperative radiographs performed to monitor fracture healing, the mean healing time was 3.3 months (3–4 months). Final postoperative function according to the AOFAS ankle-hindfoot score shows 6 excellent cases, 3 good cases. No serious complications such as postoperative infection, bone and internal fixation exposure, osteofascial compartment syndrome, or vascular nerve injury occurred.

Conclusion: The new retrograde tibial intramedullary nail (RTN) has some unique advantages, and its treatment of distal tibial fractures can achieve good efficacy, but further studies are still needed to verify it.

Keywords: distal tibia, fracture, retrograde tibial intramedullary nail, surgery, retrospective study

INTRODUCTION

Distal tibial fractures are a relatively common type of injury in clinical practice, accounting for approximately 10% of all tibial fractures (1, 2). Due to the proximity of the distal tibia to the ankle joint, fracture repositioning, fixation difficulties, poor local soft tissue coverage and blood supply are currently a challenging clinical problem (3). Common surgical treatment options include reduction and internal fixation, and reduction and internal fixation with anterograde tibial intramedullary nails. However, both have certain shortcomings. Compared with plates, the anterograde tibial nail (ATN) reduces the impact on local soft tissue and periosteal blood flow. However, due to the gradual widening of the distal tibial medullary cavity, poor repositioning and instability of fixation are likely to appear (4–6). In recent years, Kuhn et al. designed a novel retrograde tibial intramedullary nail, which provides a new option for minimally invasive treatment of distal tibial fractures (7). Until now, there is no report about the clinical application of new RTN. In this article, we monitored fracture healing time and recorded postoperative ankle functional outcomes after distal tibial fracture surgery and observed the occurrence of postoperative complications.

METHODS

Inclusion criteria: age ≥18 years and distal tibial epiphysis closed; diagnosis of distal tibial fracture, i.e. fracture within 11 cm of the articular surface of the distal tibia; closed fracture or open fracture of Gustilo type I or II; according to OTA (Orthopaedic Trauma Association) fracture classification: 43-A1/A2/A3, 43-C1/C2. Exclusion criteria: combined with ipsilateral tibial proximal or middle tibial stem fracture; pathological fracture or old fracture; ankle deformity; local skin and soft tissue defect and infection; combined vascular and nerve injury requiring repair; patients with poor basic conditions, combined with multiple medical disorders and unable to tolerate surgery. In the retrospective study, from July 2020 to April 2021, we analyzed a total of 9 patients. The RTN is provided by Double Medical Technology Inc (China), which is called metal interlocking intramedullary nail with the registration number of 20153131195. The nail was 8 mm in diameter and 140 mm in length.

All surgeries were performed by the same orthopedic surgeons. If fibula fractures affect the stability of the ankle (within 8 cm above the malleolar fossa), open reduction and plate fixation of the fibula are performed first via the lateral approach. In patients with intra-articular fractures, the distal tibial articular fragments were fixed with lag screw, then the treatment of metaphyseal fractures with RTN were followed.The 2 cm long incision started at the tip of the medial malleolus with sharp dissection and separation. Under the protective sleeve device, a guide wire was inserted and confirmed by C-arm fluoroscopy. The insertion point was at the midpoint of the medial malleolus in both anteroposterior (AP) and lateral radiographs. Moreover, the insertion direction was parallel to the medial cortex in AP fluoroscopy, which located at the anatomical axis of the distal tibia in lateral fluoroscopy. Along the the guide wire, a cannulated awl was used to create a hole and path until reaching the medullary canal. Then, the guide wire and awl were moved and RTN was assembled on the aiming device. With low force and small twisting movements, the nail was introduced into the the medullary canal until the end was flush with the cortex of medial malleolus. C-arm fluoroscopy served to confirm the reduction and correct nail position. If satisfactory, the proximal and distal locking screws were placed through the the trocar combination, and an end cap was introduced at the nail end finally. If the fracture had significant angulation or lateral displacement, the nail was returned and the fracture was corrected by some reduction techniques. For example, blocking screws, percutaneous clamps at the fracture site, and open clamp application with minimal incision were all viable. The typical case is shown in **Figures 1–3**.

Postoperative anticoagulation was performed for 24 h, and functional ankle exercises were started 2–3 days after surgery. Regular follow-up and monthly postoperative x-ray imaging was performed to monitor fracture healing. Further rehabilitation and weight bearing guided by review results. At the final follow-up, if the angle of the distal tibial coronal plane was greater than 5°, the ankle was considered to have an inversion or valgus deformity. The clinical outcome was also evaluated using the AOFAS ankle-hindfoot score

RESULTS

A retrospective study of 9 patients with distal tibial fractures with new retrograde tibial intramedullary nailing for closed reduction and internal fixation was performed (**Table 1**). The patients, 4 male and 5 female, are followed up for mean 7.9 months (5–12 months). The age range of the included patients was 18–69 years with a mean of 51.8 years. There are 3 cases with left-sided fracture and 6 cases with right-sided fracture. 5 cases are caused by traffic injury and 4 cases are caused by falls. The fractures were classified according to OTA classification, with 6 cases of extra-articular fractures (A1, A2, A3) and 3 cases of intra-articular fractures (C1, C2). The length of the tibial stem fracture line from the articular surface was 7.9–10.8 cm, with an average of 9.1 cm. There were 5 closed fractures and 4 open fractures (according to Gustilo typing: 2 cases of type I and 2 cases of type II). Nine patients had a combined fibula fracture, one patient had a combined thoracic trauma and one patient had a combined craniocerebral trauma. The time between injury and RTN surgery ranged from 5 to 16 days, with a mean of 11.4 days. Plates were used for internal fixation in 4 cases with fibula fracture. The mean healing time was 3.3 months (3–4 months) according to monthly postoperative X-ray imaging. All achieved clinical healing of the fracture and returned to daily life and work successfully. The imaging evaluation showed no angulation of the distal tibial coronal plane greater than 5°, and no inversion deformity occurred. Ankle-hindfoot

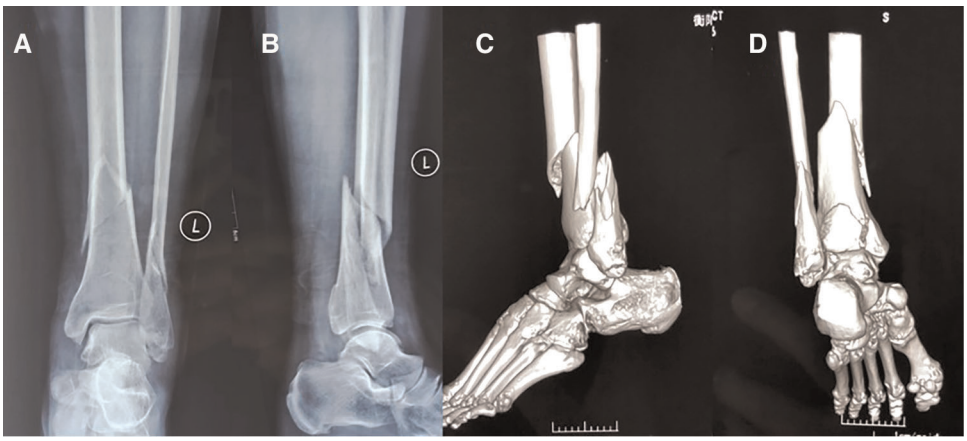

FIGURE 1 | Typical case: female, 54age, fall injury, OTA fracture staging type 42-C1. (**A**) Preoperative X-ray orthopantomograph of distal tibial fracture; (**B**) Preoperative X-ray lateral radiograph of distal tibial fracture; (**C,D**) 3D CT of ankle showing posterior ankle fracture.

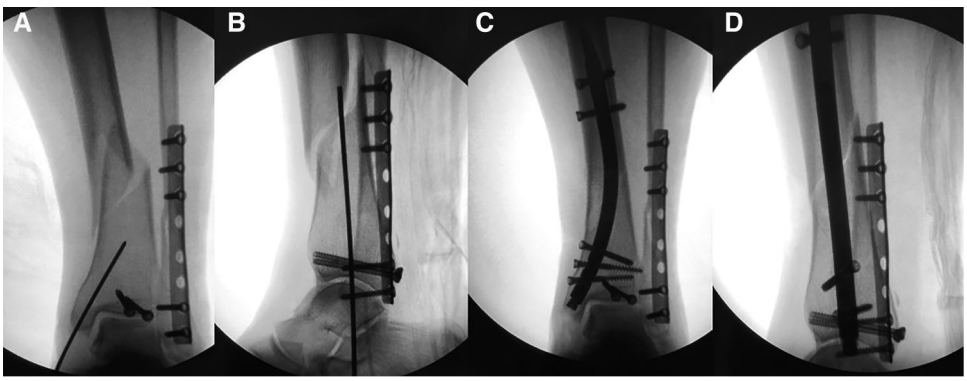

FIGURE 2 | (**A,B**) firstly, the posterior lateral ankle approach was taken, and plates and tension screws were applied to fix the fibula and posterior ankle fractures (RTN guide pins at the medial ankle site), and the orthogonal and lateral films were positioned under intraoperative fluoroscopy, respectively; (**C,D**) a medial minimally invasive incision was used for RTN placement to fix the tibial metaphysis fracture, and the orthogonal and lateral films were taken, respectively.

score according to AOFAS indicated 6 excellent cases, 3 good cases. No patients had serious complications, including infection, bone and internal fixation exposure, osteofascial compartment syndrome, or vascular nerve injury.

DISCUSSION

Distal tibial fractures are more common in clinical practice and have specific anatomic features (1,2). The cross-sectional morphology of the tibia changes from trigonous to quadrangular in the middle and lower third of the tibia, and the medullary cavity becomes progressively wider. In addition, the soft tissue around the distal tibia is less and very heterogeneous, and there is no muscle attachment on the anterior medial side. And its local extramedullary blood supply is relatively insufficient, while the trophoblastic vessels in the medullary cavity are relatively homogeneous. Therefore, the local resistance to infection and bone healing of the distal tibia is poor, and infection, delayed fracture healing and non-healing are likely to occur. High-energy injuries are often accompanied by severe soft tissue injuries or open fractures, which makes the management of distal tibial fractures more difficult. In our series, most were high-energy injury cases, and some of them had hyperpigmentation of the lower extremity due to chronic diseases such as varicose veins, which undoubtedly made the treatment more difficult.

Currently, plates and intramedullary nails are the two main forms of internal fixation, and many studies have shown no significant difference in the overall efficacy of the two treatment modalities (3, 8, 9). However, plate fixation is more demanding on soft tissue conditions. Although percutaneous minimally invasive plate technique can reduce soft tissue stripping, we still need to be alert to this serious problem,

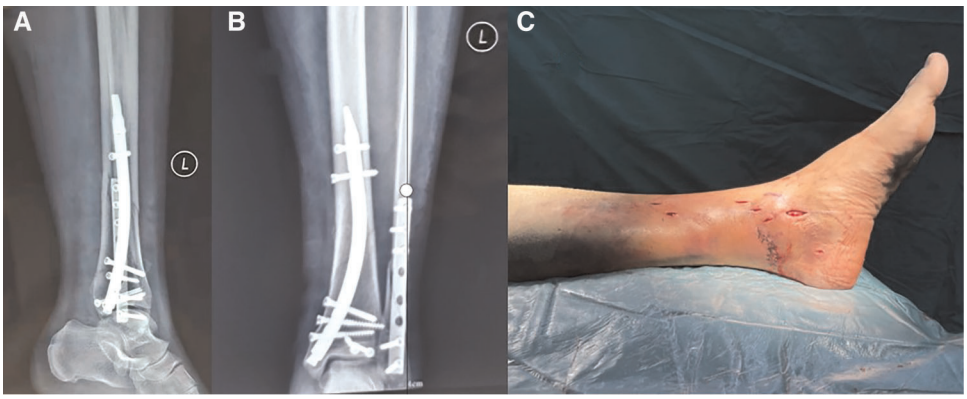

FIGURE 3 | (**A**) X-ray orthopantomogram at one month after1 closed reduction RTN internal fixation of distal tibial fracture; (**B**) X-ray lateral radiograph at one month after1 closed reduction RTN internal fixation of distal tibial fracture; (**C**) surgical incision of the affected limb after closed reduction RTN internal fixation of distal tibial fracture.

TABLE 1 | Patient data for closed reduction of distal tibial fracture with new retrograde tibial intramedullary nail internal fixation.

Medical Record Number	Gender	Age (years)	Injury types	Left / Right	AO/OTA Fracture Types	Length of fracture line from joint surface (cm)	Open fracture/ Gustilo typing	Combined injuries	Fracture healing Time (month)	The angulation of the distal tibial coronal plane (°)	AOFAS Rating
1	Female	57	Traffic Injuries	Right	43-A1	7.9	Not applicable	Cranial Trauma	3	3	Excellent
2	Male	18	Fall injury	Left	43-A1	8.7	Not applicable	None	3	5	Excellent
3	Female	69	Traffic Injuries	Right	43-C2	10.2	Type I	None	4	2	Good
4	Male	54	Fall injury	Right	43-C2	10.8	Type II	None	3	4	Excellent
5	Male	66	Traffic Injuries	Right	43-A2	9.4	Type II	None	4	2	Good
6	Male	45	Traffic Injuries	Left	43-A2	8.3	Not applicable	Chest Trauma	4	0	Excellent
7	Female	52	Traffic Injuries	Right	43-A3	9.2	Type I	None	3	3	Excellent
8	Female	54	Fall injury	Left	43-C1	9.6	Not applicable	None	3	0	Excellent
9	Female	51	Fall injury	Right	42-A1	8.2	Not applicable	None	3	2	Good

especially in patients with poor local soft tissue conditions. In recent years, with the continuous development of the ATN technique, its indications have been extended to distal tibial fractures with satisfactory results. However, due to the gradual widening of the distal tibial medullary cavity, the special anatomical structure prevents the intramedullary nail from fitting tightly into the medullary cavity, which makes the fracture prone to poor repositioning and lack of stability, resulting in malunion and delayed healing (10). Therefore, ATN treatment of distal tibial fractures often requires a combination of reduction techniques such as blocking screws (11, 12), but this undoubtedly increases the difficulty and technical requirements of the procedur. In addition, it also has some adverse effects on the knee joint (13).

In 2014, Kuhn et al. reported a new type of RTN with a distally curved banana-shaped main nail and multiple interlocking nails at both ends to form a multi-axial fixation (7). For the indications of RTN, it has been noted that it can be used for extra-articular fractures of the distal tibia and some intra-articular fractures (OTA typing: 43-A1/A2/A3, 43-C1/C2 types) (14). In our group, there were 6 cases of extra-articular fractures (3 cases of A1 type, 2 cases of A2 type, 1case of A3 type) and intra-articular fractures accounted for 3 cases (1 case of C1 type, 2 cases of C2 type), and all patients

obtained good results. For intra-articular fractures, we first applied tension screws to fix the intra-articular bone block, and then applied RTN to treat distal tibial epiphysis fractures. In addition, RTN may be the only intramedullary nailing option for patients combined with internal fixation of ipsilateral tibial plateau fractures or total knee replacement.

Through literature review and preliminary clinical application, we believe that the new RTN has some unique advantages. First, In terms of biomechanics, the RTN has better resistance to rotation and similar axial stability compared with the ATN (15). Second, compared with the distal medial tibial plate, the RTN has both better rotation and axial stability (16). It is well known that good biomechanical stability is one of the necessary conditions for fracture healing, and all patients in this group successfully achieved the fracture healing, which also reflects the good stability of the RTN. Third, because the intramedullary nail has a distal curved banana shape, it is more compatible with the morphology of the distal tibia. In the initial clinical application, we believe that the fracture repositioning and fixation is simpler and more convenient by using RTN. In all cases, only 1 patient required an adjunctive repositioning technique such as blocking nail, and postoperative radiographic measurements showed no occurrence of distal tibial valgus deformity. Forth, RTN used the medial ankle as the entry point, thus avoiding anterior knee pain, and postoperative results showed that it also had less impact on the ankle joint. However, RTN may have a risk of distant ankle pain and susceptibility to fracture, which needs to be verified with a larger sample size and long-term follow-up. Fifth, due to the shorter RTN, its locking nail aiming device has a high accuracy, and all the locking nails in this group of patients could be accurately placed one first time, which relatively reduced the operation time and radiation exposure. Also, the shorter intramedullary nail did not pass through the isthmus of the tibial trunk and had relatively less impact on the bone marrow cavity. This may have reduced the risk of fat embolism, especially in patients with combined lung injury or multiple injuries. However, we currently have a small number of cases and further studies are needed for confirmation.

CONCLUSION

In conclusion, the novel RTN for distal tibial fractures can achieve satisfactory efficacy and has some unique advantages. However, we need to increase the number of cases and follow-up time and conduct further prospective randomized controlled studies to provide a more solid basis for the wide application of RTN.

DATA AVAILABILITY STATEMENT

The original contributions presented in the study are included in the article/Supplementary Material, further inquiries can be directed to the corresponding author/s.

ETHICS STATEMENT

Ethical review and approval was not required for the study on human participants in accordance with the local legislation and institutional requirements. The patients/participants provided their written informed consent to participate in this study.

Written informed consent was obtained from the individual (s) for the publication of any potentially identifiable images or data included in this article.

AUTHOR CONTRIBUTIONS

BP and WG wrote the first draft of the letter, and coordinated and integrated comments. TW, WT and MH critically revised and edited successive drafts of the manuscript. All authors contributed to the article and approved the submitted version.

FUNDING

The Hunan Provincial Department of Education Project (No. 20b507). This funding is provided by BP.

REFERENCES

1. Nourisa J, Rouhi G. Biomechanical evaluation of intramedullary nail and bone plate for the fixation of distal metaphyseal fractures. *J Mech Behav Biomed Mater*. (2016) 56:34–44. doi: 10.1016/j.jmbbm.2015.10.029
2. Daolagupu AK, Mudgal A, Agarwala V, Dutta KK. A comparative study of intramedullary interlocking nailing and minimally invasive plate osteosynthesis in extra articular distal tibial fractures. *Indian J Orthop*. (2017) 51:292–8. doi: 10.4103/0019-5413.205674
3. Kariya A, Jain P, Patond K, Mundra A. Outcome and complications of distal tibia fractures treated with intramedullary nails versus minimally invasive plate osteosynthesis and the role of fibula fixation. *Eur J Orthop Surg Traumatol*. (2020) 30:1487–98. doi: 10.1007/s00590-020-02726-y
4. Fawdington RA, Lotfi N, Beaven A, Fenton P. Does the use of blocking screws improve radiological outcomes following intramedullary nailing of distal tibia fractures? *Strategies Trauma Limb Reconstr*. (2019) 14:11–4. doi: 10.5005/jp-journals-10080-1418
5. Lee C, Brodke DJ, Stefanski JT, Gurbani A. Staying out of trouble with intramedullary nailing of distal tibia fractures. *J Am Acad Orthop Surg*. (2021) 29:e62–e71. doi: 10.5435/jaaos-d-20-00309
6. Baseri A, Bagheri MA, Rouhi G, Aghighi MR, Bagheri N. Fixation of distal tibia fracture through plating, nailing, and nailing with Poller screws: a comparative biomechanical-based experimental and numerical investigation. *Proc Inst Mech Eng H*. (2020) 234(10):1129–38. doi: 10.1177/0954411920941664
7. Kuhn S, Appelmann P, Pairon P, Mehler D, Rommens PM. The Retrograde Tibial Nail: presentation and biomechanical evaluation of a new concept in the treatment of distal tibia fractures. *Injury*. (2014) 45(Suppl 1):S81–6. doi: 10.1016/j.injury.2013.10.025
8. Polat A, Kose O, Canbora K, Yanık S, Guler F. Intramedullary nailing versus minimally invasive plate osteosynthesis for distal extra-articular tibial fractures: a prospective randomized clinical trial. *J Orthop Sci*. (2015) 20:695–701. doi: 10.1007/s00776-015-0713-9

9. Mioc ML, Prejbeanu R, Deleanu B, Anglitoiu B, Haragus H, Niculescu M. Extra-articular distal tibia fractures-controversies regarding treatment options. A single-centre prospective comparative study. *Int Orthop*. (2018) 42(4):915–9. doi: 10.1007/s00264-018-3775-4
10. Brinkmann E, DiSilvio F, Tripp M, Bernstein M, Summers H, Lack WD. Distal nail target and alignment of distal tibia fractures. *J Orthop Trauma*. (2019) 33:137–42. doi: 10.1097/bot.0000000000001358
11. Hannah A, Aboelmagd T, Yip G, Hull P. A novel technique for accurate Poller (blocking) screw placement. *Injury*. (2014) 45(6):1011–4. doi: 10.1016/j.injury.2014.02.029
12. Moongilpatti Sengodan M, Vaidyanathan S, Karunanandaganapathy S, Subbiah Subramanian S, Rajamani SG. Distal tibial metaphyseal fractures: does blocking screw extend the indication of intramedullary nailing? *ISRN Orthop*. (2014) 2014:542623. doi: 10.1155/2014/542623
13. Soraganvi PC, Anand-Kumar BS, Rajagopalakrishnan R, Praveen-Kumar BA. Anterior knee pain after tibial intra-medullary nailing: is it predictable? *Malays Orthop J*. (2016) 10:16–20. doi: 10.5704/moj.1607.004
14. Kuhn S, Appelmann P, Pairon P, Gruszka D, Rommens PM. Retrograde tibial nail: anatomical implantation and surgical feasibility study. *Acta Chir Orthop Traumatol Cech*. (2015) 82(3):203–8.
15. Kuhn S, Appelmann P, Pairon P, Mehler D, Hartmann F, Rommens PM. A new angle stable nailing concept for the treatment of distal tibia fractures. *Int Orthop*. (2014) 38:1255–60. doi: 10.1007/s00264-013-2267-9
16. Kuhn S, Appelmann P, Mehler D, Pairon P, Rommens PM. Retrograde tibial nailing: a minimally invasive and biomechanically superior alternative to angle-stable plate osteosynthesis in distal tibia fractures. *J Orthop Surg Res*. (2014) 9:35. doi: 10.1186/1749-799x-9-35

Conflict of Interest: The authors declare that the research was conducted in the absence of any commercial or financial relationships that could be construed as a potential conflict of interest

Publisher's Note: All claims expressed in this article are solely those of the authors and do not necessarily represent those of their affiliated organizations, or those of the publisher, the editors and the reviewers. Any product that may be evaluated in this article, or claim that may be made by its manufacturer, is not guaranteed or endorsed by the publisher.

Copyright © 2022 Peng, Wan, Tan, Guo and He. This is an open-access article distributed under the terms of the Creative Commons Attribution License (CC BY). The use, distribution or reproduction in other forums is permitted, provided the original author(s) and the copyright owner(s) are credited and that the original publication in this journal is cited, in accordance with accepted academic practice. No use, distribution or reproduction is permitted which does not comply with these terms.

frontiers | Frontiers in Surgery

ORIGINAL RESEARCH
published: 10 May 2022
doi: 10.3389/fsurg.2022.891869

A New Antirotation Strategy of K-Wire Tension Band Therapy for Patellar Fracture

*Fengpo Sun†, Yawen Zhang†, Quan Ji, Tongyi Zhang, Yi Zhu, Ze Zhang, Ruining Han and Liangyuan Wen**

Department of Orthopedics, Beijing Hospital, National Center of Gerontology, Institute of Geriatric Medicine, Chinese Academy of Medical Sciences, Beijing, China

Background: Patellar fracture is a common phenomenon observed in orthopedic clinics. Many methods have been shown to be effective in the fixation of patellar fracture. However, there are few studies on the antirotation effect of these methods. The purpose of this study is to present a new strategy of K-wire tension band therapy for patellar fracture and explore the antirotation effect of the modified tension band method on patellar fracture.

Methods: A retrospective clinical observation study was conducted on 75 patients with patellar fracture. Totally, 46 patients were enrolled to the traditional group, who received the traditional K-wire tension band therapy. The modified group included 29 patients on whom our new strategy was implemented. The operation time, intraoperative blood loss, and fracture healing time were collected to compare the two operations and the knee society score (KSS) scores after the operations, and complications were recorded and retrieved to indicate the effectiveness of the two treatments.

Results: The preoperative baseline data (gender, age, fracture types) of the two groups showed no significant statistical difference. Similarly, there was no significant difference in the operation time, intraoperative blood loss, and fracture healing time between the two groups. The KSS clinical scores 1 year after operation was 90 (84, 95) for the traditional group as compared with 99 (97, 100) for the modified group ($p < 0.05$). The KSS functional scores 1 year after operation in the two groups were 90 (65, 90) and 100 (90, 100) ($p < 0.05$). The incidences of complications due to the rotation of K-wires in the traditional group and the modified group were 76.1% (35 of 46) and 6.9% (2 of 29) with a significant statistical difference ($p < 0.05$).

Conclusion: This study shows that our modified tension band therapy is an effective strategy for antirotation in the treatment of patellar fracture and proves that it can achieve better clinical outcomes than the traditional K-wire tension band method. This new strategy may be a safe and effective clinical technique for the treatment of patellar fracture. However, more prospective randomized controlled trials with larger sample sizes are still needed to further prove its efficacy.

Keywords: patellar fracture, tension band method, antirotation, internal fixation, trauma

OPEN ACCESS

Edited by:
Paphon Sa-ngasoongsong, Ramathibodi Hospital, Mahidol University, Thailand

Reviewed by:
Junlin Zhou, Capital Medical University, China
Elif Keskinöz, Acıbadem University, Turkey

***Correspondence:**
Liangyuan Wen
wenliangyuanbjyy@163.com

†These authors have contributed equally to this work

Specialty section:
This article was submitted to Orthopedic Surgery, a section of the journal Frontiers in Surgery

Received: *08 March 2022*
Accepted: *18 April 2022*
Published: *10 May 2022*

Citation:
Sun F, Zhang Y, Ji Q, Zhang T, Zhu Y, Zhang Z, Han R and Wen L (2022) A New Antirotation Strategy of K-Wire Tension Band Therapy for Patellar Fracture. Front. Surg. 9:891869. doi: 10.3389/fsurg.2022.891869

BACKGROUND

Patellar fractures are relatively common injuries in adults destroying the continuity of the extensor mechanism of the knee and accounting for about 1% of all skeletal fractures (1). The patellar is the largest sesamoid in the human body that can increase the lever arm of quadriceps femoris. This can add an additional 60% of the force needed to gain full extension (2). Operation is necessary for patellar fractures, especially for displaced or step-off fractures above 2 mm, in order to regain the full force of the knee extension. The most popular methods for patellar operation include the K-wire tension band, cable pin, and cannulated screws (3). The K-wire tension band method is extensively applied for all types of patellar fracture due to its excellent prognosis. Favorable outcomes in this method for patellar fracture have been reported (4, 5). But the incidence of complications such as skin prominence and ulceration due to the rotation of K-wires is rather high (6, 7). These complications usually affect rehabilitation efforts, necessitating a second operation to remove the hardware. So, we invented a new K-wire tension band method to avoid the rotation of K-wires and reduce the related incidence of complications.

To ascertain the effectiveness of this new technique in the treatment of patellar fracture, we conducted a retrospective cohort study to evaluate the postoperative outcome of patellar fracture patients using the modified K-wire tension band method and the traditional K-wire tension band method. The main purpose of our study was to compare the antirotation performance of the two methods.

MATERIALS AND METHOD

Patients

Between January 2016 and December 2018, 75 patients with patellar fracture were treated either with the traditional K-wire tension band method or with the modified method. The traditional K-wire tension band method was used in patients before October 2017, and patients from November 2017 to December 2018 underwent the modified method. The clinical data of the patients including gender, age, fracture type, operation time, intraoperative blood loss, fracture healing time, knee society score (KSS) scores after operation and complications were recorded and analyzed in our study. The complications due to the rotation of K-wires were recorded, including skin prominence or damage or the limitation of knee flexion movement. The primary outcome was the rotation of K-wires. The secondary outcome was the symptoms that occurred due to the rotation of the K-wires, including skin irritability and ulceration and fixation failure, including the breakage of the K-wires or titanium cables, and titanium cables unhooking the connection of the K-wires.

Instruments

The 2.0-mm titanium K-wires and titanium cables used in this study were obtained from DePuy Synthes company. Studies have shown that the most useful of these materials is titanium. The use of titanium eliminates the possibility of allergic reactions to nickel in other materials (8).

Procedure

We used this new strategy in compliance with the principles of the Declaration of China. The protocol of this study was reviewed and approved by the Institutional Review Board of Beijing Hospital (2018BJYYEC-032-05).

Under general or spinal anesthesia, surgery was performed in supine position. The tourniquet was used in each case. An incision was made along the longitudinal axis of the knee joint. After the patellar was presented, the fracture was then reduced with reduction forceps. Two 2.0-mm K-wires were inserted into the fragments to fix the fracture. The titanium cable was then placed as a figure-of-eight pattern around the K-wires in front of the patellar. More K-wires were used according to the fracture type. According to the type of group by which the patients were divided, we used the traditional K-wire band method or the modified method to fix the fracture.

In the group of the modified method, the proximal ends of the K-wires were bent toward the patellar by 180°, and we drilled holes in the superior extreme of the patellar with a 2.5-mm K-wire near the corresponding site of the bended part of the 2.0-mm K-wires. Then, we knocked the 2.0-mm K-wires downward to insert the bended part into the holes to prevent the rotation of the K-wires. The specific case surgical techniques are indicated in **Figure 1**. Preoperative and postoperative radiographs of the specific cases are shown in **Figure 2**.

In the group of the traditional method, the proximal ends of the K-wires were bent toward the patellar. Preoperative and postoperative radiographs of the specific cases are shown in **Figure 3**.

Statistical Method

Summary statistics were presented as frequencies and proportions for categorical variables and means with standard deviations or medians with interquartile ranges for continuous variables depending on data distribution. We compared baseline characteristics between study groups using Student's *t*-tests or the Mann–Whitney *U* test for continuous variable and χ^2 tests for categorical variables, as appropriate. A score of $p < 0.05$ was considered as a significant statistical difference.

RESULTS

The traditional tension band method was used in 46 patients, and the modified method was used in 29 patients. The age, gender, and fracture type were comparable (**Table 1**). With the accumulation of sample size, more detailed baseline data of patient can be further analyzed and compared (9). The data of operation and outcome is presented in **Table 2**. The operation time and blood loss in the two groups were similar and did not have significant statistical differences ($p > 0.05$). The healing times of the patellar fractures in the two groups

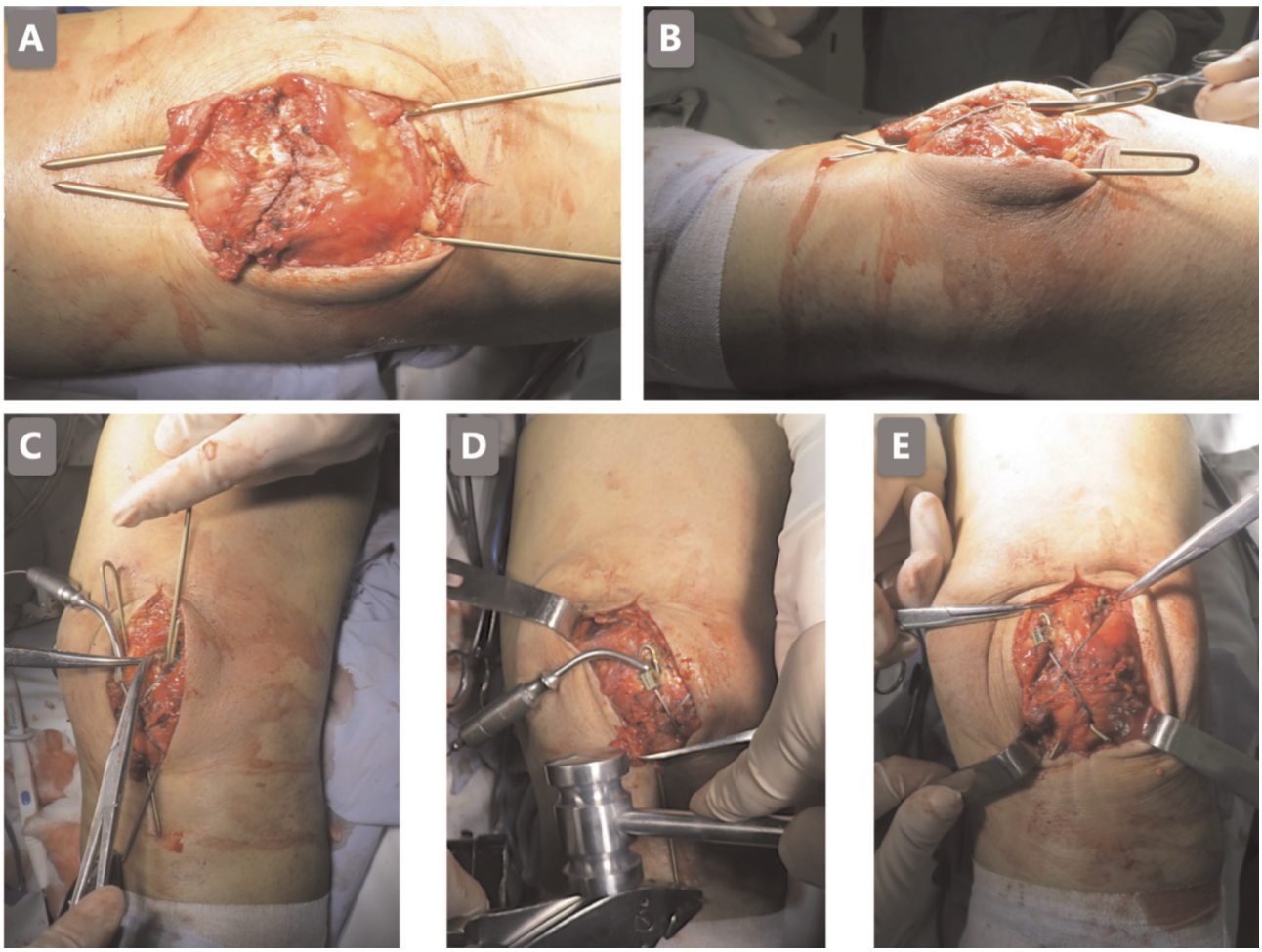

FIGURE 1 | The patellar was fixed with two titanium K-wires with a titanium cable (**A**); the proximal K-wires were bent to 180° (**B**); the holes in the superior extreme of the patellar were drilled next to the bent part of the K-wires (**C**); the K-wires were knocked into the holes (**D**); the 1-mm titanium cable was placed as a figure-of-eight pattern (**E**).

were similar (3.9 ± 1.2 months vs. 3.8 ± 1.1 months, $p = 0.153$). The KSS clinical scores 1 year after operation in the traditional method group and the modified method group were 90 (84, 95) and 99 (97, 100), respectively, with a significant statistical difference ($p < 0.05$). The KSS functional scores 1 year after operation in both groups were 90 (65, 90) and 100 (90, 100) with a significant statistical difference ($p < 0.05$).

The incidences of complications due to the rotation of K-wires in the traditional group and the modified group were 76.1% (35 of 46) and 6.9% (2 of 29), respectively, with a significant statistical difference ($p < 0.05$). We chose the rotation of K-wires as our primary outcome. The subitems of the complications were also analyzed (**Table 3**).

Primary Outcome

The average time of onset of primary outcome complications in the traditional method was 3.2 months, and there was no primary outcome complications in the modified method. A total of 35 of the 46 patients in the traditional group suffered the rotation of K-wires, but no patient in the modified group suffered K-wire rotation.

Secondary Outcome

Of the 46 patients in the traditional method, 14 patients sustained simple rotation injuries (**Figure 4A**). There were 18 patients in the traditional method group and 1 patient in the modified method group who sustained cable unhooking injuries (**Figure 4B**). One patient in the traditional method group and one patient in the modified method group suffered fixation breakage. However, the broken fixation of the two groups was different. Cable breakage (**Figure 4C**) occurred in the traditional group, and K-wire breakage (**Figure 4D**) occurred in the modified group. Of the 46 patients in the traditional method group, 4 patients suffered skin ulceration (**Figure 4E**).

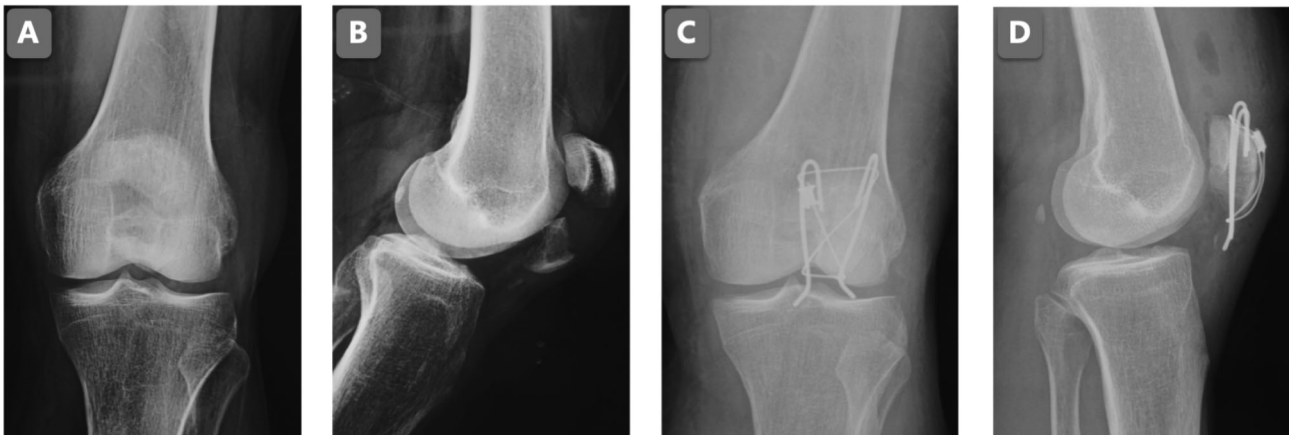

FIGURE 2 | The AP knee joint X-ray before the surgery (**A**); the lateral knee joint X-ray before the surgery (**B**); the AP knee joint X-ray post the modified method surgery (**C**); the lateral knee joint X-ray post the modified method surgery (**D**).



FIGURE 3 | The AP knee joint X-ray before the surgery (**A**); the lateral knee joint X-ray before the surgery (**B**); the AP knee joint X-ray post the traditional method surgery (**C**); the lateral knee joint X-ray post the traditional method surgery (**D**).

DISCUSSION

The results of the present study showed that our new method presented excellent antirotation performance, better functional outcomes, and a lower complication rate compared with the traditional technique.

Many operation techniques are applied in clinical practice. Patellar plate, cable pin, headless screw, headed screw, and K-wire tension band are commonly adopted worldwide. Patellar plates have many shapes such as star plate, shield plate, and bilateral fixed-angle plate (10–12). Several studies have demonstrated efficacy in the treatment of plate fractures (13, 14), but most biomechanical studies about patellar plates have used the transverse patellar fracture models. Only a few studies in the literature have focused on the application of the patellar plate to comminuted patellar fractures. Thelen et al. performed cadaver testing of a fixed-angle plate in a comminuted plate fracture (13). Wurm et al. used an angular stable plate to treat a comminuted patellar fracture and achieved an overall complication rate of about 6% (14). But it is difficult to fix screws to comminuted fractures, because the patellar may be too comminuted to have enough space for the screws to hold. The result of the layered patellar fracture using a locking plate was also not satisfactory.

Another category of internal fixator is the tension band. Some of the cables used in the clinic include titanium cable and stainless-steel cable. K-wires, lag screws, cannulated screws, and headless screws are used, along with cables, to enhance strength. Some biomechanical tests have demonstrated the reliability of tension band wiring with screws in transverse patellar fractures (15, 16). But an adverse conclusion was reported in Wagner's research. The strength of

TABLE 1 | Demographic and clinical characteristics of patients of patellar fracture.

	Traditional group (*N* = 46)	Modified group (*N* = 29)	*p*-value
Age (IQR, year)	64 (54, 75)	63 (60, 67)	0.632
Sex [no. (%)]			0.535
Men	24 (52.2)	13 (44.8)	
Women	22 (47.8)	16 (55.2)	
AO classification [no. (%)]			0.554
C1	9 (19.6)	7 (24.1)	
C2	9 (19.6)	3 (10.3)	
C3	28 (60.8)	19 (65.6)	

IQR, Interquartile range.

TABLE 2 | The data of operation and outcome.

	Traditional group (*N* = 46)	Modified group (*N* = 29)	*p*-value
Operation duration ($\mu \pm \sigma$, min)	67.6 ± 9.8	63.6 ± 15.4	0.170
Blood loss ($\mu \pm \sigma$, ml)	93.7 ± 18.0	100.3 ± 27.1	0.205
Healing time ($\mu \pm \sigma$, month)	3.9 ± 1.2	3.8 ± 1.1	0.805
Complication [no. (%)]	35 (76.1)	2 (6.9)	<0.001
KSS score (clinic, IQR)	90 (84, 95)	99 (97, 100)	<0.001
KSS score (function, IQR)	90 (65, 90)	100 (90, 100)	<0.001

KSS, knee society score; IQR, Interquartile range.

TABLE 3 | The primary outcome and secondary outcome.

	Traditional group (*N* = 46)	Modified group (*N* = 29)	*p*-value
Complication [no. (%)]	35 (76.1)	2 (6.9)	<0.001
Primary outcome			
Rotation of K-wires [no. (%)]	35 (76.1)	0 (0)	<0.001
Secondary outcome			
Simple rotation [no. (%)]	14 (30.4)	0 (0)	0.001
Cable unhooking [no. (%)]	18 (39.1)	1 (3.4)	0.001
Fixation breakage [no. (%)]	1 (2.2)	1 (3.4)	1.000
Skin ulceration [no. (%)]	4 (8.7)	0 (0)	0.269
Skin irritability [no. (%)]	24 (52.2)	0 (0)	<0.001

cannulated lag screws with tension band wiring was not found suitable for the biomechanical test and showed a displacement of 2.8 mm after 100 cycles, and this meant implant failure (10). Also, in comminuted patellar fractures, there may not be enough space for the screws to hold. These screws may cause excessive bone loss and additional risk of fracture and make it difficult to fix a small patellar (17, 18). So, screws cannot be used in all types of patellar fractures. In contrast, K-wires have been found to be superior to screws at this point of time. We can even use 1.4-mm K-wires to fix small fragments. Huang et al. supposed that K-wires are essential in the treatment of comminuted patellar fracture, because these wires have the ability to turn comminuted fractures into simple fractures, and they concluded that if there is no K-wire fixation, displacement can easily occur (19). The sturdiness of the tension band with K-wires was testified in a mass of articles and clinical practices (20, 21). With increased movement of the knee in some patients, K-wires will rotate in these patients. In our study, most patients suffered the rotation of K-wires in the first 3 months after operation. From 3 weeks to 3 months after operation, there was swelling of the knee, and it increased over time. Some elderly patients delayed the inevitable by opting for rehabilitation later than 3 months after operation. The rotation of K-wires may lead to a stimulation of the skins of the front knee and also ulceration up to 40% of patients (22). Our data showed that in the traditional method group, 52.2% (24 of 46) patients suffered skin irritability and 8.7% (4 of 46) patients suffered skin ulceration. These complications may hinder rehabilitation. But we found that not all K-wire-rotation patients experienced hardware stimulation. This may be due to the fact that not all rotated K-wires were bent too much or the subcutaneous tissue in front of the patellar in some patients was thicker. To prevent the rotation of the K-wires, we bent the proximal part of the wires to 180° and knocked the bent part into the upper extreme of the patellar. This will enable the fixing of K-wires with the patellar and preventing their rotation. To achieve this objective, we drilled a hole at the point where the bent part will be knocked in at the superior extreme of the patellar with 2.5-mm K-wires after the 2.0-mm K-wires fixed the main fragments. To avoid the titanium cable or stainless-steel cable slipping from the K-wires, we should keep enough K-wires out of the patellar. But the outside part should not be too long to stimulate the skin. In our experience, the appropriate length of the outside part of the K-wires should be 5 mm. The inside part of the K-wires knocked into the patellar should not be too short, else the loop will be overloaded and will crack. Sufficient inside part length can also increase the fixation stability. At least 5-mm wires are recommended on the basis of our experience.

According to **Table 2**, the average operating time of the modified method was similar to that of the traditional method. Compared with the traditional method, we added the procedures of drilling two holes in the upper extreme of the patellar, knocking the K-wires into the holes and bending the wires to 180°. Usually, these procedures might consume some time, but in our case, the time taken was not long (usually 1–3 min). The amount of blood loss in the modified method group was a little more than in the traditional method, but no statistical difference was found between the two groups. To drill the two holes, a 0.5- to 1-cm long incision had to be made, and this left open the possibility of causing more blood loss during operation. However, the core data of operation between the two groups were similar, so the safety of the modified method was in no way less than that of the traditional method.

Some scholars supposed that the K-wire tension band technique cannot fix comminuted patellar fractures because

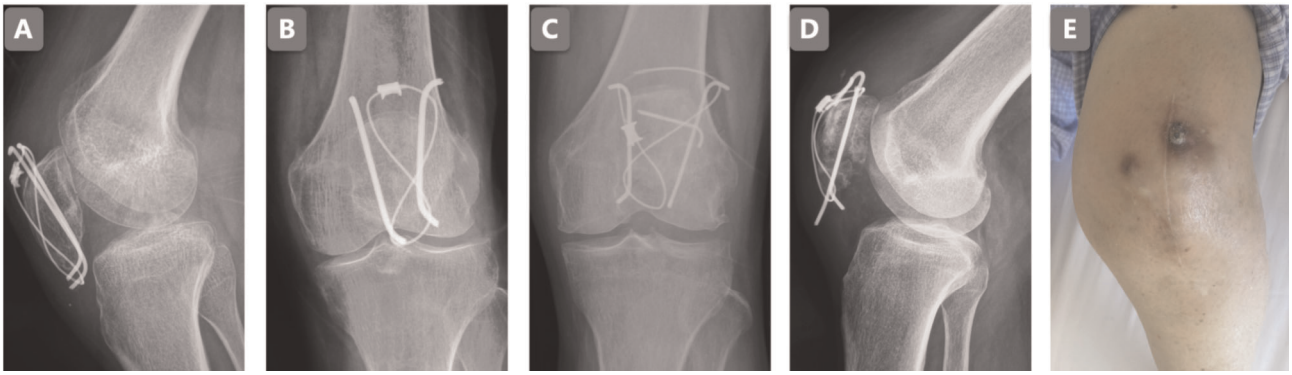

FIGURE 4 | Complications: simple rotation (**A**); cable unhooking (**B**); cable breakage (**C**); K-wire breakage (**D**); skin ulceration (**E**).

K-wires do not have sufficient thickness (11), but in our study, we did not find any knee displacement using the modified method during the follow-up, especially in C3-type patellar fractures. Our study result revealed that the KSS score 1 year after surgery in the modified method group was significantly higher than that in the traditional method group. Due to the bending of the K-wires and their embedding into the patellar, their rotation was avoided. To avoid irritation from K-wires, the bent part of the wires should not be left outside of the patellar too much, but if left too short, the cable might unhook from the K-wires. Because we adopted this modified procedure, we did not see any rotation of the K-wires in patients who belonged to the modified method group. So, when these patients underwent rehabilitation and were put in an exercise regimen after the operation, they did not experience any skin irritation symptoms due to the rotation of the K-wires. No limits were imposed during their rehabilitation, and the more the rehabilitation, the higher was the KSS score. But in long-term observation, patients in the traditional group cannot enjoy the advantages offered by the modified method, especially after they remove the internal fixator placed on them.

One patient in the modified method group suffered K-wire breakage, and one patient in the traditional method group suffered titanium cable breakage. In the former group, we found that the breakage was associated with the 180° bending of the K-wires. The K-wires we used were made of titanium. When K-wires made of titanium are bent to a such high degree, the mechanical strength would decline sharply. In the process of flexion–extension, the K-wires might break.

CONCLUSION

Based on the present results, we can state that our modified method could effectively avoid the rotation of K-wires, provide improved knee function at 12 months after surgery, and reduce complications resulting from such rotation. Our modified method is easy to perform and may provide a better clinical choice in the treatment of patellar fractures. However, the issue of K-wire breakage due to buckling needs to be addressed. Meanwhile, a prospective randomized controlled trial with a larger sample size is needed to further confirm our results.

DATA AVAILABILITY STATEMENT

The raw data supporting the conclusions of this article will be made available by the authors, without undue reservation.

ETHICS STATEMENT

The studies involving human participants were reviewed and approved by The protocol of this study was reviewed and approved by the Institutional Review Board of Beijing Hospital (2018BJYYEC-032-05). Written informed consent for participation was not required for this study in accordance with the national legislation and the institutional requirements.

AUTHOR CONTRIBUTIONS

FS and YZ were responsible for drafting the manuscript and analyzing the data. QJ, TZ, YZ, ZZ, and RH were responsible for doing the literature search. LW was responsible for the research design, review, and quality supervision of the manuscript. All authors contributed to the article and approved the submitted version.

FUNDING

This study was supported by the Beijing Hospital Clinical Research 121 Project (BJ-2018-087).

REFERENCES

1. Melvin JS, Mehta S. Patellar fractures in adults. *J Am Acad Orthop Surg*. (2011) 19(4):198. doi: 10.5435/00124635-201104000-00004
2. Sermon A. AO principles of fracture management. *Acta Chir Belg*. (2018).
3. Sayum Filho J, Lenza M, Tamaoki MJ, Matsunaga FT, Belloti JC. Interventions for treating fractures of the patella in adults. *Cochrane Database Syst Rev*. (2021) 2(2):Cd009651. doi: 10.1002/14651858.CD009651.pub3
4. Kim Y, Kwon M, Ryu JY, Moon SW. Biomechanical analysis of the Kirschner-wire depth of the modified tension band wiring technique in transverse patellar fractures: an experimental study using the finite-element method. *Clin Orthop Surg*. (2021) 13(3):315–9. doi: 10.4055/cios20253
5. Schnabel B, Scharf M, Schwieger K, Windolf M, Pol Bv, Braunstein V, et al. Biomechanical comparison of a new staple technique with tension band wiring for transverse patella fractures. *Clin Biomech*. (2009). doi: 10.1016/j.clinbiomech.2009.08.002
6. Tian QX, Hai Y, Du XR, Xu ZY, Lu T, Shan L, et al. Comparison of tension-band wiring with the cable pin system in patella fractures. *J Orthop Trauma*. (2015) 29(12):e459–63. doi: 10.1097/BOT.0000000000000400
7. Hoshino CM, Tran W, Tiberi JV, Black MH, Li BH, Gold SM, et al. Complications following tension-band fixation of patellar fractures with cannulated screws compared with Kirschner wires. *J Bone Joint Surg Ser A*. (2013) 95(7):653–9. doi: 10.2106/JBJS.K.01549
8. Jastifer JR, Gustafson PA, Silva LF, Noffsinger S, Coughlin MJ. Nitinol, stainless steel, and titanium Kirschner wire durability. *Foot Ankle Spec*. (2021) 14(4):317–23. doi: 10.1177/1938640020914677
9. Unnanuntana A, Rebolledo BJ, Khair MM, DiCarlo EF, Lane JM. Diseases affecting bone quality: beyond osteoporosis. *Clin Orthop Relat Res*. (2011) 469(8): 2194–206. doi: 10.1007/s11999-010-1694-9
10. Wagner FC, Neumann MV, Wolf S, Jonaszik A, Izadpanah K, Piatek S, et al. Biomechanical comparison of a 3.5 mm anterior locking plate to cannulated screws with anterior tension band wiring in comminuted patellar fractures. *Injury*. (2020) 51(6):1281–7. doi: 10.1016/j.injury.2020.03.030
11. Thelen S, Schneppendahl J, Baumgärtner R, Eichler C, Koebke J, Betsch M, et al. Cyclic long-term loading of a bilateral fixed-angle plate in comparison with tension band wiring with K-wires or cannulated screws in transverse patella fractures. *Knee Surg Sports Traumatol Arthrosc*. (2013) 21(2):311–7. doi: 10.1007/s00167-012-1999-1
12. Thelen S, Betsch M, Schneppendahl J, Grassmann J, Hakimi M, Eichler C, et al. Fixation of multifragmentary patella fractures using a bilateral fixed-angle plate. *Orthopedics*. (2013) 36(11): E1437–43. doi: 10.3928/01477447-20131021-29
13. Thelen S, Schneppendahl J, Jopen E, Eichler C, Koebke J, Schönau E, et al. Biomechanical cadaver testing of a fixed-angle plate in comparison to tension wiring and screw fixation in transverse patella fractures. *Inj Int J Care Inj*. (2012) 43(8):1290–5. doi: 10.1016/j.injury.2012.04.020
14. Wurm S, Bühren V, Augat P. Treating patella fractures with a locking patella plate - first clinical results. *Inj Int J Care Inj*. (2018) 49:S51–5. doi: 10.1016/j.injury.2017.11.033
15. Lee KH, Lee Y, Lee YH, Cho BW, Kim MB, Baek GH. Biomechanical comparison of three tension band wiring techniques for transverse fracture of patella: Kirschner wires, cannulated screws, and ring pins. *J Orthop Surg (Hong Kong)*. (2019) 27(3): 2309499019882140. doi: 10.1177/2309499019882140
16. Wild M, Eichler C, Thelen S, Jungbluth P, Windolf J, Hakimi M. Fixed-angle plate osteosynthesis of the patella - an alternative to tension wiring? *Clin Biomech*. (2010) 25(4): 341–7. doi: 10.1016/j.clinbiomech.2009.12.010
17. Kakazu R, Archdeacon MT. *Surgical management of patellar fractures*. Orthopedic Clinics of North America (2016).
18. Shang P, Zhang L, Hou Z, Bai X, Ye X, Xu Z, et al. Morphometric measurement of the patella on 3D model reconstructed from CT scan images for the southern Chinese population. *Chin Med J*. (2014) 127(1):96–101.
19. Huang SL, Xue JL, Gao ZQ, Lan BS. Management of patellar fracture with titanium cable cerclage. *Medicine*. (2017) 96(44):e8525. doi: 10.1097/MD.0000000000008525
20. Fortis AP, Milis Z, Kostopoulos V, Tsantzalis S, Kormas P, Tzinieris N, et al. Experimental investigation of the tension band in fractures of the patella. *Injury*. (2002) 33(6):489–93. doi: 10.1016/S0020-1383(01)00173-5
21. Ali M, Kuiper J, John J. Biomechanical analysis of tension band wiring (TBW) of transverse fractures of patella. *Chin J Traumatol* (2016). doi: 10.1016/j.cjtee.2016.06.009
22. Tan H, Dai P, Yuan Y. Clinical results of treatment using a modified K-wire tension band versus a cannulated screw tension band in transverse patella fractures: a strobe-compliant retrospective observational study. *Medicine*. (2016) 95(40):e4992. doi: 10.1097/MD.0000000000004992

Conflict of Interest: The authors declare that the research was conducted in the absence of any commercial or financial relationships that could be construed as a potential conflict of interest.

Publisher's Note: All claims expressed in this article are solely those of the authors and do not necessarily represent those of their affiliated organizations, or those of the publisher, the editors and the reviewers. Any product that may be evaluated in this article, or claim that may be made by its manufacturer, is not guaranteed or endorsed by the publisher.

Copyright © 2022 Sun, Zhang, Ji, Zhang, Zhu, Zhang, Han and Wen. This is an open-access article distributed under the terms of the Creative Commons Attribution License (CC BY). The use, distribution or reproduction in other forums is permitted, provided the original author(s) and the copyright owner(s) are credited and that the original publication in this journal is cited, in accordance with accepted academic practice. No use, distribution or reproduction is permitted which does not comply with these terms.

frontiers | Frontiers in Surgery

ORIGINAL RESEARCH
published: 25 May 2022
doi: 10.3389/fsurg.2022.911141

A comparative Study of Novel Extramedullary Fixation and Dynamic Hip Screw in the Fixation of Intertrochanteric Fracture: A Finite-Element Analysis

Kai Ding[1,2†], Yanbin Zhu[1,2†], Haicheng Wang[1,2], Yonglong Li[1,2], Weijie Yang[1,2], Xiaodong Cheng[1,2], Yingze Zhang[1,2,3,4], Wei Chen[1,2,3] and Qi Zhang[1,2]**

[1]Trauma Emergency Center, The Third Hospital of Hebei Medical University, Shijiazhuang, China, [2]Key Laboratory of Biomechanics of Hebei Province, Orthopaedic Research Institute of Hebei Province, Shijiazhuang, China, [3]NHC Key Laboratory of Intelligent Orthopaedic Equipment, the third hospital of hebei medical university, Shijiazhuang, China, [4]Chinese Academy of Engineering, Bingjiaokou Hutong, Beijing, China

OPEN ACCESS

Edited by:
Paphon Sa-ngasoongsong, Mahidol University, Thailand

Reviewed by:
Nattapon Chantarapanich, Kasetsart University, Thailand
Junlin Zhou, Beijing Chaoyang Hospital, Capital Medical University, China

***Correspondence:**
Qi Zhang
drzhangqi1@163.com

†These authors have contributed equally to this work

Specialty section:
This article was submitted to Orthopedic Surgery, a section of the journal Frontiers in Surgery

Received: 02 April 2022
Accepted: 02 May 2022
Published: 25 May 2022

Citation:
Ding K, Zhu Y, Wang H, Li Y, Yang W, Cheng X, Zhang Y, Chen W and Zhang Q (2022) A comparative Study of Novel Extramedullary Fixation and Dynamic Hip Screw in the Fixation of Intertrochanteric Fracture: A Finite-Element Analysis. Front. Surg. 9:911141. doi: 10.3389/fsurg.2022.911141

Background: Dynamic hip screw (DHS) is one of the most widely internal fixations for stabilizing intertrochanteric fracture, however, with a high risk of postoperative complications. The triangle support fixation plate (TSFP) is developed to reduce the postoperative complications. The purpose of study is to evaluate the biomechanical performance of the DHS and TSFP and demonstrate the rationality of triangular internal fixation for stabilizing intertrochanteric fractures.

Methods: The CT data of the proximal femur were used to establish finite-element models. Evans type I and IV intertrochanteric fracture were constructed and stabilized with the DHS and TSFP. The Von-Mises stress, maximum principal stress, minimum principal stress, and displacement were used to evaluate the biomechanical effect of two implants on intertrochanteric fracture.

Results: Under a 600N axial load, the maximum stress and displacement of an intact proximal femur were 13.78 MPa and 1.33 mm, respectively. The peak stresses of the bone in the TSFP were 35.41 MPa and 68.97 MPa for treating Evans type I and IV intertrochanteric fractures, respectively, which were lower than those in the DHS. The maximum overall displacement and relative distance of the fracture surface in the DHS fixation model were 1.66 mm and 0.10 mm for treating Evans type I intertrochanteric fracture, which was 29.59% and 150% higher than that in the TSFP, and were 2.24 mm and 0.75 mm for treating Evans type IV intertrochanteric fracture, which was 42.58% and 650% higher than that in the TSFP.

Conclusions: In conclusion, the TSFP has obvious advantages in stress distribution and stability than the DHS, providing a promising option for the treatment of intertrochanteric fractures.

Keywords: triangular structure, intertrochanteric fracture, finite-element analysis, biomechanical performance, DHS, TSFP

INTRODUCTION

As an osteoporosis-directly-related fracture, intertrochanteric fracture is highly prevalent in the elderly, accounting for approximately 3.4% of all fractures, and is expected to reach 4.6 million worldwide by the year 2050 (1, 2). Compared with the other type of hip fracture, femoral neck fracture, intertrochanteric fractures are associated with a higher risk of postoperative complications including mortality, with the latter reported at rates ranging from 11% to 29% within one year (3–6). Early surgical treatment within 24–48 h after injury is recommended as the standard intervention method to achieve quick functional recovery and reduced postoperative complications (7).

Among various operative methods, open reduction with DHS fixation is considered the gold standard for the treatment of stable intertrochanteric fractures (8–10). From the point of view of biomechanics, the DHS and other techniques reconstruct the anatomical structure of the tension trabeculae, and the fulcrum shifts outward, increasing the length of the force arm. The above internal fixation does not reconstruct the fracture of the tension line of the proximal femur (11, 12). Even if a slight load is applied to the femoral head, it can be amplified at the nail and plate, which can easily cause backout and hip inversion. Due to the limitations of the DHS per se in design, the DHS is related to various postoperative complications, including withdrawal, cut-out, and varus collapse, with fixation-failure rates of 1.5%–21%. It is suggested that posteromedial cortical integrity is critical to the clinical prognosis for the DHS fixing intertrochanteric fractures (13–16). In addition, lateral cortical integrity contributes greatly to stability, and the loss of lateral cortical integrity is reported to be associated with up to a 6-time risk of reoperation (10, 17).

Analyses of these failure cases indicated that the single fixation screw of the DHS could not support adequate force to counteract the fractured trabeculae, leading to direct hardware-related complications, and the ideal internal fixation devices should first be able to address this problem.

In this study, we will present our innovation, the TSFP, where the supporting screw is added to form a stable triangular structure with the main plate and fixing screw, thus enhancing the ability to resist the tension and compression force at the proximal femur (18–21). In 2009, our research team first proposed the concept of triangular support fixation that the anti-tension screw was added to form a double triangular structure with the main plate and anticompression screw (18, 19), and 3 Chinese granted patents were obtained (ZL200920254063.4, ZL200920254062.x, ZL201120370391.8). Theatrically, this will reduce the dependence on posteromedial and lateral cortical integrity and further minimize the occurrence of hardware-related complications.

In this study, our main aim was to compare the stress distribution and stability of two implant fixation models by using finite-element analysis and verify whether the innovated triangular support fixation could have superior biomechanics of intertrochanteric fractures compared with the traditional DHS. Finite-Element Analysis (FEA) is a numerical analysis method to simulate the real physical system (geometry and load conditions) by using mathematical approximation. It is widely used in the trauma field because of its advantages of simple operation, convenient model acquisition, and strong experimental reliability (11, 12, 22).

METHODS AND MATERIAL

The study protocol was approved by the Institutional Review Board (IRB) and conformed to the provisions of the Declaration of Helsinki. Written informed consent was obtained from the volunteers prior to the study commencement.

Three-Dimensional Models

A healthy volunteer (male, age 27 years, height 173 cm, and body weight 60 kg) without a history of lower extremity injury was included. The volunteer underwent a 64 slice spiral CT scan (SOMATOM Definition AS Siemens, Germany) with a slice of 0.625 mm from the hip joint to the knee joint. The CT data were used to establish a three-dimensional model of the proximal femur in Mimics 21.0 (Materialise company, Leuven,). The proximal femoral model was imported into Geomagic 13.0 (Geomagic company, USA) to generate the solid models. Hypermesh 2014 (Altair Company, USA) was used to mesh the solid model with C3D4 elements.

According to their real dimensions, the DHS and TSFP were constructed by UG-NX 12.0 (Siemens Company, USA). The length, dimension, and angle of the DHS and TSFP are demonstrated in **Figure 1** (**Figures 1**, **2**). We considered Evans I and IV intertrochanteric fractures as typically stable and unstable intertrochanteric fractures, respectively. To brief the research plan of this study, Evans type I and IV intertrochanteric fractures were included. These fractures were created and stabilized with the DHS and TSFP in UG-NX 12.0, respectively. The key point of the TSFP was an added supporting screw, which constituted a cross-structure with the locking screw through the fitting hole (sliding hole or threaded hole), forming a double triangle fixation of the main plate, locking screw, and supporting screw in a three-dimensional space.

Material Properties

The models were imported into Abaqus6.14(Dassault Systèmes Solid Works Corp., Concord, MA, USA). The bone and implant were set as homogeneous, isotropic, and linear elastic materials. On the basis of previous literature, the Young's modulus of the cortical and cancellous bone was 17 GPa and 1.5 GPa, while the Poisson's ratio was 0.3 for both (23, 24). The Young's modulus and Poisson's ratio of the implant were 110 GPa and 0.316 (25), respectively.

Boundary Conditions

The full bonding was used as an interface between the supporting screw, fixating screw, and main plate in the TSFP model. The interfaces between the screw and the plate were assumed as fully bonding in the DHS model. The tied

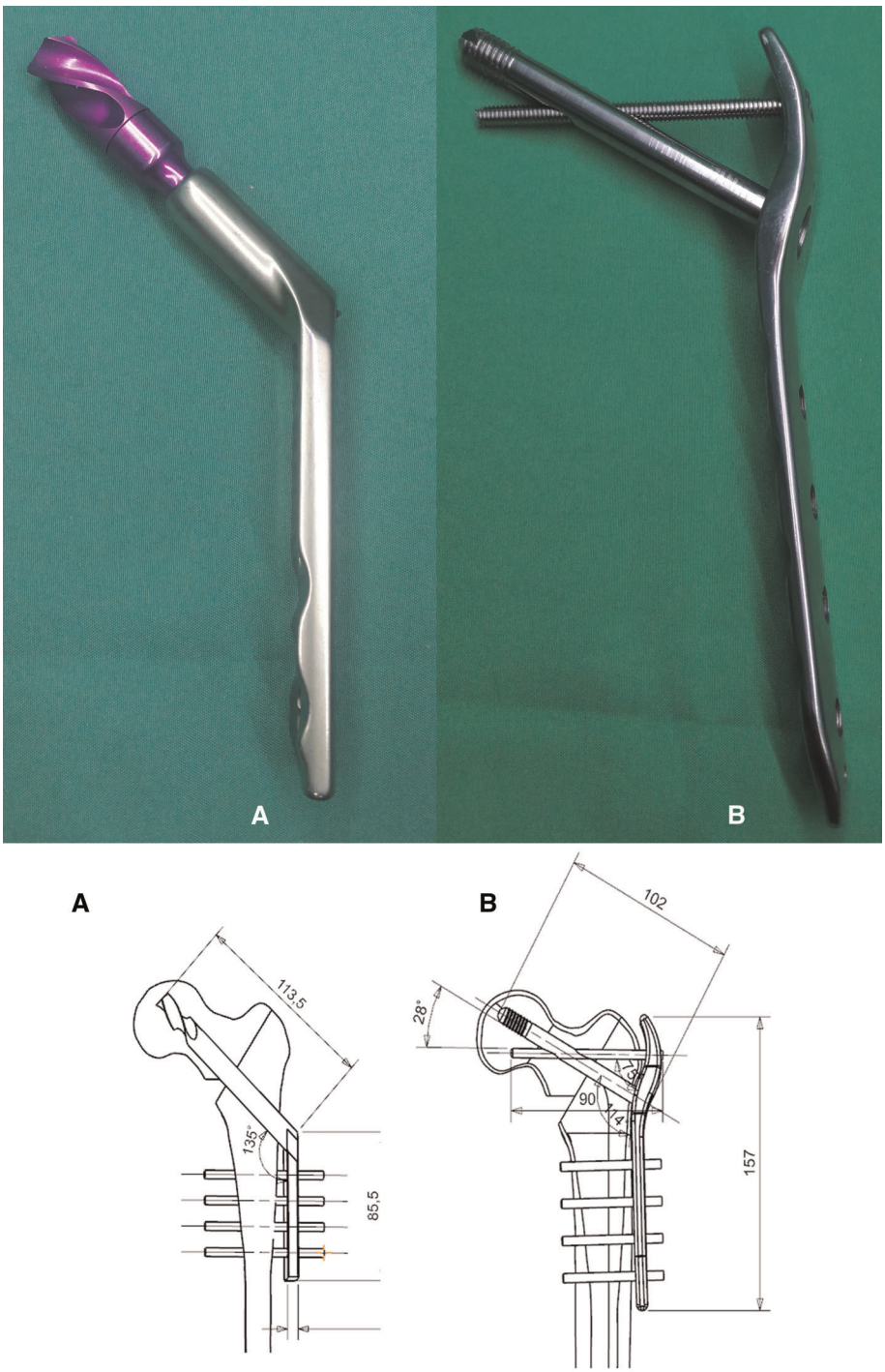

FIGURE 1 | Diagram, detail, and specifications of internal fixation devices; (**A**) DHS; and (**B**) TSFP.

interactions between screw thread/bone and screw/ cortical bone were used to mimic the holding force. Other bone–screw and bone–bone interfaces were assumed as surface-to-surface contact relation. The friction coefficient was set as 0.3 (18, 26, 27). In this experiment, loads were applied using distributed coupling constraints. A concentrated force load was applied at the reference point, i.e., vertically above the femoral head. All construct models were applied with a load of 600N (one leg standing load force). The distal end of the femoral model was completely fixed in all degrees of freedom (**Figure 3**).

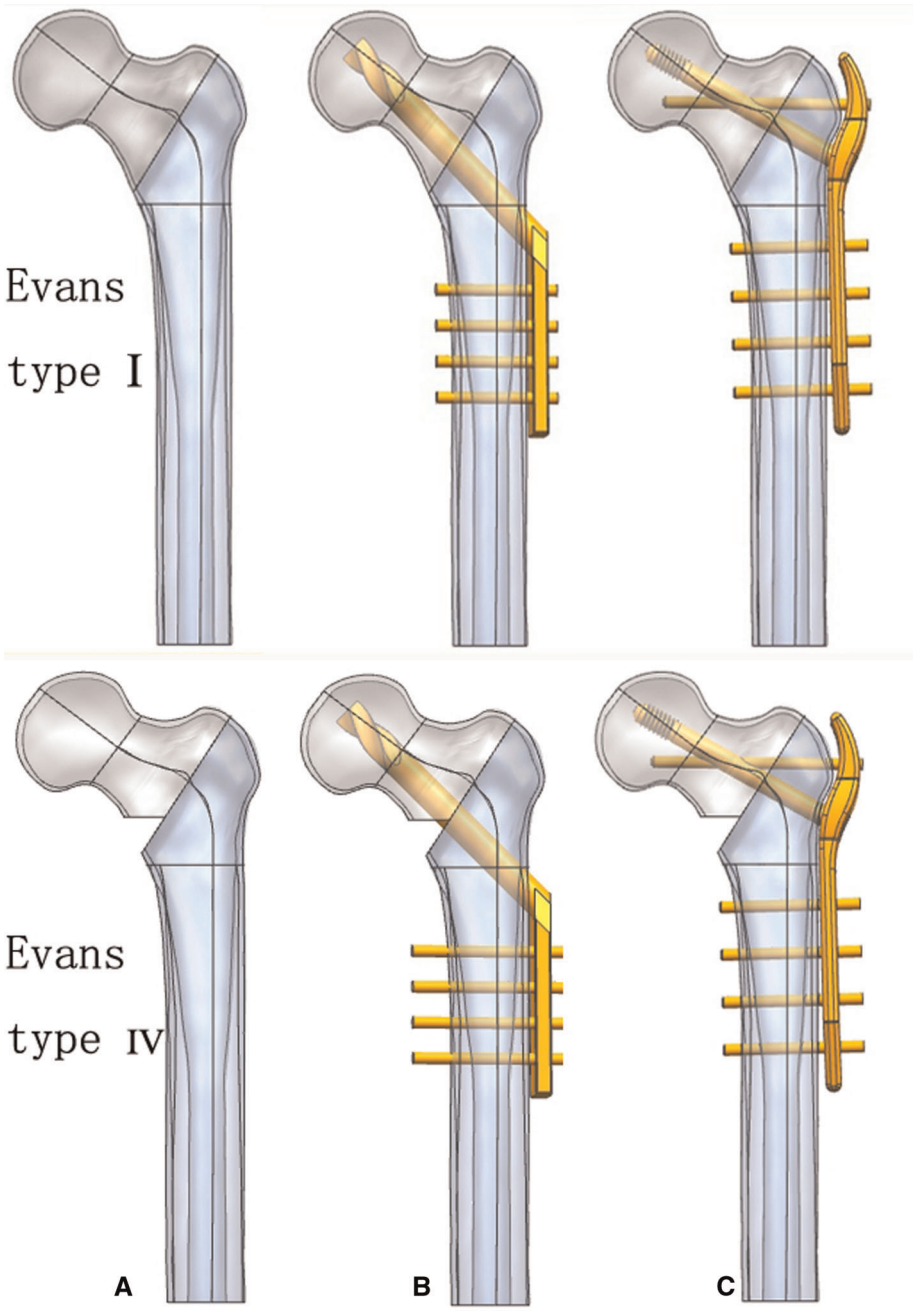

FIGURE 2 | Geometric modeling of stable and unstable intertrochanteric fracture models and three implant fixation models; (**A**) the Evans type I and IV intertrochanteric fractures; (**B**) DHS fixation model; and (**C**) TSFP fixation model.

Validation of Finite-Element Models

In this study, we tested the maximum von-Mises stress on the cancellous and cortical bones of the proximal femur to analyze mesh convergence and validate the model. The selected method was widely used in the convergence test (27, 28). The convergence criterion used was a change of <5%. The final model was made of 7,564 nodes and 93,332 elements (mesh size: 2 mm) (**Figure 4**).

The finite-element model was validated with a biomechanical study where the proximal femoral bone was fixed under the same boundary conditions. Femur specimens were selected from donated male cadavers. Specimens with rheumatism,



FIGURE 3 | Boundary conditions of the models.

tuberculosis, tumors, or abnormal bone quality were excluded using imaging examinations. The biomechanical testing machine (BOSE ElectroForce 3520-AT, BOSE Company, USA) was used to apply load. A 16-channel stress–strain tester (m + p, Hannover, Germany) and strain gauges (BF3503AA, Chengdu, China) were used to detect and record the stains of marker points. The strain values of nine marked points in the specimen were collected to compare with those in the finite-element analysis. From the comparison of the results, we found that our finite-element model of proximal femur was reliable and effective (**Figures 5**, **6** and **Table 1**).

RESULTS

The Von Mises Stress and Displacement Distribution of the Intact Bone

The maximum stress of the intact bone was 13.78 MPa, which was located at the medial femoral cortex. The maximum stress of the lateral femoral cortex was 6.31 MPa. The maximum displacement was 1.33 mm (**Figure 7**).

The Von Mises Stress, Maximum Principal Stress, and Minimum Principal Stress Distribution of the DHS and TSFP Models for the Fixation of Evans Type I and IV Intertrochanteric Fracture

For the DHS and TSFP groups, a stress concentration of the medial and lateral femoral cortex occurred around the fracture and the hole adjacent to the main plate, respectively. The Von Mises stress, maximum principal stress, and minimum principal stress concentration of the DHS were located at the junction of the fixation screw and plate and those of the TSFP were placed on the junction of the supporting screw, fixating screw, and main plate.

For Evans type I intertrochanteric fracture, the maximum mises stresses of the medial cortex, lateral cortex, and implant in the DHS were 1.19 times, 2.55 times, and 1.15 times greater than those in the TSFP, respectively. The DHS was 1.08 times and 1.11 times as much minimum and maximum principal stress extreme as the TSFP (**Figures 8–11** and **Tables 2–4**).

For Evans type IV intertrochanteric fracture, the maximum mises stresses of the medial cortex, lateral cortex, and implant in the DHS were 41.66%, 4.99 times, and 1.70 times as much as that in the TSFP, respectively. The DHS was 1.51 times and 1.65 times as much minimum and maximum principal stress extreme as the TSFP (**Figures 8–11** and **Tables 2–4**).

The Displacement Distribution of Two Implants for Treatment of Evans Type I and IV Intertrochanteric Fracture

For two variations, the maximum displacement values of the DHS for stabilizing Evans type I and IV intertrochanteric fractures were 1.66 mm and 2.24 mm and those of the TSFP were 1.28 mm and 1.57 mm, respectively.

The maximum relative displacements of the fracture surface of the DHS for fixing Evans type I and IV intertrochanteric fractures were 0.10 mm and 0.75 mm, respectively, and those of the TSFP were 0.04 mm and 0.10 mm, respectively (**Figures 8**, **9** and **Tables 2**, **3**).

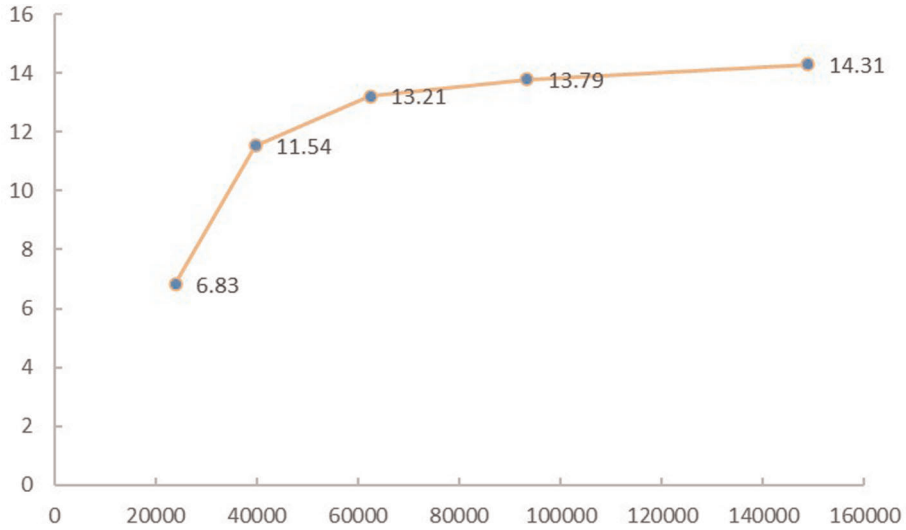

FIGURE 4 | The von Mises stress on the cancellous and cortical bone of the proximal femur was tested to analyze the mesh convergence and validate the model.

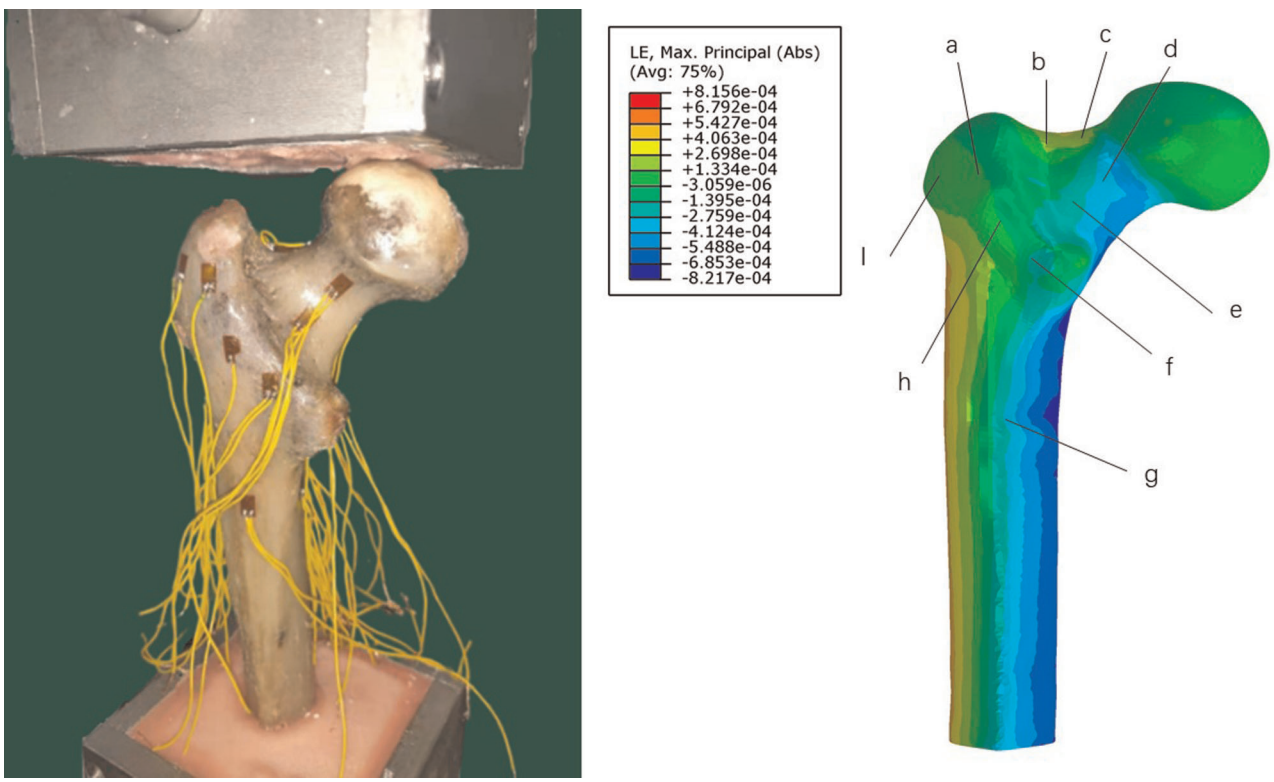

FIGURE 5 | Results of the validated experiment. (**A**): biomechanical study; and (**B**): finite-analysis element.

DISCUSSION

In the current study, we found that the TSFP showed superior biomechanical performances, including reducing the reliance of the DHS on the posteromedial and lateral femoral cortex, increasing the construct stability, and improving the stress distribution of the implant. The main reason for the improved biomechanics of the implant construct model is the cross structure of the supporting and fixating screws. The concept of triangular support fixation would be important to improve

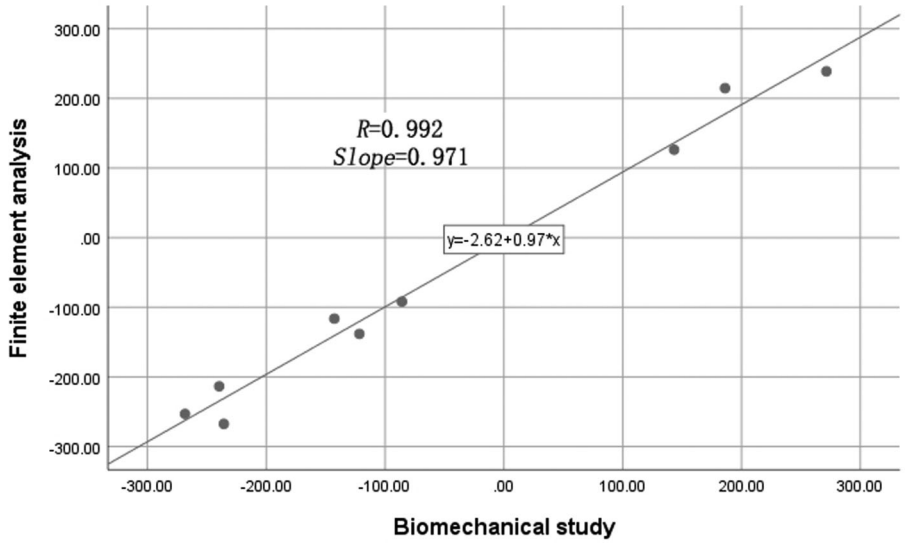

FIGURE 6 | Recording the strain value of marker points in the biomechanical study and finite-element analysis.

TABLE 1 | The strain values of the biomechanical test and finite-element analysis (10^{-6}).

Maker point	a	b	c	d	e	f	g	h	i
Finite-element analysis	126.32	238.87	214.65	−253.24	−116.37	−267.54	−213.54	−91.94	−138.25
Biomechanical study	143.26	271.46	186.15	−268.39	−142.74	−235.74	−239.62	−85.83	−121.62

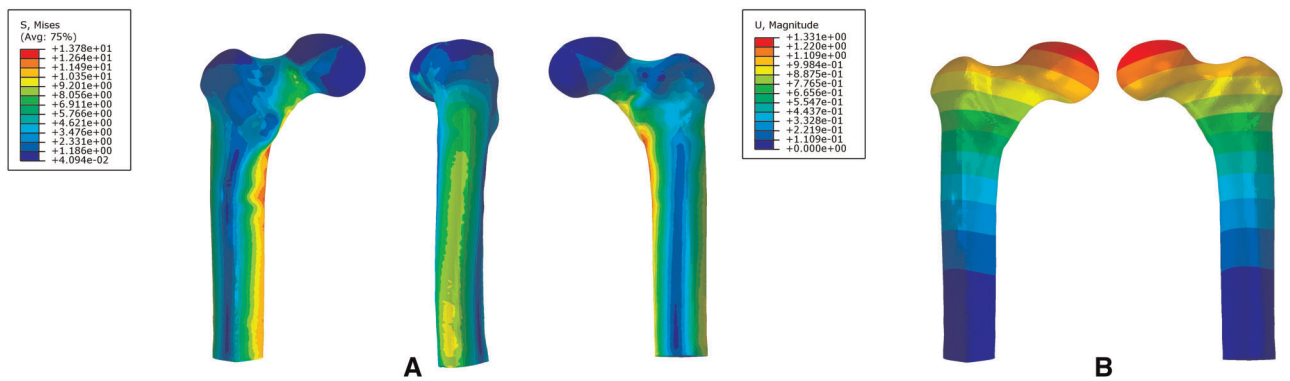

FIGURE 7 | The stress distribution (**A**) and displacement distribution (**B**) of an intact proximal femur.

clinical outcomes and reduce postoperative complications in treating various intertrochanteric fractures.

The TSFP provides a better biomechanical performance than the DHS in terms of mechanical aspects. This is due to the unique double triangular structure of the TSFP. First, the first triangle is composed of the cancellous bone of the femoral head, supporting screw, and fixing screw, which is called a mixed triangle. The second triangle, called a metal triangle, is constructed by simulating the triangular cantilever structure of the proximal femur which is made up of the supporting screw, fixing screw, and main plate. The fixing and supporting screws are kept in line with the spatial position and orientation of the trabecular system of the proximal femur. According to our result, the TSFP has less relative distance of fracture section, which shows that the mixed triangular structure can obviously improve the holding force of the fracture fragment. Secondly, the metal triangle plays the similar role of the screw-plate joint of the DHS, and three fulcrums of the metal triangle greatly disperse the stress concentration of the screw-plate joint. Moreover, the supporting screw and main plate together support the fixing

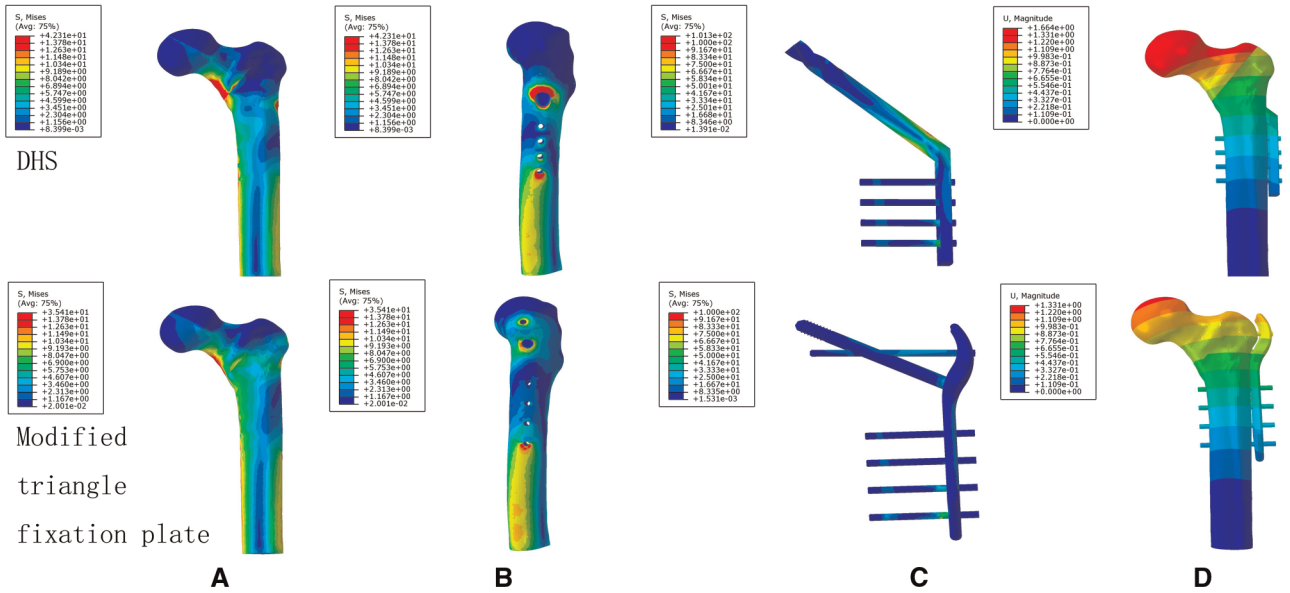

FIGURE 8 | The stress distribution and displacement distribution of two implant fixations of a stable intertrochanteric fracture; (**A**) the stress distribution of bone models; (**B**) the stress distribution of the lateral femoral cortex; (**C**) the stress distribution of an implant model; (**D**) the displacement distribution of three implant fixation models. The figure shows that the TSFP has improved the stress distribution of the implant and bone models and increased the construct stability of the fixation of Evans type I intertrochanteric fracture.

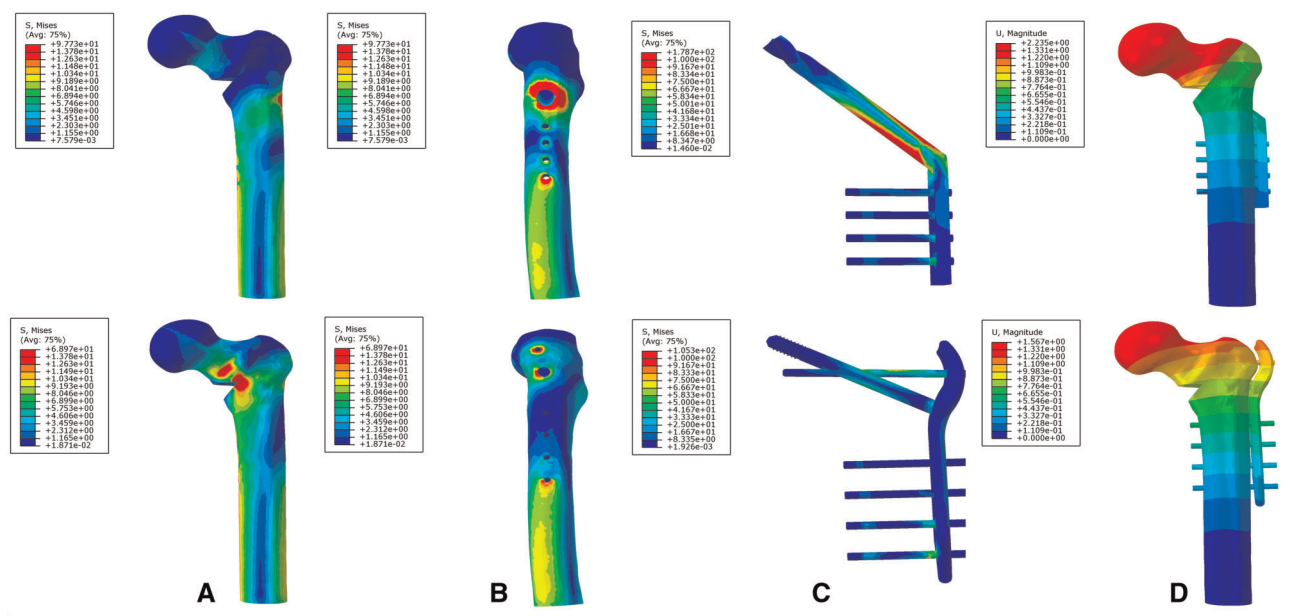

FIGURE 9 | The stress distribution and displacement distribution of two implant fixations of an unstable intertrochanteric fracture; (**A**) the stress distribution of bone models; (**B**) the stress distribution of the lateral femoral cortex; (**C**) the stress distribution of an implant model; (**D**) the displacement distribution of three implant fixation models. The figure shows that the TSFP has improved the stress distribution of the implant and bone models and increased the construct stability of the fixation of Evans type IV intertrochanteric fracture.

screw, forming a double-pivot fixation to improve the overall stability of the intertrochanteric fracture. The triangle structure of the TSFP has better resistance to the tension and compression force in the proximal femur than the single fixing screw, reducing tension and compression force component to the femur which has lower requirement on the integrity of femoral posteromedial and lateral cortex. The double triangular structure perfectly solves the stress concentration of the

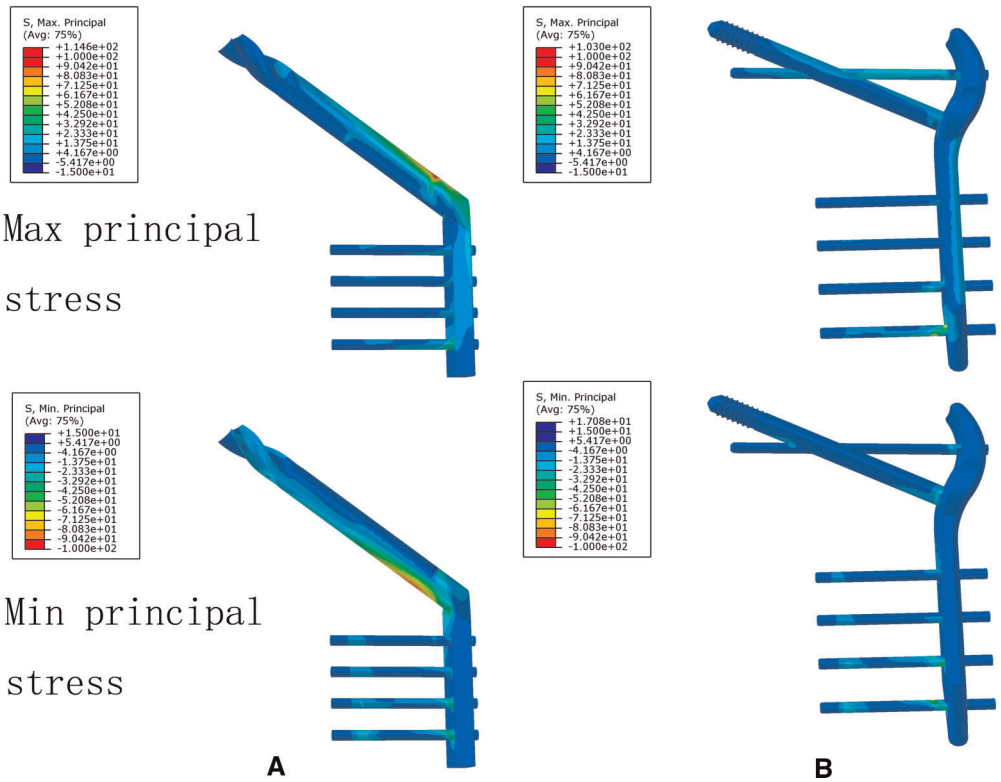

FIGURE 10 | The maximum principal stress and minimum principal stress extremes of two implant models for the treatment of a stable intertrochanteric fracture. The figure shows that the TSFP has improved the maximum principal stress distribution compared with DHS for the fixation of Evans type I intertrochanteric fracture.

screw-plate junction, reduces excessive dependence on the posteromedial and lateral cortex, and increases the stability of the fracture fixation model compared with the DHS, which has important clinical implications for reducing the risk of postoperative reduction loss, varus collapse, screw cut-out, and so on.

The biomechanical difference between the DHS and the TSFP was a result of varying the fixation mechanism for intertrochanteric fracture. The fixation mechanism of the DHS for intertrochanteric fracture was summarized as "two points and one line." That is, one line is the fixing screw, and the two points are the posteromedial and lateral cortex of the proximal femur. Due to a huge bending moment of the proximal femur, body loading was transmitted to the tension and compression force, which single fixation screw could not fully counteract. Also, the posteromedial and lateral cortex in the proximal femur act as fulcrums to counteract the tension and compression force component, respectively. Biomechanically, only if the support of both posteromedial and lateral femoral cortex is maintained, the DHS fixation of intertrochanteric fractures will be safe (29). Therefore, the peak stresses of the posteromedial and lateral femoral cortex in the DHS fixation model were 42% and 4.99 times of those in the TSFP for treating an unstable intertrochanteric fracture, which could be explained by the fact that the DHS construct model had a higher instability and separation of the fracture fragment than that of the TSFP with the loss of the posteromedial femoral cortex. The triangle structure is more suitable for intertrochanteric fracture than for a single fixing screw.

The literature review showed that clinical effects were increasing with the continuous development of extramedullary devices from the DHS to the MSP (Medoff sliding plate) and the LCP to the PCCP (percutaneous compression plating system) (30). However, the above instrument was not currently used for the main treatment of intertrochanteric fracture. Although the MSP and LCP increased the construct stability and reduced the risk of fixation-related complications, intraoperative soft tissue dissection and bleeding were difficult to avoid because of the complex surgical procedure (31–33). The PCCP achieved a minimally invasive procedure, but its double parallel lag screw still could not solve the long lever arm and stress concentration of the screw-plate junction (34, 35). Intramedullary fixation has gradually become the mainstream treatment for intertrochanteric fractures due to minimal invasion, small soft tissue injury, and shortening of the long arm (36, 37). However, the single fixing screw of Gamma nail and PFNA was also not counteracted with the tension and compression force of the proximal femur like the DHS, leading to an overreliance on the femoral cortex, whose fixation-related failures reached between 2.5% and 12.5% (30, 38–40). Although there was an in-depth understanding of the trabecular system of proximal femur, the concept of triangular

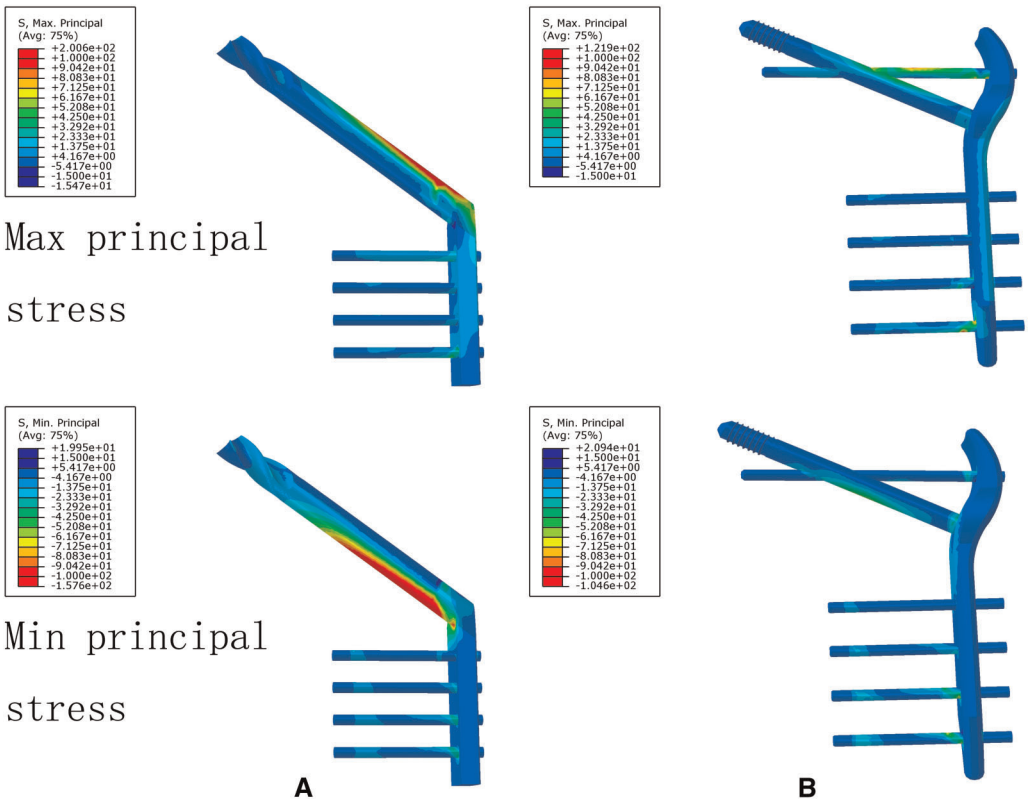

FIGURE 11 | The maximum principal stress and minimum principal stress extremes of two implant models for the treatment of an unstable intertrochanteric fracture. The figure shows that the TSFP has improved the maximum principal stress distribution compared with DHS for the fixation of Evans type IV intertrochanteric fracture.

TABLE 2 | The maximum displacement and stress values of two implant models for the treatment of stable intertrochanteric fracture.

Implant models	Maximum stress (MPa)			Maximum displacement (mm)	
	Medial cortex	Lateral cortex	Implant	Fixation models	Relative fracture surface
DHS	42.31	39.14	101.28	1.66	0.10
TSFP	35.41	15.36	88.02	1.28	0.04

TABLE 3 | The maximum displacement and stress values of two implant models for the treatment of an unstable intertrochanteric fracture.

Implant models	Maximum stress (MPa)			Maximum displacement (mm)	
	Medial cortex	Lateral cortex	Implant	Fixation models	Relative fracture surface
DHS	28.73	97.73	178.74	2.24	0.75
TSFP	68.97	19.58	105.31	1.57	0.10

support fixation was first put forward by our research team, and 3 Chinese granted patents were obtained in 2009. The TSFP had high stability, combining the advantages of intramedullary and

TABLE 4 | The maximum principal stress and minimum principal stress distribution of two implant models for the treatment of unstable and stable intertrochanteric fractures (MPa).

Implant models	Stable intertrochanteric fracture		Unstable intertrochanteric fracture	
	Max principal stress	Min principal stress	Max principal stress	Min principal stress
DHS	114.61	−89.65	200.63	−157.63
TSFP	103.04	−83.28	121.92	−104.55

extramedullary fixation. We considered that the TSFP was a bionic internal fixation of the proximal femur, which could be suitable for various intertrochanteric fractures, and had a great impact on the prognosis of intertrochanteric fractures. Finally, we will also carry out the biomechanical and clinical studies of the TSFP and promote the clinical application of the TSFP in intertrochanteric fracture.

There are some limitations in this study. First, the properties of the bone were set as homogeneous, isotropic, and linear elastic behavior, which were different from those of the actual bone. However, the bone model was validated with the biomechanical study, and the difference was within the acceptable range ($R = 0.992$, $Slope = 0.971$). Second, we

explored the optimal biomechanical effects of the different implantation points of the supporting screw versus the fixation screw in the lateral wall on intertrochanteric fractures. Third, because different intertrochanteric fractures have its own unique characteristics, the absence of an Evans II/III/V intertrochanteric fractures model in this study limited the value of our research. Finally, the four-hole side-plate DHS selected in the study was one fixation type in clinical practice, but to the question whether the DHS was the optimal fixation for intertrochanteric fractures, there was a lack of biomechanical and clinical evidence (41–43). In addition, the DHS has a variety of structures and material properties, which may impact the results of this study.

In conclusion, the TSFP reduced dependence on the femoral posteromedial and lateral cortex and improved the stability and stress distribution of the construct model. The TSFP conformed to the biomechanical characteristics of the proximal femur, which is a promising internal fixation for intertrochanteric fractures.

DATA AVAILABILITY STATEMENT

The original contributions presented in the study are included in the article/Supplementary Material; further inquiries can be directed to the corresponding author/s.

ETHICS STATEMENT

This study has been reviewed and approved by the Institutional Review Board of The Third Hospital of Hebei Medical University. Written informed consent was provided by the participants.

All authors have read and contributed to the submitted manuscript and have no conflict of interest to declare. Identifying images or other personal or clinical details of participants are not presented.

AUTHOR CONTRIBUTIONS

KD, LY, XC, and HW analyzed and interpreted the data. KD, WC, and YZ wrote the manuscript. WC, YZ, and QZ contributed most to the revision of this manuscript. QZ WC, and YZ designed the study. QZ and WC conducted the search for relevant studies. All authors contributed to the article and approved the submitted version.

FUNDING

This study was supported by the Support Program for the National Natural Science Foundation of China (Grant No. 82072447); Hebei Province fund for Distinguished Young Scholars (H2021206329). The funding source has no role in the study design, conduct, data collection, or statistical analysis.

REFERENCES

1. Chen W, Lv H, Liu S, Liu B, Zhu Y, Chen X, et al. National incidence of traumatic fractures in China: a retrospective survey of 512 187 individuals. *Lancet Glob Health*. (2017) 5:e807–17. doi: 10.1016/s2214-109x(17)30222-x
2. Gullberg B, Johnell O, Kanis JA. World-wide projections for hip fracture. *Osteoporos Int*. (1997) 7:407–13. doi: 10.1007/pl00004148
3. Keyak JH, Falkinstein Y. Comparison of in situ and in vitro CT scan-based finite element model predictions of proximal femoral fracture load. *Med Eng Phys*. (2003) 25:781–7. doi: 10.1016/s1350-4533(03)00081-x
4. Guzon-Illescas O, Perez Fernandez E, Crespí Villarias N, Quirós Donate FJ, Peña M, Alonso-Blas C, et al. Mortality after osteoporotic hip fracture: incidence, trends, and associated factors. *J Orthop Surg Res*. (2019) 14:203. doi: 10.1186/s13018-019-1226-6
5. Kannegaard PN, van der Mark S, Eiken P, Abrahamsen B. Excess mortality in men compared with women following a hip fracture. National analysis of comedications, comorbidity and survival. *Age Ageing*. (2010) 39:203–9. doi: 10.1093/ageing/afp221
6. Elis J, Chechik O, Maman E, Steinberg EL. Expandable proximal femoral nails versus 95° dynamic condylar screw-plates for the treatment of reverse oblique intertrochanteric fractures. *Injury*. (2012) 43:1313–7. doi: 10.1016/j.injury.2012.05.004
7. Kokoroghiannis C, Aktselis I, Deligeorgis A, Fragkomichalos E, Papadimas D, Pappadas I. Evolving concepts of stability and intramedullary fixation of intertrochanteric fractures–a review. *Injury*. (2012) 43:686–93. doi: 10.1016/j.injury.2011.05.031
8. Babhulkar S. Unstable trochanteric fractures: Issues and avoiding pitfalls. *Injury*. (2017) 48:803–18. doi: 10.1016/j.injury.2017.02.022
9. Parker MJ, Handoll HH. Gamma and other cephalocondylic intramedullary nails versus extramedullary implants for extracapsular hip fractures in adults. *Cochrane Database Syst Rev*. (2005) 19:Cd000093. doi: 10.1002/14651858.CD000093.pub3
10. Palm H, Jacobsen S, Sonne-Holm S, Gebuhr P. Integrity of the lateral femoral wall in intertrochanteric hip fractures: an important predictor of a reoperation. *J Bone Joint Surg Am*. (2007) 89:470–5. doi: 10.2106/jbjs.F.00679
11. Mahaisavariya B, Chantarapanich N, Riansuwan K, Sitthiseripratip K. Prevention of excessive medialisation of trochanteric fracture by a buttress screw: a novel method and finite element analysis. *J Med Assoc Thai*. (2014) 97(Suppl 9):S127–32.
12. Jitprapaikulsarn S, Chantarapanich N, Gromprasit A, Mahaisavariya C, Patamamongkonchai C. Single lag screw and reverse distal femur locking compression plate for concurrent cervicotrochanteric and shaft fractures of the femur: biomechanical study validated with a clinical series. *Eur J Orthop Surg Traumatol*. (2021) 31:1179–92. doi: 10.1007/s00590-020-02868-z
13. Jensen JS, Sonne-Holm S, Tøndevold E. Unstable trochanteric fractures. A comparative analysis of four methods of internal fixation. *Acta Orthop Scand*. (1980) 51:949–62. doi: 10.3109/17453678008990900
14. Clawson DK. Trochanteric fractures treated by the sliding screw plate fixation method. *J Trauma*. (1964) 4:737–52. doi: 10.1097/00005373-196411000-00001
15. Mulholland RC, Gunn DR. Sliding screw plate fixation of intertrochanteric femoral fractures. *J Trauma*. (1972) 12:581–91. doi: 10.1097/00005373-197207000-00006
16. Wolfgang GL, Bryant MH, O'Neill JP. Treatment of intertrochanteric fracture of the femur using sliding screw plate fixation. *Clin Orthop Relat Res*. (1982):148–58.
17. Hsu CE, Shih CM, Wang CC, Huang KC. Lateral femoral wall thickness. A reliable predictor of post-operative lateral wall fracture in intertrochanteric fractures. *Bone Joint J*. (2013) 95-b:1134–8. doi: 10.1302/0301-620x.95b8.31495

18. Ding K, Zhu Y, Li Y, Wang H, Cheng X, Yang W, et al. Triangular support intramedullary nail: A new internal fixation innovation for treating intertrochanteric fracture and its finite element analysis. *Injury*. (2022) 20: S0020-1383(22)00222-4. doi: 10.1016/j.injury.2022.03.032
19. Wang H, Yang W, Ding K, Zhu Y, Zhang Y, Ren C, et al. Biomechanical study on the stability and strain conduction of intertrochanteric fracture fixed with proximal femoral nail antirotation versus triangular supporting intramedullary nail. *Int Orthop*. (2022) 46:341–50. doi: 10.1007/s00264-021-05250-8
20. Zhu Y, Ding K, Li Y, Wang H, Chen W, Hou ZZ, et al. Biomechanical comparison of triangle supporting fixation system and Gamma nail fixation in the treatment of intertrochanteric fractures of the femur: finite element analysis. *Chin J Orthop*. (2021) 41:1361–6. doi: 10.3760/cma.j.cn121113-20210601-00394
21. Zhang YZ, Wang HC, Chen W, Zhu Y, Ding K, Hou ZZ, et al. Triangular supporting fixation: an innovative surgical approach for intertrochanteric fractures of the Temur – evidence from a biomechanical study. *Chin J Orthop Trauma!*. (2021) 23:461–6. doi: 10.3760/cma.j.cn115530-20210602-00255
22. Chantarapanich N, Riansuwan K. Biomechanical performance of short and long cephalomedullary nail constructs for stabilizing different levels of subtrochanteric fracture. *Injury*. (2022) 53:323–33. doi: 10.1016/j.injury.2021.11.064
23. Ding K, Yang W, Wang H, Zhan S, Hu P, Bai J, et al. Finite element analysis of biomechanical effects of residual varus/valgus malunion after femoral fracture on knee joint. *Int Orthop*. (2021) 45:1827–35. doi: 10.1007/s00264-021-05039-9
24. Cun Y, Dou C, Tian S, Li M, Zhu Y, Cheng X, et al. Traditional and bionic dynamic hip screw fixation for the treatment of intertrochanteric fracture: a finite element analysis. *Int Orthop*. (2020) 44:551–9. doi: 10.1007/s00264-019-04478-9
25. Ding K, Yang W, Zhu J, Cheng X, Wang H, Hao D, et al. Titanium alloy cannulated screws and biodegradable magnesium alloy bionic cannulated screws for treatment of femoral neck fractures: a finite element analysis. *J Orthop Surg Res*. (2021) 16:511. doi: 10.1186/s13018-021-02665-2
26. Tsuang FY, Hsieh YY, Kuo YJ, Chen CH, Lin FH, Chen CS, et al. Assessment of the suitability of biodegradable rods for use in posterior lumbar fusion: an in-vitro biomechanical evaluation and finite element analysis. *PLoS One*. (2017) 12:e0188034. doi: 10.1371/journal.pone.0188034
27. Li M, Zhao K, Ding K, Cui YW, Cheng XD, Yang WJ, et al. Titanium alloy gamma nail versus biodegradable magnesium alloy bionic gamma nail for treating intertrochanteric fractures: a finite element analysis. *Orthop Surg*. (2021) 13:1513–20. doi: 10.1111/os.12973
28. Zhan S, Jiang D, Xu J, Ling M, Yang K, Li Y, et al. Influence of the proximal screws of buttress plates on the stability of vertical femoral neck fractures: a finite element analysis. *BMC Musculoskelet Disord*. (2020) 21:842. doi: 10.1186/s12891-020-03853-7
29. Socci AR, Casemyr NE, Leslie MP, Baumgaertner MR. Implant options for the treatment of intertrochanteric fractures of the hip: rationale, evidence, and recommendations. *Bone Joint J*. (2017) 99-b:128–33. doi: 10.1302/0301-620x.99b1.Bjj-2016-0134.R1
30. Yu X, Wang H, Duan X, Liu M, Xiang Z. Intramedullary versus extramedullary internal fixation for unstable intertrochanteric fracture: a meta-analysis. *Acta Orthop Traumatol Turc*. (2018) 52:299–307. doi: 10.1016/j.aott.2018.02.009
31. Foss NB, Kehlet H. Hidden blood loss after surgery for hip fracture. *J Bone Joint Surg Br*. (2006) 88:1053–9. doi: 10.1302/0301-620x.88b8.17534
32. Jewell DP, Gheduzzi S, Mitchell MS, Miles AW. Locking plates increase the strength of dynamic hip screws. *Injury*. (2008) 39:209–12. doi: 10.1016/j.injury.2007.05.018
33. Medoff RJ, Maes K. A new device for the fixation of unstable pertrochanteric fractures of the hip. *J Bone Joint Surg Am*. (1991) 73:1192–9.
34. Cheng Q, Huang W, Gong X, Wang C, Liang X, Hu N. Minimally invasive percutaneous compression plating versus dynamic hip screw for intertrochanteric fractures: a randomized control trial. *Chin J Traumatol*. (2014) 17:249–55. doi: 10.3760/cma.j.issn.1008-1275.2014.05.001
35. Gotfried Y. Percutaneous compression plating of intertrochanteric hip fractures. *J Orthop Trauma*. (2000) 14:490–5. doi: 10.1097/00005131-200009000-00005
36. Parker MJ, Handoll HH. Gamma and other cephalocondylic intramedullary nails versus extramedullary implants for extracapsular hip fractures in adults. *Cochrane Database Syst Rev*. (2010) 26:Cd000093. doi: 10.1002/14651858.CD000093.pub5
37. Haidukewych GJ. Intertrochanteric fractures: ten tips to improve results. *J Bone Joint Surg Am*. (2009) 91:712–9.
38. Liu Y, Tao R, Liu F, Wang Y, Zhou Z, Cao Y, et al. Mid-term outcomes after intramedullary fixation of peritrochanteric femoral fractures using the new proximal femoral nail antirotation (PFNA). *Injury*. (2010) 41:810–7. doi: 10.1016/j.injury.2010.03.020
39. Horner NS, Samuelsson K, Solyom J, Bjørgul K, Ayeni OR, Östman B. Implant-related complications and mortality after use of short or long gamma nail for intertrochanteric and subtrochanteric fractures: a prospective study with minimum 13-year follow-up. *JB JS Open Access*. (2017) 2:e0026. doi: 10.2106/jbjs.Oa.17.00026
40. Zheng L, Wong DW, Chen X, Chen Y, Li P. Risk of proximal femoral nail antirotation (PFNA) implant failure upon different lateral femoral wall thickness in intertrochanteric fracture: a finite element analysis. *Comput Methods Biomech Biomed Engin*. (2021) 25:1–9. doi: 10.1080/10255842.2021.1964488
41. Chen Y, Wei ZZ, Zhang Kl, Li Z. Biocompatibility comparison between different dynamic hip screws for femoral intertrochanteric fractures. *J Clin Rehabilitative Tissue Eng Res*. (2011) 15:9100–3. doi: 10.3969/j.issn.1673-8225.2011.48.043
42. Rog D, Grigsby P, Hill Z, Pinette W, Inceoglu S, Zuckerman L. A biomechanical comparison of the two- and four-hole side-plate dynamic hip screw in an osteoporotic composite femur model. *J Orthop Surg (Hong Kong)*. (2017) 25:2309499017717199. doi: 10.1177/2309499017717199.
43. Yian EH, Banerji I, Matthews LS. Optimal side plate fixation for unstable intertrochanteric hip fractures. *J Orthop Trauma*. (1997) 11:254–9. doi: 10.1097/00005131-199705000-00003

Conflict of Interest: The authors declare that the research was conducted in the absence of any commercial or financial relationships that could be construed as a potential conflict of interest.

Publisher's Note: All claims expressed in this article are solely those of the authors and do not necessarily represent those of their affiliated organizations, or those of the publisher, the editors and the reviewers. Any product that may be evaluated in this article, or claim that may be made by its manufacturer, is not guaranteed or endorsed by the publisher.

Copyright © 2022 Ding, Zhu, Wang, Li, Yang, Cheng, Zhang, Chen and Zhang. This is an open-access article distributed under the terms of the Creative Commons Attribution License (CC BY). The use, distribution or reproduction in other forums is permitted, provided the original author(s) and the copyright owner(s) are credited and that the original publication in this journal is cited, in accordance with accepted academic practice. No use, distribution or reproduction is permitted which does not comply with these terms.

frontiers | Frontiers in Surgery

CASE REPORT
published: 27 May 2022
doi: 10.3389/fsurg.2022.898664

Case Report and Preliminary Exploration: Protection of Supraclavicular Nerve Branches during Internal Fixation of Clavicular Fractures through Preoperative Ultrasound Localization

*Yulin Wang[1], Jiapeng Huang[2], Jianjun Li[1], Jinfeng Zhou[1], Qiang Zheng[1], Zhixue Chen[3], Penghui Wei[1] and Wenxi Tang[1]**

[1]Department of Anesthesiology, Qilu Hospital (Qingdao), Cheeloo College of Medicine, Shandong University, Qingdao, China, [2]Department of Anesthesiology and Perioperative Medicine (JH), University of Louisville, Louisville, KY, United States of America, [3]Department of Orthopedics and traumatology, Qilu Hospital (Qingdao), Cheeloo College of Medicine, Shandong University, Qingdao, China

OPEN ACCESS

Edited by:
Paphon Sa-ngasoongsong, Ramathibodi Hospital, Mahidol University, Thailand

Reviewed by:
Prangmalee Leurcharusmee, Chiang Mai University,Thailand
Volkan Ozen, Cemil Tascioglu City Hospital,Turkey

***Correspondence:**
Wenxi Tang
tavakkolreza.73@gmail.com

Specialty section:
This article was submitted to Orthopedic Surgery, a section of the journal Frontiers in Surgery

Received: *17 March 2022*
Accepted: *05 May 2022*
Published: *27 May 2022*

Citation:
Wang Y, Huang J, Li J, Zhou J, Zheng Q, Chen Z, Wei P and Tang W (2022) Case Report and Preliminary Exploration: Protection of Supraclavicular Nerve Branches during Internal Fixation of Clavicular Fractures through Preoperative Ultrasound Localization. Front. Surg. 9:898664. doi: 10.3389/fsurg.2022.898664

Introduction: Protecting the supraclavicular nerve during internal fixation of clavicular fractures can reduce numbness in its innervation area after surgery. Previous methods for supraclavicular nerve protection are empirical, time-consuming, and approximate. In this report, we verified the feasibility of using ultrasound for percutaneous localization of the terminal branches of the supraclavicular nerve and the feasibility of an ultrasound-guided skin flap reserve technique for nerve protection.

Case Presentations: A high-frequency linear array probe was used in three cases to trace the supraclavicular nerve from its origin at the superficial cervical plexus on the surface of the clavicle. In the first case, the feasibility of percutaneous ultrasound localization of the terminal branches of the supraclavicular nerve was determined by performing an ultrasound-guided nerve block. In the second case, the feasibility of this method was determined by directly isolating this nerve under direct vision. In the third case, after the ultrasound localization, the nerves were protected by intraoperative skin retention. In the first case, skin anesthesia of the innervation area of the intermediate branch of the supraclavicular nerve was achieved. In the second case, the part of the nerve that crosses the surface of the clavicle was quickly found and successfully protected, and no obvious abnormal skin sensations were noted after the operation. In the third case, there was no abnormal sensation in most of the associated skin except for the innervation area of the lateral branch of the supraclavicular nerve.

Conclusions: The medial and intermediate branches of the supraclavicular nerve could be located over the skin by ultrasound, and this could be helpful in quickly isolating these nerves intraoperatively. Retaining the corresponding skin can protect the function of these nerve branches and effectively reduce the area of skin numbness after surgery.

Keywords: ultrasound, supraclavicular nerve, clavicle fracture, internal fixation, neuroprotection, case report

INTRODUCTION

Fractures of the clavicle are frequent injuries and account for 2%–5% of all fractures of the human body (1, 2), and nearly 80% of clavicle fractures occur in the middle segment (3). Steel plates are considered the gold-standard treatment for midclavicular fractures (4). The branches of the supraclavicular nerve are the main sensory nerves distributed in the skin over the clavicle and its surroundings. Conventional open reduction with internal plate fixation of clavicular fractures can easily damage the branches of the supraclavicular nerve, and anterior chest wall numbness secondary to injury of these branches is a common complication of this operation. The reported incidence of this complication is 55.3%–86%, and it is a burden to 61.9% of these patients. Various degrees of cutaneous numbness are reported to persist in 66.7% of patients and may become permanent (5–7). Protection of the supraclavicular nerve during internal fixation of clavicular fractures could significantly reduce the numbness and other postoperative discomforts (5,8–10).

Oblique incisions, mini-open plating, and preservation of the supraclavicular nerve under direct vision are common approaches to ensure neuroprotection (8, 9). Neuroprotection achieved through an oblique incision and mini-open plating depends on the surgeon's experience and is time-consuming (5). All these methods carry the potential risk of unintentional nerve injury. The mean diameters of the common trunk, intermediate branch, and lateral branch of the supraclavicular nerve are 4.1, 2.5, and 2.7 mm, respectively (11). Ultrasound-guided blocks of these nerve branches have been used by anesthesiologists. However, there are no reports describing the diameters of the terminal branches of the supraclavicular nerve (over and adjacent to the clavicle) and how to identify them with ultrasound. We hypothesized that the terminal branches of the supraclavicular nerve can be located through the skin by ultrasound and that this could aid in protecting the supraclavicular nerve during internal fixation of clavicular fractures. We verified this hypothesis using three cases in this study. This study was approved by the Medical Ethics Committee of the Qilu Hospital (Qingdao), Shandong University. Written informed consent was obtained from all the patients.

CASE PRESENTATION

Case 1

In the first case, we tested whether the terminal branches of the supraclavicular nerve could be traced out by ultrasound, as no previous studies had shown their ultrasound images.

The first case was of a 37-year-old healthy man (the first author of this article). A 15 MHZ high-frequency linear array probe (Wisonic Medical Technology, Shenzhen, China) was placed at the mid-posterior border of the sternocleidomastoid muscle (SCM). Four hypoechoic dots were identified on the surfaces of the anterior and medial scalene muscles. One dot was found on the surface of the scalenus anterior muscle (the phrenic nerve), and the other three dots were on the surface of the medial scalenus muscle; these were believed to be branches of the superficial cervical plexus (**Figure 1A**). The probe was then moved caudally, and one of the branches of the superficial cervical plexus extended down to the clavicle and anterior to the supraclavicular artery, which is an oval hypoechoic structure (**Figure 1B**). Approximately 1 cm closer to the superior margin of the clavicle, this image disappeared, and two fascicular hyperechoic masses emerged from the hypodermal tissue and extended to the clavicle (**Figure 1C**). These two hyperechoic structures were believed to be the main branches of the supraclavicular nerve. Anterior to the supraclavicular artery, 2% lidocaine (0.5 ml) was injected near these nerves using the out-of-plane technique. Sensory blockade was evaluated after 5 min (**Figure 1D**), and the evaluation confirmed that the medial and intermediate rami of the supraclavicular nerve were located correctly. The path of the supraclavicular nerve was therefore traced and marked on the skin under ultrasound guidance (**Figure 1D**).

Case 2

In the second case, we confirmed the feasibility of locating the terminal branches of the supraclavicular nerve by separating the nerve under direct vision (separating the nerve under direct vision is a common neuroprotection technique).

Case 2 involved a 69-year-old woman who was scheduled for an open reduction and internal fixation of a right clavicle fracture. Two milligrams of midazolam and 50 μg of fentanyl intravenous injection were given to sedate the patient and alleviate her pain. Using our previous method, we identified the possible supraclavicular nerve by tracing it caudally from the superficial cervical plexus to where it crosses the clavicle (**Figure 2A**). About 0.5 ml of 2% lidocaine was injected near the nerve using the out-of-plane technique. Sensory blockade was evaluated as previously described (**Figure 2B**), and it proved that these suspected nerves were the medial and intermediate rami of the supraclavicular nerve. Thence, 1 min after skin incision, this nerve was found in the subcutaneous tissue near the puncture point of the supraclavicular nerve block. Under direct visualization, the nerve was located over

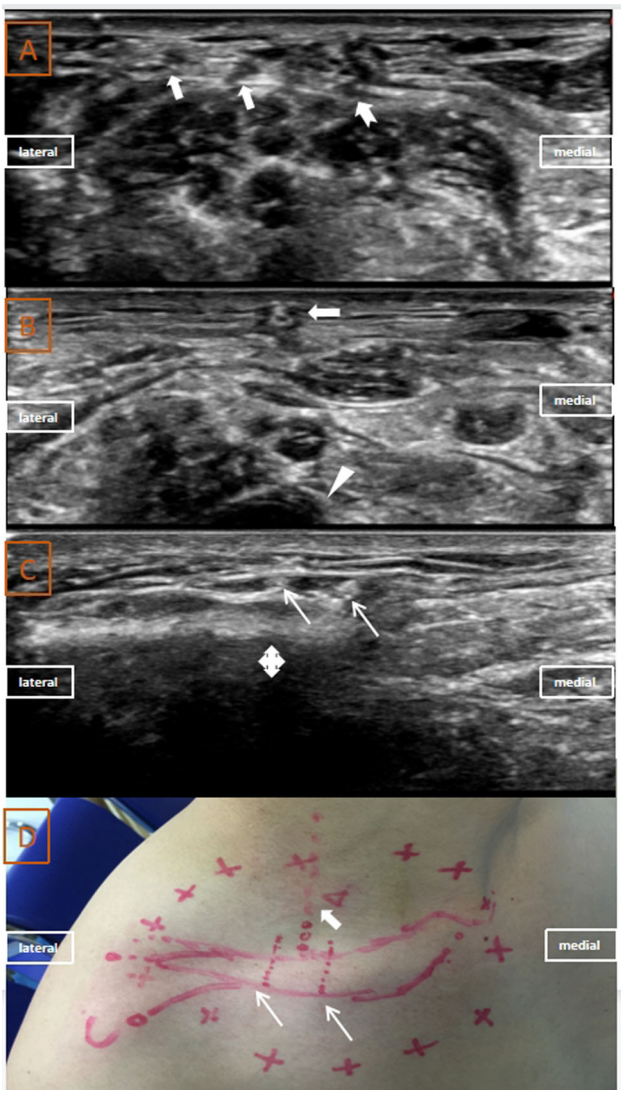

FIGURE 1 | Ultrasound images, projection on the body surface and sensory block area of the supraclavicular nerve in Case 1: (**A**) ultrasound images of phrenic nerve (indicated with swallowtail arrow) and superficial cervical plexus (indicated with a thick white arrow); (**B**) ultrasound image of the supraclavicular nerve (indicated with a thick white arrow) anterior to the supraclavicular artery (indicated with a white arrowhead); (**C**) ultrasound images of branches of the supraclavicular nerve (indicated with thin white arrows) anterior to the clavicle (indicated with a cross arrow); (**D**) projection of the supraclavicular nerve on the body surface (indicated with a white arrow) and the sensory block area (red circle).

the middle of the clavicle, and it extended beyond it (**Figure 1C**). It was carefully separated from the clavicle and protected using rubber strips. A steel plate was placed under the supraclavicular nerve to prevent nerve injury (**Figure 1C**). Follow-up at 24 h after surgery revealed that the patient had no obvious numbness in the skin areas around the clavicle and no significant sensory deficit. In this case, we did not find the inferior branch of the intermediate ramus of the supraclavicular nerve neither with ultrasound nor with open direct visualization; this may be attributed to anatomical variation.

Case 3

Finally, in case 3, we verified the feasibility of protecting the supraclavicular nerve by retaining the skin flap over it during surgery (this is an innovative technique proposed by our team).

This case was of a 27-year-old man scheduled for an internal plate fixation indicated for a right clavicle fracture. Similarly, after intravenous injection of the sedative and analgesic, we used the previously described method to identify the three possible branches of the supraclavicular nerve at the surface of the clavicle (**Figures 3A, B**). The paths of these nerves were marked on the skin, and the incision line was designed to avoid damaging these nerves (**Figure 3C**). We made a horizontal incision, retaining a skin bridge (flap) over the nerve in the middle of the clavicle, and cutting the skin from both ends of the clavicle (**Figures 3D, E**). The steel plate was then placed over the periosteum of the clavicle through a subcutaneous tunnel (separation of the subcutaneous tissue and insertion of the plate were carefully performed tightly against the periosteum to minimize nerve injuries) (**Figure 3D**). On the third postoperative day, the patient complained of numbness and hyperalgesia in the skin below the lateral one-third of the clavicle. The sensation in the areas below the medial two-thirds of the clavicle was normal (**Figure 3F**).

DISCUSSION

Our report suggests that locating the important distal branches of the supraclavicular nerve with ultrasound is possible and protecting these nerves by retaining the skin over them is feasible. However, sensory loss of the lateral one-third area was still present in the third case, and this may be due to the transection of the lateral branch of the supraclavicular nerve.

The supraclavicular nerve is a cutaneous sensory nerve originating from the C3 and C4 roots of the superficial cervical plexus. The supraclavicular nerve commonly divides into intermediate and lateral branches, and in some cases, there may be an additional medial branch (11–13). In most cases, these branches arise from a common trunk behind the posterior border of the SCM. The intermediate ramus emerges beneath the posterior border of the SCM, descends distally and anteriorly, and divides into two or three secondary branches. Its most medial branch crosses the middle third of the clavicle and its most lateral branch crosses the second lateral quarter of the clavicle to supply sensory innervations to the skin over the anterior upper part of the chest. The lateral ramus passes directly towards the acromial process, crosses the anterior border of the trapezius muscle, and divides into several branches that supply the skin of the shoulder. The medial ramus runs down along the posterior edge of the SCM to the clavicle, and then crosses through the platysma to provide sensory innervation to the sternal notch (11–13).

Open reduction and internal fixation of clavicular fractures can easily cause iatrogenic injury to branches of the

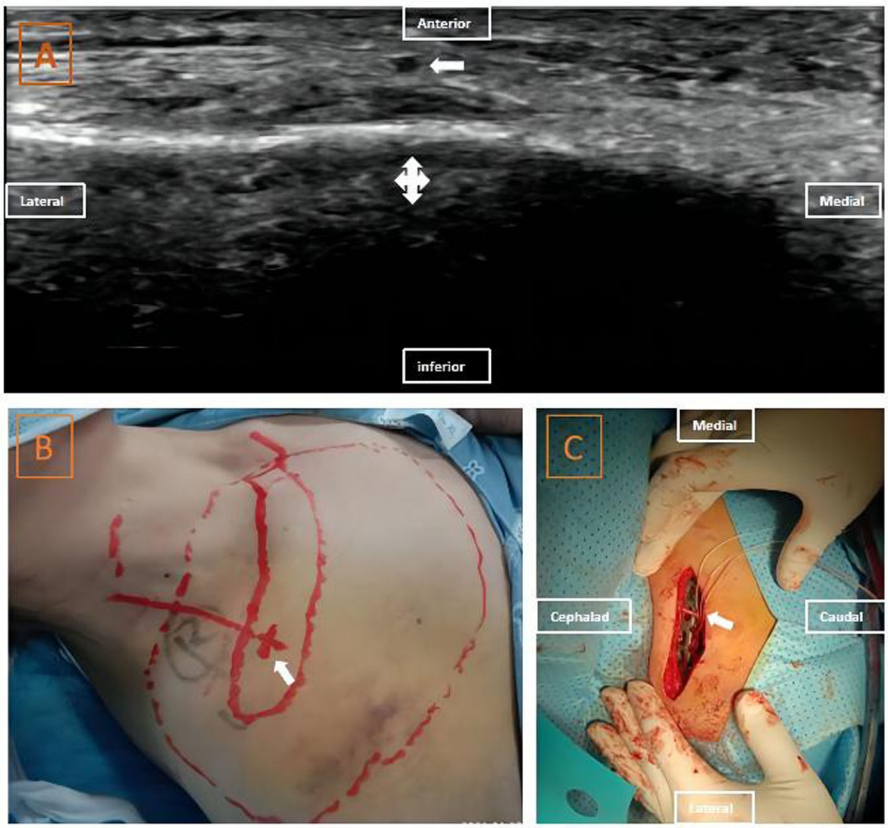

FIGURE 2 | Ultrasound images, projection on the body surface, sensory block area and intraoperative view of supraclavicular nerve in case 2: (**A**) ultrasound images of the supraclavicular nerve anterior to the clavicle; (**B**) projection of the supraclavicular nerve on the body surface and the sensory block area. (**C**) intraoperative view of the supraclavicular nerve. The thick white arrow indicates the supraclavicular nerve; the cross arrow indicates the clavicle.

supraclavicular nerve, and in the absence of neuroprotective measures, more than half of the patients develop numbness and other discomforts that affect their quality of life (5–7). Supraclavicular nerve-sparing techniques can reduce the incidence of anterior chest wall numbness from 86% to 35% (5). Therefore, surgeons advocate for the protection of the supraclavicular nerve during surgery. Previous methods of protecting the supraclavicular nerve include oblique incision, mini-open plating, and direct preservation of the nerve after horizontal skin incisions. The first two techniques are unreliable because they are based on the surgeon's experience in determining the location of the nerves. The latter technique requires a longer surgical time to dissect the nerve. Preoperative ultrasound localization might help surgeons to easily locate the nerve (before incision) and adjust the incision away from the nerves (e.g., preservation of the skin flap over the supraclavicular nerve after ultrasound localization).

Selective supraclavicular nerve block guided by ultrasound has been reported in some surgeries (14, 15). However, to the best of our knowledge, there are no studies on this technique for intraoperative neuroprotection, and no studies have reported the technique of identifying terminal branches of the supraclavicular nerve using ultrasound images taken over the surface of the clavicle.

Ultrasound and magnetic resonance imaging (MRI) are imaging methods that can be used to identify nerves; however, the use of MRI has not been reported for cutaneous nerve identification (16). For nerves, the resolution of ultrasonic techniques is stronger than that of MRI (17, 18). In addition, ultrasound is less expensive and more convenient. Ultrasound can be used to continuously track down a nerve along its path while marking the corresponding location on the overlying skin surface; this is a unique advantage of ultrasonic techniques over MRI.

This is our preliminary study on the use of ultrasound imaging to protect supraclavicular nerve branches during surgery. We acknowledge the following limitations of this study. First, according to anatomy (11–13), the innervation area of the lateral branch of the supraclavicular nerve did not appear to be affected by the nerve blocks in cases 1 and 2, whereas case 3 showed injury of the lateral branch of the supraclavicular nerve. This indicates that we failed to locate the terminal rami of the lateral branch of the supraclavicular nerve. This may be due to the smaller diameter of these rami, low ultrasound image contrast with the surrounding tissue, or poor resolution of the equipment. The use of a higher frequency myoskeletal ultrasound-dedicated probes may help identify all branches of the supraclavicular nerve. Second, because the

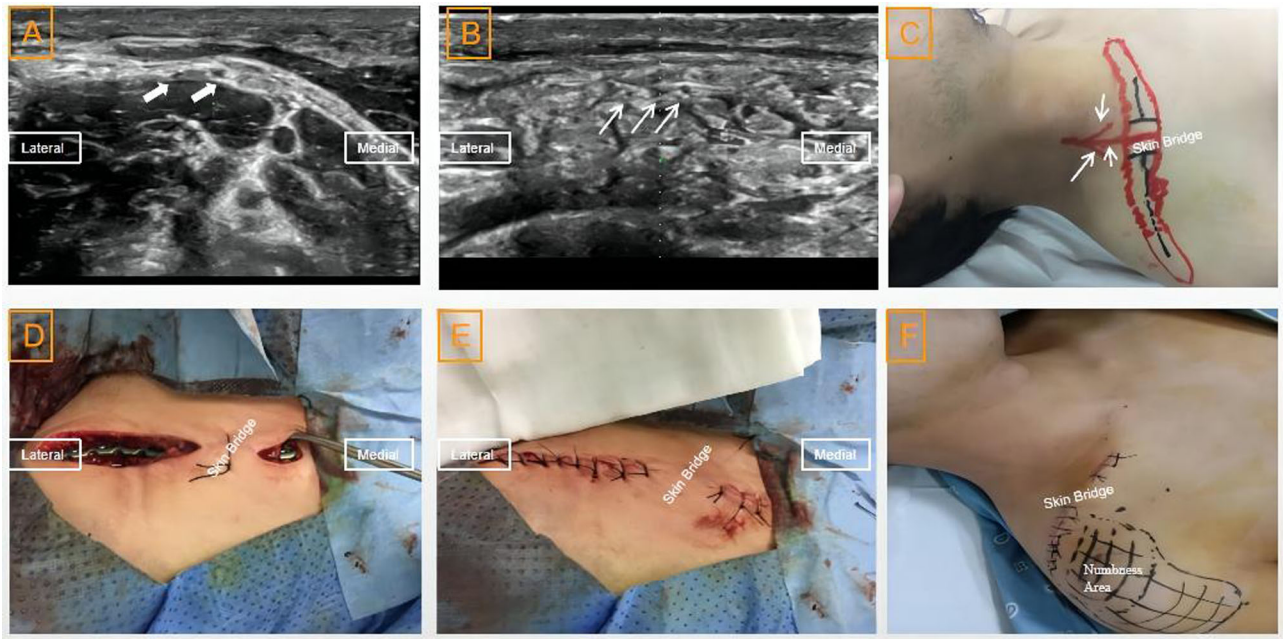

FIGURE 3 | Ultrasound images, projection on body surface of the supraclavicular nerve, skin flap (bridge) and numbness area after the operation in case 3: (**A**) ultrasound images of the branches of the supraclavicular nerve at its origin (indicated with a thick white arrow); (**B**) ultrasound images of the branches of the supraclavicular nerve (indicated with a thin white arrow) anterior to the clavicle (indicated with a white cross arrow); (**C**) projection of the branches of the supraclavicular nerve on the body surface and skin flap (bridge) before the operation; (**D**) skin flap during the operation; (**E**) skin flap after the operation; and (**F**) numbness area after the operation.

identification of these nerves partially depends on the surgeon's mastery of anatomy, this newly introduced technique of preoperative localization of the supraclavicular nerve is limited by anatomical variations of the nerve and its branches.

In conclusion, preoperative ultrasound localization of the terminal rami of the medial and intermediate branches of the supraclavicular nerve was feasible and could help avoid iatrogenic nerve injury during surgery.

DATA AVAILABILITY STATEMENT

The original contributions presented in the study are included in the article/supplementary material; further inquiries can be directed to the corresponding author.

ETHICS STATEMENT

The studies involving human participants were reviewed and approved by the Medical Ethics Committee of Qilu Hospital (Qingdao), Shandong University. The patients/participants provided their written informed consent to participate in this study. Written informed consent was obtained from the individual(s) for the publication of any potentially identifiable images or data included in this article.

AUTHOR CONTRIBUTIONS

WT and YW designed this study. JH, QZ, JZ, and ZC provided the relative techniques. WT and YW wrote the first draft of the manuscript. JH, JL, JZ, QZ, and PW revised the manuscript. PW and WT created the figure. All authors contributed to the article and approved the submitted version.

FUNDING

This work was funded by the Natural Science Foundation of Shandong Province (ZR2020QH291 and ZR2020MH126), Key Research and Development Plan of Shandong Province (2019GSF108228), Qingdao Key Health Discipline Development Fund (2019), Qingdao Outstanding Health Professional Development Fund (2019), and Scientific Research Foundation of Qilu Hospital of Shandong University (Qingdao) (QDKY2018QN12).

ACKNOWLEDGMENTS

The authors thank the staff in the Department of Orthopedics and traumatology, Qilu Hospital (Qingdao), Cheeloo College of Medicine, Shandong University, for their help and cooperation in this study.

REFERENCES

1. van der Linde RA, Beetz I, van Helden SH. Plating for midshaft clavicular fractures: the impact on quality of life and functional outcome. *Injury*. (2017) 48:2778–83. doi: 10.1016/j.injury.2017.10.032
2. Lenza M, Faloppa F. Surgical interventions for treating acute fractures or non-union of the middle third of the clavicle. *Cochrane Database Syst Rev*. (2015) 5:CD007428. doi: 10.1002/14651858.CD009363.pub3
3. Robinson CM. Fractures of the clavicle in the adult: epidemiology and classification. *J Bone Joint Surg Br*. (1998) 80:476–84. doi: 10.1302/0301-620X.80B3.0800476
4. Wilson DJ, Scully WF, Min KS, Harmon TA, Harmon AT, Eichinger KJ, et al. Biomechanical analysis of intramedullary vs. superior plate fixation of transverse midshaft clavicle fractures. *J Shoulder Elbow Surg*. (2016) 25:949–53. doi: 10.1016/j.jse.2015.10.006
5. Huang D, Deng Y, Cheng J, Bong YR, Schwass M, Policinski I. Comparison of patient reported outcomes following clavicle operative fixation using supraclavicular nerve sparing and supraclavicular nerve sacrificing techniques-A cohort study. *Injury*. (2020) S0020-1383(20):30923-2. doi: 10.1016/j.injury.2020.10.100
6. Wang L, Ang M, Lee KT, Naidu G, Kweke E. Cutaneous hypoesthesia following plate fixation in clavicle fractures. *Indian J Orthop*. (2014) 48:10–3. doi: 10.4103/0019-5413.125478
7. Christensen TJ, Horwitz DS, Kubiak EN. Natural history of anterior chest wall numbness after plating of clavicle fractures: educating patients. *J Orthop Trauma*. (2014) 28:642–7. doi: 10.1097/BOT.0000000000000095
8. Beirer M, Postl L, Crönlein M, Siebenlist S, Huber-Wagner S, Braun KF, et al. Does a minimal invasive approach reduce anterior chest wall numbness and postoperative pain in plate fixation of clavicle fractures? *BMC Musculoskelet Disord*. (2015) 16:128. doi: 10.1186/s12891-015-0592-4
9. Li R, Ke T, Xiong S, Xiong G, Lin Z, Lin F. Comparison of the effectiveness of oblique and transverse incisions in the treatment of fractures of the middle and outer third of the clavicle. *J Shoulder Elbow Surg*. (2019) 28:1308–15. doi: 10.1016/j.jse.2019.03.021
10. Wang K, Dowrick A, Choi J, Rahim R, Edward E. Post-operative numbness and patient satisfaction following plate fixation of clavicular fractures. *Injury*. (2010) 41:1002–5. doi: 10.1016/j.injury.2010.02.028
11. Havet E, Duparc F, Tobenas-Dujardin A-C, Muller J-M, Fréger P. Morphometric study of the shoulder and subclavicular innervation by the intermediate and lateral branches of supraclavicular nerves. *Surg Radiol Anat*. (2007) 29:605–10. doi: 10.1007/s00276-007-0258-5
12. Mehta A, Birch R. Supraclavicular nerve injury: the neglected nerve? *Injury*. (1997) 28:491–2. doi: 10.1016/S0020-1383(97)00041-7; Nathe T, Tseng S, Yoo B. The anatomy of the supraclavicular nerve during surgical approach to the clavicular shaft. *Clin Orthop Relat Res*. (2011) 469:890–4. doi: 10.1007/s11999-010-1608-x
13. Nathe T, Tseng S, Yoo B. The anatomy of the supraclavicular nerve during surgical approach to the clavicular shaft. *Clin Orthop Relat Res*. (2011) 469:890–4. doi: 10.1007/s11999-010-1608-x
14. Maybin J, Townsley P, Bedforth N, Allanl A. Ultrasound guided supraclavicular nerve blockade: first technical description and the relevance for shoulder surgery under regional anaesthesia. *Anaesthesia*. (2011) 66:1053–5. doi: 10.1111/j.1365-2044.2011.06907.x
15. Ozen V. Ultrasound-guided, combined application of selective supraclavicular nerve and low-dose interscalene brachial plexus block in a high-risk patient. *Hippokratia*. (2019) 23:25–7.
16. Holzgrefe RE, Wagner ER, Singer AD, Daly CA. Imaging of the peripheral nerve: concepts and future direction of magnetic resonance neurography and ultrasound. *J Hand Surg Am*. (2019) 44:1066–79. doi: 10.1016/j.jhsa.2019.06.021
17. Walker FO. Ultrasonography in peripheral nervous system diagnosis. *Continuum (Minneap Minn)*. (2017) 23:1276–94. doi: 10.1212/CON.0000000000000522
18. Hobson-Webb LD. Emerging technologies in neuromuscular ultrasound. *Muscle Nerve*. (2020) 61:719–25. doi: 10.1002/mus.26819

Conflict of Interest: The authors declare that the research was conducted in the absence of any commercial or financial relationships that could be construed as a potential conflict of interest.

Publisher's Note: All claims expressed in this article are solely those of the authors and do not necessarily represent those of their affiliated organizations, or those of the publisher, the editors and the reviewers. Any product that may be evaluated in this article, or claim that may be made by its manufacturer, is not guaranteed or endorsed by the publisher.

Copyright © 2022 Wang, Huang, Li, Zhou, Zheng, Chen, Wei and Tang. This is an open-access article distributed under the terms of the Creative Commons Attribution License (CC BY). The use, distribution or reproduction in other forums is permitted, provided the original author(s) and the copyright owner(s) are credited and that the original publication in this journal is cited, in accordance with accepted academic practice. No use, distribution or reproduction is permitted which does not comply with these terms.

frontiers | Frontiers in Surgery

SYSTEMATIC REVIEW
published: 01 June 2022
doi: 10.3389/fsurg.2022.893404

Comparative Efficacy of Three Minimally Invasive Procedures for Kümmell's Disease: A Systematic Review and Network Meta-Analysis

Yajian Wang, Bo Liu, Zhenwei Sun, Yaning Zhang and Jiangping Su**

Department of Orthopedics, Linfen People's Hospital, Linfen, China

Background: Percutaneous vertebroplasty (PVP), percutaneous kyphoplasty (PKP), and bone-filling mesh containers(BFC) are three viable minimally invasive techniques that have been used to treat Kümmell's disease(KD). However, there is still debate as to which is safer and more effective. This study summarized the pros and cons of the three techniques in the treatment of KD through network meta-analysis(NMA).

Methods: All eligible published clinical control studies comparing PVP, PKP, and BFC for KD up to December 2021 were collected by online search of Cochrane Library, PubMed, Embase, CNKI, Wanfang Database, and Chinese biomedical literature database. Data were extracted after screening, and Stata 16.0 software was used to perform the network meta-analysis.

Results: Four randomized controlled trials (RCTs) and 16 retrospective case-control studies (CCTs) with a total of 1114 patients were included. The NMA results showed no statistical difference between the 3 procedures in terms of improving patients' clinical symptoms. PKP was most likely to be the most effective in correcting kyphosis, while BFC was likely to be the most effective in managing the occurrence of cement leakage. No statistical differences were found in the incidence of new vertebral fractures in adjacent segments.

Conclusions: Ranking analysis showed that BFC has the highest likelihood of being the optimal procedure for the treatment of KD, based on a combined assessment of effectiveness in improving patients' symptoms and safety in the occurrence of adverse events.

Keywords: vertebroplasty, osteoporosis, vertebral compression fractures, Kümmell's disease, network meta-analysis

OPEN ACCESS

Edited by:
Paphon Sa-ngasoongsong, Ramathibodi Hospital, Mahidol University, Thailand

Reviewed by:
Lin Zheng, Zhejiang University, China
Konstantinos Kafchitsas, Johannes Gutenberg University Mainz, Germany

***Correspondence:**
Jiangping Su
sujiangping0800@126.com
Yaning Zhang
petj031@126.com

Specialty section:
This article was submitted to Orthopedic Surgery, a section of the journal Frontiers in Surgery

Received: *10 March 2022*
Accepted: *13 May 2022*
Published: *01 June 2022*

Citation:
Wang Y, Liu B, Sun Z, Zhang Y and Su J (2022) Comparative Efficacy of Three Minimally Invasive Procedures for Kümmell's Disease: A Systematic Review and Network Meta-Analysis. Front. Surg. 9:893404. doi: 10.3389/fsurg.2022.893404

INTRODUCTION

Kümmell's disease (KD) is a form of delayed ischemic osteonecrosis following vertebral trauma, usually secondary to osteoporotic vertebral compression fractures (OVCFs) in the elderly (1). The radiological features are characterized by vertebral body collapse, intravertebral vacuum cleft (IVC), and pseudoarthrosis formation (2). Patients with KD tend to have intractable low back pain and severe kyphotic deformity. As the incidence of OVCF increases, the incidence of

KD also tends to increase annually and can be as high as 12.1%–42.4% (3). Given that vertebrae with osteonecrosis fail to heal spontaneously, conservative treatment usually cannot yield satisfactory outcomes (4). In addition, there is a high risk of delayed neurological deficit following the vertebral collapse. Therefore, surgical treatments are highly recommended, especially for patients with intact neurological function, minimally invasive procedures are more popular (5, 6).

Percutaneous vertebroplasty (PVP), percutaneous kyphoplasty (PKP), and bone-filling mesh containers (BFC) are three minimally invasive procedures for the treatment of OVCFs in the elderly (7, 8). Likewise, their application in the treatment of KD has been gradually carried out in clinical practice with satisfactory outcomes (9). However, due to the specificity and complexity of KD, the application of minimally invasive techniques focuses not only on pain relief but also on preventing the deterioration of the deformity and the consequent nerve damage. In general, the concept of the minimally invasive procedure is to achieve treatment by delivering bone cement into the vertebral body (10). Specifically, PVP was performed by injecting bone cement into the compressed vertebral body under high pressure (11), whereas PKP was achieved by dilating the vertebral body with a balloon prior to cement injection (12). BFC was designed to control the dispersion of the bone cement within the vertebral body through a mesh container (13). Evidence from OVCFs showed that cement injection under high pressure can lead to associated complications, with bone cement leakage being the most common one (14). The presence of cleft within the vertebral body and even the formation of pseudo-articulations in KD implies a higher incidence of cement leakage. Therefore, how to reduce the incidence of cement leakage has become an unavoidable issue when choosing a treatment plan for KD.

To date, numerous studies have reported the clinical efficacy of the three procedures for the treatment of KD, but no consensus has been reached. To our knowledge, no study has systematically evaluated the advantages and disadvantages of these three minimally invasive procedures. Here, we collected the best available evidence to determine which approach has the highest effectiveness and fewest complications for KD by using a network meta-analysis (NMA), to provide useful evidence for clinical decision making.

MATERIALS AND METHODS

This study was conducted in accordance with the Preferred Reporting Items for systematic reviews and meta-analysis

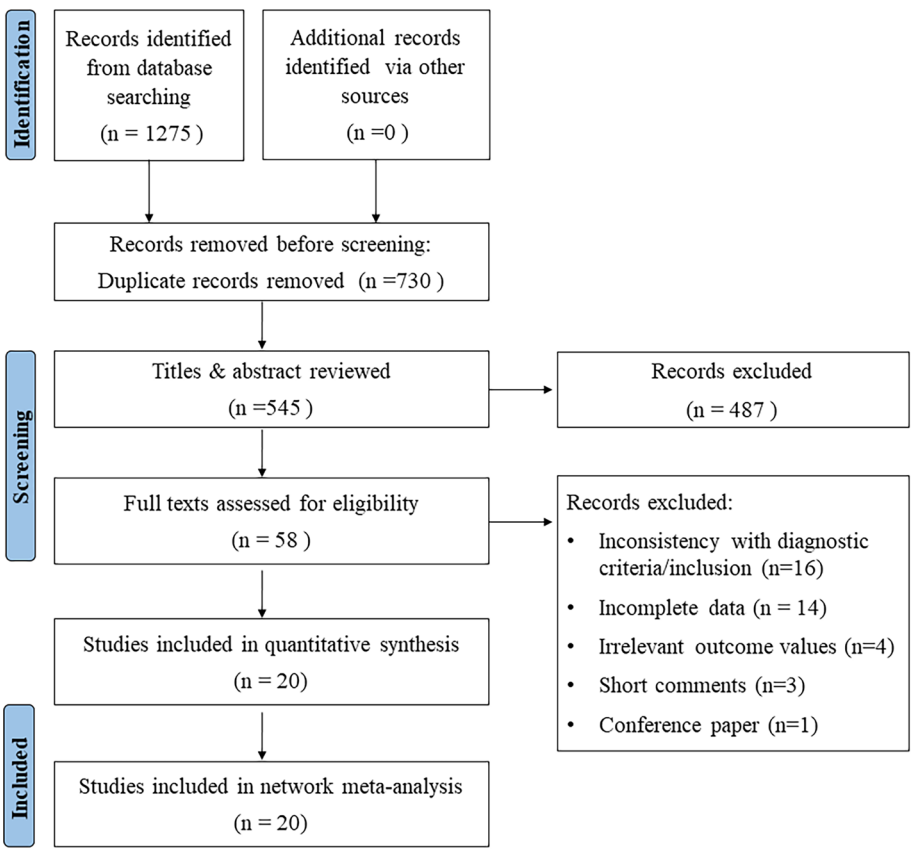

FIGURE 1 | Flow diagram of the study identification and selection process.

(PRISMA) guidelines (15) and the PRISMA NMA extension statement (16).

Search Strategy

The literature retrieval was carried out by searching electronic databases including Pubmed, Embase, Cochrane Library, CNKI, and Wanfang Data. All relevant studies were retrieved from inception to December 2021. No limitations were applied to the language of publication. The keywords and mesh terms for the searching strategy were "Kümmell", "vertebral osteonecrosis", "vertebral pseudarthrosis", "intravertebral vacuum cleft", "vertebroplasty", "PVP", "percutaneous kyphoplasty", "PKP", "vesselplasty", "bone-filling mesh container", "compression fracture", "OVCF". A secondary search of the references of all eligible literature was also conducted to find additional papers omitted by the initial search strategy.

Inclusion and Exclusion Criteria

Studies included in this review had to meet predefined criteria according to the PICOS approach (17). The inclusion criteria were as follows: (i). Patients: Adult patients with a clinical diagnosis of KD; (ii). Intervention: PVP, PKP, or BFC; (iii). Comparator: comparison of the effectiveness and safety of different treatment methods; (iv) Outcomes: visual analogue scale (VAS) score, Oswestry Disability Index (ODI), Cobb angle, cement leakage, and re-fracture of adjacent segments; (v). Study design: prospective randomized controlled trials (RCTs) or retrospective clinical control trials (CCTs). Studies meeting the following criteria were excluded: (i). Adult patients with a diagnosis of pathological fractures caused by primary or metastatic vertebral tumors; (ii). Single-armed studies without PVP/PKP/BFC as control, or cadaveric specimens/animals/biomechanical studies, or comparisons between high and low viscosity cements; (iii). Outcome evaluation did not include any of the above observations. (iv). Duplicate publications, reviews, conference abstracts, case series, letters, comments.

Data Extraction and Literature Quality Assessment

Two reviewers (B.L. & Z.W.S.) independently screened all included studies. Data were extracted and put into a standardized form after reading the full text. Cross-checks were conducted to ensure consistency in the quality of literature extraction and analysis of results. Any apprehension encountered was resolved through discussions with a third person (Y.J.W.).

The methodological bias assessments of the included RCTs and CCTs were performed in compliance with the Cochrane risk of bias (RoB) tool (18) and risk of bias in non-randomized studies of interventions (ROBINS-I) tool (19), respectively. The average risk of bias contributions for each

TABLE 1 | The characteristics of included studies.

Studies	Design	Cases	Gender (M/F)		Age (years)		Procedures	Outcomes
Chen et al. (21)	CCT	33/30	4/29	3/27	69.2 ± 6.3	68.7 ± 6.5	PVP、PKP	a, d, e
Kong et al. (22)	CCT	24/29	8/16	7/22	70.5 ± 6.4	71.9 ± 7.0	PVP、PKP	a, b, c, d, e
Zhang et al. (23)	CCT	38/35	10/28	9/26	75.58 ± 4.97	73.74 ± 4.35	PVP、PKP	a, d, e
Gao et al. (24)	CCT	38/35	20/18	16/19	73 ± 6	75 ± 6	PVP、PKP	a, b, d
Yu et al. (25)	CCT	48/20	10/38	4/16	74.6	75.9	PVP、PKP	a, b, c, d, e
Yu et al. (26)	CCT	14/28	5/9	9/19	74.47 ± 5.79	71.56 ± 8.35	PVP、PKP	a, b, c, d
Zhang et al. (27)	CCT	22/13	7/15	5/8	72.82 ± 6.99	74.38 ± 5.66	PVP、PKP	d
Feng and Sun (28)	CCT	20/20	5/15	7/13	72.02 ± 4.96	72.43 ± 5.64	PVP、PKP	a, b, c, d
Yu et al. (29)	CCT	20/28	2/18	3/25	67.21 ± 4.57	67.05 ± 4.03	PVP、PKP	a, b, c, d, e
Wang et al. (30)	RCT	22/22	11/11	11/11	75.50 ± 5.00	74.90 ± 6.50	BFC、PKP	a, b, c, d
Xu et al. (31)	CCT	31/31	15/16	14/17	68.3 ± 1.9	67.9 ± 2.1	PVP、BFC	a, b, d
Duan et al. (32)	RCT	19/19	9/10	8/11	77 ± 5	76 ± 4	PVP、BFC	a, b, c, d, e
Han et al. (33)	CCT	31/31	13/18	11/20	71.3 ± 5.2	70.9 ± 6.4	BFC、PKP	a, b, c, d
Wan et al. (34)	CCT	23/18	17/24		74.5		BFC、PKP	d
Duan et al. (35)	RCT	20/20	9/11	8/12	>60	>60	BFC、PKP	b, c, d, e
Sun et al. (36)	CCT	28/35	8/20	13/22	70.3	71.5	BFC、PKP	a, b, c, d, e
Guo et al. (37)	CCT	38/6/30	17/21	3/3	14/16	65.3 ± 5.9	63.9 ± 4.8	66.5 ± 7.2	PVP、BFC、PKP	a, b, d
Chang et al. (38)	RCT	28/28	6/22	8/20	75.0 ± 5.8	75.1 ± 5.7	PVP、PKP	a, b, d, e
Yao et al. (39)	CCT	35/40	16/19	18/22	68.0 ± 3.6		PVP、PKP	a, b, c, d, e
Dai et al. (40)	CCT	30/34	9/21	12/22	75.81 ± 7.12	75.12 ± 6.92	PVP、PKP	d, e

Note. *RCT, randomized controlled trials; CCT, retrieved clinical control trails; PVP, percutaneous vertebroplasty; PKP, Percutaneous kyphoplasty; BFC, bone-filling mesh containers; a, VAS scores; b, ODI scores; c, Cobb's angle; d, cement leakage; e, adjacent segments re-fracture.*

comparison within the network was shown with reference to the Confidence in Network Meta-Analysis(CINeMA) (20).

Statistical Analysis

The analyses of NMA were completed and plotted using Stata 16.0 statistical software (StataCorp LLC, TX, USA). The results of the analysis of dichotomous variables were presented as relative risk (RR) or odds ratio (OR), and continuous variables were presented as weighted mean difference (WMD), both were expressed as 95% confidence interval (CI). For each observation, the inconsistency model was first applied, and the consistency model could be used for further analysis when the inconsistency test results were not significant (p-value >0.05). The node-splitting method was used to assess inconsistencies with both global and local to clarify the validity of direct and indirect comparisons. The surface under the cumulative ranking curve (SUCRA) was used to rank the superiority of different minimally invasive techniques. Forest plots were generated to show the relative risk and 95% CI of the outcomes of interest.

RESULTS

Literature Search Results

A total of 1,275 studies were identified as potentially relevant by the search strategy. 730 duplicate or irrelevant studies were first removed. After screening the titles and abstracts, 487 ineligible studies were rejected. Based on the inclusion and exclusion criteria, 20 studies (21–40) were finally included for NMA after assessing the full text. The PRISMA flow chart for the literature selection was shown in **Figure 1**.

Four RCTs and 16 CCTs were identified, with a total of 1,114 patients. 438 (39.3%) received PVP, 496 (44.5%) had PKP, and 180 (16.2%) were treated with BFC. Study characteristics, patients' demographics, and clinical data were shown in **Table 1**.

Risk of Bias Assessment

The assessments of the risk of methodological bias for RCTs and CCTs were shown in **Supplementary Figures S1A, S1B, S2A, S2B**, respectively. The average risk of bias contributions for each comparison within the network was summarized in **Supplementary Figure S3**.

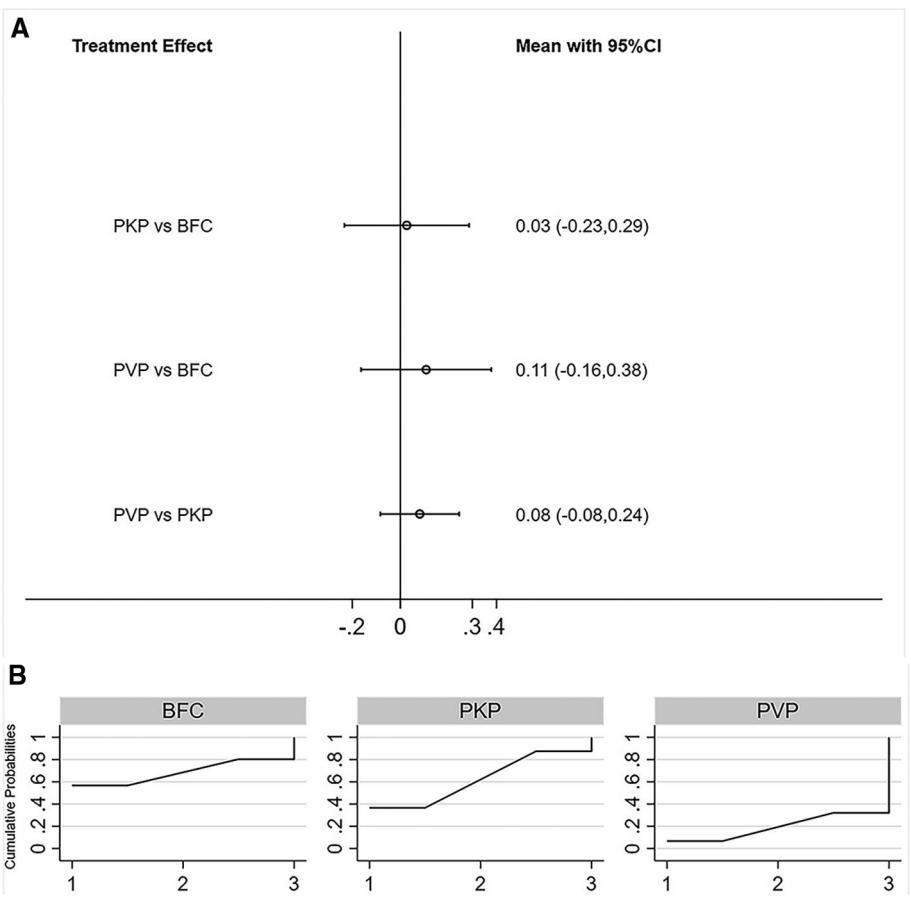

FIGURE 2 | Forest plot of VAS score (**A**) and relevant SUCRA of each procedure (**B**). PVP, percutaneous vertebroplasty; PKP, Percutaneous kyphoplasty; BFC, bone-filling mesh containers.

Effectiveness

VAS Score

A total of 16 studies reported postoperative VAS (21–26, 28–33, 36–39). The inconsistency model and the consistency model yielded consistent results($p = 0.43$, **Supplementary Figure S4**). The node split analysis also showed the consistency of direct and indirect comparisons (**Supplementary Table S1**).

All three procedures improved the patients' postoperative VAS scores, but the differences were not statistically significant between any two procedures (**Figure 2A**). The SUCRA of each procedure were shown in **Figure 2B**. Based on this, the probability of obtaining the lowest VAS score was ranked, and the probability of BFC being the best option was 53.5% (**Supplementary Table S2**).

ODI Score

Fifteen studies reported postoperative ODI scores for statistical analysis (22, 24–26, 28–33, 35–39). Consistency models and inconsistency models ($p = 0.93$, **Supplementary Figure S5**), direct and indirect comparisons (**Supplementary Table S1**), both yielded consistent results. All three procedures improved postoperative ODI scores, however, no statistically significant differences were found between any two procedures (**Figure 3A**). The SUCRA of each procedure were shown in **Figure 3B**. The probability ranking based on SUCRA showed that BFC had an 81.5% probability of being the best option for improving postoperative ODI (**Supplementary Table S3**).

Cobb Angle

A total of 11 studies reported postoperative Cobb angle improvement (22, 25–26, 28–30, 32, 33, 35, 36, 39). Similarly, both consistency models vs inconsistency models ($p = 0.41$, **Supplementary Figure S6**), direct vs indirect comparisons (**Supplementary Table S1**), obtained consistent results. NMA results showed that PKP resulted in better postoperative Cobb angle improvement compared to PVP, neither PKP vs PVP, nor BFC vs PVP showed statistical difference(**Figure 4A**). The SUCRA of each procedure were shown in **Figure 4B**. The ranking results showed that the probability of PKP being the best procedure was 75.4% (**Supplementary Table S4**).

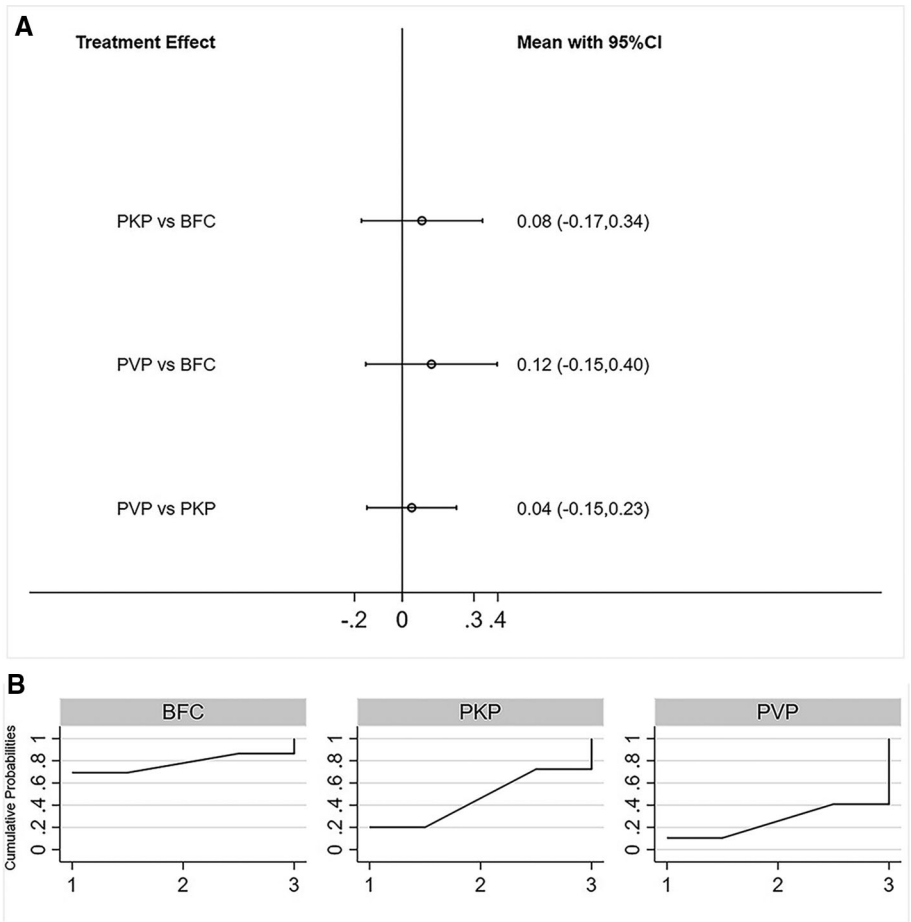

FIGURE 3 | Forest plot of ODI score (**A**) and relevant SUCRA of each procedure (**B**). PVP, percutaneous vertebroplasty; PKP, Percutaneous kyphoplasty; BFC, bone-filling mesh containers.

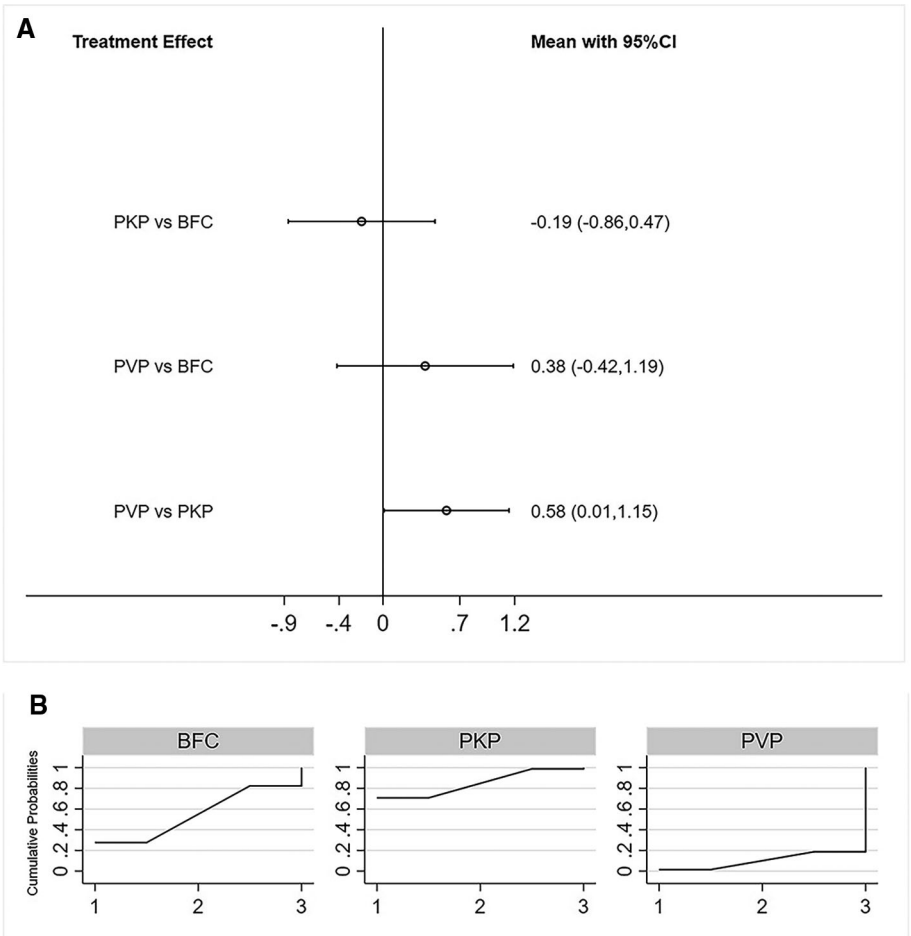

FIGURE 4 | Forest plot of cobb angle (**A**) and relevant SUCRA of each procedure (**B**). PVP, percutaneous vertebroplasty; PKP, Percutaneous kyphoplasty; BFC, bone-filling mesh containers.

Cement Leakage

All 20 studies reported the incidence of bone cement leakage for statistical analysis (21–40). Consistency models and inconsistency models ($p = 0.69$, **Supplementary Figure S7**), direct and indirect comparisons (**Supplementary Table S1**), yielded consistent results. The incidence of bone cement leakage was ranked from low to high as BFC < PKP < PVP, with statistically significant differences between any two procedures(**Figure 5A**). The SUCRA of each procedure were shown in **Figure 5B**. The probability of BFC being the best procedure in terms of reducing the rate of cement leakage was 100% (**Supplementary Table S5**).

Adjacent Segments Re-Fracture

Eleven studies reported the incidence of re-fractures in adjacent segments for statistical analysis (21–23, 25, 29, 32, 36, 36, 38–40). Consistency models and inconsistency models($p = 0.86$, **Supplementary Figure S8**), direct and indirect comparisons (**Supplementary Table S1**), yielded consistent results. There was no statistically significant difference in the incidence of postoperative re-fracture of adjacent segments among all three procedures (**Figure 6A**). The SUCRA of each procedure were shown in **Figure 6B**. The probability of BFC being the best procedure in terms of reducing the occurrence of adjacent segment re-fracture was 79.2% (**Supplementary Table S6**).

DISCUSSION

Compared to OVCFs, KD manifests as a rare and relatively complex spinal disorder, characterized mainly by greater vertebral instability, progressive deterioration, and more likely combined neurological deficit (41). Since the results of conservative treatment are usually limited, surgical treatment has become an option for more patients. For KD with neurological integrity, minimally invasive treatments are the preferred surgical approaches (42). With advances in disease understanding, the standardized diagnosis and therapeutic management of KD needs to be established with the support of high-level evidence. Numerous clinical studies have compared the clinical efficacy of PVP, PKP, and BFC for the

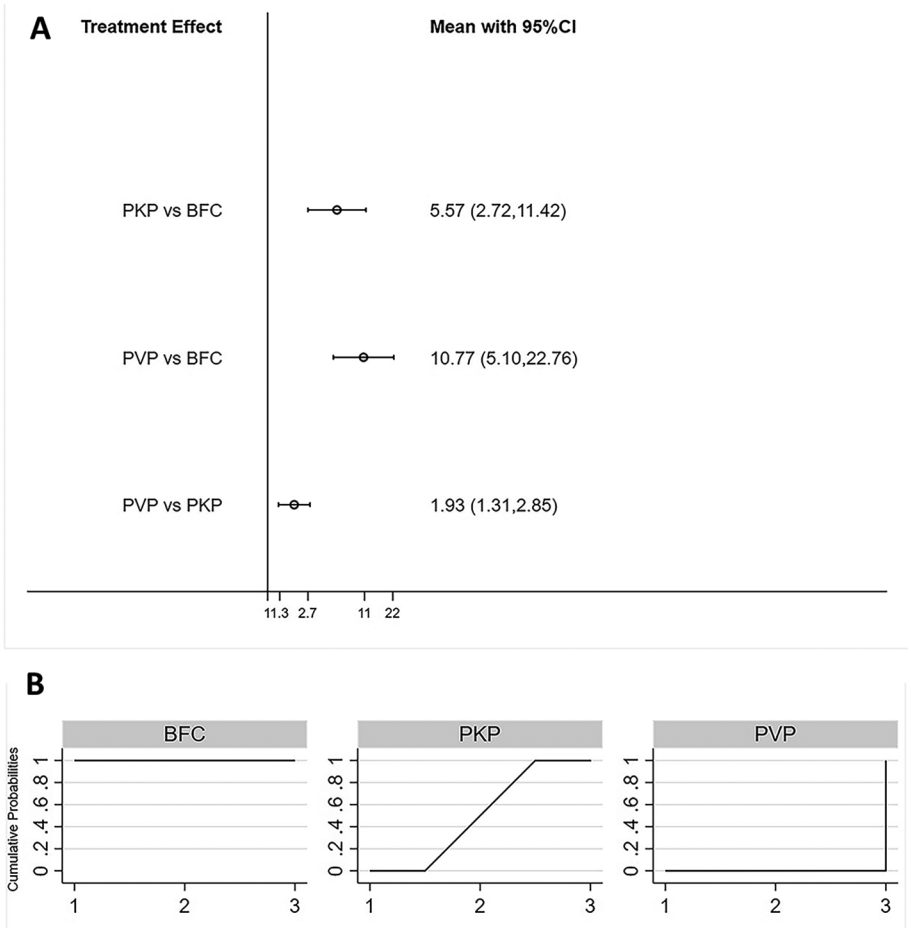

FIGURE 5 | Forest plot of cement leakage (**A**) and relevant SUCRA of each procedure (**B**). PVP, percutaneous vertebroplasty; PKP, Percutaneous kyphoplasty; BFC, bone-filling mesh containers.

treatment of KD (9, 35). Currently, the consensus is that all three minimally invasive procedures can improve patients' symptoms, such as the relief of pain, improvement of functional status, and quality of life. However, there is still controversy regarding safety. It is inconclusive whether one procedure is better than the other in the treatment of KD. Therefore, we performed a network meta-analysis of the three minimally invasive procedures, ranking the likelihood of being the best procedure for each clinical outcome and presenting an objective and comprehensive view of their pros and cons.

With regard to the clinical outcomes, even after the addition of BFC, our findings were generally consistent with that of previous conventional meta-analysis which directly compared PVP vs PKP for the treatment of KD (9). That was, no statistical difference was found among the three procedures in terms of VAS and ODI scores, but PKP provided better kyphosis correction than PVP. This was attributed to the balloon expansion effect related to PKP (43). In the case of BFC, although homogeneous diffusion of the bone cement was achieved by the mesh container, it did not show the advantage of correcting the deformity over PVP. However, it demonstrated a definite advantage over the other two procedures in terms of preventing cement leakage. PVP performed the worst outcome in terms of bone cement leakage management. A meta-analysis showed that the incidence of cement leakage was as high as 54.7% and 18.4% for PVP and PKP, respectively (44). There is no doubt that the application of BFC offered a new option for the prevention of bone cement leakage.

In addition, other attempts have been carried out to optimize injection protocols to reduce bone cement leakage. Taking the most economical PVP as an example, surgeons have developed a sequential infusion of bone cement was prepared into a late-phase filiform or early-phase mass shape (similar to high-viscosity bone cement) and injected slowly, followed by the infusion of the bone cement as an early- or midphase filiform shape. By doing so the bone cement leakage rate can be reduced from 41.7% to 14.3% (45). This was similar to the outcome of treating KD with a high-viscosity bone cement product, which reduced the cement leakage rate from 45.2% to 13.6% (46). Moreover, studies have been conducted to modify the composition of bone cements to better match the

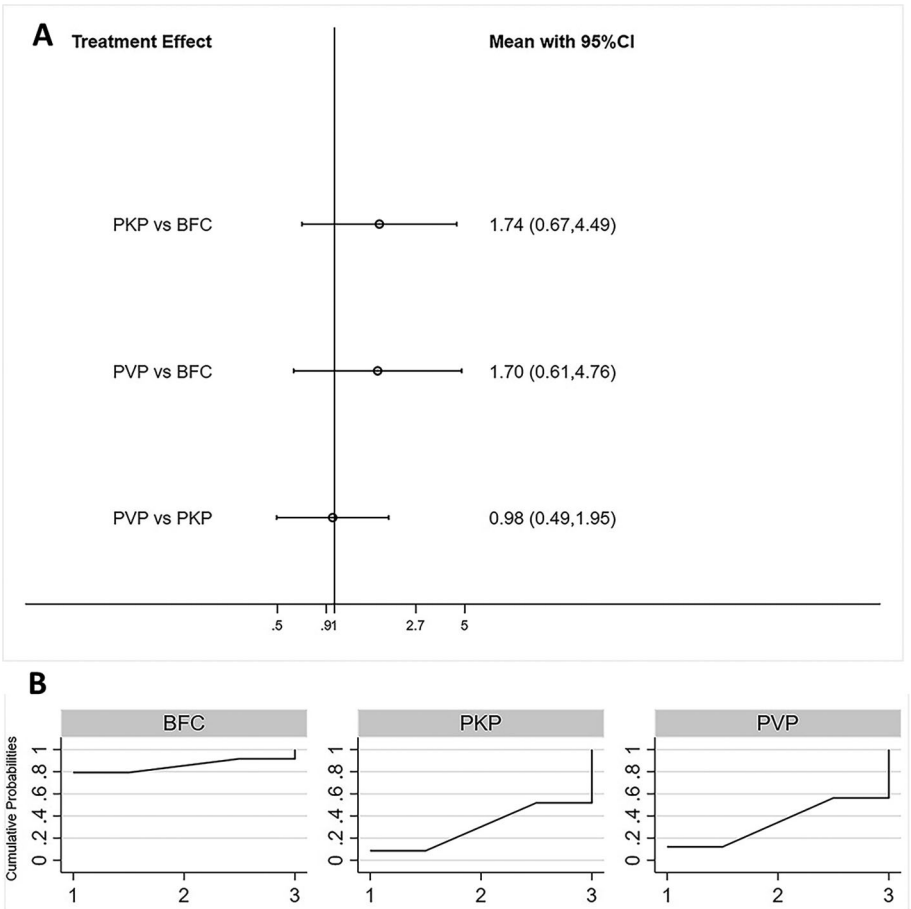

FIGURE 6 | Forest plot of adjacent segments re-fracture (**A**) and relevant SUCRA of each procedure (**B**). PVP, percutaneous vertebroplasty; PKP, Percutaneous kyphoplasty; BFC, bone-filling mesh containers.

biological and biomechanical characteristics of the human body. The addition of mineralized collagen to bone cement has been shown to have similar clinical efficacy as traditional bone cement and can reduce the incidence of bone cement leakage (47). The results of these new technologies are promising, and we look forward to more clinical studies based on these new technologies to comprehensively assess their clinical applicability. Meanwhile, regarding the issue of cement leakage, there is no doubt that it has the potential to lead to catastrophic consequences. However, we would like to have more discussion about this. We think more attention should be paid to how many cement leaks are true "adverse events," i.e., what type of cement leak occurred, whether it led to new clinical symptoms, and what percentage of early or late revisions resulted from it. On this basis, we believe it is more meaningful to compare the pros and cons of the different procedures, but unfortunately, we were not able to obtain enough information from the included literature for a comprehensive analysis, and we expect new studies to cover the details of adverse events.

Undeniably, this study has some limitations. It is well known that the lack of large sample size, multicenter, prospective randomized controlled trials is a common gap in current clinical studies. When RCTs are not sufficient to answer the question of interest, nonrandomized studies can be included for meta-analysis (48). Sixteen of the enrolled studies we included were CCTs, which may have a low-quality grade due to lack of randomization and blinding, as well as the possibility of greater potential bias. When we evaluated the methodological quality of these studies using the ROBINS-I tool, their measurement of outcomes and selection of the reported results were both at high risk, implying a possible overestimation of treatment effects. Therefore, this needs to be taken into account when referring to the results of this study. There is no doubt that more prospective multicenter RCTs with long-term follow-up are needed to evaluate the clinical efficacy of the three procedures for KD. In addition, the study locations included were all in China, or rather, this study tended to reveal the effectiveness of these three minimally invasive procedures for the treatment of KD in the Chinese population. The good point is that we performed NMA, an advanced form of meta-analysis, to integrate and compare both direct and indirect evidence from clinical studies to

inform clinical decisions by means of a ranked manner (49). To the best of our knowledge, this is the first NMA evaluating minimally invasive approaches for the treatment of KD.

In conclusion, this NMA performed a hierarchical ranking of the effectiveness and safety of three minimally invasive procedures for patients with KD. The ranking analysis showed that BFC had the highest likelihood of being the best procedure for the treatment of KD based on a combined assessment of effectiveness in improving patient symptoms and safety in the occurrence of adverse events. Our findings present new evidence for the selection of minimally invasive treatments for KD, providing surgeons with informative support in clinical practice, decision making, and guideline designation.

DATA AVAILABILITY STATEMENT

The original contributions presented in the study are included in the article/**Supplementary Material**, further inquiries can be directed to the corresponding author/s.

AUTHOR CONTRIBUTIONS

All authors listed have made a substantial, direct, and intellectual contribution to the manuscript, approved the final version to be published, and have agreed to be accountable for all aspects of the work. All authors contributed to the article and approved the submitted version.

FUNDING

This study was supported by seed grant from Linfen People's Hospital (No. T20210521180). The funding body had no role in the design of the study, data collection, analysis, interpretation, and in writing the manuscript.

ACKNOWLEDGMENTS

The authors would like to thank Congcong QIN for his help with the statistical analysis of the data in this paper.

SUPPLEMENTARY MATERIAL

The Supplementary Material for this article can be found online at: https://www.frontiersin.org/articles/10.3389/fsurg.2022.893404/full#supplementary-material.

REFERENCES

1. Swartz K, Fee D. Kümmell's disease: a case report and literature review. *Spine (Phila Pa 1976).* (2008) 33:E152–5. doi: 10.1097/BRS.0b013e3181657f31
2. Chen Z, Lou C, Yu W, He D. Comparison of intravertebral clefts between Kümmell disease and acute osteoporotic vertebral compression fracture: a radiological study. *Orthop Surg.* (2021) 13:1979–86. doi: 10.1111/os.13025
3. Fang X, Yu F, Fu S, Song H. Intravertebral clefts in osteoporotic compression fractures of the spine: incidence, characteristics, and therapeutic efficacy. *Int J Clin Exp Med.* (2015) 8:16960–8. PMCID: PMC4659139
4. Kim JE, Choi SS, Lee MK, Lee DK, Cho SI. Failed percutaneous vertebroplasty due to insufficient correction of intravertebral instability in Kummell's disease: a case report. *Pain Pract.* (2017) 17:1109–14. doi: 10.1111/papr.12561
5. Liu F, Chen Z, Lou C, Yu W, Zheng L, He D, et al. Anterior reconstruction versus posterior osteotomy in treating Kümmell's disease with neurological deficits: a systematic review. *Acta Orthop Traumatol Turc.* (2018) 52:283–8. doi: 10.1016/j.aott.2018.05.002
6. Adamska O, Modzelewski K, Stolarczyk A, Kseniuk J. Is Kummell's disease a misdiagnosed and/or an underreported complication of osteoporotic vertebral compression fractures? A pattern of the condition and available treatment modalities. *J Clin Med.* (2021) 10:2584. doi: 10.3390/jcm10122584
7. Zuo X-H, Zhu X-P, Bao H-G, Xu C-J, Chen H, Gao X-Z, et al. Network meta-analysis of percutaneous vertebroplasty, percutaneous kyphoplasty, nerve block, and conservative treatment for nonsurgery options of acute/subacute and chronic osteoporotic vertebral compression fractures (OVCFs) in short-term and long-term effects. *Medicine (Baltimore).* (2018) 97:e11544. doi: 10.1097/MD.0000000000011544
8. Wu H, Wang S, La H, Liao Y. Efficacy and safety of bone-filling mesh container in treatment of osteoporotic vertebral compression fractures: a meta-analysis. *Chin J Traumatol.* (2020) 36:433–41. doi: 10.3760/cma.j.issn.1001-8050.2020.05.009
9. Zhang B, Chen G, Yang X, Fan T, Chen Z. Percutaneous kyphoplasty versus percutaneous vertebroplasty for neurologically intact osteoporotic Kümmell's disease: a systematic review and meta-analysis. *Global Spine J.* (2021) 12:2192568220984129. doi: 10.1177/2192568220984129
10. He Z, Zhai Q, Hu M, Cao C, Wang J, Yang H, et al. Bone cements for percutaneous vertebroplasty and balloon kyphoplasty: current status and future developments. *J Orthop Translat.* (2015) 3:1–11. doi: 10.1016/j.jot.2014.11.002
11. Hurley MC, Kaakaji R, Dabus G, Shaibani A, Walker MT, Fessler RG, et al. Percutaneous vertebroplasty. *Neurosurg Clin N Am.* (2009) 20:341–59. doi: 10.1016/j.nec.2009.03.001
12. Yu C-W, Hsieh M-K, Chen L-H, Niu C-C, Fu T-S, Lai P-L, et al. Percutaneous balloon kyphoplasty for the treatment of vertebral compression fractures. *BMC Surgery.* (2014) 14:3. doi: 10.1186/1471-2482-14-3
13. Yang X, Wu G, Sun Y, Pang H, Huang X, Xu G. Vesselplasty using the Mesh-HoldTM bone-filling container for the treatment of pathological vertebral fractures due to osteolytic metastases: a retrospective study. *Eur J Radiol.* (2020) 126:108962. doi: 10.1016/j.ejrad.2020.108962
14. Nieuwenhuijse MJ, Van Erkel AR, Dijkstra PDS. Cement leakage in percutaneous vertebroplasty for osteoporotic vertebral compression fractures: identification of risk factors. *Spine J.* (2011) 11:839–48. doi: 10.1016/j.spinee.2011.07.027
15. Moher D, Liberati A, Tetzlaff J, Altman DG, Group PRISMA. Preferred reporting items for systematic reviews and meta-analyses: the PRISMA statement. *Ann Intern Med.* (2009) 151:264–9, W64. doi: 10.7326/0003-4819-151-4-200908180-00135
16. Hutton B, Salanti G, Caldwell DM, Chaimani A, Schmid CH, Cameron C, et al. The PRISMA extension statement for reporting of systematic reviews incorporating network meta-analyses of health care interventions: checklist and explanations. *Ann Intern Med.* (2015) 162:777–84. doi: 10.7326/M14-2385
17. Methley AM, Campbell S, Chew-Graham C, McNally R, Cheraghi-Sohi SPICO. PICOS and SPIDER: a comparison study of specificity and sensitivity in three search tools for qualitative systematic reviews. *BMC Health Serv Res.* (2014) 14:579. doi: 10.1186/s12913-014-0579-0.
18. Higgins JPT, Thomas J, Chandler J, Cumpston M, Li T, Page MJ, et al. *Cochrane Handbook for Systematic Reviews of Interventions*. John Wiley & Sons (2019). 726 p.

19. Morgan RL, Thayer KA, Santesso N, Holloway AC, Blain R, Eftim SE, et al. Evaluation of the risk of bias in non-randomized studies of interventions (ROBINS-I) and the "target experiment" concept in studies of exposures: rationale and preliminary instrument development. *Environ Int*. (2018) 120:382–7. doi: 10.1016/j.envint.2018.08.018
20. Nikolakopoulou A, Higgins JPT, Papakonstantinou T, Chaimani A, Giovane CD, Egger M, et al. CINeMA: an approach for assessing confidence in the results of a network meta-analysis. *PLoS Med*. (2020) 17:e1003082. doi: 10.1371/journal.pmed.1003082
21. Chen SL, Wang YS, Liu HJ, Wang Z, Liu YF, Han SH, et al. Clinical results of percutaneous vertebroplasty and kyphoplasty for the treatment of osteoporotic Kummell's disease. *Chin J Exp Surg*. (2012) 29:523–5. doi: 10.3760/cma.j.issn.1001-9030.2012.03.061
22. Kong L-D, Wang P, Wang L-F, Shen Y, Shang Z-K, Meng L-C. Comparison of vertebroplasty and kyphoplasty in the treatment of osteoporotic vertebral compression fractures with intravertebral clefts. *Eur J Orthop Surg Traumatol*. (2014) 24(Suppl 1):S201–8. doi: 10.1007/s00590-013-1374-z
23. Zhang G-Q, Gao Y-Z, Chen S-L, Ding S, Gao K, Wang H-Q. Comparison of percutaneous vertebroplasty and percutaneous kyphoplasty for the management of Kümmell's disease: a retrospective study. *Indian J Orthop*. (2015) 49:577–82. doi: 10.4103/0019-5413.168752
24. Gao YZ, Zhang GQ, Xing S, Chen SL, Ding S. Comparative analysis of percutaneous vertebroplasty and percutaneous kyphoplasty in the treatment of the elderly with Kümmell's disease. *Chin J Geriatr Orthop Rehabil(Electronic Edition)*. (2016) 2:136–40. doi: 10.3877/cma.j.issn.2096-0263.2016.03.002
25. Yu W, Jiang X, Ye L, Yao Z. Comparison of effectiveness between percutaneous vertebroplasty and percutaneous kyphoplasty for treatment of osteoporotic vertebral compression fracture with intravertebral vacuum cleft. *Zhongguo Xiu Fu Chong Jian Wai Ke Za Zhi*. (2016) 30:1104–10. doi: 10.7507/1002-1892.20160225
26. Yu HM, Li YZ, Yao XD, Lin JK, Pan YC, Zhuang HF, et al. Percutaneous vertebroplasty or percutaneous kyphoplasty for Kummell's disease with vertebral posterior wall collapse: how to treat individually? *ChinJ Tissue En Res*. (2016) 20:3856–62. doi: 10.3969/j.issn.2095-4344.2016.26.009
27. Zhang J, Fan Y, He X, Meng Y, Huang Y, Jia S, et al. Is percutaneous kyphoplasty the better choice for minimally invasive treatment of neurologically intact osteoporotic Kümmell's disease? A comparison of two minimally invasive procedures. *Int Orthop*. (2018) 42:1321–6. doi: 10.1007/s00264-018-3832-z
28. Feng F, Sun YL. A comparison of clinical efficacy of percutaneous vertebroplasty and percutaneous kyphoplasty in the treatment of Kümmell disease. *Chin J Bone Joint*. (2018) 7:225–9. doi: 10.3969/j.issn.2095-252X.2018.03.014
29. Yu X, Wang T, Yang JZ, Bi LY, Yang YD, Wang FX, et al. A retrospective trial of percutaneous vertebroplasty versus percutaneous kyphoplasty for treatment of Kümmell's diseases. *J Trad Chin Orthop Trauma*. (2018) 30:25–35.
30. Wang XY, Chen ZX, Zhong SL, Han H, Chen HP. Bone filling mesh container affuse bone cement for treatment of Kümmell's disease. *Chin J Bone Joint Injury*. (2018) 33:470–3. doi: 10.7531/j.issn.1672-9935.2018.05.006
31. Xu Y, Guan Z, Li YX, Chen F. A bone filling mesh container for treating senile osteoporotic vertebral compression fractures combined with intravertebral cleft sign. *Chi J Tissue Eng Res*. (2019) 23:1477–82. doi: 10.3969/j.issn.2095-4344.1603
32. Duan ZK, Zou JF, Kang XG, He XL, He CJ. Efficacy of bone-filling mesh container vertebroplasty in treatingfor Kümmell's disease. *Chin J Anesthesiol*. (2019) 39:1334–6. doi: 10.3760/cma.j.issn.0254-1416.2019.11.015
33. Han J, Huang Y. Effect of mesh bag vertebroplasty in the treatment of osteoporotic vertebral compression fractures with vertebral body fissure sign. *J Cervicodynia Lumbodynia*. (2019) 40:788–91. doi: 10.3969/j.issn.1005-7234.2019.06.019
34. Wan B, Mei GL, Xiong XM, Shi HG, Deng XG, Gu T, et al. Clinical observation on the treatment of type II Kummell disease with bone filling mesh container implantation vertebroplasty. *Sichuan Med J*. (2019) 40:908–11. doi: 10.16252/j.cnki.issn1004-0501-2019.09.009
35. Duan Z-K, Zou J-F, He X-L, Huang C-D, He C-J. Bone-filling mesh container versus percutaneous kyphoplasty in treating Kümmell's disease. *Arch Osteoporos*. (2019) 14:109. doi: 10.1007/s11657-019-0656-4
36. Sun YL, Xiong XM, Wan D, Deng XG, Shi HG, Song SM, et al. Comparison of effectiveness of Vesselplasty and percutaneous kyphoplasty for Kümmell disease. *Zhongguo Xiu Fu Chong Jian Wai Ke Za Zhi*. (2020) 34 (12):1539–44. doi: 10.7507/1002-1892.202007064
37. Guo X, Zhao WQ, He JC, Wang GJ, Liu BB, Shen CH, et al. Comparison of the curative effect of three methods of cementoplasty in treating Kümmell's disease. *J Intervent Rodiol*. (2020) 29:309–14. doi: 10.3969/j.issn.1008-794X.2020.03.019
38. Chang J-Z, Bei M-J, Shu D-P, Sun C-J, Chen J-B, Xiao Y-P. Comparison of the clinical outcomes of percutaneous vertebroplasty vs. kyphoplasty for the treatment of osteoporotic Kümmell's disease:a prospective cohort study. *BMC Musculoskelet Disord*. (2020) 21:238. doi: 10.1186/s12891-020-03271-9
39. Yao GW, Yu H, Wang W, Zhou YQ, Wang YP, Chen X. Comparison between percutaneous vertebroplasty and kyphoplasty for treatment of Kummell's disease. *Int J Orthop*. (2020) 41:371–5. doi: 10.3969/j.issn.1673-7083.2020.06.011
40. Dai S, Qin R, Shi X, Yang H. Percutaneous vertebroplasty versus kyphoplasty for the treatment of neurologically intact osteoporotic Kümmell's disease. *BMC Surg*. (2021) 21:65. doi: 10.1186/s12893-021-01057-x
41. Li H, Liang C-Z, Chen Q-X. Kümmell's disease, an uncommon and complicated spinal disorder: a review. *J Int Med Res*. (2012) 40:406–14. doi: 10.1177/147323001204000202
42. Li K-C, Li AF-Y, Hsieh C-H, Liao T-H, Chen C-H. Another option to treat Kümmell's disease with cord compression. *Eur Spine J*. (2007) 16:1479–87. doi: 10.1007/s00586-006-0094-z
43. Yang H, Chen L, Zheng Z, Yin G, Lu WW, Wang G, et al. Therapeutic effects analysis of percutaneous kyphoplasty for osteoporotic vertebral compression fractures: a multicentre study. *J Orthop Translat*. (2017) 11:73–7. doi: 10.1016/j.jot.2017.04.003
44. Zhan Y, Jiang J, Liao H, Tan H, Yang K. Risk factors for cement leakage after vertebroplasty or kyphoplasty: a meta-analysis of published evidence. *World Neurosurg*. (2017) 101:633–42. doi: 10.1016/j.wneu.2017.01.124
45. Zhang X, Li Y-C, Liu H-P, Zhou B, Yang H-L. Treatment of Kümmell's disease with sequential infusion of bone cement: a retrospective study. *World J Clin Cases*. (2020) 8:5887–93. doi: 10.12998/wjcc.v8.i23.5887
46. Zhang L, Wang J, Wang Y, Feng X. Comparison of high- and low-viscosity cement percutaneous vertebroplasty with manipulative reduction for the treatment of Kümmell's disease: a retrospective cohort study. *J Back Musculoskelet Rehabil*. (2022) 35:301–7. doi: 10.3233/BMR-191778
47. Zhu J, Yang S, Yang Y, Yao T, Liu G, Fan S, et al. Modified poly(methyl methacrylate) bone cement in the treatment of Kümmell disease. *Regen Biomater*. (2021) 8:rbaa051. doi: 10.1093/rb/rbaa051
48. Shrier I, Boivin J-F, Steele RJ, Platt RW, Furlan A, Kakuma R, et al. Should meta-analyses of interventions include observational studies in addition to randomized controlled trials? A critical examination of underlying principles. *Am J Epidemiol*. (2007) 166:1203–9. doi: 10.1093/aje/kwm189
49. Efthimiou O, Debray TPA, van Valkenhoef G, Trelle S, Panayidou K, Moons KGM, et al. GetReal in network meta-analysis: a review of the methodology. *Res Synth Methods*. (2016) 7:236–63. doi: 10.1002/jrsm.1195

Conflict of Interest: The authors declare that the research was conducted in the absence of any commercial or financial relationships that could be construed as a potential conflict of interest.

Publisher's Note: All claims expressed in this article are solely those of the authors and do not necessarily represent those of their affiliated organizations, or those of the publisher, the editors and the reviewers. Any product that may be evaluated in this article, or claim that may be made by its manufacturer, is not guaranteed or endorsed by the publisher.

Copyright © 2022 Wang, Liu, Sun, Zhang and SU. This is an open-access article distributed under the terms of the Creative Commons Attribution License (CC BY). The use, distribution or reproduction in other forums is permitted, provided the original author(s) and the copyright owner(s) are credited and that the original publication in this journal is cited, in accordance with accepted academic practice. No use, distribution or reproduction is permitted which does not comply with these terms.

frontiers | Frontiers in Surgery

SYSTEMATIC REVIEW
published: 27 June 2022
doi: 10.3389/fsurg.2022.922135

Wide-Awake Local Anesthesia With no Tourniquet Versus General Anesthesia for the Plating of Distal Radius Fracture: A Systematic Review and Meta-Analysis

*Ting-Yu Tu[1], Chih-Yang Hsu[2], Pei-Chin Lin[3,4] and Chun-Yu Chen[1,5,6]**

[1]Department of Orthopedics, Kaohsiung Veterans General Hospital, Kaohsiung, Taiwan, [2]Division of Nephrology, Department of Internal Medicine, Kaohsiung Veterans General Hospital, Kaohsiung, Taiwan, [3]Department of Medical Education and Research, Kaohsiung Veterans General Hospital, Kaohsiung, Taiwan, [4]Department of Pharmacy, School of Pharmacy, Kaohsiung Medical University, Kaohsiung, Taiwan, [5]Department of Occupational Therapy, Shu-Zen Junior College of Medicine and Management, Kaohsiung, Taiwan, [6]Department of Biomedical Engineering, I-Shou University, Kaohsiung, Taiwan

Background: Distal radius fractures are treated using open reduction and internal fixation and using general anesthesia (GA) or regional blocks. A new technique, wide-awake local anesthesia with no tourniquet (WALANT), allows this operation to be conducted in nonsedated patients without the use of tourniquets.

Objective: We analyzed whether WALANT yields better outcomes than GA in the treatment of patients with distal radius fractures.

Evidence Review: We searched the PubMed, Cochrane Library, Embase, and Scopus databases for cases of distal radius fractures treated using WALANT or GA. The outcomes of interest were duration of preparation for surgery, duration of surgery, blood loss, and length of postoperative hospitalization; visual analog scale (VAS), Mayo wrist score, and Quick Disabilities of the Arm, Shoulder and Hand (QuickDASH) questionnaire score on postoperative day 1; range of motion (ROM); time until bone union; and complication rate.

Findings: We systematically reviewed 4 studies with a total of 263 patients (128 with WALANT and 135 with GA). In comparison with GA, WALANT required less time for preparation for surgery, shorter postoperative hospitalization, and lower postoperative day 1 VAS scores; however, blood loss was greater. Functional outcomes (ROM, QuickDASH score, and Mayo wrist score), complication rates, and times until union did not differ considerably between the two methods.

Conclusion: The included studies demonstrated that durations of preparation for surgery and postoperative hospitalization were shorter and pain on postoperative day 1 was less severe with WALANT than with GA. Although blood loss in surgery was greater with WALANT, this technique is a novel and promising alternative to GA.

Keywords: wide-awake local anesthesia no tourniquet, WALANT, general anesthesia, GA, distal radius, fracture, fixation

OPEN ACCESS

Edited by:
Paphon Sa-ngasoongsong, Mahidol University, Thailand

Reviewed by:
David Joshua Mayich, Vitalité Health Network, Canada
Tulyapruek Tawonsawatruk, Mahidol University, Thailand

****Correspondence:***
Chun-Yu Chen
iergy2000@gmail.com

Specialty section:
This article was submitted to Orthopedic Surgery, a section of the journal Frontiers in Surgery

Received: *17 April 2022*
Accepted: *06 June 2022*
Published: *27 June 2022*

Citation:
Tu T-Y, Hsu C-Y, Lin P-C and Chen C-Y (2022) Wide-Awake Local Anesthesia With no Tourniquet Versus General Anesthesia for the Plating of Distal Radius Fracture: A Systematic Review and Meta-Analysis. Front. Surg. 9:922135. doi: 10.3389/fsurg.2022.922135

HIGHLIGHTS

- A meta-analysis and systematic review compared wide-awake local anesthesia with no tourniquet (WALANT) versus general anesthesia (GA) in patients with a distal radius fracture.
- WALANT is a promising alternative to GA for its reliable, cost-effective, and time-saving qualities, especially in older patients and those with various comorbidities.
- Durations of preparation for surgery and postoperative hospitalization were shorter and pain on postoperative day 1 was less severe with WALANT than with GA.

INTRODUCTION

Distal radius fracture, a common upper-limb injury worldwide, has a bimodal age distribution pattern: It tends to occur in young adults with high-energy trauma and in older adults with osteoporosis (1). Open reduction and internal fixation provide immediate stability to support patients' quick return to daily life and regular work. Such fixation with plates can be performed by administering regional blocks (e.g., Bier's block and brachial plexus block) or general anesthesia (GA) to patients. With both types of anesthesia, a tourniquet can be used to control bleeding and provide a clear surgical field. However, administering regional blocks is technically demanding and requires special equipment, and GA can be dangerous in patients at high risk for complications (2).

A new method of administering anesthesia, wide-awake local anesthesia with no tourniquet (WALANT), was conceived by Lalonde et al. (3) The WALANT technique involves the local administration of lidocaine and epinephrine into the surgical field, thereby allowing to conduct the operation without using sedation or tourniquets (4). It is used mainly in numerous hand and wrist procedures such as trigger finger (5), carpal tunnel release (6), wrist arthroscopy for triangular fibrocartilage complex repair (7), radial forearm perforator flap (8), tendon repair or transfer (9, 10), and internal fixation or implant removal for metacarpal fractures (11).

In comparison with GA, WALANT can be performed in older patients and in those with various comorbidities. Intraoperative anesthetic monitoring is not required, and hand or wrist function can be assessed in real time with the cooperation of nonsedated patients (12). Furthermore, it precludes not only postoperative pain and swelling of soft tissues caused by the tourniquet (13) but also anesthetic care after surgery and complications such as nausea and vomiting caused by GA. Therefore, WALANT is more cost-effective because postoperative hospitalization is reduced (14) and the services of anesthesiologists and preoperative testing for sedation are not required (15).

Fixation of distal radius fractures necessitates a wide surgical field and complicated bony procedures. Therefore, our concern is whether WALANT is a feasible alternative to GA in surgical treatment. To compare the effectiveness of WALANT with that of GA in surgical treatment, we conducted a systematic review and meta-analysis. The outcomes of interest were duration of preparation for surgery, duration of surgery, blood loss, and duration of postoperative hospitalization; visual analog scale (VAS) score, Mayo wrist score, and Quick Disabilities of the Arm, Shoulder and Hand (QuickDASH) questionnaire score on postoperative day 1; range of motion (ROM), measured by wrist flexion and wrist extension; time until bone union; and complication rate.

METHODS

Search Strategy

The study was conducted according to the Preferred Reporting Items for Systematic Review and Meta-Analysis guidelines. We searched the PubMed, the Cochrane Library, Embase, and Scopus databases for publications up to February 10, 2021, with the following search terms: "distal radius fracture," "wide-awake local anesthesia no tourniquet," and "WALANT" (search details are listed in the supplement). Randomized controlled trials (RCTs) and cohort studies were included, as were studies in which distal radius fractures were treated using a surgical intervention and WALANT or GA. Perioperative variables and clinical outcomes were included. Comments, letters, case reports, case series, editorials, proceedings, and personal communications were excluded. The search strategies are illustrated in the supplement. We also manually searched the reference lists of the relevant studies to retrieve additional studies. No language or date restriction was applied in this systematic search.

Because a meta-analysis does not involve human subjects, institutional review board review, ethical approval, and informed consent were not required.

Study Selection and Data Extraction

Studies were reviewed and selected by two independent reviewers. When study eligibility was uncertain, a third reviewer was consulted. The following information was extracted from the included studies: the name of the first author, year of publication, study design, sample size, participants' ages, follow-up period, distal radius fracture classification, WALANT solutions, injection procedure, postoperative medication regimen, and surgical outcomes.

Quality Assessment

Two independent reviewers used the Newcastle–Ottawa Scale to assess the quality of the included retrospective cohort studies in terms of the selection bias (four items), comparability bias (one item), and outcome bias (three items). With the exception of one comparability item that was rated a maximum of two stars, each item was assigned one star at most if the quality of the study was high. The highest possible rating on the Newcastle–Ottawa Scale is 9 stars. A study with a score of 8 or 9 stars was recognized as high quality; 5–7 stars, as moderate or low quality; and fewer than 5 stars, as poor quality. After reviewers independently rated all studies, any disagreements were resolved through discussion.

RCTs were appraised by the Cochrane Collaboration's Risk of Bias Tool (16) in the following six categories: (1) selection bias (use of random sequencing generation), (2) selection bias (use of allocation concealment), (3) detection bias (degree of "blinding" of outcome assessment), (4) performance bias (degree of "blinding" of participants and personnel), (5) attrition bias (presence of incomplete outcome data), and (6) reporting bias (as selective reporting). Each category was provided with one of three ratings: low, high, and unclear risk of bias. The overall risk of bias was considered low when all domains were rated as having a low risk of bias. It was considered unclear if at least one domain was considered to have an unclear risk of bias, but no domain was rated as having a high risk of bias; the overall risk of bias was otherwise considered high. After all studies were rated independently, any disagreements were resolved through discussion.

Outcome Measures

Outcomes of interest were perioperative variables and clinical outcomes such as duration of preparation for surgery, duration of surgery, blood loss, and length of postoperative hospitalization; VAS score, Mayo wrist score, and QuickDASH score on postoperative day 1; ROM, measured by wrist flexion and wrist extension; time to bone union; and complication rate.

Statistical Analysis

For the assessment of continuous data, we used mean differences (MDs) with corresponding 95% confidence intervals (CIs). For the assessment of dichotomous data, we used relative risk and 95% CIs. A p value of <0.05 was considered statistically significant. To assess the heterogeneity of the studies, we used Cochran's Q test with the I^2 statistic. The I^2 values were defined as follows: 0%–24% heterogeneity was considered low; 25%–49% heterogeneity was considered moderate; 50%–74% heterogeneity was considered high; and 75%–100% heterogeneity was considered extremely high. Because the number of studies included in the meta-analysis was small, heterogeneity tests had low statistical power (17), and because we observed heterogeneity between studies, random-effects models were conservatively applied for the meta-analysis (18). In addition, the National Research Council recommended the use of random-effects approaches for meta-analyses and the exploration of sources of variation in study results (19). Pooled effects sizes were calculated, and a two-sided p value of <0.05 was considered to indicate statistical significance. We used the statistical software Comprehensive Meta-Analysis, version 3.0 (Biostat, Englewood, NJ, USA) to perform all analyses.

RESULTS

Search Results

We identified 42 potentially eligible studies in the initial search (**Figure 1**). We excluded 22 duplicates and 9 irrelevant studies by reviewing titles and abstracts. The remaining 11 studies underwent full-text review, and 7 were excluded because they were case series or one-arm studies or had different inclusion criteria. Four studies (2, 20–22) were thus included in the systematic review.

Study Characteristics

Table 1 summarizes the main demographics of these four studies. Huang et al. (21) and Yi et al. (22) conducted retrospective cohort studies, and Tahir et al. (2) and Hamid et al. (20) conducted RCTs. The total number of patients in these studies was 263; 128 underwent surgery with WALANT, and 135 with GA. The Arbeitsgemeinschaft für Osteosynthesefragen (AO)/Orthopedic Trauma Association (OTA) classification varied across studies; with C2 fractures being the most common (22.1%), followed by A2 fractures (15.2%). The mean ages of patients among the studies ranged from 41 to 65 years. The lengths of follow-up ranged from 4 weeks to 1 year.

Summary of Outcomes

Table 2 lists the outcomes of interest in each study. Preparation time for surgery was considerably shorter with WALANT than with GA in the studies conducted by Tahir et al. (2) and Huang et al. (21); duration of surgery was considerably longer with WALANT in Hamid et al.'s study (20) but substantially shorter in Tahir et al.'s study (2) Blood loss was considerably greater with WALANT in the studies conducted by Tahir et al. (2) and Huang et al. (21) Duration of hospitalization was substantially shorter after surgery with WALANT in the studies conducted by Tahir et al. (2), Huang et al. (21), and Yi et al. (22) VAS scores were considerably lower 1 day after surgery with WALANT in the studies conducted by Tahir et al. (2) and Huang et al. (21); the QuickDASH score was substantially lower (which indicates better functional outcome) after surgery with WALANT in Hamid et al.'s study (20); in all these studies, Mayo wrist scores, wrist flexion, wrist extension, time to bone union, and complication rates did not differ between patients who underwent surgery using WALANT and surgery using GA. The total complication rate was 0.8% after surgery using WALANT (1 of 128 patients) and 5.9% after surgery using GA (8 of 135 patients). The proportions of patients requiring revision surgery were 0.8% after initial surgery with WALANT (1 of 128 patients) and 1.5% after surgery with GA (2 of 135 patients).

Meta-Analysis

All studies were included in the meta-analysis and evaluated for differences in the outcomes of interest (**Figure 2**). Preparation for surgery using WALANT was significantly shorter than that for surgery using GA (MD = −10.841; 95% CI, −12.570 to −9.113; $p = 0.000$), with no heterogeneity observed in these two studies (2, 20) ($I^2 = 0\%$; $\chi^2 = 0.198$; $p = 0.656$; **Figure 2A**). Duration of surgery did not differ significantly between the two techniques (MD = −1.511; 95% CI, −9.798 to 6.777; $p = 0.721$), and extreme heterogeneity was found among the four studies ($I^2 = 87.40\%$; $\chi^2 = 23.822$; $p = 0.000$; **Figure 2B**). Blood loss was significantly greater during surgery using WALANT

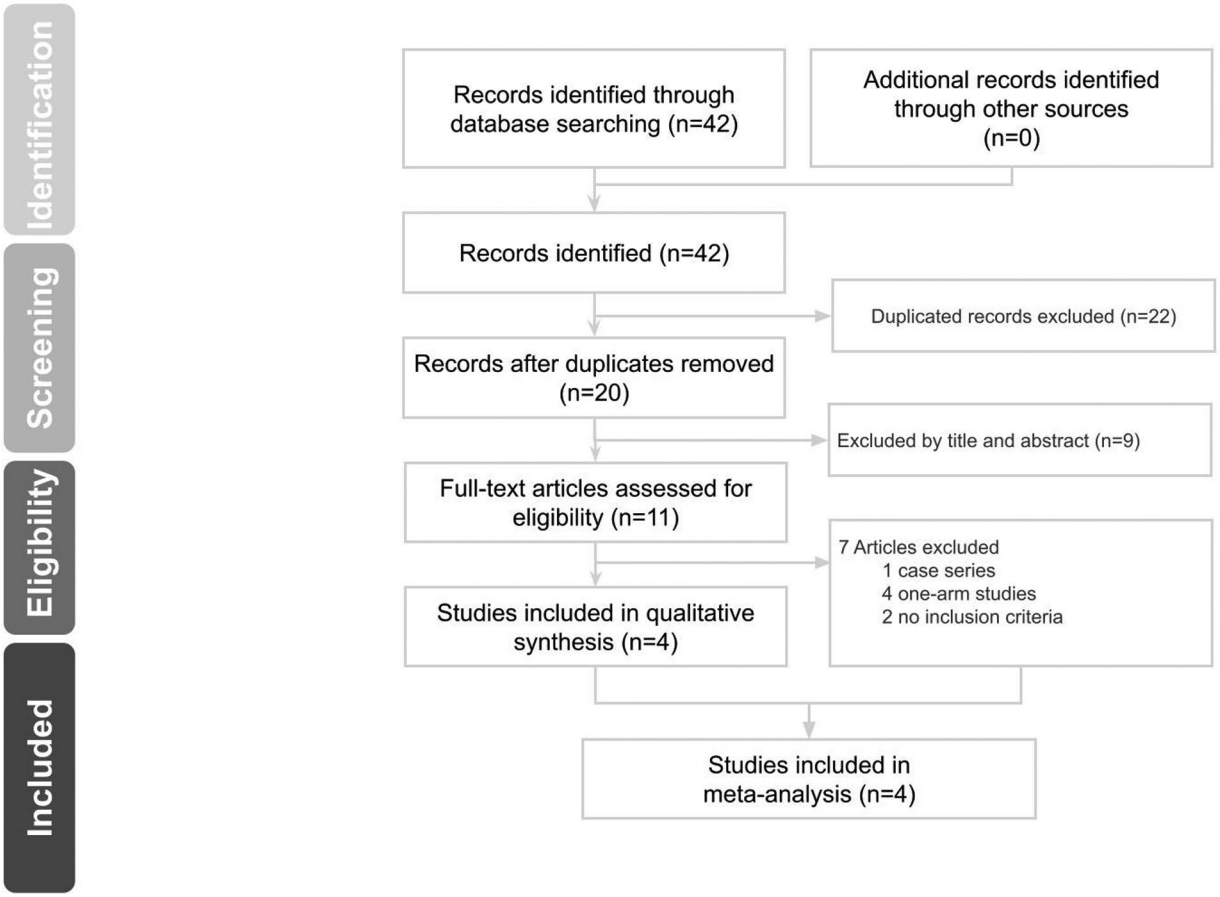

FIGURE 1 | PRISMA flow diagram of study selection.

than during surgery using GA (MD = 8.755; 95% CI, 0.909–16.602; $p = 0.029$), and extreme heterogeneity was noted among the four studies ($I^2 = 93.725\%$; $\chi^2 = 47.810$; $p = 0.000$; **Figure 2C**). Hospitalization was significantly shorter after surgery using WALANT than after surgery using GA (MD = −1.023; 95% CI, −1.218 to −0.829; $p = 0.000$), and no heterogeneity was noted among three studies (2,21,22) ($I^2 = 0\%$; $\chi^2 = 0.135$; $p = 0.935$; **Figure 2D**). VAS scores were significantly lower the day after surgery using WALANT (MD = −1.097; 95% CI, −2.192 to −0.003; $p = 0.049$), and extreme heterogeneity was observed among three studies (2, 21, 22) ($I^2 = 95.083\%$; $\chi^2 = 40.674$; $p = 0.000$; **Figure 2E**). No significant differences between the two techniques were found for the following outcomes of interest: Mayo wrist scores (MD = 0.321; 95% CI, −3.102 to 3.743; $p = 0.854$), for which heterogeneity between two studies (2, 21) was high ($I^2 = 58.505\%$; $\chi^2 = 2.410$; $p = 0.121$; **Figure 2F**); QuickDASH scores (MD = −1.234; 95% CI, −3.544 to 1.076; $p = 0.295$), for which heterogeneity between two studies (2, 21) was extremely high ($I^2 = 93.71$; $\chi^2 = 15.904$; $p = 0.000$; **Figure 2G**); wrist flexion (MD = −0.856; 95% CI, −4.126 to 2.414; $p = 0.608$), for which heterogeneity among three studies (2, 21, 22) was high ($I^2 = 67.724\%$; $\chi^2 = 6.197$; $p = 0.045$; **Figure 2H**); wrist extension (MD = 1.107; 95% CI, −0.530 to 2.745; $p = 0.185$), for which no heterogeneity was found among three studies (2, 21, 22) ($I^2 = 0\%$; $\chi^2 = 1.910$; $p = 0.385$; **Figure 2I**); time until bone union (MD = −0.644; 95% CI, −1.492 to 0.203; $p = 0.136$), for which no heterogeneity was found between two studies (2, 22) ($I^2 = 0\%$; $\chi^2 = 0.814$; $p = 0.367$; **Figure 2J**); and complication rates (relative risk = 0.294; 95% CI, 0.072–1.204; $p = 0.089$), for which no heterogeneity was found among four studies (2, 21, 22) ($I^2 = 0\%$; $\chi^2 = 0.822$; $p = 0.844$; **Figure 2K**).

Quality Assessment

The Newcastle–Ottawa Scale was used to evaluate the quality of the studies by Huang et al. (21) and Yi et al. (22) (**Table 3**), and the Cochrane Collaboration's Risk of Bias Tool was used to evaluate bias in the studies conducted by Tahir et al. (2) and Hamid et al. (20) The studies conducted by Huang et al. (21) and Yi et al. (22) were considered to have superior quality. The risk of bias in the studies conducted by Tahir et al. (2) and Hamid et al. (20) was considered high caused by performance bias ("blinding" of participants and personnel in both studies).

TABLE 1 | Demographic characteristics of the studies included in the systematic review.

Study	Type	Intervention	Size (M/F)	Follow-up	Age (mean ± SD)	Fracture pattern (number of patients)	Inclusion criteria	Exclusion criteria	WALANT solution	Injection	Postoperative medication	Approach	Implant choice
Huang et al. (2019) (21)	RCS	WALANT	21 (8/13)	1 y	65.29 ± 15.47	A2 (3), A3 (6), B2 (5), C1 (3), C2 (4)	Acute traumatic injury, closed, unilateral distal radius fractures	Associated injury in other organs Multiple fractures Combined accessory wrist arthroscopic procedure	5–10 mL 1% lidocaine + 1:40,000 epinephrine	3–5 mL 1% lidocaine hematoma block → WALANT solution injected on volar side of DR → 5 mL WALANT solution beneath PQ	Tramadol, 37.5 mg/325 mg; acetaminophen twice/day	Henry	Volar locking Plate (2.4 mm LCP Distal Radius system, Synthes)
		GA	26 (9/17)		62.31 ± 14.42	A2 (9), A3 (5), B2 (2), C1 (1), C2 (8), C3 (1)			NA	230 mg Hg tourniquet			
Tahir et al. (2020) (2)	RCT	WALANT	55 (31/24)	2 and 6 wk, 1 y	46.6 ± 10.91	A2 (6), A3 (5), B1 (11), B3 (5), C1 (7), C2 (15), C3 (6)	Isolated closed fracture of the distal radius within 10 days	Open fracture of the distal radius Bilateral distal radius fracture Active infection in the body Contraindication for WALANT Noncooperative patients Bleeding tendency Hypersensitive to lidocaine Polytrauma patients	0.9% normal saline + 2% lidocaine + 1:100,000 epinephrine	3–5 mL 2% lidocaine hematoma block → WALANT solution injected on four skin points where 2 cm apart from the distal wrist crease → additional 5 mL WALANT solution beneath PQ	Tramadol, 37.5 mg/325 mg; acetaminophen, twice/day; calcium supplements	Henry	Volar Locking plates (Double medical Technologies, Fujian, China)
		GA	56 (28/28)		49.7 ± 9.3	A2 (5), A3 (7), B1 (6), B3 (9), C1 (7), C2 (9), C3 (13)			NA	250 mg Hg tourniquet			
Yi et al. (2020) (22)	RCS	WALANT	20 (19/1)	4 wk	41.7 ± 16.37	A2 (1), A3 (2), B1 (1), B2 (2), B3 (5), C1 (3), C2 (4), C3 (2)	Distal radius fracture Patients consent to participate	NA	50 mL 0.9% normal saline + 50 mL lidocaine HCl 2% + 1 mL adrenaline acid tartrate 0.18% 1 mg/mL + 10 mL sodium bicarbonate 8.4%	WALANT solution injected subcutaneously along the modified Henry skin incision, 1 cm beyond the incision site and three dots[a] along radial border of radius	NA	Modified Henry	Volar Plating

(*continued*)

TABLE 1 | Continued

Study	Type	Intervention	Size (M/F)	Follow-up	Age (mean ± SD)	Fracture pattern (number of patients)	Inclusion criteria	Exclusion criteria	WALANT solution	Injection	Postoperative medication	Approach	Implant choice
		GA	20 (10/10)		44.3 ± 17.63	A2 (1), A3 (4), B1 (2), B2 (3), B3 (3), C1 (2), C2 (3), C3 (2)			NA	NA			
Hamid et al. (2021) (20)	RCT	WALANT	32 (21/11)	3 and 6 wk, 3 and 6 mo	47.19 ± 8.19	A2 (9), A3 (2), B1 (2), B2 (2), B3 (6), C1 (3), C2 (6), C3 (2)	Distal radius fracture Patients consent to participate	Peripheral vascular disease Diabetes mellitus Ischemic heart disease Psychiatric illness Allergy to lignocaine Patient demanding GA	50 mL of normal saline + 50 mL of lidocaine 2% +1 mL of 1:1,000 adrenaline solution + 10 mL of 8.4% sodium bicarbonate	10 mL of WALANT solution injected subcutaneously along the modified Henry skin incision, 30 mL was injected into the periosteal layer at three dots[a]	Tramadol, 50 mg three times a day; paracetamol, 1,000 mg four times a day	Modified Henry	Volar Plating
		GA	33		49.48 ± 6.02	A2 (6), A3 (2), B1 (3), B2 (6), B3 (2), C1 (2), C2 (9), C3 (3)			NA	NA			

WALANT, wide-awake local anesthesia and no tourniquet; RCS, Retrospective cohort study; DR, distal radius; PQ, pronator quadratus; GA, general anesthesia; RCT, Randomized controlled trial; NA, not applicable.
[a]*At each dot, 10 mL of the WALANT solution was injected at different angles into the volar (4 mL), lateral (2 mL) and posterior (4 mL) aspects of the radius within the periosteal layer.*

TABLE 2 | Patients' outcomes presented in the studies.

Study	Intervention	Size	Preparation time, min (mean ± SD)	Surgery time, min (mean ± SD)	Blood loss, mL (mean ± SD)	Post-operation Day 1 VAS (mean ± SD)	Postoperative hospital stay, days (mean ± SD)	Union time, wk (mean ± SD)	Extension (mean ± SD)	Flexion (mean ± SD)	Mayo wrist score (mean ± SD)	QuickDASH score (mean ± SD)	Complication (case / total)	Revision (*n*)
Huang et al. (2019) (21)	WALANT	21	25.38 ± 4.59	68.10 ± 9.28	22.62 ± 6.82	1.95 ± 0.67	1.38 ± 0.5	20.76 ± 4.35	50.24 ± 9.28	67.14 ± 9.95	86.67 ± 7.13	NA	0 / 21	0
	GA	26	37.31 ± 11.16	64.42 ± 10.42	8.62 ± 9.23	3.27 ± 1.28	2.46 ± 0.71	22.46 ± 4.17	49.42 ± 6.22	71.35 ± 8.19	84.04 ± 7.35		0 / 26	0
Tahir et al. (2020) (2)	WALANT	55	23.0 ± 3.85	61.30 ± 9.28	23.40 ± 8.50	1.20 ± 0.62	0.20 ± 0.50	15.3 ± 2.31	54.8 ± 6.45	65.9 ± 6.01	86.3 ± 5.08	10.2 ± 2.80	0 / 55	0
	GA	56	33.7 ± 5.81	68.80 ± 14.97	11.50 ± 4.25	3.00 ± 1.24	1.20 ± 0.78	15.8 ± 2.54	52.9 ± 4.45	64.3 ± 4.47	87.3 ± 5.13	10.2 ± 2.99	3 / 56	0
Yi et al. (2020) (22)	WALANT	20	NA	86 ($p = 0.079$)	49 ($p = 0.67$)	NA	1 ($p = 0.009$)	NA	NA	NA	NA	NA	1 / 20	1
	GA	20		102	63		2						3 / 20	0
Hamid et al. (2021) (20)	WALANT	32	NA	61.22 ± 7.72	14.88 ± 5.29	2.66 ± 0.60	NA	NA	70.47 ± 8.17	72.81 ± 7.18	NA	4.09 ± 0.89	0 / 32	0
	GA	33		55.30 ± 7.90	13.03 ± 2.78	2.85 ± 0.80			71.36 ± 5.63	74.55 ± 5.64		4.45 ± 0.87	2 / 33	2

SD, standard deviation; VAS, visual analog scale; QuickDASH, Quick Disabilities of the Arm, Shoulder and Hand questionnaire; WALANT, wide-awake local anesthesia and no tourniquet; GA, general anesthesia; NA, not applicable.

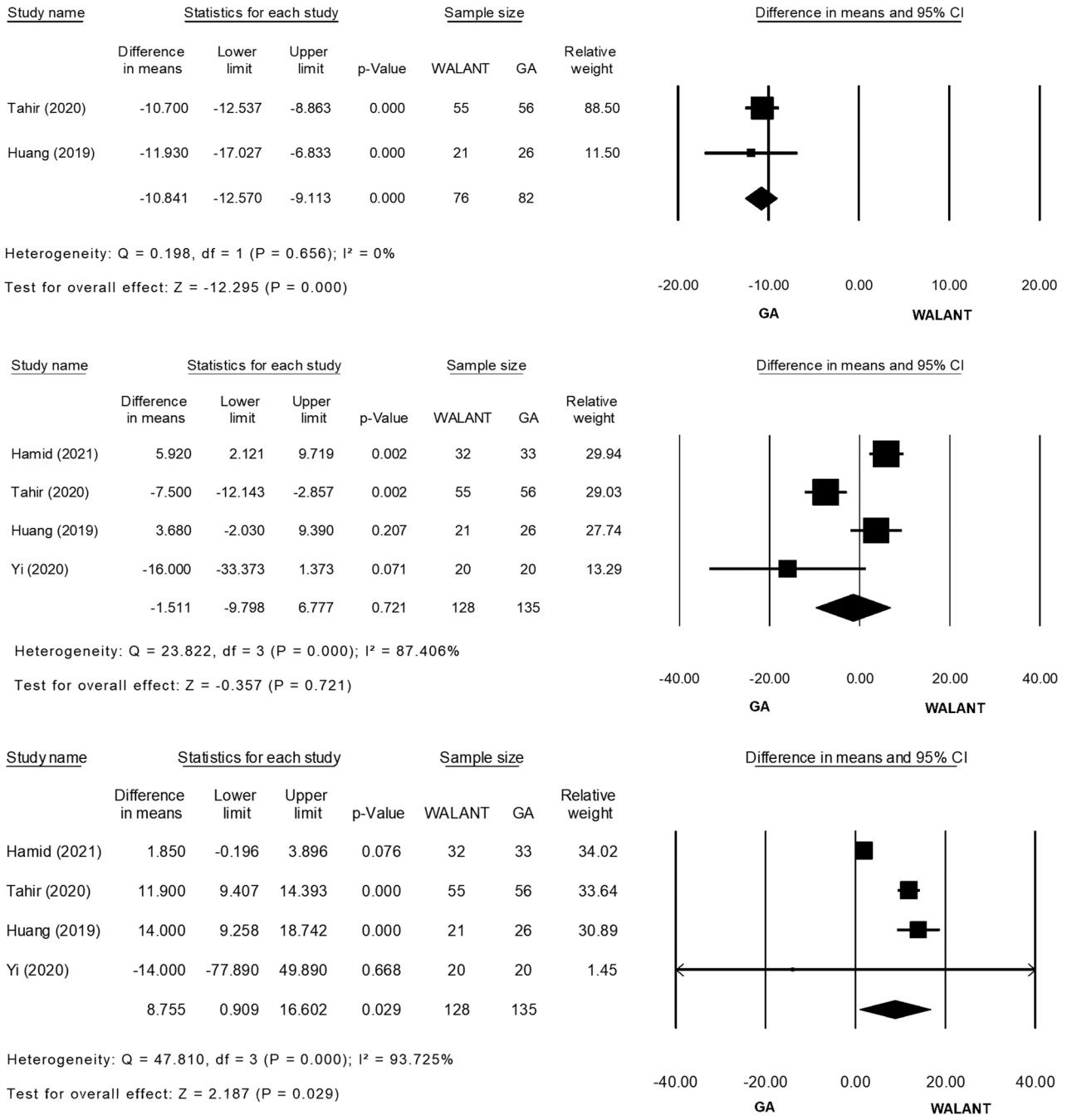

FIGURE 2 | (Continued)

DISCUSSION

For a long time, epinephrine was considered the leading cause of severe complications, such as gangrene or necrosis, following hand or wrist surgeries. However, Lalonde et al. showed that epinephrine injections produced no digital tissue loss or skin necrosis in 3,110 consecutive patients (3). Because epinephrine was proven safe, McKee et al. (23, 24) proposed waiting approximately 30 min after administering the injection to maximize hemostasis before making an incision. The widely accepted maximal dose of lidocaine that is believed to be safe for upper extremity surgery is 7 mg/kg (25). The addition of epinephrine prolongs the duration of action of lidocaine from 30–60 min to 120–360 min (26). The acidity of the solution (pH: 4.2) is likely to cause pain to the patient during injection; therefore, buffering the WALANT solution (1%

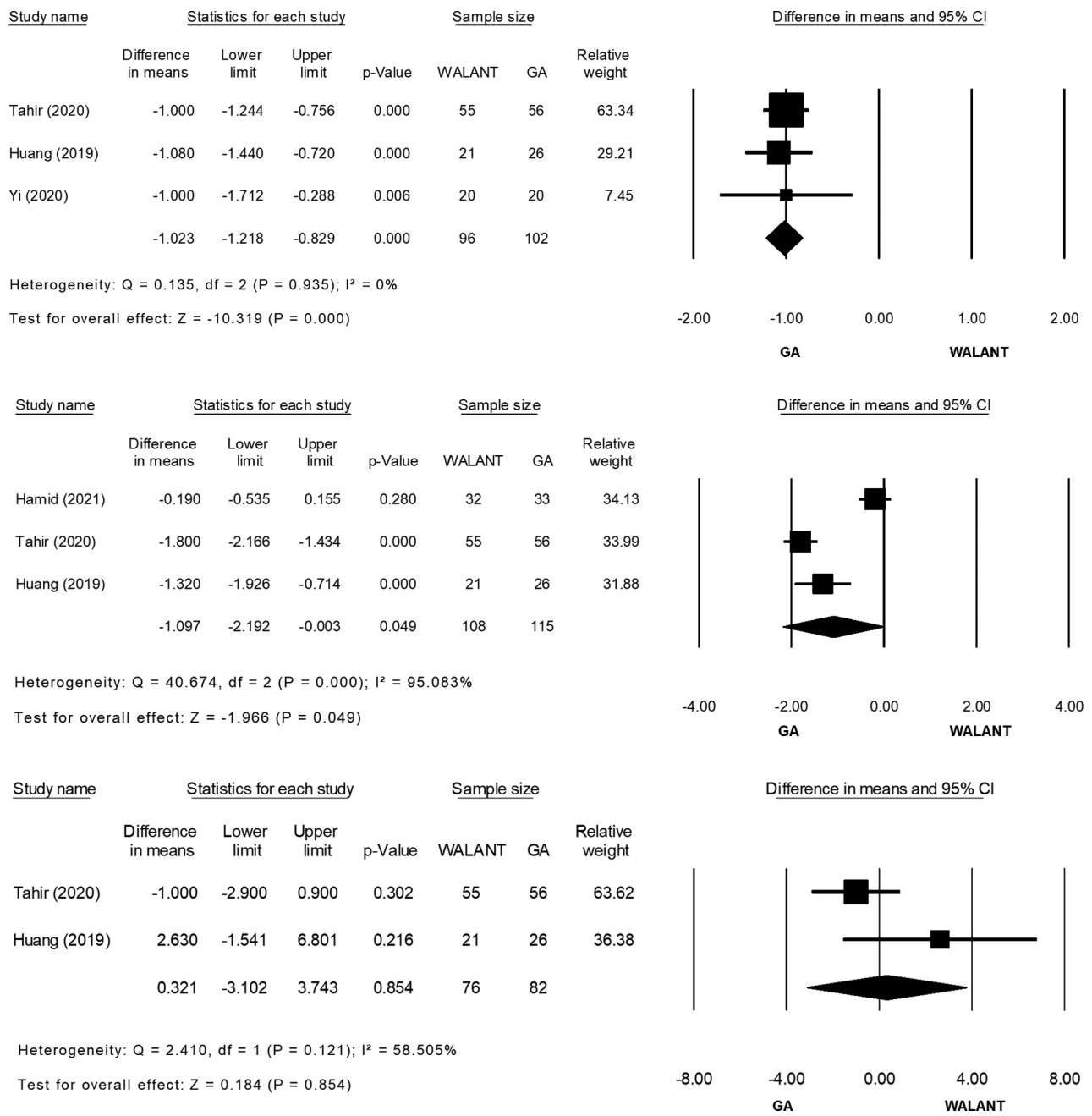

FIGURE 2 | (Continued)

lidocaine with 1:100,000 epinephrine) with 8.4% sodium bicarbonate at a ratio of 1:20 to reach the physiologic pH of 7.4 was recommended (27, 28). According to a Cochrane review (29), patients favor buffered lidocaine over unbuffered lidocaine.

WALANT appears to be a safe, cost-effective, and time-efficient technique. Compared with GA, the primary advantages of WALANT are that (1) because a tourniquet is not required, postoperative discomfort, muscle necrosis, and nerve injury can be avoided. (2) Deep sedation is not essential; thus, recovery is faster, fewer side effects such as nausea and vomiting occur, and the anesthesia risk in older patients with multiple comorbidities is lower. (3) Patients do not need to fast overnight, which minimizes the risk of glycemic change in patients with diabetes before surgery. (4) Preoperative testing—such as blood tests, chest radiographs, electrocardiography, and medical clearance—and the services of an anesthesiologist and postoperative anesthetic care are

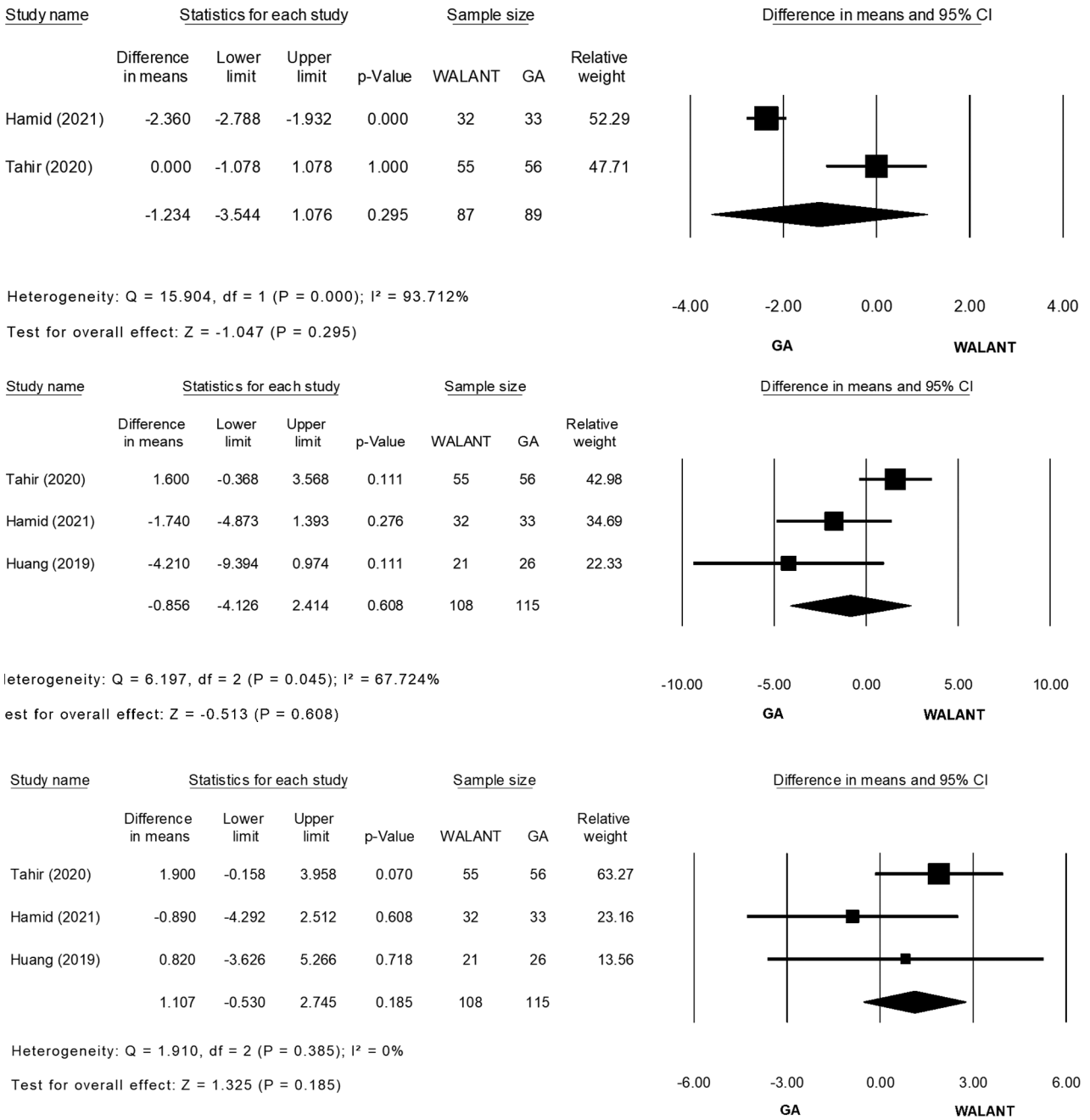

FIGURE 2 | (Continued)

not required, which thereby saves time and decreases costs (30). However, WALANT application was restricted in case of patients with needle phobia, peripheral vascular diseases or active infection, bleeding tendency, abnormal clotting profile, and hypersensitivity to lidocaine (2).

A mean saving of USD 1320 in health care costs, including anesthesia cost, preoperative cost, and postoperative cost, was noted in an American study in which the cost of WALANT was compared with that of GA in surgery for carpal tunnel syndrome (31). Furthermore, despite the MDs in annual household incomes between the United States and Pakistan, Tahir et al. demonstrated that WALANT costs less in hospital spending (USD 202.10; $p < 0.001$) compared with GA in terms of repairs of distal radius fracture in both countries (2). In contrast, Caggiano et al. (32) showed that the choice of anesthesia considerably affected total nonsurgical time, room turnover time, in-room presurgical time, and in-room postsurgical time; for instance, local

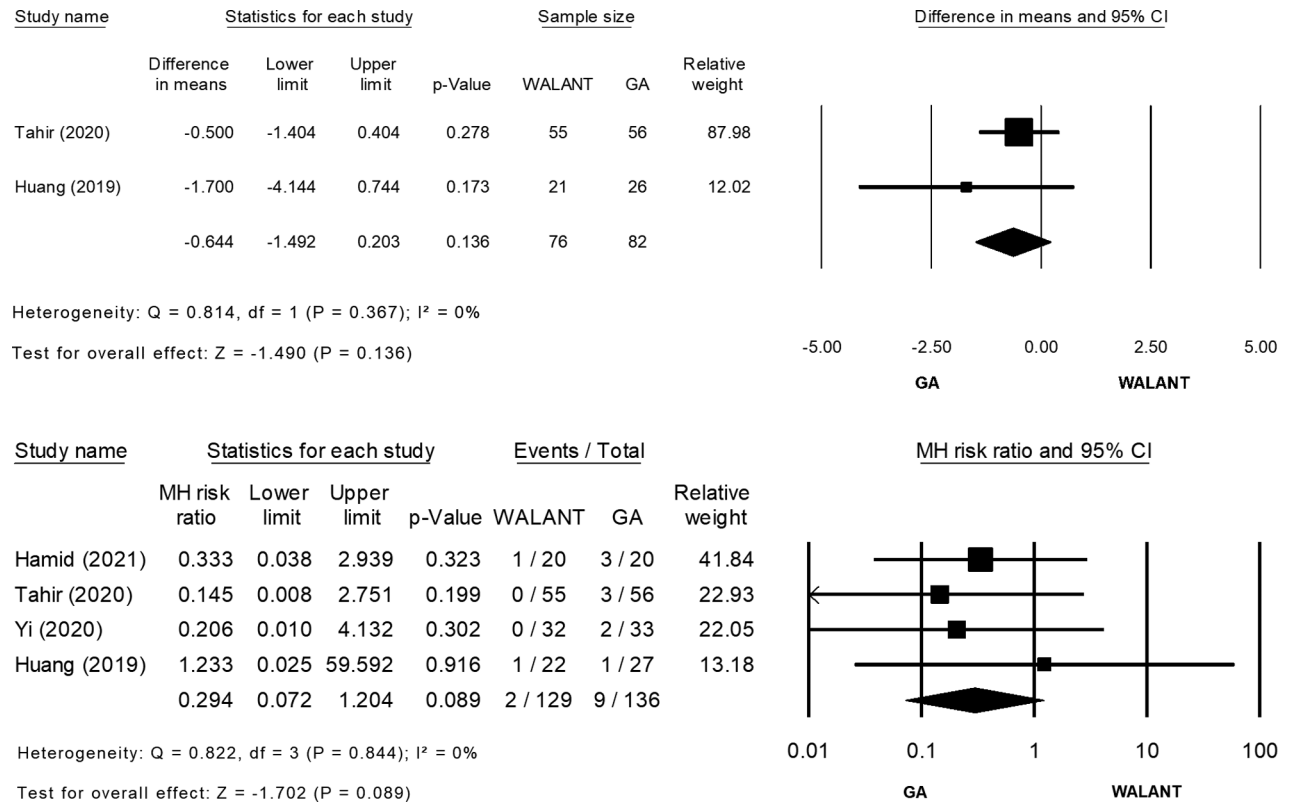

FIGURE 2 | (**A**) Forest plot of Preparation time for surgery (minute) comparing WALANT with GA. (**B**) Forest plot of Surgery time (minute) comparing WALANT with GA. (**C**) Forest plot of Blood loss (mL) comparing WALANT with GA. (**D**) Forest plot of Postoperative Hospital stays comparing WALANT with GA. (**E**) Forest plot of Post-operation day 1 visual analog scale (VAS) comparing WALANT with GA. (**F**) Forest plot of Mayo Wrist score comparing WALANT with GA. (**G**) Forest plot of Quick DASH score comparing WALANT with GA. (**H**) Forest plot of Wrist Flexion (degree) comparing WALANT with GA. (**I**) Forest plot of Wrist Extension (degree) comparing WALANT with GA. (**J**) Forest plot of Union time (week) comparing WALANT with GA. (**K**) Forest plot of Complication rate comparing WALANT with GA.

anesthesia reduced the total nonsurgical time by 40% in comparison with GA. In the repair of distal radius fractures, WALANT, a safe, cost-effective, and time-efficient technique, resulted in better patient satisfaction ($p < 0.001$) compared with GA (2).

In this quantitative, comparative meta-analysis of four studies (two retrospective cohort studies and two RCTs) with a total of 263 patients, C2 and A2 were the most common types of distal radius fractures according to the AO/OTA classification. With WALANT, preparation for surgery and postoperative hospitalization were shorter and VAS scores on postoperative day 1 were lower, but blood loss was greater in comparison with GA. For conventional GA, an anesthesiologist and nursing staff must be available, in addition to information about the patient's medical history and vital sign monitoring equipment, before and after anesthesia induction, and the patient needs to be intubated. WALANT does not require the abovementioned staff and procedures, and surgical preparation time can thus be substantially shortened. Because a tourniquet is not used, the pain in the upper arm is reduced, and the painful swelling and ecchymosis caused by the immediate venous return after release of the tourniquet can be avoided. When pain decreases and the effects of deep sedation, including nausea, vomiting, and dizziness, do not occur, hospitalization is considerably shortened. However, no significant differences were found between the two techniques in terms of the functional outcome (ROM, QuickDASH score, and Mayo wrist score), complication rate, and time to bone union. The total complication rates were lower after surgery using WALANT (0.8%) than after surgery using GA (5.9%), and the proportions of patients requiring revision surgery using WALANT (0.8%) were lower than those using GA (1.5%).

Complications with GA occurred in three patients in the study by Yi et al. (20), who experienced nausea and vomiting for 1 day; in one patient with attrition injury and two patients with mild wound inflammation in the study by Tahir et al. (2); and in one patient with screw penetration of the wrist joint and another with distal radioulnar joint dissociation (both of whom underwent subsequent revision surgery) in the study by Hamid et al. (20). Conversely, complications with WALANT—a reduction in radial inclination and an increase in dorsal tilt, treated using revision surgery with K-wire augmentation—were noted in

TABLE 3 | Risk of bias assessment of included studies.

Study	Newcastle–Ottawa scale	Selection bias				Comparability bias	Outcome bias			Quality
		Representativeness of the exposed cohort	Selection of the non-exposed cohort	Ascertainment of exposure	Outcome of interest was not present at start of study	Comparability of cohorts on the design	Assessment of outcome	Follow-up long enough for outcomes to occur	Adequacy of follow-up of cohorts	
Huang et al. (2019) (21)	RCS	*	*	*	*	*	*	*	*	High
Yi et al. (2020) (22)	RCS	*	*	*	*	*	*	*	*	High

Study	ROB	Selection bias		Reporting bias	Performance bias	Detection bias	Attrition bias	Other bias	Risk of bias
		Random sequence generation	Allocation concealment						
Tahir et al. (2020) (2)	RCT	Low	Low	Low	High	Low	Low	Low	High
Hamid et al. (2021) (20)	RCT	Low	Unclear	Unclear	High	Unclear	Low	Low	High

On Newcastle–Ottawa scale, high quality: 8–9 stars (*), moderate quality: 5–7 stars (*), low quality: <5 stars (*).
RCS, Retrospective cohort study; RCT, Randomized controlled trial; ROB, The Cochrane Collaboration's Risk of Bias Tool.

one patient in the study by Yi et al.. The definitive functional outcome and complication rate after surgery should depend on the severity of the fracture in terms of whether it involves the joint surface, the appropriate selection and placement of an implant, and the reduction and surgical technique. In addition to disparate surgery-related problems, different postoperative rehabilitation protocols and medications may have contributed to the discrepancies in functional outcomes among the studies. Therefore, the present study of these two different anesthesia approaches revealed only differences in immediate recovery and pain after surgery but not in different functional outcomes and complication rates.

This study had several limitations. First, the follow-up periods in most studies varied and were no more than 1 year; several outcomes and complications may have emerged during a more extended follow-up period. Second, these four studies with small sample sizes (two nonrandomized controlled studies and two randomized controlled studies with an overall high risk of bias) may have been affected by various biases and a low statistical power. Third, the high heterogeneity among studies that was observed for some outcomes may be attributable to different covariates. Incongruous distribution among different types of distal radius fractures and different WALANT solution formulas presumably resulted in heterogeneity in surgery duration and blood loss among studies. Last, despite the apparently lower complication rate using WALANT compared with GA, some of the complications that necessitated secondary revisions were associated with technical problems rather than problems associated with anesthesia. The misattribution of these complications might cause misclassification bias. There are still some distinctions in the anesthesia methods used in these included articles. Moreover, different epinephrine and xylocaine concentrations were administered. Further research is essential for further investigation and objective observations of factors such as oozing status, difficulty of reduction, patients' pain perceptions, and variation in vital signs during surgery.

In summary, this systemic review and meta-analysis demonstrated that WALANT, in comparison with GA, shortened the time required for the preparation of surgery, shortened postoperative hospitalization, and resulted in less pain 1 day after distal radius fracture fixation; however, blood loss was greater with WALANT, which is a drawback. According to some studies (2, 21), even if blood loss is greater without the use of a tourniquet, it is still minimal and does not affect the operation. Otherwise, the final functional outcome and complication rates did differ considerably between the two different anesthetic approaches. Although this study showed that WALANT is a favorable alternative to GA in terms of reliability, cost-effectiveness, and time saved, each patient should be treated on a case-by-case basis because both treatments have benefits and drawbacks.

DATA AVAILABILITY STATEMENT

The original contributions presented in the study are included in the article/Supplementary Material, further inquiries can be directed to the corresponding author/s.

AUTHOR CONTRIBUTIONS

Study conception and design: C-YC; Acquisition of data: T-YT; Analysis and interpretation of data: T-YT, C-YH, P-CL, C-YC; Writing (original draft preparation): T-YT; Writing (review and editing): C-YH, P-CL, C-YC; Guarantor: C-YC. All authors contributed to the article and approved the submitted version.

ACKNOWLEDGMENTS

We thank all the authors of the studies included in our meta-analysis and meta-analysis discussion group of Kaohsiung Veterans General Hospital. Special thanks to Hamid et al. and Universiti Kebangsaan Malaysia, Kuala Lumpur, MYS.

REFERENCES

1. Nellans KW, Kowalski E, Chung KC. The epidemiology of distal radius fractures. *Hand Clin*. (2012) 28(2):113–25. doi: 10.1016/j.hcl.2012.02.001
2. Tahir M, Chaudhry EA, Zaffar Z, Anwar K, Mamoon MAH, Ahmad M, et al. Fixation of distal radius fractures using wide-awake local anaesthesia with no tourniquet (WALANT) technique. *Bone Joint Res*. (2020) 9(7):429–39. doi: 10.1302/2046-3758.97.BJR-2019-0315.R1
3. Lalonde D, Bell M, Benoit P, Sparkes G, Denkler K, Chang P. A multicenter prospective study of 3,110 consecutive scases of elective epinephrine use in the fingers and hand: the dalhousie project clinical phase. *J Hand Surg*. (2005) 30(5):1061–7. doi: 10.1016/j.jhsa.2005.05.006
4. Pires Neto PJ, Moreira LA, Las Casas PP. Is it safe to use local anesthesia with adrenaline in hand surgery? WALANT technique. *Rev Bras Ortop*. (2017) 52 (4):383–9. doi: 10.1016/j.rbo.2017.05.002
5. Codding JL, Bhat SB, Ilyas AM. An economic analysis of MAC versus WALANT: a trigger finger release surgery case study. *Hand (New York, NY)*. (2017) 12(4):348–51. doi: 10.1177/1558944716669693
6. Gunasagaran J, Sean ES, Shivdas S, Amir S, Ahmad TS. Perceived comfort during minor hand surgeries with wide awake local anaesthesia no tourniquet (WALANT) versus local anaesthesia (LA)/tourniquet. *J Orthop Surg (Hong Kong)*. (2017) 25(3):2309499017739499. doi: 10.1177/2309499017739499
7. Hagert E, Lalonde DH. Wide-awake wrist arthroscopy and open TFCC repair. *J Wrist Surg*. (2012) 1(1):55–60. doi: 10.1055/s-0032-1312045
8. Prasetyono TO. Tourniquet-Free hand surgery using the one-per-mil tumescent technique. *Arch Plast Surg*. (2013) 40(2):129–33. doi: 10.5999/aps.2013.40.2.129
9. Lalonde D, Martin A. Epinephrine in local anesthesia in finger and hand surgery: the case for wide-awake anesthesia. *J Am Acad Orthop Surg*. (2013) 21(8):443–7. doi: 10.5435/JAAOS-21-08-443
10. Nakanishi Y, Omokawa S, Kobata Y, Shimizu T, Kira T, Onishi T, et al. Ultrasound-guided selective sensory nerve block for wide-awake forearm tendon reconstruction. *Plast Reconstr Surg Glob open*. (2015) 3(5):e392. doi: 10.1097/GOX.0000000000000365
11. Xing SG, Tang JB. Surgical treatment, hardware removal, and the wide-awake approach for metacarpal fractures. *Clin Plast Surg*. (2014) 41(3):463–80. doi: 10.1016/j.cps.2014.03.005
12. Teo I, Lam W, Muthayya P, Steele K, Alexander S, Miller G. Patients' perspective of wide-awake hand surgery–100 consecutive cases. *J Hand Surg Eur Vol*. (2013) 38(9):992–9. doi: 10.1177/1753193412475241

13. Al Youha S, Lalonde DH. Update/Review: changing of use of local anesthesia in the hand. *Plast Reconstr Surg Glob open*. (2014) 2(5):e150. doi: 10.1097/GOX.0000000000000095
14. Bismil M, Bismil Q, Harding D, Harris P, Lamyman E, Sansby L. Transition to total one-stop wide-awake hand surgery service-audit: a retrospective review. *JRSM Short Rep*. (2012) 3(4):23. doi: 10.1258/shorts.2012.012019
15. Lalonde D, Martin A. Tumescent local anesthesia for hand surgery: improved results, cost effectiveness, and wide-awake patient satisfaction. *Arch Plast Surg*. (2014) 41(4):312–6. doi: 10.5999/aps.2014.41.4.312
16. Higgins JPT, Altman DG, Gøtzsche PC, Jüni P, Moher D, Oxman AD, et al. The Cochrane Collaboration's tool for assessing risk of bias in randomised trials. *BMJ*. (2011) 343:d5928. doi: 10.1136/bmj.d5928
17. Hardy RJ, Thompson SG. Detecting and describing heterogeneity in meta-analysis. *Stat Med*. (1998) 17(8):841–56. doi: 10.1002/(SICI)1097-0258(19980430)17:8<841::AID-SIM781>3.0.CO;2-D
18. Takkouche B, Cadarso-Suárez C, Spiegelman D. Evaluation of old and new tests of heterogeneity in epidemiologic meta-analysis. *Am J Epidemiol*. (1999) 150(2):206–15. doi: 10.1093/oxfordjournals.aje.a009981
19. Combining Information. *Statistical issues and opportunities for research*. Washington, DC: The National Academies Press (1992).
20. Abd Hamid MH, Abdullah S, Ahmad AA, Narin Singh PSG, Soh EZF, Liu CY, et al. A randomized controlled trial comparing wide-awake local anesthesia with no tourniquet (WALANT) to general anesthesia in plating of distal radius fractures with pain and anxiety level perception. *Cureus*. (2021) 13(1):e12876. doi: 10.7759/cureus.12876
21. Huang YC, Chen CY, Lin KC, Yang SW, Tarng YW, Chang WN. Comparison of wide-awake local anesthesia no tourniquet with general anesthesia with tourniquet for volar plating of distal radius fracture. *Orthopedics*. (2019) 42(1):e93–8. doi: 10.3928/01477447-20181206-01
22. Yi LM, Ahmad AA, Ruslan SR, Abdullah S, Ahmad AR. Plating distal radius fractures using wide-awake local anesthesia no tourniquet (WALANT) versus general anesthesia: a cohort study. *J Hand Surg Glob Online*. (2020) 2(6):331–8. doi: 10.1016/j.jhsg.2020.09.003
23. McKee DE, Lalonde DH, Thoma A, Glennie DL, Hayward JE. Optimal time delay between epinephrine injection and incision to minimize bleeding. *Plast Reconstr Surg*. (2013) 131(4):811–4. doi: 10.1097/PRS.0b013e3182818ced
24. McKee DE, Lalonde DH, Thoma A, Dickson L. Achieving the optimal epinephrine effect in wide awake hand surgery using local anesthesia without a tourniquet. *Hand (New York, NY)*. (2015) 10(4):613–5. doi: 10.1007/s11552-015-9759-6
25. Lalonde DH, Wong A. Dosage of local anesthesia in wide awake hand surgery. *J Hand Surg*. (2013) 38(10):2025–8. doi: 10.1016/j.jhsa.2013.07.017
26. Higgins A, Lalonde DH, Bell M, McKee D, Lalonde JF. Avoiding flexor tendon repair rupture with intraoperative total active movement examination. *Plast Reconstr Surg*. (2010) 126(3):941–5. doi: 10.1097/PRS.0b013e3181e60489
27. Lee HJ, Cho YJ, Gong HS, Rhee SH, Park HS, Baek GH. The effect of buffered lidocaine in local anesthesia: a prospective, randomized, double-blind study. *J Hand Surg*. (2013) 38(5):971–5. doi: 10.1016/j.jhsa.2013.02.016
28. Strazar AR, Leynes PG, Lalonde DH. Minimizing the pain of local anesthesia injection. *Plast Reconstr Surg*. (2013) 132(3):675–84. doi: 10.1097/PRS.0b013e31829ad1e2
29. Cepeda MS, Tzortzopoulou A, Thackrey M, Hudcova J, Arora Gandhi P, Schumann R. Adjusting the pH of lidocaine for reducing pain on injection. *Cochrane Database Syst Rev*. (2010) (12):Cd006581. doi: 10.1002/14651858.CD006581.pub2
30. Steiner MM, Calandruccio JH. Use of wide-awake local anesthesia no tourniquet in hand and wrist surgery. *Orthop Clin North Am*. (2018) 49(1):63–8. doi: 10.1016/j.ocl.2017.08.008
31. Alter TH, Warrender WJ, Liss FE, Ilyas AM. A cost analysis of carpal tunnel release surgery performed wide awake versus under sedation. *Plast Reconstr Surg*. (2018) 142(6):1532–8. doi: 10.1097/PRS.0000000000004983
32. Caggiano NM, Avery 3rd DM, Matullo KS. The effect of anesthesia type on nonsurgical operating room time. *J Hand Surg*. (2015) 40(6):1202–9.e1. doi: 10.1016/j.jhsa.2015.01.037

Conflict of Interest: The authors declare that the research was conducted in the absence of any commercial or financial relationships that could be construed as a potential conflict of interest.

Publisher's Note: All claims expressed in this article are solely those of the authors and do not necessarily represent those of their affiliated organizations, or those of the publisher, the editors and the reviewers. Any product that may be evaluated in this article, or claim that may be made by its manufacturer, is not guaranteed or endorsed by the publisher.

Copyright © 2022 Tu, Hsu, Lin and Chen. This is an open-access article distributed under the terms of the Creative Commons Attribution License (CC BY). The use, distribution or reproduction in other forums is permitted, provided the original author(s) and the copyright owner(s) are credited and that the original publication in this journal is cited, in accordance with accepted academic practice. No use, distribution or reproduction is permitted which does not comply with these terms.

frontiers | Frontiers in Surgery

ORIGINAL RESEARCH
published: 28 June 2022
doi: 10.3389/fsurg.2022.926745

A New Nomogram Model for Predicting 1-Year All-Cause Mortality After Hip Arthroplasty in Nonagenarians With Hip Fractures: A 20-Year Period Retrospective Cohort Study

*Xingchen Lu[1†], Ziming Wang[1†], Feifei Chong[2], Yu Wang[1], Siyu Wu[1], Quanyin Du[1], Wenlong Gou[1], Keyun Peng[1] and Yan Xiong[1]**

[1]Department of Orthopaedics, Daping Hospital, Army Medical University (Third Military Medical University), Chongqing, China, [2]Department of Clinical Nutrition, Daping Hospital, Army Medical University (Third Military Medical University), Chongqing, China

OPEN ACCESS

Edited by:
Paphon Sa-ngasoongsong, Mahidol University, Thailand

Reviewed by:
Matthew Tristan Wallace, MedStar Franklin Square Medical Center, United States
Mati Pääsuke, University of Tartu, Estonia

***Correspondence:**
Yan Xiong
xiongyan815@163.com

†These authors have contributed equally to this work

Specialty section:
This article was submitted to Orthopedic Surgery, a section of the journal Frontiers in Surgery

Received: 23 April 2022
Accepted: 31 May 2022
Published: 28 June 2022

Citation:
Lu X, Wang Z, Chong F, Wang Y, Wu S, Du Q, Gou W, Peng K and Xiong Y (2022) A New Nomogram Model for Predicting 1-Year All-Cause Mortality After Hip Arthroplasty in Nonagenarians With Hip Fractures: A 20-Year Period Retrospective Cohort Study. Front. Surg. 9:926745. doi: 10.3389/fsurg.2022.926745

Background: China has become an ageing society and as it continues to age, it will face an increasing number of hip fractures in nonagenarians. However, few preoperative assessment tools to determine the postoperative mortality risk in nonagenarians with hip fracture were available. The aim of this study was to identify all-cause mortality risk factors after hip arthroplasty in nonagenarians with hip fractures and to establish a new nomogram model to optimize the individualized hip arthroplasty in nonagenarians with hip fractures.

Methods: We retrospectively studied 246 consecutive nonagenarians diagnosed with hip fracture from August 2002 to February 2021 at our center. During the follow-up, 203 nonagenarians with a median age of 91.9 years treated with hip arthroplasty were included, of which 136 were females and 67 were males, and 43 nonagenarians were excluded (40 underwent internal fixation and 3 were lost to follow-up). The full cohort was randomly divided into training (50%) and validation (50%) sets. The potential predictive factors for 1-year all-cause mortality after hip arthroplasty were assessed by univariate and multivariate COX proportional hazards regression on the training set, and then, a new nomogram model was established and evaluated by concordance index (C-index) and calibration curves.

Results: After analyzing 44 perioperative variables including demographic characteristics, vital signs, surgical data, laboratory tests, we identified that age-adjusted Charlson Comorbidity Index (aCCI) ($p = 0.042$), American Society of Anesthesiologists (ASA) classification ($p = 0.007$), Urea ($p = 0.028$), serum Ca^{2+} ($p = 0.011$), postoperative hemoglobin ($p = 0.024$) were significant predictors for 1-year all-cause mortality after

hip arthroplasty in the training set. The nomogram showed a robust discrimination, with a C-index of 0.71 (95%CIs, 0.68–0.78). The calibration curves for 1-year all-cause mortality showed optimal agreement between the probability as predicted by the nomogram and the actual probability in training and validation sets.

Conclusion: A novel nomogram model integrating 5 independent predictive variables were established and validated. It can effectively predict 1-year all-cause mortality after hip arthroplasty in nonagenarians with hip fracture and lead to a more optimized and rational therapeutic choice.

Keywords: nomogram, nonagenarians, hip fractures, hip arthroplasty, all-cause mortality

INTRODUCTION

The aging process of China is accelerating, 115 million will be over 80 years old and 0.6 million are expected to become centenarians by 2050 (1). Population aged more than 90 years in China accounted for 15% of the global nonagenarians at the end of 2017 (2). The incidence of hip fracture increases with age (3). Unless the patients face high risk of intraoperative death or difficulties to access to surgical care, operative treatment for most hip fractures is recommended, and arthroplasty is generally preferred for the management of displaced femoral-neck fractures and unstable intertrochanteric fractures in the elderly (4, 5), because of the obvious advantages such as early weight-bearing training, reduced bed-related and implant-related complications.

Despite advances in medical and surgical treatments for geriatrics with hip fractures, postoperative mortality has increased with increasing age, especially in nonagenarians with significant comorbidity (6, 7). Several studies have investigated the risk factors contributing to mortality in the extremely old patients (8, 9), with the goal of helping clinicians and surgeons to reduce risk and improve outcomes. Nevertheless, risk factors related to 1-year mortality were rarely investigated in previous studies and few attempts have been made to quantify the contribution of established risk factors to postoperative mortality in nonagenarians with hip fracture. The aim of the present study was to develop a new nomogram model for the management of hip fractures in nonagenarians and to investigate the potential risk factors correlating with 1-year all-cause mortality after hip arthroplasty in nonagenarians.

MATERIALS AND METHODS

Date Source

We performed a retrospective cohort study to assess mortality and the risk factors that influence it following hip arthroplasty in the nonagenarians with hip fractures from August 2002 to February 2021 in Daping Hospital of Third Military Medical University (Army Medical University). The inclusion criteria were as follows: (1) patients aged more than 90 years old; (2) low-energy or fragility-type hip fractures; (3) patients who received total hip arthroplasty or hemiarthroplasty; and (4) availability of complete clinical and follow-up data. Nonagenarians with neoplastic-related pathological hip fractures and multiple fractures, as well as non-operatively managed hip fractures were excluded from the current analysis. The study protocol was approved by the Ethics Committee of Daping Hospital of Army Medical University (2022[89]). All authors had access to the results of the study, reviewed and edited the final manuscript, and were involved in the decision to submit the manuscript for publication.

Outcome Variables

The primary outcome for this study was mortality, which was obtained from the electronic medical record (EMR) and from telephone follow-ups using a uniformed questionnaire by two trained physicians. The date of the surgery was used as the starting point of the patient's observed survival time, and the end of follow-up or the date of death was used as the observation end point. The follow-up period ended on February 28, 2022. Patients were considered lost to follow-up if they were out of contact or refused to provide the current information. In order to analyze which variables were the potential risk factors relating to postoperative mortality, 44 preoperative, intraoperative, and postoperative variables were collected and analyzed. Age-adjusted Charlson Comorbidity Index (aCCI) and ASA classification were subsequently calculated for each patient as a global measure of health status (**Table 2**).

Model Construction and Evaluation

The patients were randomly assigned into training (50%) and validation (50%) sets. Univariate and multivariate COX proportional hazards regression were performed on the training set to identify the significant independent factors. A nomogram was then established to present these factors and their corresponding points for the risk of 1-year all-cause mortality. The predictive accuracy and discriminative ability were determined using the C-index. Calibration of the nomogram for 1-year all-cause mortality was performed by comparing the predicted and observed probability.

Statistical Analysis

Statistical analyses were performed using R package version 4.1.0 (Institute for Statistics and Mathematics, Vienna, Austria). Categorical variables were described as count (%)

and compared using the chi-square test or Fisher's exact test, while continuous variables were described as $\bar{x} \pm s$ and compared using the t-test. The missing values of all potential predictors (missing rate of less than 10.0%) were imputed by expectation-maximization (EM) method. Univariate Cox regression analysis was adopted to identify the potential predictive factors which reached a p value of less than 0.05 in training set. Then the variables with $p < 0.05$ were entered into multivariate COX proportional hazards regression to screen the significant independent factors. Hazard ratio (HR) was estimated, and the corresponding 95% confidence interval (95% CI) and p value were reported at the same time. The rms package was used to formulate a prognostic nomogram based on the results of multivariate analysis. The C-index and the calibration curve were applied to assess the discrimination and calibration of the nomogram. $p < 0.05$ was considered statistically significant.

RESULTS

Baseline Characteristics

During the study period, 246 nonagenarians who suffered hip fractures underwent operations. Of these, 203 patients who met the inclusion criteria were enrolled, and the remaining 43 were excluded (40 underwent internal fixation and 3 were lost to follow-up). For the 203 nonagenarians, the observed survival time was 1–120 months, average of 31.08 months, median of 60.5 months. The cumulative deaths in postoperative 1 month, 3 months, 6 months and 12 months was 21(10.3%), 30(14.8%), 37(18.2%) and 58(29.6%), respectively. The main causes of death were presented in **Table 1**. 203 eligible patients were randomly divided into training (50%, $n = 102$) and validation (50%, $n = 101$) sets. The baseline characteristics of the patients including demographic characteristics, vital signs, surgical data and laboratory tests

TABLE 1 | The main causes of 58 deaths.

System	Disease	Number
MODS	Two or more organ systems presented dysfunctional	13
Cardiogenic Disease	Myocardial Infarction, Cardiac Failure, Malignant Arhythmia	8
Cerebral Diseases	Cerebral Infarction, Cerebral Hemorrhage	5
Respiratory Diseases	Respiratory Failure, Pulmonary Infection	4
Digestive Diseases	Gastrointestinal Hemorrhage, Infection of Digestive canal	2
Accidents	The patients fell while walking and died after a period of time in bed	2
Malignant Tumor	liver cancer	1
Dysoemia	The patients died at home and the causes of death were not confirmed by doctors	23

MODS, Multiple Organ Dysfunction Syndrome.

TABLE 2 | Demographic and clinical characteristics of the included nonagenarians with hip fracture.

Variables	Training ($n = 102$)	Validation ($n = 101$)	p-value
Age cohorts (years), No. (%)			
90–94	89 (87.3)	86 (85.1)	0.663
≥95	13 (12.7)	15 (14.9)	
Gender (female), No. (%)	72 (70.6)	64 (63.4)	0.298
Length before admission (hours), No. (%)			
≤72	46 (45.1)	46 (45.5)	0.736
73–168	34 (33.3)	39 (38.6)	
169–504	16 (15.7)	12 (11.9)	
>504	6 (5.9)	4 (4.0)	
Preoperative length of stay (days), No. (%)			
<2	47 (46.1)	32 (31.7)	0.029
2–3	16 (15.7)	30 (29.7)	
>3	39 (38.2)	39 (38.6)	
Fracture type, No. (%)			
Femoral neck fracture	37 (36.3)	48 (47.5)	0.119
Intertrochanteric fracture	65 (63.7)	53 (52.5)	
Left/Right, No. (%)			
Left	60 (58.8)	60 (59.4)	1.000
Right	42 (41.2)	41 (40.6)	
aCCI, mean (SD)	5.09 ± 1.05	5.03 ± 1.01	0.687
Pulse (beats/min), No. (%)			
<60	4 (3.9)	3 (3.0)	0.418
60–100	89 (87.3)	83 (82.2)	
>100	9 (8.8)	15 (14.9)	
Systolic pressure (mmHg), No. (%)			
90–119	9 (8.8)	18 (17.8)	0.188
120–139	34 (33.3)	38 (37.6)	
140–159	30 (29.4)	24 (23.8)	
160–179	23 (22.5)	14 (13.9)	
≥180	6 (5.9)	7 (6.9)	
Diastolic pressure (mmHg), No. (%)			
<60	8 (7.8)	9 (8.9)	0.596
60–79	54 (52.9)	57 (56.4)	
80–89	32 (31.4)	23 (22.8)	
90–99	7 (6.9)	9 (8.9)	
100–109	1 (1.0)	3 (3.0)	
Cardiac function classification, No. (%)			
NYHA I&II	73 (71.5)	68 (67.3)	0.512
NYHA III&IV	29 (28.4)	33 (32.7)	
ASA classification, No. (%)			
ASA I&II	46 (45.1)	41 (40.6)	0.571
ASA III&IV	56 (54.9)	60 (59.4)	
Operation type, No. (%)			
Hemiarthroplasty	94 (92.2)	97 (96.0)	0.373
Total hip arthroplasty	8 (7.8)	4 (4.0)	

(*continued*)

TABLE 2 | Continued

Variables	Training (*n* = 102)	Validation (*n* = 101)	*p*-value
Anesthesia, No. (%)			
Nerve block anesthesia	88 (86.3)	88 (87.1)	1.000
Intravertebral anesthesia	10 (9.8)	9 (8.9)	
General anesthesia	4 (3.9)	4 (4.0)	
Operation time (min), No. (%)			
<60	8 (7.8)	4 (4.0)	0.399
60–120	86 (84.3)	91 (90.1)	
>120	8 (7.8)	6 (5.9)	
Blood transfusion, No. (%)	25 (24.5)	20 (19.8)	0.500
White-cell count ($\times10^9$/L), No. (%)			
<4.00	2 (2.0)	3 (3.0)	0.879
4.00–10.00	75 (73.5)	72 (71.3)	
≥10.01	25 (24.5)	26 (25.7)	
Platelet count ($\times10^9$/L), No. (%)			
<100	11 (10.8)	17 (16.8)	0.421
100–300	82 (80.4)	74 (73.3)	
>300	9 (8.8)	10 (9.9)	
Percentage of neutrophl >75%, No. (%)	55 (53.9)	66 (65.3)	0.116
Hematocrit, No. (%)			
≥40 (Male), ≥35 (Female)	21 (20.6)	20 (19.8)	0.889
<40 (Male), <35 (Female)	81 (79.4)	81 (80.2)	
Albumin <35 g/L, No. (%)	65 (63.7)	30 (70.3)	0.371
Albumin/Globulin, No. (%)			
<1.2	56 (54.9)	48 (47.5)	0.292
1.2–2.4	45 (44.1)	53 (52.5)	
>2.4	1 (1.0)	0 (0.0)	
Lactate dehydrogenase >250 U/L, No. (%)	28 (27.5)	23 (22.8)	0.518
Alkaline phosphatase >125 U/L (Male) & >135 U/L(Female), No. (%)	10 (9.8)	8 (7.9)	0.806
Na+(mmol/L), No. (%)			
<135	20 (19.6)	20 (19.8)	0.764
135–145	79 (77.5)	80 (79.2)	
>145	3 (2.9)	1 (1.0)	
K+(mmol/L), No. (%)			
<3.5	8 (7.8)	19 (18.8)	0.030
3.5–5.5	93 (91.2)	82 (81.2)	
>5.5	1 (1.0)	0 (0.0)	
Anion gap (mmol/L), No. (%)			
<8	18 (17.6)	23 (22.8)	0.099
8–16	80 (78.4)	78 (77.2)	
>16	4 (3.9)	0 (0.0)	
Creatinine ≥97 μmmol/L, No. (%)	28 (27.5)	19 (18.8)	0.183
Urea >8.0 mmol/L, No. (%)	49 (48.0)	42 (41.6)	0.398
FIB(g/L), No. (%)			
<2	3 (2.9)	0 (0.0)	0.204
2–4	44 (43.1)	40 (39.6)	
>4	55 (53.9)	61 (60.4)	
APTT(s), No. (%)			
<24	5 (4.9)	1 (1.0)	0.292
24–40	95 (93.1)	99 (98.0)	
>40	2 (2.0)	1 (1.0)	
TT(s), No. (%)			
<11	0 (0.0)	2 (2.0)	0.495
11–18	101 (99.0)	98 (97.0)	
>18	1 (1.0)	1 (1.0)	
PT1(s), No. (%)			
<9.4	2 (2.0)	0 (0.0)	0.317
9.4–13.8	94 (92.2)	97 (96.0)	
>13.8	6 (5.9)	4 (4.0)	
PTINR, No. (%)			
<0.76	1 (1.0)	0 (0.0)	0.609
0.76–1.16	96 (94.1)	98 (97.0)	
>1.16	5 (4.9)	3 (3.0)	
D-dimmer >500 μg/L, No. (%)	92 (90.2)	98 (97.0)	0.082
CRP >10 mg/L, No. (%)	80 (78.4)	90 (89.1)	0.056
ESR >20 mm/60 min, No. (%)	78 (76.5)	81 (80.2)	0.610
Blood glucose(mmol/L), No. (%)			
<3.9	3 (2.9)	1 (1.0)	0.607
3.9–6.9	81 (79.4)	84 (83.2)	
≥7.0	18 (17.6)	16 (15.8)	
Total bilirubin >23 μmmol/L, No. (%)	18 (17.6)	20 (19.8)	0.722
Ca^{2+} <2.11 mmol/L, No. (%)	57 (55.9)	62 (61.4)	0.477
cl^-(mmol/L), No. (%)			
<99	18 (17.6)	14 (13.9)	0.516
99–110	76 (74.5)	82 (81.2)	
>110	8 (7.8)	5 (5.0)	
Preoperative hemoglobin (g/L)	104.92 ± 18.28	107.07 ± 19.45	0.419
Postoperative hemoglobin (g/L)	86.82 ± 13.28	89.83 ± 13.62	0.113

aCCI, age-adjusted Charlson Comorbidity Index; ASA classification, American Society of Anesthesiologists classification; Na^+, serum sodium; K^+, serum potassium; Ca2+, serum calcium; cl-, serum chlorine; FIB, fibrinogen; APTT, activated partial thromboplastin time; TT, thrombin time; PT1, prothrombin time 1; PTINR, international normalized ratio of prothrombin time; CRP, C-reactive protein; ESR, erythrocyte sedimentation rate.

are listed in **Table 2**. The baseline data were similar between the training and validation set, and deaths of 30 (29.4%) and 28 (27.7%) in the training and validation set, respectively

TABLE 3 | Univariate and multivariate COX proportional hazards regression analysis of the fatal outcome of nonagenarians undergoing arthroplasty after hip fracture in the Training cohort.

Variables	Univariate COX analysis		Multivariate COX analysis	
	HR (95% CIs)	*p*	HR (95% CIs)	*p*
Age (≥95 years)	1.04 (0.66–1.66)	0.859		
Gender (female), No. (%)	0.91 (0.55–1.5)	0.698		
Length before admission (hours)				
≤72	Ref.			
73–168	1.08 (0.63–1.83)	0.786		
169–504	1.24 (0.63–2.46)	0.533		
>504	0.62 (0.24–1.62)	0.330		
Preoperative length of stay (days)				
<2	Ref.			
2–3	1.07 (0.54–2.12)	0.837		
>3	1.05 (0.64–1.74)	0.842		
Fracture type (Intertrochanteric fracture)	1.5 (0.93–2.43)	0.097		
Left/Right	1.18 (0.74–1.87)	0.484		
aCCI	1.48 (1.18–1.87)	0.001	1.3 (1.01–1.67)	0.042
Pulse (beats/min)				
<60	Ref.			
60–100	1.29 (0.4–4.11)	0.671		
>100	1.83 (0.47–7.13)	0.384		
Systolic pressure (mmHg)				
90–119	Ref.			
120–139	0.88 (0.39–1.96)	0.750		
140–159	0.77 (0.33–1.8)	0.549		
160–179	1.08 (0.46–2.53)	0.867		
≥180	1.12 (0.33–3.77)	0.856		
Diastolic pressure (mmHg)				
<60	Ref.			
60–79	0.91 (0.36–2.32)	0.840		
80–89	0.94 (0.35–2.48)	0.895		
90–99	0.38 (0.1–1.44)	0.155		
100–109	2.37 (0.27–20.61)	0.434		
Cardiac function classification (NYHA III&IV)	1.26 (0.93–1.7)	0.131		
ASA classification (ASA III&IV)	1.97 (1.22–3.18)	0.006	2.05 (1.22–3.44)	0.007
Operation type (Hemiarthroplasty)	0.88 (0.38–2.07)	0.775		
Anesthesia				
Nerve block anesthesia	Ref.			
Intravertebral anesthesia	1.16 (0.52–2.58	0.714		
General anesthesia	1.01 (0.36–2.78	0.989		
Operation time (min)				
<60	Ref.			
60–120	0.88 (0.35–2.21)	0.791		
>120	0.98 (0.32–3.03)	0.978		
Blood transfusion	1.51 (0.86–2.64)	0.148		
White-cell count ($\times 10^9$/L)				
<4.00	Ref.			

(*continued*)

TABLE 3 | Continued

Variables	Univariate COX analysis		Multivariate COX analysis	
	HR (95% CIs)	*p*	HR (95% CIs)	*p*
4.00–10.00	1.3 (0.3–5.72)	0.728		
≥10.01	1.82 (0.39–8.44)	0.442		
Platelet count ($\times10^9$/L)				
<100	Ref.			
100–300	1.14 (0.54–2.4)	0.724		
>300	1.48 (0.53–4.12)	0.451		
Percentage of neutrophl >75%	1.94 (1.2–3.13)	0.007		
Hematocrit <40 (Male), <35 (Female)	1.72 (0.92–3.21)	0.087		
Albumin <35 g/L	0.81 (0.49–1.32)	0.392		
Albumin/Globulin				
<1.2	Ref.			
1.2–2.4	0.58 (0.36–0.95)	0.029		
>2.4	0.9 (0.12–6.56)	0.916		
Lactate dehydrogenase >250 U/L	1.12 (0.67–1.86)	0.660		
Alkaline phosphatase >125 U/L (Male) & >135 U/L (Female)	1.06 (0.51–2.21)	0.877		
Na+(mmol/L)				
<135	Ref.			
135–145	0.72 (0.4–1.3)	0.270		
>145	13.36 (3.36–53.21)	<0.001		
K+(mmol/L)				
<3.5	Ref.			
3.5–5.5	0.52 (0.25–1.1)	0.085		
>5.5	7.89 (0.92–67.77)	0.060		
Anion gap (mmol/L)				
<8	Ref.			
8–16	0.95 (0.51–1.78)	0.879		
>16	1.93 (0.62–6.07)	0.258		
Creatinine ≥97 μmmol/L	1.86 (1.14–3.04)	0.014		
Urea >8.0 mmol/L	2.02 (1.25–3.26)	0.004	1.74 (1.06–2.85)	0.028
FIB (g/L)				
<2	Ref.			
2–4	0.94 (0.27–3.19)	0.915		
>4	1.28 (0.38–4.29)	0.686		
APTT(s)				
<24	Ref.			
24–40	0.36 (0.14–0.92)	0.032		
>40	3 (0.56–16.03)	0.199		
TT(s)	3.29 (0.45–24.21)	0.242		
PT1(s)				
<9.4	Ref.			
9.4–13.8	1.05	0.946		
>13.8	0.9	0.896		
PTINR				
<0.76	Ref.			
0.76–1.16	1.87 (0.26–13.54)	0.537		

(*continued*)

TABLE 3 | Continued

Variables	Univariate COX analysis		Multivariate COX analysis	
	HR (95% CIs)	*p*	HR (95% CIs)	*p*
>1.16	0.79 (0.07–8.7)	0.844		
D-dimmer >500 μg/L	1.7 (0.73–3.95)	0.218		
CRP >10 mg/L	1.44 (0.81–2.54)	0.212		
ESR >20 mm/60 min	1.04 (0.61–1.78)	0.889		
Blood glucose (mmol/L)				
<3.9	Ref.			
3.9–6.9	0.56 (0.17–1.81)	0.334		
≥7.0	0.71 (0.2–2.48)	0.590		
Total bilirubin >23 μmmol/L	1.52 (0.84–2.73)	0.163		
Ca^{2+} <2.11 mmol/L	0.6 (0.37–0.95)	0.030	0.54 (0.33–0.87)	0.011
cl^-(mmol/L)				
<99	Ref.			
99–110	1.01 (0.54–1.89)	0.977		
>110	1.49 (0.56–3.98)	0.424		
Preoperative hemoglobin (g/L)	0.99 (0.98–1)	0.044		
Postoperative hemoglobin (g/L)	0.97 (0.96–0.99)	0.003	0.98 (0.96–1.00)	0.024

aCCI, age-adjusted Charlson Comorbidity Index; ASA classification, American Society of Anesthesiologists classification; Na^+, serum sodium; K^+, serum potassium; Ca^{2+}, serum calcium; cl-, serum chlorine; FIB, fibrinogen; APTT, activated partial thromboplastin time; TT, thrombin time; PT1, prothrombin time 1; PTINR, international normalized ratio of prothrombin time; CRP, C-reactive protein; ESR, erythrocyte sedimentation rate.

($p = 0.790$). Preoperative length of stay and serum K+ differed significantly between the training and validation set ($p < 0.05$), while the remaining variables between the two sets presented no difference.

Prognostic Factors for 1-Year All-Cause Mortality After Hip Arthroplasty in Nonagenarians With Hip Fractures

Table 3 that were based on the univariate and multivariate COX proportional hazards regression analysis presents the predictors for 1-year all-cause mortality in the training set of 102 cases (30 deaths). First, univariate Cox regression analysis was applied to reveal the potential prognostic predictors, and revealed that 11 of 44 predictors were significantly associated with 1-year all-cause mortality. Furthermore, the results of multivariate analysis showed that aCCI (HR = 1.3), ASA classification (III&IV, HR = 2.05), Urea (>8.0 mmol/L, HR = 1.74), serum Ca^{2+}(<2.11 mmol/L, HR = 0.54), postoperative hemoglobin (HR = 0.98) were significant predictors for 1-year all-cause mortality after hip arthroplasty in nonagenarians suffered hip fractures.

Development and Validation of the Prognostic Nomogram

Based on the Akaike information criteria (AIC), 5 independent prognostic predictors, including aCCI (HR = 1.3, 95% CI, 1.01–1.67, $p = 0.042$), ASA classification (HR = 2.05, 95% CI, 1.22–3.44, $p = 0.007$), Urea (HR = 1.74, 95% CI, 1.06–2.85, $p = 0.028$), serum Ca^{2+} (HR = 0.54, 95% CI, 0.33–0.87, $p = 0.011$), postoperative hemoglobin (HR = 0.98, 95% CI, 0.96–1.00, $p = 0.024$) were selected for the construction of the prognostic nomogram (**Figure 1**). The C-index for 1-year all-cause mortality after hip arthroplasty in nonagenarians with hip fractures was 0.71 (95% CIs, 0.68–0.78). The optimal agreement between nomogram-predicted probability and the result of observation in both the training and validation set was showed clearly by the calibration curve (**Figure 2**).

DISCUSSION

One-year mortality after hip fractures surgery in the elderly is more than 27% (10–13). In our study, the one-year mortality is as high as 29.6% in nonagenarians. These extremely old patients have high operative risk and difficult perioperative management and require more precise treatment. Risk prediction is one of the advantages of precision medicine, and the precision of prediction models need to develop from cohort customization to personalize management. Accompanied by the development of artificial intelligence, new risk prediction models are emerging constantly, we applied Cox regression models and predictive nomogram in the current study, aimed to develop a simple and intuitive model to interpret complex clinical indicators, to help clinicians screen out high-risk patients, and to help patients understand the high mortality associated with these factors easily. To our knowledge, this is the first study to use one new nomogram model to predict the risk factors for mortality after

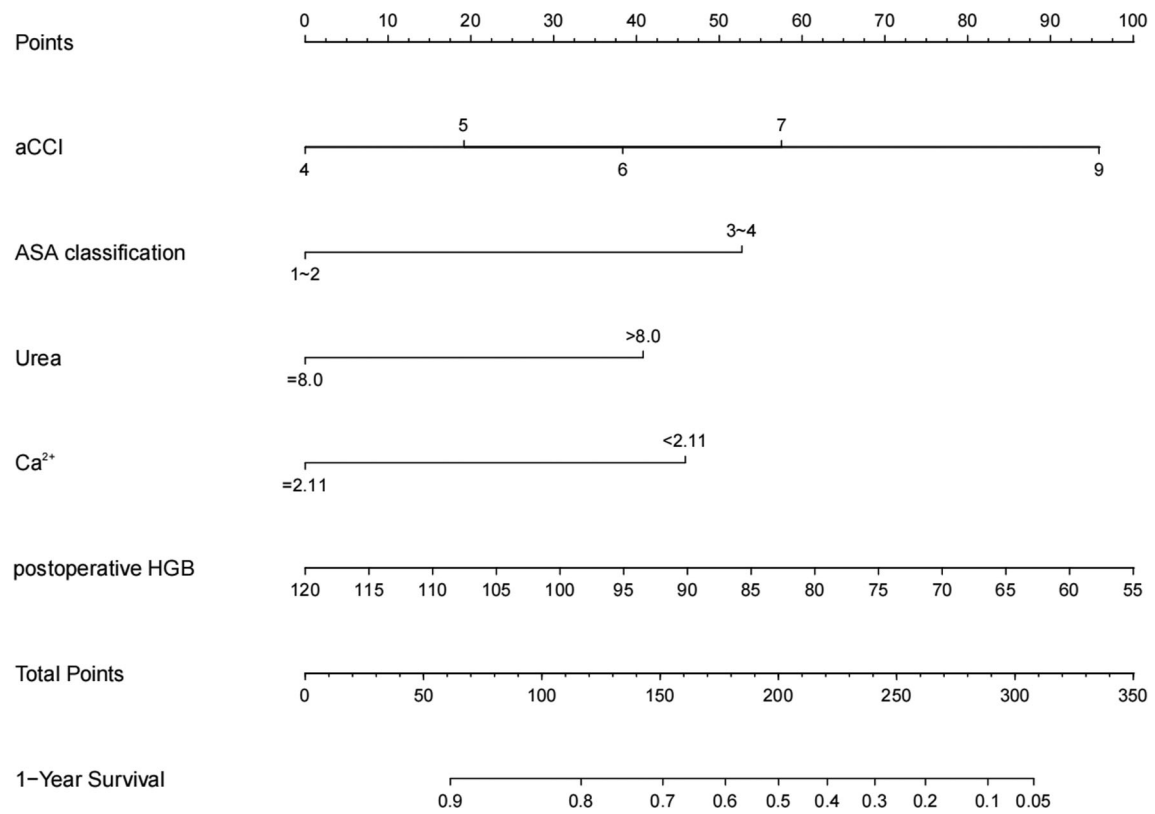

FIGURE 1 | A nomogram for prediction of 1-year mortality after arthroplasty in nonagenarians with hip fractures. aCCI, age-adjusted Charlson Comorbidity Index; ASA classification, American Society of Anesthesiologists classification; Ca^{2+}, serum calcium; HGB, hemoglobin.

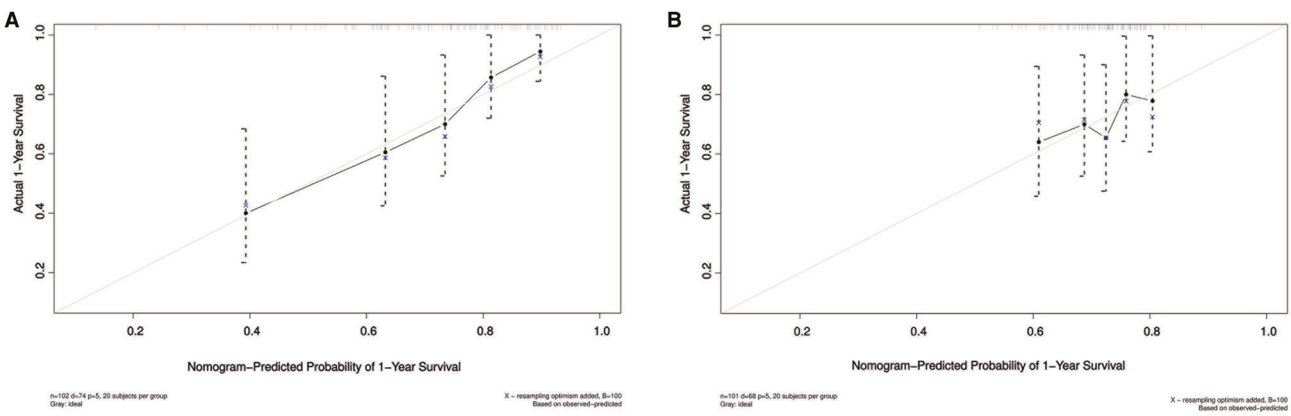

FIGURE 2 | Calibration curves. (**A**) Calibration curves showing the probability of 1-year mortality between the nomogram prediction and the actual observation in training set; (**B**) Calibration curves showing the probability of 1-year mortality between the nomogram prediction and the actual observation in the validation set. The prediction probability of the nomogram for 1-year mortality was plotted on the X-axis, and the actual probability was plotted on the Y-axis.

arthroplasty for nonagenarians with hip fractures. In the past, most relevant studies had focused on the incidence of adverse events during the postoperative hospital stay or one month after surgery, while we followed the cohort for up to two decades, and the focus of the study was not limited to short-term survival rate but extended to medium and long-term

survival rate. We limited the subjects to over 90 years old and arthroplasty for hip fractures, so as to reduce the influence of bias and confounding factors as much as possible. A stable predictive nomogram was constructed by COX regression, and aCCI, ASA classification, Urea, serum Ca2+, and postoperative hemoglobin were confirmed as the potential independent risk factors for 1-year all-cause mortality after hip arthroplasty in nonagenarians with hip fractures.

Comorbidities are common in the elderly with hip fractures. Patients with three or more comorbidities or a complex medical history have significantly increased mortality compared with those with no comorbidities (14, 15). Multiple comorbidities often co-exist and interact with each other. It is difficult to summarize the overall organ or body function by analyzing a single or specific type of disease. In order to comprehensively evaluate and quantify patients' comorbidities and physiological functions, aCCI and ASA classification were introduced in our study. aCCI is an assessment tool that combines age factors and quantifies a variety of comorbidities. aCCI and Charlson comorbidity index (CCI) are both predictors of post-operative complications with aCCI being the better predictive determinant (16). The ASA classification includes five levels to assess the patient's physical condition and perioperative risk. Both aCCI and ASA classification are common tools for operative risk stratification. Previous studies have attempted to use CCI and ASA for risk stratification and suggested that CCI performed better than ASA classification in the prediction for 1-year mortality after surgery for hip fractures (17, 18). However, some studies suggested that ASA classification was an independent risk factor for it, rather than CCI (19). In our study, both aCCI and ASA classification are potential risk factors, which consists of the report of Ek et al. (20). Additionally, we realized that serum urea, as one of the indicators of renal function, is an independent risk factor for postoperative mortality. This may indicate that renal disease as a serious comorbidity has a great impact on prognosis.

Hypocalcemia occurs in more than 30% of elderly orthopedic patients (21, 22). Clinical symptoms related to it are rare, but calcium ion is an important electrolyte, neurotransmitter and coagulation factor, so perioperative hypocalcemia is closely related to blood loss (21) and delirium (23). Even more, chronic hypocalcemia can severely affect cardiac contractility and electrical activity (24), which undoubtedly increases the risk of perioperative adverse events. Xu et al. (25) found that hypocalcemia could shorten the overall survival of the elderly, and our study regarded hypocalcemia as a potential risk factor for mortality within 1 year after surgery. Chewcharat et al. (26) found that the fluctuating serum sodium trajectory and hyponatremia was associated with the high in-hospital and 1-year mortality. Hypokalemi is common in hypertensive patients with hypotensor treatment and was considered to be associated with increased all-cause and cardiovascular mortality (27). While our study did not find the potential association between hypernatremia, hypokalemia and postoperative mortality, this may be due to the limitations of sample size or the complexity of the physiology of nonagenarians or differences in time periods. We should pay more attention to hypocalcemia and other blood indexes that may increase the mortality risk, and addressed them preoperatively for optimization of patient status for the operation.

Anemia is one of the most common complications after surgery for hip fracture in the elderly and is also an important factor leading to delirium, weakness, poor recovery of daily life, and even death (28, 29). Anemia on hospital admission is an independent predictor for long-term mortality in patients with hip fractures (30). During the perioperative period, hemoglobin is a direct indicator for the identification of anemia and the main basis for blood transfusion (31–34), meanwhile it is helpful for the classification of anemia and guiding perioperative fluid management in combination with hematocrit. Durán-Nah et al. (35) reported that intraoperative bleeding $\geq$400 mL and preoperative hemoglobin <11 g/dL were closely related to allogeneic blood transfusion. In our study, we included not only preoperative hemoglobin but also postoperative hemoglobin to facilitate dynamic assessment of its risk. Moreover, we found that postoperative hemoglobin is more meaningful than preoperative hemoglobin, which generally reflects the body's ability to recover from the shock of surgery. Our experience in treatment of anemia is restrictive blood transfusion: when hemoglobin is lower than 80 g/L, red blood cell is given; anemia should be corrected first before operation, and hemoglobin should be tested dynamically after operation to determine the timing of blood transfusion.

There were several limitations in this study. First, be subjected to the limitations of description bias of medical records and the great time span, some information that may affect prognosis was not analyzed in detail, such as pre- and postoperative cognitive function (cognitive deficit, dementia), preoperative activity of daily living, including habitual physical activity level, preoperative residence, preoperative physical function (e.g., handgrip strength, mobility, activity of daily living index), postacute rehabilitation of the patients. Second, it is a single-center, retrospective study with relatively small sample size, which was insufficient to generate a model containing all potential confounding factors and lacked external validation. Third, the development and validation sets were affected by selection bias. Besides, due to the low mortality and small number of deaths during the period from postoperative hospitalization to six months in our study, we did not analyze the risk factors for mortality at different time points during this period.

CONCLUSION

We established and validated a novel nomogram based on aCCI, ASA classification, Urea, serum Ca^{2+} and postoperative hemoglobin, that could effectively predict 1-year all-cause mortality after hip arthroplasty in nonagenarians with hip fracture. It would be helpful for clinicians to identify high-risk

patients, conduct reasonable and individualized perioperative managements.

DATA AVAILABILITY STATEMENT

The raw data supporting the conclusions of this article will be made available by the authors, without undue reservation.

ETHICS STATEMENT

Our study on human participants was reviewed and approved by the Ethics Committee of Daping Hospital of Army Medical University based in Chongqing, China (7 April 2022, ID 2022 [89]).

AUTHOR CONTRIBUTIONS

YX proposed the conception and design of the study. XL, ZW, YW, SW, QD, WG and KP collected and assembled the data. FC, XL and ZW analyzed and interpreted the data. XL, ZW drafted the manuscript. All authors contributed to the article and approved the submitted version.

FUNDING

This work was supported by the Medical Research Project jointly funded by the Chongqing Science and Technology Commission and the Chongqing Health Commission (2022ZDXM011).

REFERENCES

1. Fang EF, Xie C, Schenkel JA, Wu C, Long Q, Cui H, et al. A research agenda for ageing in China in the 21st century (2nd edition): focusing on basic and translational research, long-term care, policy and social networks. *Ageing Res Rev*. (2020) 64:101174. doi: 10.1016/j.arr.2020.101174
2. United Nations, Department of Economic and Social Affairs, Population Division. World population ageing 2017 (ST/ESA/SER.A/408). (2017). Available from: https://population.un.org/ProfilesOfAgeing2017/index.html (Accessed October 15, 2018).
3. Zhang C, Feng J, Wang S, Gao P, Xu L, Zhu J, et al. Incidence of and trends in hip fracture among adults in urban China: a nationwide retrospective cohort study. *PLoS Med*. (2020) 17(8):e1003180. doi: 10.1371/journal.pmed.1003180
4. Bhandari M, Swiontkowski M. Management of acute hip fracture. *N Engl J Med*. (2017) 377(21):2053–62. doi: 10.1056/NEJMcp1611090
5. Tu DP, Liu Z, Yu YK, Xu C, Shi XL. Internal fixation versus hemiarthroplasty in the treatment of unstable intertrochanteric fractures in the elderly: a systematic review and meta-analysis. *Orthop Surg*. (2020) 12(4):1053–64. doi: 10.1111/os.12736
6. Holt G, Macdonald D, Fraser M, Reece AT. Outcome after surgery for fracture of the hip in patients aged over 95 years. *J Bone Joint Surg Br*. (2006) 88(8):1060–4. doi: 10.1302/0301-620X.88B8.17398
7. Bokshan SL, Marcaccio SE, Blood TD, Hayda RA. Factors influencing survival following hip fracture among octogenarians and nonagenarians in the United States. *Injury*. (2018) 49(3):685–90. doi: 10.1016/j.injury.2018.02.004
8. Mayordomo-Cava J, Abásolo L, Montero-Fernandez N, Ortiz-Alonso J, Vidán-Astiz M, Serra-Rexach JA. Hip fracture in nonagenarians: characteristics and factors related to 30-day mortality in 1177 patients. *J Arthroplasty*. (2020) 35(5):1186–93. doi: 10.1016/j.arth.2019.12.044
9. Leal JA, Garcia LF, Peña OR, Gomez-Gelvez A. Patients aged ninety years and older are exposed to increased risk of one-year mortality after hip fractures. *Eur J Orthop Surg Traumatol*. (2021) 31(7):1501–6. doi: 10.1007/s00590-021-02918-0
10. NHFD. *Annual Report*. (2019). Available from: https://www.nhfd.co.uk/20/hipfractureR.nsf/docs/2019Report (Accessed 18, 2020).
11. Gundel O, Thygesen LC, Gögenur I, Ekeloef S. Postoperative mortality after a hip fracture over a 15-year period in Denmark: a national register study. *Acta Orthop*. (2020) 91(1):58–62. doi: 10.1080/17453674.2019.1680485
12. McLeod G, Kennedy I, Simpson E, Joss J, Goldmann K. Pilot project for a web-based dynamic nomogram to predict survival 1 year after hip fracture surgery: retrospective observational study. *Interact J Med Res*. (2022) 11(1):e34096. doi: 10.2196/34096
13. Forssten MP, Bass GA, Ismail AM, Mohseni S, Cao Y. Predicting 1-year mortality after hip fracture surgery: an evaluation of multiple machine learning approaches. *J Pers Med*. (2021) 11(8):727. doi: 10.3390/jpm11080727
14. Roche JJ, Wenn RT, Sahota O, Moran CG. Effect of comorbidities and postoperative complications on mortality after hip fracture in elderly people: prospective observational cohort study. *BMJ*. (2005) 331(7529):1374. doi: 10.1136/bmj.38643.663843.55
15. Crawford ZT, Southam B, Matar R, Avilucea FR, Bowers K, Altaye M, et al. A nomogram for predicting 30-day mortality in elderly patients undergoing hemiarthroplasty for femoral neck fractures. *Geriatr Orthop Surg Rehabil*. (2020) 11:2151459320960087. doi: 10.1177/2151459320960087
16. Marya SK, Amit P, Singh C. Impact of Charlson indices and comorbid conditions on complication risk in bilateral simultaneous total knee arthroplasty. *Knee*. (2016) 23(6):955–9. doi: 10.1016/j.knee.2016.05.013
17. Pan L, Ning T, Wu H, Liu H, Wang H, Li X, et al. Prognostic nomogram for risk of mortality after hip fracture surgery in geriatrics. *Injury*. (2022) 53(4):1484–9. doi: 10.1016/j.injury.2022.01.029
18. Varady NH, Gillinov SM, Yeung CM, Rudisill SS, Chen AF. The Charlson and elixhauser scores outperform the american society of anesthesiologists score in assessing 1-year mortality risk after hip fracture surgery. *Clin Orthop Relat Res*. (2021) 479(9):1970–9. doi: 10.1097/CORR.0000000000001772
19. Quach LH, Jayamaha S, Whitehouse SL, Crawford R, Pulle CR, Bell JJ. Comparison of the Charlson Comorbidity Index with the ASA score for predicting 12-month mortality in acute hip fracture. *Injury*. (2020) 51(4):1004–10. doi: 10.1016/j.injury.2020.02.074
20. Ek S, Meyer AC, Hedström M, Modig K. Comorbidity and the association with 1-year mortality in hip fracture patients: can the ASA score and the Charlson Comorbidity Index be used interchangeably? *Aging Clin Exp Res*. (2022) 34(1):129–36. doi: 10.1007/s40520-021-01896-x
21. Wang Z, Chen X, Chen Y, Yang L, Wang H, Jiang W, et al. Low serum calcium is associated with perioperative blood loss and transfusion rate in elderly patients with hip fracture: a retrospective study. *BMC Musculoskelet Disord*. (2021) 22(1):1025. doi: 10.1186/s12891-021-04914-1
22. Gai P, Sun H, Sui L, Wang G. Hypocalcaemia after total knee arthroplasty and its clinical significance. *Anticancer Res*. (2016) 36(3):1309–11.
23. Wang LH, Xu DJ, Wei XJ, Chang HT, Xu GH. Electrolyte disorders and aging: risk factors for delirium in patients undergoing orthopedic surgeries. *BMC Psychiatry*. (2016) 16(1):418. doi: 10.1186/s12888-016-1130-0
24. Yang YC, Shen FR, Lu YQ. Hypocalcemia: a reversible cause of T wave alternans and heart failure. *J Zhejiang Univ Sci B*. (2014) 15(6):598–600. doi: 10.1631/jzus.B1400078
25. Xu J, Chen X, Wang X, Zhu C, Hu Y, Yang X, et al. Preoperative hyponatremia and hypocalcemia predict poor prognosis in elderly gastric cancer patients. *Cancer Manag Res*. (2019) 11:8765–80. doi: 10.2147/CMAR.S211603
26. Chewcharat A, Thongprayoon C, Cheungpasitporn W, Mao MA, Thirunavukkarasu S, Kashani KB. Trajectories of serum sodium on in-hospital and 1-year survival among hospitalized patients. *Clin J Am Soc Nephrol*. (2020) 15(5):600–7. doi: 10.2215/CJN.12281019

27. Krogager ML, Søgaard P, Torp-Pedersen C, Bøggild H, Lee CJ, Bonde A, et al. Impact of plasma potassium normalization on short-term mortality in patients with hypertension and hypokalemia or low normal potassium. *BMC Cardiovasc Disord*. (2020) 20(1):386. doi: 10.1186/s12872-020-01654-3
28. Gregersen M. Postoperative red blood cell transfusion strategy in frail anemic elderly with hip fracture. A randomized controlled trial. *Dan Med J*. (2016) 63 (4):B5221.
29. Doody K, Mohamed KM, Butler A, Street J, Lenehan B. Adverse event recording post hip fracture surgery. *Ir Med J*. (2013) 106(10):300–2.
30. Zhang L, Yin P, Lv H, Long A, Gao Y, Zhang L, et al. Anemia on admission is an independent predictor of long-term mortality in hip fracture population: a prospective study with 2-year follow-up. *Medicine (Baltimore)*. (2016) 95(5): e2469. doi: 10.1097/MD.0000000000002469
31. Kim MS, Kim JD, Ro KH, Park JJ, Rhee YG. Hematologic profile in reverse total shoulder arthroplasty: perioperative and postoperative blood loss. *J Shoulder Elbow Surg*. (2019) 28(9):1737–42. doi: 10.1016/j.jse.2019.01.027
32. Fazal MA, Bagley C, Garg P. Predictors for perioperative blood transfusion in elderly patients with extra capsular hip fractures treated with cephalomedullary nailing. *Chin J Traumatol*. (2018) 21(1):16–9. doi: 10.1016/j.cjtee.2017.09.002
33. Luangwaranyoo A, Suksintharanon M, Tangadulrat P, Iamthanaporn K, Hongnaparak T, Yuenyongviwat V. Factors for blood transfusions following hemi hip arthroplasty for patients with femoral neck fracture. *Geriatr Orthop Surg Rehabil*. (2020) 11:2151459320972993. doi: 10.1177/2151459320972993
34. Wang JQ, Chen LY, Jiang BJ, Zhao YM. Development of a nomogram for predicting blood transfusion risk after hemiarthroplasty for femoral neck fractures in elderly patients. *Med Sci Monit*. (2020) 26:e920255. doi: 10.12659/MSM.920255
35. Durán-Nah JJ, Pastelín-Ruiz SE, Miam-Viana Ede J. Perioperative risk factors associated with allogeneic blood transfusion in patients with hip fracture surgery. *Rev Med Inst Mex Seguro Soc*. (2015) 53(4):406–13.

Conflict of Interest: The authors declare that the research was conducted in the absence of any commercial or financial relationships that could be construed as a potential conflict of interest.

Publisher's Note: All claims expressed in this article are solely those of the authors and do not necessarily represent those of their affiliated organizations, or those of the publisher, the editors and the reviewers. Any product that may be evaluated in this article, or claim that may be made by its manufacturer, is not guaranteed or endorsed by the publisher.

Copyright © 2022 Lu, Wang, Chong, Wang, Wu, Du, Gou, Peng and Xiong. This is an open-access article distributed under the terms of the Creative Commons Attribution License (CC BY). The use, distribution or reproduction in other forums is permitted, provided the original author(s) and the copyright owner(s) are credited and that the original publication in this journal is cited, in accordance with accepted academic practice. No use, distribution or reproduction is permitted which does not comply with these terms.

frontiers | Frontiers in Surgery

SYSTEMATIC REVIEW
published: 04 July 2022
doi: 10.3389/fsurg.2022.922637

The Application of Platelet-Rich Plasma for Patients Following Total Joint Replacement: A Meta-Analysis of Randomized Controlled Trials and Systematic Review

*Hongxin Shu, Zhenjun Huang, Xinyan Bai, Zhiyu Xia, Nanye Wang, Xiaoling Fu, Xigao Cheng and Bin Zhou**

Department of Orthopedics, The Second Affiliated Hospital of Nanchang University, Nanchang, China

OPEN ACCESS

Edited by:
Paphon Sa-ngasoongsong, Ramathibodi Hospital, Mahidol University, Thailand

Reviewed by:
Tulyapruek Tawonsawatruk, Mahidol University, Thailand
Konstantinos Markatos, Salamina Medical Center, Greece

***Correspondence:**
Bin Zhou
zhoubinndefy@163.com

Specialty section:
This article was submitted to Orthopedic Surgery, a section of the journal Frontiers in Surgery

Received: *18 April 2022*
Accepted: *13 June 2022*
Published: *04 July 2022*

Citation:
Shu H, Huang Z, Bai X, Xia Z, Wang N, Fu X, Cheng X and Zhou B (2022) The Application of Platelet-Rich Plasma for Patients Following Total Joint Replacement: A Meta-Analysis of Randomized Controlled Trials and Systematic Review. Front. Surg. 9:922637. doi: 10.3389/fsurg.2022.922637

Background: The clinical efficacy of platelet-rich plasma (PRP) in the treatment of total joint replacement (TJR) remains inconclusive. In this paper, systematic review and meta-analysis was adopted to assess the efficacy of using PRP for the treatment of TJR.

Methods: A comprehensive search of Medline, Embase, and Cochrane library databases for randomized controlled trial (RCT) articles recording data of PRP for TJR was conducted from inception to February 2022. Outcomes concerned were pain, range of motion (ROM), WOMAC score, length of hospital stay (LOS), hemoglobin (Hb) drop, total blood loss, wound healing rate, and wound infection. The methodological quality of the included RCTs was evaluated by using the Cochrane Risk of Bias Tool 2.0 (RoB 2.0). The Grading of Recommendations Assessment, Development, and Evaluation (GRADE) was utilized to assess the level of evidence for the outcomes. Subgroup analysis was conducted according to the type of TJR.

Results: Ten RCTs were included in the meta-analysis. In the TKA subgroup, the available data demonstrated that there were significant differences in the outcomes of pain and Hb drop, while it was the opposite of ROM, WOMAC score, LOS, total blood loss, wound healing rate, and wound infection. In the THA subgroup, no significant differences could be seen between two groups in the outcomes of LOS and wound infection. However, the PRP group gained a higher wound healing rate in the THA subgroup.

Conclusion: The application of PRP did not reduce blood loss but improved the wound healing rate. However, more prospective and multicenter studies are warranted to confirm these results.

Keywords: meta-analysis, randomized controlled trial, total joint replacement, total knee arthroplasty, total hip arthroplasty, platelet-rich plasma

BACKGROUND

Total joint replacement (TJR) is a common surgical procedure in which the weight-bearing surface of a joint is replaced to restore its capacity and function (1–5). During the operation, TJR can cause many complications, including blood loss, deep vein thrombosis, and wound complications (5). These disorders have a poor prognosis and can cause severe pain, which increases the length of hospital stay (LOS), medical costs, and even the risk of deep vein thrombosis (DVT) (6). Nowadays, multiple approaches have been used to manage complications arising after TJR, including fibrin tissue adhesive, epidural infusion, and oral opioids (3, 7, 8). However, the treatment outcome is not satisfactory and is accompanied by side effects (9).

Platelet-rich plasma (PRP) has been increasingly used in the field of sports injuries and has attracted extensive attention due to its high safety, simple preparation, and ease of extraction (10). PRP is a highly concentrated platelet solution extracted from autologous whole blood by centrifugation. PRP can release high concentrations of autogenous growth factors, including transforming growth factor β1 (TGF-β1), platelet-derived growth factor, insulin-like growth factor (IGF), and epidermal growth factor (EGF), which can promote chondrocyte proliferation and vascular growth to accelerate wound site repair (11). A large amount of fibrin also contributes to wound repair, which facilitates wound contraction and provides scaffolding (12, 13). Previous meta-analysis demonstrated that PRP does accelerate wound healing for diabetic foot ulcers and venous ulcers (14). However, the clinical evidence for TJR was lacking.

In recent years, an increasing number of studies on the use of PRP in TJR have been conducted, but many clinical studies have not drawn definitive conclusions on the efficacy and safety of PRP. A previous meta-analysis (15) concluded that there was no significant difference in pain at 24 h and 48 h, which is contradictory to a recent study (16). Ma J et al (17) performed a meta-analysis including six randomized controlled trials (RCTs), demonstrating that PRP reduced blood loss after total knee arthroplasty (TKA). However, data from subsequent studies on this topic revealed that there was no statistical difference between the PRP group and the control group (18–20). RCTs published in recent years may alter previous conclusions on the effect of PRP. Hence, this systematic review and meta-analysis related to the use of topical PRP for TJR was performed to explore the potential clinical values of PRP.

MATERIAL AND METHODS

This systematic review was conducted by following Preferred Reporting Items for Systematic Reviews and Meta-Analyses (PRISMA) (21). Because it was a review of the existing literature, and there was no registered protocol, ethical approval was not necessary.

Search Strategy

Relevant randomized controlled trials (RCTs) were identified from databases Medline, the Cochrane library, and Embase. The search strategy for Medline was as follows: (("Platelet-rich plasma" or "PRP") and ("Arthroplasty, Replacement, Hip" or "THA" or "THA" or "Total Joint Arthroplasty" or "Arthroplasty, Replacement, Knee" or "TKA")). The last search date was February 2, 2022. We manually searched for eligible references by reading the title and abstract. In addition, we manually screened previous reviews and reference lists of relevant studies to broaden the search.

Study Selection

After downloading all citations, RCTs were reviewed by two independent investigators (HS, ZH), and any disagreements were resolved by a third investigator (BZ). All RCTs meeting the following inclusion criteria were considered: patients (age>18 years) who underwent primary TJR; and PRP intervention in the experiment group. There were no restrictions on the year of publication, and language was limited to English. The following types were excluded: letter, case report, case series, review, non-RCT, and Quasi-RCT.

Data Extraction

The following items were extracted from eligible studies by two independent investigators (HS, ZH): name of first author, year of publication, country of origin, the number of patients in each group, the number of males in each group, mean (± standard deviation) age of patients per group, type of operation, type of prosthesis, type of PRP, preparation of PRP, and the dose of PRP. A standardized Microsoft Excel file was used to record the data and a third investigator (BZ) verified the collected data.

Critical Appraisal

Based on Cochrane Collaboration's tool, risk of bias 2.0 (RoB 2.0) (22) was assessed by two independent investigators (HS, ZH), and any disputes were resolved by another investigator (BZ). The overall level of evidence for each endpoint was evaluated by Grading of Recommendations dations Assessment, Development, and Evaluation (GRADE) (23).

Outcomes and Statistical Analysis

The outcomes of interest were pain, range of motion (ROM), Western Ontario and McMaster Osteoarthritis Index (WOMAC) score, length of hospital stay (LOS), hemoglobin (Hb) drop, total blood loss, wound healing rate, and wound infection. Visual analogue scale (VAS) was used to measure pain, which consisted of a scale of 1 to 10. All calculations were performed using STATA 17.0 software (StataCorp, College Station, TX). For continuous outcomes, mean difference (MD) was calculated, and the risk ratio (RR) was calculated for dichotomous outcomes. Heterogeneity was calculated using the I2 statistical and Chi-square test, indicating high heterogeneity when I2 was greater than 50%. In this case, a random-effects model was used; otherwise, we conducted the fixed-effects model. The p-value of less than 0.05 was defined as a significant difference. Summary effect measures were presented along with their corresponding 95% confidence intervals (CIs). Sensitivity analyses were conducted by omitting one study at a time, and subgroup analyses were

performed to explore the source of bias according to the type of TJR. Egger's test and Begg's test were performed to assess publication bias (24, 25).

RESULTS

Study Selection

The literature search resulted in 456 hits, of which 101 were duplicates and were excluded. After screening based on titles and abstracts, the full text of 21 relevant studies was eligible. Three case reports, four non-English, three reviews, and one letter were excluded. Subsequently, a total of 10 origin RCTs (16, 18, 26–33) were included in the current systematic review (**Figure 1**).

Study Characteristics

The studies are summarized in **Table 1**. A total of 772 patients who underwent TKA or total hip arthroplasty (THA) were included, of which 332 were in the PRP group. Eight studies reported the effect of PRP on TKA, one study reported that on THA, and one study reported that on TKA and THA. The studies were published between 2009 and 2021. The risk of bias is presented in **Figure 2**. One study (31) was defined as high bias and two studies (18, 27) were defined as low bias.

Pooled Results

Pain

A total of 3 studies (16, 18, 30) accessed pain following total knee arthroplasty by using VAS, which included 161 cases. As shown in **Figure 3**, the PRP group had a similar VAS score to the control group at postoperative day (POD) 1 (MD = −0.47, 95%CI: −1.31 to 0.38), POD 2 (MD = −0.63, 95%CI: −1.38 to 0.13), but 3-week (MD = −0.92, 95%CI: −1.25 to −0.60) and 2-month (MD = −0.93, 95%CI: −1.24 to −0.63) scores were significantly lower than those of the control group.

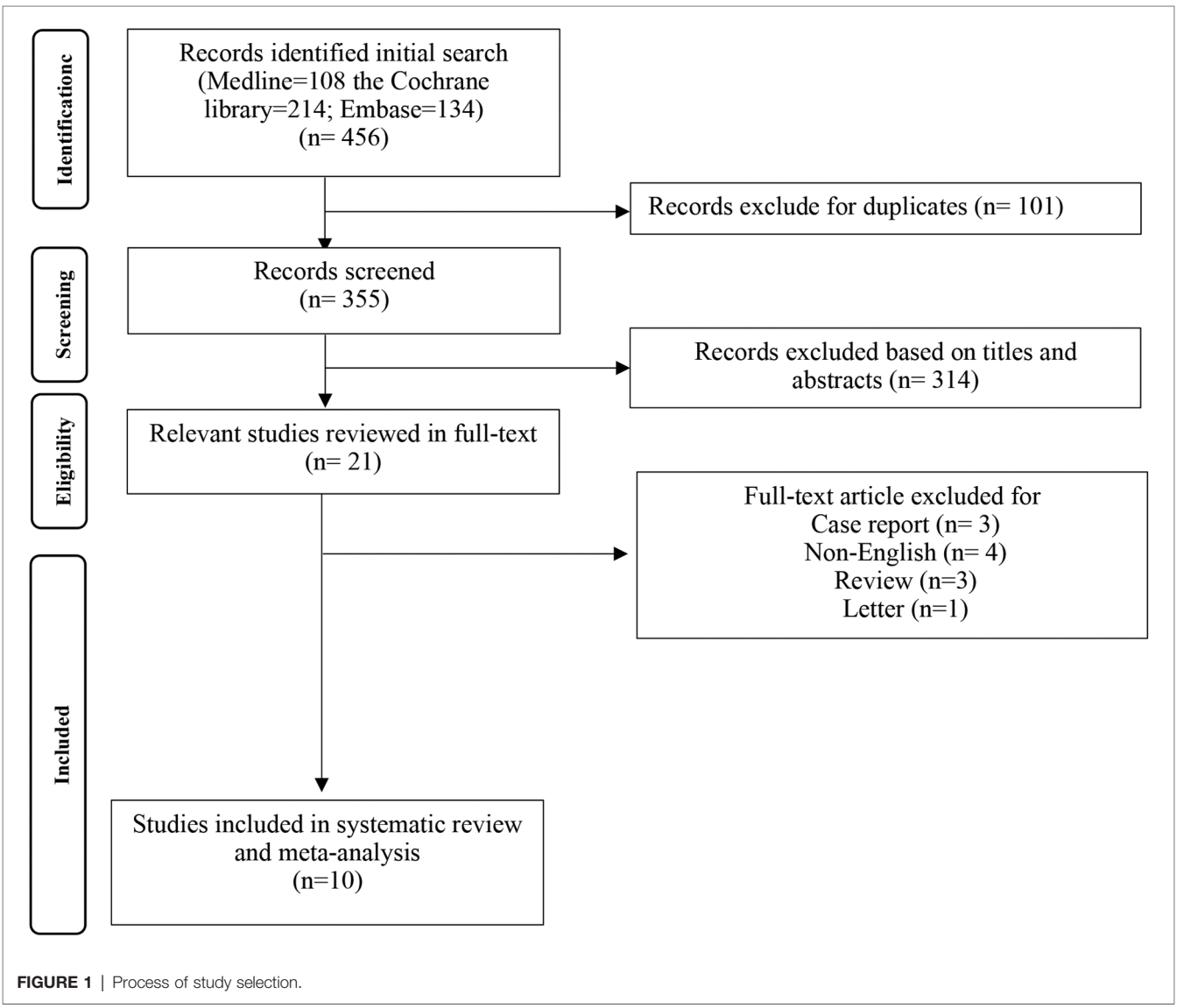

FIGURE 1 | Process of study selection.

TABLE 1 | Summary of included randomized controlled trials.

The first author	Country	Study design	No. patients (PRP/Control)	No. males (PRP/Control)	Age, mean (SD)		Follow-up, months	TKA/ THA	Unilateral/ bilateral	Type of prosthesis	Type of PRP; Product or Manual Protocol (No. of Spins)*	PRP dosage, mL
					PPR	Control						
Peerbooms JC (2009)	Netherlands	RCT	50/52	6/8	76 (4.1)	78 (5.2)	3	TKA	Yes/no	Cemented	LR-PRP; Biomet Biologics GPS	6
Horstmann WG (2011)	Netherlands	RCT	20/20	14/13	67 (6)	66 (6.75)	1.5	TKA	Yes/no	Cemented	LR-PRP; Biomet Biologics GPS	11
Aggarwal AK (2014)	India	RCT	7/14	NR	56.43 (7.59)	53.79 (9.75)	6	TKA	Yes/yes	Cemented	LP-PRP; Immuguard III-PL	8
Morishita M (2014)	Japan	RCT	20/20	2/0	72 (4.1)	74.7 (5.7)	1	TKA	Yes/no	Cemented	LR-PRP; Accelerate Concentrating System	5
Guerreiro JPF (2015)	Brazil	RCT	20/20	6/8	66.4 (9)	71.6 (6.5)	2	TKA	Yes/no	NR	LP-PRP; manual (2 spins)	10
Mochizuki T (2016)	Japan	RCT	109/206	92/106	73 (7.8)	73.4 (8.2)	0.5	TKA	Yes/no	Cemented	NR; manual (1 spin)	5
Evans DC (2018)	United States	RCT	30/30	10/13	NR	NR	1.5	TKA and THA	NR	Cemented	LR-PRP; SmartPrep 2 System	10
Guerreiro JPF (2019)	Brazil	RCT	20/21	7/6	69.14 (6.5)	66.4 (7.25)	24	TKA	NR	NR	LP-PRP; manual (2 spins)	10
Tandogan RN (2020)	Turkey	RCT	40/40	5/4	68 (7)	70 (7)	3 weeks	TKA	Yes/no	Cemented	LR-PRP; Vivostat Processor Unit	4-6
Capion SC (2021)	Denmark	RCT	17/17	3/8	65.6 (8.5)	68.9 (7.1)	4 weeks	THA	NR	NR	LR-PRP; manual (3 spins)	20

*NR, not reported; TKA, total knee arthroplasty; THA, total hip arthroplasty; RCT, randomized controlled trials; PRP, platelet-rich plasma; LP, leukocyte-poor; LR, leukocyte-rich; *, without the use of commercially available kits.*

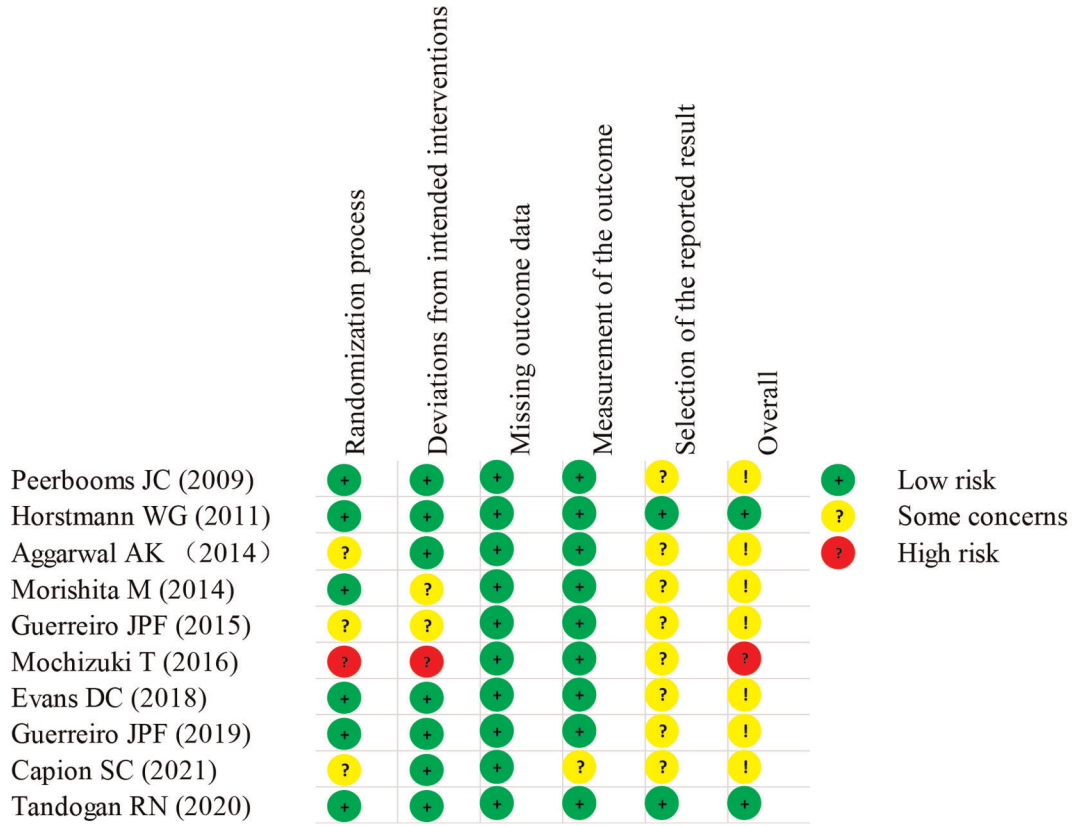

FIGURE 2 | Risk of bias assessment of the included studies.

Range of Motion

Five studies (18, 26, 28, 30, 31) reported ROM following total knee arthroplasty in a total of 529 cases. Between the PRP group and the control group, the ROM was similar at POD 2 (MD = 1.90, 95%CI: −1.08 to 4.87), POD 5 (MD = 3.16, 95% CI: −0.73 to 7.06), 1-week (MD = −1.06, 95%CI: −4.62 to 1.42), 2-week (MD = −0.88, 95%CI: −3.70 to 1.94), and 6-week (MD = 3.88, 95%CI: −5.23 to 12.98) (**Figure 4**)

WOMAC Score

The data on WOMAC score at 6-week, 2-month, 3-month, and 6-months following total knee arthroplasty were recorded in four RCTs (16, 26, 28, 30). The WOMAC score did not significantly differ between the two groups at 6-week (MD = −2.37, 95%CI: −9.78 to 5.04), 2-month (MD = 2.90, 95%CI: −3.97 to 9.76), 3-month (MD = −0.71, 95%CI: −8.51 to 7.08), and 6-month (MD = −0.69, 95%CI: −1.65 to 0.28) (**Figure 5**).

Length of Hospital Stay

Three RCTs (18, 27, 28) reported the length of hospital stay following total knee arthroplasty, and one RCT (33) provided data on total hip arthroplasty. Compared with the control group, no significant difference was found in the THA subgroup (MD = 0.00, 95%CI: −0.86 to 0.86) and TKA subgroup (MD = −1.27, 95%CI: −2.90 to 0.35) (**Figure 6A**).

Hemoglobin Drop at POD 1

Hemoglobin drop following total knee arthroplasty at POD 1 was reported in three RCTs (16, 26, 31) in 458 cases. Compared with the control group, hemoglobin drop was lower in the PRP group (MD = −0.21, 95%CI: −0.40 to −0.02) (**Figure 6B**).

Total Blood Loss

Data from three RCTs (18, 29, 31) demonstrated that total blood loss in the PRP group was similar to that of the control group following total knee arthroplasty (MD = −56.50, 95%CI: −131.13 to 18.12) (**Figure 6C**).

Wound Healing Rate in 4 Weeks

One study (29) provided total knee arthroplasty data and one (33) provided total hip arthroplasty data on wound healing rates within 4 weeks. There was no significant difference in the TKA subgroup (MD = 1.12, 95%CI: 0.91 to 1.38), while there was a significant difference in the THA subgroup (MD = 2.13, 95%CI: 1.05 to 4.29) (**Figure 7A**).

Wound Infection

Four original studies reported the data of TKA, one study (33) reported the data of THA, and one study (32) reported the

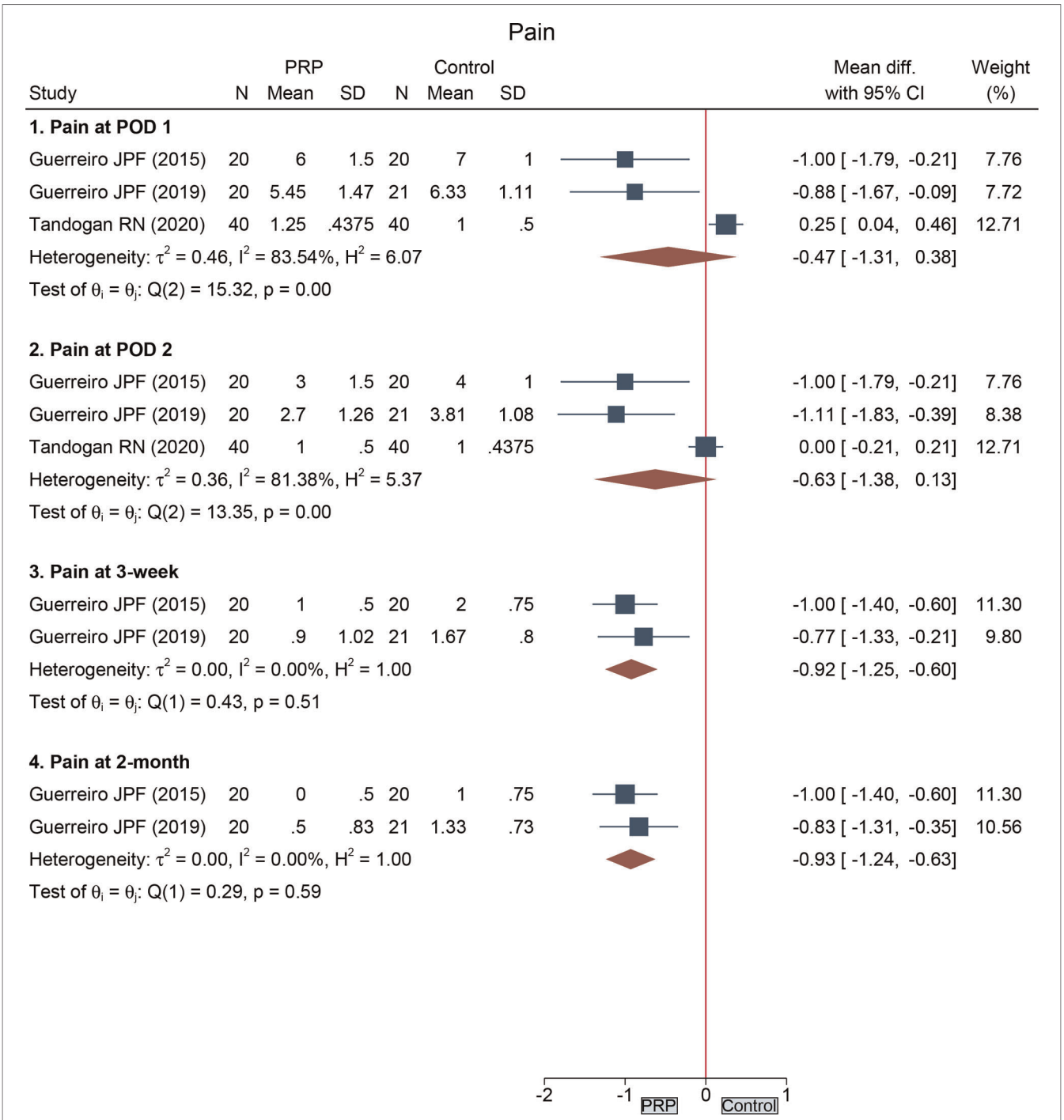

FIGURE 3 | Forest plot presents the pooled results for pain in the total knee arthroplasty subgroup.

data of TKA and THA. However, there was no significant difference in all subgroups (**Figure 7B**).

GRADE Assessment

Table 2 shows the quality of evidence for each outcome. The certainty of pain at 2 months, ROM at POD 5, and WOMAC score at 6 months was high. The level of evidence for ROM at 2 weeks, ROM at 6 weeks, WOMAC score at 6 weeks, and hemoglobin drop was low. The rest of the outcomes were regarded as moderate-level evidence.

Publication Bias and Sensitivity Analysis

Due to the limitations in the number of origin studies, Egger's test and Begg's test could not be conducted to assess

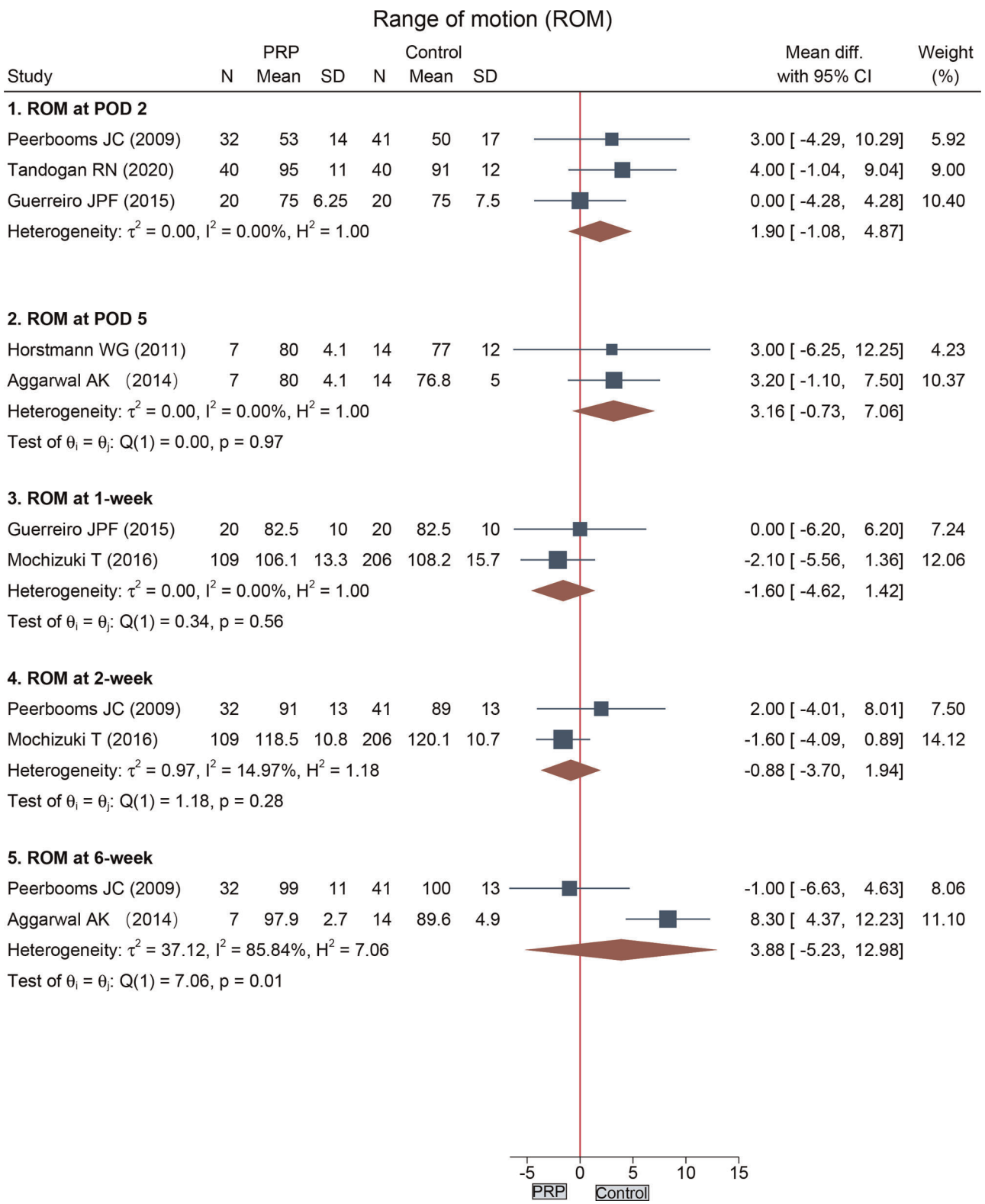

FIGURE 4 | Forest plot presents the pooled results for the range of motion in the total knee arthroplasty subgroup.

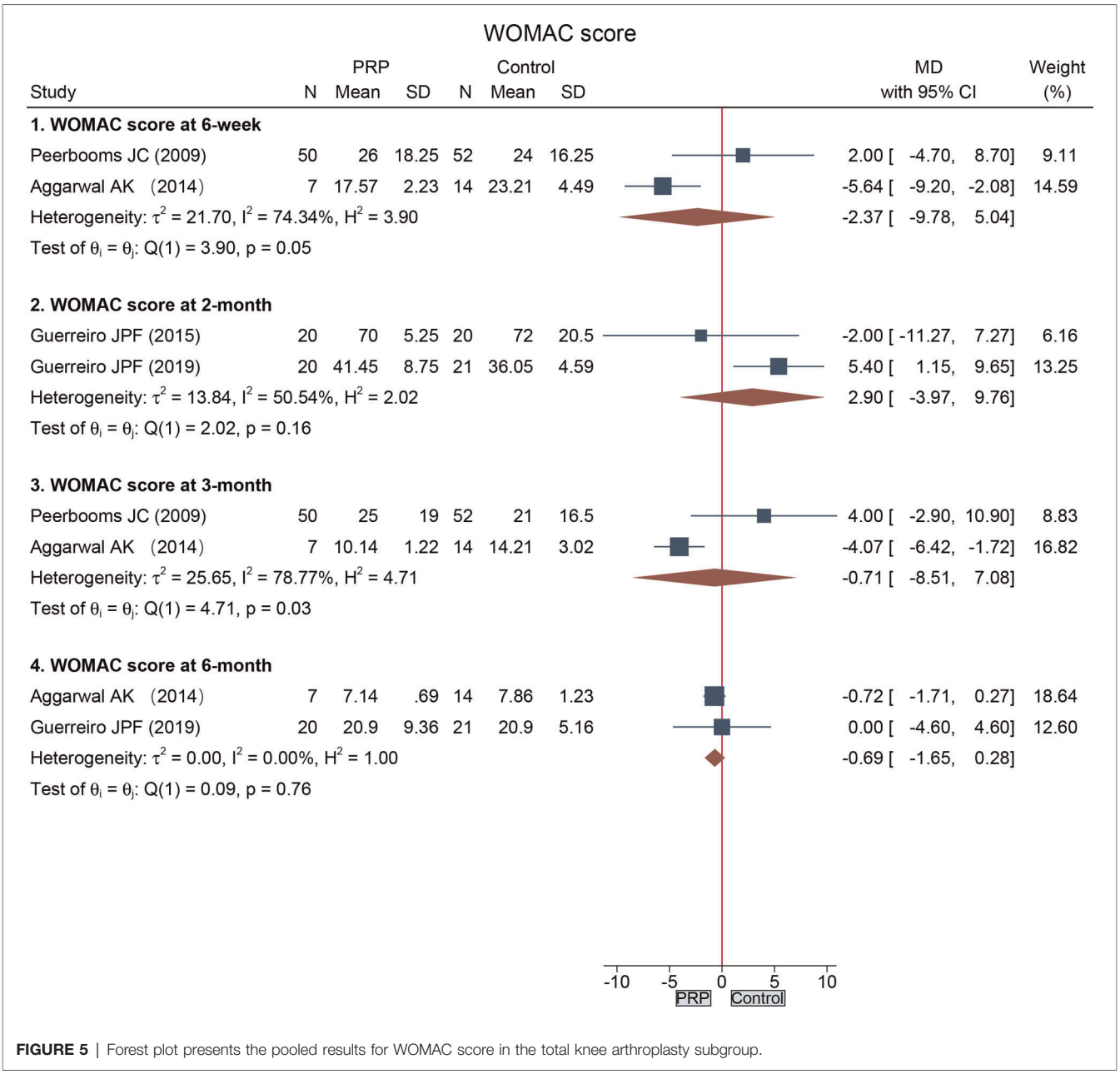

FIGURE 5 | Forest plot presents the pooled results for WOMAC score in the total knee arthroplasty subgroup.

publication bias. After sensitivity analysis, the results of the current study did not change and were considered stable.

DISCUSSION

The current systematic review provided the latest evidence involving 772 cases on PRP for TJR. In the TKA subgroup, the available data demonstrated that there was a significant difference in the outcomes of pain and Hb drop, while there was no significant difference in the outcomes for ROM, WOMAC score, LOS, total blood loss, wound healing rate, and wound infection. Moreover, the pooled results found that the PRP group and the control group had similar outcomes of LOS and wound infection in the THA subgroup. Interestingly, data from the included studies revealed that the application of PRP had a positive effect on wound healing rates.

Previous systematic review and meta-analysis including both RCTs and non-RCTs held different points with the current study (15). In this study, Li FX et al included 11 origin studies (7 RCTs, and 4 non-RCTs) to investigate the effect of PRP for TKA, and the pooled results demonstrated that ROM at 3 days and 3 months were significantly higher than in the control group, whereas statistical difference was found in our study. It is noteworthy that non-RCTs included by Li FX et al contributed to bias, which may explain a different point of view from the current study. In another meta-analysis conducted by Ma J et al, which contained 6 RCTs and

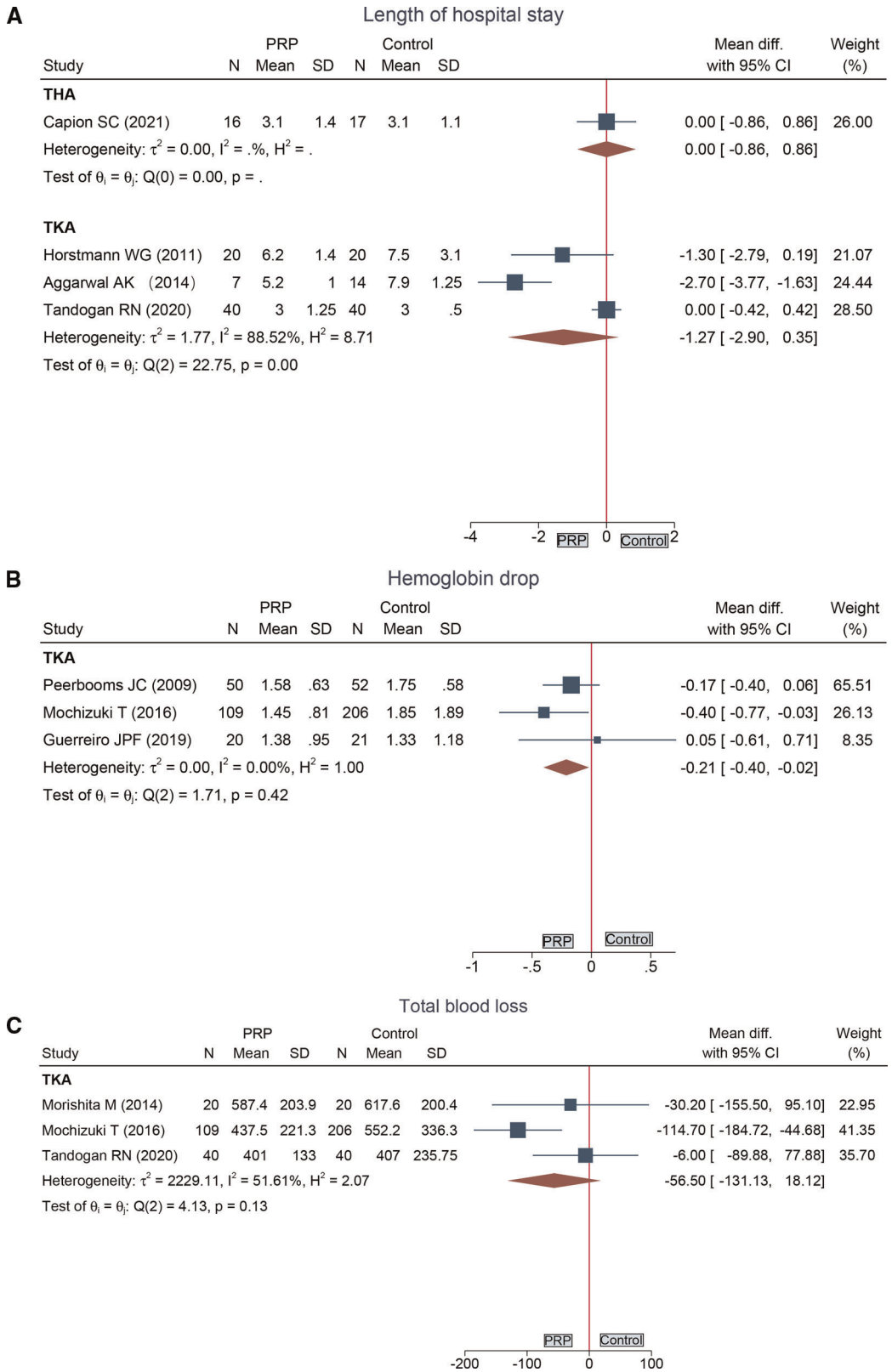

FIGURE 6 | Forest plot presents the pooled results for: (**A**) length of hospital stay; (**B**) hemoglobin drop; (**C**) total blood loss.

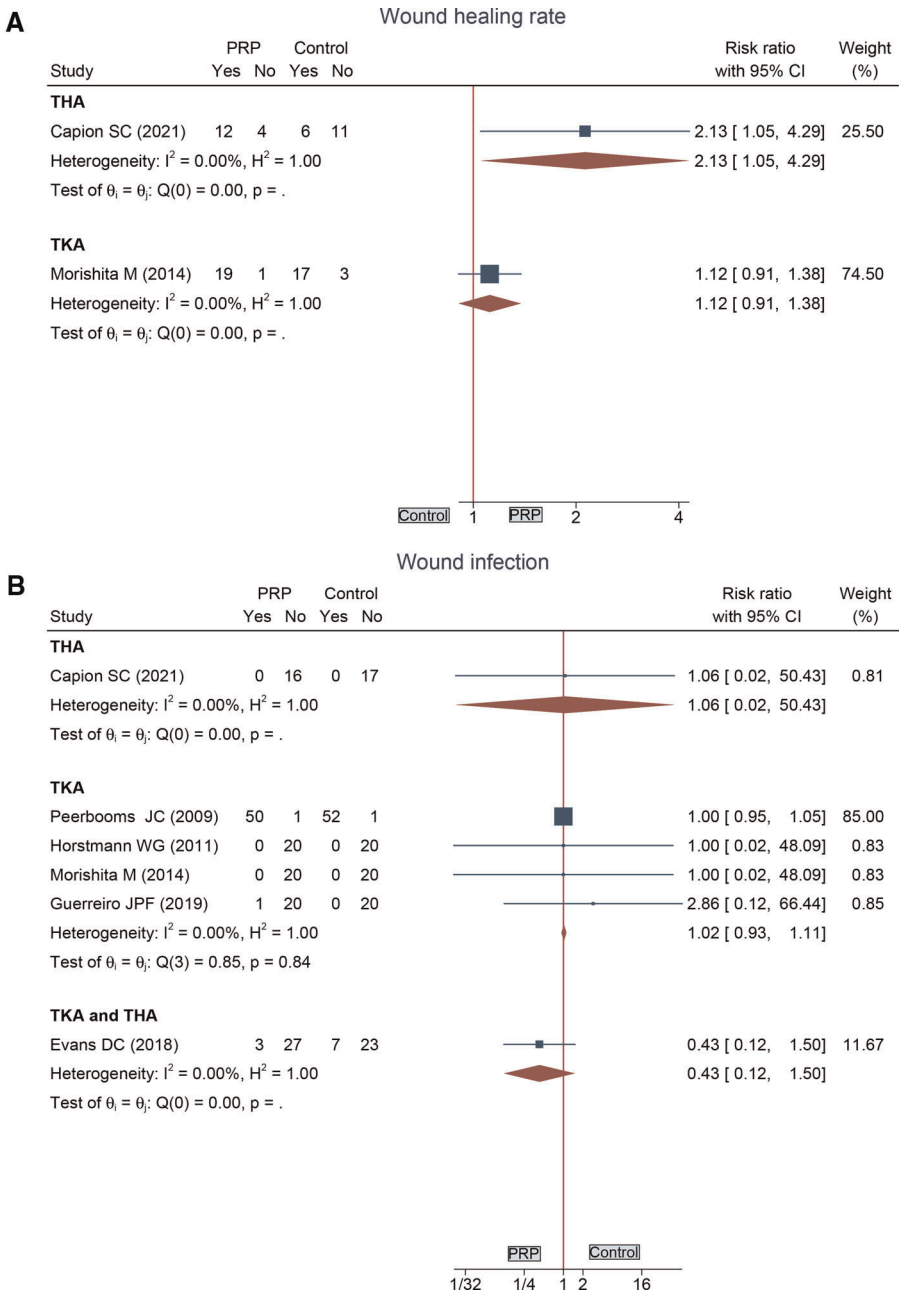

FIGURE 7 | Forest plot presents the pooled results for: (**A**) wound healing rate; (**B**) wound infection.

enrolled 529 patients, it was demonstrated that the application of PRP did decrease the length of hospital stay after TKA (17). However, recently, Capion SC et al (33) found no significant difference in terms of length of hospital stay following TKA between two groups ($P = .223$). Combining the data from Capion SC et al, we found that there was no significant difference in terms of length of hospital stay in the TKA subgroup. For the outcome of hemoglobin drop, a significant difference was found in the study of Ma J et al (17), while Guerreiro JPF et al (16) found no distinction. After pooling the data of Guerreiro JPF et al, the synthesized result of the current meta-analysis remained significant.

Many technologies and drugs have emerged to reduce blood loss during and after total joint replacement (34). It was reported that platelet-rich plasma contributes to reducing blood loss for TJR (17, 28, 31, 35). However, Tingstad EM et al (19) analyzed the data from 93 patients who underwent TKA and discovered that PRP injections did not reduce blood loss ($P = .686$). In a systematic review, Muchedzi TA et al (20) included ten studies to assess average blood loss for patients

TABLE 2 | GRADE assessment for outcomes reported in randomized controlled trials (RCTs) on PRP vs control for total knee arthroplasty.

Outcomes	No. of studies	Study design	Risk of bias	Inconsistency	Indirectness	Imprecision	Other considerations	No. of patients		Relative effect (95% CI)	Certainty[a]
								PRP	Control		
Pain at POD 1	3	RCT	No	Serious[c]	No	No	No	80	81	MD −0.47 (−1.31, 0.38)	⊕⊕⊕◯ Moderate
Pain at POD 2	3	RCT	No	Serious[c]	No	No	No	80	81	MD −0.63 (−1.38, 0.13)	⊕⊕⊕◯ Moderate
Pain at 3 weeks	2	RCT	No	No	No	No	No	40	41	MD −0.92 (−1.25, −0.60)	⊕⊕⊕⊕ High
Pain at 2 months	2	RCT	No	No	No	No	No	40	41	MD −0.93 (−1.24, −0.63)	⊕⊕⊕⊕ High
ROM at POD 2	3	RCT	No	No	No	No	Serious[d]	110	112	MD 1.90 (−1.09, 4.87)	⊕⊕⊕◯ Moderate
ROM at POD 5	2	RCT	No	No	No	No	No	27	34	MD 3.16 (−0.73, 7.06)	⊕⊕⊕⊕ High
ROM at 1 week	2	RCT	Serious[b]	No	No	No	No	129	226	MD −1.60 (−4.62, 1.42)	⊕⊕⊕◯ Moderate
ROM at 2 weeks	2	RCT	Serious[b]	No	No	No	Serious[d]	159	258	MD −0.88 (−0.37, 1.94)	⊕⊕◯◯ Low
ROM at 6 weeks	2	RCT	No	Serious[c]	No	No	Serious[d]	70	72	MD 3.88 (−5.23, 12.98)	⊕⊕◯◯ Low
WOMAC score at 6 weeks	2	RCT	No	Serious[c]	No	No	Serious[d]	57	66	MD −2.37 (−9.78, 5.04)	⊕⊕◯◯ Low
WOMAC score at 2 months	2	RCT	No	Serious[c]	No	No	No	40	41	MD 2.90 (−3.97, 9.76)	⊕⊕⊕◯ Moderate
WOMAC score at 3 months	2	RCT	No	Serious[c]	No	No	No	57	66	MD −0.71 (−8.51, 7.08)	⊕⊕⊕◯ Moderate
WOMAC score at 6 months	2	RCT	No	No	No	No	No	27	35	MD −0.69 (−1.65, 0.28)	⊕⊕⊕⊕ High
Length at hospital stay	3	RCT	No	Serious[c]	No	No	No	67	74	MD −1.27 (−2.90, 0.35)	⊕⊕⊕◯ Moderate
Hemoglobin drop	3	RCT	Serious[b]	No	No	No	Serious[d]	179	279	MD −0.21 (−0.40, −0.02)	⊕⊕◯◯ Low
Total blood loss	3	RCT	Serious[b]	No	No	No	No	169	266	MD −56.50 (−131.13, 18.12)	⊕⊕⊕◯ Moderate
Wound infection	4	RCT	No	No	No	No	Serious[d]	110	113	RR 1.02 (0.93, 1.11)	⊕⊕⊕◯ Moderate

[a]*GRADE Working Group grades of evidence: High quality = we are very confident that the true effect lies close to that of the estimate of the effect.; Moderate quality = we are moderately confident in the effect estimate: the true effect is likely to be close to the estimate of the effect, but there is a possibility that it is substantially different; Low quality = our confidence in the effect estimate is limited: the true effect may be substantially different from the estimate of the effect; Very low quality = we have very little confidence in the effect estimate: the true effect is likely to be substantially different from the estimate of effect.*

[b]*Downgraded one level for concerns with performance bias.*

[c]*Downgraded one level for $I^2 > 50\%$.*

[d]*Downgraded one level for publication bias.*

during TKA, and they also did not find statistical differences between the PRP group and the control group ($P = .07$). Tranexamic acid (TA) administration during TKA had been demonstrated to reduce blood loss (36). Tandogan RN et al (18) evaluated the effect of platelet-rich fibrin (PRF) on blood loss by comparing the combined utilization of PRF and TA with TA alone, and the data showed no significant difference between two groups ($P = .722$). In this meta-analysis, we synthesized the latest evidence and revealed that PRP did not reduce total blood loss in patients following TKA.

Platelet-rich plasma has a strong effect on wound repair (37, 38). A meta-analysis of 15 RCTs by Xia Y et al (14) concluded that additional application of PRP enhanced chronic wound closure. Analogously, the current study provided evidence that PRP accelerates wound healing in total hip arthroplasty. However, there was no significant difference in the total knee arthroplasty subgroup. The reason for the different results may be the differences in cavity between the knee and the hip. A systematic review conducted by Muchedzi TA et al's also found no benefit of PRP application on wound score after TKA ($P = .33$) (20). To the best of our knowledge, this is the first meta-analysis to demonstrate a positive effect of PRP on improving wound rates for patients following THA. Additionally, increased skin healing may be associated with a reduced economic burden. A cost-effectiveness analysis (CEA) conducted by Russo S et al (39) implied that additional PRP was a cost-effective or even a cost-saving alternative treatment for diabetic foot ulcers (incremental cost-effectiveness ratio [ICER] −€613/ QALY). For knee osteoarthritis, however, Rajan PV et al (40) conducted a Markov decision analysis and demonstrated that PRP injections were not cost-effective due to the lack of clinical evidence for pain relief, improved function, and delayed TKA. Here, our study provided the latest data on pain relief for TKA, although the pooled results of postoperative function were not statistically different. Furthermore, the events of wound infection were pooled in the current study, but no difference was found, demonstrating that intraoperative PRP was safe.

Several limitations should be noted. First, only 10 RCTs were extracted in the current meta-analysis. More high-quality RCTs, in the future, are needed to investigate these results. Second, the high heterogeneity should not be ignored. Third, publication bias is a concern, because non-English studies were excluded. Fourth, there is a lack of available data on THA, and only one eligible study was included in this meta-analysis. Therefore, future work should focus on the effect of PRP on THA.

CONCLUSION

The application of platelet-rich plasma to patients following total keen arthroplasty is associated with pain relief and decreased Hb drop. In addition, available data reveal that platelet-rich plasma accelerates wound healing rates in patients undergoing total hip arthroplasty. Intra-operative PRP is active; however, more prospective and multicenter studies are warranted to confirm these results.

DATA AVAILABILITY STATEMENT

The datasets presented in this study can be found in online repositories. The names of the repository/repositories and accession number(s) can be found in the article/ Supplementary Material.

AUTHOR CONTRIBUTIONS

HS and ZH designed the study; XB, ZX, and NW performed the data collection; HS, XF, and XC did the data analysis; HS and BZ wrote the article. All authors contributed to the article and approved the submitted version.

FUNDING

This work was supported by the Science and Technology Plan of Jiangxi Provincial Health and Family Planning Commission (No. 20195226).

DISCLOSURE

There is no known competing financial interests or personal relationships that could have appeared to influence the work reported in this paper.

REFERENCES

1. Sax OC, Chen Z, Bains SS, Salib CG, Pervaiz SS, Mont MA, et al. Timing and type of bariatric surgery preceding total knee arthroplasty leads to similar complications and outcomes. *J Arthroplasty*. (2022) 2022:S0883-5403(22) 00093-6. doi: 10.1016/j.arth.2022.01.076
2. Werner A, Jäger M, Schmitz H, Krauspe R. Joint preserving surgery for osteonecrosis and osteochondral defects after chemotherapy in childhood. *Klin Padiatr*. (2003) 215(6):332–7. doi: 10.1055/s-2003-45495
3. Sun XL, Zhao ZH, Ma JX, Li FB, Li YJ, Meng XM, et al. Continuous local infiltration analgesia for pain control after total knee arthroplasty: a meta-analysis of randomized controlled trials. *Medicine (Baltimore)*. (2015) 94 (45):e2005. doi: 10.1097/MD.0000000000002005
4. Tay HP, Wang X, Narayan SW, Penm J, Patanwala AE. Persistent postoperative opioid use after total hip or knee arthroplasty: a systematic review and meta-analysis. *Am J Health Syst Pharm*. (2022) 79(3):147–64. doi: 10.1093/ajhp/zxab367
5. Xiao PL, Hsu CJ, Ma YG, Liu D, Peng R, Xu XH, et al. Prevalence and treatment rate of osteoporosis in patients undergoing total knee and hip arthroplasty: a systematic review and meta-analysis. *Arch Osteoporos*. (2022) 17(1):16. doi: 10.1007/s11657-021-01055-9
6. Januel JM, Chen G, Ruffieux C, Quan H, Douketis JD, Crowther MA, et al. Symptomatic in-hospital deep vein thrombosis and pulmonary embolism following hip and knee arthroplasty among patients receiving recommended prophylaxis: a systematic review. *Jama*. (2012) 307(3):294–303. doi: 10.1001/jama.2011.2029
7. Moghtadaei M, Farahini H, Faiz SH, Mokarami F, Safari S. Pain management for total knee arthroplasty: single-injection femoral nerve block versus local infiltration analgesia. *Iran Red Crescent Med J*. (2014) 16(1):e13247. doi: 10.5812/ircmj.13247

8. Lee DH, Padhy D, Lee SH, Kim TK, Choi J, Han SB. Shed blood re-transfusion provides no benefit in computer-assisted primary total knee arthroplasty. *Knee Surg Sports Traumatol Arthrosc*. (2011) 19(6):926–31. doi: 10.1007/s00167-010-1228-8
9. Tang JZ, Nie MJ, Zhao JZ, Zhang GC, Zhang Q, Wang B. Platelet-rich plasma versus hyaluronic acid in the treatment of knee osteoarthritis: a meta-analysis. *J Orthop Surg Res*. (2020) 15(1):403. doi: 10.1186/s13018-020-01919-9
10. Nguyen RT, Borg-Stein J, McInnis K. Applications of platelet-rich plasma in musculoskeletal and sports medicine: an evidence-based approach. *Pm r*. (2011) 3(3):226–50. doi: 10.1016/j.pmrj.2010.11.007
11. Zhu Y, Yuan M, Meng HY, Wang AY, Guo QY, Wang Y, et al. Basic science and clinical application of platelet-rich plasma for cartilage defects and osteoarthritis: a review. *Osteoarthritis Cartilage*. (2013) 21(11):1627–37. doi: 10.1016/j.joca.2013.07.017
12. Houdek MT, Wyles CC, Stalboerger PG, Terzic A, Behfar A, Moran SL. Collagen and fractionated platelet-rich plasma scaffold for dermal regeneration. *Plast Reconstr Surg*. (2016) 137(5):1498–506. doi: 10.1097/PRS.0000000000002094
13. Romano F, Paolino FM, Rizzo BA, Russo A, Southworth S, Serra R, et al. The use of growth factors, CD34(+) cells and fibrin for the management of chronic venous ulcers. *Int Wound J*. (2016) 13(5):1011–3. doi: 10.1111/iwj.12500
14. Xia Y, Zhao J, Xie J, Lv Y, Cao DS. The efficacy of platelet-rich plasma dressing for chronic nonhealing ulcers: a meta-analysis of 15 randomized controlled trials. *Plast Reconstr Surg*. (2019) 144(6):1463–74. doi: 10.1097/PRS.0000000000006281
15. Li FX, Li Y, Qiao CW, Zhu J, Chen J, Zhang PY. Topical use of platelet-rich plasma can improve the clinical outcomes after total knee arthroplasty: a systematic review and meta-analysis of 1316 patients. *Int J Surg*. (2017) 38:109–16. doi: 10.1016/j.ijsu.2016.12.013
16. Guerreiro JPF, Lima DR, Bordignon G, Danieli MV, Queiroz AO, Cataneo DC. Platelet-rich plasma (prp) and tranexamic acid (txa) applied in total knee arthroplasty. *Acta Ortop Bras*. (2019) 27(5):248–51. doi: 10.1590/1413-785220192705214417
17. Ma J, Sun J, Guo W, Li Z, Wang B, Wang W. The effect of platelet-rich plasma on reducing blood loss after total knee arthroplasty: a systematic review and meta-analysis. *Medicine (Baltimore)*. (2017) 96(26):e7262. doi: 10.1097/MD.0000000000007262
18. Tandogan RN, Polat M, Beyzadeoglu T, Karabulut E, Yildirim K, Kayaalp A. Topical co-delivery of platelet rich fibrin and tranexamic acid does not decrease blood loss in primary total knee arthroplasty compared to the standard of care: a prospective, randomized, controlled trial. *Knee Surg Sports Traumatol Arthrosc*. (2021) 29(2):519–28. doi: 10.1007/s00167-020-05938-1
19. Tingstad EM, Bratt SN, Hildenbrand KJ, O'Malley BA, Mitchell ER, Gaddis CE, et al. Platelet-rich plasma does not decrease blood loss in total knee arthroplasty. *Orthopedics*. (2015) 38(5):e434–6. doi: 10.3928/01477447-20150504-63
20. Muchedzi TA, Roberts SB. A systematic review of the effects of platelet rich plasma on outcomes for patients with knee osteoarthritis and following total knee arthroplasty. *Surgeon*. (2018) 16(4):250–8. doi: 10.1016/j.surge.2017.08.004
21. Page MJ, Moher D, Bossuyt PM, Boutron I, Hoffmann TC, Mulrow CD, et al. PRISMA 2020 Explanation and elaboration: updated guidance and exemplars for reporting systematic reviews. *Br Med J*. (2021) 372:n160. doi: 10.1136/bmj.n160
22. Sterne JAC, Savović J, Page MJ, Elbers RG, Blencowe NS, Boutron I, et al. Rob 2: a revised tool for assessing risk of bias in randomised trials. *Br Med J*. (2019) 366:l4898. doi: 10.1136/bmj.l4898
23. Guyatt GH, Oxman AD, Schünemann HJ, Tugwell P, Knottnerus A. GRADE guidelines: a new series of articles in the journal of clinical epidemiology. *J Clin Epidemiol*. (2011) 64(4):380–2. doi: 10.1016/j.jclinepi.2010.09.011
24. Egger M, Davey Smith G, Schneider M, Minder C. Bias in meta-analysis detected by a simple, graphical test. *Br Med J*. (1997) 315(7109):629–34. doi: 10.1136/bmj.315.7109.629
25. Begg CB, Mazumdar M. Operating characteristics of a rank correlation test for publication bias. *Biometrics*. (1994) 50(4):1088–101. doi: 10.2307/2533446
26. Peerbooms JC, de Wolf GS, Colaris JW, Bruijn DJ, Verhaar JA. No positive effect of autologous platelet gel after total knee arthroplasty. *Acta Orthop*. (2009) 80(5):557–62. doi: 10.3109/17453670903350081
27. Horstmann WG, Slappendel R, van Hellemondt GG, Wymenga AW, Jack N, Everts PA. Autologous platelet gel in total knee arthroplasty: a prospective randomized study. *Knee Surg Sports Traumatol Arthrosc*. (2011) 19(1):115–21. doi: 10.1007/s00167-010-1207-0
28. Aggarwal AK, Shashikanth VS, Marwaha N. Platelet-rich plasma prevents blood loss and pain and enhances early functional outcome after total knee arthroplasty: a prospective randomised controlled study. *Int Orthop*. (2014) 38(2):387–95. doi: 10.1007/s00264-013-2136-6
29. Morishita M, Ishida K, Matsumoto T, Kuroda R, Kurosaka M, Tsumura N. Intraoperative platelet-rich plasma does not improve outcomes of total knee arthroplasty. *J Arthroplasty*. (2014) 29(12):2337–41. doi: 10.1016/j.arth.2014.04.007
30. Guerreiro JP, Danieli MV, Queiroz AO, Deffune E, Ferreira RR. Platelet-rich plasma (PRP) applied during total knee arthroplasty. *Rev Bras Ortop*. (2015) 50(2):186–94. doi: 10.1016/j.rbo.2014.05.005
31. Mochizuki T, Yano K, Ikari K, Hiroshima R, Kawakami K, Koenuma N, et al. Platelet-rich plasma for the reduction of blood loss after total knee arthroplasty: a clinical trial. *Eur J Orthop Surg Traumatol*. (2016) 26(8):901–5. doi: 10.1007/s00590-016-1821-8
32. Evans DC, Evans BG. The effects of platelet-rich plasma and activated collagen on wound healing in primary total joint arthroplasty. *Orthopedics*. (2018) 41(2):e262–e7. doi: 10.3928/01477447-20180213-05
33. Capion SC, Jørgensen HBL, Ågren MS, Daugaard H, Ribel-Madsen S, Marando D, et al. The wound healing effect of local leukocyte platelet-rich plasma after total hip arthroplasty: a randomized controlled trial. *Wound Repair Regen*. (2021) 29(6):988–95. doi: 10.1111/wrr.12967
34. Lu Q, Peng H, Zhou GJ, Yin D. Perioperative blood management strategies for total knee arthroplasty. *Orthop Surg*. (2018) 10(1):8–16. doi: 10.1111/os.12361
35. Gardner MJ, Demetrakopoulos D, Klepchick PR, Mooar PA. The efficacy of autologous platelet gel in pain control and blood loss in total knee arthroplasty. an analysis of the haemoglobin, narcotic requirement and range of motion. *Int Orthop*. (2007) 31(3):309–13. doi: 10.1007/s00264-006-0174-z
36. Wang F, Zhao KC, Zhao MM, Zhao DX. The efficacy of oral versus intravenous tranexamic acid in reducing blood loss after primary total knee and hip arthroplasty: a meta-analysis. *Medicine (Baltimore)*. (2018) 97(36):e12270. doi: 10.1097/MD.0000000000012270
37. Sclafani AP, Azzi J. Platelet preparations for use in facial rejuvenation and wound healing: a critical review of current literature. *Aesthetic Plast Surg*. (2015) 39(4):495–505. doi: 10.1007/s00266-015-0504-x
38. Jee CH, Eom NY, Jang HM, Jung HW, Choi ES, Won JH, et al. Effect of autologous platelet-rich plasma application on cutaneous wound healing in dogs. *J Vet Sci*. (2016) 17(1):79–87. doi: 10.4142/jvs.2016.17.1.79
39. Russo S, Landi S, Courric S. Cost-Effectiveness analysis for the treatment of diabetic foot ulcer in France: platelet-rich plasma vs standard of care. *Clinicoecon Outcomes Res*. (2022) 14:1–10. doi: 10.2147/CEOR.S327191
40. Rajan PV, Ng MK, Klika A, Kamath AF, Muschler GF, Higuera CA, et al. The cost-effectiveness of platelet-rich plasma injections for knee osteoarthritis: a markov decision analysis. *J Bone Joint Surg Am*. (2020) 102(18):e104. doi: 10.2106/JBJS.19.01446

Conflict of Interest: The authors declare that the research was conducted in the absence of any commercial or financial relationships that could be construed as a potential conflict of interest.

Publisher's Note: All claims expressed in this article are solely those of the authors and do not necessarily represent those of their affiliated organizations, or those of the publisher, the editors and the reviewers. Any product that may be evaluated in this article, or claim that may be made by its manufacturer, is not guaranteed or endorsed by the publisher.

Copyright © 2022 Shu, Huang, Bai, Xia, Wang, Fu, Cheng and Zhou. This is an open-access article distributed under the terms of the Creative Commons Attribution License (CC BY). The use, distribution or reproduction in other forums is permitted, provided the original author(s) and the copyright owner(s) are credited and that the original publication in this journal is cited, in accordance with accepted academic practice. No use, distribution or reproduction is permitted which does not comply with these terms.

frontiers | Frontiers in Surgery

CASE REPORT
published: 06 July 2022
doi: 10.3389/fsurg.2022.922896

Unicompartmental Knee Arthroplasty for Knee Osteoarthritis With the Pellegrini–Stieda Lesion: A Case Report

Qiuyuan Wang[1,2], Wanshou Guo[2], Zhencai Shi[2], Weiguo Wang[2] and Qidong Zhang[2]**

[1]Graduate School of Beijing University of Chinese Medicine, Beijing, China, [2]Department of Orthopaedic Surgery, China–Japan Friendship Hospital, Beijing, China

Pellegrini–Stieda lesion is described as ossification on the origin of medial collateral ligament. We present a case of end-stage knee osteoarthritis with the Pellegrini–Stieda lesion treated by unicompartmental knee arthroplasty (UKA). During the postoperative follow-up, an interesting change occurred such that the ossification lesion disappeared gradually and did not relapse. It is supposed that the disappearance was caused by UKA changing the abnormal biomechanics of the varus osteoarthritic knee.

Keywords: unicompartmental knee arthroplasty, Pellegrini–Stieda lesion, knee osteoarthritis, ossification, medial collateral ligament (MCL)

OPEN ACCESS

Edited by:
Paphon Sa-ngasoongsong, Mahidol University, Thailand

Reviewed by:
Lu Yungchang, Mackay Memorial Hospital, Taiwan
Guanglei Cao, Capital Medical University, China

***Correspondence:**
Wanshou Guo
zrgwsbucm@163.com
Qidong Zhang
zhangqidong1982@sina.com

Specialty section:
This article was submitted to Orthopedic Surgery, a section of the journal Frontiers in Surgery

Received: *18 April 2022*
Accepted: *13 June 2022*
Published: *06 July 2022*

Citation:
Wang Q, Guo W, Shi Z, Wang W and Zhang Q (2022) Unicompartmental Knee Arthroplasty for Knee Osteoarthritis With the Pellegrini–Stieda Lesion: A Case Report. Front. Surg. 9:922896. doi: 10.3389/fsurg.2022.922896

INTRODUCTION

Pellegrini–Stieda lesion is usually described as ossification on the origin of medial collateral ligament (MCL) (1–5). Its clinical significance was first studied and reported by Pellegrini in 1905 and then by Stieda in 1908 (6, 7). The mechanism of the Pellegrini–Stieda lesion was found to be associated with trauma (4, 8–10). Conservative therapies are usually adopted for curing the lesion (11–13), and surgical cases with good outcomes have also been reported in the literature (14). This article reports the case of end-stage knee osteoarthritis with the Pellegrini–Stieda lesion treated by unicompartmental knee arthroplasty.

CASE PRESENTATION

A 76-year-old woman was hospitalized for acute exacerbation pain and activity limitation of the left knee. Over 10 years ago, she started to feel pain in her left knee. The pain often worsened after long-time weight-bearing activity and could be relieved by rest. She always accepted conservative treatment (oral and external-used non-steroidal anti-inflammatory drugs, physical therapy, and acupuncture) and received a fair curative effect. Five days back, her left knee pain unexpectedly worsened, accompanied by joint swelling and a sense of knee joint locking. She experienced difficulty with climbing stairs and her pain-free walking distance was less than 100 m. A physical examination of the left knee showed tenderness on the medial side, especially on the medial joint space, a weak positive floating patella test, and a

0–5° to 100° range of motion (ROM). The HSS score of the left knee was 55. An x-ray of the left knee indicated a degenerative lesion in the medial knee compartment, presented as narrowed joint space and subchondral sclerosis (**Figure 1A**). A strip-shaped high-density shadow in the medial is noticeable (**Figures 1A, C**). Further MRI examination of the left knee showed ossification involving medial collateral ligament (MCL) and medial joint capsule (**Figure 2**). The ossification was considered as the Pellegrini–Stieda lesion.

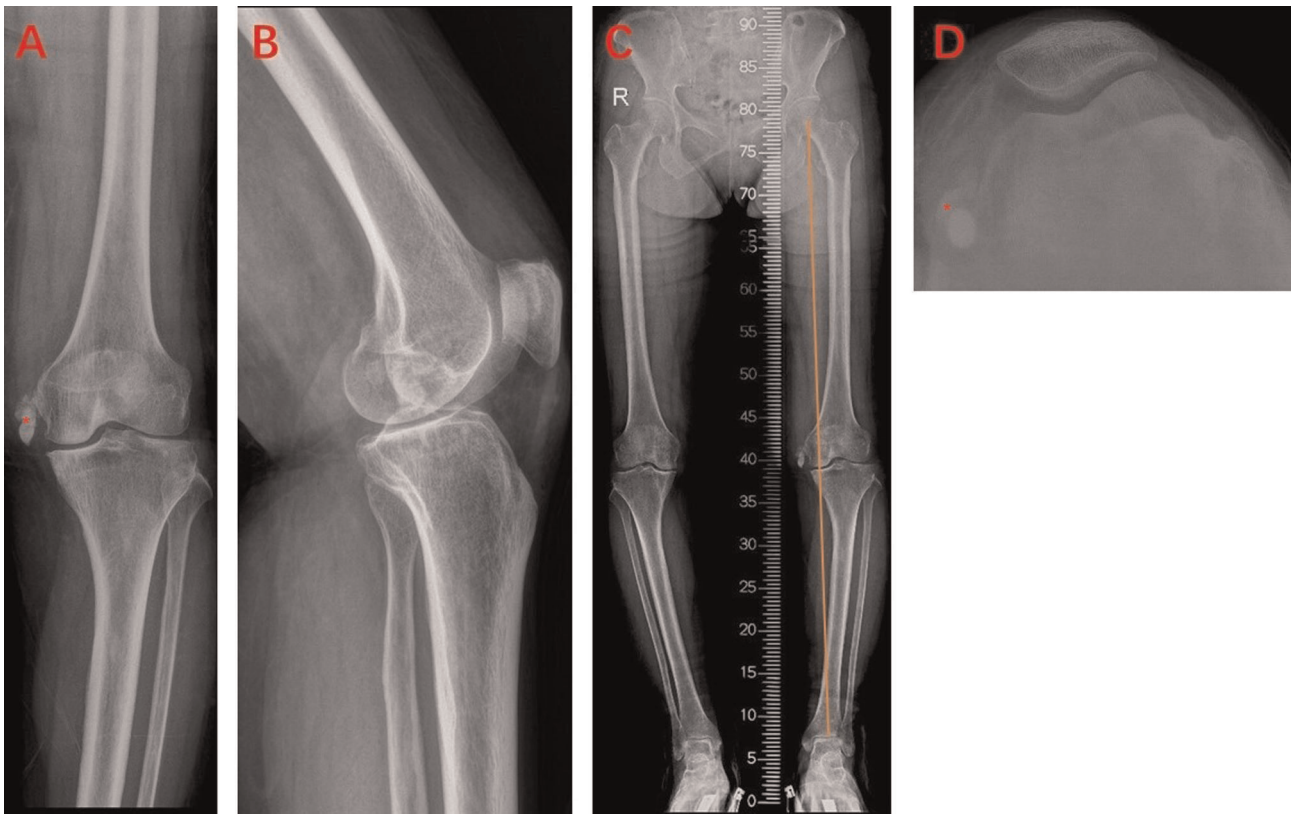

FIGURE 1 | Preoperative x-ray of the left knee. (**A**) AP view; (**B**) lateral view; (**C**) full-weight bearing view; (**D**) merchant view. *Pellegrini–Stieda lesion.

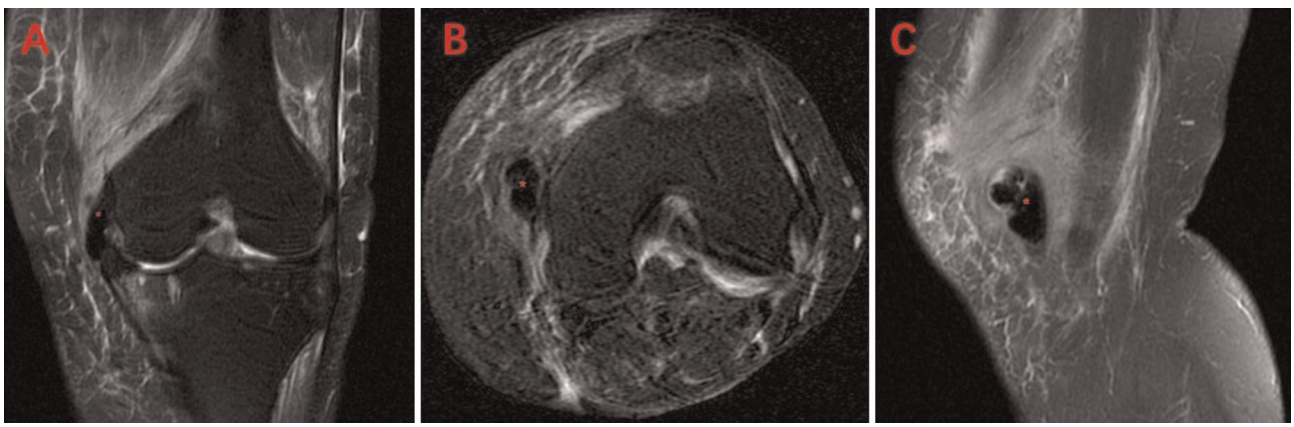

FIGURE 2 | Preoperative MRI of the left knee. (**A**) Coronal T2 weighted image (T2WI); (**B**) transverse axis proton density weighted image (PDWI); (**C**) sagittal T2WI. *Pellegrini–Stieda lesion.

According to the anteroposterior and lateral view of the x-ray, the cartilage wear area was mainly located in the anteromedial of the left knee (**Figures 1A, B**). The full-weight-bearing x-ray showed varus deformity of the left knee, and the intra-articular deformity occupied the main (**Figure 1D**). So, we conducted medial mobile-bearing unicompartmental knee arthroplasty (Oxford UKA, Zimmer Biomet, Warsaw, IN, United States) for this patient. Intraoperatively, we found cartilage injury on the medial tibial plateau and medial femoral condyle (Outerbridge grade III). The synovium around the medial femoral condyle presented hyperemia and edema. The pathology of the synovium found villous hyperplasia and indicated acute and chronic inflammation (**Figure 3**). The surgery progressed well, and the patient returned to the ward safely after recovery from anesthesia. Then, she was treated with common therapies such as analgesia, ice compress, infection prevention, early functional exercises, etc. Her postoperative recovery was good, and the ROM was 0-0–110° on discharge. The postoperative x-ray indicated that the varus deformity was corrected, and the position of the prosthesis was satisfactory **(Figures 4A–C**).

However, the x-ray during follow-up showed a surprising finding. The postoperative x-ray during hospitalization showed that the medial ossification lesion still existed and was almost the same as that of preoperative x-ray. However, the postoperative 3-month x-ray showed that the ossification lesion shrank obviously and became discontinuous (**Figure 4D**). Nine months after surgery, the x-ray found that the ossification lesion entirely disappeared (**Figure 4E**). The latest outpatient follow-up was on postoperative 3.5 years, and no relapse of the ossification lesion was found on the x-ray (**Figure 4F**). The patient was satisfied with her left knee function, and the HSS score was 90 at the last follow-up.

DISCUSSION

To our knowledge, this is the first case report of UKA treating end-stage osteoarthritis with the Pellegrini–Stieda lesion. The most valuable finding was that the ossification lesion disappeared gradually after UKA and did not relapse during the follow-up. We suppose this interesting change may be related to the improvement in the biomechanical environment induced by UKA. As UKA can restore the tension of MCL and correct the varus deformity (15–17), the abnormal biomechanics of the osteoarthritic knee was reversed (18, 19). Of course, the mechanism behind this change is highly complex, and more studies are required on this special and interesting clinical finding.

The anatomic location of the Pellegrini–Stieda lesion has always been controversial. Pellegrini described that the lesion was located at the origin of knee MCL according to the findings of surgical removal (6). While, according to the cadaver study, Stieda held a different opinion that the lesion was located medial to the origin of the gastrocnemius medial head muscle (7). In subsequent studies and reports, the Pellegrini–Stieda lesion can also involve the adductor magnus tendon and posterior attachment of medial patellofemoral ligament (MPFL) (5, 14, 20). From the MRI of our case, the ossification lesion involved MCL and medial joint capsule. So, the characteristics of this case fit the descriptions of the Pellegrini–Stieda lesion in the literature. Mendes et al. proposed a classification for the Pellegrini–Stieda lesion on the basis of anatomic and clinical studies (5). According to their description, our case belongs to type I for representing a beak-like appearance with an inferior orientation and femoral attachment.

With regard to surgical techniques, we followed the basic principles of Oxford UKA that the balance of flexion and extension gap was achieved only by osteotomy and the tension

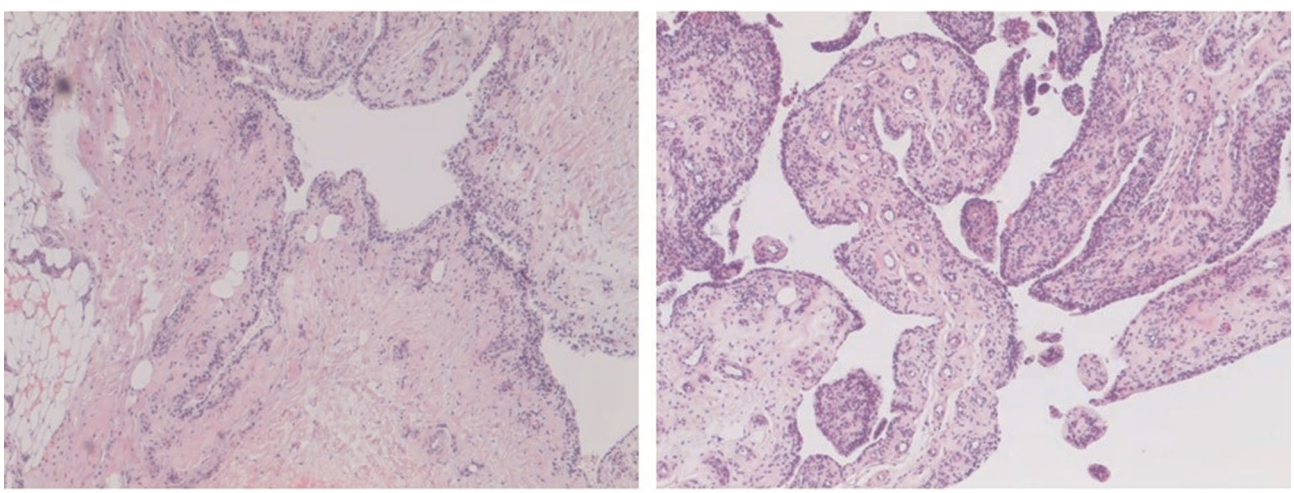

FIGURE 3 | Pathology of the synovium.

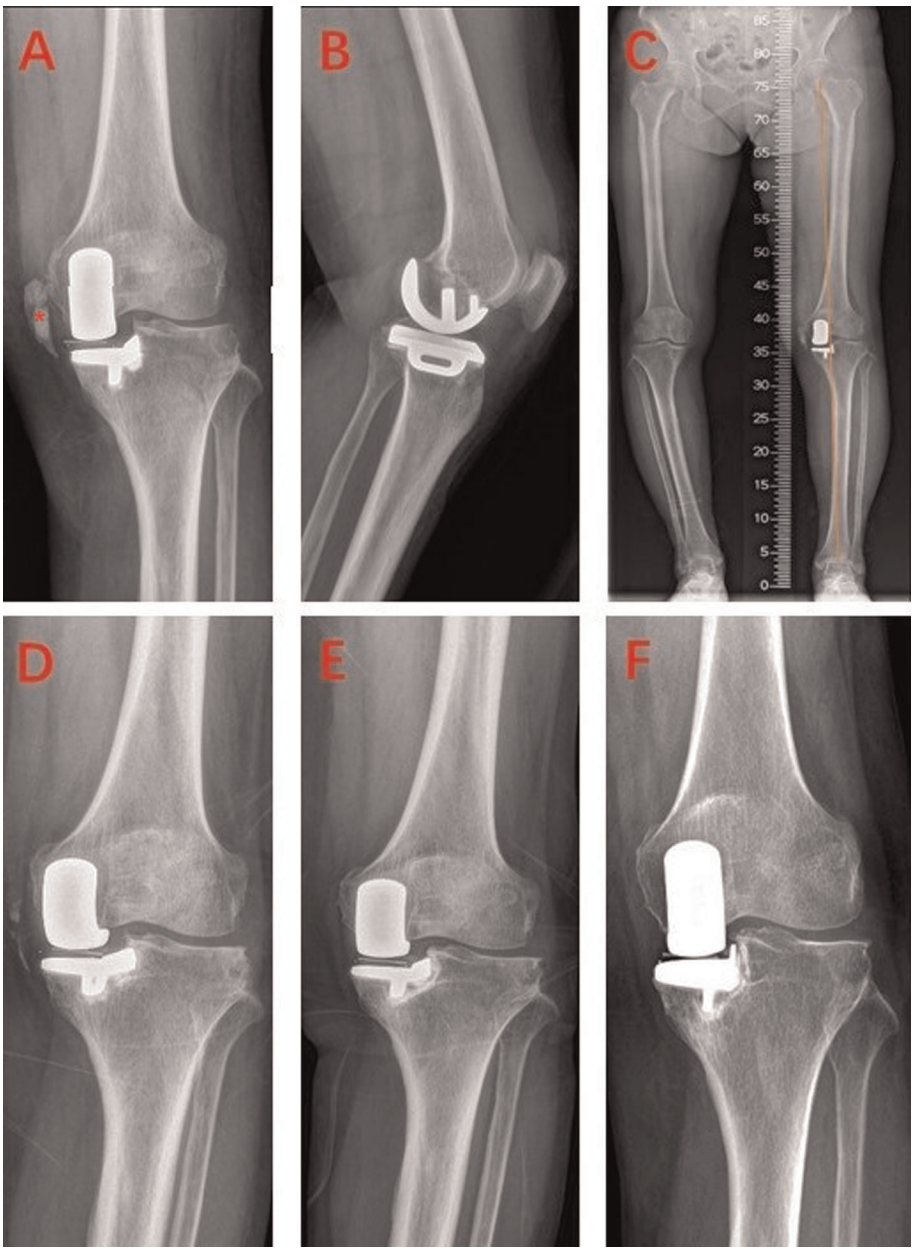

FIGURE 4 | Postoperative x-ray during discharge and follow-up. (**A**–**C**) X-ray at discharge, *Pellegrini–Stieda lesion; (**D**) postoperative 3 months; (**E**) postoperative 9 months; (**F**) postoperative 3.5 years.

of MCL was recovered by the filling the mobile bearing into the joint space. Any procedure on MCL may affect the soft tissue balance. Therefore, no release on MCL or any intervention on the ossification lesion was performed.

The characteristic of medical history is another noteworthy point of this case. The patient complained that her left knee pain had been presented for over 10 years and the pain became acute 5 days before hospitalization. Although her pain could perhaps be attributed to osteoarthritis, the real reason for its worsening is worth analyzing, as the symptomatic progression of osteoarthritis is usually chronic (21). Although uncommon, an acute inflammatory state of osteoarthritis is highly possible for this case. But our speculation suggests that the acute pain was mainly due to the impingement between the ossification lesion and synovium, which could lead to synovial interposing and acute synovitis. The pathologic results also testify to this. Due to the varus knee deformity, the load of medial knee compartment became heavier, and the tension of MCL also decreased (22). In this condition, it is possible to generate impingement between the ossification lesion and the surrounding synovium. While, after

UKA, the hyperplastic arthritic synovium was removed, the worn medial compartment was replaced, and the tension of MCL was also recovered. As a result, the patient's pain was released.

CONCLUSION

This article presents a case of end-stage knee osteoarthritis with the Pellegrini–Stieda lesion treated by UKA. Surprisingly, the ossification lesion disappeared gradually during the post-operative follow-up and did not relapse. It was supposed that the disappeared ossification was due to UKA reserving the abnormal biomechanics of the varus osteoarthritic knee. More studies are required to investigate this phenomenon.

DATA AVAILABILITY STATEMENT

The raw data supporting the conclusions of this article will be made available by the authors, without undue reservation.

AUTHOR CONTRIBUTIONS

QYW wrote the manuscript, WSG and ZCS provided the case information, and WGW and QDZ analyzed and discussed the case. All authors contributed to the article and approved the submitted version.

FUNDING

This work is supported by the National Natural Science Foundation of China (Grant number 82072494, 81972130), the Capital Health Research and Development of Special (Grant number 2020-2-4067), the Elite Medical Professionals project of the China-Japan Friendship Hospital (Grant number ZRJY2021-GG08), and the Municipal Natural Science Foundation of Beijing of China (Grant number:7202183).

REFERENCES

1. Somford MP, Janssen R, Meijer D, Roeling T, Brown Jr C, Eygendaal D. The Pellegrini–Stieda Lesion of the knee: an anatomical and radiological review. *J Knee Surg*. (2019) 32:637–41. doi: 10.1055/s-0038-1666867
2. Majjhoo A, Sagar H. Pellegrini–Stieda disease: calcification of the medial collateral ligament. *J Clin Rheumatol*. (2011) 17(8):456. doi: 10.1097/RHU.0b013e31820568db
3. Houston AN, Roy WA, Faust RA, Ewin DM, Espenan PA. Pellegrini–Stieda syndrome: report of 44 cases followed from original injury. *South Med J*. (1968) 61:113–7. doi: 10.1097/00007611-196802000-00001
4. Somford MP, Lorusso L, Porro A, Loon CV, Eygendaal D. The Pellegrini–Stieda lesion dissected historically. *J Knee Surg*. (2018) 31:562–7. doi: 10.1055/s-0037-1604401
5. Mendes LF, Pretterklieber ML, Cho JH, Garcia GM, Resnick DL, Chung CB. Pellegrini–Stieda disease: a heterogeneous disorder not synonymous with ossification/calcification of the tibial collateral ligament-anatomic and imaging investigation. *Skeletal Radiol*. (2006) 35:916–22. doi: 10.1007/s00256-006-0174-5
6. Pelligrini A. Ossificazione traumatica del ligamento collaterale tibiale dell'articolazione del ginocchio sinistro. *Clin Moderna*. (1905) 11:433–9.
7. Stieda A. Ueber eine typische verletzung am unteren femurende. *Arch F Klin Chir*. (1908) 85:815–26.
8. McAnally JL, Southam SL, Mlady GW. New thoughts on the origin of Pellegrini–Stieda: the association of PCL injury and medial femoral epicondylar periosteal stripping. *Skeletal Radiol*. (2009) 38:193–8. doi: 10.1007/s00256-008-0604-7
9. Altschuler EL, Bryce TN. Images in clinical medicine. Pellegrini–Stieda syndrome. *N Engl J Med*. (2006) 354:e1. doi: 10.1056/NEJMicm040406
10. Lee CH, Tan CF, Kim O, Suh KJ, Yao MS, Chan WP, et al. Osseous injury associated with ligamentous tear of the knee. *Can Assoc Radiol J*. (2016) 67:379–86. doi: 10.1016/j.carj.2016.02.002
11. Greidanus BD. A novel treatment of painful medial collateral ligament calcification (Pellegrini–Stieda syndrome): a case report. *Clin J Sport Med*. (2021) 32(4):e441–2. doi: 10.1097/JSM.0000000000000982
12. Wang JC, Shapiro MS. Pellegrini–Stieda syndrome. *Am J Orthop (Belle Mead NJ)*. (1995) 24:493–7.
13. De Vis JB, Kersemans P. Pellegrini–Stieda disease. *JBR-BTR*. (2010) 93:275. doi: 10.5334/jbr-btr.339
14. Theivendran K, Lever CJ, Hart WJ. Good result after surgical treatment of Pellegrini–Stieda syndrome. *Knee Surg Sports Traumatol Arthrosc*. (2009) 17:1231–3. doi: 10.1007/s00167-009-0725-0
15. Zhang Q, Yue J, Wang W, Chen Y, Zhao Q, Guo W. FTFA Change under valgus stress force radiography is useful for evaluating the correctability of intra-articular varus deformity in UKA. *Arch Orthop Trauma Surg*. (2018) 138:1003–9. doi: 10.1007/s00402-018-2945-6
16. Tuecking LR, Savov P, Richter T, Windhagen H, Ettinger M. Clinical validation and accuracy testing of a radiographic decision aid for unicondylar knee arthroplasty patient selection in midterm follow-up. *Knee Surg Sports Traumatol Arthrosc*. (2020) 28:2082–90. doi: 10.1007/s00167-020-05912-x
17. Winnock de Grave P, Luyckx T, Ryckaert A, Noyez J, Gunst P, Van den Daelen L. Medial unicompartmental knee arthroplasty with a fixed bearing implant. *JBJS Essent Surg Tech*. (2019) 9:e26. doi: 10.2106/JBJS.ST.18.00083
18. Peersman G, Slane J, Vuylsteke P, Fuchs-Winkelmann S, Dworschak P, Heyse T, et al. Kinematics of mobile-bearing unicompartmental knee arthroplasty compared to native: results from an in vitro study. *Arch Orthop Trauma Surg*. (2017) 137:1557–63. doi: 10.1007/s00402-017-2794-8
19. Koh YG, Park KM, Kang KT. Influence of preservation of normal knee contact stress on other compartments with respect to the tibial insert design for unicompartmental knee arthroplasty. *Appl Bionics Biomech*. (2019) 2019:9246379. doi: 10.1155/2019/9246379
20. McArthur TA, Pitt MJ, Garth WP, Narducci CA. Pellegrini–Stieda ossification can also involve the posterior attachment of the MPFL. *Clin Imaging*. (2016) 40:1014–7. doi: 10.1016/j.clinimag.2016.06.001
21. Sacitharan PK. Ageing and osteoarthritis. *Subcell Biochem*. (2019) 91:123–59. doi: 10.1007/978-981-13-3681-2_6
22. Fishkin Z, Miller D, Ritter C, Ziv I. Changes in human knee ligament stiffness secondary to osteoarthritis. *J Orthop Res*. (2002) 20:204–7. doi: 10.1016/S0736-0266(01)00087-0

Conflict of Interest: The authors declare that the research was conducted in the absence of any commercial or financial relationships that could be construed as a potential conflict of interest.

Publisher's Note: All claims expressed in this article are solely those of the authors and do not necessarily represent those of their affiliated organizations, or those of the publisher, the editors and the reviewers. Any product that may be evaluated in this article, or claim that may be made by its manufacturer, is not guaranteed or endorsed by the publisher.

Copyright © 2022 Wang, Guo, Shi, Wang and Zhang. This is an open-access article distributed under the terms of the Creative Commons Attribution License (CC BY). The use, distribution or reproduction in other forums is permitted, provided the original author(s) and the copyright owner(s) are credited and that the original publication in this journal is cited, in accordance with accepted academic practice. No use, distribution or reproduction is permitted which does not comply with these terms.

frontiers | Frontiers in Surgery

TYPE Original Research
PUBLISHED 18 July 2022
DOI 10.3389/fsurg.2022.911742

Check for updates

OPEN ACCESS

EDITED BY
Paphon Sa-ngasoongsong,
Mahidol University, Thailand

REVIEWED BY
Martin Ortler,
Innsbruck Medical University, Austria
Fabio Cofano,
University of Turin, Italy

*CORRESPONDENCE
Paerhati Rexiti
parhart@vip.sina.com

†These authors have contributed equally to this work.

SPECIALTY SECTION
This article was submitted to Orthopedic Surgery, a section of the journal Frontiers in Surgery

RECEIVED 03 April 2022
ACCEPTED 28 June 2022
PUBLISHED 18 July 2022

CITATION
Kahaer A, Maimaiti X, Maitirouzi J, Wang S, Shi W, Abuduwaili N, Zhou Z, Liu D, Maimaiti A and Rexiti P (2022) Biomechanical investigation of the hybrid modified cortical bone screw–pedicle screw fixation technique: Finite-element analysis.
Front. Surg. 9:911742.
doi: 10.3389/fsurg.2022.911742

COPYRIGHT
© 2022 Kahaer, Maimaiti, Maitirouzi, Wang, Shi, Abuduwaili, Zhou, Liu, Maimaiti and Rexiti. This is an open-access article distributed under the terms of the Creative Commons Attribution License (CC BY). The use, distribution or reproduction in other forums is permitted, provided the original author(s) and the copyright owner(s) are credited and that the original publication in this journal is cited, in accordance with accepted academic practice. No use, distribution or reproduction is permitted which does not comply with these terms.

Biomechanical investigation of the hybrid modified cortical bone screw–pedicle screw fixation technique: Finite-element analysis

Alafate Kahaer[1†], Xieraili Maimaiti[1†], Julaiti Maitirouzi[2], Shuiquan Wang[3], Wenjie Shi[4], Nueraihemaiti Abuduwaili[5], Zhihao Zhou[1], Dongshan Liu[1], Abulikemu Maimaiti[1] and Paerhati Rexiti[1*]

[1]Department of Spine Surgery, The First Affiliated Hospital of Xinjiang Medical University, Urumqi, China, [2]College of Mechanical Engineering, Xinjiang University, Urumqi, China, [3]Department of Anatomy, College of Basic Medicine, Xinjiang Medical University, Urumqi, China, [4]First Clinical Medical College, Xinjiang Medical University, Urumqi, China, [5]Department of Imaging Center, The First Affiliated Hospital of Xinjiang Medical University, Urumqi, China

Background: Hybrid fixation techniques including the both modified cortical bone trajectory (MCBT) and traditional trajectory (TT) at the L4 and L5 lumbar segment are firstly proposed by our team. Therefore, the purpose of this study is to evaluate and provide specific biomechanical data of the hybrid fixation techniques including the MCBT and TT.

Methods: Four human cadaveric specimens were from the anatomy laboratory of Xinjiang Medical University. Four finite-element (FE) models of the L4–L5 lumbar spine were generated. For each of them, four implanted models with the following fixations were established: TT-TT (TT screw at the cranial and caudal level), MCBT-MCBT (MCBT screw at the cranial and caudal level), hybrid MCBT-TT (MCBT screw at the cranial level and TT screw at the caudal level), and TT-MCBT (TT screw at the cranial level and MCBT screw at the caudal level). A 400-N compressive load with 7.5 N/m moments was applied to simulate flexion, extension, lateral bending, and rotation, respectively. The range of motion (ROM) of the L4–L5 segment and the posterior fixation, the von Mises stress of the intervertebral disc, and the posterior fixation were compared.

Results: Compared to the TT-TT group, the MCBT-TT showed a significant lower ROM of the L4–L5 segment ($p \leq 0.009$), lower ROM of the posterior fixation ($p < 0.001$), lower intervertebral disc stress ($p < 0.001$), and lower posterior fixation stress ($p \leq 0.041$). TT-MCBT groups showed a significant lower ROM of the L4–L5 segment ($p \leq 0.012$), lower ROM of the posterior fixation ($p < 0.001$), lower intervertebral disc stress ($p < 0.001$), and lower posterior fixation stress ($p \leq 0.038$).

Abbreviations: MCBT, modified cortical bone trajectory; CBT, cortical bone trajectory; TT, traditional trajectory; TLIF, transforaminal lumbar interbody fusion; FE, finite element; 3D, 3-dimensional; ANOVA, analysis of variance; ROM, range of motion; ASD, adjacent segment degeneration.

Conclusions: The biomechanical properties of the hybrid MCBT-TT and TT-MCBT techniques at the L4–L5 segment are superior to that of stability MCBT-MCBT and TT-TT techniques, and feasibility needs further cadaveric study to verify.

KEYWORDS

traditional trajectory, modified cortical bone trajectory, hybrid fixation technique, 3-dimensional finite-element analysis, lumbar spine

Introduction

For decades, the pedicle screw fixation technique has been the mainstay in the lumbar spine surgery (1), but it has several defects such as screw loosening, breakage, and extensive muscle dissection (2, 3), these were more common in patients with osteoporosis (4, 5). To acquire superior fixation strength, scholars had made many attempts from the shape design of screw to the curing of screw tracks, such as designing expandable pedicle screw, hydroxyapatite coating of the screw surface, and cement augmentation (6, 7). However, they have not been popularized in the clinic due to the high price, potential safety hazards including cement polymerization fever, chemical toxicity, and leakage.

In 2009, Santoni et al. (8) proposed the cortical bone trajectory (CBT) technique, changing the long axis of cancellous bone as a screw path compared to the pedicle screw. Cortical bone, on the other hand, does not produce significant osteopenia with degeneration compared with cancellous bone. The trajectory was 10 deg laterally in the axial plane and 25 deg cranially in the sagittal plane (9) (**Figure 1B**), with the entry points located at the 5 and 7 o'clock orientation of the left and right pedicle, respectively (10). CBT technique increased the pullout load by 30%, torque by 1.7 times (8, 11). However, cortical bone throughout the screw track has not been unreservedly used by CBT, especially the medial wall of the pedicle and the lateral margin of the superior endplate (12). Therefore, to compensate the defects in anatomical reference, entry point, and screw trajectory, we previously proposed the modified cortical bone trajectory (MCBT) technique (12) (**Figure 1C**). The insertion point of the MCBT technique close to the midline increasing the purchase of the screw because of the contact between the screw and the medial wall of the pedicle (12). MCBT technique avoids the facet joint degeneration caused by the interaction between the facet joint and the screw hub (13). In addition, increasing of the medio-lateral angle and screw length makes the screw head contact with the cortical bone in the anterior lateral edge of the upper endplate of the vertebral body. The MCBT technique makes full use of the cortical bone of inferior wall of pedicle by reducing cranio-caudal angle, especially in transforaminal lumbar interbody fusion (TLIF) (13). This was consistent with the results of Petrone et al. (14), Penner et al. (15), and Marengo et al. (16). Decompression of the lateral recess on the caudal vertebral body is often required, while complete decompression of the lateral recess cannot be completed after the MCBT was used. In addition, complete decompression may destroy the insertion point of the CBT and the MCBT screws. Isthmic fracture or lumbar spondylolisthesis was a contraindication for CBT and MCBT techniques (8, 9). Calvert et al. (17) demonstrated that CBT could be an alternative when the failure of the pedicle screw fixation occurs.

We firstly proposed the hybrid MCBT-TT and TT-MCBT techniques to make up for the defects of CBT and MCBT techniques, especially nerve decompression effect, and aim to provide the fixation technique with superior stability and strength. The ROM of the fixation segment and posterior fixation are inversely proportional to the stability of the vertebral body and the fixation. The equivalent stress of the intervertebral disc and the fixation are related to stability of the cage after lumbar fusion and the strength limit of fixation (18). In this study, the biomechanical properties of the hybrid techniques were discussed in detail by FE analysis method.

Materials and methods

Model development of the L4–L5 lumber spine

We have completed the construction and validation of the FE models in L4–L5 lumbar spine and analyzed the TT-TT group in the earlier study (19). In this study, the construction methods, material properties, and meshes were referred to the previous models (19). The cortical bone was defined as the 0.5 mm thickness outward from the outer layer of cancellous bone according to the density mapping based on CT scan data (20). Intervertebral disc was composed of incompressible annulus fibrosus and nucleus pulposus. The fluid-like behavior of the incompressible nucleus pulposus was simulated with linear elasticity (Poisson's value = 0.45). Meshed models were finally generated with a maximum size of 1.5 mm and a minimum size of 0.5 mm. ABAQUS 2019 (ABAQUS, Providence, Rhode Island, USA) was used for the material properties setting and FE analysis.

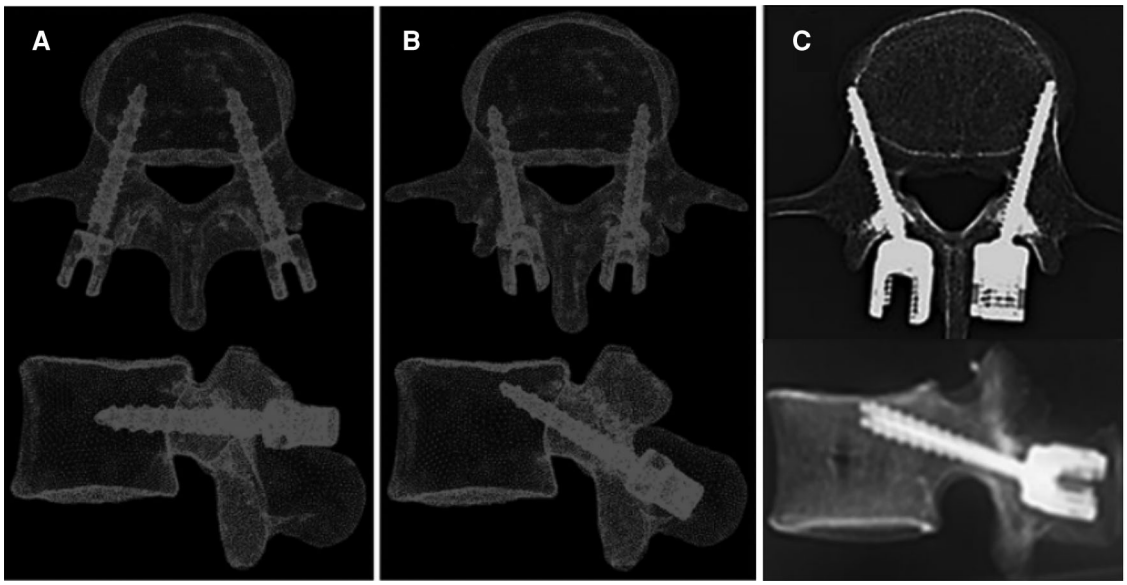

FIGURE 1
Schematic diagram of three different lumbar posterior fixations: (A). traditional trajectory (TT) (9), (B) cortical bone trajectory (CBT) (9), and (C) modified cortical bone trajectory (MCBT) (12).

Construction of surgical models

Four different posterior fixations were established: (1) TT-TT group, pedicle screws at the cranial, and caudal levels (**Figures 2A,E**) (19); (2) MCBT-MCBT group, MCBT screws at the cranial, and caudal levels (**Figures 2B,F**); (3) MCBT-TT group, MCBT screws at the cranial level, and TT screws at the caudal level (**Figures 2C,G**); and (4) TT-MCBT group, TT screws at the cranial level, and MCBT screws at the caudal level (**Figures 2D,H**). Sixteen FE models were established based on the four specimens. The insertion point of the MCBT screw was demonstrated in the earlier studies (12, 13) (**Figures 2B,F**). The TT screw is 6.0 mm in diameter and 45 mm in length, the MCBT screw is 4.5 mm in diameter and 40 mm in length, and titanium-based rod measured 5.5-mm in diameter.

Boundary and loading conditions

All models were fixed at the inferior surface of the L5 vertebral body. A 400 N vertical axial preload with 7.5 Nm moment was applied on the superior surface of the L4 vertebral body to simulate flexion, extension, left-right lateral bending, and left-right rotation. The relationship between the L4 and L5 vertebral body and the intervertebral disc was defined as mutual contact, using face-to-face correspondence. The ROM of the L4–L5 segment and posterior fixation, von Mises stress of the intervertebral disc, and posterior fixation were investigated.

Statistical methods

SPSS 26.0 software was used for data analysis and processing. Mean values of quantitative data were presented as mean ± standard deviation. One-way analysis of variance was used for the analysis of differences. When the differences were statistically significant, *post hoc* test was performed using the least significant difference (LSD) method. For all results, $p < 0.05$ was considered statistically significant.

Results

ROM of the L4–L5 segment

Compared to the TT-TT group, the MCBT-TT group showed a significantly lower ROM ($p \leq 0.012$), and compared with the MCBT-MCBT group, the TT-MCBT group showed significantly lower ROM only in flexion and right lateral bending ($p \leq 0.045$). There was no significant difference between the MCBT-TT group and the TT-MCBT group ($p > 0.05$). Among the four posterior fixation models, the TT-MCBT group showed the lowest ROM (**Figure 3**). Compared to the TT-TT group, ROM of the MCBT-TT group reduced by 37%, 24%, 34%, 47%, 32%, and 29% in flexion, extension,

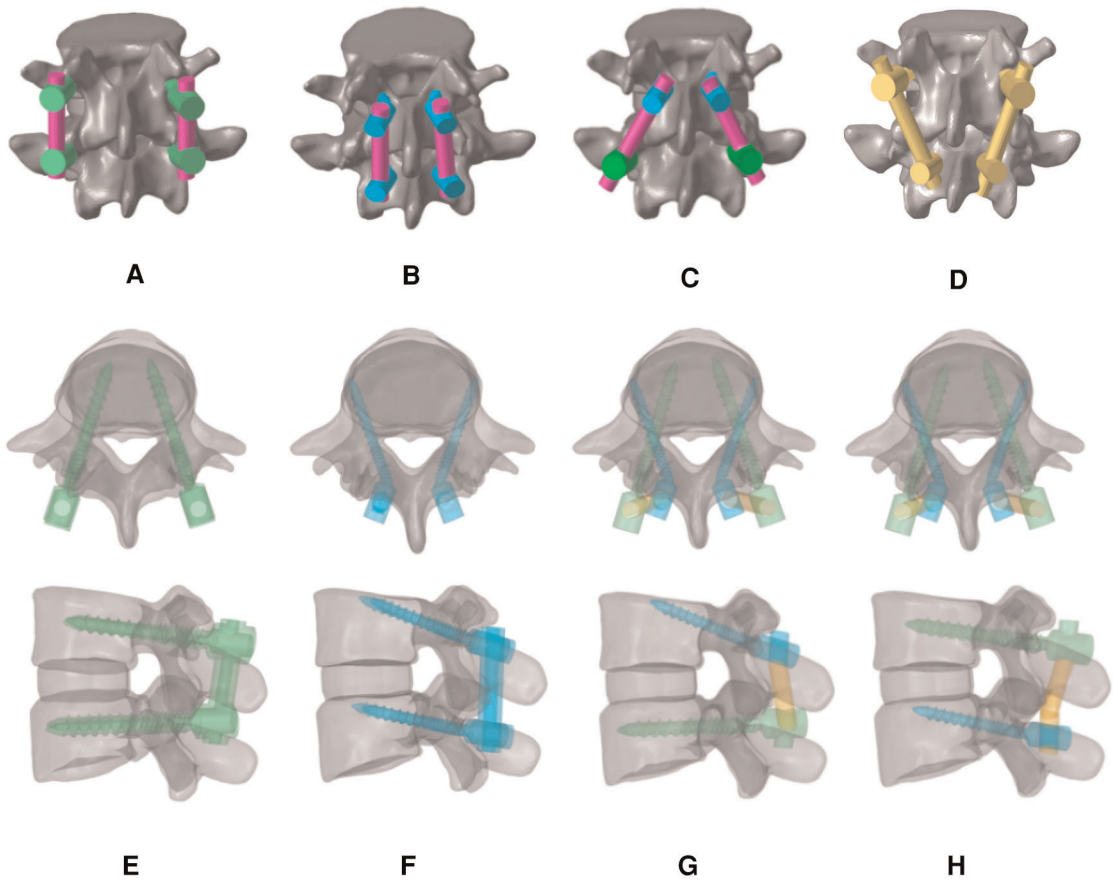

FIGURE 2
FE models of the lumbar vertebra and diagrams from the axial and sagittal views: (A) TT screws at the cranial and caudal levels (TT-TT) (19), (B) MCBT screws at the cranial and caudal levels (MCBT-MCBT), (C) MCBT screws at the cranial level and TT screws at the caudal level (MCBT-TT), (D) TT screws at the cranial level and MCBT screws at the caudal level (TT-MCBT), and (E(19)–H) were the axial and sagittal views of each respective technique of (A–D).

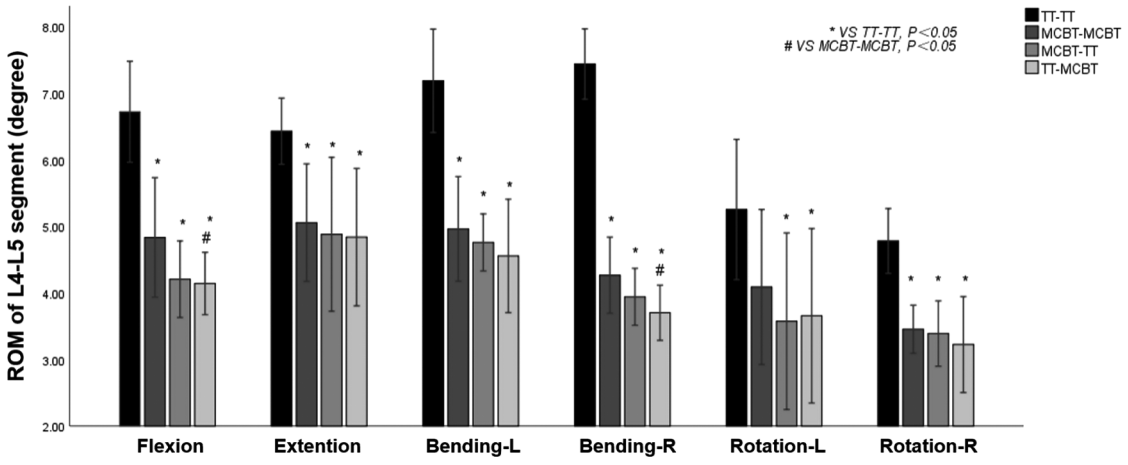

FIGURE 3
Mean values and minimum–maximum ranges of the ROMs of the fixation segment in four fixation models.

left-right bending, and left-right rotation, respectively. The TT-MCBT group reduced by 38%, 25%, 37%, 50%, 30%, and 33% in all working conditions, respectively. Compared to the MCBT-MCBT group, the TT-MCBT reduced by 14% and 13% in flexion and right lateral bending, respectively.

ROM of the posterior fixation

Compared to the TT-TT group, the MCBT-TT, and the TT-MCBT group showed significantly lower ROM in all working conditions ($p < 0.001$). Compared to the MCBT-MCBT group, the MCBT-TT group showed significantly lower ROM only in flexion and right rotation conditions ($p \leq 0.021$). There was no significant difference between the MCBT-TT and TT-MCBT groups in all working conditions ($p > 0.05$). Among the four posterior fixation models, the TT-TT group showed the largest ROM ($2.38° \pm 0.22°$) and the TT-MCBT group showed the lowest ROM ($0.46° \pm 0.07°$) (Figure 4). Compared to the TT-TT group, MCBT-TT group reduced by 55%, 51%, 33%, 36%, 51%, and 39% in flexion, extension, left-right lateral bending, and left-right rotation, respectively. The TT-MCBT group was reduced by 55%, 49%, 29%, 36%, 49%, and 42% in all conditions, respectively. Compared to the MCBT-MCBT group, MCBT-TT was reduced by 13% and 2% in flexion and right rotation, respectively. The TT-MCBT was reduced by 15% and 7% in flexion and right rotation, respectively.

Von Mises stress of the intervertebral disc

Compared to the TT-TT group, the MCBT-MCBT, MCBT-TT, and TT-MCBT groups showed significantly lower disc stress ($p < 0.001$). Compared to the MCBT-MCBT group, the MCBT-TT group was significantly reduced in flexion, extension, and rotation ($p < 0.006$), and there was no significant difference in lateral bending ($p > 0.05$). There was no significant difference between the MCBT-TT and TT-MCBT groups ($p > 0.05$). Compared to the TT-TT group, MCBT-MCBT group was reduced by 47%, 42%, 34%, 37%, 37%, and 33% in flexion, extension, left-right lateral bending, and left-right rotation, respectively. These were 64%, 54%, 42%, 46%, 53%, and 55% in the MCBT-TT group, and 64%, 53%, 43%, 45%, 52%, and 50% in the TT-MCBT group. Compared to the MCBT-MCBT group, MCBT-TT group was reduced by 32%, 21%, 26%, and 32% in flexion, extension, left rotation, and right rotation, respectively. These were 32%, 19%, 24%, and 25%, respectively in the same working conditions, in the TT-MCBT group (Figure 5).

Von Mises stress of the posterior fixation

The MCBT-TT and TT-MCBT groups showed superior load-sharing ability, and the von Mises stress of the posterior fixations were lower than that of the TT-TT and MCBT-MCBT groups (Figure 6). Compared to the TT-TT group, the posterior fixation stress was significantly lower in the MCBT-MCBT group in flexion, extension, left lateral bending, and left rotation conditions ($p < 0.021$), and significantly lower in the MCBT-TT and TT-MCBT groups in all conditions ($p < 0.041$). There was no significant difference between the MCBT-TT and MCBT-MCBT groups ($p > 0.05$). Compared to the TT-TT group, MCBT-MCBT group was reduced by 45%, 37%, 36%, and 44% in flexion, extension, left lateral bending, and left rotation, respectively. In the MCBT-TT group, the

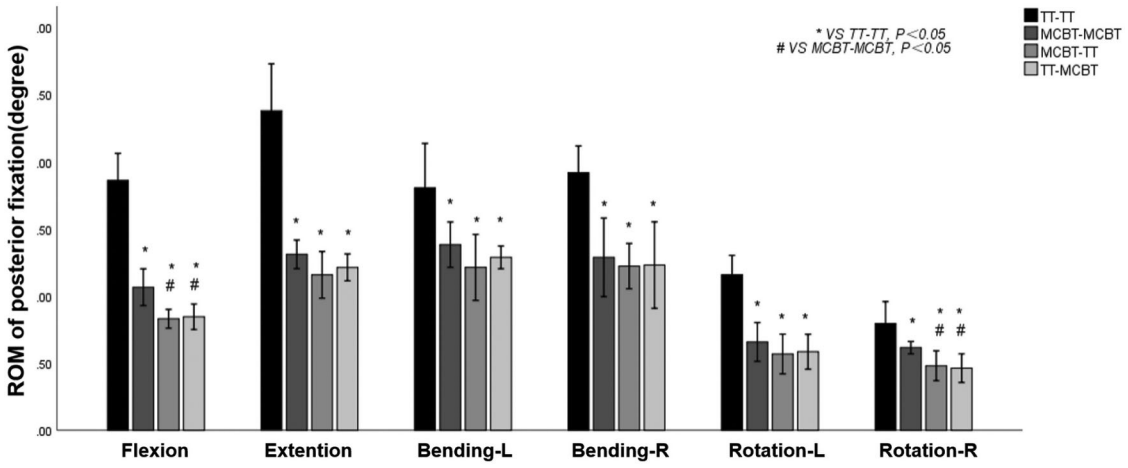

FIGURE 4
Mean values and minimum–maximum ranges of the ROMs of posterior fixations in four fixation models.

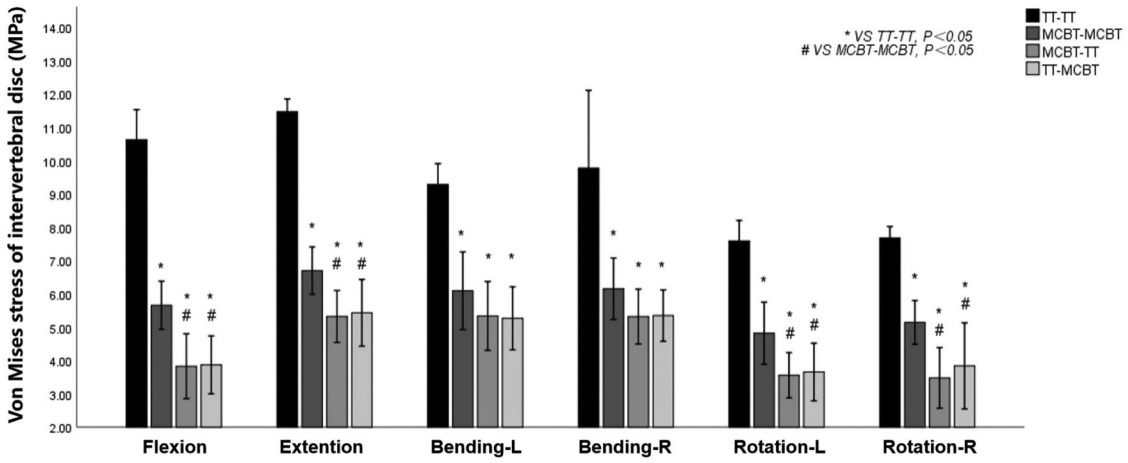

FIGURE 5
Mean values and minimum–maximum ranges of disc stresses at the fixation segment in four fixation models.

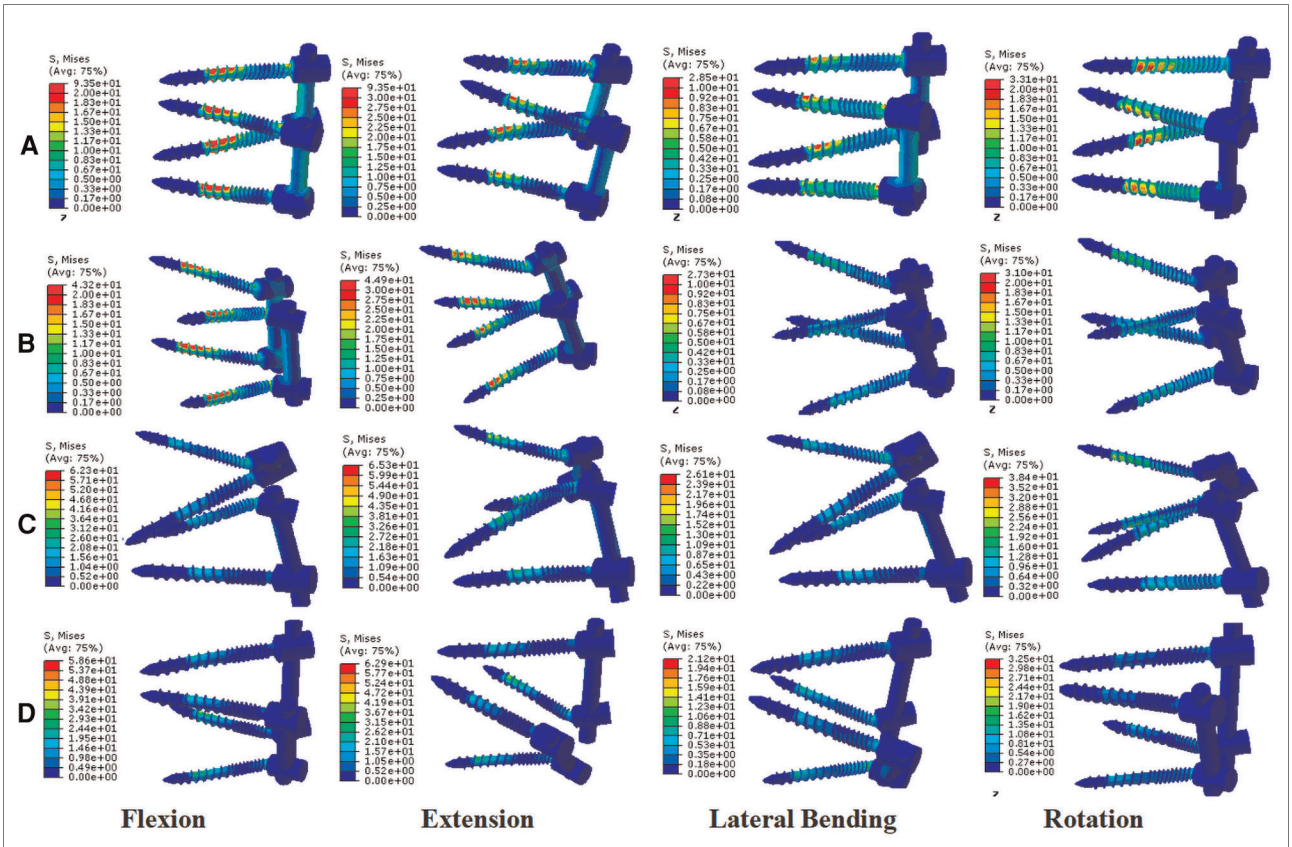

FIGURE 6
Stress nephograms over the posterior fixations of four different fixation models: (A) the TT-TT group, (B) the MCBT-MCBT group, (C) the MCBT-TT group, and (D) the TT-MCBT group.

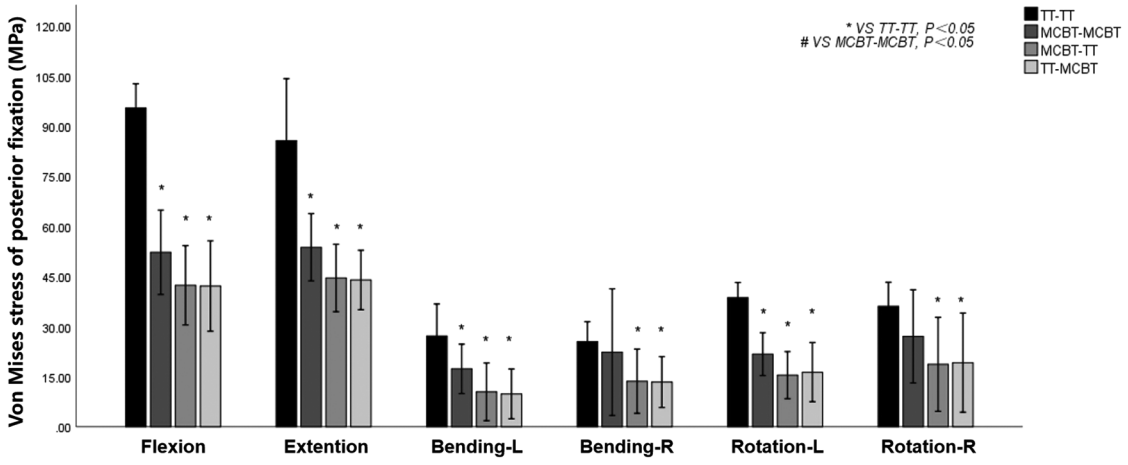

FIGURE 7
Mean values and minimum–maximum ranges of the posterior fixation stress in four fixation models.

posterior fixation stress was reduced by 56%, 48%, 62%, 47%, 60%, and 48% in flexion, extension, left-right lateral bending, and left-right rotation, and 56%, 49%, 64%, 48%, 58%, and 47% in the TT-MCBT group, respectively (**Figure 7**).

Discussion

The MCBT technique was previously proposed by our team (12, 13), aiming to make full use of the cortical bone, especially the medial wall of the pedicle and the lateral cortical bone of the superior endplate of the vertebral body. Reviewing the anatomy of the lumbar spine, the thickness of the bony cortex around the pedicle varies as follows: inferior wall > superior wall > medial wall > lateral wall (21). Fujiwara et al. (22) demonstrated that insertional torque increases with the increase of the medio-lateral angle and decrease of the distance from the anterior lateral edge of the upper endplate of the vertebral body. The screw insertion point of the MCBT technique moved 2.0–3.0 mm inward based on CBT, increased the bony cortex around the screw insertion point and medial wall of the pedicle and the anterior lateral edge of the upper endplate of the vertebral body by increasing the medio-lateral angle from 10° and decreasing the cranio-caudal angle from 25° according to the CBT technique, and it further increased the insertional torque (12, 13, 22). Petrone et al. (14) reached the superior anterior third of the vertebral endplate by decreasing the both cranio-caudal and medio-lateral angle of the screw to improve the biomechanical properties. Edwards et al. (23) demonstrated that cortical bone of the endplate in the marginal zone was thicker. Apparently, the holding force of the screw increases with the content of the thicker cortical bone around the screw. If the entry point moves inward, it can get the effect of contacting the medial wall of the pedicle, extending the screw length, and reaching the anterior lateral edge of the upper endplate of the vertebral body. In a nutshell, whether to increase or decrease the medio-lateral angle of the screw need further investigation with larger sample size. MCBT technique compensated the defects of the CBT technique. However, we found that the MCBT technique still has certain defects. Complete decompression of the recess was not possible with MCBT screw fixation, because extended decompression may destroy the insertion point of the MCBT screw. Isthmic fracture was also a contraindication to the MCBT technique. In summary, we proposed the hybrid screw insertion technique of MCBT-TT and TT-MCBT to compensate the defects of CBT or MCBT techniques. In a nutshell, this study confirms the *triangle stable effect* (24, 25) once again that stability of the hybrid MCBT-TT and TT-MCBT techniques is superior to the counterparts which had higher parallelogram-effect (**Figures 2G,H**).

Santoni et al. (8) and Matsukawa et al. (26) demonstrated with *in vitro* experiment that CBT screw has a higher purchase compared to the pedicle screw. However, Baluch et al. (27), demonstrated that there was no significant difference in the pullout strength. The differences in experimental results may be due to the deviation of the insertion point and angle, which causes the bias. The destruction of the screw trajectory causes an inability to insert the screw twice in a cadaveric study. However, FE analysis can replicate the model, and with the premise of 3D reconstruction of the lumbar spine, complete, accurate, and idealized screw insertion can be performed, which ensures the accuracy and reproducibility of the experiment and avoids the interference of confounding factors on the experimental results.

Matsukawa et al. (26) demonstrated that, compared to the TT-TT group, the CBT-CBT group showed superior vertebral stability in flexion and extension, while inferior in lateral bending. In the present study, compared to the TT-TT group, the ROM of the fixation segment in the MCBT-TT group was significantly reduced in all working conditions (**Figure 3**) ($p \leq 0.012$). This difference may be due to the length of the MCBT screw ($L = 40$ mm), the head and hub of the MCBT screw were in the cortical bone area while the CBT screw hub was in the cortical bone, but the head is not. McLachlin et al. (28) proposed the *teeter-totter* mechanism, that is, the increase in the ROM of the screw caused by the swing of the screw head while the screw hub was fixed. However, both head and hub of the MCBT screw were in the cortical bone, it was not prone to swing. There was no significant difference between the MCBT-TT group and the TT-MCBT group ($p > 0.05$). In patients with osteoporosis, the purchase of the screw was not strong because of the reduced bone mineral density in cancellous bone (29), which led to the occurrence of the *teeter-totter* phenomenon. However, the *teeter-totter* phenomenon was not easy to occur when the head of the MCBT screw reaches the cortical bone at the lateral cortical bone of the superior endplate. Matsukawa et al. (30) demonstrated that the screw with greater length improves the fixation strength in rotation. The length of pedicle screw used in this study was 45 mm and the MCBT screw ($L = 40$ mm), while the pedicle screw diameter ($D = 6.0$ mm) was thicker than the MCBT screw ($D = 4.5$ mm). Although the length of the two screws were similar, but the ROM of the posterior fixations were different because the bony environment at the head and hub of the two screws were different. These results indicated that screw thickness or length was not an independent factor determining the stability of the fixation, which was consistent with the results of McLachlin et al. (28). In the TT-TT group, the intervertebral disc stress was more concentrated and higher, with the greatest stress in extension (11.47 ± 0.24 Mpa). In the MCBT-TT group, the intervertebral disc stress was more dispersed and lower, with the least stress in rotation (3.48 ± 0.57 Mpa). Rastegar et al. (31) demonstrated that cage subsidence was one of the risk factors for failure of lumbar interbody fusion. With the increase of cage stress, subsidence rate increased gradually (18). However, the lumbar fusion was not performed in this study, but it can be deduced from the intervertebral disc stress that lumbar interbody fusion combined with hybrid fixation techniques may reduce the cage stress and occurrence of cage subsidence increasing the bone fusion rate after lumbar fusion surgery. Von Mises stress of the pedicle screw in the TT-TT group evenly dispersed between the central cancellous bone area and screw hub, and the stress value was higher but evenly dispersed (**Figure 6**), which was consistent with the previous study of Chen et al. (32). Von Mises stress of the pedicle screw was significantly reduced in the MCBT-TT and the TT-MCBT groups. The stress of the pedicle screw in the TT-TT group was the largest in flexion condition (95.45 ± 4.55 Mpa), which was significantly reduced in the MCBT-TT group (42.35 ± 7.46 Mpa) and the TT-MCBT group (42.13 ± 8.50 Mpa) ($p < 0.05$), both of them were reduced by 56%. This result was consistent with the results of Ren et al. (33). Hybrid techniques have a superior stress dispersion effect, which may reduce the risk of fixation failure. Wang et al. (34) simulated the thoracolumbar FE model and demonstrated that the von Mises stress of the CBT-TT group was higher in lateral bending but lower in the other conditions compared to the TT-TT group during cross-stage fixation. In the present study, the von Mises stress of the MCBT-TT group was lower in lateral bending compared to the TT-TT group, although the diameter of the CBT screw ($D = 5.0$ mm, $L = 35$ mm) in the study of Wang et al. (34) was thicker than the MCBT screw ($D = 4.5$ mm, $L = 40$ mm) used in this study, but the length was shorter than the MCBT screw. The possible reason for this difference was that the contact of the screw head with the anterior lateral edge of the upper endplate of the vertebral body, the increase in screw length improved the stability of the vertebral body, which was consistent with the results of Matsukawa et al. (10).

Polly et al. (35) demonstrated that torque was reduced by 34% when the pedicle screw was re-placing after it was pulled out. Increasing the screw length and diameter when re-placing the screw improved the fixation strength, when screw diameter increases by 1 mm and the screw length increases by 5–10 mm, the fixation strength of the re-placed screw was similar to that of the original screw, but there was a risk of pedicle burst. Matsukawa et al. (30) demonstrated that pedicle screw with a larger diameter and longer length significantly improved the pullout strength, and the screw head reached the anterior lateral edge of the upper endplate of the vertebral body of the vertebral body to form a structure similar to bi-cortical fixation. The MCBT screw used in the present study had a smaller diameter ($D = 4.5$ mm), MCBT screw with a larger diameter may further increase the stability of hybrid fixation. Pedicle screw damages the facet joints inevitably, resulting in reduced vertebral stability and adjacent segment degeneration (ASD) (36), MCBT screw can avoid this problem. Masaki et al. (37) and Rodriguez et al. (38) demonstrated that CBT screw can be used cranially when ASD occurs at the proximal level and the fusion stage needed to be extended after lumbar surgery with the pedicle screw. The results of the present study were consistent with the above results. If a revision surgery was required for postoperative ASD, the MCBT screw can be an alternative for the pedicle screw. The non-parallel trajectory of pedicle screws in the same vertebral body had the *triangle stable effect* (24, 25), which increases the stability of posterior fixation. The results of the present study demonstrated that the stability of the hybrid MCBT-TT and the TT-MCBT techniques were superior to that

of the TT-TT and the MCBT-MCBT techniques with the contribution of the *triangle stable effect* (24, 25).

As with any FE analysis, certain limitations were inherent in the present study. First, there was a lack of an adjacent segment that provides an indispensable role in evaluating the relationship between hybrid techniques and ASD. Second, the limited number of specimens was insufficient to allow more convincing conclusions. Third, there was only one size of TT and MCBT screws, thus the biomechanical effects of various screw diameters and lengths in the hybrid techniques have not been considered extensively in the present study. The present study did not standardize the sizes of the MCBT and the TT screws in the hybrid techniques.

Conclusion

This study reflects the biomechanical properties of the hybrid MCBT-TT and TT-MCBT techniques. The stability of the hybrid MCBT-TT and the TT-MCBT techniques were superior to that of TT-TT and MCBT-MCBT techniques, providing a preliminary biomechanical theoretical basis for the application of hybrid lumbar fixation techniques in patients with osteoporosis. However, the present study did not analyzed the effects of the hybrid techniques on the adjacent segment. The authors concluded that the hybrid MCBT-TT and the TT-MCBT techniques can be the optimal choices for lumbar posterior fixation in patients with osteoporosis.

Data availability statement

The raw data supporting the conclusions of this article will be made available by the authors, without undue reservation.

Ethics statement

The study design was approved by the Ethics Committee of Xinjiang Medical University before data collection and analysis (Approval No.20210401-01). All methods were carried out in accordance with relevant guidelines and regulations.

Author contributions

AK and XM were responsible for conceptualization, methodology, and writing - original draft. JM, SW, WS, and NA were responsible for data curation, software, and validation. ZZ, DL, and AM were responsible for visualization. PR was responsible for conceptualization, writing - reviewing, editing, and supervision. All authors contributed to the article and approved the submitted version.

Funding

This study was supported by Natural Science Foundation of Xinjiang Uygur Autonomous Region, Science Foundation for Distinguished Young Scholars (Grant No. 2021D01E29).

Acknowledgments

The authors thank Department of Anatomy, College of Basic Medicine, Xinjiang Medical University for providing the human cadaveric specimen.

Conflict of interest

The authors declare that the research was conducted in the absence of any commercial or financial relationships that could be construed as a potential conflict of interest.

Publisher's note

All claims expressed in this article are solely those of the authors and do not necessarily represent those of their affiliated organizations, or those of the publisher, the editors and the reviewers. Any product that may be evaluated in this article, or claim that may be made by its manufacturer, is not guaranteed or endorsed by the publisher.

References

1. Roy-Camille R, Saillant G, Mazel C. Plating of thoracic, thoracolumbar, and lumbar injuries with pedicle screw plates. *Orthop Clin North Am.* (1986) 17:147–59. doi: 10.1016/S0030-5898(20)30425-9

2. Wittenberg RH, Shea M, Swartz DE, Lee KS, White AA, Hayes WC. Importance of bone mineral density in instrumented spine fusions. *Spine (Phila Pa 1976).* (1991) 16:647–52. doi: 10.1097/00007632-199106000-00009

3. Rosinski AA, Mittal A, Odeh K, Ungurean V. Alternatives to traditional pedicle screws for posterior fixation of the degenerative lumbar spine. *JBJS Rev.* (2021) 9:10. doi: 10.2106/JBJS.RVW.20.00177

4. Sugisaki K, An HS, Espinoza Orias AA, Rhim R, Andersson GBJ, Ne I. In vivo three-dimensional morphometric analysis of the lumbar pedicle isthmus. *Spine (Phila Pa 1976).* (2009) 34:2599–604. doi: 10.1097/BRS.0b013e3181b52a37

5. Di Silvestre M, Parisini P, Lolli F, Bakaloudis G. Complications of thoracic pedicle screws in scoliosis treatment. *Spine (Phila Pa 1976)*. (2007) 32:1655–61. doi: 10.1097/BRS.0b013e318074d604

6. Becker S, Chavanne A, Spitaler R, Kropik K, Aigner N, Ogon M, et al. Assessment of different screw augmentation techniques and screw designs in osteoporotic spines. *Eur Spine J*. (2008) 17:1462–9. doi: 10.1007/s00586-008-0769-8

7. Ponnusamy KE, Iyer S, Gupta G, Khanna AJ. Fixation of the osteoporotic spine: biomechanical and clinical considerations. *Spine J*. (2011) 11:54–63. doi: 10.1016/j.spinee.2010.09.024

8. Santoni BG, Hynes RA, McGilvray KC, Rodriguez-Canessa G, Lyons AS, Henson MA, et al. Cortical bone trajectory for lumbar pedicle screws. *Spine J*. (2009) 9:366–73. doi: 10.1016/j.spinee.2008.07.008

9. Matsukawa K, Yato Y, Imabayashi H, Hosogane N, Asazuma T, Nemoto K. Biomechanical evaluation of the fixation strength of lumbar pedicle screws using cortical bone trajectory: a finite element study. *J Neurosurg Spine*. (2015) 23:471–8. doi: 10.3171/2015.1.SPINE141103

10. Matsukawa K, Yato Y, Nemoto O, Imabayashi H, Asazuma T, Nemoto KL. Morphometric measurement of cortical bone trajectory for lumbar pedicle screw insertion using computed tomography. *J Spinal Disord Tech*. (2013) 26:E248–53. doi: 10.1097/BSD.0b013e318288ac39

11. Matsukawa K, Yato Y, Hynes RA, Imabayashi H, Hosogane N, Asazuma T, et al. Cortical bone trajectory for thoracic pedicle screws: a technical note. *Clin Spine Surg*. (2017) 30:E497–504. doi: 10.1097/BSD.0000000000000130

12. Rexiti P, Abudurexiti T, Abuduwali N, Wang S, Sheng W. Measurement of lumbar isthmus parameters for novel starting points for cortical bone trajectory screws using computed radiography. *Am J Transl Res*. (2018) 10:2413–23. PMID: 30210680; PMCID: PMC6129534

13. Rexiti P, Aierken G, Wang S, Abudurexiti T, Abuduwali N, Deng Q, et al. Anatomical research on strength of screw track fixation in novel cortical bone trajectory for osteoporosis lumbar spine. *Am J Transl Res*. (2019) 11:6850–9. PMID: 31814892; PMCID: PMC6895526

14. Petrone S, Marengo N, Ajello M, Lavorato A, Penner F, Cofano F, et al. Cortical bone trajectory technique's outcomes and procedures for posterior lumbar fusion: a retrospective study. *J Clin Neurosci*. (2020) 76:25–30. doi: 10.1016/j.jocn.2020.04.070

15. Penner F, Marengo N, Ajello M, Petrone S, Cofano F, Veneziani Santonio F, et al. Preoperative 3D CT planning for cortical bone trajectory screws: a retrospective radiological cohort study. *World Neurosurg*. (2019) 126:e1468–74. doi: 10.1016/j.wneu.2019.03.121

16. Marengo N, Matsukawa K, Monticelli M, Ajello M, Pacca P, Cofano F, et al. Cortical bone trajectory screw placement accuracy with a patient-matched 3-dimensional printed guide in lumbar spinal surgery: a clinical study. *World Neurosurg*. (2019) 130:e98–104. doi: 10.1016/j.wneu.2019.05.241

17. Calvert GC, Lawrence BD, Abtahi AM, Bachus KN, Brodke DS. Cortical screws used to rescue failed lumbar pedicle screw construct: a biomechanical analysis. *J Neurosurg Spine*. (2015) 22:166–72. doi: 10.3171/2014.10.SPINE14371

18. Guo HZ, Tang YC, Guo DQ, Liang D, Zhang SC. Biomechanical evaluation of four different posterior instrumentation techniques for single-level transforaminal lumbar interbody fusion: a finite element analysis. *Am J Transl Res*. (2020) 12:6160–9. PMID: 33194021; PMCID: PMC7653581

19. Kahaer A, Zhou Z, Maitirouzi J, Wang S, Shi W, Abuduwaili N, et al. Biomechanical investigation of the posterior pedicle screw fixation system at level L4–L5 lumbar segment with traditional and cortical trajectories: a finite element study. *J Healthc Eng*. (2022) 8:1–11. doi: 10.1155/2022/4826507

20. Wang K, Jiang C, Wang L, Wang H, Niu W. The biomechanical influence of anterior vertebral body osteophytes on the lumbar spine: a finite element study. *Spine J*. (2018) 18:2288–96. doi: 10.1016/j.spinee.2018.07.001

21. Li B, Jiang B, Fu Z, Zhang D, Wang T. Accurate determination of isthmus of lumbar pedicle: a morphometric study using reformatted computed tomographic images. *Spine (Phila Pa 1976)*. (2004) 29:2438–44. doi: 10.1097/01.brs.0000144355.50660.65

22. Fujiwara S, Ohnishi Y, Iwatsuki K, Kishima H. Cortical bone trajectory fixation cause low compression force in anterior vertebral column. *N Am Spine Soc J*. (2022) 10:100113. doi: 10.1016/j.xnsj.2022.100113

23. Edwards WT, Zheng Y, Ferrara LA, Yuan HA. Structural features and thickness of the vertebral cortex in the thoracolumbar spine. *Spine (Phila Pa 1976)*. (2001) 26:218–25. doi: 10.1097/00007632-200101150-00019

24. Ruland CM, McAfee PC, Warden KE, Cunningham BW. Triangulation of pedicular instrumentation. A biomechanical analysis. *Spine (Phila Pa 1976)*. (1991) 16:S270–6. doi: 10.1097/00007632-199106001-00019

25. Barber JW, Boden SD, Ganey T, Hutton WC. Biomechanical study of lumbar pedicle screws: does convergence affect axial pullout strength? *J Spinal Disord*. (1998) 11:215–20. doi: 10.1097/00002517-199806000-00007

26. Matsukawa K, Yato Y, Kato T, Imabayashi H, Asazuma T, Kl N. In vivo analysis of insertional torque during pedicle screwing using cortical bone trajectory technique. *Spine (Phila Pa 1976)*. (2014) 39:E240–5. doi: 10.1097/BRS.0000000000000116

27. Baluch DA, Patel AA, Lullo B, Havey RM, Voronov LI, Nguyen NL, et al. Effect of physiologic loads on cortical and traditional pedicle screw fixation. *Spine (Phila Pa 1976)*. (2014) 39:1297–302. doi: 10.1097/BRS.000000000 0000553

28. McLachlin SD, Beaton BJ, Sabo MT, Gurr KR, Bailey SI, Bailey CS, et al. Comparing the fixation of a novel hollow screw versus a conventional solid screw in human sacra under cyclic loading. *Spine (Phila Pa 1976)*. (2008) 33:1870–5. doi: 10.1097/BRS.0b013e3181808c75

29. Compston JE, Mcclung MR, Leslie WD. Osteoporosis. *Lancet*. (2019) 393:364–76. doi: 10.1201/9781003039235-33

30. Matsukawa K, Yato Y, Imabayashi H. Impact of screw diameter and length on pedicle screw fixation strength in osteoporotic vertebrae: a finite element analysis. *Asian Spine J*. (2021) 15:566–74. doi: 10.31616/asj.2020.0353

31. Rastegar S, Arnoux PJ, Wang X, Aubin CÉ. Biomechanical analysis of segmental lumbar lordosis and risk of cage subsidence with different cage heights and alternative placements in transforaminal lumbar interbody fusion. *Comput Methods Biomech Biomed Eng*. (2020) 23:456–66. doi: 10.1080/10255842.2020.1737027

32. Chen CS, Chen WJ, Cheng CK, Jao E, Chueh SC, Wang CC. Failure analysis of broken pedicle screws on spinal fixation. *Med Eng Phys*. (2005) 27:487–96. doi: 10.1016/j.medengphy.2004.12.007

33. Ren H, Maitirouzi J, Rexiti P, Luo H. Finite element analysis of lumbar vertebrae under the pull-out strength of screw in cortical bone trajectory technique. *Chin J Tissue Eng Res*. (2021) 25:5771–6. doi: 10.12307/2021.340

34. Wang TN, Wu BL, Duan RM, Yuan YS, Qu MJ, Zhang S, et al. Treatment of thoracolumbar fractures through different short segment pedicle screw fixation techniques: a finite element analysis. *Orthop Surg*. (2020) 12:601–8. doi: 10.1111/os.12643

35. Polly Jr DW, Orchowkis JR, Ellenbogen RG. Revision pedicle screws. Bigger, longer shims—what is best? *Spine (Phila Pa 1976)*. (1998) 23:1374–9. doi: 10.1097/00007632-199806150-00015

36. Kim HJ, Chun HJ, Lee HM, Kang KT, Lee CK, Chang BS, et al. The biomechanical influence of the facet joint orientation and the facet tropism in the lumbar spine. *Spine J*. (2013) 13:1301–8. doi: 10.1016/j.spinee.2013.06.025

37. Ueno M, Imura T, Inoue G, Takaso M. Posterior corrective fusion using a double-trajectory technique (cortical bone trajectory combined with traditional trajectory) for degenerative lumbar scoliosis with osteoporosis: technical note. *J Neurosurg Spine*. (2013) 19:600–7. doi: 10.3171/2013.7.SPINE13191

38. Rodriguez A, Neal MT, Liu A, Somasundaram A, Hsu W, Branch Jr CL. Novel placement of cortical bone trajectory serews in previously instrumented pedicles for adjacent-segment lumbar disease using CT image-guided navigation. *Neurosurg Focus*. (2014) 36:E9. doi: 10.3171/2014.1.FOCUS13521

frontiers | Frontiers in Surgery

TYPE Original Research
PUBLISHED 29 July 2022
DOI 10.3389/fsurg.2022.926329

Check for updates

OPEN ACCESS

EDITED BY
Paphon Sa-ngasoongsong,
Mahidol University, Thailand

REVIEWED BY
Gabriel Tender,
Louisiana State University, United States
Chen Kangwu,
The First Affiliated Hospital of Soochow University, China

*CORRESPONDENCE
Xiao-feng Liu
1720548593@qq.com

†These authors have contributed equally to this work

SPECIALTY SECTION
This article was submitted to Orthopedic Surgery, a section of the journal Frontiers in Surgery

RECEIVED 22 April 2022
ACCEPTED 12 July 2022
PUBLISHED 29 July 2022

CITATION
Peng Y-j, Zhao T-b, Dai J, Wang Q-l, Zhang Qian-zhong-yi, Cao J-y and Liu X-f (2022) Clinical comparison of three-dimensional exoscope vs. operative microscope in transforaminal lumbar interbody fusion: A retrospective case-control study. Front. Surg. 9:926329. doi: 10.3389/fsurg.2022.926329

COPYRIGHT
© 2022 Peng, Zhao, Dai, Wang, Zhang, Cao and Liu. This is an open-access article distributed under the terms of the Creative Commons Attribution License (CC BY). The use, distribution or reproduction in other forums is permitted, provided the original author(s) and the copyright owner(s) are credited and that the original publication in this journal is cited, in accordance with accepted academic practice. No use, distribution or reproduction is permitted which does not comply with these terms.

Clinical comparison of three-dimensional exoscope vs. operative microscope in transforaminal lumbar interbody fusion: A retrospective case-control study

Yu-jian Peng[1†], Tian-bu Zhao[2†], Jun Dai[1], Qian-liang Wang[1], Qian-zhong-yi Zhang[1], Jun-yin Cao[1] and Xiao-feng Liu[1*]

[1]Department of Orthopedic Surgery, The Second Affiliated Hospital of Soochow University, Suzhou, China, [2]Department of Emergency Surgery, The Second Affiliated Hospital of Soochow University, Suzhou, China

Purpose: Here, we sought to determine the safety and feasibility of three-dimensional exoscope (3D EX). We compared data on surgery, complications, postoperative drainage, hematology, and clinical outcomes in the group that underwent transforaminal lumbar interbody fusion (TLIF) using an operative microscope (OM) relative to those treated using 3D EX.
Methods: We retrospectively reviewed records on 74 patients who underwent one- or two-level TLIF from August 2019 to October 2020. Repeated measures analysis of variance was used to compare pre- and post-operative visual analogue scale (VAS) scores and oswestry disability index (ODI). We used analysis of covariance to compare pre- and post-operative erythrocyte count (RBC), hemoglobin (Hb), and hematocrit (Hct). Independent sample t-tests was used to compare postoperative drainage volume, total blood loss (TBL), visible blood loss (VBL) and hidden blood loss (HBL).
Results: There were no significant differences in VAS and ODI scores between the two groups at all time points (all $p > 0.05$). RBC and HBL did not differ significantly between the two groups (all $p > 0.05$). There were significant differences in postoperative drainage volume,TBL, Hb, and Hct values when using 3D EX relative to OM in two-level TLIF (all $p < 0.05$), but not for one-level TLIF (all $p > 0.05$). The two groups differed significantly with regards to VBL when used for one- or two-level TLIF (all $p < 0.05$).
Conclusion: Our data show that 3D EX is a suitable alternative to OM in TLIF. Relative to OM, 3D EX has important strengths in reducing perioperative bleeding in two-level TLIF.

KEYWORDS

three-dimensional exoscope, transforaminal lumbar interbody fusion (TILF), hidden blood loss (HBL), case-control study, interverbal disc degeneration

Introduction

Intervertebral disc degeneration (IDD), a major cause of degenerative spinal disease, severely affects quality of life in elderly populations. Globally, about 266 million people develop degenerative spine disease annually, which poses significant socioeconomic burden in developed countries (1, 2). Spinal fusion is the standard treatment for painful IDD after failed conservative treatment (3). Transforaminal lumbar interbody fusion (TLIF) is currently the main surgical procedure for IDD treatment (4). The introduction of the operative microscope (OM) as a visualization tool for TLIF procedures represented significant advancement. OM allows clear, magnified visualization of anatomical structures, thereby avoiding injury to nerves and blood vessels. With a focal length of 200–415 mm, OM provides space for microsurgical instruments to be placed in the operating space.

Despite its advantages, OM has drawbacks, including a lack of ergonomic design and extreme microscope positional angles needed for successful decompression, especially the contralateral aspect. These compromise the surgeons' neutral posture, forcing them into a non-ergonomic posture (5). This is even worse for assistants who must adapt to the microscope height set by the operator. The exoscope attempts to overcome the limitations of OM. However, it is reported that compared with OM, hand-eye coordination is clearly affected in the traditional two-dimensional exoscope (2D EX) due to limited depth perception (6).

To overcome the shortcomings of OM and 2D EX, a three-dimensional exoscope (3D EX) has been developed. Several 3D EX systems are currently available for neurosurgery, including the VITOM® 3D (Karl Storz SE & Co. KG, Tuttlingen, Germany), KINEVO® (Carl Zeiss Meditec AG, Oberkochen, Germany), ModusV™ (Synaptive Medical, Toronto, Canada), and ORBEYE™ (Olympus, Tokyo, Japan) (7). Relative to 3D EX mentioned above, the MITAKA KV II (Mitaka Co, Tokyo, Japan) has greater working distance and higher max magnification. 3D EX produces high-quality images with a field of wide and a focal distance of 300–1,000 mm. The high focal distance offers a larger workspace for spine surgery. Because visualizations are displayed on large digital monitors, independence from the eyepiece allows the surgeon and assistant to work ergonomically without contorting their posture (8, 9). Moreover, the 3D technique overcomes the lack of stereoscopic visualization (10). Past studies have mainly focused on the ergonomic advantage of 3D EX (8, 11, 12). Here, we compared data on surgery, complications, postoperative drainage, hematological parameters, and clinical outcomes in patients who underwent TLIF treatment with OM relative to those treated using 3D EX TLIF. To our knowledge, this is the first study to examine the effect of 3D EX on patients undergoing TLIF.

Materials and methods

Clinical materials

Ethical approval for this retrospective study was granted by the ethics committee of the Second Affiliated Hospital of Soochow University (approval No. JD-HG-2021-13). Patients were eligible if they underwent a one- or two- level TLIF between L1–S1 for a symptomatic lumbar spinal stenosis or lumbar spondylolisthesis, and they had both complete data. Bilateral decompression was performed in all patients. All surgeries were completed by the same senior surgeons in our hospital. The exclusion criteria were as follows: (1) previous lumbar surgery、infections and tumors (2) antiplatelet or anticoagulant drugs (3) hematological malignancies, bleeding disorders, chronic liver disease. (4) unilateral decompression. (5) patients with missing data. Finally, 74 patients were enrolled in the study. Two groups were formed according to the type of microscope. 3D EX group consisted of 32 patients and OM group consisted of 42 patients.

Exoscope equipment and operating room set-up

The 3D EX (MITAKA KV II, Mitaka Co,Tokyo, Japan) consists of an exoscope, video recorder, light source, and stereoscopic monitor. Compared to a standard OM (S88, ZEISS Inc, Oberkochen, Germany), the 3D EX has longer working distance, wider field of view, and higher magnification. The general parameters of the two different equipment are shown in **Table 1**. The surgeon uses 3D glasses to see the 3D image on the stereoscopic monitor. The 3D video monitor is best when positioned on the opposite side of the operating table, to the right of the assistant. A second monitor, in a similar position just behind and to the right of the surgeon, offers the assistant an identical field of view (**Figure 1**).

Surgical technique

The decompression process in the 3D EX group (from facetectomy to cage placement) were carried out and recorded

TABLE 1 Compare the general parameters of the two different microscopes.

	3D EX (MITAKA KV II)	OM (S88)
Working distance(mm)	300–1000	200–415
Zoom ratio	1:8	1:6
Maximum magnification	×40	×13
Resolution(line pairs)	58	56

3D EX, the three-dimensional exoscope; OM, the operating microscope.



FIGURE 1
Operating room set-up for 3D EX. 1: Surgeon; 2: Assistant; 3: Scrub nurse; 4: 3D EX(MITAKA KV II); 5 and 6: The 3D video monitor.

with the assistance of the EX. Patients were placed in the prone position after general anesthesia. The posterior elements of the spine were exposed to the bases of the transverse processes through a midline longitudinal incision. Pedicle screws were placed into the upper and subjacent vertebral pedicle of the segmental lesions. Facet joint and lamina were exposed (**Figure 2A**). An ultrasonic bone scalpel was used in a unilateral laminectomy and inferior facetectomy (**Figure 2B**). The ligamentum flavum was removed with forceps to expose dural sac and the lateral margin of the ipsilateral nerve root (**Figure 2C**). At this point, the epidural veins required coagulation with bipolar cautery (**Figure 2D**). After good exposure of the intervertebral space (**Figure 2E**), discectomy was performed when a soft herniated disc was identified (**Figure 2F**). After appropriate endplate preparation (**Figure 2G**), a cage was filled with bone chips and inserted into the central part of the disc space (**Figure 2H**). Decompression of the neural structures was verified by a micro-hook (**Figure 2I**). Finally, both rods were mounted under slight compression. In the OM group, microscopic TLIF was performed as described by Harms and Jes-zenszky et al. (13). Surgeries were performed by the same team consisting of three experienced spine surgeons in our hospital.

Outcome measures

Drainage evaluation

Two negative pressure drainage tubes were placed before wound closure. The drain was removed when its output

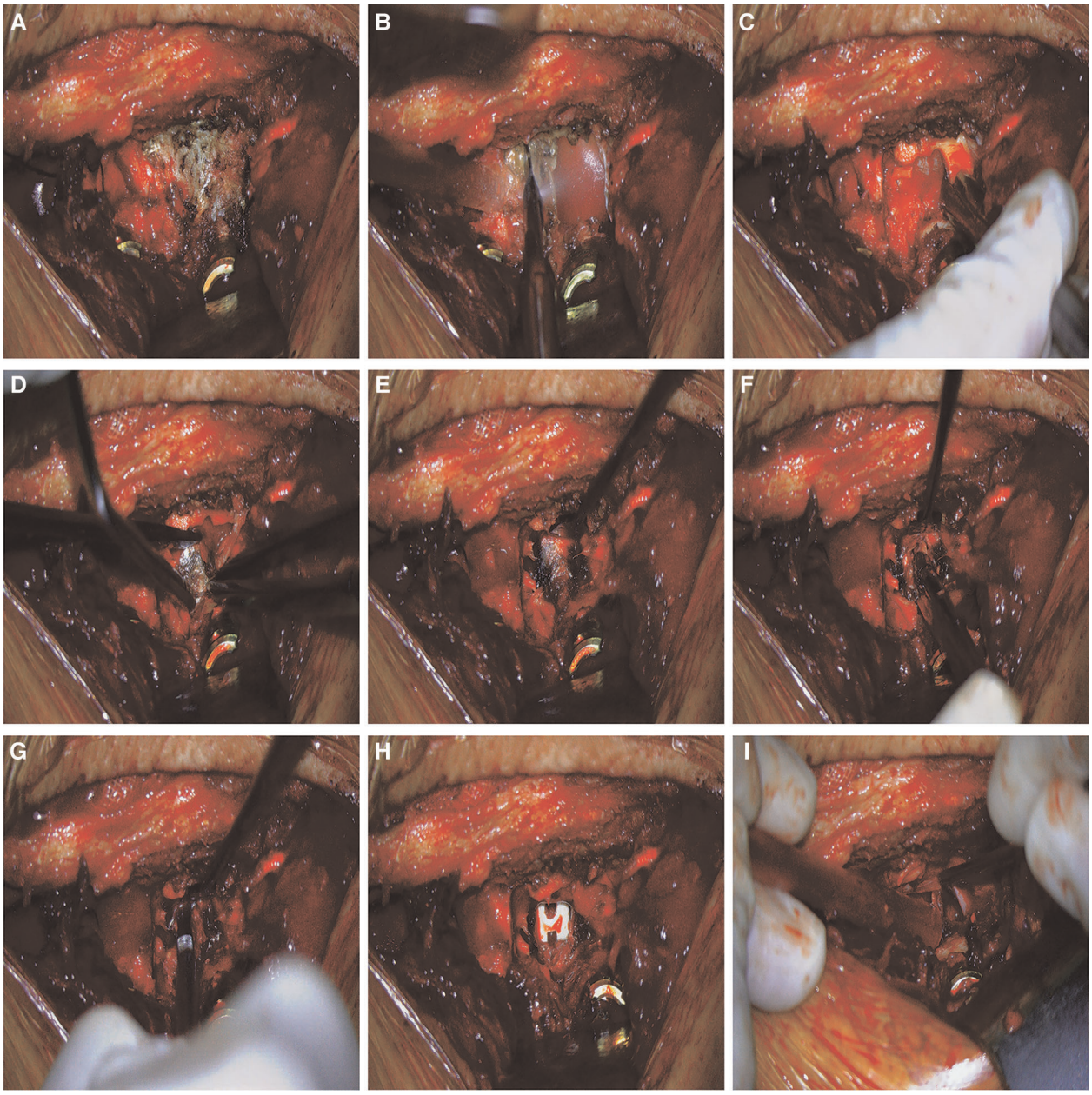

FIGURE 2
Surgical procedures of 3D EX TLIF. (A) Facet joint and lamina were exposed. (B) The ultrasonic bone scalpel was used in a unilateral laminectomy and inferior facetectomy. (C) The ligamentum flavum was removed with forceps to expose dural sac. (D) The epidural veins required coagulation with bipolar cautery. (E) Exposure of the disc space. (F). Discectomy was performed when a soft herniated disc was identified. (G) Endplate preparation. (H) A cage was filled with bone chips and inserted into the central part of the disc space. (I) Decompression of the neural structures was verified by a micro-hook.

reached ≤50 ml in 24 h, irrespective of drainage duration. Drainages were emptied between 6 and 7AM, each working day. Drainage volume was recorded each day after surgery until drainage tube removal and the total drainage volume determined by summing daily volumes. Drainage tube removal time was also recorded.

Perioperative blood loss and hematological evaluation

Preoperative blood routine tests were done within a week before operation. Because 48–72 h were allowed for hemodynamic stabilization, postoperative blood routine tests were done during the recovery period, 2–3 days after surgery.

To calculate total blood loss, we first estimated total blood volume (TBV) using the Nadler formula (14) as follows: TBV = k1 × height (m^3)+k2 × weight (kg)+k3. For men: k1 = 0.3669, k2 = 0.03219, and k3 = 0.6041. For women: k1 = 0.3561, k2 = 0.03308, and k3 = 0.1833. We used total blood loss (TBL) calculated using Gross' formula (15) as follows: TBL = TBV × (Hct_{Preop}-Hct_{Postop})/Hct_{ave} (Hct_{Preop}: hematocrit, Hct, before the operation; Hct_{Postop} = HCT value after operation; Hct_{ave} = average Hct_{Preop} and the Hct_{Postop}). If either reinfusion or allogeneic RBC transfusion was performed, the TBL formula was calculated as follows: TBL = TBV×(Hct_{Preop}−Hct_{Postop})/Hct_{ave} + Blood infusion. Decisions on whether red blood cell (RBC) transfusion was necessary or not were made by surgeons during surgery, or by attending physicians after surgery. Patients with hemoglobin (Hb) levels of <8.0 g/dl or who were symptomatic received postoperative transfusion. Visible blood loss (VBL) was calculated using the formula: VBL = intraoperative blood loss + postoperative drainage. Hidden blood loss was calculated using the formula: HBL = total blood loss - visible blood loss.

TABLE 2 Patient baseline demographic characteristics.

Variables	OM	3D EX	*p*-value
One-level	23	20	
Surgical level			
L2-L3	0 (0.00%)	2 (10.00%)	0.116
L3-L4	0 (0.00%)	2 (10.00%)	
L4-L5	21 (91.30%)	13 (65.00%)	
L5-S1	2 (8.70%)	3 (15.00%)	
Age, year	60.30 ± 9.25	61.30 ± 10.22	0.739
Sex			
Male	8 (34.78%)	10 (50.00%)	0.313
Female	15 (65.22%)	10 (50.00%)	
Height, m	1.62 ± 0.09	1.63 ± 0.08	0.734
Weight, kg	61.50 ± 10.49	65.88 ± 11.64	0.202
BMI, kg/m^2	23.41 ± 2.87	24.72 ± 2.91	0.145
ASA score			
I	9	8	0.749
II	13	10	
III	1	2	
Disease			
Lumbar spinal stenosis	22 (95.65%)	18 (90.00%)	0.590
Lumbar spondylolisthesis	1 (4.35%)	2 (10.00%)	
Two-level	19	12	
Surgical level			
L2-L3, L3-L4	1 (5.26%)	1 (8.33%)	0.764
L3-L4, L4-L5	6 (31.58%)	5 (41.67%)	
L4-L5, L5-S1	12 (63.16%)	6 (50.00%)	
Age, year	61.11 ± 13.04	60.83 ± 6.28	0.947
Sex			
male	10 (52.63%)	7 (58.33%)	1.000
female	9 (47.37%)	5 (41.67%)	
Height, m	165 ± 0.07	1.67 ± 0.10	0.514
Weight, kg	67.16 ± 9.10	72.25 ± 11.24	0.176
BMI	24.52 ± 4.99	25.84 ± 4.24	0.250
ASA score			
I	8	4	0.862
II	10	7	
III	1	1	
Disease			
Lumbar spinal stenosis	18 (94.74%)	12 (100.00%)	1.000
Lumbar spondylolisthesis	1 (5.26%)	0 (0.00%)	

Continuous variables were expressed as mean ± SD, Categorical variables were expressed as percentage (%). BMI, body mass index; ASA score, American society of anesthesiologists classification score; 3D EX: the three-dimensional exoscope; OM: the operating microscope.

Evaluation of clinical outcomes

Clinical outcomes were assessed using visual analogue scale (VAS) scores for back and leg pain, and the Oswestry disability

TABLE 3 The surgical data and related postoperative complications.

	OM	3D EX	*p*-value
One-level	23	20	
Operation time, min	138.61 ± 28.31	145.00 ± 31.58	0.488
Intraoperative blood loss, ml	130.43 ± 55.88	114.50 ± 63.62	0.387
Blood transfusion, *n*	0 (0.00%)	2 (10.00%)	0.210
Shed autologous blood reinfusion, *n*	1 (4.34%)	0 (0.00%)	1.000
Blood infusion volume, ml	200.00 ± 0.00	250.00 ± 70.71	0.667
Postoperative hospital stay, day	7.39 ± 2.55	6.40 ± 1.67	0.135
Complications			
Dural tear	2 (8.70%)	0 (0.00%)	0.491
Infection	0 (0.00%)	0 (0.00%)	1.000
Two-level	19	12	
Operation time, min	168.42 ± 43.11	171.67 ± 29.18	0.820
Intraoperative blood loss, ml	255.26 ± 114.13	229.17 ± 65.57	0.426
Blood transfusion, n	0 (0.00%)	0 (0.00%)	1.000
Shed autologous blood reinfusion, n	15 (78.95%)	5 (41.67%)	0.035*
Blood infusion volume, ml	102.40 ± 65.51	97.60 ± 55.78	0.885
Postoperative hospital stay, day	7.05 ± 1.68	6.42 ± 1.00	0.247
Complications			
Dural tear	0 (0.00%)	0 (0.00%)	1.000
Revision	0 (0.00%)	0 (0.00%)	1.000

Continuous variables were expressed as mean ±SD, Categorical variables were expressed as percentage (%). 3D EX, the three-dimensional exoscope; OM, the operating microscope, *p < 0.05.

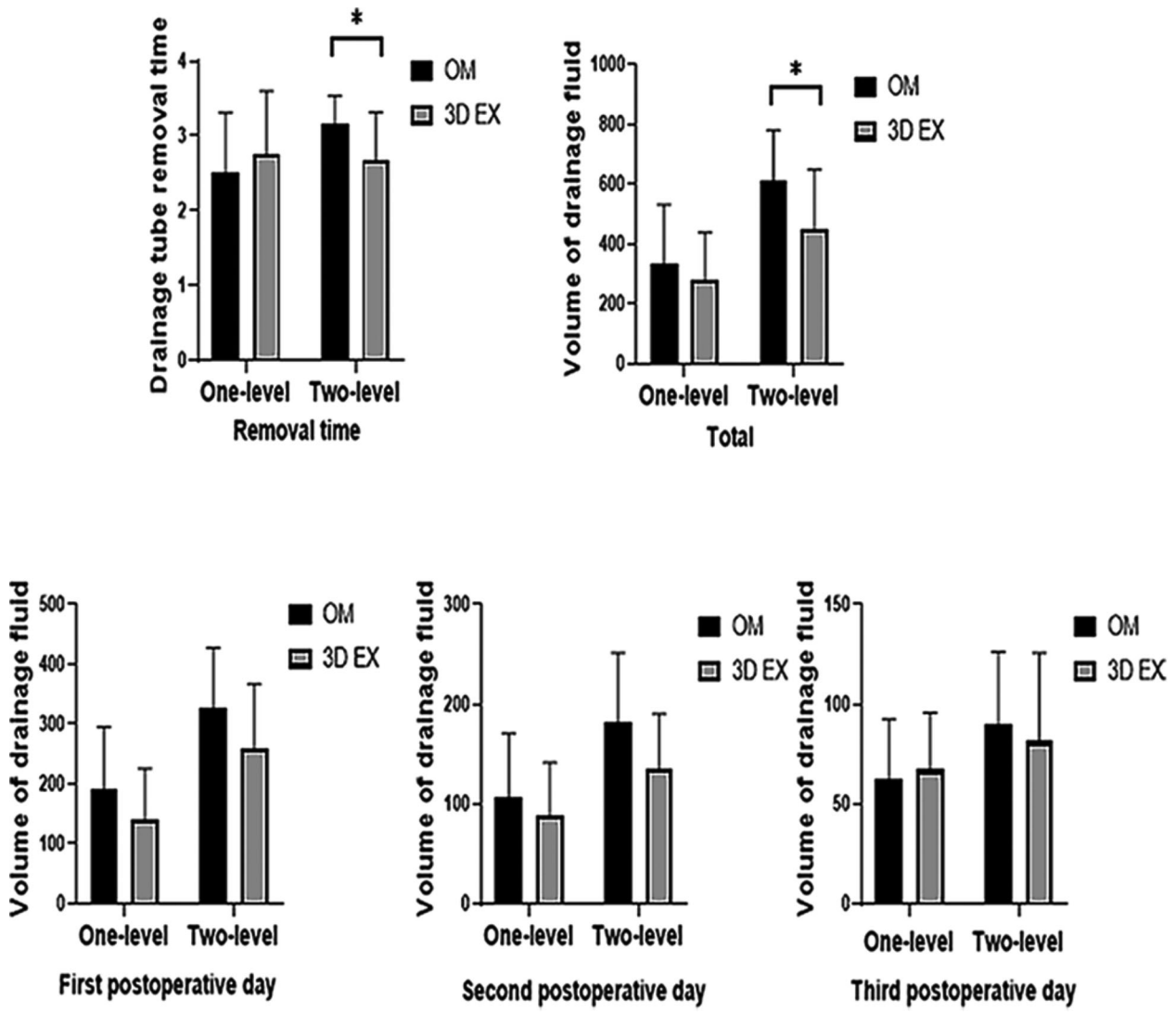

FIGURE 3
Drainage data results. 3D EX, the three-dimensional exoscope; OM, the operating microscope; *$p < 0.05$; **$p < 0.001$.

index (ODI). ODI and VAS scores were taken preoperation, 1 week, 1 month, 3 months, 6 months, and 12 months after surgery. Postoperative complications including dural tear and revision were watched and evaluated.

Statistical analysis

All statistical analyses were done using SPSS version 20.0 (IBM). Enumeration data are expressed in percentage. Measurement data are expressed as mean ± SD. Unless stated otherwise, independent-sample t test was used for measurement data. Chi-square and Fisher exact tests were used for enumeration data. Analysis of covariance was used to compare pre- and post-operative RBC, Hb, and Hct. VAS and ODI were analyzed using general linear models repeated measures analysis of variance. $P < 0.05$ indicated statistically significant differences.

Results

Characteristics of the participants at baseline

A total of 74 patients met the inclusion criteria. Of these, 32 were treated using 3D EX, with 20 undergoing one-level TLIF, and 12 undergoing two-level TLIF. OM was used to treat 42

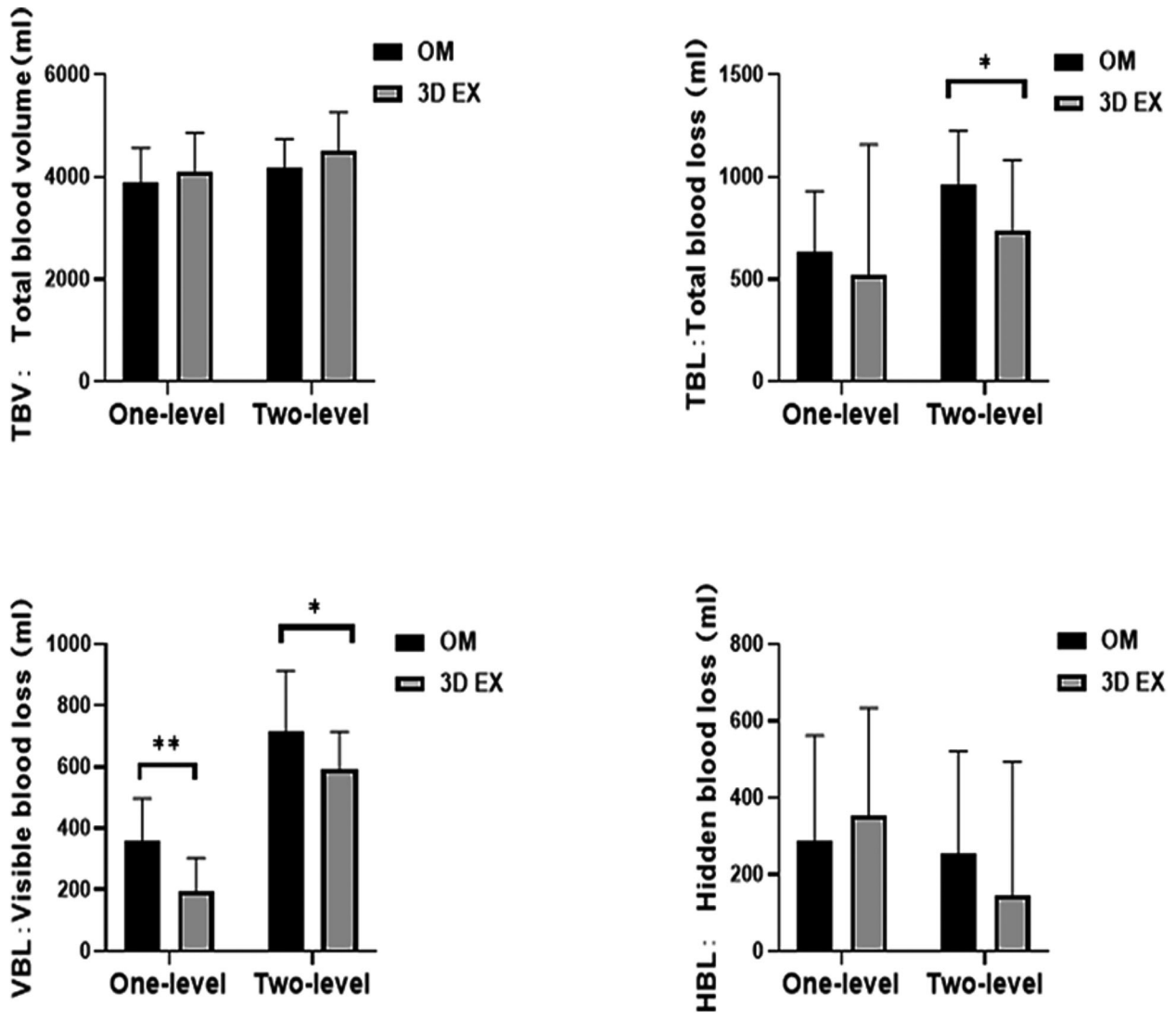

FIGURE 4
Perioperative blood loss results. 3D EX, the three-dimensional exoscope; OM, the operating microscope; *$p < 0.05$; **$p < 0.01$; ns not statistic difference.

patients, with 23 undergoing one-level TLIF and 19 undergoing two-level TLIF. Of the patients who underwent 3D EX, 30 were diagnosed using lumbar spinal stenosis, while 2 were diagnosed using lumbar spondylosis. Of those treated using OM, 40 were diagnosed using lumbar spinal stenosis, while 2 were diagnosed using lumbar spondylosis. There were no significant differences in the demographics of the two groups. The participants main clinical features are shown on Table 2.

Surgical data and related postoperative complications

The two groups did not differ significantly with regards to operative time, intraoperative blood loss, blood infusion volume and postoperative hospital stay. There was statistically significant difference in the use of shed autologous blood reinfusion in the 3D EX vs. OM in two-level TLIF ($p = 0.035$) but not in one-level TLIF ($p = 1.000$). The rate of postoperative complications did not differ significantly between the two groups. Surgical data and associated postoperative complications are summarized on Table 3.

Drainage data results

Drainage fluid volume on the 1st, 2nd, or 3rd day after operation did not differ between the two groups. The mean total drainage fluid volume and drainage tube removal time differed significantly between the 3D EX and OM groups in

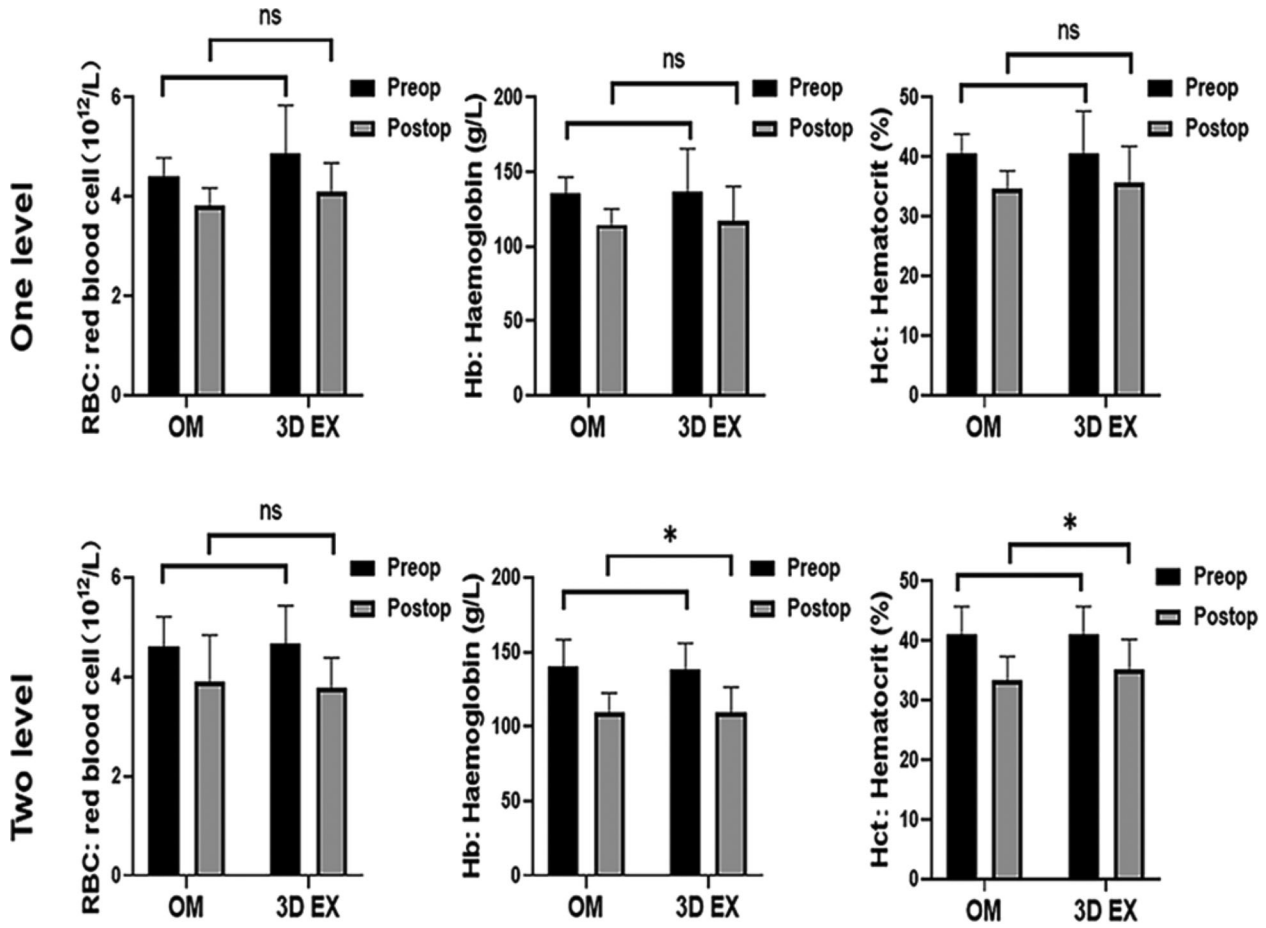

FIGURE 5
Hematological results. 3D EX, the three-dimensional exoscope; OM, the operating microscope; *$p < 0.05$; **$p < 0.01$; ns not statistic difference.

two-level TLIF ($p = 0.021$, $p = 0.012$) but not in one-level TLIF ($p = 0.313$, $p = 0.367$). Drainage data are shown on Figure 3.

Perioperative blood loss and hematological results

To control baseline imbalances, RBC, Hb, and Hct was adjusted using analysis of covariance tests. RBC levels did not differ significantly between the two groups. There were significant differences in the levels of Hb and Hct values upon using 3D EX, relative to OM for two-level TLIF ($p = 0.004$, $p = 0.018$), but not for one-level TLIF ($p = 0.533$, $p = 0.140$). The two groups did not differ significantly with regards to PBV and HBL. VBL values differed significantly between the two groups. TBL values differed significantly when 3D EX was used for two-level TLIF relative to OM ($p = 0.046$), but not for one-level TLIF ($p = 0.305$). Perioperative blood loss results were shown in Figure 4 and hematological results were shown in Figure 5.

Clinical outcomes

Postoperative ODI and VAS scores for low back pain, and leg pain were significantly lower than before surgery (all $p < 0.05$). The two groups did not differ significantly with regards to the levels of VAS and ODI at all timepoints (Figure 6). Pre and post-operation 3D TLIF x-rays were shown in Figure 7

Discussion

The replacement of OM with a high-definition exoscope system in neurosurgery was demonstrated in 2008 (16). Moreover, Ali Shirzadi et al. showed that the video telescope operating monitor (VITOM) system of spinal surgery offers outstanding image quality and an ease of manipulation rivaling OM (17). However, these studies focused on 2D EX only. A major drawback of 2D EX is the lack of stereopsis. In recent years, the development of 3D visualization technology has led to the development of 3D exoscopic visualization

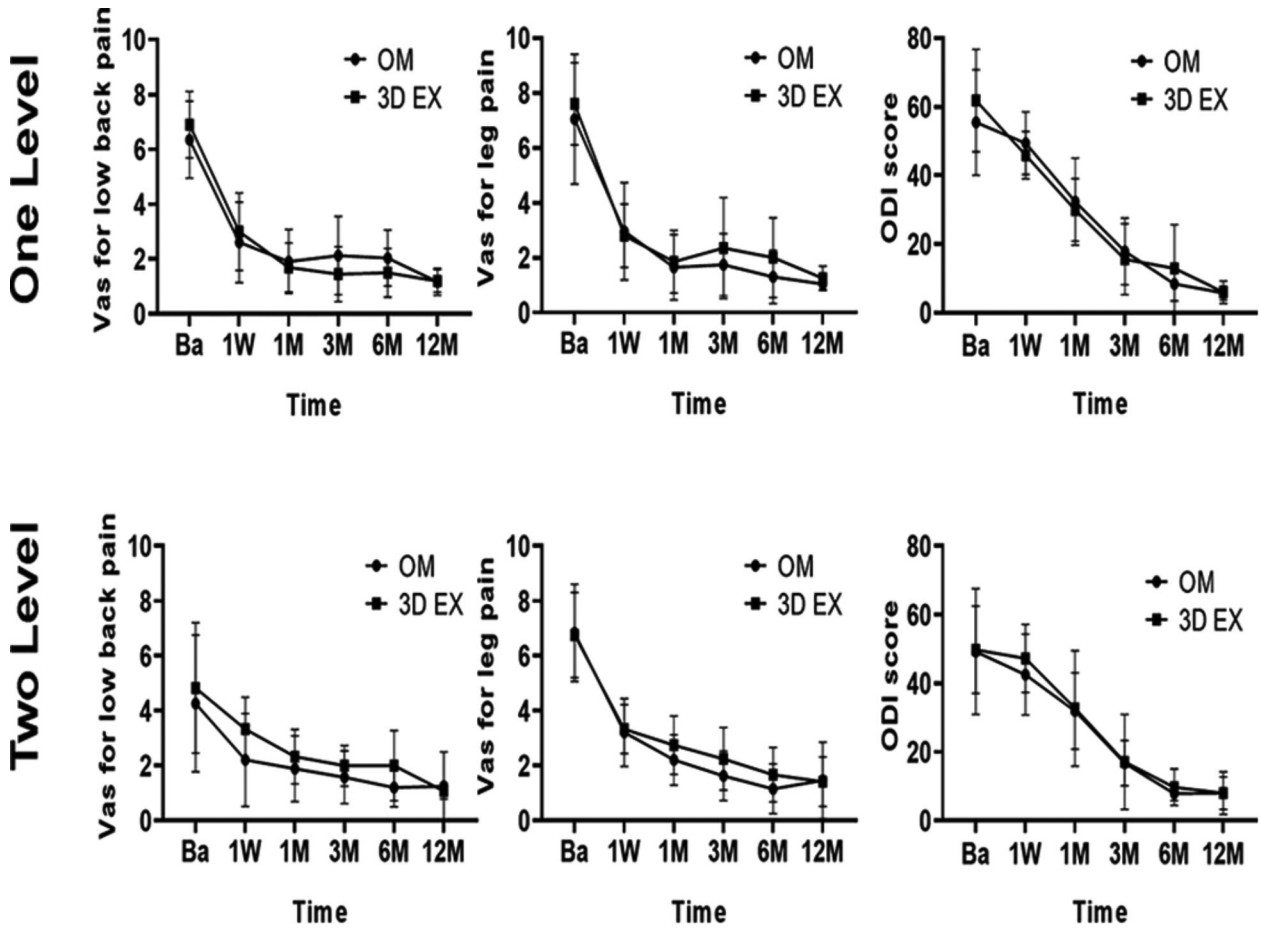

FIGURE 6
Clinical outcomes. 3D EX, the three-dimensional exoscope; OM, the operating microscope; Ba, baseline; 1W, 1week; 1M, 1month; 3M, 3 months; 6M, 6months; 12M, 12months.

which has been used in spinal microsurgery (10, 18–21). However, these reports are mainly based on uncontrolled case reports containing small numbers of subjects, or initial technical reports. There are currently no controlled trials in this area. In this retrospective case-control study, we examined the effect of 3D EX on patients undergoing TLIF.

A shortcoming of past studies was that they only examined intraoperative blood loss during spinal surgery. Zhang et al. found that intraoperative blood loss only explained 36.52% of TBL in TLIF (22). It needed to be emphasized that HBL and postoperative drainage during the perioperative period in TLIF. The main novelties in this paper are the use of drainage data, TBV, TBL, VBL, and HBL. We demonstrate the potential advantages of 3D EX in reducing bleeding by component analysis of perioperative blood loss. What's more, we illuminate directions for perioperative blood management strategies for TLIF.

The most important finding in this article is that 3D EX significantly reduced postoperative drainage volume and perioperative bleeding volume in two-level TLIF relative to OM. Our results show that in two-level TLIF, 3D EX was associated with shorter drainage tube removal time, less total volume of drainage fluid, less use of autologous blood reinfusion, higher postoperative Hb and Hct, and less TBL and VBL relative to the OM group. However, the one level TLIF did not vary as much as in the two levels TLIF. Significant difference could only be found in VBL. Relative to two-level TLIF, one-level TLIF has the advantage of a shorter operation time, less blood loss, and less trauma to patients. Thus, differences were not marked in one-level TLIF.

The following reasons may account for less perioperative bleeding in 3D EX. First, relative to OM, 3D EX is ergonomically improved. Consistent with past findings (19), 3D EX does not confine the surgeon to the eyepieces, reducing fatigue. The wide viewing field and long focal distance of 3D EX offers the surgeon ample space, which may reduce surgical stress, and lower the risk of complications. In operation procedures, wound closure is done only after careful

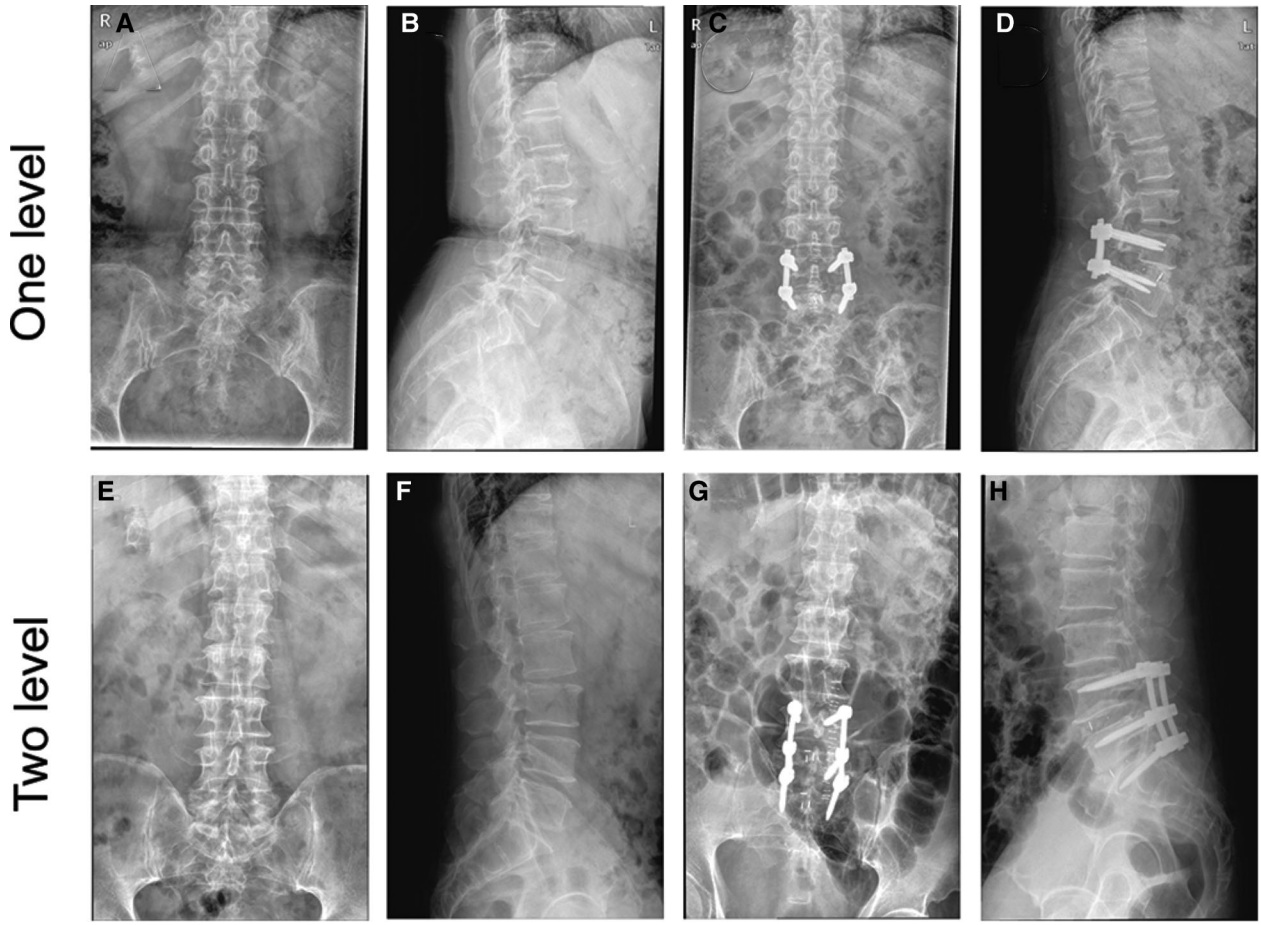

FIGURE 7
Pre and post-operation 3D TLIF x-rays. (A) Preoperative anteroposterior x-ray of one level TLIF. (B) Preoperative lateral x-ray of one level TLIF. (C) Postperative anteroposterior x-ray of one level TLIF. (D) Postperative lateral x-ray of one level TLIF. (E) Preoperative anteroposterior x-ray of two level TLIF. (F) Preoperative lateral x-ray of two level TLIF. (G) Postperative anteroposterior x-ray of two level TLIF. (H) Postperative lateral x-ray of two level TLIF.

control of the hemostasis at the end of operation. Especially in complex surgeries with long operation time, the surgeons just do not have enough patience and energy for meticulous hemostasis. 3D EX decreases fatigue during long or complicated procedures, enabling surgeons to meticulous hemostasis in the last surgical phase. What's more, the surgeons do not need to switch between microscopic perspective to normal perspective. This make management of surgical instruments for hemostasis more convenient and shallow and deep tissue hemostasis are able to complete at the same time, which promotes intraprocedural hemostasis efficiency. Secondly, the whole surgical team can view the high quality 3D images, which improves the team's cohesion and training effectiveness (11, 23), as well as improve active participation by the entire team, including nurses and anesthesiologists. For example, once epidural venous plexus bleeding occurs, nurses may also be able to respond more quickly to prepared hemostatic materials and anesthesiologists can provide hypotensive anesthesia to reduce the extent of intraoperative bleeding. Importantly, the wide and clear visual field reduce the need for further microscope adjustments. Especially for intraoperative cage implantation and cage position adjustment, 3D EX eliminates the need for microscope adjustments. Upon laser-guided focusing, clear image of the shallow and deep tissues are simultaneously visible. Thus, this technology can reduce operative time by minimizing the time spent adjusting the microscope position, angle of view, and focus. The superficial and deep hemostasis could conduct at the same time without adjustment.

Various studies have shown that anemia after spinal surgery is associated with increased prolonged hospital stay, postoperative complications, blood transfusion, and mortality (24–26). Our findings show that 3D EX reduces TBL, VBL, and total drainage volume in two-level TLIF, suggesting that patients who undergo 3D EX may have lower incidence of postoperative anemia, which may improve their outcomes.

However, we found no intergroup differences with regards to operative time, postoperative hospital stay, and complication rates, which is consistent with past findings (9, 17). This may be due to the small sample size, Another possible explanation is that the TBL of TLIF was too low to reflect advantages of 3D EX. Further studies are needed to determine if 3D EX decreases postoperative hospital stay and complications.

In this retrospective study, both VAS and ODI scores of the two groups improved relative to pre-operative scores and did not differ significantly between the two groups at all timepoints. Because postoperative drainage volume, TBL and VBL did not have a noticeable impact on neurological recovery.

This study has some limitations. First, due to its retrospective design, this study carries inherent deficiencies that may cause confusion or bias. Secondly, all the cases were from a single center and the sample size was small, especially in two-levels TLIF. Thirdly, only cases of lumbar degenerative disc disease were included in the study, with patients with intraspinal tumors excluded. Finally, because our results are based on a single surgical team, they may be challenging to reproduce.

Conclusion

Here, we show that 3D EX can be used as an alternative to OM in TLIF. Our data show that relative to OM, 3D EX is superior in reducing perioperative bleeding in two-level TLIF. Although the findings should be interpreted with caution, a major strength of this study is that it included perioperative bleeding instead of intraoperative bleeding. Further studies are needed to validate these findings. Our findings highlight 3D EX as an emerging field that will markedly improve microsurgery.

Data availability statement

The original contributions presented in the study are included in the article/**Supplementary Material**, further inquiries can be directed to the corresponding author/s.

Ethics statement

The studies involving human participants were reviewed and approved by The Ethics Committee of the Second Affiliated Hospital of Soochow University. The ethics committee waived the requirement of written informed consent for participation.

Author contributions

YP: Writing Original draft preparation; TZ: Writing-Reviewing and Editing; QW and JD: Data analysis and Methodology; QZ and JC: Data curation; XL: Supervision and conceptualization. All authors contributed to the article and approved the submitted version.

Funding

This study is sponsored by the National Natural Science Foundation of China (82002345,81902239), the Science and Technology Project of Suzhou (KJXW2019011) and the Preliminary Research Project of the Second Affiliated Hospital of Soochow University (SDFEYBS1905).

Acknowledgments

The authors thank all of the participants in the Second Affiliated Hospital of Soochow University, and we thank the support of patients.

Conflict of interest

The authors declare that the research was conducted in the absence of any commercial or financial relationships that could be construed as a potential conflict of interest. The reviewer C.K. declared a shared parent affiliation with the authors to the handling editor at the time of review.

Publisher's note

All claims expressed in this article are solely those of the authors and do not necessarily represent those of their affiliated organizations, or those of the publisher, the editors and the reviewers. Any product that may be evaluated in this article, or claim that may be made by its manufacturer, is not guaranteed or endorsed by the publisher.

Supplementary material

The Supplementary Material for this article can be found online at: https://www.frontiersin.org/articles/10.3389/fsurg.2022.926329/full#supplementary-material.

References

1. Ravindra VM, Senglaub SS, Rattani A, Dewan MC, Hartl R, Bisson E, et al. Degenerative lumbar spine disease: estimating global incidence and worldwide volume. *Global Spine J*. (2018) 8(8):784–94. doi: 10.1177/2192568218770769

2. Dagenais S, Caro J, Haldeman S. A systematic review of low back pain cost of illness studies in the United States and internationally. *Spine J*. (2008) 8(1):8–20. doi: 10.1016/j.spinee.2007.10.005

3. Sun W, Wang P, Hu H, Kong C, Hai Y, Lu S. Retrospective study on effectiveness of Activ L total disc replacement. *J Orthop Surg Res*. (2021) 16 (1):2. doi: 10.1186/s13018-020-02116-4

4. Oh HS, Lee SH, Hong SW. Anterior dislodgement of a fusion cage after transforaminal lumbar interbody fusion for the treatment of isthmic spondylolisthesis. *J Korean Neurosurg Soc*. (2013) 54(2):128–31. doi: 10.3340/jkns.2013.54.2.128

5. Mamelak AN, Nobuto T, Berci G. Initial clinical experience with a high-definition exoscope system for microneurosurgery. *Neurosurgery*. (2010) 67 (2):476–83. doi: 10.1227/01.NEU.0000372204.85227.BF

6. Mamelak AN, Drazin D, Shirzadi A, Black KL, Berci G. Infratentorial supracerebellar resection of a pineal tumor using a high definition video exoscope (VITOM(R)). *J Clin Neurosci*. (2012) 19(2):306–9. doi: 10.1016/j.jocn.2011.07.014

7. Fiani B, Jarrah R, Griepp DW, Adukuzhiyil J. The role of 3D exoscope systems in neurosurgery: an optical innovation. *Cureus*. (2021) 13(6):e15878. doi: 10.7759/cureus.15878

8. Takahashi S, Toda M, Nishimoto M, Ishihara E, Miwa T, Akiyama T, et al. Pros and cons of using ORBEYE for microneurosurgery. *Clin Neurol Neurosurg*. (2018) 174:57–62. doi: 10.1016/j.clineuro.2018.09.010

9. Ariffin MHM, Ibrahim K, Baharudin A, Tamil AM. Early experience, setup, learning curve, benefits, and complications associated with exoscope and three-dimensional 4K hybrid digital visualizations in minimally invasive spine surgery. *Asian Spine J*. (2020) 14(1):59–65. doi: 10.31616/asj.2019.0075

10. Oertel JM, Burkhardt BW. Vitom-3D for exoscopic neurosurgery: initial experience in cranial and spinal procedures. *World Neurosurg*. (2017) 105:153–62. doi: 10.1016/j.wneu.2017.05.109

11. Kwan K, Schneider JR, Du V, Falting L, Boockvar JA, Oren J, et al. Lessons learned using a high-definition 3-dimensional exoscope for spinal surgery. *Oper Neurosurg (Hagerstown)*. (2019) 16(5):619–25. doi: 10.1093/ons/opy196

12. Beez T, Munoz-Bendix C, Beseoglu K, Steiger HJ, Ahmadi SA. First clinical applications of a high-definition three-dimensional exoscope in pediatric neurosurgery. *Cureus*. (2018) 10(1):e2108. doi: 10.7759/cureus.2108

13. Harms JG, Jeszenszky D. Die posteriore, lumbale, interkorporelle Fusion in unilateraler transforaminaler Technik. *Oper Orthop Traumatol*. (1998) 10 (2):90–102. doi: 10.1007/s00064-006-0112-7

14. Nadler SB, Hidalgo JH, Bloch T. Prediction of blood volume in normal human adults. *Surgery*. (1962) 51(2):224–32. PMID: 21936146

15. Gross JB. Estimating allowable blood loss: corrected for dilution. *Anesthesiology*. (1983) 58(3):277–80. doi: 10.1097/00000542-198303000-00016

16. Mamelak AN, Danielpour M, Black KL, Hagike M, Berci G. A high-definition exoscope system for neurosurgery and other microsurgical disciplines: preliminary report. *Surg Innov*. (2008) 15(1):38–46. doi: 10.1177/1553350608315954

17. Shirzadi A, Mukherjee D, Drazin DG, Paff M, Perri B, Mamelak AN, et al. Use of the video telescope operating monitor (VITOM) as an alternative to the operating microscope in spine surgery. *Spine (Phila Pa 1976)*. (2012) 37(24): E1517–23. doi: 10.1097/BRS.0b013e3182709cef

18. Weil AG, Obaid S, Chaalala C, Shedid D, Magro E, Seizeur R, et al. Three-dimensional endoscopic magnification for treatment of thoracic spinal dural arteriovenous fistulas: technical note. *Oper Neurosurg (Hagerstown)*. (2018) 14 (3):259–66. doi: 10.1093/ons/opx122

19. Barbagallo GMV, Certo F. Three-dimensional, high-definition exoscopic anterior cervical discectomy and fusion: a valid alternative to microscope-assisted surgery. *World Neurosurg*. (2019) 130:e244–e50. doi: 10.1016/j.wneu.2019.06.049

20. Burkhardt BW, Csokonay A, Oertel JM. 3D-exoscopic Visualization using the VITOM-3D in cranial and spinal neurosurgery. What are the limitations? *Clin Neurol Neurosurg*. (2020) 198:106101. doi: 10.1016/j.clineuro.2020.106101

21. Yao Y, Xiong C, Wei T, Yao Z, Zhu F, Xu F. Three-dimensional high-definition exoscope (Kestrel View II) in anterior cervical discectomy and fusion: a valid alternative to operative microscope-assisted surgery. *Acta Neurochir (Wien)*. (2021) 163(12):3287–96. doi: 10.1007/s00701-021-04997-8

22. Zhang H, Chen ZX, Sun ZM, Jiang C, Ni WF, Lin Y, et al. Comparison of the total and hidden blood loss in patients undergoing open and minimally invasive transforaminal lumbar interbody fusion. *World Neurosurg*. (2017) 107:739–43. doi: 10.1016/j.wneu.2017.08.113

23. Moisi MD, Hoang K, Tubbs RS, Page J, Fisahn C, Paulson D, et al. Advancement of surgical visualization methods: comparison study between traditional microscopic surgery and a novel robotic optoelectronic visualization tool for spinal surgery. *World Neurosurg*. (2017) 98:273–7. doi: 10.1016/j.wneu.2016.11.003

24. Sachdeva I, Carmouche JJ. Postoperative anemia predicts length of stay for geriatric patients undergoing minimally invasive lumbar spine fusion surgery. *Geriatr Orthop Surg Rehabil*. (2020) 11:2151459320911874. doi: 10.1177/2151459320911874

25. Benton JA, Ramos RG, Gelfand Y, Krystal JD, Yanamadala V, Yassari R, et al. Prolonged length of stay and discharge disposition to rehabilitation facilities following single-level posterior lumbar interbody fusion for acquired spondylolisthesis. *Surg Neurol Int*. (2020) 11:411. doi: 10.25259/SNI_707_2020

26. Shillingford JN, Laratta JL, Lombardi JM, Mueller JD, Cerpa M, Reddy HP, et al. Complications following single-level interbody fusion procedures: an ACS-NSQIP study. *J Spine Surg*. (2018) 4(1):17–27. doi: 10.21037/jss.2018.03.19

frontiers | Frontiers in Surgery

TYPE Original Research
PUBLISHED 05 August 2022
DOI 10.3389/fsurg.2022.926825

Check for updates

OPEN ACCESS

EDITED BY
Paphon Sa-ngasoongsong,
Mahidol University, Thailand

REVIEWED BY
Mati Pääsuke,
University of Tartu, Estonia
Junlin Zhou,
Capital Medical University, China
Lu Yungchang,
Mackay Memorial Hospital, Taiwan

*CORRESPONDENCE
Baofeng Li
niren79817@163.com
Bei Chen
bzcheese@126.com

†These authors have contributed equally to this work and share first authorship.

SPECIALITY SECTION
This article was submitted to Orthopedic Surgery, a section of the journal Frontiers in Surgery

RECEIVED 23 April 2022
ACCEPTED 20 July 2022
PUBLISHED 05 August 2022

CITATION
Luo Y, Lin S, Kong L, Jin Y, Wang R, Zhang Y, Li B and Chen B (2022) The clinical outcomes of surgical treatment for chronic ankle instability by anatomical reconstruction of the anterior talofibular ligament with autologous half-bundle peroneal longus tendon: A retrospective study.
Front. Surg. 9:926825.
doi: 10.3389/fsurg.2022.926825

COPYRIGHT
© 2022 Luo, Lin, Kong, Jin, Wang, Zhang, Li and Chen. This is an open-access article distributed under the terms of the Creative Commons Attribution License (CC BY). The use, distribution or reproduction in other forums is permitted, provided the original author(s) and the copyright owner(s) are credited and that the original publication in this journal is cited, in accordance with accepted academic practice. No use, distribution or reproduction is permitted which does not comply with these terms.

The clinical outcomes of surgical treatment for chronic ankle instability by anatomical reconstruction of the anterior talofibular ligament with autologous half-bundle peroneal longus tendon: A retrospective study

Yeqiang Luo[1†], Shanghui Lin[1†], Lingchuang Kong[1†], Yan Jin[1], Renkai Wang[1], Ying Zhang[1], Baofeng Li[1*] and Bei Chen[2*]

[1]Department of Orthopedics, General Hospital of Southern Theater Command, The first School of Clinical Medicine, Southern Medical University, Guangzhou, China, [2]Department of Radiation Oncology, Nanfang Hospital, Southern Medical University, Guangzhou, China

The anterior talofibular ligament is the weakest and most vulnerable lateral ligament to be injured, and it can replace anatomical position through anatomical reconstruction. The purpose of this study is to evaluate clinical outcomes after an autologous half-bundle peroneus longus tendon anatomical reconstruction. We conducted a retrospective analysis by enrolling 34 patients [22 male and 12 female, median age 21 (range 19–26) years] with anterior talofibular ligament injury from January 2018 to March 2020. All patients underwent a ligament anatomical reconstruction operation with autologous half-bundle peroneus longus tendon and followed up with an average time of 16.21 ± 3.20 (range 12–24) months, with no loss of patients to follow-up during the study period. The American Orthopedic Foot, Ankle Society Score (AOFAS), Visual Analogue Score (VAS), and Anterior Tibiotalar Translation were used to assess the curative effect. All the indexes were compared between the preoperative and at the final follow-up to discover the related statistical differences. The AOFAS score improved significantly from an average preoperative score of 56.91 ± 3.79 to 94.12 ± 2.51 at the final followed-up ($p < 0.001$). Meanwhile, the pre-operation VAS pain score decreased from 5.94 ± 1.32 to 1.71 ± 0.87 ($p < 0.001$). Additionally, the Anterior tibiotalar translation decreased from 16.40 ± 1.85 to 5.20 ± 0.57 mm at the final followed-up ($p < 0.001$). The anterior drawer test was negative for all patients after the operation. Considering the outcomes, we concluded that anatomical reconstruction of the anterior talofibular ligament with autologous half-bundle peroneal longus tendon was a proper and safe procedure for chronic lateral ankle instability, and it had good clinical results and minimal complications.

KEYWORDS
anatomical reconstruction, anterior talofibular ligament, autologous tendon, chronic ankle instability, ligament repair, peroneal longus tendon

Introduction

Ankle sprains are a clinically common sports injury disease. According to the literature, 80% of all ankle sprains involved the lateral ligaments of the ankle (1). The anterior talofibular ligament is the weakest and most vulnerable lateral ligament to be injured because of anatomical differences in the lateral ligaments. Although conservative treatment for most acute lateral ankle ligament injuries is effective, some of them will continue to develop chronic ankle instability which eventually leads to traumatic arthritis (2). Over the past few decades, there have been many types of surgery for chronic ankle instability, including ligament repair, anatomical reconstruction, non-anatomical reconstruction, and arthroscopic techniques (3–6). Non-anatomical reconstruction surgery uses local tendon grafts to repair ligaments, without the need to repair ligament remnants. However, many studies have shown that subtalar joint stiffness can ensue from non-anatomical reconstruction (7–9). Therefore, arthroscopic and anatomical repairs and reconstructions have recently become a popular treatment for injuries of the anterior talofibular ligament. Direct ligament repair, known as the Brostrom technique, remains the historic benchmark (4). Anatomical repair is based on the anatomical position of the ligament to recover the normal anatomical structure and joint biomechanics of the ligament, and it has become increasingly popular. We were interested in determining if using an autologous half bundle peroneus longus tendon would work best to reconstruct the anterior talofibular ligament. We hypothesized that this operation had good clinical outcomes and a low risk of complications. We compared the American Orthopedic Foot, Ankle Society Score (AOFAS), Visual Analogue Score (VAS), and Anterior Tibiotalar Translation between the preoperative and final followed-up to evaluate clinical outcomes after an autologous half bundle peroneus longus tendon anatomical reconstruction.

Patients and methods

Patient selection

The ethical committee of the General Hospital of Southern Theater Command of PLA approved the study. In this study, we retrospectively analyzed 34 patients [22 male and 12 female, median age 21 (range 19–26) years] who underwent a ligament anatomical reconstruction operation using autologous half-bundle peroneal longus tendon for anterior talofibular ligament injury in our hospital from January 2018 to March 2020. All patients were informed preoperatively of the procedure's risks, advantages, and disadvantages, and signed an informed consent form. All procedures performed in studies involving human participants were following the ethical standards of the institutional and national research committee and with the 1964 Helsinki Declaration and its later amendments or comparable ethical standards. For this type of study, formal consent is not required.

Inclusion criteria included all patients who had pain and discomfort in the lateral ankle joint, and the ankle joint anterior drawer test was positive. All patients had a previous history of repeated varus ankle sprains more than 3 times, and 6 months of conservative treatment without improvement. The ankle stress plain radiographs showed anterior tibiotalar translation, and the MRI showed the anterior fibular ligament's disorganized or absent structure. These patients had no foot or ankle fractures and had not received any foot or ankle surgery.

Exclusion criteria included acute injury to the lateral ankle ligament and patients with the chronic consumptive disease or medical disease who could not tolerate the surgery. Patients with severe ankle osteoarthritis or a history of foot and ankle fractures or surgery were also excluded from the study. The presence of concomitant ligament injury was also an exclusion criterion.

Operative technique

All patients were operated on by the senior author (B.F.L.) and the first assistant (L.C.K.). The patient was placed in a supine position, combined spinal-epidural anesthesia. After satisfactory anesthesia, a tourniquet was placed on the root of the thigh of the affected limb. A drape was disinfected routinely after blood evacuation. An arc-shaped incision of 3–4 cm was made below the tip of the lateral malleolus. The subcutaneous tissue and fascia were isolated, and the sural nerve was carefully protected. During the operation, the ankle anterior drawer test and varus stress test were performed again to check the ankle stability and explore the ligament damage, which confirmed that the anterior talofibular ligament could not be anatomically repaired, requiring reconstructive surgery. Graft preparation: We made a

longitudinal incision of about 1 cm which was made along the posterior side of the lateral malleolus, and the peroneus longus tendon was fully exposed in the surgical field. the peroneus longus tendon was bisected into two bundles with a hemostat, one was large and the other is small. We chose the small bundle, which was about a third of the total tendon. The tendon was extracted with a tendon extractor. The residual muscle was removed from the tendon and the tendon was folded into double strands with 6 cm in length and 4.5 mm in diameter. The folded end was fixed by the adjustable Arthrex Endobutton loop (Arthrex Endobutton loop ®; Rui Shi Medical Instrument Co, Shanghai, China). Then, using a suture to suture the ends of the autologous half-bundle peroneus longus tendon (**Figures 1A,B**). The tendon graft was pre-loaded 15 lb for ten minutes. Fibular tunnel and talus tunnel preparation: A 3.0 mm Kirschner wire was drilled from the end of the anterior talofibular ligament toward the posterolateral border of the fibular, and using a 4.5-mm cannulated drill system to prepare for the fibular bone tunnel. The guidewire was placed at a 30 angle from the fibular shaft and 5 to 7 mm from the articular surface of the distal fibula (**Figure 1C**). The ATFL's talus attachment was debrided, and a tunnel was made in the footprint of the talar attachment. The nosed guide needle was drilled vertically from the outside to the inside of the talus along the guide needle with 4.5 mm in diameter and with a depth of 20 mm (**Figure 1D**). Under the guidance of the needle, two sutures were respectively passed through the bone tunnels as a traction suture. The tendon was gradually pulled into the fibular tunnel until the adjustable Arthrex Endobutton loop reached the exit of the fibular tunnel, and then the tendon was reverse-pulled until the loop was close to the posterior margin of the fibula. The ankle joint was fixed in a neutral position, and the other end of the tendon was pulled into the talus tunnel and fixed the tendon with a 4.5 * 20 mm absorbable interference screw (MILAGRO ADVANCE, Puits Godet 20 Neuchatel, CH 2000, Switzerland). After the ankle flexion and extension activity were good, the tail of the braided tendon was fixed by an extrusion screw of the appropriate size (**Figures 1E,F**). Checked ankle range of motion and stability, layered by layered suture closure incision.

Rehabilitation

The ankle joint was fixed in a neutral position with a short leg cast for 4 weeks after surgery. Patients were allowed to walk non-weight- bearing with double crutches. In the early stage, the toes were moved slowly and to the maximum extent possible without causing pain in the ankle joint, and straight leg raising training of both lower extremities could be performed. At 4 weeks postoperatively, the patient should start walking on crutches and perform functional rehabilitation, including muscle strength and balance training. At 6 weeks postoperatively, the patient is allowed to be fully weight-bearing, and the ankle dorsiflexion, plantar flexion, varus and valgus resistance muscle exercises could be performed using yoga elastic bands.

Evaluation of curative effect

In our study, we used the Visual Analogue Scale (VAS) score to evaluate ankle pain. We used the American Orthopaedic Foot and Ankle Society score (AOFAS) to assess ankle functional recovery, and we followed up to observe the occurrence of complications. The AOFAS score consists of three components: pain (40 points), function (50 points) and alignment (10 points). The total score of 90–100 is considered excellent, 75–89 is good, 50–74 is acceptable, and less than 50 is poor. We also measured the preoperative and postoperative anterior tibiotalar translation to evaluate the outcomes.

Statistical analysis

Statistical analysis was performed by IBM SPSS Statistics for Windows, Version 21.0(IBM, USA). A normality analysis was performed to continuous variables using the Shapiro-Wilk test. To compare the pre-operative and post-operative indexes, Paired Samples Test was applied for parametric data. The value of $p < 0.05$ was considered statistically significant.

Results

We enrolled 34 anterior talofibular ligament injury patients treated by the autologous half-bundle peroneal longus tendon anatomical reconstruction and they were subsequently followed up at an average time of 16.21 ± 3.20(range 12–24) months, with no loss of patients to follow-up during the study period. The demographic of all patients was summarized in **Table 1**. Data are shown as mean with ± standard deviation and (range) unless otherwise indicated. In the final follow-up, there were significant improvements in the anterior drawer test results, American Orthopedic Foot and VAS score, and Tegner active level, as seen in **Table 2**. The AOFAS score improved significantly from an average preoperative score of 56.91 ± 3.79 to 94.12 ± 2.51 at the final follow-up ($p < 0.001$). Meanwhile, the pre-operation VAS pain score decreased from 5.94 ± 1.32 to 1.71 ± 0.87 ($p < 0.001$). Additionally, the Anterior tibiotalar translation decreased from 16.40 ± 1.85 to 5.20 ± 0.57 mm at the final follow-up ($p < 0.001$). The anterior drawer test was negative in all patients after the operation. 2 patients had a local complication. At the final follow-up, 2(5.88%) patients had local complications. One patient still had recurrent sprains after surgery, and the

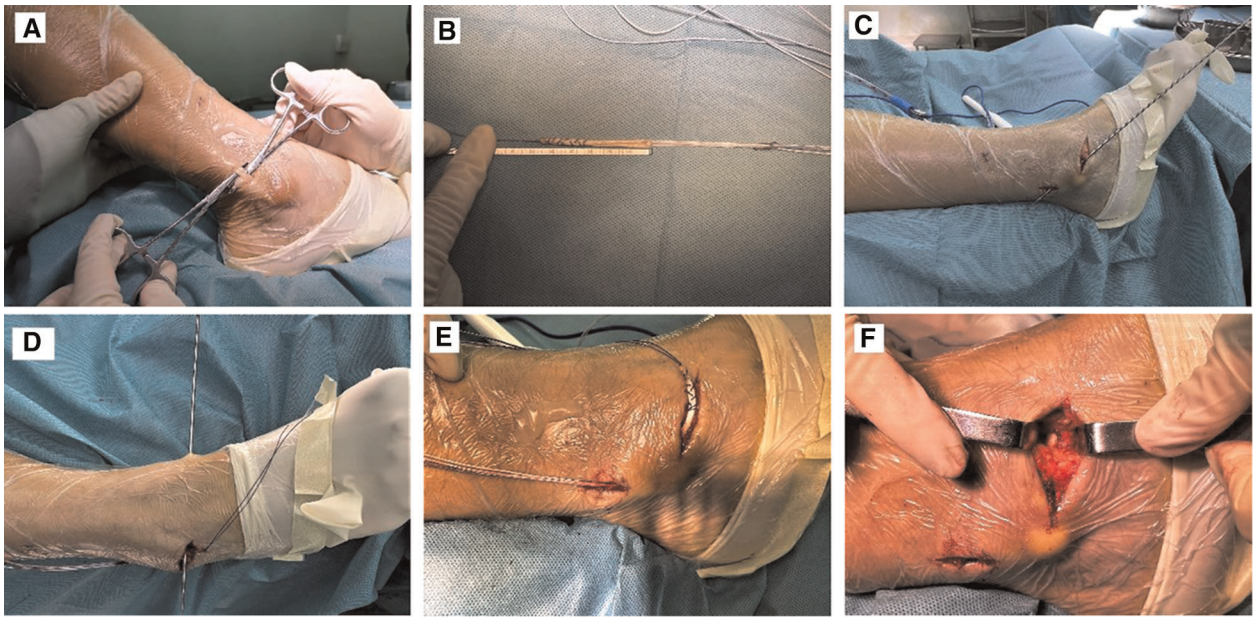

FIGURE 1
The surgical procedure of anatomical reconstruction of the anterior talofibular ligament with autologous half-bundle peroneal longus tendon. (A,B) The autologous half-bundle peroneal longus tendon preparation. (C) Fibular tunnel preparation. (D) Talus tunnel preparation. (E,F) The autologous half-bundle peroneal longus tendon implantation.

patient felt pain and swelling in the ankle joint, which could be due to traumatic arthritis caused by repeated ankle sprains. Another patient had pain and swelling in the affected ankle, which may be caused by the friction between the ankle muscle and the adjustable Arthrex Endobutton loop. The complications of all patients were summarized in Table 3.

Discussion

Acute lateral ankle ligament injury is one of the most common problems in foot and ankle medicine (10). If the ligament injury is not timely treated, the patient's foot will be repeatedly inverted during walking, which will eventually go on to chronic ankle instability and wear and tear of the ankle cartilage, which can lead to traumatic arthritis of the ankle joint and affect the patient's daily life. In our study, we rebuilt the anterior talofibular ligament with an autologous half-bundle peroneus longus tendon to increase the stability of the ankle joint. The fibula was fixed with an Endobutton adjustable loop, and the talus was fixed with an Arthrex extrusion screw (Figures 2A–D). We found that the postoperative AOFAS score increased 37.21 points on average compared with that before the operation. The ankle flexion and extension, hindfoot activity, and healthy side were not significantly different, and satisfactory results were obtained. Moreover, during the operation, the method of anterior cruciate ligament reconstruction was adopted. Based on the anatomical operation of the anterior talofibular ligament, the tendon was fixed by Endobutton adjustable loop. The operation was simple, the damage to surrounding tissues was reduced, the operation time was greatly shortened, and the purpose of anatomical reconstruction was achieved. Meanwhile, a small surgical incision is conducive to the early functional exercise of patients.

With the development of medical imaging, there are numerous measures to diagnose ligament injury, including

TABLE 1 Demographic data of all included patients (mean ± standard deviation).

Variable	Data
Age (years)	21.88 ± 2.10(19–26)
Gender	Male $n = 22$/Female $n = 12$
Side	Left $n = 15$/Right $n = 19$
Follow-up (months)	16.21 ± 3.20(range 12–24)

TABLE 2 Results of anatomic ATFL reconstruction with autologous half-bundle peroneus longus tendon for CLAI (mean ± standard deviation).

	Pre-operation	Final follow-up	*p*-value
AOFAS	56.91 ± 3.79	94.12 ± 2.51	$p < 0.001$
VAS	5.94 ± 1.32	1.71 ± 0.87	$p < 0.001$
Anterior tibiotalar translation (mm)	16.40 ± 1.85	5.20 ± 0.57	$p < 0.001$

TABLE 3 Complications of anatomic ATFL reconstruction with autologous half-bundle peroneus longus tendon for CLAI.

Pain	**2/34**
Ankylosis	0/34
Infection	0/34
Swelling	2/34
Delayed Wound Healing	0/34
Recurrent Sprains or Instability	1/34
Osteoarthritis	1/34

stress radiography, MRI, and ultrasound. Clinical assessment of ankle stability is complicated by the fact that lateral ligament tensions vary with relative degrees of ankle dorsiflexion or plantar flexion (11). The anterior drawer test (ADT) and the talar tilt angle are commonly used in clinical practice to assess lateral ankle ligament injury. The ATFL is an anatomic linkage between the distal fibula and the talus, which limits the sagittal talar translation and axial rotation (12). Phisitkul et al. (13) studied that the ADT is more accurate in diagnosing ATFL injury than standard direct AD testing. Imaging plays a key role in diagnosing ATFL injury. Imaging modalities used to assess lateral ankle ligament stability include stress radiographs, MRI, and ultrasound. Stress radiographs have acted as an objective supplement to physical examination (14). However, studies have shown that the substantial translation and rotation components inherent in any AD maneuver and the TT testing have potential confounding factors for subtalar motion (10). Hoffman et al evaluated the accuracy of stress radiography and concluded that stress radiographs underestimate anterior talar translation and talar tilt angles (14). Morvan et al. (15) found that MRI was sensitive for identifying ATFL abnormality. However, MRI has a high sensitivity but low specificity. As a result, using MRI to recognize additional periarticular pathology rather than as a primary diagnostic tool for CLAI (12). Therefore, when the diagnosis of ankle ligament injury is clear, early surgical treatment should be actively performed.

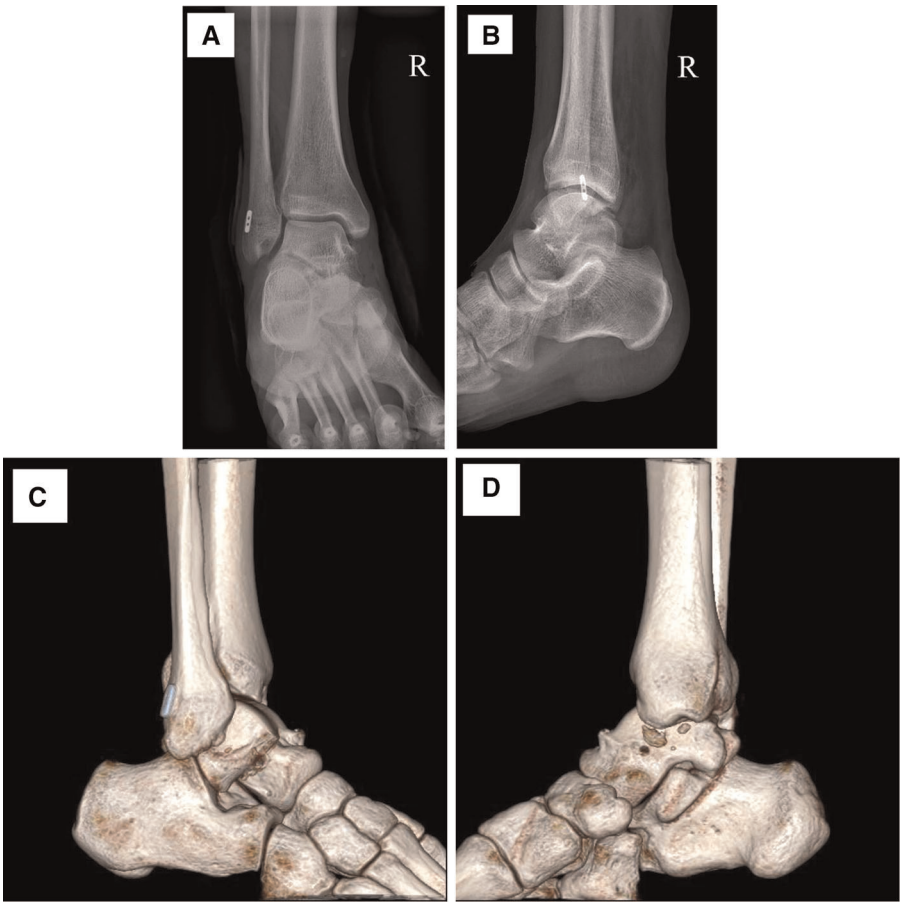

FIGURE 2
A typical case of the anterior talofibular ligament injury after anatomical reconstruction with autologous half-bundle peroneal longus tendon. (A) Post-operative X-ray image in the anterior position. (B) Post-operative X-ray image in the lateral position. (C,D) Post-operative CT reconstruction image in the sagittal position.

For an acute injury, conservative treatment is the first choice, and the principle of RICE (Rest, Icing, Compression, Elevation) is often followed in clinical practice. Surgical treatment for patients with an old sprain or residual function instability. As with many advancements in the field of orthopedic surgery, there are very many methods for surgical treatment of anterior talofibular ligament injury in the clinic, and the current prevailing methods are largely simple repair, anatomical repair, and autologous or allogeneic tendon reconstruction. Nonanatomic reconstruction surgery uses local tendon grafts to repair ligaments, without the need to repair ligament remnants. However, many studies have shown that subtalar joint stiffness can ensue from the nonanatomic reconstruction (7–9). Colville et al. (8) reported that Evans, Chrisman-Snook, and Waston-Jones techniques did not restore physiologic ankle range of motion. In recent years, the arthroscopic-Brostrom technique incorporates the inferior extensor retinaculum into the primary construct. It has the advantages of less trauma, no need to sacrifice autologous tendons, and better biomechanical strength, and has been widely recognized. However, some scholars suggested that this operation could cause ligamentous laxity and various hindfoot malalignment. Additionally, it was not suitable for those patients who had fewer ligament stumps and poor surrounding tissue conditions. As a result, although the Brostrom technique is the golden standard, it can only be used when the tissue quality of the elongated ligament is sufficient for repair (16–21). As an alternative to direct ligament repair, anatomical reconstruction using autologous or allogeneic tendons has become increasingly popular. The anatomical reconstruction had similar strength and stiffness to the native ligament and could restore the ankle joint. However, the clinical circumstances that require the use of graft reconstruction remain undetermined. As a result, compared with traditional surgery, anatomical reconstruction of the anterior talofibular ligament with autologous half-bundle peroneal longus tendon, using Endobutton adjustable loop fixation tendon, could make less surgical trauma, helps patients with early rehabilitation, and reduce the damage to the surrounding soft tissue. It was an effective anatomical reconstruction of the anterior talofibular ligament and obtained a satisfactory curative effect.

Limitations

Firstly, in this study, we used an adjustable Arthrex Endobutton loop, which may increase the patient's financial burden and, owing to individual differences, may cause local complications; Secondly, we did not take into account gender differences, physical activity and postoperative functional rehabilitation training, which is also a limitation of this study. Thirdly, the average follow-up time of patients is short, and the long-term efficacy needs further observation. Moreover, due to anatomical differences in the fibula, it was easy to cause fibula fracture when preparing the fibula tunnel. Finally, the AOFAS score used is not a validated outcome scale for the evaluation of ankle instability, and consequently, some clinical aspects may have been overlooked.

Conclusion

Anatomical reconstruction of the anterior talofibular ligament with autologous half-bundle peroneal longus tendon was a proper and safe procedure for chronic lateral ankle instability, and it had good clinical results and minimal complications.

Data availability statement

The original contributions presented in the study are included in the article/Supplementary Material, further inquiries can be directed to the corresponding author/s.

Ethics statement

The studies involving human participants were reviewed and approved by The ethical committee of the General Hospital of Southern Theater Command of PLA. The patients/participants provided their written informed consent to participate in this study. Written informed consent was obtained from the individual(s) for the publication of any potentially identifiable images or data included in this article.

Author contributions

YQL and SHL wrote the article and prepared **Figures 1**, **2** and **Tables 1**–**3**. All authors reviewed the article, including LCK, YJ, YZ, BC, and BFL. All authors contributed to the article and approved the submitted version.

Funding

This study was supported by the Nature Science Foundation of China (no. 81972895), and the Science and Technology Project of Guangzhou (no. 202102080595).

Conflict of interest

The authors declare that the research was conducted in the absence of any commercial or financial relationships that could be construed as a potential conflict of interest.

Publisher's note

All claims expressed in this article are solely those of the authors and do not necessarily represent those of their affiliated organizations, or those of the publisher, the editors and the reviewers. Any product that may be evaluated in this article, or claim that may be made by its manufacturer, is not guaranteed or endorsed by the publisher.

References

1. Ferran NA, Maffulli N. Epidemiology of sprains of the lateral ankle ligament Complex. *Foot Ankle Clin*. (2006) 11(3):659–62. doi: 10.1016/j.fcl.2006.07.002

2. Behrens SB, Drakos M, Lee BJ, Paller D, Hoffman E, Koruprolu S, et al. Biomechanical analysis of brostrom versus brostrom-gould lateral ankle instability repairs. *Foot Ankle Int*. (2013) 34(4):587–92. doi: 10.1177/1071100713477622

3. Brattstrom H. Tenodesis employing the method of watson-jones for the treatment of recurrent subluxation of the ankle. *Acta Orthop Scand*. (1953) 23 (2):132–6. doi: 10.3109/17453675308991205

4. Broström L. Sprained ankles. VI. Surgical treatment of "chronic" ligament ruptures. *Acta Chir Scand*. (1966) 132(5):551–65. PMID: 5339635

5. Chrisman OD, Snook GA. Reconstruction of lateral ligament tears of the ankle. An experimental study and clinical evaluation of seven patients treated by a new modification of the elmslie procedure. *J Bone Joint Surg Am*. (1969) 51(5):904–12. doi: 10.2106/00004623-196951050-00007

6. Gould N, Seligson D, Gassman J. Early and late repair of lateral ligament of the ankle. *Foot Ankle*. (1980) 1(2):84–9. doi: 10.1177/107110078000100206

7. Bahr R, Pena F, Shine J, Lew WD, Tyrdal S, Engebretsen L. Biomechanics of ankle ligament reconstruction. An in vitro comparison of the broström repair, watson-jones reconstruction, and a new anatomic reconstruction technique. *Am J Sports Med*. (1997) 25(4):424–32. doi: 10.1177/036354659702500402

8. Colville MR, Marder RA, Zarins B. Reconstruction of the lateral ankle ligaments. A biomechanical analysis. *Am J Sports Med*. (1992) 20(5):594–600. doi: 10.1177/036354659202000518

9. Hollis JM, Blasier RD, Flahiff CM, Hofmann OE. Biomechanical comparison of reconstruction techniques in simulated lateral ankle ligament injury. *Am J Sports Med*. (1995) 23(6):678–82. doi: 10.1177/036354659502300607

10. Guillo S, Bauer T, Lee JW, Takao M, Kong SW, Stone JW, et al. Consensus in chronic ankle instability: aetiology, assessment, surgical indications and place for arthroscopy. *Orthop Traumatol Surg Res*. (2013) 99(8 Suppl):S411–9. doi: 10.1016/j.otsr.2013.10.009

11. Fujii T, Kitaoka HB, Watanabe K, Luo ZP, An KN. Ankle stability in simulated lateral ankle ligament injuries. *Foot Ankle Int*. (2010) 31(6):531–7. doi: 10.3113/FAI.2010.0531

12. Chang SH, Morris BL, Saengsin J, Tourné Y, Guillo S, Guss D, et al. Diagnosis and treatment of chronic lateral ankle instability: review of our biomechanical evidence. *J Am Acad Orthop Surg*. (2021) 29(1):3–16. doi: 10.5435/JAAOS-D-20-00145

13. Phisitkul P, Chaichankul C, Sripongsai R, Prasitdamrong I, Tengtrakulcharoen P, Suarchawaratana S. Accuracy of anterolateral drawer test in lateral ankle instability: a cadaveric study. *Foot Ankle Int*. (2009) 30(7):690–5. doi: 10.3113/FAI.2009.0690

14. Hoffman E, Paller D, Koruprolu S, Drakos M, Behrens SB, Crisco JJ, et al. Accuracy of plain radiographs versus 3d analysis of ankle stress test. *Foot Ankle Int*. (2011) 32(10):994–9. doi: 10.3113/FAI.2011.0994

15. Morvan A, Klouche S, Thes A, Hardy P, Bauer T. Reliability and validity of preoperative mri for surgical decision making in chronic lateral ankle instability. *Eur J Orthop Surg Traumatol*. (2018) 28(4):713–9. doi: 10.1007/s00590-017-2116-4

16. Nery C, Raduan F, Del Buono A, Asaumi ID, Cohen M, Maffulli N. Arthroscopic-Assisted broström-gould for chronic ankle instability: a long-term follow-up. *Am J Sports Med*. (2011) 39(11):2381–8. doi: 10.1177/0363546511416069

17. Karlsson J, Bergsten T, Lansinger O, Peterson L. Reconstruction of the lateral ligaments of the ankle for chronic lateral instability. *J Bone Joint Surg Am*. (1988) 70(4):581–8. doi: 10.2106/00004623-198870040-00015

18. Brodsky AR, O'Malley MJ, Bohne WH, Deland JA, Kennedy JG. An analysis of outcome measures following the broström-gould procedure for chronic lateral ankle instability. *Foot Ankle Int*. (2005) 26(10):816–9. doi: 10.1177/107110070502601005

19. Buerer Y, Winkler M, Burn A, Chopra S, Crevoisier X. Evaluation of a modified broström-gould procedure for treatment of chronic lateral ankle instability: a retrospective study with critical analysis of outcome scoring. *Foot Ankle Surg*. (2013) 19(1):36–41. doi: 10.1016/j.fas.2012.10.005

20. Baumbach SF, Braunstein M, Herterich V, Böcker W, Waizy H, Polzer H. Arthroscopic repair of chronic lateral ankle instability. *Oper Orthop Traumatol*. (2019) 31(3):201–10. doi: 10.1007/s00064-019-0595-7

21. Shahrulazua A, Ariff Sukimin MS, Tengku Muzaffar TM, Yusof MI. Early functional outcome of a modified brostrom-gould surgery using bioabsorbable suture anchor for chronic lateral ankle instability. *Singapore Med J*. (2010) 51(3):235–41. PMID: 20428746

frontiers | Frontiers in Surgery

TYPE Original Research
PUBLISHED 11 August 2022
DOI 10.3389/fsurg.2022.915090

Check for updates

OPEN ACCESS

EDITED BY
Hangue Park,
Texas A&M University, United States

REVIEWED BY
Freeman Miller,
Alfred I. duPont Hospital for Children, United States
Yaodong Gu,
Ningbo University, China

*CORRESPONDENCE
Patarawan Woratanarat
pataraw@yahoo.com

SPECIALTY SECTION
This article was submitted to Orthopedic Surgery, a section of the journal Frontiers in Surgery

RECEIVED 07 April 2022
ACCEPTED 07 July 2022
PUBLISHED 11 August 2022

CITATION
Klaewkasikum K, Patathong T, Angsanuntsukh C, Woratanarat T, Sanguantrakul J and Woratanarat P (2022) The ankle kinematic reference of normal gait pattern in Thai adults.
Front. Surg. 9:915090.
doi: 10.3389/fsurg.2022.915090

COPYRIGHT
© 2022 Klaewkasikum, Patathong, Angsanuntsukh, Woratanarat, Sanguantrakul and Woratanarat. This is an open-access article distributed under the terms of the Creative Commons Attribution License (CC BY). The use, distribution or reproduction in other forums is permitted, provided the original author(s) and the copyright owner(s) are credited and that the original publication in this journal is cited, in accordance with accepted academic practice. No use, distribution or reproduction is permitted which does not comply with these terms.

The ankle kinematic reference of normal gait pattern in Thai adults

Krongkaew Klaewkasikum[1], Tanyaporn Patathong[1], Chanika Angsanuntsukh[1], Thira Woratanarat[2], Jongsook Sanguantrakul[3] and Patarawan Woratanarat[1]*

[1]Department of Orthopaedics, Faculty of Medicine Ramathibodi Hospital, Mahidol University, Bangkok, Thailand, [2]Department of Preventive and Social Medicine, Faculty of Medicine, Chulalongkorn University, Bangkok Thailand, [3]National Electronics and Computer Technology Center, National Science and Technology Development Agency, Pathumthani, Thailand

Objective: This study was aimed to establish the reference values of ankle kinematics and factors associated with ankle kinematics of healthy Thai adults.
Methods: A prospective cohort was conducted among healthy volunteers aged between 18 and 40 years and evaluated gait analysis between 2016 and 2020. After applying the modified Halen Hayes marker set, participants were assigned to walk 8–10 rounds with their preferred speed. Demographic data i.e., age, gender and body mass index (BMI) and ankle kinematics (varus-valgus, dorsiflexion-plantar flexion, foot progression, and ankle rotation) using motion analysis software were recorded and analyzed.
Results: 98 volunteers (60 females and 38 males) aged 28.6 $\pm$ 5.4 years with body mass index 21.2 $\pm$ 2.0 kg/m^2 were included. The average ranges of ankle kinematics entire gait cycle were varus-valgus –1.62 to 3.17 degrees, dorsiflexion-plantar flexion 0.67 to 14.52 degrees, foot progression –21.73 to –8.47 degrees, and ankle rotation 5.22 to 9.74 degrees. The ankle kinematic data in this study population was significantly different from the normal values supplied by OrthoTrak software of the motion analysis program, especially more ankle internal rotation at mid-stance (5.22 vs. –12.10 degrees) and terminal stance (5.48 vs. –10.74 degrees) with $P < 0.001$. Foot progression significantly exhibited more external rotation for 1.5 degrees on the right compared to the left side, and for 5 degrees more in males than females. One increment in age was significantly correlated with ankle internal rotation at mid-swing (coefficient 0.21 degrees, $P = 0.039$). BMI had no statistical association with ankle kinematics. Statistical parametric mapping for full-time series of angle assessments showed significantly different foot progression at initial contact and terminal stance between sides, and our ankle kinematics significantly differed from the reference values of the motion analysis program in all planes ($P < 0.05$).
Conclusion: The reference of ankle kinematics of Thai adults was established and differences between sides and the normal values of the motion analysis program were identified. Advanced age was associated with ankle internal rotation, and male gender was related to external foot progression. Further studies are needed to define all-age group reference values.

KEYWORDS

motion analysis, foot progression, ankle rotation, gender, culture

Introduction

The ankle joint mainly interacts with the ground to facilitate walking and performing activities (1). Its motions are varus-valgus occurring in the frontal plane; dorsiflexion-plantar flexion in the sagittal plane; foot progression and ankle rotation in the transverse plane (2, 3). The three-dimensional motion analysis system is widely used to evaluate ankle movements (4–8). This method requires a normal reference from healthy population to differentiate from abnormal conditions. Nevertheless, the reference value may not be universally applicable for every settings and populations (9).

Various references of ankle kinematics and possible contributing factors have been researched. Previous studies have proposed age, gender, culture (10), body shape, gait parameters (11), motion systems, settings (12), ethnic and geography (9, 11). Age and ethnics were primary factors related to ankle kinematics (9–11, 13–16). A systematic review and meta-analysis highlighted that advanced age diminished ankle motions, particularly in the sagittal plane (13). Elderly tended to have weaker plantar flexor leading to limited ankle moment at push-off than the younger age (14, 15). The best available evidence in Thai adults, aged 20–69 years, found ankle dorsiflexion-plantar flexion at toe off significantly reduced after age of 40 years (16). However, the authors investigated only the sagittal plane of ankle kinematics and did not compare with the standard reference of the motion system. Furthermore, they used the VICON system which cannot be applied to alternate motion analysis platforms.

Since the ankle kinematics varied among race, anthropometry, gait parameters, setting, and only sagittal plane was available among Thai adults, this study was aimed to investigate 3-dimension ankle kinematics in healthy Thai adults to provide better understanding our country-specific ankle kinematic pattern, and establish normative data as a reference of ankle joint complex in all dimensions. Even though the hips, knees, and ankles contributed to gait analysis, we would like to focus on the ankle joint to specify the reference values in all planes and compared with those of the motion analysis program. We included Thais, mostly indifferent geography, and our setting used the Motion Analysis program. This brought us to focus on age, gender, and BMI that could be related with the ankle kinematics and compared the reference values of the motion analysis program to ours. The results from this study would add the reference values not only ankle dorsiflexion-plantar flexion, but also ankle varus-valgus, foot progression, and ankle rotation; factors related with the ankle kinematics; and demonstrated how they differed from those of the motion analysis program. Moreover, the new reference values would help determining abnormal motion such as ankle instability, neuromuscular disorders, and deformity.

Methods

A prospective cohort was conducted at Gait Laboratory, Department of Orthopaedics between 2016 and 2020. This study was approved by the Ethics Committee of Faculty of Medicine Ramathibodi Hospital (ID 06-59-26ว).

Participants

Healthy Thai volunteers were included if their ages were between 18 years and 40 years in which presented the mature gait pattern; had a BMI between 18.5 and 25 kg/m^2; and willing to participate in the study. This age range could avoid the toe-off reduction effect after 40 years old (16) and is commonly used to establish normal gait data (11, 17, 18). The exclusion criteria were having orthopedic problems within last 6 months; neuromuscular disorders; or loss of balance control.

Procedures

After providing informed consent, all volunteers underwent motion analysis. Regarding the modified Helen Hayes technique, 29 reflective markers were attached over participants' bony landmarks and both ankles, **Figure 1** (18). All participants were asked to walk across 8 meters of the walkway, for 8–10 rounds with their preferred walking speed. Eight digital cameras captured all walking motion and Cortex software, Motion Analysis Corp, Santa Rosa, CA was used to track and process data. After ensuring the participants were familiar with their walking and all reflective markers were detected, the best 6 right, and 6 left gait cycles (2 cycles of 3 gait trials) were averaged and computed joint angle pattern for each participant. Gait velocity (m/s), stride length (m), and step length (m) were evaluated. Ankle kinematics in the frontal plane: ankle varus-valgus; the sagittal plane: dorsiflexion-plantar flexion; the transverse plane: foot progression, and also ankle rotation was assessed in degrees by motion analysis software (Orthotrak, Motion Analysis Corp).

Data collection

We collected independent variables as gender, age, weight (kg), height (cm), body mass index; BMI (kg/m^2), gait velocity, stride length, and step length, and dependent variables as the mean and standard deviation of ankle kinematics in all planes at heel strike, mid-stance, terminal stance, and mid-swing phases of the gait cycle. The ankle kinematic data was reported %gait cycle (0–100%) for each plane and defined as heel strike 0%–2%, mid-stance 12%–

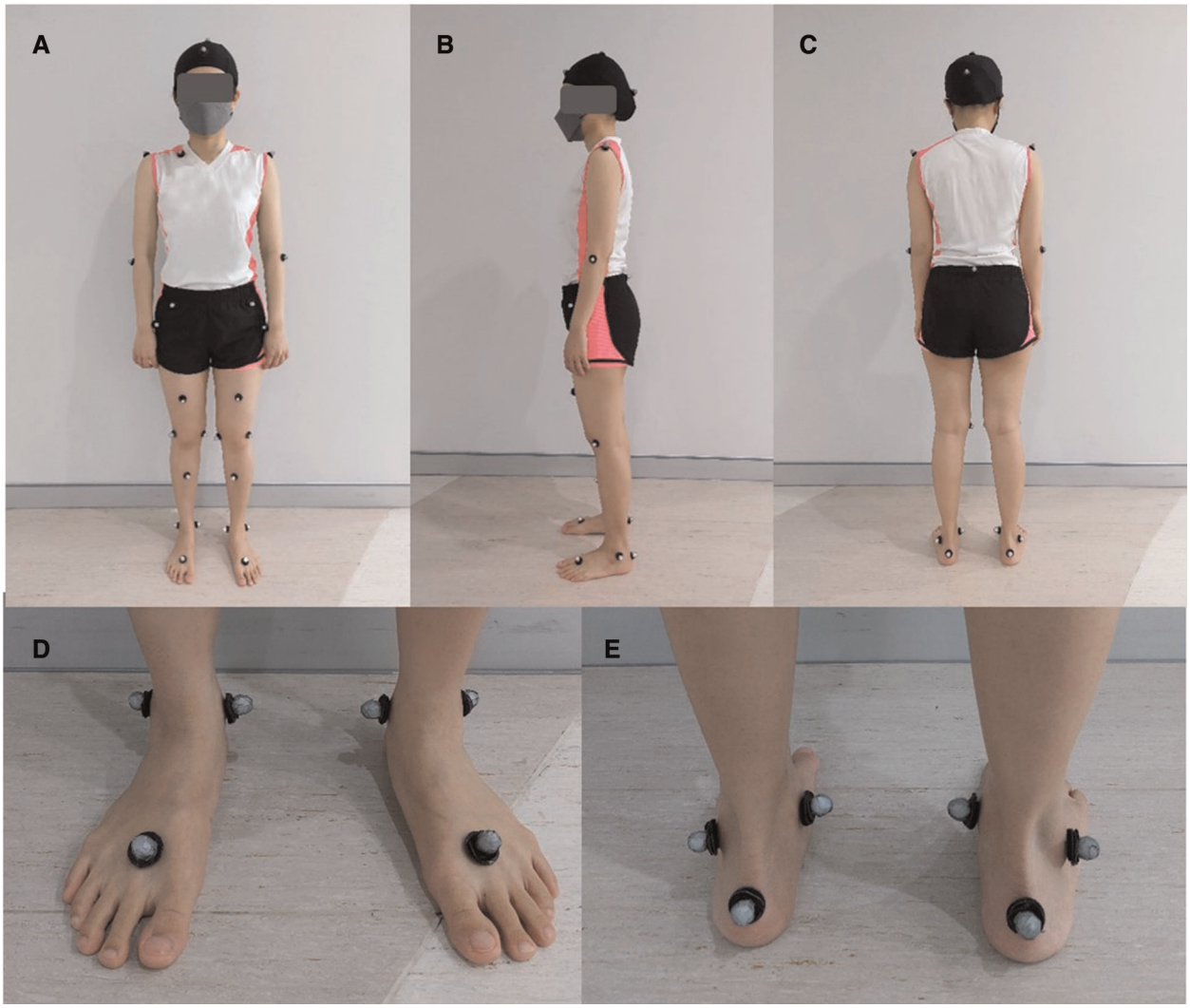

FIGURE 1
The modified Helen Hayes technique with 29 reflective markers included medial knees, (A) front, (B) side, and (C) back; and medial malleoli of the ankles, (D) front, and (E) back.

31%, terminal stance 31%–50%, and mid-swing 74%–87% of the gait cycle (19). The ankle kinematics were retrieved from the reference of the motion analysis program (20) for gait laboratories (OrthoTrak software, Motion Analysis Corporation, Santa Rosa, CA, USA) in order to compare with ours at a point of gait cycle i.e., heel strike, mid-stance, terminal stance and mid-swing.

Statistical analysis

Baseline characteristics were presented as mean (standard deviation) for continuous variables and frequency (percentage) for categorical data. Ankle kinematics were summarized and compared between sides using paired t-test or Wilcoxon signed-rank test, in case of a non-normal distribution. Our ankle kinematic data was compared to the motion analysis reference using one-sample t-test or Wilcoxon signed-rank test. The relationship between age, gender, BMI and ankle kinematics was assessed by using linear regression reported as beta coefficient with 95% confidence interval (CI). Two-tailed tests with P-values 0.05 were considered statistically significant. Estimated sample size was 98, based on an alpha error of 0.05, beta error of 0.2, mean ankle dorsiflexion at mid-stance from a pilot study of 9.35 ± 1.2 degrees), and that mean from the previous study of Thai adults of 10.21 ± 3.16 degrees (16). All analysis was performed using STATA version 15.0 (StataCorp, College Station, Texas 77845 USA).

In order to observe the full-time series of the angle assessments, statistical parametric mapping (SPM) was performed. The two-tailed paired t-test was used to compare the ankle kinematics between sides. The comparison between the ankle kinematic angle of Thai adults and the reference values supplied by the motion analysis program were computed by two-tailed unpaired t-test at each time point of right and left gait cycles. SPM was implemented in MATLAB (R2020b, The MathWorks Inc) using open-source code (M.0.4.8, www.spm1d.org). The significance level was set at $\alpha = 0.05$.

Results

Participant's demographic data

A total of 98 volunteers aged average of 28.6 ± 5.4 years, 62 (63.3%) of them were female. The mean height was 165.6 ± 7.6 cm and mean weight was 58.3 ± 9.2 kg. The mean BMI was 21.2 ± 2.0 kg/m^2. Demographic data were presented in Table 1.

Ankle kinematics

Ankle kinematics were reported as ankle varus-valgus, ankle dorsiflexion-plantar flexion, foot progression, and ankle rotation. From Table 2, the right and left ankles were in the varus position at heel strike and mid-swing. For the sagittal and transverse planes, there was ankle dorsiflexion, external foot progression and ankle internal rotation entire gait cycle. The average ankle kinematics entire gait cycle ranged from −1.62 to 3.17 degrees for varus-valgus, 0.67 to 14.52 degrees for dorsiflexion-plantar flexion, −21.73 to −8.47 degrees for foot progression, and 5.22–9.74 degrees for ankle rotation (Table 3).

TABLE 1 Participants demographic data.

Characteristics	$N = 98$
Age (year), mean (SD)	28.6 (5.4)
Gender (*N*, %)	
Female	60 (61.2)
Male	38 (38.8)
Height (cm), mean (SD)	165.6 (7.6)
Weight (kg), mean (SD)	58.3 (9.2)
BMI (kg/m^2), mean (SD)	21.2 (2.0)
Gait velocity (m/s), mean (SD)	1.1 (0.1)
Stride length (m), mean (SD)	1.2 (0.1)
Right step length (m), mean (SD)	0.6 (0.0)
Left step length (m), mean (SD)	0.6 (0.0)

SD = standard deviation.

TABLE 2 The comparison of ankle kinematics between sides.

Ankle kinematics (degree)	Right ($N = 98$)		Left ($N = 98$)		*P*-value
	Mean	SD	Mean	SD	
Varus-valgus					
Heel strike	1.771	9.157	3.583	9.204	0.201
Mid-stance	−2.657	8.907	−0.571	9.030	0.082
Terminal stance	−1.609	9.830	0.587	9.996	0.102
Mid-swing	2.386	8.802	3.963	8.695	0.179
Dorsiflexion-plantar flexion					
Heel strike	0.818	3.269	0.522	3.119	0.433
Mid-stance	7.437	2.956	6.912	3.046	0.077
Terminal stance	14.626	3.047	14.404	3.065	0.494
Mid-swing	3.719	3.717	3.049	3.946	0.081
Foot progression					
Heel strike	−12.148	5.197	−10.772	6.147	0.004*
Mid-stance	−9.122	5.069	−7.818	6.201	0.011*
Terminal stance	−11.179	5.205	−9.718	6.380	0.005*
Mid-swing	−22.175	7.035	−21.280	7.467	0.119
Rotation					
Heel strike	5.437	6.444	5.463	5.111	0.968
Mid-stance	5.224	6.501	5.221	5.351	0.937
Terminal stance	5.297	6.239	5.668	5.087	0.559
Mid-swing	9.339	7.043	10.132	5.726	0.298

+ = ankle varus, dorsiflexion, internal rotation and internal foot progression; − = ankle valgus, plantar flexion, external foot progression and external rotation.
*Significant *P*-value < 0.05.

Side difference

The ankle kinematics were not statistically different between sides, except foot progression at the stance phase ($P = 0.004$ at heel strike, $P = 0.011$ at mid-stance, and $P = 0.005$ at terminal stance). Descriptive data of bilateral 3-dimension ankle kinematics were presented in Table 2. SPM analysis showed significantly different foot progression at initial contact ($P = 0.041$) and terminal stance ($P = 0.004$) between sides, Figure 2.

Reference data

Inception data of ankle kinematics at heel strike, mid-stance, terminal stance, and mid-swing were summarized as graphs (Figure 3). Comparing to the reference of the motion analysis program, our ankle kinematics significantly increased ankle varus, dorsiflexion, internal rotation of foot progression and ankle rotation ($P < 0.001$), except ankle varus-valgus at mid-stance ($P = 0.19$) (Table 3 and Figure 4). Regarding SPM analysis stratified by sides, the ankle kinematic angle of ours significantly differed from the reference values supplied by the

TABLE 3 The comparison between different reference data sets.

Ankle kinematics (degree)	Thai adults ($N = 98$)		Motion analysis Software		*P*-value
	Mean	SD	Mean	SD	
Varus-valgus					
Heel strike	2.677	7.676	−0.250	0.399	<0.001*
Mid-stance	−1.614	7.601	−0.869	0.563	0.186
Terminal stance	−0.512	8.371	−2.553	1.129	0.029*
Mid-swing	3.174	7.355	−0.189	0.316	<0.001*
Dorsiflexion-plantar flexion					
Heel strike	0.670	2.738	1.588	1.648	0.001*
Mid-stance	7.174	2.624	4.190	1.370	<0.001*
Terminal stance	14.515	2.602	12.716	1.241	<0.001*
Mid-swing	3.384	3.372	0.921	2.635	<0.001*
Foot progression					
Heel strike	−11.459	5.216	−16.359	3.965	<0.001*
Mid-stance	−8.469	5.118	−11.572	2.600	<0.001*
Terminal stance	−10.448	5.268	−13.406	2.559	<0.001*
Mid-swing	−21.728	6.686	−25.957	6.849	<0.001*
Rotation					
Heel strike	5.452	4.796	−8.661	5.040	<0.001*
Mid-stance	5.222	4.918	−12.095	4.338	<0.001*
Terminal stance	5.482	4.709	−10.743	3.524	<0.001*
Mid-swing	9.736	5.323	−7.081	4.715	<0.001*

+ = ankle varus, dorsiflexion, internal foot progression and internal rotation, − = ankle valgus, plantar flexion, external foot progression and external rotation.
*Significant *P*-value < 0.05.

motion program in all planes (Figure 5). Significant *P*-value of each plane (Figure 5) were demonstrated as varus-valgus (left side: $P = 0.047$, 0.004, and 0.004; right side: $P = 0.001$), dorsiflexion-plantar flexion (left side: $P = 0.042$, <0.001, 0.004, and 0.006; right side: $P = 0.009$, < 0.001, 0.002, and 0.016), foot progression (left side: $P < 0.001$, and 0.047; right side: $P <$ 0.001, and 0.046), and ankle rotation ($P < 0.001$ for both sides).

Relationship with age, gender, and BMI

According to significant side difference in foot progression (Table 2), the right and the left side were taken into account by separately relating with age, gender and BMI. From Table 4, advanced age had significantly correlated with ankle internal rotation at mid-swing (beta coefficient 0.21, $P =$ 0.039), and tended to have ankle valgus, plantar flexion with external foot progression. Male gender had approximately 5 degrees more external foot progression than the female group at heel strike, mid-stance, and terminal stance of the right (P = 0.002, 0.002, and 0.008, respectively) and the left sides ($P = 0.006$, 0.012, and 0.032, respectively). The relationship between BMI did not reach statistical significance with the ankle kinematics in all planes (Table 4).

Discussion

This prospective study established normative 3-dimension ankle kinematic references including foot progression for Thai adults. We found significant difference between our data and the motion analysis reference in all planes, except ankle varus-valgus in mid-stance. Foot progression differed between sides and related well with gender. Age was significantly associated with ankle rotation at mid-swing, whereas there was no significant relationship between ankle kinematics and BMI.

Ankle kinematics varied with regards to racial, cultural, and ethnic properties. Im et al. (11) compared gait characteristics between Korean and Western young adults. Most of motion patterns and excursions were similar but ranges of angles were different. Average ankle motion of Koreans (Motion Analysis) was −1.9 to 3.3, −17.5 to 10.8 and −17.3 to −3.5 degrees for inversion-eversion, dorsiflexion-plantar flexion, and rotation, respectively (11). Although the mean ankle kinematics from Western's studies (Elite, VICON) were −3.2 to 9.2 (21) for inversion-eversion, and −22.6 to 10.9 (21) and −14.0 to 11.5(18) for dorsiflexion-plantarflexion, and −19.0 to −5.0 for rotation (18), our ankle motion obviously showed more varus, dorsiflexion, internal foot progression, and ankle internal rotation (Table 5) when compared to the motion analysis program and other studies (11, 18, 21). For ankle dorsiflexion, it resembled Cho et al (17), and Brockett et al (2), but was contradictory to the other reports of plantar flexion during the first rocker (11, 16, 18, 21). Our data showed striking ankle internal rotation (min-max difference 4.68, average total rotation 20.48, standard deviation 8.46), while the study from Korea (11) using the same motion analysis system reported min-max difference of −17.3, average total rotation −3.50 (standard deviation 13.8). This emphasizes that culture, anthropometry, and other factors might contribute to these differences (9).

Ankle kinematics may vary between sides. The previous study demonstrated 3–5 degrees of ankle dorsiflexion-plantar flexion differences (22). Our study found that only foot progression at the stance phase was 1–2 degrees different between sides, and associated with gender. The right foot was significantly more external rotated that the left one. Males demonstrated external foot progression or out-toeing about 5 degrees more than females. Men's habits or lifestyles may alter foot progression at the stance phase. Cibulka et al (23) reported an average foot progression in men was 3 degrees more external rotation than in women. The authors proposed the tibiofemoral external torsion might contribute to external

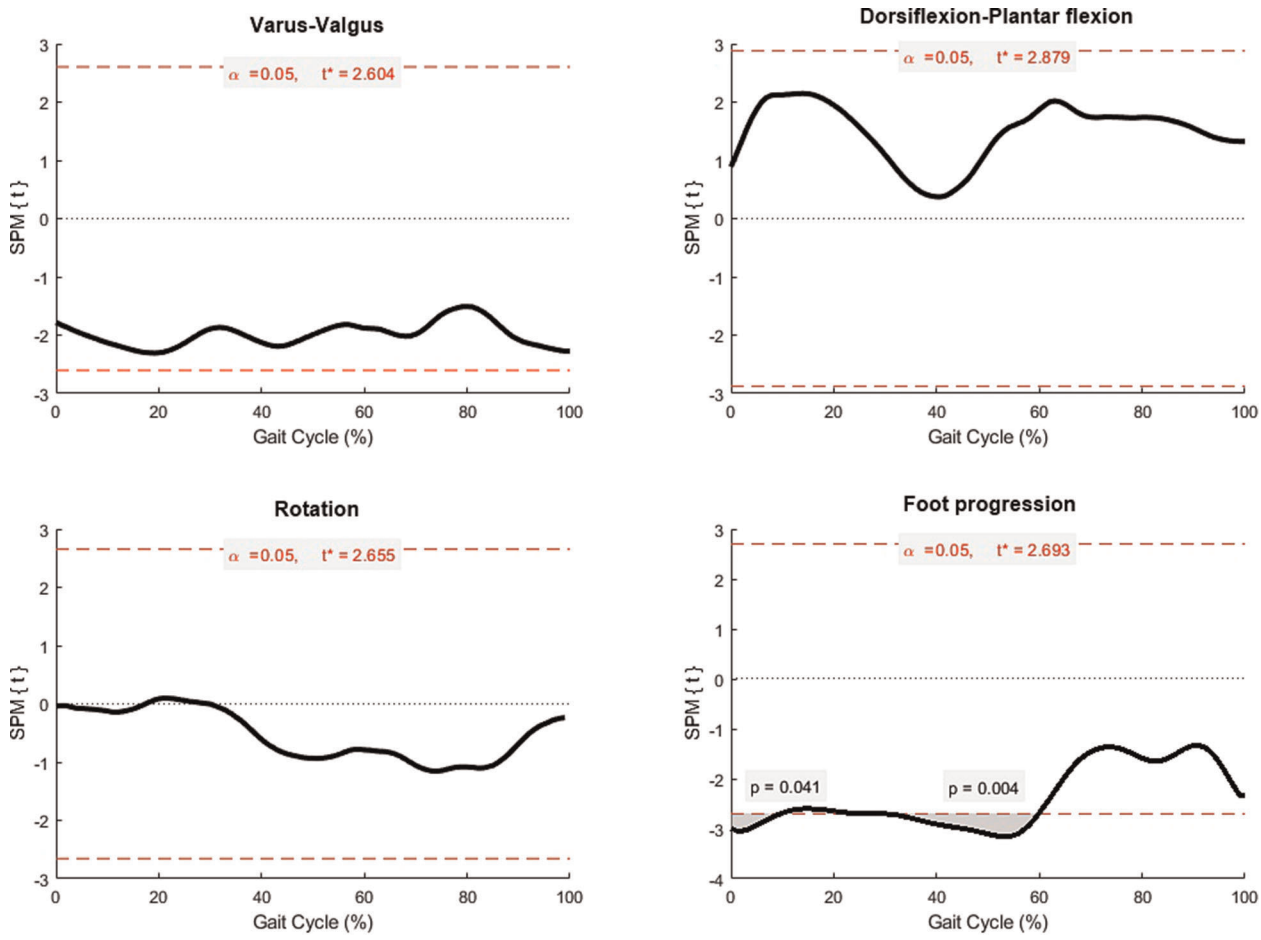

FIGURE 2
Statistical parametric mapping (SPM) comparing ankle kinematics between sides (black line), and grey area represented significant difference at points of time with $P < 0.05$.

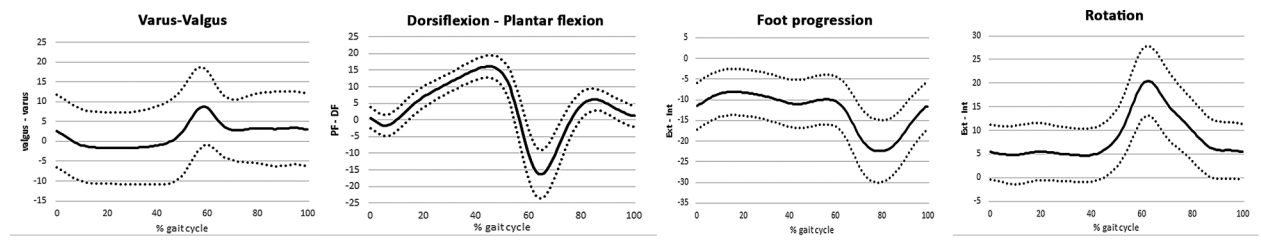

FIGURE 3
Ankle kinematic curves (degree) during gait cycle from our reference, mean (solid line) and standard deviation (dotted line), PF = plantar flexion, DF = dorsiflexion, Ext = external rotation, and Int = internal rotation.

foot progression, whilst hip internal rotation was associated with internal foot progression. However, other studies concluded that gender had no effect on ankle kinematics without considering the foot progression (11, 16–18).

Participants' age ranges between 18 and 40 years old usually express the mature gait pattern, with less variability when compared with children, and are unaffected from degenerative changes when compared to the elderly. Our study

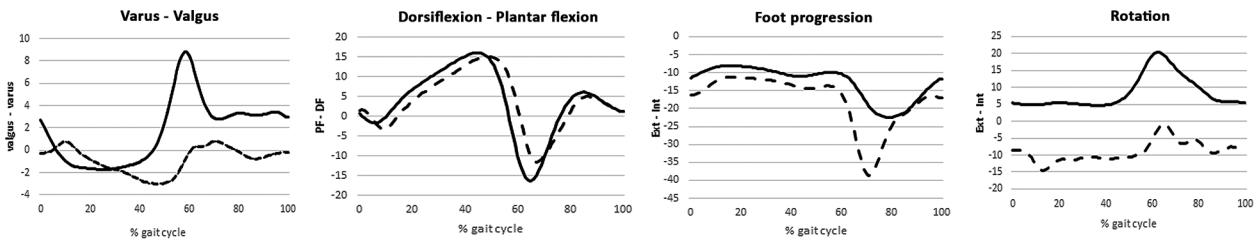

FIGURE 4
The comparison of ankle kinematics between our data (solid line) and the motion analysis reference (broken line), PF = plantar flexion, DF = dorsiflexion, Ext = external rotation, and Int = internal rotation.

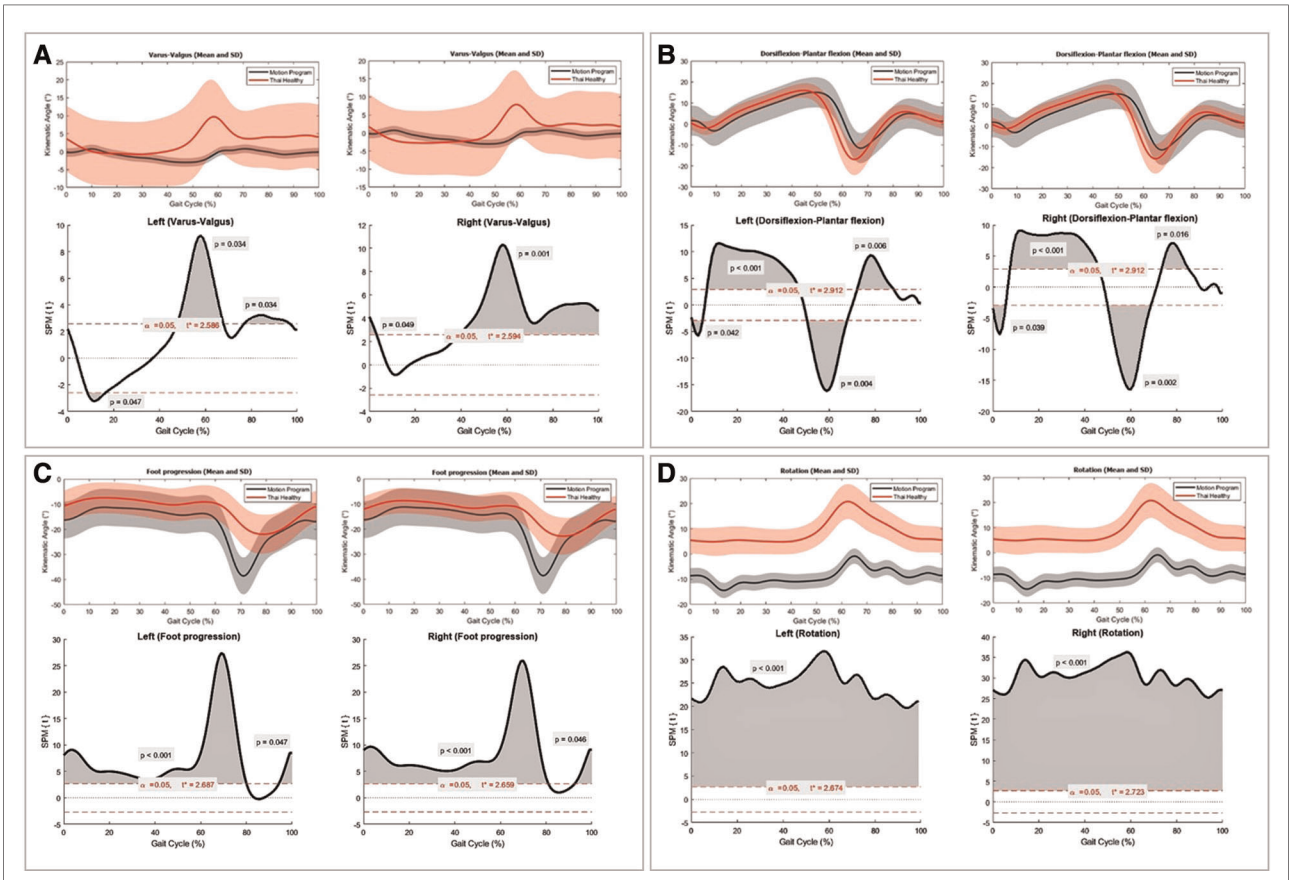

FIGURE 5
The comparisons of right and left ankle kinematics between Thai adults (red), the reference values of the motion analysis program (grey), mean (line) and standard deviation (shaded area). Statistical parametric mapping (SPM) demonstrated full-time series analysis of different ankle kinematics between two data sets (black curve). Grey areas under the black curve represented significant differences at gait cycle (%) point of time with $P < 0.05$. (A) varus-valgus, (B) dorsiflexion-plantar flexion, (C) foot progression, and (D) ankle rotation planes.

demonstrated significant association between age 18 and 40 years and ankle rotation at mid-swing (0.21-degree per increment 1 year of age). The ankle kinematics in other planes, especially dorsiflexion-plantar flexion was not significantly different in this young age range. Praditpod et al (16) conducted the sagittal plane gait analysis in healthy Thais, aged 20–69 years old, using the VICON system. The authors found that advanced age was negatively correlated with ankle dorsiflexion-plantarflexion at toe-off, without correlation at heel contact, foot flat, mid-stance and heel off.

TABLE 4 The relationship between ankle kinematics and age, gender, and BMI.

Ankle kinematics (degree)	Age (years)			Male gender			BMI (kg/m^2)		
	Coefficient	95% CI	*P*-value	Coefficient	95%CI	*P*-value	Coefficient	95%CI	*P*-value
Varus-valgus									
Heel strike	−0.04	−0.32, 0.25	0.802	0.51	−2.66, 3.68	0.750	0.60	−0.15, 1.35	0.117
Mid-stance	0.04	−0.24, 0.32	0.784	0.32	−2.82, 3.46	0.840	0.64	−0.11, 1.39	0.092
Terminal stance	0.08	−0.23, 0.39	0.599	−0.08	−3.54, 3.38	0.964	0.62	−0.20, 1.45	0.136
Mid-swing	0.02	−0.25, 0.30	0.858	−0.21	−3.26, 2.83	0.889	0.55	−0.17, 1.27	0.134
Dorsiflexion-plantar flexion									
Heel strike	−0.06	−0.16, 0.05	0.287	0.88	- 0.23, 2.00	0.120	−0.01	−0.28, 0.26	0.938
Mid-stance	−0.017	−0.12, 0.08	0.729	0.99	−0.07, 2.06	0.067	−0.03	−0.29, 0.23	0.803
Terminal stance	−0.01	−0.11, 0.08	0.782	−0.16	−1.24, 0.91	0.767	0.09	−0.16, 0.35	0.475
Mid-swing	−0.08	−0.20, 0.05	0.213	0.77	−0.61, 2.16	0.272	−0.24	−0.58, 0.09	0.146
Right foot progression									
Heel strike	−0.05	−0.24, 0.15	0.634	−3.34	−5.38, −1.30	0.002*	−0.44	−0.95, 0.07	0.087
Mid-stance	−0.03	−0.22, 0.16	0.756	−3.18	−5.17, −1.18	0.002*	−0.39	−0.89, 0.10	0.116
Terminal stance	−0.05	−0.25, 0.14	0.599	−2.84	−4.92, −0.76	0.008*	−0.36	−0.87, 0.16	0.171
Mid-swing	−0.22	−0.48, 0.04	0.092	1.65	−1.24, 4.54	0.261	0.14	−0.56, 0.84	0.693
Left foot progression									
Heel strike	−0.03	−0.26, 0.19	0.781	−3.49	−5.93, −1.05	0.006*	−0.37	−0.98, 0.24	0.228
Mid-stance	−0.07	−0.30, 0.16	0.553	−3.19	−5.67, −0.70	0.012*	−0.34	−0.96, 0.27	0.271
Terminal stance	−0.10	−0.34, 0.14	0.393	−2.83	−5.40, −0.25	0.032*	−0.32	−0.95, 0.31	0.314
Mid-swing	−0.22	−0.50, 0.05	0.109	1.15	−1.94, 4.23	0.462	−0.12	−0.86, 0.62	0.753
Rotation									
Heel strike	0.13	−0.05, 0.31	0.147	0.38	−1.60, 2.36	0.705	0.40	−0.07, 0.87	0.093
Mid-stance	0.17	−0.01, 0.35	0.062	0.44	−1.59, 2.47	0.668	0.28	−0.20, 0.77	0.248
Terminal stance	0.14	−0.04, 0.31	0.121	0.06	−1.88, 2.01	0.948	0.15	−0.31, 0.63	0.505
Mid-swing	0.21	0.01, 0.40	0.039*	−8.67	−3.06, 1.33	0.434	0.46	−0.06, 0.98	0.085

*Significant *P*-value < 0.05.

According to restraint strength of plantar flexor, the elderly tended to have lesser plantar flexion, and ankle moment at push-off than the younger age (14, 15). BMI did not contribute to ankle joint kinematics changes, but high body mass tended to increase ankle varus, plantar flexion, external foot progression, and ankle internal rotation. Recent study compared the difference of BMI groups on the change of gait kinematics by using the H-Gait system with inertial sensors to record gait data (24), they showed no difference of ankle kinematics between BMI 18.5 and 25 kg/m^2. This finding was similar to our study, even though we used Motion analysis software for gait analysis.

Apart from different gait analysis systems, discrepancy of measurement may indicate variation of ankle kinematics within population. Regarding an ankle joint complex, gait analysis cannot separately measure rotation and other movements of talar joints (2). Skin motion artifact affects joint movement in the frontal and transverse planes (21). The amount of discrepancy among adduction–abduction, flexion–extension, and internal–external rotation are roughly to 50%, 10% and 100%, respectively (21). In addition, deviations between intra- and inter-examiner can occur in the position of marker on anatomical landmark which has a difference about 6–21 and 13–25 millimeters, respectively (22). Different marker models might influence ankle kinematic results. Kadaba and colleague designed the marker system of Helen Hayes and found significant errors in the ankle inversion-eversion and rotation angles throughout the gait cycle (18). Although our study referred the Helen Hayes marker set from previous studies (18), we modified it by adding the medial knee and the medial malleolus markers. We ensured perfect marker positions since all of our participants had normal BMI and well-prominent bony landmarks. All 29 markers, including hidden medial knees, were clearly detected by digital cameras and well-connected together in the program.

In light of limited evidence of the normal gait pattern in Thailand, we are able to define the reference values of gait in Thai adults. The strengths of this study are objective measurements of ankle kinematics using standardized Motion Analysis Software, adequate sample size, and appropriate

TABLE 5 The comparison of ankle kinematics between studies.

Variables	Our study (*N* = 98)	Im et al. (11) 2006 (*N* = 32)	Cho et al. (17) 2004 (*N* = 98)	Benedetti et al. (21) 1998 (*N* = 20)	Kadaba et al. (18) 1990 (*N* = 40)
Setting	Thailand	Korea	Korea	Italy	USA
Age (year), mean (range)	28.6 (18–40)	Female = 25 Male = 24.1	Female = 22.9 Male = 23.5	43 (20 −72)	NA (18–40)
Measurement system	Motion Analysis Santa Rosa, USA	Motion Analysis Santa Rosa, USA	VICON 370 Oxford, UK	Elite system Milano, Italy	VICON Oxford, UK
Gait velocity (m/s), mean (SD)	1.12 (0.1)	1.14 (0.1)	1.16 (0.1)	1.26 (0.2)	1.34 (0.2)
Stride length (m), mean (SD)	1.20 (0.1)	1.27 (0.1)	1.21 (0.1)	1.40 (0.2)	1.41 (0.1)
Total varus-valgus (degree)					
Min-max difference	−1.7	−1.9	NA	−3.2	NA
Mean (SD)	8.8 (1.8)	3.3 (5.2)		9.2 (13.4)	
Total dorsiflexion-plantar flexion (degree)					
Min-max difference	−16.3	−17.5	−12.0	−22.6	−14.0
Mean (SD)	16.1 (3.6)	10.8 (28.3)	19.5 (31.5)	10.9 (33.5)	11.5 (25.5)
Total rotation (degree)					
Min-max difference	4.7	−17.3	NA	NA	−19.0
Mean (SD)	20.5 (8.5)	−3.5 (13.8)			−5.0 (14.0)

NA = not available; SD = standard deviation; + = ankle varus, dorsiflexion, internal rotation and internal foot progression; − = ankle valgus, plantar flexion, external foot progression and external rotation.

statistical analysis. Our study established kinematics of the ankle joint complex which is involved in motion of the foot and ankle in ankle varus-valgus, ankle dorsiflexion-plantar flexion, foot progression and ankle rotation. Moreover, we added the factor of BMI accompanied with ankle motion of healthy subjects in addition to previous evidences. This reference is useful to understand ankle movement pattern of Thai adults and may use to detect gait problem in patients with ankle injury and neuromuscular problems in the future. Moreover, factors related to ankle kinematics might predict some pathology, i.e., ankle internal rotation in advanced age. The limitations of our study are (1) unable to generalize for adults older than 40 years; (2) inconsiderate hip and knee kinematics; and (3) unavailable baseline characteristics of the motion analysis reference data to be compared. Race and culture may affect gait pattern such as cadence and joint moment (17). Walking speed is a main factor influences the ankle-foot complex plantarflexion at toe-off and during swing phases (11, 21). Further study of all hip, knee, and ankle kinematics is needed to provide reference values of complete gait analysis. Also, the effect of gait characteristics on joint kinematics as well as race and cultural background should be investigated. According to Thai traditionally culture, we hypothesize that females are most familiar with a sit one leg tucked back to one side or side monk. Similar to W-sitting with one leg, this posture promotes femoral internal rotation. This may lead to internal rotation of the foot during walking and decreasing external rotated foot progression, particularly in females.

Conclusion

This study established the normal reference ankle kinematics of Thai adult, aged 18–40 years, which is significantly different from that of the motion analysis program in all three planes. External foot progression was appeared on the right more than the left side, and males more than females. The greater age was correlated with the ankle internal rotation. This new reference value may be suitable for Thai adults, and further population-based study is required to estimate reference values for all age groups.

Data availability statement

The original contributions presented in the study are included in the article/Supplementary Material, further inquiries can be directed to the corresponding author/s.

Ethics statement

The studies involving human participants were reviewed and approved by Ethics Committee of Faculty of Medicine Ramathibodi Hospital. The patients/participants provided their written informed consent to participate in this study.

Author contributions

KK, PW, CA and TP contributed to research design. KK, TP and JS performed the data collection and analysis. PW and CA proceed data interpretation. KK, TW, and PW writing, and critically revising the manuscript. All authors contributed to the article and approved the submitted version.

Funding

This study was supported by Faculty of Medicine Ramathibodi Hospital, Mahidol University

Conflict of interest

The authors declare that the research was conducted in the absence of any commercial or financial relationships that could be construed as a potential conflict of interest.

Publisher's note

All claims expressed in this article are solely those of the authors and do not necessarily represent those of their affiliated organizations, or those of the publisher, the editors and the reviewers. Any product that may be evaluated in this article, or claim that may be made by its manufacturer, is not guaranteed or endorsed by the publisher.

References

1. Aquino MRC, Resende RA, Kirkwood RN, Souza TR, Fonseca ST, Ocarino JM. Spatial-temporal parameters, pelvic and lower limb movements during gait in individuals with reduced passive ankle dorsiflexion. *Gait Posture*. (2022) 93:32–8. doi: 10.1016/j.gaitpost.2022.01.010

2. Brockett CL, Chapman GJ. Biomechanics of the ankle. *Orthop Trauma*. (2016) 30:232–8. doi: 10.1016/j.mporth.2016.04.015

3. Ravella KC, Ahmad J, Amirouche F. Biomechanics of the Ankle Joint. In: Koh J, Zaffagnini S, Kuroda R, Longo UG, Amirouche F, editors. *Orthopaedic Biomechanics in Sports Medicine*. Cham: Springer International Publishing (2021) p. 401–13.

4. Middleton K, Vickery-Howe D, Dascombe B, Clarke A, Wheat J, McClelland J, et al. Mechanical differences between men and women during overground load carriage at self-selected walking speeds. *Int J Environ Res Public Health*. (2022) 19:3927–41. doi: 10.3390/ijerph19073927

5. Watabe T, Takabayashi T, Tokunaga Y, Watanabe T, Kubo M. Copers exhibit altered ankle and trunk kinematics compared to the individuals with chronic ankle instability during single-leg landing. *Sports Biomech*. (2022):1–13. doi: 10.1080/14763141.2022.2058989. [Epub ahead of print]

6. Balasukumaran T, Gottlieb U, Springer S. Spatiotemporal gait characteristics and ankle kinematics of backward walking in people with chronic ankle instability. *Sci Rep*. (2020) 10:11515. doi: 10.1038/s41598-020-68385-5

7. Wang Z-p, Qiu Q-e, Chen S-h, Chen B-c, Lv X-t. Effects of unstable shoes on lower limbs with different speeds. *Phys Act Health*. (2019) 3:82–8. doi: 10.5334/paah.41

8. Ugbolue UC, Robson C, Donald E, Speirs KL, Dutheil F, Baker JS, et al. Joint angle, range of motion, force, and moment assessment: responses of the lower limb to ankle plantarflexion and dorsiflexion. *Appl Bionics Biomech*. (2021) 2021:1232468. doi: 10.1155/2021/1232468

9. Al-Obaidi S, Wall JC, Al-Yaqoub A, Al-Ghanim M. Basic gait parameters: a comparison of reference data for normal subjects 20 to 29 years of age from Kuwait and Scandinavia. *J Rehabil Res Dev*. (2003) 40:361–6. doi: 10.1682/jrrd.2003.07.0361

10. Grimston SK, Nigg BM, Hanley DA, Engsberg JR. Differences in ankle joint complex range of motion as a function of age. *Foot Ankle*. (1993) 14:215–22. doi: 10.1177/107110079301400407

11. Im W, Choe H, Jeong M, Ryu T, Choe H. A comparison of Gait characteristics between Korean and Western Young People. *J Ergon Soc Korea*. (2006) 25:33–42. doi: 10.1016/j.ergon.2006.09.013

12. Mündermann L, Corazza S, Andriacchi TP. The evolution of methods for the capture of human movement leading to markerless motion capture for biomechanical applications. *J Neuroeng Rehabil*. (2006) 3:6. doi: 10.1186/1743-0003-3-6

13. Boyer KA, Johnson RT, Banks JJ, Jewell C, Hafer JF. Systematic review and meta-analysis of gait mechanics in young and older adults. *Exp Gerontol*. (2017) 95:63–70. doi: 10.1016/j.exger.2017.05.005

14. Arnold JB, Mackintosh S, Jones S, Thewlis D. Differences in foot kinematics between young and older adults during walking. *Gait Posture*. (2014) 39:689–94. doi: 10.1016/j.gaitpost.2013.09.021

15. Jung S, Yi J, Song C. Biomechanical alterations of gait termination in middle-aged and elderly women. *J Phys Ther Sci*. (2016) 28:861–7. doi: 10.1589/jpts.28.861

16. Praditpod N, Tantipoon P. Effects of age and gender on reference value of kinematic gait parameters among healthy Thai adults aged 20-69 years. *JMTPT*. (2016) 28:308–21. doi: 10.14456/arch-ahs

17. Cho SH, Park JM, Kwon OY. Gender differences in three dimensional gait analysis data from 98 healthy Korean adults. *Clin Biomech (Bristol, Avon)*. (2004) 19:145–52. doi: 10.1016/j.clinbiomech.2003.10.003

18. Kadaba MP, Ramakrishnan HK, Wootten ME. Measurement of lower extremity kinematics during level walking. *J Orthop Res*. (1990) 8:383–92. doi: 10.1002/jor.1100080310

19. Silva LM, Stergiou N. Chapter 7 – The basics of gait analysis. In: N Stergiou, editors. *Biomechanics and gait analysis*. Nebraska: Academic Press (2020). p. 225–50.

20. Sutherland DH. The evolution of clinical gait analysis. Part II kinematics. *Gait Posture*. (2002) 16:159–79. doi: 10.1016/s0966-6362(02)00004-8

21. Benedetti MG, Catani F, Leardini A, Pignotti E, Giannini S. Data management in gait analysis for clinical applications. *Clin Biomech (Bristol, Avon)*. (1998) 13:204–15. doi: 10.1016/s0268-0033(97)00041-7

22. Moriguchi C, Sato T, Coury HJC. Ankle movements during normal gait evaluated by flexible electrogoniometer. *Braz J Phys Ther*. (2007) 11:205–11. doi: 10.1590/S1413-35552007000300006

23. Cibulka MT, Winters K, Kampwerth T, McAfee B, Payne L, Roeckenhaus T, et al. Predicting foot progression ankle during gait using two clinical measures in healthy adults, A preliminary study. *Int J Sports Phys Ther*. (2016) 11:400–8.

24. Rosso V, Agostini V, Takeda R, Tadano S, Gastaldi L. Influence of BMI on gait characteristics of young adults: 3D evaluation using inertial sensors. *Sensors (Basel)*. (2019) 19:4221. doi: 10.3390/s19194221

frontiers | Frontiers in Surgery

TYPE Case Report
PUBLISHED 30 August 2022
DOI 10.3389/fsurg.2022.918303

Check for updates

OPEN ACCESS

EDITED BY
Paphon Sa-ngasoongsong,
Ramathibodi Hospital, Mahidol University, Thailand

REVIEWED BY
Kerstin Hagberg,
Sahlgrenska University Hospital, Sweden
Samuel Oliver Poore,
University of Wisconsin-Madison, United States

*CORRESPONDENCE
Thomas Mittlmeier
thomas.mittlmeier@med.uni-rostock.de

SPECIALTY SECTION
This article was submitted to Orthopedic Surgery, a section of the journal Frontiers in Surgery

RECEIVED 12 April 2022
ACCEPTED 22 July 2022
PUBLISHED 30 August 2022

CITATION
Krause K, Richter K, Beyer T, Aschoff HH, Fischer D-C and Mittlmeier T (2022) Elective transfemoral amputation and simultaneous implantation of a transcutaneous osseointegrated prosthesis stem as salvage treatment after knee joint arthrodesis with poor function: A case report.
Front. Surg. 9:918303.
doi: 10.3389/fsurg.2022.918303

COPYRIGHT
© 2022 Krause, Richter, Beyer, Aschoff, Fischer and Mittlmeier. This is an open-access article distributed under the terms of the Creative Commons Attribution License (CC BY). The use, distribution or reproduction in other forums is permitted, provided the original author(s) and the copyright owner(s) are credited and that the original publication in this journal is cited, in accordance with accepted academic practice. No use, distribution or reproduction is permitted which does not comply with these terms.

Elective transfemoral amputation and simultaneous implantation of a transcutaneous osseointegrated prosthesis stem as salvage treatment after knee joint arthrodesis with poor function: A case report

Katharina Krause[1,2], Katherina Richter[1,2], Thomas Beyer[3], Horst Heinrich Aschoff[1], Dagmar-Christiane Fischer[2] and Thomas Mittlmeier[1]*

[1]Department of Traumatology, Hand and Reconstructive Surgery, University Medical Centre Rostock, Rostock, Germany, [2]Department of Pediatrics, University Medical Centre Rostock, Rostock, Germany, [3]Department of Diagnostic and Interventional Radiology, Pediatric Radiology and Neuroradiology, University Medical Centre Rostock, Rostock, Germany

Background: Surgical reconstruction of anterior cruciate ligament ruptures is a well-established procedure, and although it is for the vast majority of patients without severe complications, total knee joint arthroplasty, arthrodesis of the knee, and finally transfemoral amputation have to be considered in the worst-case scenario.
The case: We report a case of a patient with a 13-year history of recurrent failure after anterior cruciate ligament reconstruction. She claimed she had severely impaired mobility secondary to a knee joint arthrodesis *via* an Ilizarov circular frame 2 years ago and chronic immobilizing pain, making a permanent medication with opioids necessary. She was aware of the therapeutic options and asked for transfemoral amputation and concomitant supply with a transcutaneous osseointegrated prosthesis system (TOPS).
Procedures: After careful evaluation and clinical work-up, the indication for transfemoral amputation and concomitant implantation of the prosthetic stem into the femoral cavity was secured. Six weeks after the creation of the stoma for coupling of the artificial limb and onset of physiotherapy, balance and gait training were scheduled. Full weight-bearing and walking without crutches were allowed 12 weeks after the index procedure. This sequence of events was paralleled by a series of pre-defined examinations, that is, questionnaires and mobility scores addressing the situation of transfemoral amputees, as well as standardized clinical gait analysis. The latter was performed before surgery and 6, 9, and 18 months after the index procedure.
Outcome: At the time of the index procedure, opioids could be tapered to zero, and the patient quickly regained her walking abilities during the rehabilitation period. Clinical gait analysis confirmed the restoration of bilateral symmetry by mutual approximation of kinematics and kinetics to a standard gait pattern.

Conclusion: The outcome of our patient strengthens the therapeutic potential of a unilateral transfemoral amputation in combination with TOPS. Nevertheless, long-term follow-up is necessary to detect future complications of this approach.

KEYWORDS

ACL reconstruction, surgical complication, knee joint arthrodesis, transfemoral amputation, transcutaneous osseointegrated prosthesis system, gait analysis

Introduction

Anterior cruciate ligament (ACL) ruptures are among the most common knee injuries, and surgical reconstruction generally allows for return to pre-injury level of activity in 75%–97% of patients (1). However, failure of the procedure and severe complications such as persistent functional impairments, osteoarthritis, chronic pain, and deep infections may occur in a reasonable number of patients (1). In the worst-case scenario, total knee joint arthroplasty, arthrodesis of the knee, and transfemoral amputation have to be considered as salvage procedures (2, 3). Although the latter option is irreversible by nature, it has the potential to restore functional abilities if performed properly, that is, surgery and fitting with an artificial leg (4). In general, coupling between the artificial leg and the residual limb is achieved by the use of an individually designed socket and corresponding liner to ensure optimal fit and transfer of force required for walking with the artificial leg. Apart from problems related to force transmission, socket-related problems such as skin irritations ranging up to ulcerations, excessive sweating, time-consuming donning, and doffing are commonly noted [for a review, see other studies (5–9)]. During the last two to three decades, transcutaneous bone-anchored osseointegrated prosthesis systems (TOPS) have become a reliable alternative for rehabilitation, especially for patients with recurrent problems associated with the socket (7–11). While the risk of recurrent infections due to the transcutaneous implant turned out to be much lower than expected, switching from socket prosthesis to a bone-anchored one is associated with numerous advantages ranging from improved rehabilitation and autonomous mobility up to the restoration of osseoperception (7, 8, 10, 11). Apart from differences regarding the geometry, the retention as well as the bone- and skin-implant interfaces, and the abutment for connection of the exoprosthesis, the principle of function is always the same (12).

Case report

We report on a case of a 31-year-old woman who presented with a knee joint arthrodesis and an almost non-functioning leg, impeding her mobility and the care for her two children, ages 2 and 4 years, respectively. Clinical work-up revealed a 13-year history (**Figure 1A**) of recurrent failure following ACL reconstruction and numerous surgical interventions due to recalcitrant deep joint infection ending up with a knee joint arthrodesis *via* an Ilizarov circular frame (**Figure 1A**). Despite proven osseous fusion of the arthrodesis employing CT scanning, the patient suffered from immobilizing pain making a permanent medication with opioids necessary. In addition, signs and symptoms of early degenerative joint disease were already present in the contralateral hip. She was pretty well-informed on the rehabilitative power of a transfemoral amputation, especially when combined with a bone-anchored prosthesis. Given the clinical findings and the explicit wish of the patient, an elective transfemoral amputation with concomitant implantation of a bone-anchored prosthesis as well as a panel of follow-up examinations to evaluate rehabilitation and outcome even in the perception of the patient was consented (**Table 1**).

Surgical procedures and supportive treatment

The patient received preoperative routine antibiotic prophylaxis with a third-generation cephalosporin 30 min before induction of general anesthesia. The dysfunctional leg was dissected 25 cm below the greater trochanter, at a level determined by the length and diameter of the implant. During the preparation of the residual femur, multiple tissue samples were taken from the intramedullary canal for microbiological testing, and all of them scored negative. The femoral stem (Eska Orthopaedics, Lübeck, Germany) with a size of 15 mm × 180 mm (diameter × length) was driven into the medullary canal, and a tight press-fit was achieved (7). The muscles of the thigh were cut and shaped to avoid perspective interference with the prosthetic stem adaptor. The postoperative course was uneventful and, most interestingly, the patient was free of pain almost immediately after surgery in that opioids could be tapered to zero within less than 4 weeks. About 6 weeks after the first surgery the stoma of the TOPS was created using a specific circular punch. The skin-perforating bridging connector was attached to the femoral component essentially as described (7) and conventional means of postsurgical analgesics were employed. Starting the second postoperative day, the patient was

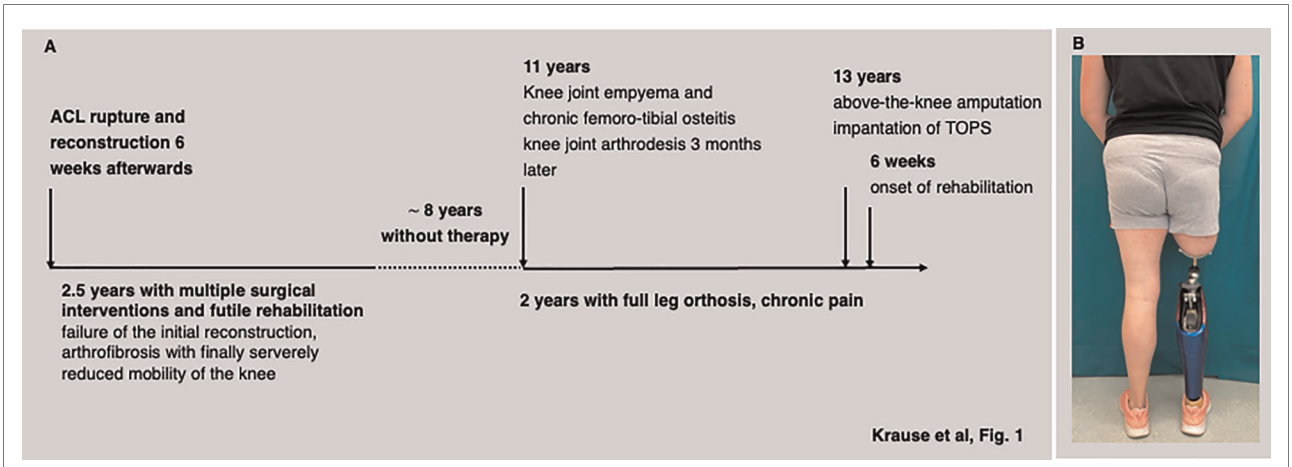

FIGURE 1
History of disease (A) and a photograph of the patient 18 months after switching to transcutaneous osseointegrated prosthesis system (TOPS) (B).

TABLE 1 Time schedule of the examinations.

	Prior to surgery	Postoperative		
		6 months	9 months	18 months
MRI of the thighs	×		×	
Clinical gait analysis	×	×	×	×
SIGAM and K-level		×		
AMPPRO		×	×	×
Fall Risk Index		×	×	×
LCI-5		×	×	×

instructed about daily self-care of the stoma, that is, to clean it twice daily with mild soap and water (7). Furthermore, she was equipped with a prosthesis, consisting of a microprocessor-controlled knee (Genium ×3, Otto Bock, Duderstadt, Germany) with a low-weight prosthetic foot (Taleo, Otto Bock, Duderstadt, Germany). She was encouraged to start walking with crutches to ensure partial weight-bearing of initially 5–10 kg. Full weight-bearing and walking without crutches were allowed about 6 weeks after the second surgery. Physiotherapy, gait, and balance training were initiated once she had received the prosthesis and was continued for about 4 months in order to restore her walking abilities (**Figure 1B**).

Clinical gait analysis and questionnaires

For standardized clinical gait analysis, the GRAIL (Gait Real-time Analysis Interactive Lab; Motekforce Link, Amsterdam) was used essentially as described and the same immersive virtual reality was presented throughout the examinations (13). Per examination, the patient was allowed to familiarize herself by walking for at least 5 min at a self-selected comfortable speed. Subsequently, spatio-temporal parameters of gait together with kinematic and kinetic data were recorded during a 30-s interval, representing at least 52 steps. Mean and standard deviation were calculated and for spatio-temporal parameters repeated measures, ANOVA (SPSS statistical package 25, SPSS Inc. Chicago, Illinois, USA) was employed to assess longitudinal changes. Similarly, the mean of kinetic and kinematic data were plotted for longitudinal comparison.

Restoration of walking abilities and autonomous mobility was characterized by the K-level, by the SIGAM grade (14, 15), the Amputee Mobility Predictor with the use of a prosthesis (AMPPRO) test (16), scoring of the Fall Risk Index (17), and the patient-reported Locomotor Capabilities Index (LCI-5) (18). Magnetic resonance imaging (1.5T Magnetom Avanto Fit, Siemens Healthineers, Germany) 9 months after the index procedure served as a tool to assess the muscle volumes of both thighs relative to the findings prior to surgery. In particular, the length of the region investigated corresponds to the length of the stump with the bottom edge of the tuber ischiadicum as an upper border. Transversal T1-weighted fat/water-separated sequences were recorded and a 3D slicer was employed for quantification (19).

Results

Outcome

The surgical procedures and postoperative recovery were uneventful and already at the time of the index procedure opioids could be tapered to zero. The artificial leg was coupled to the bone-anchored prosthetic stem the second day after the creation of the stoma, and since then, the patient

followed a supervised balance and gait training to restore walking abilities.

Magnetic resonance imaging confirmed severe atrophy of the thigh before the index procedure with muscle volumes of 1,781 cm^3 on the affected side and 2,750 cm^3 on the non-affected side in the corresponding thigh section. While 9 months after surgery the muscle volume of the affected thigh was almost the same as before, a 23% increase on the contralateral side was noted (**Figure 2**).

Clinical gait analysis

Standardized clinical gait analysis confirmed severe limping and seriously impaired walking abilities at the time of the first presentation (**Figure 3**). Beyond a rather short stride length and an overall low walking speed kinetic and kinematic features deviated markedly from normal. This holds especially true for the non-affected side and might be taken as an indicator of the increased risk for degenerative joint disease and subsequent aggravation of here already poor mobility.

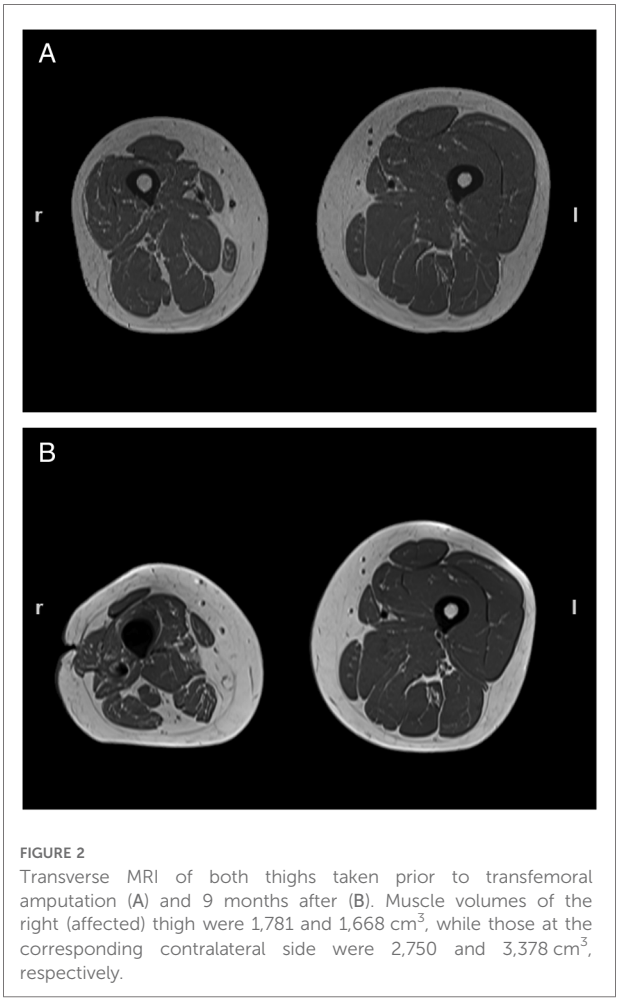

FIGURE 2
Transverse MRI of both thighs taken prior to transfemoral amputation (**A**) and 9 months after (**B**). Muscle volumes of the right (affected) thigh were 1,781 and 1,668 cm^3, while those at the corresponding contralateral side were 2,750 and 3,378 cm^3, respectively.

Already 6 months after switching to TOPS, the spatio-temporal characteristics of gait were significantly improved and these changes persisted during the follow-up period. In particular, walking speed was almost doubled (0.50 ± 0.00 m/s at baseline vs. 0.96 ± 0.00 m/s at the time of the last follow-up examination; $p < 0.001$). The cadence (steps per minute) increased from 38.6 ± 0.37 at baseline up to 50.9 ± 0.48 ($p < 0.001$) and the stride time dropped (1.55 ± 0.01 s at baseline vs. 1.18 ± 0.01 s; $p < 0.001$), while the stride length increased from 0.77 ± 0.03 m to 1.13 ± 0.01 m ($p < 0.001$) and the stride width remained rather constant (data not shown). Contrasting to an almost immediate normalization of the spatio-temporal features of gait (**Figure 3A**) and the diminished differences between the affected and non-affected leg, the continuous adaptation of the kinetic and kinematic parameters to the new situation was seen (**Figures 3B,C**). In particular, kinematic and kinetic data from the non-affected hip and knee joints steadily reverted to the physiological pattern.

The patient achieved K-level type 3 and a SIGAM mobility grade F corresponding to a near normal gait ability within 18 months postoperatively (14, 15). Likewise, the patient achieved 41, 44, and 44 points out of 47 points with the AMPPRO, 26, 28, and 27 points out of 28 points with the Tinetti test, and 47, 54, and 54 points out of 56 points with the LCI-5 at the follow-up examinations 6, 9, and 18 months after the index procedure.

Discussion

This case is two-fold unique in that we decided on a TOPS rather than the classical socket prosthesis and performed the first step of the TOPS procedure at the time of transfemoral amputation. Although there were serious concerns for infections due to the transcutaneous metal implant, these are mostly superficial and restricted to the stoma rather than ending with explantation of the prosthesis. Similarly, revision due to failure of the implant is rarely seen (7, 8, 10, 20–23).

At the time of her first presentation, she was seriously disabled with very limited autonomous mobility and chronic pain. Furthermore, she had been rather busy gaining knowledge on the pros and cons of the socket-mounted and bone-anchored prosthesis as measures to restore autonomous mobility after transfemoral amputation. Given the rather long history of the disease, she was not willing to try a socket prosthesis first, as she was seeking for a solution to her issues rather than for replacement of the existing problems with new ones. Thus, we followed her dedicated wish and paralleled the treatment and rehabilitation course with additional examinations. In particular, standardized clinical gait analysis prior to surgery confirmed severe limping with abnormal kinetics and kinematics for both legs. In other words, the risk for degenerative joint disease on the non-affected side and

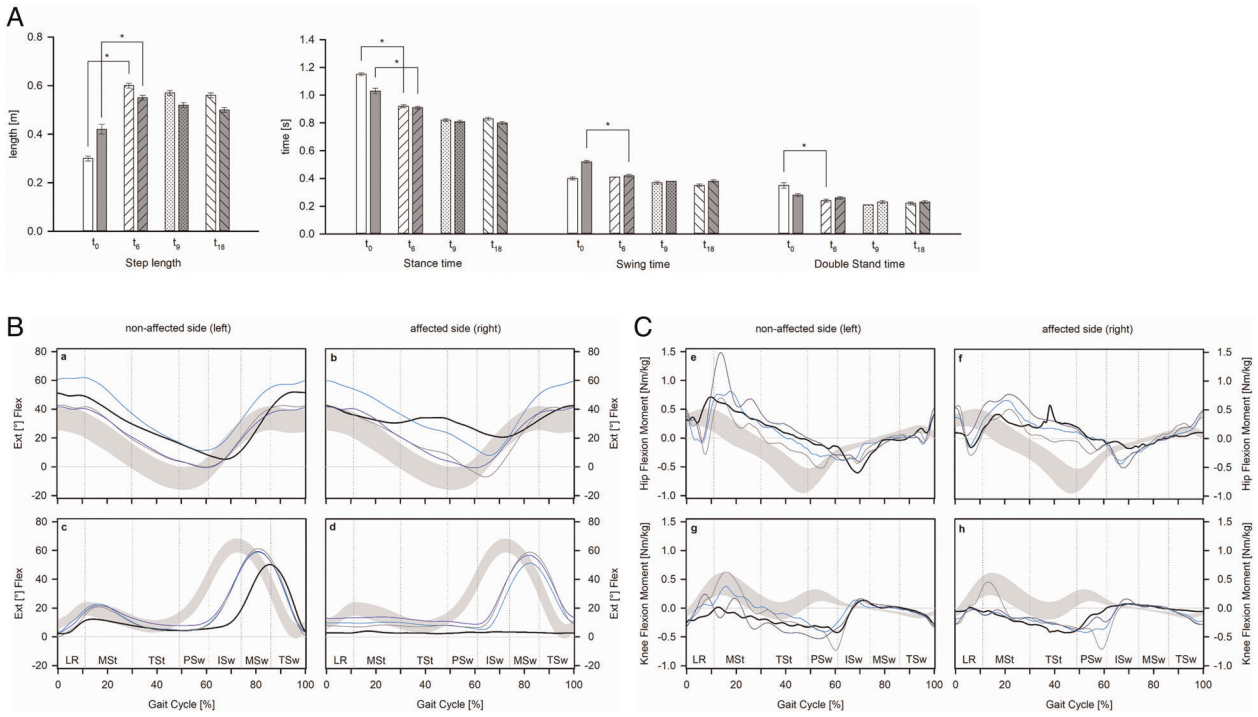

FIGURE 3
Spatio-temporal parameters of gait (A), kinematics (B), and kinetics (C) of hip and knee joints prior to transfemoral amputation and during the follow-up period. (A) Open and filled bars represent the non-affected and affected side prior to surgery (t_0) as well as 6 (t_6), 9 (t_9), and 18 (t_{18}) months after. (B) Kinematics of the hip (a,b) and knee joints (c,d) together with the normal range [gray area (24)] are presented prior to transfemoral amputation (black) as well as 6 (light blue), 9 (gray), and 18 (dark blue) months after switching to transcutaneous osseointegrated prosthesis system (TOPS). (C) Kinetics of the hip (e,f) and knee joints (g,h) together with the normal range [gray area (24)] are presented prior to transfemoral amputation (black) as well as 6 (light blue), 9 (gray), and 18 (dark blue) months after switching to TOPS. Vertical lines indicate the phases of the gait cycle, that is, LR, loading response; MSt, mid stance; TSt, terminal stance; PSw, pre-swing; ISw, initial swing; Msw, mid-swing; TSw, terminal swing (25).

subsequent aggravation of here already poor mobility is foreseeable unless the dysfunctionality of the affected leg is solved. Already 6 months after switching to TOPS, a steep improvement in her walking abilities with diminished differences between the spatio-temporal features related to the affected and non-affected leg was noted, and these changes persisted during the follow-up period. The continuous normalization of kinematic and kinetic data especially on the non-affected side has to be considered as an important prerequisite to prevent the progression of degenerative joint disease. The restoration of bilateral symmetry by mutual approximation to the standard gait pattern during the 18 months of follow-up period mirrors her constant efforts to train and improve her walking abilities.

Conclusion

Although the decision for unilateral transfemoral amputation is hard to achieve and requires careful counseling, there is no doubt that this procedure has the power to improve quality of life and autonomous mobility rather than worsening the situation. The outcome of our patient is well in line with this notion. Furthermore, a reasonable number of patients claim recurrent problems at the interface between stump and standard socket prosthesis, ranging from intradaily fluctuations of the stump volume to ulcera caused by relative movements of the socket (or liner) and the stump. Such issues may lead to fitting and re-fitting of the socket over and over and this we probably spared our patient. Nevertheless, long-term follow-up is necessary to detect future complications of TOPS.

Data availability statement

The original contributions presented in the study are included in the article/Supplementary Material, further inquiries can be directed to the corresponding author/s.

Ethics statement

Written informed consent for publication of her clinical details and images was submitted for review to the editor of this journal.

Author contributions

KK and KR collected the data and performed gait analysis. TB was responsible for MRT imaging and analysis. HHA and TM performed the surgery. KK, KR, DCF, and TM drafted the manuscript. All authors contributed to the article and approved the submitted version.

Acknowledgments

We greatly appreciate the time and enthusiasm of our patient to undergo repetitive clinical gait analysis and to fill in several questionnaires on her perception of the outcome.

Conflict of interest

The authors declare that the research was conducted in the absence of any commercial or financial relationships that could be construed as a potential conflict of interest.

Publisher's note

All claims expressed in this article are solely those of the authors and do not necessarily represent those of their affiliated organizations, or those of the publisher, the editors and the reviewers. Any product that may be evaluated in this article, or claim that may be made by its manufacturer, is not guaranteed or endorsed by the publisher.

References

1. Palazzolo A, Rosso F, Bonasia DE, Saccia F, Rossi R, Knee Committee S. Uncommon complications after anterior cruciate ligament reconstruction. *Joints*. (2018) 6(3):188–203. doi: 10.1055/s-0038-1675799

2. Hungerer S, Kiechle M, von Ruden C, Militz M, Beitzel K, Morgenstern M. Knee arthrodesis versus above-the-knee amputation after septic failure of revision total knee arthroplasty: comparison of functional outcome and complication rates. *BMC Musculoskelet Disord*. (2017) 18(1):443. doi: 10.1186/s12891-017-1806-8

3. Trouillez T, Faure PA, Martinot P, Migaud H, Senneville E, Pasquier G, et al. Above-the-knee amputation versus knee arthrodesis for revision of infected total knee arthroplasty: recurrent infection rates and functional outcomes of 43 patients at a mean follow-up of 6.7 years. *Orthop Traumatol Surg Res*. (2021) 107(4):102914. doi: 10.1016/j.otsr.2021.102914

4. Munin MC, Espejo-De Guzman MC, Boninger ML, Fitzgerald SG, Penrod LE, Singh J. Predictive factors for successful early prosthetic ambulation among lower-limb amputees. *J Rehabil Res Dev*. (2001) 38(4):379–84. PMID: 11563490

5. Butler K, Bowen C, Hughes AM, Torah R, Ayala I, Tudor J, et al. A systematic review of the key factors affecting tissue viability and rehabilitation outcomes of the residual limb in lower extremity traumatic amputees. *J Tissue Viability*. (2014) 23(3):81–93. doi: 10.1016/j.jtv.2014.08.002

6. Dudek NL, Marks MB, Marshall SC, Chardon JP. Dermatologic conditions associated with use of a lower-extremity prosthesis. *Arch Phys Med Rehabil*. (2005) 86(4):659–63. doi: 10.1016/j.apmr.2004.09.003

7. Juhnke DL, Beck JP, Jeyapalina S, Aschoff HH. Fifteen years of experience with integral-leg-prosthesis: cohort study of artificial limb attachment system. *J Rehabil Res Dev*. (2015) 52(4):407–20. doi: 10.1682/JRRD.2014.11.0280

8. Reif TJ, Khabyeh-Hasbani N, Jaime KM, Sheridan GA, Otterburn DM, Rozbruch SR. Early experience with femoral and tibial bone-anchored osseointegration prostheses. *JBJS Open Access*. (2021) 6(3):e21.00072. doi: 10.2106/JBJS.OA.21.00072

9. Leijendekkers RA, van Hinte G, Frolke JP, van de Meent H, Nijhuis-van der Sanden MW, Staal JB. Comparison of bone-anchored prostheses and socket prostheses for patients with a lower extremity amputation: a systematic review. *Disabil Rehabil*. (2017) 39(11):1045–58. doi: 10.1080/09638288.2016.1186752

10. Aschoff HH, Kennon RE, Keggi JM, Rubin LE. Transcutaneous, distal femoral, intramedullary attachment for above-the-knee prostheses: an endo-exo device. *J Bone Joint Surg Am*. (2010) 92(Suppl 2):180–6. doi: 10.2106/JBJS.J.00806

11. Reetz D, Atallah R, Mohamed J, van de Meent H, Frolke JPM, Leijendekkers R. Safety and performance of bone-anchored prostheses in persons with a transfemoral amputation: a 5-year follow-up study. *J Bone Joint Surg Am*. (2020) 102(15):1329–35. doi: 10.2106/JBJS.19.01169

12. Hoellwarth JS, Tetsworth K, Rozbruch SR, Handal MB, Coughlan A, Al Muderis M. Osseointegration for amputees: current implants, techniques, and future directions. *JBJS Rev*. (2020) 8(3):e0043. doi: 10.2106/JBJS.RVW.19.00043

13. Feldhege F, Richter K, Bruhn S, Fischer DC, Mittlmeier T. MATLAB-based tools for automated processing of motion tracking data provided by the GRAIL. *Gait Posture*. (2021) 90:422–6. doi: 10.1016/j.gaitpost.2021.09.179

14. Hofstad CJ, Bongers KTJ, Didden M, van Ee RF, Keijsers NLW. Maximal walking distance in persons with a lower limb amputation. *Sensors*. (2020) 20 (23):6770. doi: 10.3390/s20236770

15. Ryall NH, Eyres SB, Neumann VC, Bhakta BB, Tennant A. The SIGAM mobility grades: a new population-specific measure for lower limb amputees. *Disabil Rehabil*. (2003) 25(15):833–44. doi: 10.1080/0963828021000056460

16. Gailey RS, Roach KE, Applegate EB, Cho B, Cunniffe B, Licht S, et al. The amputee mobility predictor: an instrument to assess determinants of the lower-limb amputee's ability to ambulate. *Arch Phys Med Rehabil*. (2002) 83 (5):613–27. doi: 10.1053/ampr.2002.32309

17. Tinetti ME, Williams TF, Mayewski R. Fall risk index for elderly patients based on number of chronic disabilities. *Am J Med*. (1986) 80(3):429–34. doi: 10.1016/0002-9343(86)90717-5

18. Franchignoni F, Orlandini D, Ferriero G, Moscato TA. Reliability, validity, and responsiveness of the locomotor capabilities index in adults with lower-limb amputation undergoing prosthetic training. *Arch Phys Med Rehabil*. (2004) 85(5):743–8. doi: 10.1016/j.apmr.2003.06.010

19. Fedorov A, Beichel R, Kalpathy-Cramer J, Finet J, Fillion-Robin JC, Pujol S, et al. 3D Slicer as an image computing platform for the quantitative imaging network. *Magn Reson Imaging*. (2012) 30(9):1323–41. doi: 10.1016/j.mri.2012.05.001

20. Hagberg K, Branemark R. One hundred patients treated with osseointegrated transfemoral amputation prostheses–rehabilitation perspective. *J Rehabil Res Dev*. (2009) 46(3):331–44. doi: 10.1682/JRRD.2008.06.0080

21. Al Muderis M, Khemka A, Lord SJ, Van de Meent H, Frolke JP. Safety of osseointegrated implants for transfemoral amputees: a two-center prospective cohort study. *J Bone Joint Surg Am*. (2016) 98(11):900–9. doi: 10.2106/JBJS.15.00808

22. Hagberg K, Ghassemi Jahani SA, Kulbacka-Ortiz K, Thomsen P, Malchau H, Reinholdt C. A 15-year follow-up of transfemoral amputees with bone-anchored transcutaneous prostheses. *Bone Joint J*. (2020):102-B(1):55–63. doi: 10.1302/0301-620X.102B1.BJJ-2019-0611.R1

23. Marano AA, Modiri O, Rozbruch SR, Otterburn DM. Soft tissue contouring at the time of osseointegrated implant reconstruction for lower extremity amputation. *Ann Plast Surg*. (2020) 85(S1 Suppl 1):S33–6. doi: 10.1097/SAP.0000000000002329

24. Bovi G, Rabuffetti M, Mazzoleni P, Ferrarin M. A multiple-task gait analysis approach: kinematic, kinetic and EMG reference data for healthy young and adult subjects. *Gait Posture*. (2011) 33(1):6–13. doi: 10.1016/j.gaitpost.2010.08.009

25. Perry J, Burnfield JM. Gait analysis. *Normal and pathological function*. 2nd ed. Slack Inc, Thorafare NJ (2010).

frontiers | Frontiers in Surgery

TYPE Original Research
PUBLISHED 30 August 2022
DOI 10.3389/fsurg.2022.944481

Check for updates

OPEN ACCESS

EDITED BY
Paphon Sa-ngasoongsong,
Mahidol University, Thailand

REVIEWED BY
Lei Liu,
Guangdong Provincial People's Hospital, China
Deniz Çankaya,
University of Health Sciences, Turkey
Wang Chengyong,
Guangdong University of Technology, China

*CORRESPONDENCE
Liang A
aliangvvip@163.com

SPECIALTY SECTION
This article was submitted to Orthopedic Surgery, a section of the journal Frontiers in Surgery

RECEIVED 15 May 2022
ACCEPTED 22 July 2022
PUBLISHED 30 August 2022

CITATION
Li S and A L (2022) The hidden blood loss and its factors in patients undergoing minimally invasive knee arthroscopy.
Front. Surg. 9:944481.
doi: 10.3389/fsurg.2022.944481

COPYRIGHT
© 2022 Li and A. This is an open-access article distributed under the terms of the Creative Commons Attribution License (CC BY). The use, distribution or reproduction in other forums is permitted, provided the original author(s) and the copyright owner(s) are credited and that the original publication in this journal is cited, in accordance with accepted academic practice. No use, distribution or reproduction is permitted which does not comply with these terms.

The hidden blood loss and its factors in patients undergoing minimally invasive knee arthroscopy

Sheng Li[1,2] and Liang A[1,2]*

[1]Department of Orthopaedics, Affiliated Central Hospital of Shenyang Medical College, Shenyang, China, [2]Shenyang Hand Foot Clinical Research Center, Shenyang, China

Background: With respect to knee arthroscopy, assessing the amount of hidden blood loss is of great importance to avoid potential complications such as fever, anemia, difficulty in wound healing and wound infection. The current study aims to investigate the hidden blood loss and its factors in patients who underwent minimally invasive knee arthroscopy.

Methods: Consecutive patients with knee joint injury, who underwent arthroscopic minimally invasive treatment, were enrolled from January 2019 to November 2020 and were retrospectively studied. Demographic information on these patients, such as medical history and biochemical parameters, was collected. The hidden blood loss was calculated. Multivariate linear regression analysis was used to confirm independent factors associated with hidden blood loss.

Results: Finally, a total of 100 patients aged 44.78 ± 13.67 (range 17–66) years were reviewed, and it was found that a substantial amount of [387.02 ± 252.56 (range 18.89–1130.06) ml] hidden blood loss occurred after minimally invasive knee arthroscopy. Univariate analysis showed that this hidden blood loss was negatively correlated with age, gender, postoperative hemoglobin, and postoperative hematocrit (all $P < 0.05$), while it was positively correlated with body mass index (BMI), length of hospital stay, preoperative red blood cells, preoperative hemoglobin, preoperative hematocrit, blood volume, and the presence of medical conditions (all $P < 0.05$). Further multivariate linear regression indicated that preoperative hematocrit, blood volume, and postoperative hematocrit were independent factors associated with actual blood loss, and preoperative hematocrit, blood volume, postoperative hematocrit, and gender were independent factors associated with hidden blood loss, respectively (all $P < 0.05$).

Conclusion: Preoperative hematocrit, preoperative blood volume, postoperative hematocrit, and gender are the influencing factors of hidden blood loss in patients undergoing minimally invasive treatment under knee arthroscopy. More attention should be paid to hidden blood loss and its factors during the perioperative period.

KEYWORDS

arthroscopy, minimally invasive, knee, hidden blood loss, risk factors

Introduction

Arthroscopy provides a technical guarantee for the minimally invasive treatment of orthopedic knee joint injury. Compared with traditional open surgery, it has the advantages of minimized surgical trauma, less bleeding, and accelerated postoperative rehabilitation (1). At present, it is being widely used in medical surgery for sports orthopedics and is achieving good clinical results (2). However, the relevant complications after arthroscopy are also becoming a matter of wide concern, and a few examples of these are fever, anemia, difficulty in wound healing, and wound infection. In response to these complications, clinicians have found many causes, of which hidden blood loss after knee arthroscopy is being paid increasing attention by everyone, following which it has become a non-negligible factor (3). Hidden blood loss is not usually mentioned during general assessment because of its invisibility, while an association has been found between increased blood loss and perioperative complications (4). Concerning minimally invasive knee arthroscopy, evaluating hidden blood loss is of great importance to prevent the aforementioned potential complications.

Since researchers proposed the concept of hidden blood loss in 2000 (5), a series of studies on various treatments for this blood loss in the field of orthopedic surgery has been reported successively, such as minimally invasive treatment of tibial fractures (6), minimally invasive treatment of fractures, knee replacement, hip replacement, and spinal surgery (7). To the best of our knowledge, there was no report in the literature on the factors causing hidden blood loss from minimally invasive treatment with knee arthroscopy. Herein, the current study retrospectively reviewed the medical data of patients who underwent minimally invasive knee arthroscopy to evaluate hidden blood loss and identify its associated factors.

Patients and methods

The study protocol was approved by the Institutional Review Committee (IRB) of the Central Hospital Affiliated with Shenyang Medical College and followed the tenets of the Declaration of Helsinki. The IRB confirmed that informed consent was waived due to the retrospective nature of the study design and data were analyzed anonymously. From January 2019 to November 2020, 100 consecutive patients who underwent arthroscopically minimally invasive treatment for knee injuries in our hospital met our inclusion criteria and were enrolled in our study. The inclusion criteria were as follows: (1) fresh knee joint injury in one limb, no other serious trauma; (2) minimally invasive arthroscopic knee treatment; (3) blood parameters before surgery and within 3 days after surgery; (4) no hematological diseases (hemophilia or vitamin K deficiency, etc.); and (5) no history of anticoagulant drugs. The exclusion criteria were as follows: patients (1) younger than 16 years; (2) those with previous knee surgery; (3) knee surgery combined with serious blood-related diseases; and (4) oral anticoagulants before 3 months. Demographic information such as age, gender, medical history, diagnosis, and laboratory investigations as well as pre-, intra-, and postoperative data were collected *via* the electronic medical record system.

Surgical procedure invasive operation

An incision of approximately 0.5 cm in the anterolateral and medial sides of the knee was performed, the arthroscopy was located to check the joint cavity, and then the planer was cleaned to determine the injury of the cruciate ligament and meniscus. The hamstring tendon was taken out as the transplanted tendon. The edge of the irregular meniscus was removed and the torn meniscus was sutured. The process of making the cruciate ligament bone tunnel included (1) locating with a femoral and tibial guide; (2) drilling into the Kirschner wire; (3) drilling through the bone cortex with a hollow drill; (4) measuring the bone tunnel; and (5) selecting an appropriate hollow drill to drill an appropriate depth according to the tendon thickness.

Calculation of hidden blood loss

Hidden blood loss (ml) = actual total blood loss − overt blood loss + transfusion volume;

Actual total blood loss (ml) = blood volume × (preoperative hematocrit − postoperative hematocrit)/mean hematocrit (Gross equation)

The estimated blood volume (EBV) of each patient was calculated by using the Nadler formula (8). EBV $(L) = k_1 \times \text{height } (m)^3 + k_2 \times \text{weight } (kg) + k_3$, where $k_1 = 0.3669$, $k_2 = 0.03219$, and $k_3 = 0.6041$ for males and $k_1 = 0.3561$, $k_2 = 0.03308$, and $k_3 = 0.1833$ for females.

Statistical analysis

SPSS v20.0 for Windows (IBM Corp., Armonk, NY, USA) was used for data analysis. The Shapiro–Wilk test was used to assess the normality of data distribution. Continuous data were described as either mean ± standard deviation (SD) or median and range based on their distribution. A comparison among different categories was assessed by using the Student's *t*-test. Pearson's correlation analysis and Spearman's correlation analysis were performed according to the normality of data distribution. Multiple linear regression was

conducted for evaluated associated factors on blood loss. A *P*-value of less than 0.05 was considered statistically significant.

Results

All demographic and baseline characteristics of the included participants are summarized in Table 1. Among 100 patients, there were 58 (58%) males and 42 (42%) females, aged 17–66 years, with a mean of 44.78 ± 13.67 years. Their mean BMI was 18.59–36.98 kg/m^2. The mean total actual blood loss was 512.32 ± 317.29 ml, and the mean hidden blood loss was 387.02 ± 252.56 ml.

In terms of total actual blood loss, male patients ($P = 0.001$) without previous medical disease ($P < 0.001$) had a higher total actual blood loss postoperatively. Similar results were found in hidden blood loss assessments (Table 2).

In correlation analysis, age, gender, postoperative hemoglobin, postoperative hematocrit, BMI, length of hospital stay, preoperative red blood cells, preoperative hemoglobin, preoperative hematocrit, blood volume, and the presence of medical conditions were correlated with actual blood loss and hidden blood loss, respectively (all $P < 0.05$, Table 3).

Multivariate linear regression analysis demonstrated that preoperative hematocrit ($\beta = 100.407$, $P < 0.001$), blood volume ($\beta = 134.497$, $P < 0.001$), and postoperative hematocrit ($\beta = -90.944$, $P < 0.001$) were independently associated with actual blood loss (Table 4). Furthermore, preoperative hematocrit ($\beta = 78.613$, $P < 0.001$), blood volume ($\beta = 119.371$, $P < 0.001$), postoperative hematocrit ($\beta = -72.719$, $P < 0.001$), and gender ($\beta = 52.280$, $P = 0.011$) were independent factors for hidden blood loss (Table 5).

Discussion

To date, the most common complications occurring after arthroscopic surgery may be related to hidden blood loss, which is to rule out significant blood loss during surgery and postoperative drainage volume, as the part of the body's hidden loss of blood volume. Hidden blood loss is generally associated with hematocele in the joint space, interstitial hematocele, hemolysis, and stress gastrointestinal bleeding leading to hemoglobin loss (9). However, there are few reports on the factors behind hidden blood loss after knee arthroscopic surgery. To address this research gap, our study demonstrated that preoperative hematocrit, blood volume, and postoperative hematocrit were independent factors associated with actual blood loss, and preoperative hematocrit, blood volume, postoperative hematocrit, and gender were independent factors associated with hidden blood loss, respectively.

TABLE 1 Overall characteristics of the study population.

Variables	Mean ± SD (range)
Male/female	58/42
Age (years)	44.78 ± 13.67 (17–66)
BMI (kg/m^2)	25.07 ± 3.67 (18.59–36.98)
Operation time (min)	114.9 ± 47.08 (48–270)
Hospital stay (days)	12.86 ± 10.16 (4–90)
Preoperative RBC [10(12)/L]	4.86 ± 0.53 (3.7–6.15)
Preoperative hemoglobin (g/L)	148.45 ± 15.57 (99–186)
Preoperative hematocrit (%)	43.43 ± 4.37 (31.1–53.2)
Postoperative RBCl [10(12)/L]	4.3 ± 0.52 (2.78–5.55)
Postoperative hemoglobin (g/L)	131.58 ± 16.2 (77–172)
Postoperative hematocrit (%)	38.35 ± 4.42 (24.2–49)
Blood volume (L)	4.48 ± 0.68 (3.2–6.28)
Actual total blood loss (ml)	512.32 ± 317.29 (18.89–1380.06)
Hidden blood loss (ml)	387.02 ± 252.56 (18.89–1130.06)

SD, standard deviation; BMI, body mass index; RBC, red blood cell.

TABLE 2 Characteristics of included patients.

	Total actual blood loss	*P*	Hidden blood loss	*P*
Gender				
Male ($n = 58$)	595.30 ± 348.76	0.001	446.52 ± 284.4	0.003
Female ($n = 42$)	397.72 ± 225.39		304.86 ± 172.21	
Age				
≥50 ($n = 53$)	454.95 ± 293.89	0.08	344.1 ± 231.15	0.11
<50 ($n = 47$)	563.19 ± 331.12		425.08 ± 266.53	
BMI				
≥27 ($n = 25$)	570.71 ± 295.01	0.27	428.31 ± 233.98	0.35
<27 ($n = 75$)	492.86 ± 323.93		373.26 ± 258.48	
Medical disease or not				
Yes ($n = 5$)	193.38 ± 108.63	<0.001	143.38 ± 73.89	<0.001
No ($n = 95$)	529.12 ± 315.97		399.84 ± 252.24	
Epilepsy				
Right ($n = 46$)	485.82 ± 306.62	0.44	366.9 ± 247.99	0.46
Left ($n = 54$)	534.89 ± 327.27		404.16 ± 257.45	
Mechanism of injury				
Low ($n = 12$)	478.82 ± 375.5	0.69	373.82 ± 305.91	0.85
High ($n = 88$)	516.89 ± 310.74		388.82 ± 246.43	
Surgical method				
Single ($n = 34$)	460.2 ± 312.81	0.24	349.32 ± 247.06	0.29
Multiple ($n = 66$)	539.17 ± 318.61		406.44 ± 255.03	
Early postoperative complications				
Yes ($n = 35$)	508.11 ± 307.48	0.92	382.12 ± 243.21	0.89
No ($n = 65$)	514.58 ± 324.8		389.66 ± 259.28	

BMI, body mass index.

TABLE 3 Correlation between various indicators and actual blood loss and hidden blood loss.

	Actual blood loss		Hidden blood loss	
	R	*P*	*R*	*P*
Age (years)	−0.28	**<0.001**	−027	**0.007**
BMI (kg/m^2)	0.22	**0.022**	0.20	**0.046**
Operation time (min)	0.15	0.13	0.15	0.15
Hospital stay (days)	0.24	**0.02**	0.25	**0.01**
Preoperative RBC [10(12)/L]	0.45	**<0.001**	0.43	**<0.001**
Preoperative hemoglobin (g/L)	0.38	**<0.001**	0.37	**<0.001**
Preoperative hematocrit (%)	0.43	**<0.001**	0.42	**<0.001**
Postoperative RBCl [10(12)/L]	−0.13	0.21	−0.15	0.15
Postoperative hemoglobin (g/L)	−0.19	**0.05**	−0.21	**0.03**
Postoperative hematocrit (%)	−0.22	**0.03**	−0.23	**0.02**
Blood volume (L)	0.37	**<0.001**	0.35	**<0.001**
Medical disease or not	0.27	**0.007**	0.28	**0.005**
Epilepsy	0.09	0.39	0.09	0.37
Mechanism of injury	0.07	0.51	0.05	0.61
Surgical method	0.12	0.22	0.12	0.24
Early postoperative complications	0.008	0.94	0.012	0.91
Gender	−0.27	**0.006**	−0.24	**0.02**

BMI, body mass index; RBC, red blood cell.

TABLE 4 Multiple regression analysis related to actual blood loss.

	B	95% CI		*P*
		Lower	Upper	
Age (years)	−0.232	−1.057	0.592	0.577
BMI (kg/m^2)	−1.790	−5.373	1.793	0.323
Hospital stay (days)	−0.035	−1.013	0.943	0.944
Preoperative RBC [10(12)/L]	−39.513	−87.933	8.908	0.108
Preoperative hemoglobin (g/L)	0.812	−1.815	3.440	0.540
Preoperative hematocrit (%)	**100.407**	**90.252**	**110.562**	**<0.001**
Blood volume (L)	**134.497**	**105.895**	**163.100**	**<0.001**
Postoperative hemoglobin (g/L)	−2.350	−5.626	0.926	0.158
Postoperative hematocrit (%)	**−90.944**	**−102.434**	**−79.453**	**<0.001**
Medical disease or not	−10.955	−53.457	31.546	0.610
Gender	26.666	−10.031	63.362	0.152

BMI, body mass index; RBC, red blood cell; CI, confidence interval.
Bold values indicate data are statistically significant.

Numerous studies have shown that hidden blood loss is also an important factor in other surgeries that also belong to the minimally invasive category in clinical practice. Femoral fractures are common in the elderly, with more than 10% of European fracture patients dying within 30 days and more than 25% within 1 year (10). Anemia is one of the important factors associated with mortality, which increases the incidence of lung and brain diseases and disrupts the balance of oxygen supply.

TABLE 5 Multiple regression analysis associated with hidden blood loss.

	B	95% CI		*P*
		Lower	Upper	
Age (years)	0.018	−0.875	0.911	0.967
BMI (kg/m^2)	−3.722	−7.603	0.160	0.060
Hospital stay (days)	0.277	−0.782	1.337	0.604
Preoperative RBC [10(12)/L]	−29.964	−82.413	22.486	0.259
Preoperative hemoglobin (g/L)	1.083	−1.763	3.928	0.452
Preoperative hematocrit (%)	**78.613**	**67.613**	**89.614**	**<0.001**
Blood volume (L)	**119.371**	**88.388**	**150.354**	**<0.001**
Postoperative hemoglobin (g/L)	−1.845	−5.394	1.704	0.304
Postoperative hematocrit (%)	**−72.719**	**−85.166**	**−60.273**	**<0.001**
Medical disease or not	−21.102	−67.140	24.936	0.365
Gender	**52.280**	**12.530**	**92.030**	**0.011**

BMI, body mass index; RBC, red blood cell; CI, confidence interval.
Bold values indicate data are statistically significant.

At present, the intramedullary nailing fracture technique used in clinical practice is a relatively minimally invasive surgery, which reduces the surgical incision of patients and also the intraoperative visible blood loss on the surface. However, patients still show symptoms of anemia in the perioperative period, which is inseparable from hidden blood loss. Hidden blood loss accounts for a high proportion of total perioperative blood loss in patients with femoral fractures. If its influence is not considered, it often leads to anemia or hypovolemia, which will affect the postoperative recovery of patients (11). If the perioperative blood loss of elderly patients with intertrochanteric fractures is 863.8 ± 429.9 ml, then the hidden blood loss will be 772.3 ± 424.7 ml (12), and so it can be seen that the hidden blood loss is predominant. This is consistent with the results obtained by researchers (4), who observed that the total blood loss of more than 500 patients with fractures was approximately 6 times the operative blood loss. Intramedullary nailing is also used by surgeons in minimally invasive surgery for tibial fractures because of its wide indications, minimal trauma, reliable fixation, and antirotation. Also, due to less intraoperative blood loss, total blood loss in the perioperative period of patients is rarely noticed. However, when reaming intramedullary nails are used to fix tibial fractures, intramedullary nails damage the medulla and significantly increase hidden blood loss (13). Endoscopic lumbar discectomy has been standardized as a typical minimally invasive surgical technique for lumbar disc herniation (14), and studies have shown that this minimally invasive surgery also presents with a large amount of hidden blood loss (15).

The mechanism of hidden blood loss can be summarized as blood stasis in the joint cavity and interstitial space, hemolysis, and gastrointestinal bleeding. Even if wound drainage is done after surgery, bleeding in the patient's surgical area cannot be

completely discharged, and some bleeding remains in the joint cavity and tissue space and is gradually absorbed, organized, and exuded. These hemorrhages are large and do not participate in the systemic circulation, inducing the loss of hemoglobin. This may be related to the abnormal coagulation mechanism of patients suffering from rheumatoid arthritis (16) and blood system bleeding diseases. Perioperative use of anticoagulant drugs will also increase the risk of bleeding. Vascular anatomy (17) shows that the branches of the middle knee artery are distributed in the posterior condylar recess, the posterior half of the medial and lateral ventricles of the knee joint, and the posterior horn of the medial meniscus, forming a vascular plexus extending into the intercondylar fossa and supplying the anterior and posterior cruciate ligaments. The arterioles of the medial and lateral knee arteries form a periteniscal capillary plexus and annular vascular network in the synovium and joint capsule, and the meniscus; the lateral knee artery surrounds the lateral tibial condyle anteriorly and anteriorly from outside, immediately adjacent to the edge of the lateral meniscus body; the inferior transverse branch of the peripatellar artery network runs in the infrapatellar fat pad. These vessels, which supply the anterior and posterior cruciate ligaments, menisci, synovium, joint capsule, and fat pad, carry a high risk of injury during arthroscopic knee surgery, opening the possibility of hidden blood loss. In addition, the use of a tourniquet in patients also destroys the soft tissue at the extrusion site and leads to an increase of a certain amount of interstitial hematocele. Hemolysis, as another factor in the mechanism of action of hidden blood loss, is often easily overlooked. The use of a tourniquet effectively reduces significant blood loss seen intraoperatively, but excessive tourniquet time and reperfusion of limb blood loss after loosening can present additional injuries. Reactive hyperemia of the limbs can lead to a release of the tissue plasminogen activator from the vascular endothelium, which increases the fibrinolytic activity and accelerates the hemolytic reaction, resulting in hidden blood loss after surgery. After prolonged ischemia of tissues, there is a compensatory increase of anaerobic metabolism, activating a large number of oxygen-free radicals, and the body is in a state of oxidative stress (18), which can lead to red blood cell injury and induce hemolysis in the body (19). Hemolysis can further activate oxidative stress (20), resulting in hidden blood loss (21).

Prolonged surgery and blood transfusion also induce hemolysis, which is associated with the use of cardiopulmonary bypass (22) and also with oxidative cell damage (23). Transfused patients experience elevated bilirubin and decreased hemoglobin increment (24), which indicates that hemolysis is also present after transfusion, and it can also lead to hidden blood loss. In addition, gastrointestinal bleeding due to stress ulcers is also responsible for the increase in occult bleeding volume. Patient studied in the literature (25) was hospitalized several times for severe anemia of unknown origin (Hb 40-50 g/l) due to hidden blood loss from the jejunum, which was effectively controlled after treatment with gastrointestinal hemostasis. Perioperative patients are at risk of developing stress ulcers, which may lead to clinically important bleeding, and stress ulcer prevention should be taken seriously in patients in intensive care units and general wards (26).

There are many factors affecting hidden blood loss in the minimally invasive treatment of the knee joint. We hereby study to find out the related factors and guide clinical practice according to the mechanism affecting hidden blood loss. We selected 100 patients with knee joint injury who received arthroscopic minimally invasive treatment. According to the inclusion criteria, there were 58 males and 42 females, aged 17–66 years, with a mean of (44.78 ± 13.67) years; mean BMI (25.07 ± 3.67) kg/m^2; mean total actual blood loss in the study population (512.32 ± 317.29) ml; and mean hidden blood loss (387.02 ± 252.56) ml. It can be seen from the characteristics of the study population that a major part of the population is middle-aged, mainly male, with hidden blood loss accounting for approximately 76% of the actual blood loss. It can be seen that hidden blood loss is predominant in a majority of the population, which is consistent with the findings of other minimally invasive surgeries (12). Gender differences associated with hidden blood loss were found in orthognathic surgery studies, with equal gender-related percentages of blood loss (27), which is consistent with our findings. However, in another study of perioperative hidden blood loss in patients undergoing posterior lumbar fusion, gender was not associated with hidden blood loss (28). Interestingly, among patients treated with anterior cervical discectomy and fusion, male patients were an independent risk factor for hidden blood loss (29). Hidden blood loss in females was found more in univariate analysis, which was consistent with the meta-analysis exploring that the risk factors of perioperative hidden blood loss in Chinese patients with femoral fracture were female patients (30), which may be related to the unique physiological structure of women. These discrepancies may be due to different study designs, surgery methods, and perioperative management. In laparoscopic cholecystectomy, hypertension is a contributing factor to hidden blood loss (31). There is a high hidden blood loss during spinal perioperative surgery, and studies have shown that hypertension, diabetes, and heart disease are all risk factors for hidden blood loss (32). Patients with medical diseases often undergo changes in hemodynamics and blood composition, and such patients have coagulation disorders, abnormal cardiopulmonary compensation, poor vascular elasticity, and lower tolerance to anemia, which all lead to more hidden blood loss (33). Most of the patients in this study with a long hospital stay were young patients with high-energy injuries and multiple knee injuries, which potentially increase the risk of occult bleeding.

Moreover, our study demonstrated that preoperative hematocrit, blood volume, and postoperative hematocrit were independent factors associated with actual blood loss, while preoperative hematocrit, blood volume, postoperative hematocrit, and gender were independent factors associated with hidden blood loss. Through a multifactor comprehensive analysis, considering that the muscle and bone content of male patients was significantly higher than that of female patients, these results determined that the male patients had higher preoperative blood volume and preoperative hematocrit. When knee joint injury and minimally invasive surgery occurred, it was accompanied by more muscle and soft tissue injury, especially when the bone tunnel was made, and it was accompanied by more bone loss and bone injury, resulting in more severe hidden blood loss, as demonstrated by lower postoperative hematocrit. According to the present study results, we recommend that in minimally invasive knee surgery, stable normal blood pressure be maintained to prevent more hidden blood loss induced by blood pressure fluctuations, and the tourniquet use time be controlled to prevent local soft tissue injury caused by tourniquet and ischemia-reperfusion to induce more hidden blood loss. Also, the following is recommended: radiofrequency ablation knife hemostasis after loosening the tourniquet to reduce hidden blood loss (34); appropriate perioperative administration of drugs to protect the gastric mucosa to prevent the occurrence of stress ulcers; appropriate use of antioxidants, such as vitamin E and carotene, to prevent hemolysis. It is suggested to use tranexamic acid to reduce blood loss in arthroscopic surgery (35). Studies have shown that (36) tranexamic acid, combined with systemic and local application, has important clinical significance in reducing perioperative blood loss and blood cell loss in patients with femoral fracture, with good safety; it is recommended to cold-compress the incision and surrounding tissues, as low temperatures can constrict capillaries and reduce local oxygen consumption, thereby reducing hidden blood loss (37).

There were some limitations in the current study. First, the sample size was relatively small. Second, this was a retrospective study and there was no control group. In addition, some variables such as the timing of drain removal and liquid balance, which may influence the outcome of hidden blood loss, were not included, and thus, these warrant further investigation. Last but not least, this was a single-center study, so the findings need to be subjected to further validation.

Conclusion

Preoperative hematocrit, blood volume, postoperative hematocrit, and gender are independent factors for hidden blood loss in patients undergoing minimally invasive treatment of the knee joint. More attention to, and adequate management of, these factors will help reduce postoperative hidden blood loss.

Data availability statement

The raw data supporting the conclusions of this article will be made available by the authors, without undue reservation.

Ethics statement

The studies involving human participants were reviewed and approved by the Institutional Review Committee (IRB) of the Central Hospital Affiliated to Shenyang Medical College. Written informed consent to participate in this study was provided by the participants' legal guardian/next of kin.

Author contributions

All authors contributed to data analysis, drafting, or revising the article, agreed on the journal to which the article will be submitted, gave final approval for the version to be published, and agreed to be accountable for all aspects of the work. All authors contributed to the article and approved the submitted version.

Funding

The present study was supported by the Effect of Ligament Stump Treatment on Bone Tendon Healing in Anterior Cruciate Ligament Injury (Doctoral Research Start-Up Fund of Shenyang Medical College 2020, no. 20205040, SL).

Conflict of interest

The authors declare that the research was conducted in the absence of any commercial or financial relationships that could be construed as a potential conflict of interest.

Publisher's note

All claims expressed in this article are solely those of the authors and do not necessarily represent those of their affiliated organizations, or those of the publisher, the editors and the reviewers. Any product that may be evaluated in this article, or claim that may be made by its manufacturer, is not guaranteed or endorsed by the publisher.

References

1. Liu S. Early reconstruction treatment of shot putters' acute complete anterior cruciate ligament injury under knee arthroscopy. *Biomed Res.* (2017) 28 (20):8818–21.

2. Huang HF, Tian JL, Sun L, Yang XT, Shen YK, Li SS, et al. The effect of anticoagulants on venous thrombosis prevention after knee arthroscopy: a systematic review. *Int Orthop.* (2019) 43(10):2303–8. doi: 10.1007/s00264-018-4212-4

3. Panagiotis K. Hidden blood loss in spine surgery for A1–A3 thoracolumbar fractures. Comparison between three approaches. *J Invest Surg.* (2019) 32 (8):761–2. doi: 10.1080/08941939.2018.1462418

4. Foss NB, Kehlet H. Hidden blood loss after surgery for hip fracture. *J Bone Joint Surg Br.* (2006) 88(8):1053–9. doi: 10.1302/0301-620X.88B8.17534

5. Sehat KR, Evans R, Newman JH. How much blood is really lost in total knee arthroplasty? Correct blood loss management should take hidden loss into account. *Knee.* (2000) 7:151–5. doi: 10.1016/S0968-0160(00)00047-8

6. Wang JQ, Huang XJ, Guo WJ, Zhao YM, Luo P. Hidden blood loss and the influential factors after intramedullary nail fixation of extra-articular tibial fractures - a retrospective cohort study. *Injury.* (2020) 51(6):1382–6. doi: 10.1016/j.injury.2020.04.025

7. Mima Y, Yagi M, Suzuki S, Tsuji O, Nagoshi N, Okada E, et al. Hidden blood loss in extreme lateral interbody fusion for adult spinal deformity. *J Orthop Sci.* (2022):S0949-2658(22)00014-8. doi: 10.1016/j.jos.2022.01.003

8. Nadler SB, Hidalgo JU, Bloch T. Prediction of blood volume in normal human adults. *Surgery.* (1962) 57:224–32.

9. Hu M, Zhang Y, Zhao WJ, Liu X, Shi PZ, Wang JW, et al. Perioperative hidden blood loss in lumbar disk herniation patients with percutaneous endoscopic transforaminal discectomy and influencing factors. *Clin Spine Surg.* (2022) 35(5):E438–E43. doi: 10.1097/BSD.0000000000001282

10. Tian S, Shen Z, Liu Y, Zhang Y, Peng A. The effect of tranexamic acid on hidden bleeding in older intertrochanteric fracture patients treated with PFNA. *Injury.* (2018) 49(3):680–4. doi: 10.1016/j.injury.2018.01.026

11. Cui H, Chen K, Lv S, Yuan C, Wang Y. An analysis of perioperative hidden blood loss in femoral intertrochanteric fractures: bone density is an important influencing factor. *BMC Musculoskelet Disord.* (2021) 22(1):6. doi: 10.1186/s12891-020-03922-x

12. Li B, Li J, Wang S, Liu L. Clinical analysis of peri-operative hidden blood loss of elderly patients with intertrochanteric fractures treated by unreamed proximal femoral nail anti-rotation. *Sci Rep.* (2018) 8:3225. doi: 10.1038/s41598-018-21703-4

13. Wang JQ, Chen ZX, Guo WJ, Zhao YM. Comparison of plate and intramedullary nail fixation of extra-articular tibial fractures: a retrospective study exploring hidden blood loss. *Injury.* (2019) 50(2):546–50. doi: 10.1016/j.injury.2018.12.016

14. Chen F, Xin J, Su C, Liu X, Cui X. Pain variability of tissues under endoscope in percutaneous endoscopic lumbar discectomy and its significance: a retrospective study. *Pain Phys.* (2021) 24(6):E877–82. doi: 10.36076/ppj.2021.24.E877

15. Ao S, Zheng W, Wu J, Tang Y, Zhang C, Zhou Y, et al. Comparison of preliminary clinical outcomes between percutaneous endoscopic and minimally invasive transforaminal lumbar interbody fusion for lumbar degenerative diseases in a tertiary hospital: is percutaneous endoscopic procedure superior to MIS-TLIF? A prospective cohort study. *Int J Surg.* (2020) 76:136–43. doi: 10.1016/j.ijsu.2020.02.043

16. Xu S, Liang Y, Wang J, Yu G, Guo C, Zhu ZQ, et al. Blood loss of posterior lumbar interbody fusion on lumbar stenosis in patients with rheumatoid arthritis: a case-control study. *Spine.* (2019) 44(17):E1045–52. doi: 10.1097/BRS.0000000000003037

17. Jia JX, Yan XS, Song W. *Modern Clinical Applied Anatomy*. Harbin: Heilongjiang Science and Technology Press (2018). 165–7 p.

18. Chen H, Wei JQ, Wang YW, Zhou KP, He Y, Liu H, et al. Protective effects of rocuronium bromide on ischemia-reperfusion injury in skeletal muscle induced by tourniquet in patients undergoing elective unilateral total knee arthroplasty: a prospective, double blind, randomized, controlled study. *Drug Des Devel Ther.* (2020) 14:3373–84. doi: 10.2147/DDDT.S252546

19. Delvasto NL, Roem D, Bakhtiari K, Van MG, Meijers JCM, Jongerius I, et al. Iron-driven alterations on red blood cell-derived microvesicles amplify coagulation during hemolysis via the intrinsic tenase complex. *Thromb Haemostasis.* (2022) 122(1):80–91. doi: 10.1055/a-1497-9573

20. Maksimovich E, Pronko T, Yanushko ZV, Gulay I, Snezhitsky V. Assessment of oxidative stress during coronary artery bypass grafting in persons with different degrees of intraoperative hemolysis (article). *Kardiol v Belarusi.* (2019) 11 (3):418–29.

21. Yuan T, Cong Y, Meng J, Qian H, Ye W, Sun WS, et al. Arachidonic acid causes hidden blood loss-like red blood cell damage through oxidative stress reactions. *J Surg Res.* (2017) 211(1):14–20. doi: 10.1016/j.jss.2016.11.060

22. Spina S, Lei C, Pinciroli R, Berra L. Hemolysis and kidney injury in cardiac surgery: the protective role of nitric oxide therapy. *Semin Nephrol.* (2019) 39 (5):484–95. doi: 10.1016/j.semnephrol.2019.06.008

23. Sovira N, Lubis M, Wahidiyat PA, Suyatna FD, Gatot D, Bardosono S. Effects of α-tocopherol on hemolysis and oxidative stress markers on red blood cells in β-thalassemia major. *Clin Exp Pediatr.* (2020) 63(8):314–20. doi: 10.3345/cep.2019.00542

24. Roubinian NH, Reese SE, Qiao H, Plimier C, Fang F, Page GP, et al. Donor genetic and nongenetic factors affecting red blood cell transfusion effectiveness. *JCI Insight.* (2022) 7(1):e152598. doi: 10.1172/jci.insight.152598

25. Kumskova MA, Zozulya N, Dvyrnik VN, Likhachyova E, Yakovleva E, Savchenko VG. Comparison of different phenotypes of Bernard–Soulier syndrome. *Blood.* (2017) 130(1):4856. doi: 10.1182/blood.V130.Suppl_1.4856.4856

26. Xing XX, Zhu C, Chu YQ, Bai XR, Wang K, Zhang ST, et al. Physicians' knowledge, attitude, and prescribing behavior regarding stress ulcer prophylaxis in China: a multi-center study. *BMC Gastroenterol.* (2021) 21(1):402. doi: 10.1186/s12876-021-01979-z

27. Michael S, Jürgen W, Sarah-Jayne E, Irene M, Jasmin R, Thomas G, et al. Is there a hidden blood loss in orthognathic surgery and should it be considered? Results of a prospective cohort study. *J Craniomaxillofac Surg.* (2021) 49 (7):545–55. doi: 10.1016/j.jcms.2020.07.015

28. Fei L, Zhongyang L, Wen H, Xinggui T, Lipeng Z, Jianping K, et al. Hidden blood loss and the risk factors after posterior lumbar fusion surgery: a retrospective study. *Medicine (Baltimore).* (2020) 99(19):e20103. doi: 10.1097/MD.0000000000020103

29. Tongchuan C, Dong C, Shuguang W, Pengzhi S, Junwu W, Pingchuan W, et al. Perioperative hidden blood loss in elderly cervical spondylosis patients with anterior cervical discectomy fusion and influencing factors. *Geriatr Orthop Surg Rehabil.* (2021) 12:1–6. doi: 10.1177/21514593211002164

30. Tao W, Junfei G, Zhiyong H. Risk factors for perioperative hidden blood loss after intertrochanteric fracture surgery in Chinese patients: a meta-analysis. *Geriatr Orthop Surg Rehabil.* (2022) 13:1–10. doi: 10.1177/21514593221083816

31. Ren-Rui W, Yong-Li W, Xiao-Chang W, Hai Q, Zhen-Hua T, Ren-Yi X, et al. Hidden blood loss and the influencing factors after laparoscopic cholecystectomy. *ANZ J Surg.* (2020) 90(1–2):103–8. doi: 10.1111/ans.15502

32. Zhixiang G, Cong X, Hongtao Y, Xiangyu M. Statistical decision tree model analysis on hidden blood loss in the perioperative period of thoracolumbar burst fracture accompanied with neurological deficiency. *Chin J Tissue Eng Res.* (2021) 21(15):2364–9. doi: 10.3969/j.issn.2095-4344.3817

33. Yuanxing Z, Xin F, Yang M, Ke S, Wang B, Zhonghai L. Hidden blood loss and its possible risk factors in minimally invasive transforaminal lumbar interbody fusion. *J Orthop Surg Res.* (2020) 15(1):445. doi: 10.1186/s13018-020-01971-5

34. Hui-liang S, Zheng L, Ming-li F, Guang-le C. Analysis on hidden blood loss of total knee arthroplasty in treating knee osteoarthritis. *Chin Med J.* (2011) 124 (11):1653–6. doi: 10.3760/cma.j.issn.0366-6999.2011.11.009

35. Akti S, Zeybek H, Bilekli AB, Çelebi NÖ, Erdem Y, Çankaya D. The effect of tranexamic acid on hidden blood loss in total hip arthroplasty. *Jt Dis Relat Surg.* (2022) 33(1):102–8. doi: 10.52312/jdrs.2022.446

36. Jun-An L, Hai-Dong C, Ye H, Shu-Jun L. Application of tranexamic acid in the treatment of intertrochanteric fracture of femur. *Chin J Orthop Traumatol.* (2021) 34(7):601–4. doi: 10.12200/j.issn.1003-0034.2021.07.003

37. Han M, Wu C. Effects of circulatory compression cold therapy combined with nursing intervention of behavior change theory on perioperative period hidden blood loss volume and coping style of patients with intertrochanteric fracture. *Curr Med Res Pract.* (2021) 6(8):153–5. doi: 10.19347/j.cnki.2096-1413.202108051

frontiers | Frontiers in Surgery

TYPE Original Research
PUBLISHED 12 September 2022
DOI 10.3389/fsurg.2022.945013

Check for updates

OPEN ACCESS

EDITED BY
Paphon Sa-ngasoongsong,
Ramathibodi Hospital, Mahidol University, Thailand

REVIEWED BY
Juitien Shih,
Taoyuan Armed Forces General Hospital, Taiwan
Yaodong Gu,
Ningbo University, China

*CORRESPONDENCE
Hua-Wei Yin
yinhuawei1983@126.com

SPECIALTY SECTION
This article was submitted to Orthopedic Surgery, a section of the journal Frontiers in Surgery

RECEIVED 16 May 2022
ACCEPTED 23 August 2022
PUBLISHED 12 September 2022

CITATION
Zheng W-L, Wu Y-C, Shen Y-D, Yin Hua-Wei and Xu W-D (2022) Arthroscopy-assisted partial trapeziectomy combined with ligament reconstruction for thumb carpometacarpal joint osteoarthritis: A different technique. Front. Surg. 9:945013. doi: 10.3389/fsurg.2022.945013

COPYRIGHT
© 2022 Zheng, Wu, Shen, Yin and Xu. This is an open-access article distributed under the terms of the Creative Commons Attribution License (CC BY). The use, distribution or reproduction in other forums is permitted, provided the original author(s) and the copyright owner(s) are credited and that the original publication in this journal is cited, in accordance with accepted academic practice. No use, distribution or reproduction is permitted which does not comply with these terms.

Arthroscopy-assisted partial trapeziectomy combined with ligament reconstruction for thumb carpometacarpal joint osteoarthritis: A different technique

Wan-Ling Zheng[1,2,3], Yang-Chun Wu[1,2], Yun-Dong Shen[1,2,4], Hua-Wei Yin[1,2,5]* and Wen-Dong Xu[1,2,3,4,5]

[1]Department of Hand Surgery, Huashan Hospital, Fudan University, Shanghai, China, [2]Department of Hand and Upper Extremity Surgery, Jing'an District Central Hospital, Shanghai, China, [3]National Clinical Research Center for Aging and Medicine, Huashan Hospital, Fudan University, Shanghai, China, [4]Priority Among Priorities of Shanghai Municipal Clinical Medicine Center, Shanghai, China, [5]Institute of Engineering and Application Technology, Fudan University, Shanghai, China

Background: There is no consensus on the best surgery option for thumb carpometacarpal osteoarthritis (CMC OA). The traditional method has the risk of large trauma, obvious metacarpal subsidence, and decreased stability. The aim of this study is to introduce a different technique to restore the function and stability of the first carpal metacarpal joint with minimal trauma, rapid pain relief, reduced complications, and the clinical outcomes in the long-term follow-up was evaluated and statistically analyzed.

Methods: This was a retrospective study of 10 patients with a mean age of 51.8 years. The surgery consisted of removing partial trapezium through arthroscopy, reconstructing the stability with flexor carpi radialis suspension and tendon interposition. The subjective assessment included visual analog scale (VAS) of pain, quick disabilities of the arm, shoulder, and hand (Quick-DASH) score, and patient satisfaction. The range of motion, grip strength, pinch strength, and radiographic assessment, which can reflect stability of the thumb, were objectively evaluated and statistically analyzed.

Results: Ten patients were monitored at a mean follow-up of 6.8 years. The mean grip strength improved significantly from 16.64 to 22.57 kg after surgery. Pinch strength improved significantly from 3.72 to 5.71 kg on average. The Kapandji score improved significantly from 5.7 to 8.6 on average. 80% (8/10) of the patients were satisfied with this surgery. On objective indicators, the VAS score decreased significantly from 6.4 to 1.3 on average. The mean Quick-DASH score improved significantly from 6.1 to 28.9. Postoperative x-ray showed slight subsidence and dislocation of the first metacarpal in two patients and did not affect the function by measurement.

Conclusion: Arthroscopy-assisted partial trapezium resection combined with ligament reconstruction could be a workable and promising surgical technique in patients with thumb CMC OA. It can offer the advantages of minimizing surgical injury by preserving the first carpal metacarpal joint

capsule to protect its stability, with a rapid pain relief, function improvement, and satisfactory results in patients' clinical measurements.

KEYWORDS

thumb, carpometacarpal joint (CMC), osteoarthritis, arthroscopy, ligament reconstruction and tendon interposition, trapeziectomy

Introduction

One out of three people aged 55 years and older have radiographic signs of carpometacarpal osteoarthritis (CMC OA) (1–3). Patients with mild symptoms in stage I and II can wear braces to increase stability and reduce mechanical stress. Patients of stage II to stage IV, in whom symptoms remain despite conservative treatment, should be treated by operation. There are numerous options in surgical treatment, such as trapeziectomy, ligament reconstruction, and tendon interposition or suspension arthroplasty (4–6). The traditional open trapeziectomy will destroy the joint capsule and affect the stability of the joint. Second, the classical flexor carpi radialis tendon reconstruction bypasses itself and is sutured and fixed in the first metacarpal bone, which will produce a downward pulling force during movement and may aggravate the sinking of the first metacarpal bone. In recent years, many studies have focused on new methods of tendon and ligament reconstruction, as well as minimally invasive surgery under wrist arthroscopy. However, there is still no consensus on the optimal treatment.

Compared with previous studies, this article introduced a different technique of arthroscopy-assisted partial trapezium resection, combined with ligament reconstruction and tendon interposition at the same time. This method not only reduces the damage to the capsular ligament and reduces the trauma but also partially maintains the height and stability of the metacarpal bone, which can be applied to more complex cases. Specifically, arthroscopy-assisted partial trapezium resection is less invasive compared with the parallel cross section of traditional open surgery. Moreover, the ball-and-socket joint was innovatively proposed in the surgery of the first carpal and metacarpal joint in this study. By modifying the saddle shape of the first carpal metacarpal joint into ball-and-socket joint, it may be more consistent with joint physiology and more stably adapt to the multidirectional activity requirements of the first carpal metacarpal joint. Finally, the classical approach of wrapping around the flexor carpi radialis has a downward force, which may aggravate the sinking of the first metacarpal. In our surgery, the approach of suturing around the first metacarpal itself creates an upward lifting force, theoretically reducing the sinking of the metacarpal.

The aim of this study was to introduce this different surgery, and the clinical outcomes in the long-term follow-up were evaluated and statistically analyzed.

Methods

Subjects

From January 2012 to December 2021, 13 patients with thumb CMC arthritis were empirically selected and treated with this method, out of which 3 patients were lost to follow-up, leaving 10 patients (5 males and 5 females) for analysis. The indication criteria were patients with thumb CMC OA in stage II and stage III, combined with metacarpal dislocation, which required tendon and ligament reconstruction. One patient in stage IV strongly requested to attempt this surgery to delay the progression of arthritis due to the risk of metacarpal subsidence and instability after total trapeziectomy. All patients had clinical symptoms after at least 3 months of conservative treatment, confirmed by x-ray examination (**Figure 1**). According to Eaton staging (7), there were five patients in stage II, four patients in stage III, and one patient in stage IV.

Surgical procedure

Under general anesthesia, the patient was supine on an operating table with an arm board. A tourniquet (pressure: 34 kPa, limit time: 60 min) and wrist joint distraction of 15 lb were applied.

Stage I: arthroscopy-assisted partial trapezium resection

In the first step, two 4 mm transverse portals are made along the dorsoradial border of the hand with the thumb CMC joint as the center. The viewing camera is placed on the dorsoradial 1R portal to explore the articular surface; the shaver and radiofrequency are introduced in the dorsoulnar 1U portal to remove the hyperplastic synovium in the first CMC joint. The scaphoid trapezium trapezoid joint was explored and treated with the same method if needed. Then, arthroscopic partial resection of the trapezium is performed. Partial trapeziectomy is performed with the 1.9 mm burr, and part of the articular surface is removed until it shows hemispherical fossa of 3 mm depth (**Figure 2**). We polish the saddle joint and create a space for a tendon ball

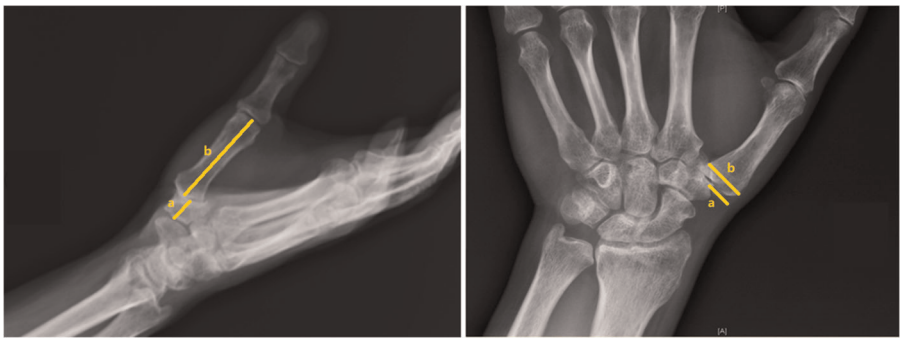

FIGURE 1
Radiograph of CMC OA with loss of joint space and radial dislocation. (Left) (a): axis of the trapezium and (b): axis of the first metacarpal; (right) (a): uncovered length of trapezium and (b): total length of trapezium.

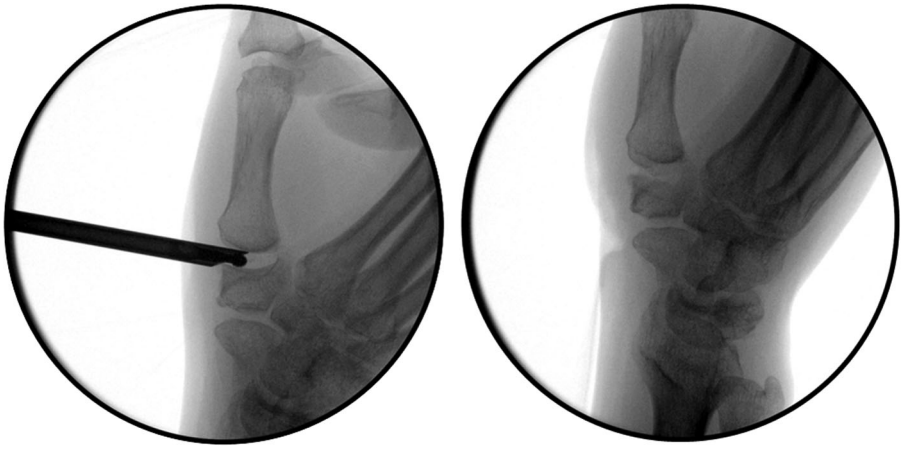

FIGURE 2
Arthroscopy-assisted partial trapezium resection. (Left): Partial trapeziectomy is performed with the 1.9 mm burr. (Right): The articular surface of the part of the trapezium is removed until it shows hemispherical fossa.

(**Supplementary Video S1**). The spur is resected to improve the range of motion (ROM) and symptoms as well as increase the stability of the basal joint.

Stage II: ligament reconstruction

A transverse incision is made at approximately 5 cm level of the transverse wrist lines to expose the flexor carpi radialis. The radial half of the tendon is transected and dissociated distally to the level of the CMC joints (**Figure 3**). A 3.0 mm k-wire is drilled gradually to expand the bone hole. Then, the strip of the flexor carpi radialis is passed from the palmar side through the transosseous tunnel in the first metacarpal to the dorsal side, and the first metacarpal bone is fixed to the second metacarpal bone with a 1.5 mm k-wire. After wrapping around the base of first metacarpal, the spare flexor tendon is sutured with itself on the volar side. The remaining tendons are sutured to form a tendon ball.

A grasper was inserted into the CMC joint from the 1R portal, which came out from the volar portal, to take the tendon ball from palmer side into the CMC joint space. Suture was used to fix the tendon ball to the dorsal side of joint capsule to prevent displacement. Large incision of the thumb CMC capsule is avoided during the whole procedure (**Figure 4**).

Postoperative management

After the surgery, a short-arm cast is fixed for 4 weeks, followed by a removable splint for another 4 weeks. The Kirschner wire was removed after 2 months (**Figure 5**). Then, patients were allowed unrestricted use of the wrist.

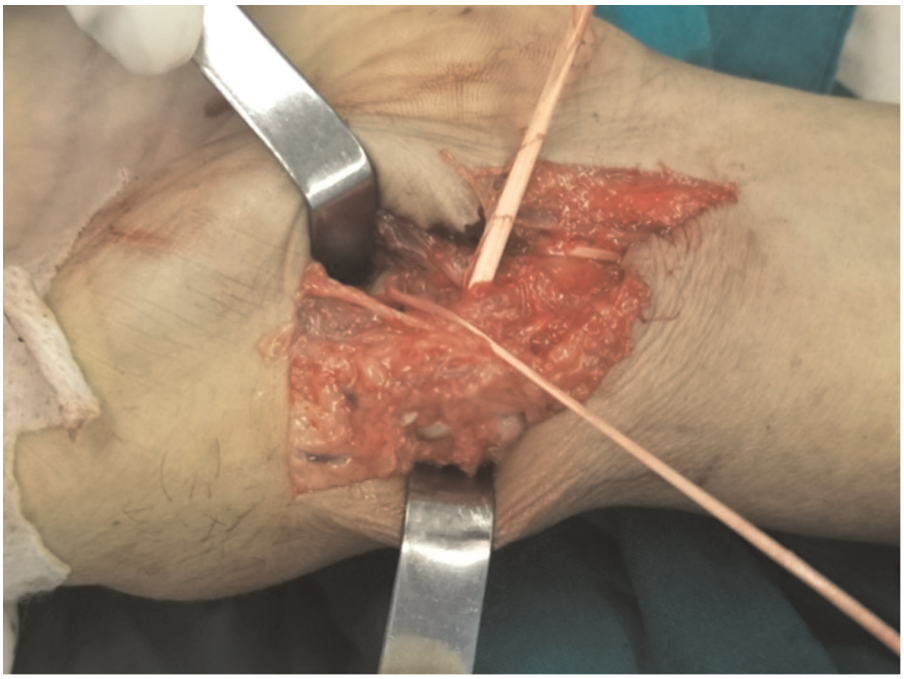

FIGURE 3
The radial half of the tendon is transected and dissociated distally to the level of the CMC joints.

Postoperative evaluation

Patients were followed up at 2 months, 6 months, and every year after surgery. Clinical data were collected by an independent examiner. As compared with the preoperative condition and contralateral side, the clinical evaluation studied the ROM of the first column according to the Kapandji score (8). Grip strength was measured in kg using a Jamar (9) dynamometer, and pinch strength were measured in kg using the Preston (10) pinchmeter. Radiographs were taken in anterior and lateral planes before and after surgery. They were screened for dislocation, subsidence, and adjacent joint OA and can be used to assess joint stability (11).

At the last follow-up visit before summary, the pain intensity was evaluated on a visual analog scale (VAS) (12) from 0 (no pain) to 10 (worst imaginable pain). The ability to carry out daily life activities was evaluated based on the quick disabilities of the arm, shoulder, and hand (Quick-DASH) (13) questionnaire. Subjective evaluation of satisfaction was done with an analytical questionnaire ranging from 0 (dissatisfaction) to 10 (great satisfaction). In addition, the patient's impression of thumb stability and ROM were evaluated by subjective as compared with the preoperative condition.

Statistical analysis

Data are presented as the mean ± standard deviation and 95% confidence intervals. The group means were compared using analysis of Student's t test. Statistical analysis was performed using SPSS 20 and $p < 0.05$ was recognized as significant.

Results

All patients underwent surgery in the same center between January 2012 and December 2021. The average age at admission was 51.8 years (range: 33–62). Mean follow-up was 6.8 years (range: 10–128 months). Preoperative characteristics are summarized in **Table 1**.

First, the 1-year follow-up data were analyzed in **Table 2**. Compared to the preoperative condition, the grip strength improved significantly to an average of 22.57 kg ($p = 0.003$). There was no significant difference relative to the grip strength in the healthy hand, which was 24.61 kg on average ($p = 0.29$). The postoperative pinch strength was also better than preoperative condition (3.72 kg preoperative, 5.71 kg postoperative, $p = 0.04$). Range of motion improved in the Kapandji score (preoperative at 5.70, postoperative at 8.60, $p < 0.001$).

Postoperative x-ray showed good joint position with neat axis alignment. Except for one patient who needed joint replacement due to severe polyarthritis of unknown cause, there was no complication like radial nerve injury, tendon rupture, tendinitis, or adjacent joint OA. At 1-year follow-up, two patients had slight metacarpal subsidence and dislocation, which did not affect the function according to the measurement.

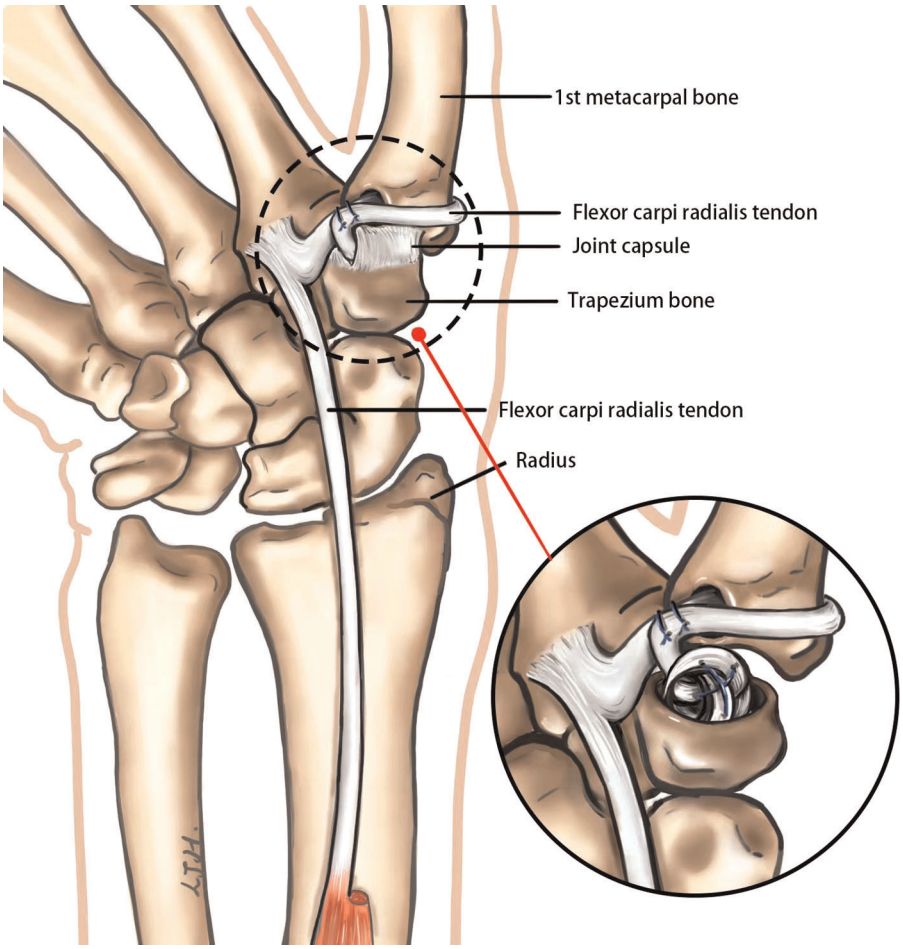

FIGURE 4
Ligament reconstruction. Surrounding the base of first metacarpal, one half of the tendon passes from the volar side to the dorsal side through the transosseous tunnel in first metacarpal and sutures with itself on the volar side.

At the final assessment, the pain was significantly decreased in all patients, the mean VAS decreased from 6.4 ± 1.3 to 1.1 ± 1.6 ($p < 0.001$), and the dexterity of the injury hand recovered well with a mean Quick-DASH score increased from 6.1 ± 13.2 to 28.9 ± 13.2 ($p = 0.001$). All patients reported a significant reduction in pain, and the Quick-DASH score was significantly increased than the preoperative condition (**Figure 6**). Meanwhile, thumb stability and ROM were also greatly improved than the preoperative condition. 80% (8/10) of the patients were satisfied with this surgery, and the mean satisfaction rating score was 8.8 ± 1.7. Detailed results are summarized in **Table 3**.

Discussion

Following the interphalangeal joints, the thumb CMC joint is the second most frequent site of hand OA (14–17). There are numerous options in surgical treatment for CMC OA, with evidence for pain relief and function improved (18). However, comparative studies on different methods and techniques have failed to clarify which techniques are best for treating CMC OA (19). In most hand surgery departments, trapeziectomy combined with ligament reconstruction and tendon interposition is still the most commonly performed technique (20). Compared to trapeziectomy alone, partial resection partially maintained the height of the first metacarpal, and the use of ligamentoplasty adds stability and hence decreases articular irritation (21). Moreover, tendon interposition provides a good buffer while maintaining height, which also helps delay the progression of arthritis. In addition, the advantages of arthroscopy are minimal trauma, rapid recovery, clear field exposure, and its convenience to remove the spur between first and second metacarpal base area to improve symptoms. Although the difficulty of the operation is slightly increased, the operation can be simplified according to

10.3389/fsurg.2022.945013

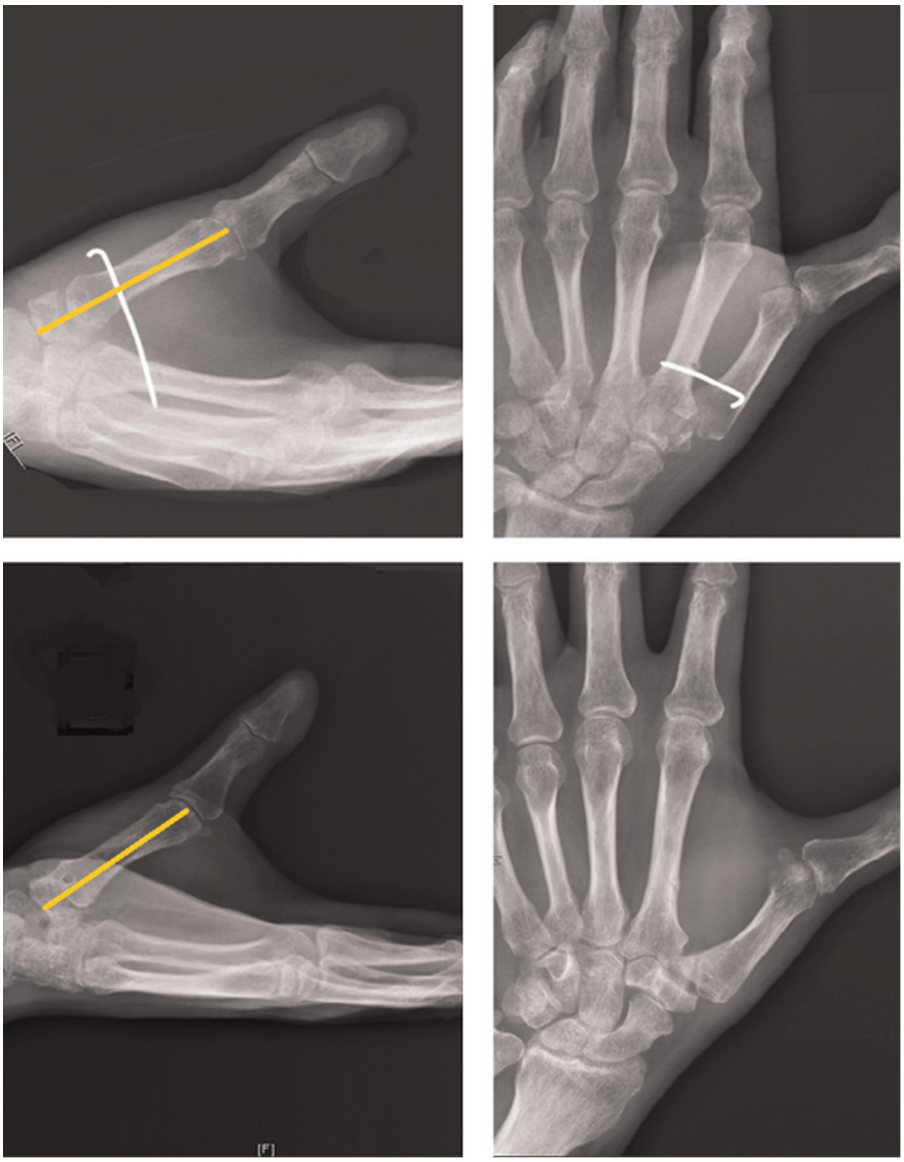

FIGURE 5
Fluoroscopy shows a good position with slight subsidence of the first metacarpal bone. (Above): Two months after surgery. (Below): Six months after surgery.

TABLE 1 Demographics of patients at baseline.

Number	Sex	Age	Injured hand	Eaton stage	Duration time (months)	Dominant hand	Causes
1	Male	53	Right	II	6	Right	Injury
2	Male	53	Left	II	4	Right	Degenerative
3	Female	59	Left	II	3	Right	Rheumatoid
4	Female	55	Left	III	6	Right	Degenerative
5	Female	62	Right	III	6	Left	Unknown cause
6	Female	57	Right	II	48	Right	Injury
7	Male	33	Right	III	24	Right	Degenerative
8	Male	39	Right	II	9	Right	Injury
9	Male	48	Left	IV	12	Right	Injury
10	Female	59	Left	III	12	Right	Degenerative

TABLE 2 Comparison of objective outcomes in the preoperative period and 1-year follow-up.

Hand measurements	Side	Mean	Difference
Grip strength, kg	Injury hand (pre)	16.64 ± 1.22 95% CI (13.88–19.40)	$P_{(pre/post)} = 0.003$ 95% CI (0.10–3.88)
	Injury hand (post)	22.57 ± 1.23 95% CI (19.79–25.35)	
	Healthy hand	24.61 ± 1.42 95% CI (21.41–27.81)	$P_{(I/H)} = 0.29$
Pinch strength, kg	Injury hand (pre)	3.72 ± 0.54 95% CI (2.12–4.88)	$P_{(pre/post)} = 0.04$ 95% CI (2.29–9.57)
	Injury hand (post)	5.71 ± 0.71 95% CI (4.10–7.32)	
	Healthy hand	5.98 ± 0.68 95% CI (4.45–7.51)	$P_{(I/H)} = 0.79$
ROM, Kapandji score	Injury hand (pre)	5.70 ± 0.56 95% CI (4.44–6.96)	$P_{(pre/post)} < 0.001$ 95% CI (1.53–4.27)
	Injury hand (post)	8.60 ± 0.34 95% CI (7.83–9.37)	
	Healthy hand	9.1 ± 0.23 95% CI (8.57–9.628)	$P_{(I/H)} = 0.24$

$P_{(pre/post)}$ means the difference between injury hand preoperative and postoperative. $P_{(I/H)}$ means the difference between injury hand and healthy hand.

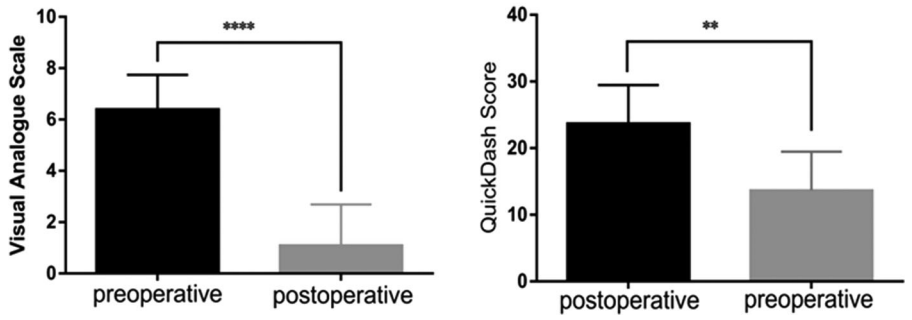

FIGURE 6
(Left) VAS values for pain. (Right) Quick-DASH score outcomes. **$p = 0.001$ and ****$p < 0.0001$.

TABLE 3 Comparison of subjective outcomes in the preoperative period and the last follow-up.

Number	Follow-up time (months)	VAS (pre/post)	Quick-DASH (pre/post)	Thumb stability	ROM	Satisfaction score
1	128	8/2	13/25	Unstable	Improved	8
2	94	7/0	11/26	Stable	Normal	10
3	95	5/0	11/22	Stable	Improved	10
4	88	5/0	11/23	Stable	Normal	10
5	100	8/5	30/38	Stable	Limited	5
6	88	5/1	13/16	Improved	Normal	10
7	57	5/0	11/20	Stable	Normal	7
8	57	7/2	13/23	Stable	Improved	9
9	10	6/1	12/20	Stable	Improved	9
10	107	8/0	12/24	Stable	Normal	10

VAS, visual analog scale; Quick-DASH, quick disabilities of the arm, shoulder, and hand; ROM, range of motion.

the patient's condition, and the application scope is wider, which has the opportunity to become the gold standard of such surgery.

The thumb CMC joint is known as the saddle joint; this shallow biconcave–convex saddle shape provides little bony stability, and thus the joint relies heavily on its flexible capsular ligaments to prevent subluxation and allow a wide arc of motion (22–24). The main advantage of our procedure is that the large incision of the thumb CMC capsule is avoided. Previous method of partial trapeziectomy is to open the capsule and make the partial trapeziectomy with oscillating saw to form a plain surface. In this procedure, a 1.9 mm burr was used to accomplish the partial trapeziectomy through small portal to minimize the injury to capsule. In

addition, hemispherical fossa might be more suitable to hold the tendon ball rather than a plain surface. Although it partially changes the physiology of the joint, it has the opportunity to become a new surgical concept for the treatment of joint diseases and has the potential to be further explored. For the tendon ball interposition step, a grasper is used to take the tendon ball into the joint space. Thus, large incision of the thumb CMC capsule is avoided during the whole procedure. These modifications make it possible to preserve the joint capsule to protect joint instability.

The results of our research have shown that this technique can significantly improve patients' clinical measurements, functional scores, and relieve patients' pain with a low complication rate. Although two patients had slight metacarpal subsidence and dislocation, it did not affect function by measurement. This finding is consistent with a recent study which concluded that there was no relationship between postoperative first metacarpal subsidence and functional outcomes (25). The surgical precautions are as follows: (1) Blunt dissection to prevent damage to the radial nerves and CMC capsule; (2) The bone holes should be smooth to prevent the tendon from breaking under stress; (3) The spur should be resected to improve ROM and symptoms and also increase the stability of basal joint; (4) The tendon ball is sutured to the dorsal side of the capsule to prevent displacement.

The study has some limitations. First, our study is a retrospective long-term review, which may include the inherent bias and underestimated the complication rate (26). To overcome the lack of a comparison group for there is no gold standard procedure for this disease, we compared data with preoperative and healthy side. Because the recovery effect was well, further research with a larger sample size is needed for verification, and further horizontal comparison of different surgical methods to screen out the gold standard CMC OA treatment is meaningful.

Conclusions

This long-term follow-up study indicates that arthroscopy-assisted partial trapezium resection combined with ligament reconstruction could be a workable and promising surgical technique in patients with thumb CMC OA. It can offer the advantages of minimizing surgical injury by preserving the first carpal metacarpal joint capsule to protect its stability, with rapid pain relief, function improvement, and satisfactory results in patients' clinical measurements.

Data availability statement

The raw data supporting the conclusions of this article will be made available by the authors, without undue reservation.

Ethics statement

The studies involving human participants were reviewed and approved by the ethics committee of our hospital. Written informed consent to participate in this study was obtained from all participants.

Author contributions

H-WY and W-DX designed the study. Y-CW, W-LZ, and Y-DS collected and prepared the data. W-LZ and H-WY drafted the article. All of the authors critically revised the article. W-DX supervised the study. All authors contributed to the article and approved the submitted version.

Funding

This work was supported by the National Natural Science Foundation of China (81801941 and 82021002), the Shanghai Technology Innovation Plan (21Y11902900), the Shanghai Municipal Clinical Medical Center Project (2017ZZ01006), and the Program of Shanghai Municipal Commission of Health and Family Planning (20164Y0018).

Conflict of interest

The authors declare that the research was conducted in the absence of any commercial or financial relationships that could be construed as a potential conflict of interest.

Publisher's note

All claims expressed in this article are solely those of the authors and do not necessarily represent those of their affiliated organizations, or those of the publisher, the editors and the reviewers. Any product that may be evaluated in this article, or claim that may be made by its manufacturer, is not guaranteed or endorsed by the publisher.

Supplementary material

The Supplementary Material for this article can be found online at: https://www.frontiersin.org/articles/10.3389/fsurg.2022.945013/full#supplementary-material.

References

1. Dahaghin S, Bierma-Zeinstra SM, Ginai AZ, Pols HA, Hazes JM, Koes BW. Prevalence and pattern of radiographic hand osteoarthritis and association with pain and disability (the Rotterdam study). *Ann Rheum Dis*. (2005) 64(5):682–7. doi: 10.1136/ard.2004.023564

2. Becker SJ, Briet JP, Hageman MG, Ring D. Death, taxes, and trapeziometacarpal arthrosis. *Clin Orthop Relat Res*. (2013) 471(12):3738–44. doi: 10.1007/s11999-013-3243-9

3. Sodha S, Ring D, Zurakowski D, Jupiter JB. Prevalence of osteoarthrosis of the trapeziometacarpal joint. *J Bone Joint Surg Am*. (2005) 87(12):2614–8. doi: 10.2106/00004623-200512000-00003

4. Cobb TK, Walden AL, Cao Y. Long-term outcome of arthroscopic resection arthroplasty with or without interposition for thumb basal joint arthritis. *J Hand Surg Am*. (2015) 40:1844–51. doi: 10.1016/j.jhsa.2015.05.010

5. Asltissimi M, Pataia E, Rampoldi M, Azzarà A, Braghiroli L. Trapeziectomy and suspension arthroplasty with the flexor carpi radialis tendon for treatment of trapeziometacarpal osteoarthritis. *Hand Surg Rehabil*. (2021) 40(2):162–6. doi: 10.1016/j.hansur.2020.11.010

6. Fulchignoni C, Morini A, Panzera RM, Merendi G, Rocchi L. F. brunelli ligamentoplasty as treatment in thumb basal joint arthritis: up to 9 years follow-up. *Tech Hand Up Extrem Surg*. (2020) 25(2):77–83. doi: 10.1097/BTH.0000000000000308

7. Eaton RG, Glickel SZ. Trapeziometacarpal osteoarthritis. Staging as a rationale for treatment. *Hand Clin*. (1987) 3(4):455–71. doi: 10.1016/S0749-0712(21)00761-7

8. Kapandji A. Clinical test of apposition and counter-apposition of the thumb. *Ann Chir Main*. (1986) 5:67–73. doi: 10.1016/S0753-9053(86)80053-9

9. Schmidt RT, Toews JV. Grip strength as measured by the Jamar dynamometer. *Arch Phys Med Rehabil*. (1970) 51:321–7. PMID: 5423802

10. Hook WE, Stanley JK. Assessment of thumb to index pulp to pulp pinch grip strengths. *J Hand Surg Br*. (1986) 11B:91–2. doi: 10.1016/0266-7681_86_90024-0

11. Gummesson C, Ward MM, Atroshi I. The shortened disabilities of the arm, shoulder and hand questionnaire (QuickDASH): validity and reliability based on responses within the full-length DASH. *BMC Musculoskelet Disord*. (2006) 7:44. doi: 10.1186/1471-2474-7-44

12. Froschauer SM, Holzbauer M, Mihalic JA, Kwasny O. TOUCH® prosthesis for thumb carpometacarpal joint osteoarthritis: a prospective case series. *J Clin Med*. (2021) 10(18):4090. doi: 10.3390/jcm10184090

13. Villafañe JH, Valdes K, Bertozzi L, Negrini S. Minimal clinically important difference of grip and pinch strength in women with thumb carpometacarpal osteoarthritis when compared to healthy subjects. *Rehabil Nurs*. (2017) 42(3):139–45. doi: 10.1002/rnj.196

14. Marotta N, Demeco A, Marinaro C, Moggio L, Pino I, Barletta M, et al. Comparative effectiveness of orthoses for thumb osteoarthritis: a systematic review and network meta-analysis. *Arch Phys Med Rehabil*. (2021) 102(3):502–9. doi: 10.1016/j.apmr.2020.06.012

15. Gillis J, Calder K, Williams J. Review of thumb carpometacarpal arthritis classification, treatment and outcomes. *Can J Plast Surg*. (2011) 19(4):134–8. doi: 10.1177/229255031101900409

16. Rocchi L, Merolli A, Giordani L, Albensi C, Foti C. Trapeziometacarpal joint osteoarthritis: a prospective trial on two widespread conservative therapies. *Muscles Ligaments Tendons J*. (2018) 7(4):603–10. doi: 10.32098/mltj.04.2017.16

17. Prosser R, Hancock MJ, Nicholson L, Merry C, Thorley F, Wheen D. Rigid versus semi-rigid orthotic use following TMC arthroplasty: a randomized controlled trial. *J Hand Ther*. (2014) 27(4):265–70, quiz 271. doi: 10.1016/j.jht.2014.06.002

18. Wolf JM, Turkiewicz A, Englund M, Karlsson J, Arner M, Atroshi I. What are the patient-reported outcomes of trapeziectomy and tendon suspension at long-term follow-up? *Clin Orthop Relat Res*. (2021) 479(9):2009–18. doi: 10.1097/CORR.0000000000001795

19. Hentz VR. Surgical treatment of trapeziometacarpal joint arthritis: a historical perspective. *Clin Orthop Relat Res*. (2014) 472:1184–9. doi: 10.1007/s11999-013-3374-z

20. Ashford-Wilson S, Ghazala CG, McLaughlin K, Harrison JWK. Failed trapeziectomy treated by thumb metacarpal base arthrodesis: a case series. *Tech Hand Up Extrem Surg*. (2021) 25(4):219–25. doi: 10.1097/BTH.0000000000000338

21. McVeigh KH, Kannas SN, Ivy CC, Garner HW, Barnes CS, Heckman MG, et al. Dynamic stabilization home exercise program for treatment of thumb carpometacarpal osteoarthritis: a prospective randomized control trial. *J Hand Ther*. (2021) S0894-1130(21):00083-1. doi: 10.1016/j.jht.2021.06.002

22. Goorens CK, Goubau J, Van Hoonacker P, Kerckhove D, Berghs B, Scheerlinck T. Addition-subtraction osteotomy without ligamentoplasty for symptomatic trapezial dysplasia with metacarpal instability. *Acta Orthop Belg*. (2013) 79(5):517–23. doi: 10.1016/j.main.2013.07.001

23. Rusli WMR, Mirza E, Tolerton S, Yong S, Johnson R, Horwitz MD, et al. Ligamentous constraint of the first carpometacarpal joint. *J Biomech*. (2021) 128:110789. doi: 10.1016/j.jbiomech.2021.110789

24. Ladd AL, Weiss AP, Crisco JJ, Hagert E, Wolf JM, Glickel SZ, et al. The thumb carpometacarpal joint: anatomy, hormones, and biomechanics. *Instr Course Lect*. (2013) 62:165–79. PMID: 23395023; PMCID: pmc3935621

25. Mirza A, Mirza JB, Klingbeil L, Pavlik 3rd JF, Muratori J, Thomas T. A modified suture suspension arthroplasty technique for the treatment of basal joint arthritis: short- to intermediate-term outcomes. *Hand*. (2021) 16(6):797–803. doi: 10.1177/1558944719886669

26. Van Laarhoven CMCA, Ottenhoff JSE, van Hoorn BTJA, van Heijl M, Schuurman AH, van der Heijden BEPA. Medium to long-term follow-up after pyrocarbon disc interposition arthroplasty for treatment of CMC thumb joint arthritis. *J Hand Surg Am*. (2021) 46(2):150.e1–150.e14. doi: 10.1016/j.jhsa.2020.07.025

frontiers | Frontiers in Surgery

TYPE Original Research
PUBLISHED 14 September 2022
DOI 10.3389/fsurg.2022.917853

Check for updates

EDITED BY
Paphon Sa-ngasoongsong,
Mahidol University, Thailand

REVIEWED BY
Nobuyuki Yamamoto,
Tohoku University, Japan
Osvaldo Mazza,
Bambino Gesù Children's Hospital (IRCCS), Italy
Yunfei Hou,
Peking University People's Hospital, China

*CORRESPONDENCE
Rui Yang
yangr@mail.sysu.edu.cn
Jingyi Hou
houjy7@mail.sysu.edu.cn

†These authors have contributed equally to this work.

SPECIALTY SECTION
This article was submitted to Orthopedic Surgery, a section of the journal Frontiers in Surgery

RECEIVED 11 April 2022
ACCEPTED 26 August 2022
PUBLISHED 14 September 2022

CITATION
Zhou M, Zhou C, Cui D, Long Y, Guo J, Zheng Z, Meng K, Zhang J, Hou J and Yang R (2022) The high resistance loop (H-loop) technique used for all-inside arthroscopic knotless suprapectoral biceps tenodesis: A case series. Front. Surg. 9:917853. doi: 10.3389/fsurg.2022.917853

COPYRIGHT
© 2022 Zhou, Zhou, Cui, Long, Guo, Zheng, Meng, Zhang, Hou and Yang. This is an open-access article distributed under the terms of the Creative Commons Attribution License (CC BY). The use, distribution or reproduction in other forums is permitted, provided the original author(s) and the copyright owner(s) are credited and that the original publication in this journal is cited, in accordance with accepted academic practice. No use, distribution or reproduction is permitted which does not comply with these terms.

The high resistance loop (H-loop) technique used for all-inside arthroscopic knotless suprapectoral biceps tenodesis: A case series

Min Zhou†, Chuanhai Zhou†, Dedong Cui, Yi Long, Jiang Guo, Zhenze Zheng, Ke Meng, Jinming Zhang, Jingyi Hou* and Rui Yang*

Department of Orthopaedic Surgery, Sun Yat-sen Memorial Hospital, Sun Yat-sen University, Guangzhou, China

Introduction: Suprapectoral tenodesis is a common technique for the treatment of long head biceps tendon lesions. However, so far, there is no gold standard treatment in all-inside arthroscopy. The purpose of the present study was to introduce and evaluate the functional outcomes of an innovative, all-inside arthroscopic high resistance loop (H-loop, high resistance to tissue cutout and 360° grasping of the tendon) technique for long head of biceps (LHB) tenodesis.

Method: From September 2020 to March 2022, a series of cases of 32 consecutive patients (28 rotator cuff tear with LHBT pathology and 4 superior labrum anterior-posterior (SLAP) tears which including 2 type II and 2 type IV) who received LHB tenodesis using all-inside arthroscopic high resistance loop technique were included in this study. The American Shoulder and Elbow Surgeon Score (ASES), Visual Analog Scale (VAS), Simple Shoulder Test Score (SST), Constant–Murley scores, and University of California at Los Angeles Scoring System (UCLA) were used to evaluate the clinical outcomes of patients in preoperative and final follow-up. Meanwhile, postoperative complications were also observed.

Result: 32 patients (14 women and 18 men, average age was 55.7 years) underwent all-inside arthroscopic knotless suprapectoral biceps tenodesis using the H-Loop stitch technique. The mean time of follow-up was 16.2 ± 2.6 months. The ASES, VAS, Constant–Murley, SST, and UCLA scores improved from 51.5 ± 15.8, 5.5 ± 1.6, 57.8 ± 14.7, 5.0 ± 2.8, and 16.1 ± 3.8 preoperatively, to 89.1 ± 7.5, 1.0 ± 0.8, 87.3 ± 5.5, 10.4 ± 1.5, and 31.3 ± 2.6 in the last follow-up, respectively ($p < 0.001$). During the follow-up, no patients in this study experienced postoperative complications such as infection of the wound, injury of nerves, and hardware failure; no patients required revision after their operation. In addition, none of the patients had cramping or a "Popeye" deformity during follow-up.

Abbreviations
LHBT, long head of biceps tendon; H-loop, high resistance loop; ASES, American Shoulder and elbow surgeon score; VAS, visual analog scale; SST, simple shoulder test score; UCLA, Los Angeles scoring system; PDS, polydioxanone suture.

Conclusion: This article presents an innovative, all-arthroscopic H-loop technique for LHB tenodesis. This technique for LHB tenodesis showed favorable functional and cosmetic outcomes, as well as high satisfaction rates. Due to its simplicity of operation and satisfactory preliminary clinical outcomes, H-loop technique is perhaps another option to choose in all-inside arthroscopic LHB tenodesis.

KEYWORDS

biceps tenodesis, H-loop, all-inside, arthroscopy, functional outcomes

Introduction

Lesions of the long head of the biceps tendon (LHBT) usually lead to pain of the shoulder and disability, and more than 60% of patients have a rotator cuff tear (1). Tenotomy and tenodesis are effective but controversial techniques for the treatment of LHBT lesions; however, there was no difference in functional results between tenotomy and tenodesis in recent studies (2).

LHBT tenotomy is technically easier to perform and is associated with early amelioration of post-operative pain, but the incidence of cosmetic deformities is higher (25%–62%) (3–5). However, in young or elderly patients with higher requirements, tenodesis is suggested to reduce the occurrence of cramping, "Popeye" deformity, and weakness in the biceps brachii (6, 7).

To overcome this problem, several LHBT fixation techniques have been described, including open and arthroscopic techniques, which provided satisfactory results without clinically significant differences (8, 9). A study performed by Gombera et al. compared arthroscopic with open LHB tenodesis (10). The results showed similar clinical outcomes between the arthroscopic suprapectoral tenodesis and open subrapectoral tenodesis groups. However, they announced that open subpectoral tenodesis may be associated with an increased risk of complications because of its requirement to expose more tissue. For open subrapectoral tenodesis, some complications have been reported, such as neurovascular injury (11, 12), fractures (13–16), and deep infection (17, 18); but the complications above can be mitigated by adopting an arthroscopic approach (19–21).

Numerous types of tenodesis techniques can be used to treat LHBT pathology, such as suture anchor, interference screw, and cortical button (22–24). Biomechanics studies have evaluated these different tenodesis techniques and showed slight differences; but there was no difference in clinical outcomes (6, 25, 26). Therefore, using a relatively simple and safe fixation method is the best choice for tenodesis.

Regarding tenodesis with suture anchor *via* arthroscopy, the Lasso-Loop stitch was commonly used (27–31).This technique provided strong tissue grasping ability, which was equivalent to interference screws (32). However, compared to the Krakow Stitch, Lasso-Loop stitch had a critical defect where the uneven load distribution of sutured tendon might lead to poor tendon fixation strength (33).

To solve these specific problems, a new Loop stich, high resistance loop (H-Loop) (invented by Jingyi Hou), was developed to provide 360° grasping of the tendon and to correct unevenness of sutured tendon load distribution. In this study, the circumferential high resistance loop grasping LHBT was introduced. The purposes of this research were: (i) to present the H-Loop stitch technique in arthroscopic LHB tenodesis; (ii) to assess the preliminary outcomes in patients with LHB tenodesis using the H-Loop stitch technique.

Materials and methods

Patient selection

The study was approved by the Ethics Committee of Sun Yat-sen Memorial Hospital of Sun Yat-sen University (SYSEC-KY-KS-2021-303), and abided by the Declaration of Helsinki and the Guidelines for Good Clinical Practice. A retrospective case series data on patients between September 2020 and March 2022 who have undergone all-inside arthroscopic knotless suprapectoral biceps tenodesis with H-Loop stitch by the senior author (R.Y.) was prospectively and consecutively collected.

The inclusive criteria included: (i) patients over 18 years of age who were diagnosed with LHBT pathologies; (ii) all arthroscopic biceps tenodesis with H-Loop stitch technique performed together with arthroscopic repair of a rotator cuff tear or superior labrum anterior-posterior (SLAP) tears; (iii) magnetic resonance imaging demonstrating LHBT pathologies that did not improve with conservative treatment after 6 months; (iv) shoulder functions were recorded and the pre- and post-operative last follow-up were compared using the American Shoulder and Elbow Surgeon Score (ASES) (34), Visual Analog Scale (VAS), Simple Shoulder Test Score (SST), Constant–Murley scores (35), and University of California at Los Angeles Scoring System (UCLA) (36). Exclusion criteria included: revision surgery after rotator cuff repair, shoulder osteoarthritis, adhesive capsulitis, and individuals with marked deformity and/or neuromuscular diseases.

According to the inclusion and exclusion criteria, a total of 32 consecutive patients (14 women, 18 men) who were diagnosed with LHBT lesions (28 rotator cuff tear with LHBT pathology

and 4 superior labrum anterior-posterior (SLAP) tears which including 2 type II and 2 type IV) and were surgically treated with the all-inside arthroscopic knotless suprapectoral biceps tenodesis with H-Loop stitch were enrolled in this study. Before the operation, all patients received extensive shoulder examination, including physical, x-ray, and MRI examination, and were diagnosed with LHBT lesion with or without other concomitant diseases of the shoulder.

Surgical technique

Anesthesia and patient positioning

After general anesthesia, the patient was placed in a lateral decubitus position on the operation table. Then, the operative shoulder was placed at 20° forward flexion and 35°–45° abduction. Continuous traction was applied through the ipsilateral upper extremity to gain a larger operative space in the glenohumeral joint.

Diagnostic arthroscopy

The standard routine portal was established in turn: posterior, anterior, and anterolateral portal. The glenohumeral joint and long head of the biceps tendon was examined thoroughly through the posterior portal. To clarify the pathological changes of the intertubercular groove part of the LHBT, the LHB needs to be pulled toward the intra-articular area using probes from the anterior approach. Hence, an anterior approach was established under arthroscopic surveillance. Additionally, a lateral portal was established by spinal needle for rotator cuff repair (Figure 1).

The H-loop stitch technique for long head of the biceps tendon

Once the LHBT tenodesis was determined, a FiberWire suture (2#, Arthrex, Naples, FL) was folded in half and inserted into the capsule with the suture grasper from the anterior portal. The suture was first released at the superior aspect of the tendon near the insertion point. One free end of the suture was held on to outside the arthroscope and the suture was grasped from the inferior aspect of the tendon in the arthroscope, while another end of the suture was pulled outside the arthroscope to construct a loop hitching around the LHBT. A SutureLasso SD 90° (Arthrex, Naples, FL), the suture shuttle device, was pierced through the midportion of the LHBT just distal to the loop through the anterior portal to advance a 0# PDS II (polydioxanone suture) (Ethicon Inc; Johnson & Johnson, Somerville, NJ) as a guiding suture. Subsequently, the SutureLasso was retrieved, and the end of the PDS suture in the capsule was grasped out through the posterior portal. A tight overhand knot was tied on the two ends of the FiberWire suture with the PDS suture. Finally, the PDS suture was pulled out from the posterior portal, helping the two suture ends shuttle the tendon. Then, a novel, self-

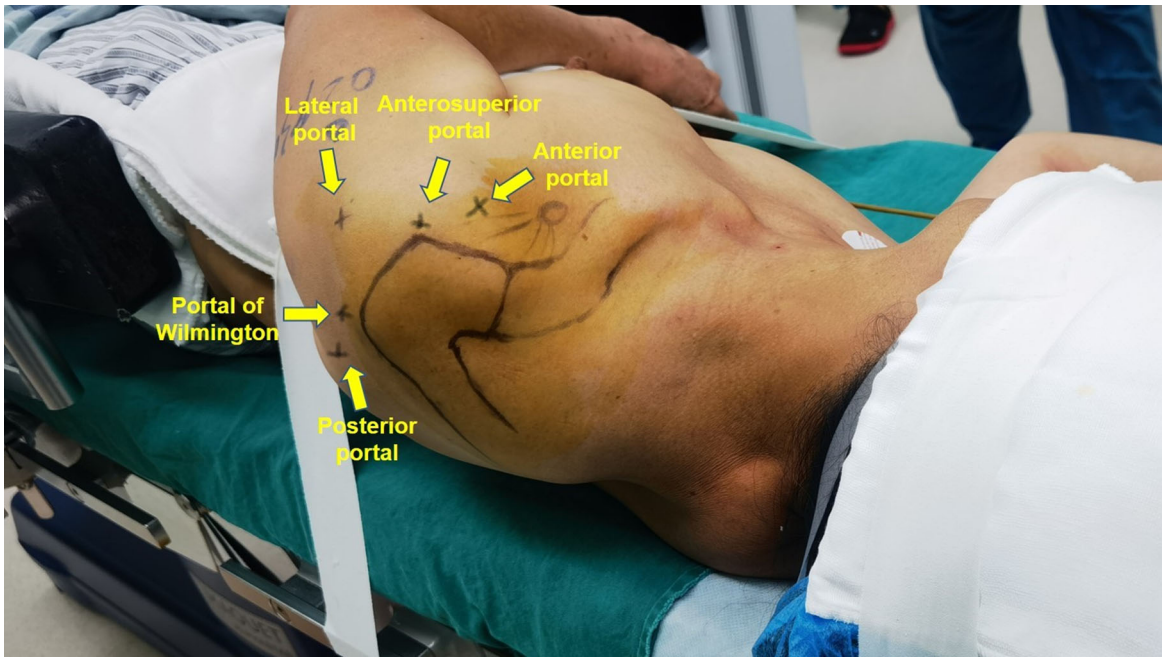

FIGURE 1
The standard anterior portal, lateral portal, posterior portal, anterosuperior portal and, portal of Wilmington had been marked.

locking, high-resistant loop configuration was constructed after removing the PDS suture (Figures 2A–E).

Long head biceps tenodesis

A punch forcep was inserted into the articular cavity through the anterior portal to detach the LHBT at the insertion site on the superior labral junction. The arthroscope was subsequently shifted to the subacromial space. The transverse ligament was completely cut and the LHBT was thoroughly exposed in the bicipital groove with radiofrequency ablation through the anterolateral portal. The tendon was provoked with the probe to further expose the bicipital groove and thorough debridement was performed with an arthroscopic burr to refresh the intended anchor site. A pilot hole was drilled *via* the bicipital groove approach to the capsule border perpendicularly with a punch for the 4.75 mm SwiveLock C Anchor (Arthrex, Naples, FL). Two free ends of the suture were loaded into the eyelet of the anchor. Finally, the anchor was placed into the pilot hole, and the tail sutures under the anchor were cut off (Figure 2F).

Rehabilitation

The arm was placed in 30° abduction with an abduction brace for 6 weeks after operation. At this stage, patients were allowed to perform gentle pendulum exercises and elbow/wrist range of motion exercises under the conduct of a physical therapist. After 6 weeks, active exercises of the shoulder and biceps were initiated. 12 weeks after the operation, biceps strengthening programs were started.

Clinical outcomes measure

The clinical results of preoperative and postoperative final follow-up were evaluated by the following scales: ASES, VAS, Constant–Murley, SST, and UCLA score. And the cramps, "Popeye" deformity, tenderness of the bicipital groove, pain during the performance of the Speed test were also evaluated. In the final follow-up, the satisfaction of this technique had been evaluated.

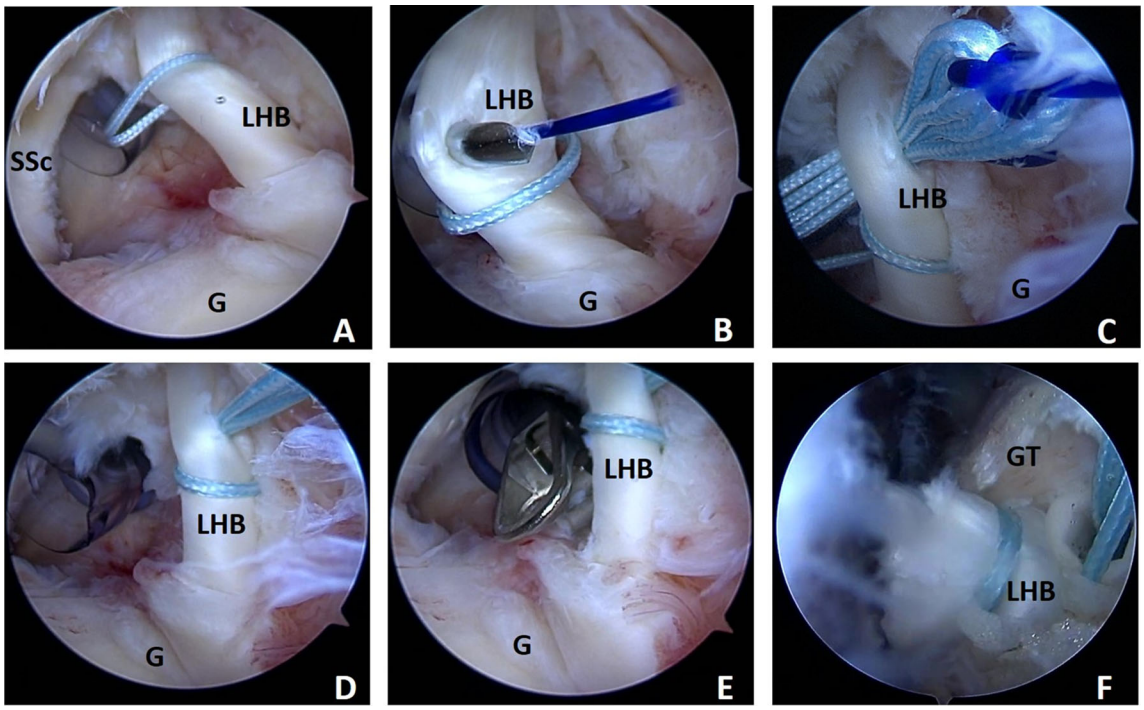

FIGURE 2
Demonstration of the high resistance loop (H-Loop) stich technique arthroscopic surgical in shoulder as viewed from the posterior portal with the patient in the lateral decubitus position using a 30° scope. (**A**) a 2# Fiber Wire suture (Arthrex, Naples, FL) was folded in half and inserted into glenohumeral joint and construct a loop hitching around the LHBT; (**B**) A Suture Lasso is pierced through the midportion of the LHBT just distal of the loop to advance a 0# PDS II Suture, as a guiding suture. (**C**) The two ends of Fiberwire suture were brought into midportion of the LHBT just distal of the loop with PDS suture; (**D**) A novel, self-locking, high-resistant rip-stop loop configuration was constructed; (**E**) The origin of LHBT was detached with a curved arthroscopic scissor. (**F**) The two free ends of the suture were pressed into the guide hole with a push lock anchor suture (Arthrex, Naples, FL) at the intertubercular groove.

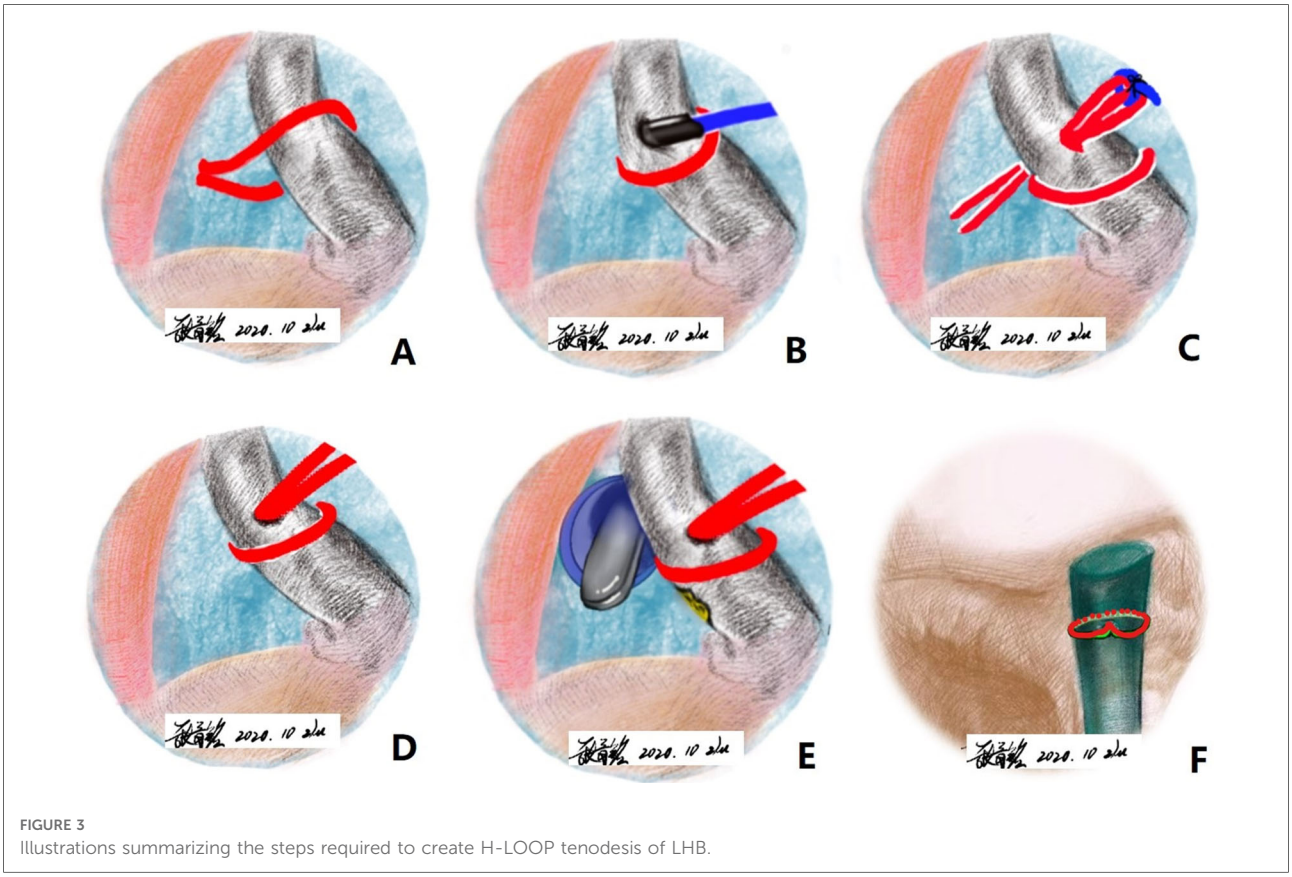

FIGURE 3
Illustrations summarizing the steps required to create H-LOOP tenodesis of LHB.

Statistical analysis

SPSS 20.0 (IBM, Armonk, USA) was used for statistical analysis. The ASES, VAS, Constant–Murley, SST, and UCLA scores between preoperative and final follow-up were compared with Wilcoxon signed-rank test for non-parametric data sets, where a P value of <0.05 was considered statistically significant. The categorical variables were measured by proportion.

Results

General outcomes

The age of patients ranged from 34 to 68 years, with a mean of 55.7 years. All cases have been followed up recently. The mean follow-up was 17 months (range, 12–20 months). In this cohort of patients, the pathology of LHBT was defined during arthroscopic surgery, and the indications for biceps tenodesis included partial tear of the LHB, symptomatic LHB tendinitis, chronic LHB tendinopathy, type 2 and type 4 SLAP tears, and subluxated or dislocated LHB with associated rotator cuff tear. Of the 32 patients, 30 (93.8%) had at least 1 additional intervention during biceps tenodesis.

Functional outcomes

ASES score

The clinical scores of the ASES showed that the mean preoperative score was 51.5 (SD = 15.8) and the mean score during the final postoperative follow-up was 89.06 (SD = 7.48), with a statistically significant difference ($p < 0.001$).

VAS score

The clinical scores of the VAS scale showed that the mean preoperative pain score was 5.5 (SD = 1.6) and the mean pain score during the final postoperative follow-up was 0.97 (SD = 0.82), with a statistically significant difference ($p < 0.001$).

Constant–murley score

The clinical scores of Constant–Murley showed that the mean preoperative score was 57.8 (SD = 14.7) and the mean pain score during the final postoperative follow-up was 87.3 (SD = 5.5), with a statistically significant difference ($p < 0.001$).

SST score

The clinical scores of the SST showed that the mean preoperative score was 5.0 (SD = 2.8) and the mean pain score

during the final postoperative follow-up was 10.4 (SD = 1.5), with a statistically significant difference ($p < 0.001$).

UCLA score

The clinical scores of the UCLA showed that the mean preoperative score was 16.06 (SD = 3.8) and the mean pain score during the final postoperative follow-up was 31.3 (SD = 2.6), with a statistically significant difference ($p < 0.001$).

The procedure has high patient satisfaction; 62.5% (12/32) of patients classified the clinical outcome as excellent and 37.5% (12/32,) as good (residual gentle tenderness in intertubercular/bicipital groove). At the final follow-up after surgery, all patients returned to their daily lives without limitations.

Complications

During the follow-up, no patients in this study experienced postoperative complications such as infection of the wound, injury of nerves, and hardware failure; no patients required revision after their operation. In addition, none of the patients had cramping or a "Popeye" deformity during the final follow-up after surgery.

Discussion

The present study was designed to introduce the all-inside arthroscopic knotless suprapectoral biceps tenodesis with H-Loop stitch and to access the preliminary outcomes in patients with LHB tenodesis using the H-Loop stitch technique. The principle finding of the present study presented good clinical results and acquired a high rate of patient satisfaction. The functional scores and pain of patients demonstrated significant improvement. No patients in this study experienced nerve damage and re-operation postoperatively. All-inside arthroscopic knotless suprapectoral biceps tenodesis with H-Loop stitch is a treatment option for LHBT disorders.

Optimal tenodesis remains a contentious issue, with current tenodesis hardware options including a wide range of implants such as interference screws, cortical buttons, and suture anchors (22–24). Due to the high biomechanical stability and good clinical outcomes, the interference screw technique has been widely used in LHB tenodesis (18, 37). However, some serious adverse events related to interference screw LHB tenodesis have also been reported successively, including humeral shaft fractures, tendon injuries within bone tunnels, and local reactions for bioabsorbable screws (38, 39). To further investigate the complications of the interference screw bone tunnel tenodesis, relevant biomechanical studies have been recently performed. The results of this study showed similar ultimate failure loads and stiffness of all-suture anchor and interference screw constructs. However, in the torsion test, implant-related fractures occurred in only 29% of the suture anchor tenodesis structures versus 170% of the interference screw tenodesis structures (25). In clinical practice, the interference screw bone tunnel tenodesis technique has been confirmed to have a higher incidence rate of postoperative cosmetic deformities and revision surgery as compared with the all-suture anchor bone surface tenodesis technique (26). Therefore, the suture anchor bone surface tenodesis technique was proposed as a reasonable option to reduce these risks. The current preliminary clinical results may support these findings, because neither humeral shaft fractures nor cosmetic deformities were observed at the final follow-up.

The suture anchor fixation technique for tenodesis is a simple and relatively safe fixation method and is widely accepted by surgeons. Lafosse first described the "Lasso-loop" technique to tenodesis in all-arthroscopic surgery (27). Additionally, other investigators have found "Lasso-loop" LHB tenodesis with suture anchor achieved more stronger and securer than the LHB tenodesis with interference screws (32). However, other biomechanical testing has demonstrated that the "Lasso-loop" technique holds only a portion of the tendon, which results in an unbalanced suture tendon load distribution, and does not avoid failure of tendon fixation due to the cutting effect of sutures on the tendon (33). To address these specific problems, Sebastian et al. introduced the Lasso Loop 360 technique to provide secure fixation and improved biomechanical properties. Compared with the Lasso-loop technology, the maximum failure load, displacement, and stiffness of Lasso Loop 360 have been improved (40). However, this technique did not solve the problem of tendon cutting by suture; meanwhile, the results of this technique were only ideal for experimental conditions and has not been clinically used and confirmed.

All-inside arthroscopic knotless suprapectoral biceps on-lay tenodesis with H-Loop stitch, which is a novel, total-grasp, self-locking, and high resistance stitch technique has obtained satisfactory clinical results in this case series. The H-loop stitch technique emphasizes the grasping of the whole biceps longus tendon, and not only demonstrates strong grip organization but also acts as a self-tightening force under stressful conditions (41). In addition, this suture loop opposes each other with the free limb of the suture, which can function as a rip-stop to prevent cutting of the tendon at the suture interface (42). The advantages of this technique are simple operation, excellent visualization, and easy to be taught and repeated under arthroscopy. At the same time, it is a cost-effective technology, because: (1) It is a simple and time-consuming technology, which saves operation time; (2) The two suture limbs can be pressed under the lateral row handling the rotator cuff without additional implants, which

TABLE 1 Technical pearls and pitfalls of H-loop tenodesis of LHB.

• A suitable anterior portal that facilitates access above and below the biceps tendon.
• The anterior portal placement cannot be placed close to the proximal aspect of biceps sulcus.
• Avoid repeatedly using the Lasso to pass through the biceps tendon to prevent injury.
•The suture of H-loops as close to insertion on labrum as possible (to allow hypotonic tenodesis).
•The intertubercular sulcus should thoroughly be debrided during the operation to reduce the occurrence of residual pain.
•The suture of H-loops should be more than 1 cm away from the incisal margin to reduce potential for suture loop pull out.

TABLE 2 Advantages and disadvantages of H-loop tenodesis of LHB.

Advantages	Disadvantages
• This technique has the advantages of simple process flow, all-arthroscopic operation under direct visualization from posterior portal.	• New learning curve for surgeons.
• This technique has an excellent visualization, and easy to be taught and repeated by surgeons.	• If the H-loop suture is placed too close to the incisal margin of the biceps, there is a possibility risk for suture pullout off the proximal biceps intraoperatively or postoperatively.
• This is a knotless and time-efficient technique, which save the operating room time;	• Insufficiency of clinical comparison data.
• This technique does not required extra incision, which may decrease tissue injury and perioperative infection.	

also reduces cost by eliminating the need for additional implants for tenodesis; (3) There is no need for an extra instrument, which can be completed with a simple lasso. In addition, this technique could be completed under arthroscopy, does not require additional separate incisions and may reduce surgical morbidity. A schematic of the steps of H-loop stitch is summarized in Figure 3. Technology-related tips and tricks are detailed in Table 1. Complete advantages and disadvantages are listed in Table 2.

The following limitations of our study must be considered. First, this tenodesis technique has potential limitations similar to those of other all-arthroscopic tenodesis techniques. This is because this technique is simply performed to fix the LHBT at the proximal part of the bicipital groove. Because thorough debridement of the intertubercular groove is not performed during the procedure, it is possible that the remnant of lesional tissue leads to residual anterior shoulder pain[25]. Secondly, the small sample size and short follow-up duration might not be enough to obtain accurate outcomes. Hence, a large sample size and longer follow-up durations are needed to obtain more precise conclusions. Thirdly, the study is short of an appropriate control group, where a randomized design comparing the H-loop tenodesis technique with the conventional tenodesis technique is required. Fourthly, patients underwent rotator cuff repair and LHB tenodesis, which confounded our results. Fifthly, data of biomechanics are lacking, and the mechanical superiority of this technology needs to be further confirmed by biomechanics in the future.

Conclusion

This article presents an innovative, all-arthroscopic H-loop technique for LHB tenodesis. Although the biomechanics of this tendon fixation technique have not been studied, it has shown favorable functional and cosmetic outcomes. Due to its simplicity of operation and satisfactory preliminary clinical outcomes, all-inside arthroscopic knotless suprapectoral biceps tenodesis with H-Loop stitch is another treatment option for LHBT disorders. However, the mechanical superiority of this technology needs to be further confirmed by biomechanics, and long-term clinical outcomes should have to follow to confirm the sustainable success of this promising technique.

Data availability statement

The raw data supporting the conclusions of this article will be made available by the authors, without undue reservation.

Ethics statement

The studies involving human participants were reviewed and approved by Ethics Committee of Sun Yat-sen Memorial Hospital of Sun Yat-sen University. The patients/participants provided their written informed consent to participate in this study.

Written informed consent was obtained from the individual(s) for the publication of any potentially identifiable images or data included in this article.

Author contributions

MZ and CHZ designed the study and contributed to writing of the draft. DDC and YL contributed to data analysis and solved technical problems in software. JG and JMZ participated in data extraction and analysis assistance. ZZZ and KM contributed to data collection. JYH and RY participated in the design of this research and provided guidance and troubleshooting. All authors agree to be

accountable for all aspects of the work. All authors read and approved the final manuscript. All authors contributed to the article and approved the submitted version.

Funding

This work was supported by the National Natural Science Foundation of China (NO. 81972067, 82002342) and the Fundamental Research Funds for the Central Universities, Sun Yat-sen University (NO. 2020004).

Acknowledgments

The authors acknowledge Phei-Er Saw for proofreading this manuscript and polishing the language.

Conflict of interest

The authors declare that the research was conducted in the absence of any commercial or financial relationships that could be construed as a potential conflict of interest.

Publisher's note

All claims expressed in this article are solely those of the authors and do not necessarily represent those of their affiliated organizations, or those of the publisher, the editors and the reviewers. Any product that may be evaluated in this article, or claim that may be made by its manufacturer, is not guaranteed or endorsed by the publisher.

References

1. Mardani-Kivi M, Keyhani S, Ebrahim-Zadeh MH, Hashemi-Motlagh K, Saheb-Ekhtiari K. Rotator cuff tear with concomitant long head of biceps tendon (LHBT) degeneration: what is the preferred choice? Open subpectoral versus arthroscopic intraarticular tenodesis. *J Orthop Traumatol*. (2019) 20 (1):26. doi: 10.1186/s10195-019-0531-5

2. Vajda M, Szakó L, Hegyi P, Erőss B, Görbe A, Molnár Z, et al. Tenodesis yields better functional results than tenotomy in long head of the biceps tendon operations-a systematic review and meta-analysis. *Int Orthop*. (2022) 46 (5):1037–51. doi: 10.1007/s00264-022-05338-9

3. Belay ES, Wittstein JR, Garrigues GE, Lassiter TE, Scribani M, Goldner RD, et al. Biceps tenotomy has earlier pain relief compared to biceps tenodesis: a randomized prospective study. *Knee Surg Sports Traumatol Arthrosc*. (2019) 27 (12):4032–7. doi: 10.1007/s00167-019-05682-1

4. Walch G, Edwards TB, Boulahia A, Nové-Josserand L, Neyton L, Szabo I. Arthroscopic tenotomy of the long head of the biceps in the treatment of rotator cuff tears: clinical and radiographic results of 307 cases. *J Shoulder Elbow Surg*. (2005) 14(3):238–46. doi: 10.1016/j.jse.2004.07.008

5. Boileau P, Baqué F, Valerio L, Ahrens P, Chuinard C, Trojani C. Isolated arthroscopic biceps tenotomy or tenodesis improves symptoms in patients with massive irreparable rotator cuff tears. *J Bone Joint Surg Am*. (2007) 89 (4):747–57. doi: 10.2106/00004623-200704000-00008

6. Hsu AR, Ghodadra NS, Provencher MT, Lewis PB, Bach BR. Biceps tenotomy versus tenodesis: a review of clinical outcomes and biomechanical results. *J Shoulder Elbow Surg*. (2011) 20(2):326–32. doi: 10.1016/j.jse.2010.08.019

7. Rhee SM, Jeong HY, Ro K, Pancholi S, Rhee YG. Double on-lay fixation using all suture-type anchor for subpectoral biceps tenodesis has favorable functional outcomes and leads to less cosmetic deformities than single on-lay fixation. *Knee Surg Sports Traumatol Arthrosc*. (2019) 27(12):4005–13. doi: 10.1007/s00167-019-05663-4

8. Abraham VT, Tan BH, Kumar VP. Systematic review of biceps tenodesis: arthroscopic versus open. *Arthroscopy*. (2016) 32(2):365–71. doi: 10.1016/j.arthro.2015.07.028

9. Vetoshkin AA, Aghamalyan HH, Gurbannazarov MK. Technique of arthroscopic suprapectoral tenodesis of the long head of the biceps with interference screw. *Arthrosc Tech*. (2021) 10(4):e1137–41. doi: 10.1016/j.eats.2021.01.008

10. Gombera MM, Kahlenberg CA, Nair R, Saltzman MD, Terry MA. All-arthroscopic suprapectoral versus open subpectoral tenodesis of the long head of the biceps brachii. *Am J Sports Med*. (2015) 43(5):1077–83. doi: 10.1177/0363546515570024

11. Ma H, Van Heest A, Glisson C, Patel S. Musculocutaneous nerve entrapment: an unusual complication after biceps tenodesis. *Am J Sports Med*. (2009) 37(12):2467–9. doi: 10.1177/0363546509337406

12. Nho SJ, Reiff SN, Verma NN, Slabaugh MA, Mazzocca AD, Romeo AA. Complications associated with subpectoral biceps tenodesis: low rates of incidence following surgery. *J Shoulder Elbow Surg*. (2010) 19(5):764–8. doi: 10.1016/j.jse.2010.01.024

13. Reiff SN, Nho SJ, Romeo AA. Proximal humerus fracture after keyhole biceps tenodesis. *Am J Orthop (Belle Mead NJ)*. (2010) 39(7):E61–3.

14. Sears BW, Spencer EE, Getz CL. Humeral fracture following subpectoral biceps tenodesis in 2 active, healthy patients. *J Shoulder Elbow Surg*. (2011) 20 (6):e7–11. doi: 10.1016/j.jse.2011.02.020

15. Dein EJ, Huri G, Gordon JC, McFarland EG. A humerus fracture in a baseball pitcher after biceps tenodesis. *Am J Sports Med*. (2014) 42(4):877–9. doi: 10.1177/0363546513519218

16. Huddleston HP, Kurtzman JS, Gedailovich S, Koehler SM, Aibinder WR. The rate and reporting of fracture after biceps tenodesis: a systematic review. *J Orthop*. (2021) 28:70–85. doi: 10.1016/j.jor.2021.11.014

17. Abtahi AM, Granger EK, Tashjian RZ. Complications after subpectoral biceps tenodesis using a dual suture anchor technique. *Int J Shoulder Surg*. (2014) 8(2):47–50. doi: 10.4103/0973-6042.137527

18. Provencher MT, McCormick F, Peebles LA, Beaulieu-Jones BR, Dekker TJ, LeClere LE, et al. Outcomes of primary biceps subpectoral tenodesis in an active population: a prospective evaluation of 101 patients. *Arthroscopy*. (2019) 35 (12):3205–10. doi: 10.1016/j.arthro.2019.06.035

19. Oflazoglu K, Menendez ME, Ring D, O'Brien TM, Archibald JD. Axillary artery injury associated with subpectoral biceps tenodesis: a case report. *J Shoulder Elbow Surg*. (2016) 25(1):e25–8. doi: 10.1016/j.jse.2015.09.021

20. Rhee PC, Spinner RJ, Bishop AT, Shin AY. Iatrogenic brachial plexus injuries associated with open subpectoral biceps tenodesis: a report of 4 cases. *Am J Sports Med*. (2013) 41(9):2048–53. doi: 10.1177/0363546513495646

21. Virk MS, Nicholson GP. Complications of proximal biceps tenotomy and tenodesis. *Clin Sports Med*. (2016) 35(1):181–8. doi: 10.1016/j.csm.2015.08.011

22. DeAngelis JP, Chen A, Wexler M, Hertz B, Grimaldi Bournissaint L, Nazarian A, et al. Biomechanical characterization of unicortical button fixation: a novel technique for proximal subpectoral biceps tenodesis. *Knee Surg Sports Traumatol Arthrosc*. (2015) 23(5):1434–41. doi: 10.1007/s00167-013-2775-6

23. Green JM, Getelman MH, Snyder SJ, Burns JP. All-arthroscopic suprapectoral versus open subpectoral tenodesis of the long head of the biceps brachii without the use of interference screws. *Arthroscopy*. (2017) 33(1):19–25. doi: 10.1016/j.arthro.2016.07.007

24. Kennedy NI, Godin JA, Ferrari MB, Sanchez G, Cinque ME, Hussain ZB, et al. Subpectoral biceps tenodesis: interference screw and cortical button fixation. *Arthrosc Tech*. (2017) 6(4):e1415–e20. doi: 10.1016/j.eats.2017.05.028

25. Frank RM, Bernardoni ED, Veera SS, Waterman BR, Griffin JW, Shewman EF, et al. Biomechanical analysis of all-suture suture anchor fixation compared with conventional suture anchors and interference screws for biceps tenodesis. *Arthroscopy*. (2019) 35(6):1760–8. doi: 10.1016/j.arthro.2019.01.026

26. Haidamous G, Noyes MP, Denard PJ. Arthroscopic biceps tenodesis outcomes: a comparison of inlay and onlay techniques. *Am J Sports Med*. (2020) 48(12):3051–6. doi: 10.1177/0363546520952357

27. Lafosse L, Van Raebroeckx A, Brzoska R. A new technique to improve tissue grip: "the lasso-loop stitch". *Arthroscopy*. (2006) 22(11):1246. e1-3. doi: 10.1016/j.arthro.2006.05.021

28. Uschok S, Herrmann S, Pauly S, Perka C, Greiner S. Combined arthroscopic tenodesis of the long head of biceps and rotator cuff repair in antero-superior cuff tears. *Arch Orthop Trauma Surg*. (2016) 136(9):1273–9. doi: 10.1007/s00402-016-2498-5

29. Hufeland M, Kolem C, Ziskoven C, Kircher J, Krauspe R, Patzer T. The influence of suprapectoral arthroscopic biceps tenodesis for isolated biceps lesions on elbow flexion force and clinical outcomes. *Knee Surg Sports Traumatol Arthrosc*. (2017) 25(10):3220–8. doi: 10.1007/s00167-015-3846-7

30. Schrock JB, Kraeutler MJ, Bravman JT. Comparison of clinical failure rates after 2 techniques of subpectoral mini-open biceps tenodesis: sequence and suture passage technique matter. *Orthop J Sports Med*. (2017) 5(9):2325967117729356. doi: 10.1177/2325967117729356

31. Cabarcas BC, Beletsky A, Liu J, Gowd AK, Manderle BJ, Cohn M, et al. Short-term clinical and return-to-work outcomes after arthroscopic suprapectoral onlay biceps tenodesis with a single suture anchor. *Arthrosc Sports Med Rehabil*. (2021) 3(4):e1065–e76. doi: 10.1016/j.asmr.2021.03.012

32. Patzer T, Rundic JM, Bobrowitsch E, Olender GD, Hurschler C, Schofer MD. Biomechanical comparison of arthroscopically performable techniques for suprapectoral biceps tenodesis. *Arthroscopy*. (2011) 27(8):1036–47. doi: 10.1016/j.arthro.2011.03.082

33. Kaback LA, Gowda AL, Paller D, Green A, Blaine T. Long head biceps tenodesis with a knotless cinch suture anchor: a biomechanical analysis. *Arthroscopy*. (2015) 31(5):831–5. doi: 10.1016/j.arthro.2014.11.043

34. Richards RR, An KN, Bigliani LU, Friedman RJ, Gartsman GM, Gristina AG, et al. A standardized method for the assessment of shoulder function. *J Shoulder Elbow Surg*. (1994) 3(6):347–52. doi: 10.1016/S1058-2746(09)80019-0

35. Scheibel M, Schröder RJ, Chen J, Bartsch M. Arthroscopic soft tissue tenodesis versus bony fixation anchor tenodesis of the long head of the biceps tendon. *Am J Sports Med*. (2011) 39(5):1046–52. doi: 10.1177/0363546510390777

36. Constant CR, Murley AH. A clinical method of functional assessment of the shoulder. *Clin Orthop Relat Res*. (1987) 214:160–4. doi: 10.1097/00003086-198701000-00023

37. Griffin JW, Cvetanovich GL, Kim J, Leroux TS, Riboh J, Bach BR, et al. Biceps tenodesis is a viable option for management of proximal biceps injuries in patients less than 25 years of age. *Arthroscopy*. (2019) 35(4):1036–41. doi: 10.1016/j.arthro.2018.10.151

38. Mellano CR, Frank RM, Shin JJ, Jain A, Zuke WA, Mascarenhas R, et al. Subpectoral biceps tenodesis with PEEK interference screw: a biomechanical analysis of humeral fracture risk. *Arthroscopy*. (2018) 34(3):806–13. doi: 10.1016/j.arthro.2017.09.012

39. Koch BS, Burks RT. Failure of biceps tenodesis with interference screw fixation. *Arthroscopy*. (2012) 28(5):735–40. doi: 10.1016/j.arthro.2012.02.019

40. Müller S, Flury R, Zimmermann S, de Wild M, Fogerty S, Lafosse L, et al. The new LassoLoop360° technique for biomechanically superior tissue grip. *Knee Surg Sports Traumatol Arthrosc*. (2019) 27(12):3962–9. doi: 10.1007/s00167-019-05604-1

41. Guo J, Hou J, Yu M, Alike Y, Long Y, Tang Y, et al. The application of H-loop in arthroscopic knotless double-row rotator cuff repairs. *Orthop Surg*. (2021) 13(7):2170–6. doi: 10.1111/os.13107

42. Burkhart SS, Denard PJ, Konicek J, Hanypsiak BT. Biomechanical validation of load-sharing rip-stop fixation for the repair of tissue-deficient rotator cuff tears. *Am J Sports Med*. (2014) 42(2):457–62. doi: 10.1177/0363546513516602

frontiers | Frontiers in Surgery

TYPE Original Research
PUBLISHED 22 September 2022
DOI 10.3389/fsurg.2022.938750

Check for updates

OPEN ACCESS

EDITED BY
Paphon Sa-ngasoongsong,
Mahidol University, Thailand

REVIEWED BY
Fan Tang,
Sichuan University, China
Hong Duan,
Sichuan University, China

*CORRESPONDENCE
Zhenfeng Li
zhenfengli163@163.com
Xinyu Liu
newyuliu@163.com

†These authors have contributed equally to this work and share the first authorship

SPECIALTY SECTION
This article was submitted to Orthopedic Surgery, a section of the journal Frontiers in Surgery

RECEIVED 08 May 2022
ACCEPTED 29 August 2022
PUBLISHED 22 September 2022

CITATION
Ma Z, Yang Q, Liu X and Li Z (2022) Application of allograft and absorbable screws in the reconstruction of a massive bone defect following resection of giant osteochondroma: A retrospective study.
Front. Surg. 9:938750.
doi: 10.3389/fsurg.2022.938750

COPYRIGHT
© 2022 Ma, Yang, Liu and Li. This is an open-access article distributed under the terms of the Creative Commons Attribution License (CC BY). The use, distribution or reproduction in other forums is permitted, provided the original author(s) and the copyright owner(s) are credited and that the original publication in this journal is cited, in accordance with accepted academic practice. No use, distribution or reproduction is permitted which does not comply with these terms.

Application of allograft and absorbable screws in the reconstruction of a massive bone defect following resection of giant osteochondroma: A retrospective study

Zhihao Ma†, Qiang Yang†, Xinyu Liu* and Zhenfeng Li*

Department of Orthopedics, Qilu Hospital of Shandong University, Jinan, China

Background: This study aims to introduce a reconstruction method of applying allografts and absorbable screws to repair large bone defects caused by the resection of giant osteochondroma.

Methods: A retrospective study of a series of patients who underwent the resection of giant osteochondroma reconstructed by allografts and absorbable screws was conducted from February 2020 to September 2021. Their demographic data, location site, area of bone defect, and pertinent operative details were recorded. The reconstruction modality of allografts was elaborated on. In the follow-up, radiographic images were utilized to determine bone union, and the Musculoskeletal Tumor Society score was used to evaluate postoperative limb function.

Results: A total of seven patients were included, including three males and four females with an average age of 16.6 ± 6.5 years. Among them, three cases of tumors occurred in the humerus and four cases occurred in the femur. The average follow-up time was 11.3 ± 3.0 months. The average area of bone defect was 25.9 ± 8.3 cm^2. No complications such as infection, nonunion, and allograft bone fracture were found during the follow-up period. Six months after the operation, the average Musculoskeletal Tumor Society score was 26.4 ± 1.6, with acceptable postoperative function.

Conclusions: The cooperative application of absorbable screw fixation and allografts including mixed cortical bone and cancellous bone, which yielded satisfactory functional outcomes and acceptable postoperative complications, is an effective reconstruction method for a massive bone defect after the resection of giant osteochondroma.

KEYWORDS

osteochondroma, massive bone defect, allograft, absorbable screw, reconstruction

Introduction

Osteochondroma is the most common benign bone tumor. Most osteochondromas are asymptomatic. The main symptoms are mechanical compression, fracture, bursitis, or malignant transformation of adjacent structures (1–4). At present, the main surgical treatment of osteochondroma is tumor resection, which aims to excise the tumor beyond

a safe margin, maintain biomechanical support, and achieve satisfactory postoperative functional outcomes. Complete resection of the exostosis, cartilage cap, and perichondrium from the base of normal bone is the recommended intervention. If the resection region of the tumor is inadequate or residuals of cartilage and perichondrium remain, there is a high risk of recurrence (5–8). A wide surgical margin aims to reduce the risk of tumor recurrence. However, for some large osteochondromas, marginal resection of the tumor without reconstruction will no doubt leave a massive bone defect inevitably. This massive bone defect may lead to unsatisfactory postoperative functional outcomes.

According to the previous studies on the biomechanical analysis of the defect in long bone, if the length of the defect exceeds a certain degree, it will affect the shear strength and antibending load of the remaining shaft after tumor resection (9–11). Therefore, it is necessary to actively carry out reconstruction surgery following the resection of the tumor to restore its biomechanical stability. We proposed a surgical technique of using allograft cortical bone and cancellous bone combined with absorbable screw fixation to reconstruct the huge bone defect after osteochondroma resection. The usage of allografts can provide mechanical support for bone defects. At the same time, cancellous bone was used to fill the gap left after the bone graft, which can increase the bone contact area between the allograft and host bone. The enlarged contact surface is capable of accelerating the process of creeping substitution between the allograft and host bone and can achieve ideal osteoinductivity to shorten the time of bone graft fusion. In addition, absorbable screws were used to ensure a temporary fixation for the brittler texture of allograft. Absorbable screws reduce the use of metal materials, which can save the patients from the pain of removing the internal fixation again in the future. In addition, absorbable screws had the advantage of reducing the opacity effect of metals in radiographs and reducing metal artifacts in computed tomography and magnetic resonance imaging.

The purpose of this study is to evaluate the feasibility of our reconstruction technique for a bone defect.

Materials and methods

Demographics

Based on the hospital data, we searched the medical records of all patients who underwent osteochondroma research from February 2020 to September 2021. The exclusion criteria were that the transverse diameter of osteochondromas did not approach 25% of the width of the bone. A total of seven patients (three males and four females) who received allografts were included in this study. Patients were followed for a minimum of 7 months (mean, 11.3 months; range, 7–14 months). Pertinent operative details such as surgery duration, estimated blood loss, and complications were also recorded (Table 1). This retrospective study was approved by our institutional review committee. All participants agreed with the data and publication of the manuscript.

TABLE 1 Osteochondroma patients' demographics ($n = 7$).

Demographic	Value
Age (years)	16.6 ± 6.5
Sex, male:female	3:4
Location	
Humerus	3
Femur	4
Area of bone defect (cm^2)	25.9 ± 8.3
Surgery duration (min)	173.6 ± 65.2
Intraoperative blood loss (ml)	181.4 ± 66.4
Follow-up time (months)	11.3 ± 3.0
Musculoskeletal Tumor Society score at 6 months after the operation	26.4 ± 1.6

Values are presented as mean ± standard deviation or number.

Surgical technique

After the success of general anesthesia, the patients were laid in a supine position, and the operation area was routinely disinfected and wrapped. The incision was selected according to the tumor's location, the skin, subcutaneous tissue, and deep fascia were cut in turn, the muscle and periosteum were stripped off, the tumor was exposed, and the tumor tissue was separated from the surrounding normal tissue. During the operation, piezosurgery was used to cut the edge of the tumor, dished to remove the tumor, and sent to routine pathological examination. After the allograft cortical bone plate and cancellous bone were properly repaired in accordance with the shape of the bone defect, the allogeneic bone plate and cancellous bone were implanted into the bone cortical defect. Then, three absorbable screws were fixed for the sake of temporary stability. Intraoperative radiographs were reviewed to assess the effect of bone graft. Antibiotics were used once before the operation (Figure 1).

Clinical follow-up

Plain radiography examination was performed every 3 months after the operation to evaluate the implantation and fusion of allogeneic bone, supplemented by the weight-bearing capacity of the target limb and the local clinical symptoms such as tenderness and vertical percussed pain at the surgical site

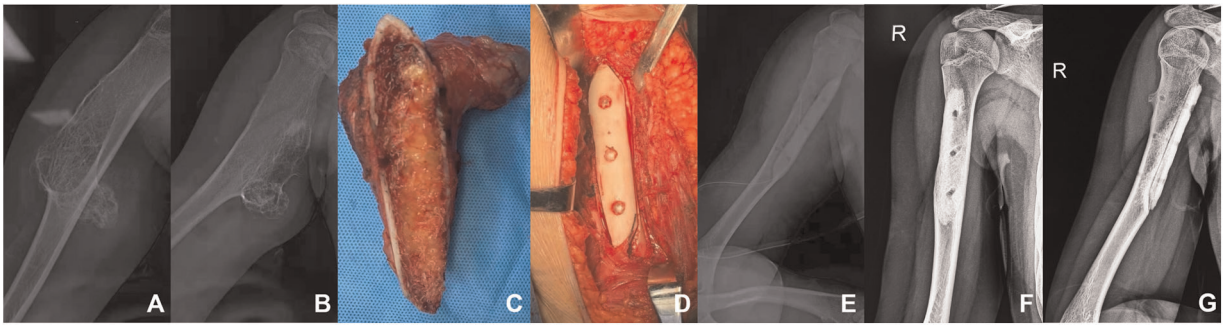

FIGURE 1
A patient with humerus osteochondroma. (**A**,**B**) The preoperative plain radiographs of the patient showed a huge osteochondroma at the proximal end of the right humerus, with a size of 12 cm * 5 cm * 5 cm. (**C**) Osteotomy was performed from the base of the tumor. (**D**) The allograft was implanted in the bone cortical defect and fixed with three absorbable screws. (**E**) Immediate postoperative radiographs. (**E**,**F**) Six months after the operation, the plain radiographs of the right humerus showed that the effect of bone graft fusion was desirable.

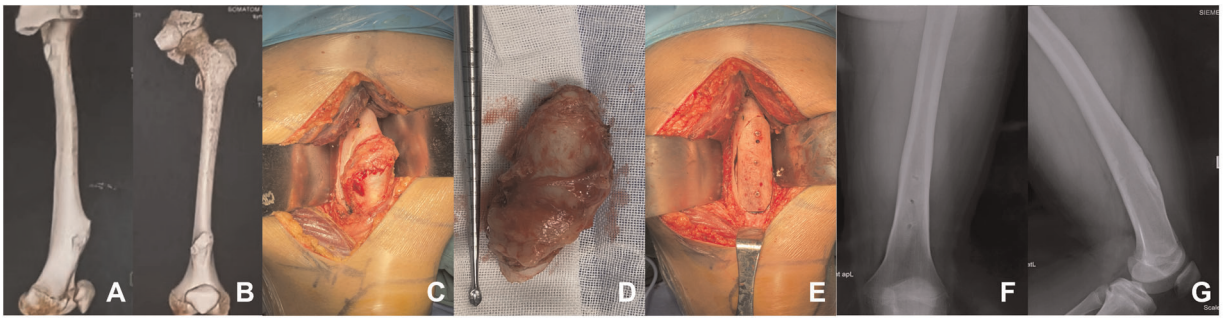

FIGURE 2
A patient with femoral osteochondroma. (**A**,**B**) The preoperative three-dimensional reconstruction of the patient showed a huge osteochondroma at the left femoral. (**C**–**E**) Osteochondroma resection was performed from the base of the tumor. The allograft was implanted in the bone cortical defect and fixed with three absorbable screws. (**F**,**G**) One year after the operation, the radiographs of the left femur showed that the effect of bone graft fusion was satisfactory.

(Figure 2). Patients were assessed by the Musculoskeletal Tumor Society score 6 months after the operation. In the process of follow-up, we attached great importance to the movement of limbs of patients and their postoperative rehabilitation.

Results

The mean age of the patients was 16.6 years, ranging from 13 to 31 years. In this study, three patients had tumors in the humerus and four had tumors in the femur. The mean area of bone defect was 25.9 ± 8.3 cm^2. The average time of surgery was 173.6 ± 65.2 min. The estimated intraoperative blood loss was 181.4 ± 66.4 ml. The average follow-up was 11.3 ± 3.0 months, ranging from a minimum of 7 months to a maximum of 14 months. None of the patients was lost to follow-up, and none of them had complications such as infection, recurrence, allograft fracture, delayed union, and nonunion for the time being. Based on the Musculoskeletal Tumor Society functional evaluation, the mean score 6 months after the operation was 26.4 ± 1.6. Plain radiographs showed signs of bone union three months after the operation, and only a few patients still had tenderness and vertical percussed pain at the surgical site. At the second follow-up, all patients had no restrictions on daily life. However, some strenuous exercises were still limited to patients to prevent fractures at the operative site.

Discussion

At present, the recommended surgical intervention for osteochondroma is marginal resection. However, a large bone defect will be left after complete resection of the giant osteochondroma, although the definition of the size of a massive bone defect has not been well determined (12).

Amanatullah et al. suggested in the biomechanical study of long bone defects that the area of the cortical defect had a negative correlation with the hardness of defective bone (11). Moreover, the average torsional stiffness has a strong linear correlation with the size of the cortical defect, so the remaining bone after resection of the bone defect is of great significance to its stability. These biomechanical analyses predicted a severe loss of torsional integrity when the cortical defect approaches 50% of the width of the femur. Simply resecting the osteochondroma without reconstruction would inevitably leave a large bone defect. The remaining cortical bone cannot obtain sufficient biomechanical support, and fracture may occur. Therefore, it is necessary to actively carry out reconstruction surgery after the resection of osteochondroma to restore the biomechanical stability of defective bone (9–11).

A reconstruction method that applicating allograft and absorbable screws to repair large bone defects caused by the resection of giant osteochondroma is introduced in this study. The transverse diameter of cortical defect, which approached 25% of the width of the bone, or the longitudinal diameter of cortical defect, which exceeded the width of the bone, is more suitable for this method. Allograft is used to obtain the strength and mechanical stability of the reconstructed bone in our surgical procedure. In the process of bone union, the contact area of allograft and host bone needs enough matching and absolute long-term stability to complete the slow process of creeping substitution. Therefore, the allograft needs long-term protection to share the stress beyond its supporting capacity. At the same time, allogenic cancellous bone is applied to fill in the medulla to preserve the bone mass after the defect as much as possible. The application of cancellous bone could fill the gap left after the bone graft so that it can increase the bone contact area between the allograft and the host bone. The enlarged contact surface is capable of accelerating the process of creeping substitution between the allograft and host bone, which could shorten the time of bone graft fusion. The usage of cancellous bone can also induce ideal osteoinduction and osteoconduction to achieve satisfactory bone union. Absorbable screws are used to provide short-term support for allografts before bone fusion.

In our study, three patients had tumors in the humerus and four had tumors in the femur. Due to the femur and tibia being the main weight-bearing bones of the human body, the stress load after reconstruction is greater. Thus, for some patients with larger femoral defects, the allograft is fixed with metal plates and screws to strengthen the mechanical stability of the affected limb. Regarding the enhancement of the stability of allograft and reduction of the risk of fracture, Gupta et al. reported that allograft augmented with intramedullary cement and plate fixation is a reliable solution (13, 14). Being the nonweight-bearing bone, the humerus has a lower bearing requirement than the femur or tibia. Therefore, we added absorbable screws for fixation instead of traditional metallic screws, and the implantation of metal plates was not necessary. Compared with the traditional metal plate and screw fixation, our technique can reduce the use of metal materials, which can save the patients from the pain of removing the internal fixation again in the future. Although the metal plate and screw internal fixation are more stable, the use of absorbable screws can also reach a favorable short-term fixation. In addition, absorbable screws have the advantages of reducing the opacity effect of metals in plain radiographs and metal artifacts in computed tomography and magnetic resonance imaging, so we are able to make an early assessment of the fusion process of cortical cancellous bone and local recurrence (15, 16). Another benefit is that postoperative pain associated with elastic modulus mismatch may be reduced. Compared with metal plates and screws, cortical allogeneic bone scaffolds can better reconstruct the biomechanical elastic modulus of bone. In some published studies, this mismatch was considered to be one of the considerable causes of postoperative pain and eventual implant failure (17–19). The price of absorbable screws is also higher.

Because the texture of allograft is brittler than that of normal bone, it is difficult for other tools to grind it into a suitable shape. As a consequence, piezosurgery was used in the process of operation to cut the interface between host bone and allograft directly into the bevel to increase the contact area of biological bone graft and make it more matched, which could shorten the healing time and enable patients to recover and exercise early. At the same time, we ground the growth axis of the bone defect into an oval in the same direction as the length and diameter of the bone according to precise match orientation to better adapt to the biomechanics of the reconstructed bone.

Although the allograft has been used as a biological bone preservation technique, several studies have reported that there remain several potential problems such as allograft fracture (20–22), infection (20–24, 25), delayed union, and nonunion (5, 25–27). Aponte-Tinao et al. reported 6 infections and 4 fractures in 80 osteoarticular distal femur allografts (20). Aponte-Tinao et al. reported in another study that the incidence of infection of the allograft was 9% (23). Sorger et al. found in their study that 17.7% of structural allografts fractured at a mean of 3.2 years after transplantation (22). A retrospective study reported that 2 of 25 patients had postoperative infection (25). In our case, none of the patients had these complications above for the time being. Although it is generally believed that the incidence of allografts is high, we found that the incidence of postoperative infection, fracture, and delayed bone union is low in our study. One possible reason is that our technique can shorten the operation time, reduce intraoperative bleeding, and reduce the incidence of short-term and long-term postoperative complications. Another reason may be that our sample size is so small that the accuracy of the results may be compromised. As a result,

patients were able to carry out simple rehabilitation training early. The passive functional exercise was necessary and could be carried out as soon as possible after the operation, which can prevent muscle atrophy and anchylosis. However, the active movement of the affected limb should be restricted in the short term to avoid fractures caused by excessive load or rotational violence.

There are several limitations, although our method of operation was very effective. First, our study was a retrospective study, which lacked a direct comparison with other treatment techniques, especially plate and screw fixation, so further case–control studies are needed to investigate whether we have the advantage. At the same time, we currently had an average follow-up period of 11.3 ± 3.0 months, which was still shorter than that reported in relevant studies. And the population was relatively small as a result of the rarity of the procedure, so late follow-up is needed to evaluate whether there would be new long-term complications. In addition, our research can be combined with the prevalent 3D printing technology so that we can better plan the bone defect and its reconstruction, including the development of personalized guide plates and vascularized stent (28–30). However, there also exist some shortcomings, such as high cost and a long learning cycle. In addition, the long-term outcomes and the remedy after the failure of 3D printing technology have not been certified clearly (31).

Conclusions

In the reconstruction of the massive bone defect after the operation of osteochondroma of a long bone, the use of allografts combined with absorbable screw fixation is an effective method of reconstruction, which achieves favorable surgical outcomes. It is safe in terms of the risk of infection and allograft fracture. Considering that it can reduce the use of metal plates and screws, it also has some advantages in reducing the metal artifacts of computed tomography or magnetic resonance imaging. In addition, because the stiffness of the allograft is closer to the bone than metal, the limb pain associated with the difference in elastic modulus mismatch can be reduced in the meantime.

Data availability statement

The raw data supporting the conclusions of this article will be made available by the authors, without undue reservation.

Author contributions

ZM and QY contributed equally to the main manuscript text and prepared figures. All authors contributed to the article and approved the submitted version.

Conflict of interest

The authors declare that the research was conducted in the absence of any commercial or financial relationships that could be construed as a potential conflict of interest.

Publisher's note

All claims expressed in this article are solely those of the authors and do not necessarily represent those of their affiliated organizations, or those of the publisher, the editors and the reviewers. Any product that may be evaluated in this article, or claim that may be made by its manufacturer, is not guaranteed or endorsed by the publisher.

References

1. Tepelenis K, Papathanakos G, Kitsouli A, Troupis T, Barbouti A, Vlachos K, et al. Osteochondromas: an updated review of epidemiology, pathogenesis, clinical presentation, radiological features and treatment options. *In Vivo*. (2021) 35 (2):681–91. doi: 10.21873/invivo.12308

2. Kitsoulis P, Galani V, Stefanaki K, Paraskevas G, Karatzias G, Agnantis NJ, et al. Osteochondromas: review of the clinical, radiological and pathological features. *In Vivo*. (2008) 22(5):633–46.

3. Garcia RA, Inwards CY, Unni KK. Benign bone tumors—recent developments. *Semin Diagn Pathol*. (2011) 28(1):73–85. doi: 10.1053/j.semdp.2011.02.013

4. Khare GN. An analysis of indications for surgical excision and complications in 116 consecutive cases of osteochondroma. *Musculoskelet Surg*. (2011) 95 (2):121–5. doi: 10.1007/s12306-011-0143-6

5. Karasick D, Schweitzer ME, Eschelman DJ. Symptomatic osteochondromas: imaging features. *AJR Am J Roentgenol*. (1997) 168(6):1507–12. doi: 10.2214/ajr.168.6.9168715

6. Xing SG, Mao T. Surgical excision of enchondromas and osteochondromas in the hand under local anaesthesia without tourniquet. *J Hand Surg Eur*. (2019) 44 (7):745–7. doi: 10.1177/1753193419845254

7. Donati D, El Ghoneimy A, Bertoni F, Di Bella C, Mercuri M. Surgical treatment and outcome of conventional pelvic chondrosarcoma. *J Bone Joint Surg Br*. (2005) 87(11):1527–30. doi: 10.1302/0301-620X.87B11.16621

8. Lotfinia I, Vahedi P, Tubbs RS, Ghavame M, Meshkini A. Neurological manifestations, imaging characteristics, and surgical outcome of intraspinal osteochondroma. *J Neurosurg Spine*. (2010) 12(5):474–89. doi: 10.3171/2009.11.SPINE0980

9. Edgerton BC, An KN, Morrey BF. Torsional strength reduction due to cortical defects in bone. *J Orthop Res*. (1990) 8(6):851–5. doi: 10.1002/jor.1100080610

10. Elias JJ, Frassica FJ, Chao EY. The open section effect in a long bone with a longitudinal defect—a theoretical modeling study. *J Biomech*. (2000) 33 (11):1517–22. doi: 10.1016/S0021-9290(00)00107-X

11. Amanatullah DF, Williams JC, Fyhrie DP, Tamurian RM. Torsional properties of distal femoral cortical defects. *Orthopedics*. (2014) 37(3):158–62. doi: 10.3928/01477447-20140225-51

12. Schemitsch EH. Size matters: defining critical in bone defect size. *J Orthop Trauma*. (2017) 31(Suppl 5):S20–2. doi: 10.1097/BOT.0000000000000978

13. Gupta S, Kafchinski LA, Gundle KR, Saidi K, Griffin AM, Wunder JS, et al. Intercalary allograft augmented with intramedullary cement and plate fixation is a reliable solution after resection of a diaphyseal tumour. *Bone Joint J*. (2017) 99-B (7):973–8. doi: 10.1302/0301-620X.99B7.BJJ-2016-0996

14. Jamshidi K, Najd-Mazhar F, Abolghasemzadeh AF, Mirzaei A. The effect of cement augmentation and anteromedial plating on proximal humerus allograft reconstruction. *J Orthop Sci*. (2017) 22(1):69–74. doi: 10.1016/j.jos.2016.09.002

15. Barrett JF, Keat N. Artifacts in CT: recognition and avoidance. *Radiographics*. (2004) 24(6):1679–91. doi: 10.1148/rg.246045065

16. Khor R, Buchan K, Kuganesan A, Ardley N, Lau KK. Orthopaedic and non-orthopaedic applications of a single-energy iterative metal artefact reduction technique and other metal artefact reduction techniques explained. *Br J Radiol*. (2016) 89(1064):20160171. doi: 10.1259/bjr.20160171

17. Ortiz-Cruz E, Gebhardt MC, Jennings LC, Springfield DS, Mankin HJ. The results of transplantation of intercalary allografts after resection of tumors. A long-term follow-up study. *J Bone Joint Surg Am*. (1997) 79(1):97–106. doi: 10.2106/00004623-199701000-00010

18. Mankin HJ, Hornicek FJ. Treatment of giant cell tumors with allograft transplants: a 30-year study. *Clin Orthop Relat Res*. (2005) 439:144–50. doi: 10.1097/01.blo.0000174684.85250.b5

19. Guo S, Meng Q, Zhao X, Wei Q, Xu H. Design and fabrication of a metastable β-type titanium alloy with ultralow elastic modulus and high strength. *Sci Rep*. (2015) 5:14688. doi: 10.1038/srep14688

20. Aponte-Tinao LA, Ritacco LE, Albergo JI, Ayerza MA, Muscolo DL, Farfalli GL. The principles and applications of fresh frozen allografts to bone and joint reconstruction. *Orthop Clin North Am*. (2014) 45(2):257–69. doi: 10.1016/j.ocl.2013.12.008

21. Getty PJ, Peabody TD. Complications and functional outcomes of reconstruction with an osteoarticular allograft after intra-articular resection of the proximal aspect of the humerus. *J Bone Joint Surg Am*. (1999) 81 (8):1138–46. doi: 10.2106/00004623-199908000-00009

22. Sorger JI, Hornicek FJ, Zavatta M, Menzner JP, Gebhardt MC, Tomford WW, et al. Allograft fractures revisited. *Clin Orthop Relat Res*. (2001) 382:66–74. doi: 10.1097/00003086-200101000-00011

23. Aponte-Tinao LA, Ayerza MA, Muscolo DL, Farfalli GL. What are the risk factors and management options for infection after reconstruction with massive bone allografts? *Clin Orthop Relat Res*. (2016) 474(3):669–73. doi: 10.1007/s11999-015-4353-3

24. Tomford WW, Thongphasuk J, Mankin HJ, Ferraro MJ. Frozen musculoskeletal allografts. A study of the clinical incidence and causes of infection associated with their use. *J Bone Joint Surg Am*. (1990) 72(8):1137–43. doi: 10.2106/00004623-199072080-00003

25. Wang Z, Guo Z, Li J, Li XD, Sang HX. Functional outcomes and complications of reconstruction of the proximal humerus after intra-articular tumor resection. *Orthop Surg*. (2010) 2(1):19–26. doi: 10.1111/j.1757-7861.2009.00058.x

26. Hornicek FJ, Zych GA, Hutson JJ, Malinin TI. Salvage of humeral nonunions with onlay bone plate allograft augmentation. *Clin Orthop Relat Res*. (2001) 386:203–9. doi: 10.1097/00003086-200105000-00026

27. Hornicek FJ, Gebhardt MC, Tomford WW, Sorger JI, Zavatta M, Menzner JP, et al. Factors affecting nonunion of the allograft–host junction. *Clin Orthop Relat Res*. (2001) 382:87–98. doi: 10.1097/00003086-200101000-00014

28. Ma H, Feng C, Chang J, Wu C. 3D-printed bioceramic scaffolds: from bone tissue engineering to tumor therapy. *Acta Biomater*. (2018) 79:37–59. doi: 10.1016/j.actbio.2018.08.026

29. Vidal L, Kampleitner C, Brennan MÁ, Hoornaert A, Layrolle P. Reconstruction of large skeletal defects: current clinical therapeutic strategies and future directions using 3D printing. *Front Bioeng Biotechnol*. (2020) 8:61. doi: 10.3389/fbioe.2020.00061

30. Zang CW, Zhang JL, Meng ZZ, Liu LF, Zhang WZ, Chen YX, et al. 3D printing technology in planning thumb reconstructions with second toe transplant. *Orthop Surg*. (2017) 9(2):215–20. doi: 10.1111/os.12326

31. Zhang L, Lu C, Lv Y, Wang X, Guo S, Zhang H. Three-dimensional printing-assisted masquelet technique in the treatment of calcaneal defects. *Orthop Surg*. (2021) 13(3):876–83. doi: 10.1111/os.12873

frontiers | Frontiers in Surgery

TYPE Systematic Review
PUBLISHED 29 September 2022
DOI 10.3389/fsurg.2022.978798

Check for updates

OPEN ACCESS

EDITED BY
Paphon Sa-ngasoongsong,
Mahidol University, Thailand

REVIEWED BY
Junlin Zhou,
Capital Medical University, China
Chenyu Sun,
AMITA Health Saint Joseph Hospital Chicago, United States

*CORRESPONDENCE
Yehai Li
ahyylyh@163.com

SPECIALTY SECTION
This article was submitted to Orthopedic Surgery, a section of the journal Frontiers in Surgery

RECEIVED 26 June 2022
ACCEPTED 14 September 2022
PUBLISHED 29 September 2022

CITATION
Guo J, Peng C, Hu Z and Li Y (2022) Different treatments for 3- or 4-part proximal humeral fractures in the elderly patients: A Bayesian network meta-analysis of randomized controlled trials.
Front. Surg. 9:978798.
doi: 10.3389/fsurg.2022.978798

COPYRIGHT
© 2022 Guo, Peng, Hu and Li. This is an open-access article distributed under the terms of the Creative Commons Attribution License (CC BY). The use, distribution or reproduction in other forums is permitted, provided the original author(s) and the copyright owner(s) are credited and that the original publication in this journal is cited, in accordance with accepted academic practice. No use, distribution or reproduction is permitted which does not comply with these terms.

Different treatments for 3- or 4-part proximal humeral fractures in the elderly patients: A Bayesian network meta-analysis of randomized controlled trials

Jiale Guo, Caiju Peng, Ziyan Hu and Yehai Li*

Department of Orthopedics, Chaohu Hospital of Anhui Medical University, Hefei, China

Background: Proximal humeral fractures are the third most common fracture in the body, and their incidence is rising year by year as the population ages. However, the treatment of the proximal humerus in parts 3 and 4 is still debatable, necessitating a network meta-analysis to determine the best treatment for each treatment modality.
Methods: We searched PubMed, Embase, Cochrane Library for randomized controlled trials on proximal humeral fractures up to June 21, 2022. We performed data extraction and literature quality assessment by two independent authors and extracted constant score and reoperation rate as indicators for evaluation. Stata software, Revman software, JAGS software and the R-based BlandAltmanLeh package, gemtc package and riags package were used to perform this Bayesian network meta-analysis.
Results: Following screening, 11 papers with a total of 648 participants were included in the analysis. The SUCRA values for the constant score were in the following order: RSA, IMN, Conservative, HA, and LP, and the SUCRA values for the reoperation rate were LP, HA, IMN, Conservative, and RSA.
Conclusion: The elderly with 3- or 4-part proximal humeral fractures should consider RSA because it received the best evaluation ranking in terms of constant score and reoperation rate.

Systematic Review Registration: https://www.crd.york.ac.uk/prospero/display_record.php?ID=CRD42022341209, identifier: CRD42022341209.

KEYWORDS

proximal humeral fractures, conservative, locking plates, intramedullary nails, hemiarthroplasty, reverse shoulder arthroplasty

Introduction

For the elderly, proximal humerus fracture (PHF) is the third most frequent fracture after hip fracture and distal radius fracture (1). Proximal humerus fractures account for about 5%–6% of all fractures in the body (2), and it is one of the four major osteoporotic fractures in the human body (3, 4) (hip fractures, vertebral compression fracture, distal

radius fracture, and proximal humerus fracture), with its main factors being falls and osteoporosis. Most proximal humeral fractures can be treated conservatively (5), with results comparable to surgical treatment (6), but the treatment of displaced three- or four-segment fractures is currently debatable. Currently, for displaced three- or four-part proximal humerus fractures, the treatment options include: non-surgical conservative treatment (Conservative), internal fixation with locking plates (LP), internal fixation with intramedullary nails (IMN), hemiarthroplasty (HA), and reverse shoulder arthroplasty (RSA). As the population ages, the incidence of proximal humeral fractures is increasing, and an epidemiological study predicts that the incidence of PHF could increase to three times the current rate in the next three decades (7). The increase in the incidence of PHF has been accompanied by changes in the use of various treatment measures. In Australia, the incidence of PHF increased from 26.8 per 100,000 person-years in 2008 to 45.7 per 100,000 person-years in 2017 (8). However, the proportion of PHF treated surgically dropped from 32.5% to 22.8%; open reduction internal fixation (ORIF) use dropped from 76.6% to 72.6%; HA use significantly decreased from 19.3% to 3%; and RSA use significantly increased from 4.1% to 24.5%. Similar trends were observed in the US, where the proportion of PHF treated surgically decreased from 16.2% to 13.9% between 2009 and 2012; ORIF use did not change significantly. Utilization of HA dropped from 52% to 39%, and RSA significantly increased from 11% to 28% (9). Investigating the causes of this shift in treatment trends is essential. At the same time, the standard of living has improved and patients have higher requirements for function after fracture, so it is necessary to choose the treatment modality with the best therapeutic effect by comparing different treatment modalities.

Although a network meta-analysis (10) has previously analyzed the comparative treatment efficacy of four of these five treatment modalities, the number of RCTs that could be included in the meta-analysis and the number of participants in the study have increased substantially from previous years given the recent updates in the data. Based on these we conducted this new network meta-analysis to re-compare the advantages and disadvantages between these treatment measures.

Methods

Study protocol and registration

Because all of the analyses were based on data from previously published studies, there was no need for ethical approval or patient consent. The Preferred Reporting Items for Systematic Reviews (PRISMA) and Meta-Analyses extension statement was used to generate this network meta-analysis (11). The *a priori* protocol for this NMA is available in the International Prospective Register of Systematic Reviews (PROSPERO): CRD42022341209.

Search strategy

We searched PubMed, Embase, Cochrane Library for randomized controlled trials on proximal humeral fractures up to June 21, 2022. We have used the following search strategy in the Pubmed database: ((“Shoulder Fractures"[Mesh]) OR ((((((((((((Fracture, Shoulder[Title/Abstract]) OR (Fractures, Shoulder[Title/Abstract])) OR (Shoulder Fracture[Title/Abstract])) OR (Humeral Fractures, Proximal[Title/Abstract])) OR (Fracture, Proximal Humeral [Title/Abstract])) OR (Fractures, Proximal Humeral[Title/Abstract])) OR (Humeral Fracture, Proximal[Title/Abstract])) OR (Proximal Humeral Fracture[Title/Abstract])) OR (Proximal Humeral Fractures[Title/Abstract])) OR (Greater Tuberosity Fractures[Title/Abstract])) OR (Fracture, Greater Tuberosity[Title/Abstract])) OR (Fractures, Greater Tuberosity [Title/Abstract])) OR (Greater Tuberosity Fracture[Title/Abstract]))) AND (((((clinical[Title/Abstract]) AND (trial [Title/Abstract])) OR (clinical trials as topic[Mesh])) OR (clinical trial[Publication Type])) OR (random allocation [Mesh])).

Study selection

The inclusion criteria: (1) all studies included in this NMA were randomized controlled trials (RCT); (2) participants in the study were on average over 70 years old and had a three- or four-part proximal humerus fracture; (3) two of the five therapy modalities (Conservative, locking plates, intramedullary nails, hemiarthroplasty, reverse total shoulder arthroplasty) are included in RCTs; (4) all contain follow-up results with a 12-month or longer follow-up period; (5) all of the literature featured is in English.

The exclusion criteria: (1) literature in a language other than English; (2) non-randomized controlled study; (3) patients in the study were diagnosed with a partial or two-part proximal humerus fracture; (4) other treatments for proximal humerus fractures.

Data extraction and quality assessment

Data extraction and quality assessment from original articles was performed independently by two authors. For some papers for which we could not obtain the data we needed, we contacted the original authors to obtain the original data for evaluation. When our two independent

writers disagree about how to process the retrieved data, we transfer it to a third author (senior head physician) to make a decision. For comparing the prognosis of treatment modalities, we use the Constant Score and reoperation rates. The extracted items included: (1) author, (2) time of publication; (3) study location; (4) treatment 1; (5) treatment 2; (6) sample size; (7) mean age; (8) sex; (9) fracture typing method; (10) fracture typing; (11) final available sample size; (12) follow-up time. Two independent reviewers utilized the Cochrane Risk of Bias Assessment tool to assess the quality of the included literature (12). The risk assessment is done through Review Manager 5.4 software. For each item was sored as high risk, uncertain risk or low risk. Similarly, for some risk assessment items that we judged to be of uncertain risk from the original article, we contacted the authors of the original article and redetermined them, following the opinion of the third author (senior chief physician) for all controversial judgments.

Statistical analysis

For some of the literature data are missing and the relevant data are not available by contacting the original authors, we replaced and converted the missing data by the following methods: some studies did not report coefficients of variation such as standard deviations (SD), and we replaced them with the maximum standard deviation of the same rating scale used in other studies (13); if only the standard deviation of the baseline, difference is reported, then we calculate the standard deviation of the endpoint data using the correlation algorithm (14); we calculate the standard deviation for those who are only given a range by dividing the range difference by four (15).

For our Bayesian network meta-analysis, we used Stata software (Stata/MP 17.0. Revision 20 Apr 2021), Revman software (Version: 5.4.1), JAGS software, and the R software (Version 4.1.3), BlandAltmanLeh package, gemtc package, and riags package. We performed sampling simulations and calculations based on random effects model using MCMC method, plotted convergent diagnostic results as convergent diagnostic plots, trajectory plots and density plots, derived relative comparison results between various treatment measures, plotted league tables, and further calculated relative ranking and surface under the cumulative ranking curve (SUCRA) values. Means under the random effects model and fixed effects model were calculated and tested for homogeneity in the literature using the BlandAltmanLeh package; if all points are within 95% LoA, this indicates good homogeneity. The node-splitting approach was used to conduct consistency tests, and between direct and indirect comparisons, p-values greater than 0.05 were deemed to be favorable (16). If heterogeneity was found, further heterogeneity was tested, with $I^2 > 50\%$ indicating heterogeneity, and for the overall results, we also looked at the total I^2.pair and I^2.cons, with values closer to 0 indicating no heterogeneity. We also performed sensitivity analyses: one literature was excluded at a time, and the remaining studies were combined for analysis to see if the results of the analysis would change.

Results

Research selection and characteristics of included study

After screening the literature and using our pre-defined search strategy, 11 studies with 648 participants were finally included in the analysis (17–27) (**Figure 1**). Three comparisons between HA and RSA, two each between Conservative and LP and Conservative and HA, and one each between RSA and LP, RSA and Conservative, HA and LP, and LP and IMN are included among the studies featured. There were no statistical differences in sample size, mean age, gender share, or fracture typing between the two groups before wise treatment, and all of the included literature met our pre-set screening criteria, were published after 2011, and all included two of the five treatment modalities for comparison (**Table 1**). The results of the other randomized controlled trials were based on the longest possible follow-up time retrieved, with the exception of one trial (20). We chose

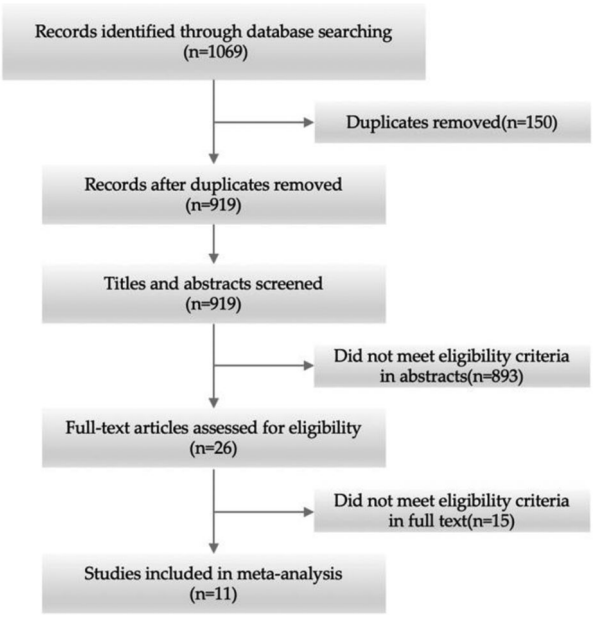

FIGURE 1
Flowchart of the trail selection.

TABLE 1 Characteristics of data extracted from the included studies.

Study	Location	Treatment	Sample size	Mean age (year)	Sex (women, %)	Fracture typing method	Fracture type	Final available	Follow-up (months)
Boons et al., 2012	Netherlands	HA	25	76.4	96	Neer	4-part (100%)	24	12
		Conservative	25	79.9	92			23	
Boyer et al., 2021	France	IMN	49	74.7	70	Neer	3-part (84%) 4-part (16%)	43	66
		LP	50	75.0	68		3-part (69%) 4-part (31%)	42	
Cai et al., 2012	China	HA	19	71.1	86	Neer	4-part (100%)	15	24
		LP	13	72.4	88			12	
Fjalestad et al., 2012	Norway	LP	25	72.2	80	OTA/AO	3-part (52%) 4-part (48%)	23	12
		Conservative	25	73.1	96		3-part (52%) 4-part (48%)	25	
Jonsson et al., 2021	Sweden	RSA	48	80.5	95	Neer	3-part (49%) 4-part (51%)	41	28.8
		HA	51	78.6	86		3-part (56%) 4-part (44%)	43	
Lopiz et al., 2019	Spain	RSA	30	82.0	86	Neer	3-part (13%) 4-part (87%)	29	12
		Conservative	32	85.0	87		3-part (17%) 4-part (83%)	30	
Lass et al., 2020	Dutch	RSA	17	74.8	52	OTA/AO	3- or 4-part	14	12
		HA	14	75.0	64			11	
Olerud-a et al., 2011	Sweden	LP	30	72.9	80	Neer	3-part (100%)	27	24
		Conservative	29	74.9	83			28	
Olerud-b et al., 2011	Sweden	HA	27	75.8	85	Neer	4-part (100%)	24	24
		Conservative	28	77.5	86			25	
Fraser et al., 2020	Norway	RSA	64	75.7	92	OTA/AO	3-part (40%) 4-part (60%)	57	24
		LP	60	74.7	87		3-part (48%) 4-part (52%)	47	
Sebastia et al., 2014	Spain	RSA	31	74.7	87	Neer	3-part (16%) 4-part (84%)	31	28.5
		HA	30	73.3	83		3-part (13%) 4-part (87%)	29	

a 12-month follow-up period for this study because six patients were missed during the 12-to-24-month follow-up period, which we believe influenced the results significantly.

Assessment of risk of bias

The outcome of the risk of bias assessment is shown in the Figure 2. For random sequence generation and allocation concealment, nine of the eleven studies were deemed low risk. Because of the small sample size, one study used "the method of minimization for allocation," and while this method is recommended for clinical trials with small sample sizes and statistically indicates a small difference between the two groups, we ultimately rated it as high risk. The method of generating and assigning secret random number series in the original publication was not determined in another study. Due to the specific nature of surgical treatment, all subjects inevitably know the surgical procedure they underwent, and therefore we judged all trials to be high risk in terms of allocation concealment. Nine studies reported the assessment of outcome indicators by independent investigators on the outcome blinded assessment, two of which (25, 26) were assessed by independent investigators on the outcome indicators at follow-up only at 24 months after surgery, and our extracted data were also at 24 months, so the risk assessment was different this time from the results of a previous meta-analysis, which we evaluated as low risk. All studies were evaluated as low risk in terms of incomplete outcome bias, selective reporting bias, and other bias items.

Statistical analysis

First, we used Stata software to generate a network evidence map (Figure 3). Through R software, we performed sampling

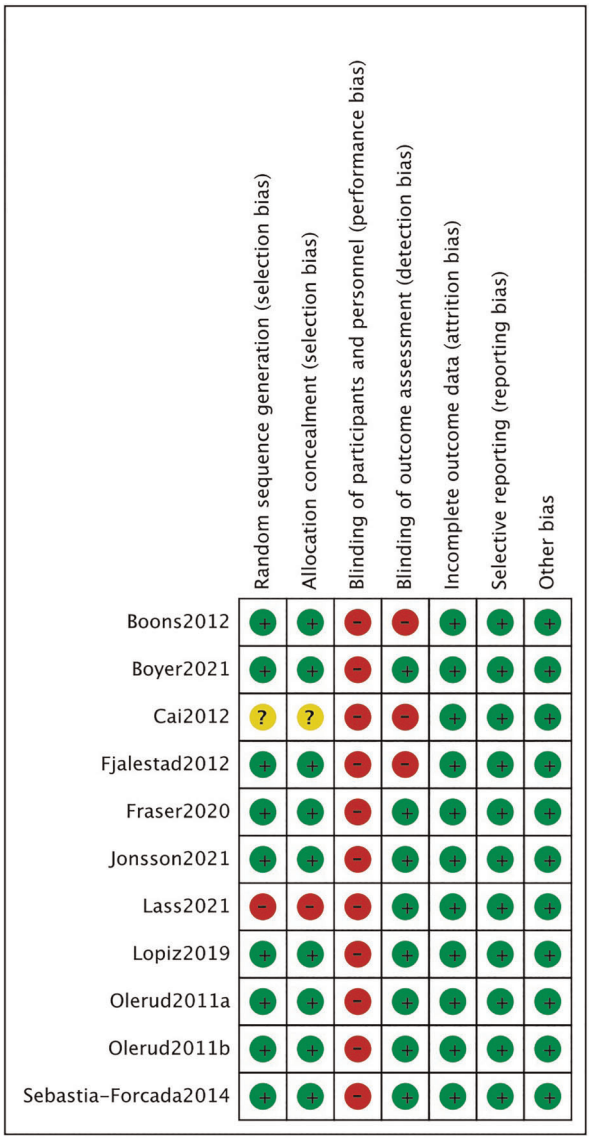

FIGURE 2
Risk of bias summary.

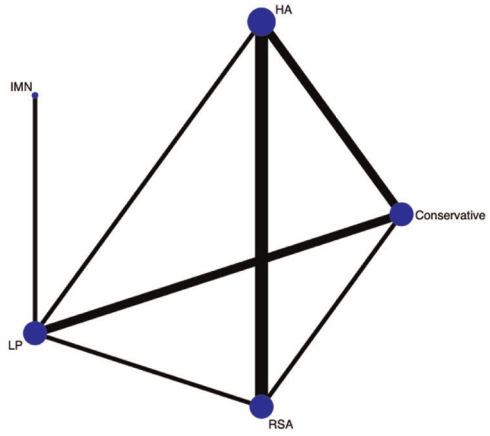

FIGURE 3
Network of the comparisons for the Bayesian network meta-analysis.

simulations and calculations using the MCMC method based on a random effects model that fits well and has heterogeneity equal to 0 (ratio 0.9279, $I^2 = 0\%$). Additionally, we acquired the convergence diagnostic data, and we generated the diagnostic plot (Figure 4), trace, and density plot based on these findings (Figure 5). The potential scale reduction factor (PSRF) is calculated (Table 2), and the model is a satisfactorily converged model in combination with the convergence diagnostic plots and PSRF values. The league table between the various interventions is shown in Table 3. The comparison between various interventions yielded ranking results between species treatment measures, and combining the ranking results (Figure 6) with the SUCRA values (Figure 7), we can obtain: the RSA ranked first (0.9716625), the IMN ranked second (0.6289875), the Conservative ranked third (0.3942625), the HA ranked fourth (0.3222875), LP ranked fifth (0.1828000). We also calculated the reoperation ranking (Figure 8) and SUCRA values (Figure 9): LP (0.8333125), HA (0.8333000), IMN (0.3352875), Conservative (0.2726875), RSA (0.2254125).

We calculated the means under the random effects model and the fixed effects model, and implemented the Bland-Altman method based on the BlandAltmanLeh package of R software to compare the results of the random effects model and the fixed effects model, and the results are shown in the Figure 10, and all points are within 95% LoA, which indicates great homogeneity.

We performed a consistency test using the nodal splitting method, and the results are shown in the forest plot (Figure 11), and the *p*-values for both direct and indirect comparisons of the various treatment measures were greater than 0.05, indicating that the results of direct and indirect comparisons of the interventions were consistent and had good consistency. I In addition, we also performed a heterogeneity check, as shown in the Figure 12, with the exception of heterogeneity between RSA and Conservative ($I^2 > 50\%$). Conservative, which had heterogeneity ($I^2 > 50\%$). The total I^2.pair and I^2.cons are zero, so there is no significant heterogeneity in the present data from the overall results. After sequentially excluding the literature and re-running the meta-analysis, none of the results of the analysis were changed from the previous ones.

Discussion

The best therapy for three- or four-part proximal humerus fractures is still up for debate. The absence of high-quality

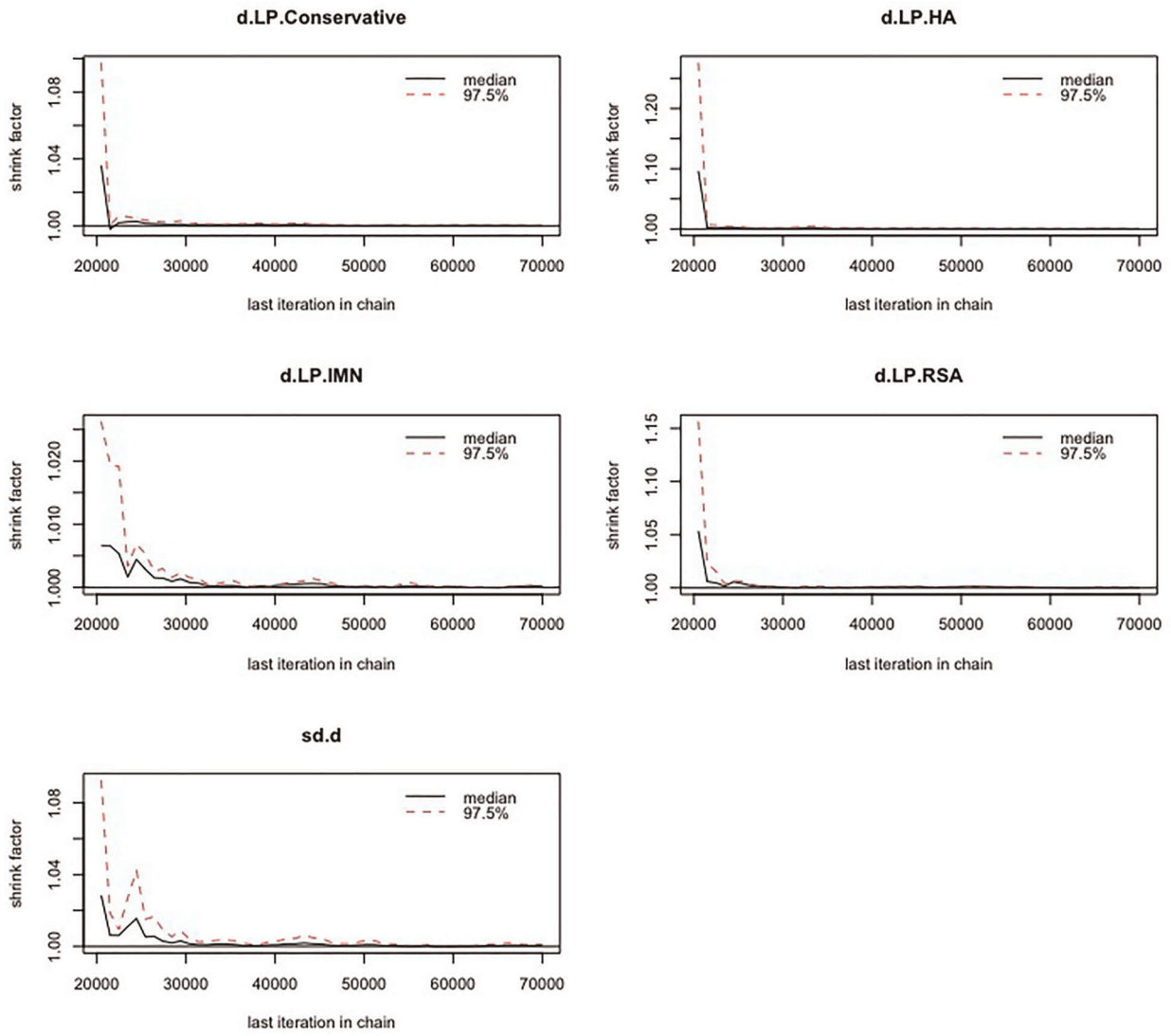

FIGURE 4
Diagnostic plot.

randomized controlled trials with large sample sizes is currently the most pressing problem in selecting the optimal treatment based on evidence. And completing such a trial would need not just multicenter teamwork, lengthy hours, and a significant sum of money, but also a number of practical and ethical concerns (it is difficult to randomize the choice of surgical approach in clinical practice). The existing studies were compiled and analyzed to draw comparative stage conclusions by conducting a meta-analysis of existing randomized controlled trials. On the other hand, by combining the analysis of the shortcomings also provide directions for future research, targeted clinical trials also improve the current predicament to a certain extent.

This is the first Bayesian network meta-analysis of 3 or 4 component fractures of the proximal humerus after Du (10). We redefined the open reduction and internal fixation, and for the first time incorporated IMN in the analysis, unlike Du. The results of our analysis were to some extent identical to the results of Du's net meta-analysis: both rated RSA as having the best clinical effect and LP as having the worst clinical effect. However, unlike previous results, our analysis showed slightly higher ranking results for Conservative than HA on the constant score, while having a low reoperation rate. And our newly added comparator IMN came in second in constant score and third in reoperation rate, but there is only one study on IMN. Studies assessing the effectiveness of IMN in 2- or 3-part proximal humeral fractures have been

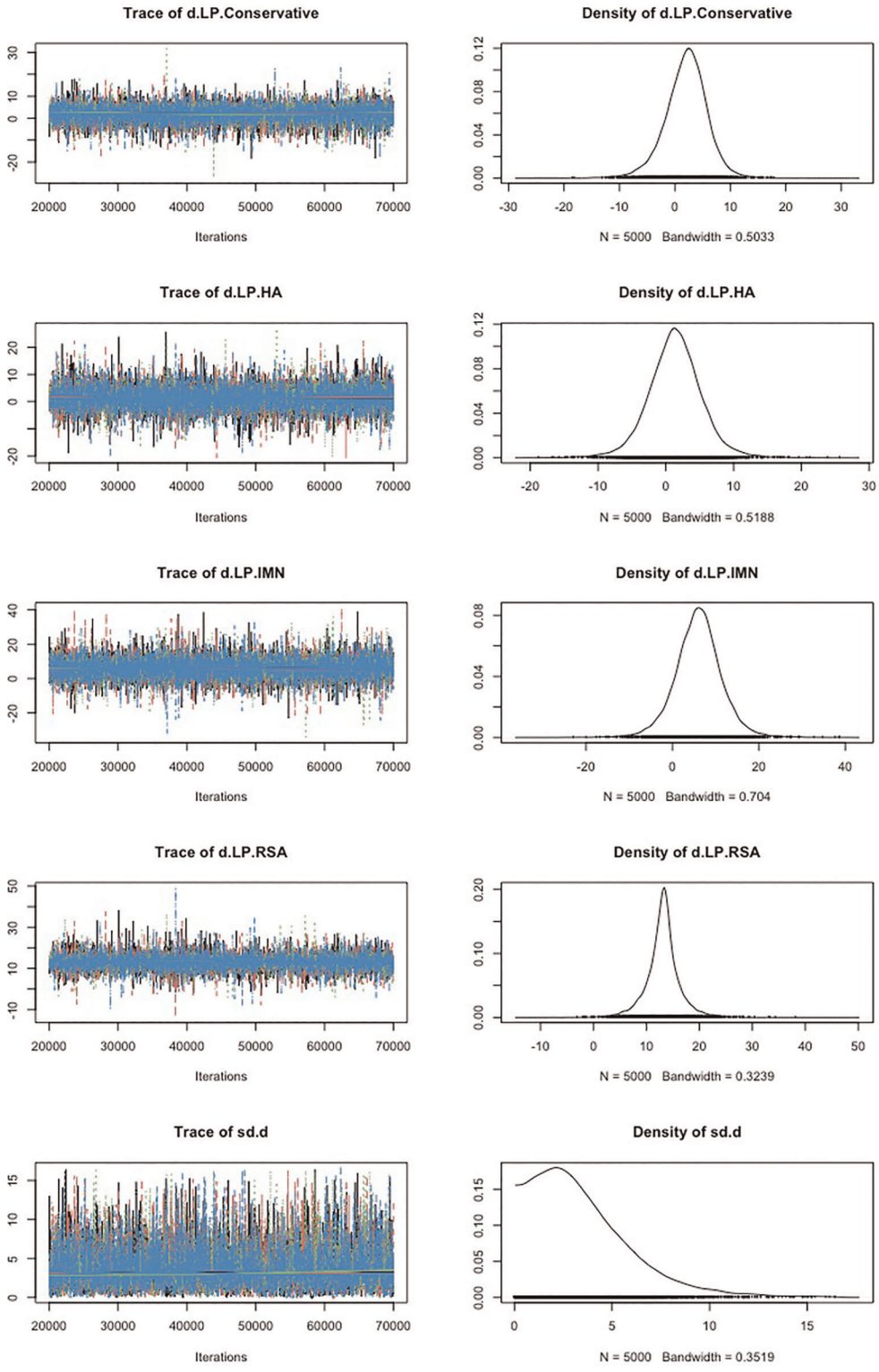

FIGURE 5
Trace, and density plot.

TABLE 2 Potential scale reduction factor (PSRF).

	Point est.	Upper C.I.
d. LP. Conservative	1	1
d. LP. HA	1	1
d. LP. IMN	1	1
d. LP. RSA	1	1
sd. d.	1	1

TABLE 3 The league table between the various interventions.

	Conservative	LP	IMN	HA	RSA
Conservative	Conservative	-2.21 (-9.11, 6.18)	3.90 (-8.95, 18.04)	-0.761 (-7.42, 6.86)	10.98 (4.54, 18.47)
LP	2.21 (-6.18, 9.11)	LP	6.02 (-5.09, 17.05)	1.36 (-6.63, 9.47)	13.19 (6.01, 20.23)
IMN	-3.90 (-18.04, 8.95)	-6.018 (-17.05, 5.09)	IMN	-4.70 (-18.20, 8.92)	7.10 (-6.18, 20.04)
HA	0.76 (-6.86, 7.42)	-1.36 (-9.47, 6.634)	4.70 (-8.92, 18.20)	HA	11.79 (5.50, 18.06)
RSA	-10.98 (-18.47, -4.54)	-13.19 (-20.23, -6.01)	-7.10 (-20.04, 6.18)	-11.79 (-18.06, -5.50)	RSA

conducted. In a randomized controlled trial of IMN and LP for two-part proximal humerus fractures, Zhu (28) found no significant differences in clinical outcomes between the two treatment options and a lower complication rate for IMN at 3-year follow-up; however, Gracitelli's (29) study found that IMN and LP produced similar clinical and radiographic outcomes but had a higher complication and reoperation rate for two- or three-part fractures. More randomized controlled trials are therefore required to confirm the effectiveness and prevalence of unfavorable events with reference to IMN.

We can observe from the league tables that none of the comparisons were statistically significant, with the exception of Conservative and RSA, LP and RSA, and HA and RSA. Combining these results, we cannot conclude that Conservative has a superior clinical outcome than HA, despite the fact that Conservative was somewhat higher in the combined ranking this time.

Retrospective study analysis of German Health Insurance Fund data by Stolberg-Stolberg et al. (30) supported our analysis by demonstrating that, after being tailored to the patient's risk profile, reverse shoulder arthroplasty resulted in statistically significantly lower mortality and fewer major

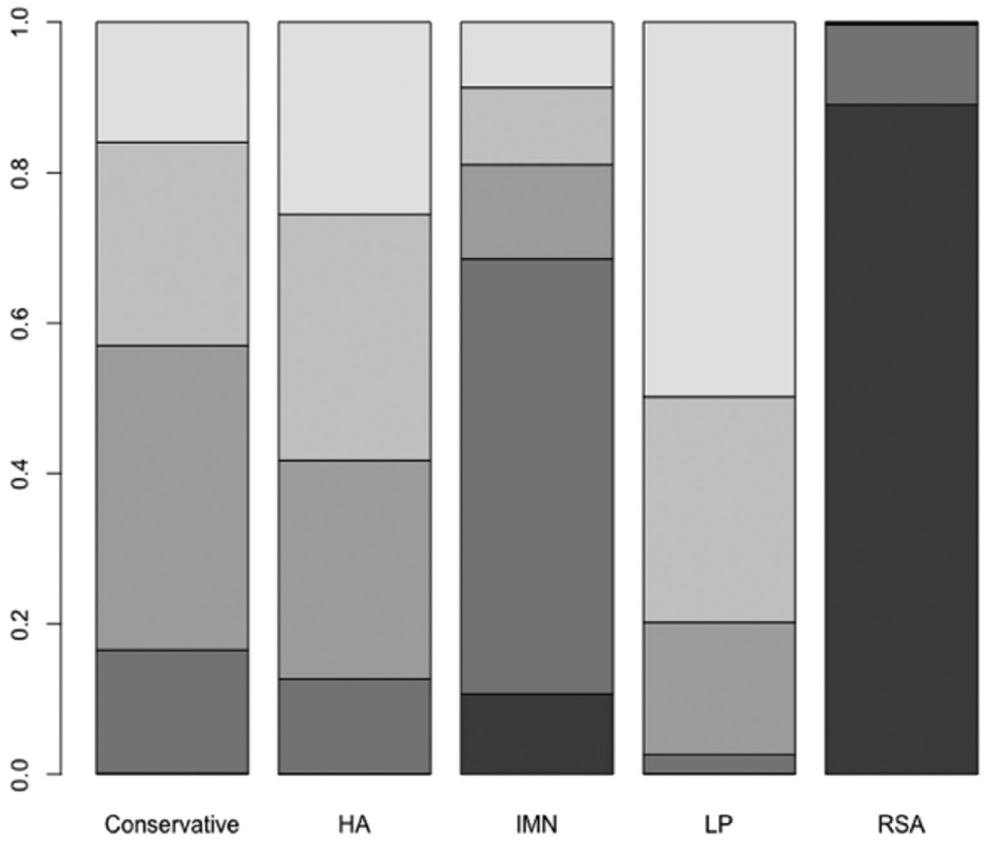

FIGURE 6
Rank probability of constant score.

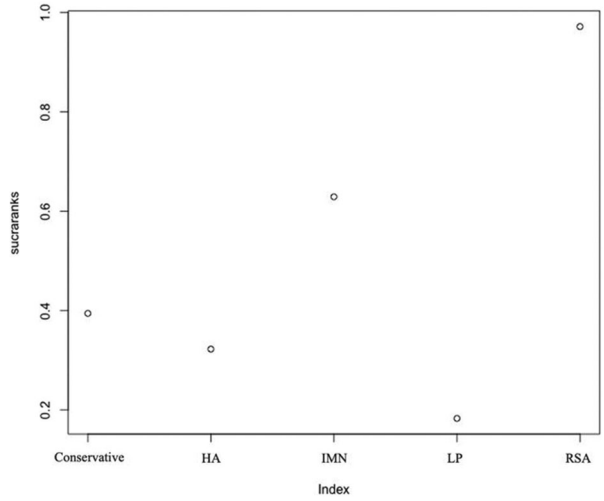

FIGURE 7
SUCRA values of constant score.

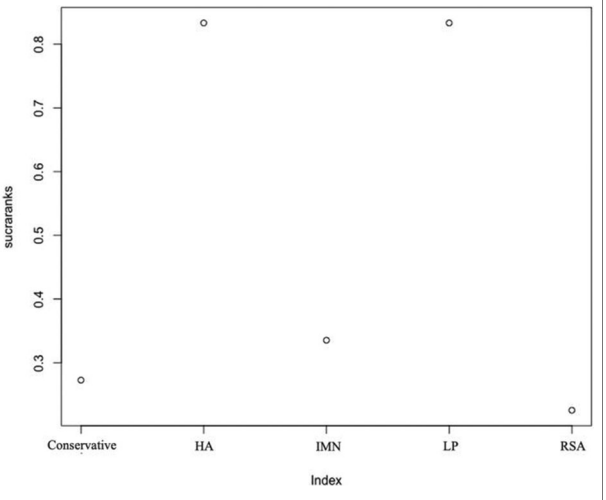

FIGURE 9
SUCRA values of reoperation.

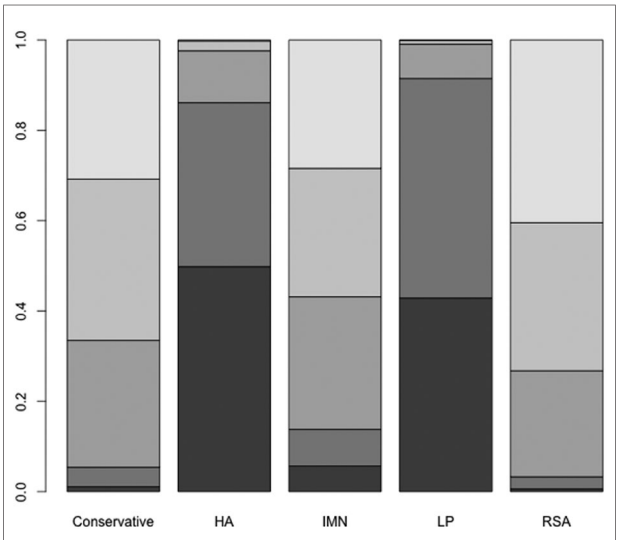

FIGURE 8
Rank probability of reoperation.

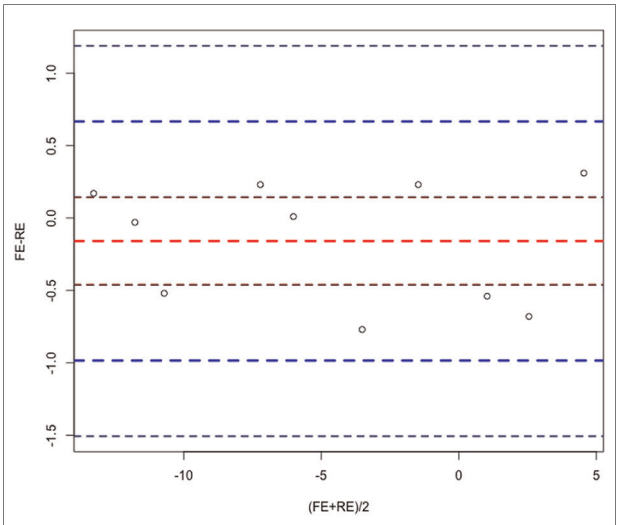

FIGURE 10
Bland–Altman diagram.

adverse events in long-term outcomes. However, the findings of Köppe's (31) study, which also examined this foundation database, were unexpected: there was a rise in in-hospital major adverse events and in-hospital perioperative complications with RSA in comparison to locking plate fixation, even after potential confounding factors like age, gender, and risk status were taken into account. Since few studies have compared in-hospital adverse events among treatment modalities, it is prudent to use RSA for proximal humeral fractures if the risk of in-hospital complications is noticeably higher, even though RSA has significant advantages over LP in terms of reoperation rates and other medium- to long-term evaluation criteria. In this area, more study is required.

To our surprise, our study also produced approximate SUCRA values for the HA and LP reoperation rates, which were different from many earlier findings. We reanalyzed the included literature by excluding each piece one at a time, and after excluding Fraser's (21) literature, we discovered that the reoperation rate SUCRA values for LP were significantly higher than HA. This finding may be related to the fact that, despite being consistently categorized as locking plate internal fixation, the technique

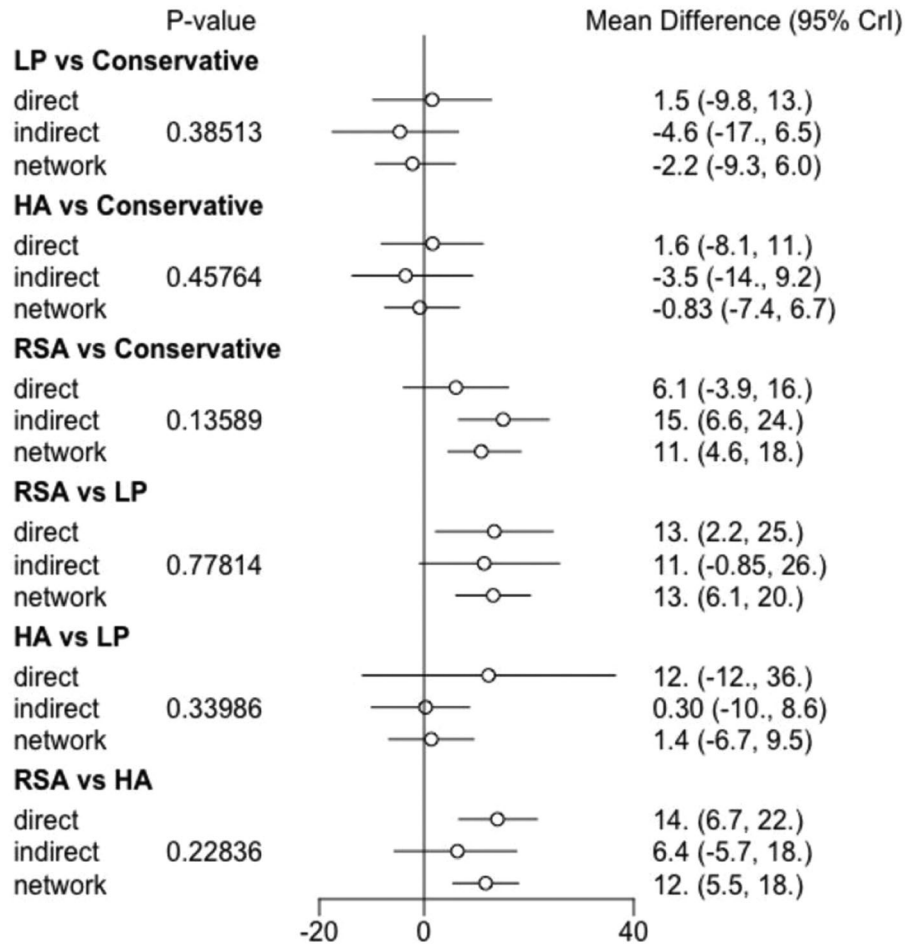

FIGURE 11
Inconsistency plot of this network meta-analysis (constant score).

of the procedure and the plates have been evolving over time (32–34). This implies that the results of earlier human research need to be viewed with greater objectivity because improved surgical procedures and plates may have reduced the incidence of negative events like reoperation rates for LP-treated proximal humeral fractures.

There is another issue that cannot be ignored: cost effectiveness. The ProFHER (PROximal Fracture of the Humerus: Evaluation by Randomisation) trial demonstrated that non-surgical treatment for PHF did not produce better results than surgical treatment in terms of patient outcomes. According to a base case economic analysis for the UK region, the cost of surgical interventions within 2 years was, on average, £1780.73 more expensive per patient than the cost of non-surgical interventions (35). Therefore, non-surgical treatment may be a more suitable treatment option in developing nations or economically underdeveloped regions. RSA has been demonstrated to be the most cost-effective method for treating complex PHF in elderly patients. The incremental cost per quality-adjusted life year (QALY) obtained with RSA relative to HA was C$13,679 (36). The anticipated cost discrepancy for QALY is $16.8 per 100 persons treated, whereas the cost differential for RSA against HA translates to a savings of $99,626 per 100 people treated (37). Additionally, RTSA has a 66% likelihood of being the most cost-effective treatment choice at a willingness-to-pay threshold of C$50,000/QALY (38). The results of the analysis of cost-effectiveness also explain, to some extent, the changes in treatment trends.

This network meta-analysis, however, has a number of drawbacks. (1) Despite the increase in the number of trials and participants included in our meta-analysis compared with the previous one, there were no more than two comparisons between all treatment modalities except between RSA and HA, which limited the significance of our conclusions to some

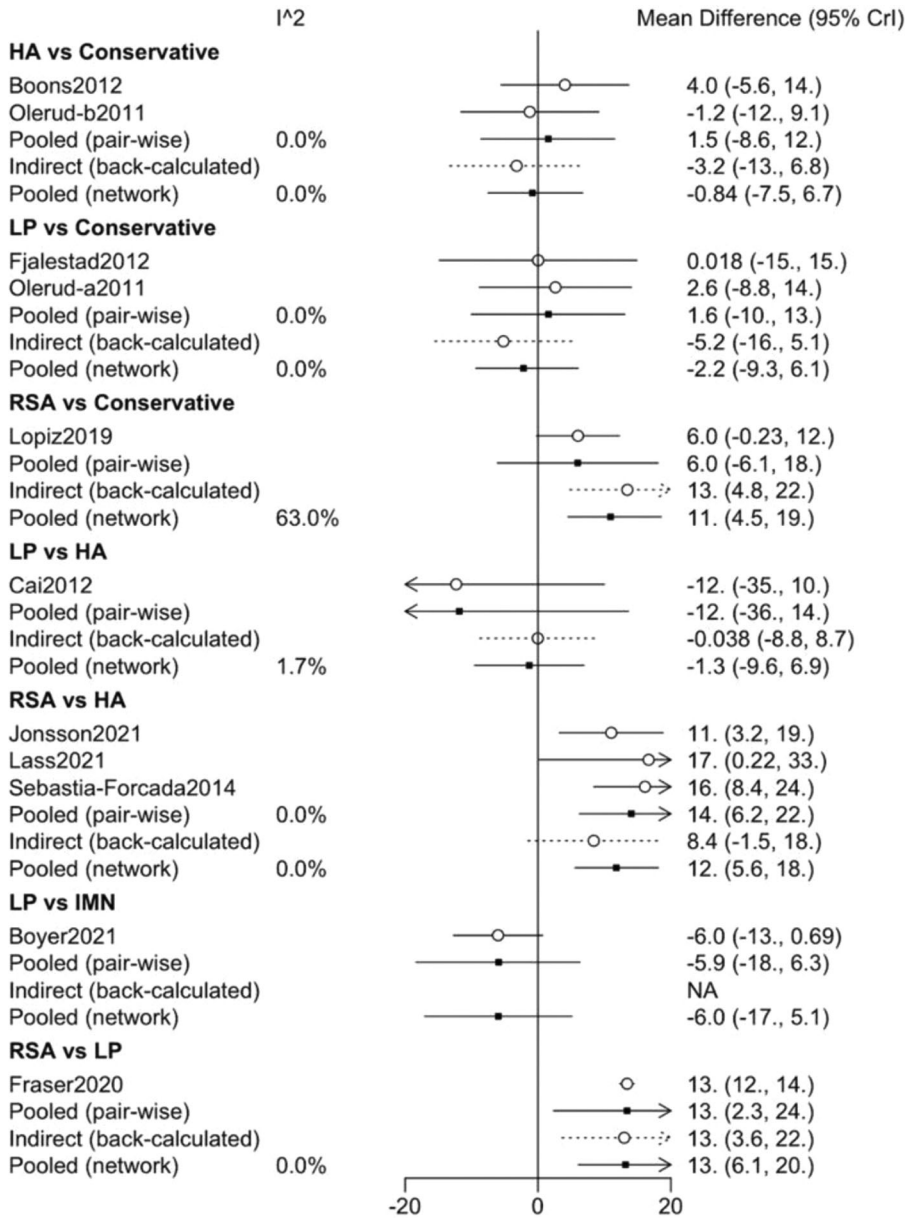

FIGURE 12
Heterogeneity plot of this network meta-analysis (constant score).

extent. (2) The different percentages of three- and four-part fractures in different trials, the reliability of the fracture classification, the technical variability of the surgeons in different studies (32), the subjective variability of constant score scores and the lack of uniform standards for postoperative functional exercise may have influenced the judgment of outcome indicators to some extent. (3) Due to the small number of included trials and the differences in reporting indicators of outcome among different trials, we only selected constant score and reoperation rate as outcome indicators for analysis, which also had some limitations. In contrast to the results of our analysis, Köppe's (31) study showed an increase in major adverse events and surgical complications with RSA compared to locking plate fixation after controlling for potential confounding variables such as age, gender, and risk status. Despite the fact that this is a retrospective study, it does highlight the limits of using reoperation rates to reflect adverse outcomes. (4) The follow-

up duration for eight of the eleven studies that were included was no longer than 2 years. The short follow-up period of the included trials was also a drawback.

Conclusion

In conclusion, from our present meta-analysis, it can be concluded that the best treatment for proximal humeral 3- or 4-part fractures is RSA, there is no statistically significant difference in constant score scores between other treatment measures, but the ranking is IMN, Conservative, HA, LP. the reoperation rate is ranked from highest to lowest LP, HA, IMN, Conservative, RSA.

Data availability statement

The original contributions presented in the study are included in the article/Supplementary Material, further inquiries can be directed to the corresponding author/s.

Author contributions

Conceptualization: JG. Methodology: JG, CP and ZH. Software: JG. Validation: CP and ZH. Formal analysis: JG, CP and ZH. Investigation: JG, CP and ZH. Resources: CP and ZH. Data curation: YL, CP and ZH. Writing—original draft preparation: JG. Writing—review and editing: JG. Visualization: JG and YL. Supervision: YL. Project administration: YL and JG. Review and editing: JG. Manuscript proof-reading: JG. All authors contributed to the article and approved the submitted version.

Conflict of interest

The authors declare that the research was conducted in the absence of any commercial or financial relationships that could be construed as a potential conflict of interest.

Publisher's note

All claims expressed in this article are solely those of the authors and do not necessarily represent those of their affiliated organizations, or those of the publisher, the editors and the reviewers. Any product that may be evaluated in this article, or claim that may be made by its manufacturer, is not guaranteed or endorsed by the publisher.

References

1. Bell JE, Leung BC, Spratt KF, Koval KJ, Weinstein JD, Goodman DC, et al. Trends and variation in incidence, surgical treatment, and repeat surgery of proximal humeral fractures in the elderly. *J Bone Joint Surg Am*. (2011) 93 (2):121–31. doi: 10.2106/jbjs.I.01505

2. Court-Brown CM, Caesar B. Epidemiology of adult fractures: a review. *Injury*. (2006) 37(8):691–7. doi: 10.1016/j.injury.2006.04.130

3. Ratti C, Vulcano E, La Barbera G, Canton G, Murena L, Cherubino P. The incidence of fragility fractures in Italy. *Aging Clin Exp Res*. (2013) 25(Suppl 1): S13–4. doi: 10.1007/s40520-013-0071-4

4. Siggeirsdottir K, Aspelund T, Jonsson BY, Mogensen B, Gudmundsson EF, Gudnason V, et al. Epidemiology of fractures in Iceland and secular trends in major osteoporotic fractures 1989-2008. *Osteoporos Int*. (2014) 25(1):211–9. doi: 10.1007/s00198-013-2422-6

5. Leino OK, Lehtimäki KK, Mäkelä K, Äärimaa V, Ekman E. Proximal humeral fractures in Finland: trends in the incidence and methods of treatment between 1997 and 2019. *Bone Joint J*. (2022) 104-b(1):150–6. doi: 10.1302/0301-620x.104b1.Bjj-2021-0987.R1

6. Rangan A, Handoll H, Brealey S, Jefferson L, Keding A, Martin BC, et al. Surgical vs nonsurgical treatment of adults with displaced fractures of the proximal humerus: the PROFHER randomized clinical trial. *JAMA*. (2015) 313 (10):1037–47. doi: 10.1001/jama.2015.1629

7. Iordens GI, Mahabier KC, Buisman FE, Schep NW, Muradin GS, Beenen LF, et al. The reliability and reproducibility of the hertel classification for comminuted proximal humeral fractures compared with the neer classification. *J Orthop Sci*. (2016) 21(5):596–602. doi: 10.1016/j.jos.2016.05.011

8. McLean AS, Price N, Graves S, Hatton A, Taylor FJ. Nationwide trends in management of proximal humeral fractures: an analysis of 77,966 cases from 2008 to 2017. *J Shoulder Elbow Surg*. (2019) 28(11):2072–8. doi: 10.1016/j.jse.2019.03.034

9. Rosas S, Law TY, Kurowicki J, Formaini N, Kalandiak SP, Levy JC. Trends in surgical management of proximal humeral fractures in the medicare population: a nationwide study of records from 2009 to 2012. *J Shoulder Elbow Surg*. (2016) 25 (4):608–13. doi: 10.1016/j.jse.2015.08.011

10. Du S, Ye J, Chen H, Li X, Lin Q. Interventions for treating 3- or 4-part proximal humeral fractures in elderly patient: a network meta-analysis of randomized controlled trials. *Int J Surg*. (2017) 48:240–6. doi: 10.1016/j.ijsu.2017.09.002

11. Hutton B, Salanti G, Caldwell DM, Anna Chaimani A, Schmid CH, Cameron C, et al. The PRISMA extension statement for reporting of systematic reviews incorporating network meta-analyses of health care interventions: checklist and explanations. *Ann Intern Med*. (2015) 162(11):777–84. doi: 10.7326/m14-2385

12. Higgins JPT, Altman DG, Gotzsche PC, Juni P, Moher D, Oxman AD, et al. The cochrane collaboration's tool for assessing risk of bias in randomised trials. *Br Med J*. (2011) 343:d5928. doi: 10.1136/bmj.d5928

13. Gregori D, Giacovelli G, Minto C, Barbetta B, Gualtieri F, Azzolina D, et al. Association of pharmacological treatments with long-term pain control in patients with knee osteoarthritis: a systematic review and meta-analysis. *JAMA*. (2018) 320 (24):2564–79. doi: 10.1001/jama.2018.19319

14. Dias S, Sutton AJ, Ades AE, Welton NJ. Evidence synthesis for decision making 2: a generalized linear modeling framework for pairwise and network meta-analysis of randomized controlled trials. *Med Decis Making*. (2013) 33 (5):607–17. doi: 10.1177/0272989×12458724

15. Hozo SP, Djulbegovic B, Hozo I. Estimating the mean and variance from the median, range, and the size of a sample. *BMC Med Res Methodol*. (2005) 5:13. doi: 10.1186/1471-2288-5-13

16. Dias S, Welton NJ, Caldwell DM, Ades AE. Checking consistency in mixed treatment comparison meta-analysis. *Stat Med*. (2010) 29(7-8):932–44. doi: 10.1002/sim.3767

17. Boons HW, Goosen JH, van Grinsven S, van Susante JL, van Loon CJ. Hemiarthroplasty for humeral four-part fractures for patients 65 years and

older A randomized controlled trial. *Clin Orthop Relat Res*. (2012) 470 (12):3483–91. doi: 10.1007/s11999-012-2531-0

18. Boyer P, Couffignal C, Bahman M, Mylle G, Rousseau M-A, Dukan R. Displaced three and four part proximal humeral fractures: prospective controlled randomized open-label two-arm study comparing intramedullary nailing and locking plate. *Int Orthop*. (2021) 45(11):2917–26. doi: 10.1007/s00264-021-05217-9

19. Cai M, Tao K, Yang C, Li S. Internal fixation versus shoulder hemiarthroplasty for displaced 4-part proximal humeral fractures in elderly patients. *Orthopedics*. (2012) 35(9):E1340–6. doi: 10.3928/01477447-20120822-19

20. Fjalestad T, Hole MO, Hovden IAH, Blucher J. Surgical treatment with an angular stable plate for complex displaced proximal humeral fractures in elderly patients: a randomized controlled trial. *J Orthop Trauma*. (2012) 26(2):98–106. doi: 10.1097/BOT.0b013e31821c2e15

21. Fraser AN, Bjordal J, Wagle TM, Karlberg AC, Lien OA, Eilertsen L, et al. Reverse shoulder arthroplasty is superior to plate fixation at 2 years for displaced proximal humeral fractures in the elderly: a multicenter randomized controlled trial. *J Bone Jt Surg*. (2020) 102(6):477–85. doi: 10.2106/jbjs.19.01071

22. Jonsson EO, Ekholm C, Salomonsson B, Demir Y, Olerud P, Collaborators SSG. Reverse total shoulder arthroplasty provides better shoulder function than hemiarthroplasty for displaced 3-and 4-part proximal humeral fractures in patients aged 70 years or older: a multicenter randomized controlled trial. *J Shoulder Elbow Surg*. (2021) 30(5):994–1006. doi: 10.1016/j.jse.2020.10.037

23. Laas N, Engelsma Y, Hagemans FJA, Hoelen MA, van Deurzen DFP, Burger BJ. Reverse or hemi shoulder arthroplasty in proximal humerus fractures: a single-blinded prospective multicenter randomized clinical trial. *J Orthop Trauma*. (2021) 35(5):252–8. doi: 10.1097/bot.0000000000001978

24. Lopiz Y, Alcobia-Diaz B, Galan-Olleros M, Garcia-Fernandez C, Lopez Picado A, Marco F. Reverse shoulder arthroplasty versus nonoperative treatment for 3-or 4-part proximal humeral fractures in elderly patients: a prospective randomized controlled trial. *J Shoulder Elbow Surg*. (2019) 28 (12):2259–71. doi: 10.1016/j.jse.2019.06.024

25. Olerud P, Ahrengart L, Ponzer S, Saving J, Tidermark J. Internal fixation versus nonoperative treatment of displaced 3-part proximal humeral fractures in elderly patients: a randomized controlled trial. *J Shoulder Elbow Surg*. (2011) 20 (5):747–55. doi: 10.1016/j.jse.2010.12.018

26. Olerud P, Ahrengart L, Ponzer S, Saving J, Tidermark J. Hemiarthroplasty versus nonoperative treatment of displaced 4-part proximal humeral fractures in elderly patients: a randomized controlled trial. *J Shoulder Elbow Surg*. (2011) 20 (7):1025–33. doi: 10.1016/j.jse.2011.04.016

27. Sebastia-Forcada E, Cebrian-Gomez R, Lizaur-Utrilla A, Gil-Guillen V. Reverse shoulder arthroplasty versus hemiarthroplasty for acute proximal humeral fractures. A blinded, randomized, controlled, prospective study. *J Shoulder Elbow Surg*. (2014) 23(10):1419–26. doi: 10.1016/j.jse.2014.06.035

28. Zhu Y, Lu Y, Shen J, Zhang J, Jiang C. Locking intramedullary nails and locking plates in the treatment of two-part proximal humeral surgical neck fractures: a prospective randomized trial with a minimum of three years of follow-up. *J Bone Joint Surg Am*. (2011) 93(2):159–68. doi: 10.2106/jbjs.J.00155

29. Gracitelli ME, Malavolta EA, Assunção JH, Kojima KE, dos Reis PR, Silva JS, et al. Locking intramedullary nails compared with locking plates for two- and three-part proximal humeral surgical neck fractures: a randomized controlled trial. *J Shoulder Elbow Surg*. (2016) 25(5):695–703. doi: 10.1016/j.jse.2016.02.003

30. Stolberg-Stolberg J, Köppe J, Rischen R, Freistühler M, Faldum A, Katthagen JC, et al. The surgical treatment of proximal humeral fractures in elderly patients. *Dtsch Arztebl Int*. (2021) 118(48):817–23. doi: 10.3238/arztebl.m2021.0326

31. Köppe J, Stolberg-Stolberg J, Rischen R, Faldum A, Raschke MJ, Katthagen JC. In-hospital complications are more likely to occur after reverse shoulder arthroplasty than after locked plating for proximal humeral fractures. *Clin Orthop Relat Res*. (2021) 479(10):2284–92. doi: 10.1097/corr.0000000000001776

32. Helfen T, Siebenbürger G, Fleischhacker E, Biermann N, Böcker W, Ockert B. Open reduction and internal fixation of displaced proximal humeral fractures. Does the surgeon's experience have an impact on outcomes? *PLoS One*. (2018) 13 (11):e0207044. doi: 10.1371/journal.pone.0207044

33. Sun Q, Wu X, Wang L, Cai M. The plate fixation strategy of complex proximal humeral fractures. *Int Orthop*. (2020) 44(9):1785–95. doi: 10.1007/s00264-020-04544-7

34. Chen JL, Chang FC, Lin SJ, Chuang PY, Peng KT, Huang KC, et al. The outcome of surgical management of proximal humeral fractures using locking plates: comparison between locking plates with different geometry. *J Shoulder Elbow Surg*. (2018) 27(12):2159–66. doi: 10.1016/j.jse.2018.05.033

35. Handoll H, Brealey S, Rangan A, Keding A, Corbacho B, Jefferson L, et al. The ProFHER (PROximal fracture of the humerus: evaluation by randomisation) trial - a pragmatic multicentre randomised controlled trial evaluating the clinical effectiveness and cost-effectiveness of surgical compared with non-surgical treatment for proximal fracture of the humerus in adults. *Health Technol Assess*. (2015) 19(24):1–280. doi: 10.3310/hta19240

36. Osterhoff G, O'Hara NN, D'Cruz J, Sprague SA, Bansback N, Evaniew N, et al. A cost-effectiveness analysis of reverse total shoulder arthroplasty versus hemiarthroplasty for the management of complex proximal humeral fractures in the elderly. *Value Health*. (2017) 20(3):404–11. doi: 10.1016/j.jval.2016.10.017

37. Sheibani-Rad S, Kuhn AW, Berrigan PS, Bedi A. Reverse total shoulder arthroplasty versus hemiarthroplasty for the treatment of proximal humerus fractures: a model-based cost-effectiveness analysis. *J Am Acad Orthop Surg*. (2021) 29(24):e1353–61. doi: 10.5435/jaaos-d-21-00166

38. Khalik H A, Humphries B, Zoratti M, Axelrod D, Kruse C, Ristevski B, et al. Reverse total shoulder arthroplasty is the most cost-effective treatment strategy for proximal humerus fractures in older adults: a cost-utility analysis. *Clin Orthop Relat Res*. (2022) 480(10):2019–21. doi: 10.1097/corr.0000000000002219

frontiers | Frontiers in Surgery

TYPE Original Research
PUBLISHED 24 October 2022
DOI 10.3389/fsurg.2022.1038066

Check for updates

OPEN ACCESS

EDITED BY
Toshimi Aizawa,
Tohoku University, Japan

REVIEWED BY
Daisuke Chiba,
Tohoku University, Japan
Kazuyoshi Baba,
Tohoku University, Japan

*CORRESPONDENCE
Patarawan Woratanarat
pataraw@yahoo.com

SPECIALTY SECTION
This article was submitted to Orthopedic Surgery, a section of the journal Frontiers in Surgery

RECEIVED 06 September 2022
ACCEPTED 05 October 2022
PUBLISHED 24 October 2022

CITATION
Angsanuntsukh C, Patathong T, Klaewkasikum K, Jungtheerapanich W, Saisongcroh T, Mulpruek P and Woratanarat P (2022) Factors for selective ultrasound screening in newborns with developmental dysplasia of the hip (DDH). Front. Surg. 9:1038066. doi: 10.3389/fsurg.2022.1038066

COPYRIGHT
© 2022 Angsanuntsukh, Patathong, Klaewkasikum, Jungtheerapanich, Saisongcroh, Mulpruek and Woratanarat. This is an open-access article distributed under the terms of the Creative Commons Attribution License (CC BY). The use, distribution or reproduction in other forums is permitted, provided the original author(s) and the copyright owner(s) are credited and that the original publication in this journal is cited, in accordance with accepted academic practice. No use, distribution or reproduction is permitted which does not comply with these terms.

Factors for selective ultrasound screening in newborns with developmental dysplasia of the hip (DDH)

Chanika Angsanuntsukh[1], Tanyaporn Patathong[1], Krongkaew Klaewkasikum[1], Witoon Jungtheerapanich[2], Tanyawat Saisongcroh[1], Pornchai Mulpruek[1] and Patarawan Woratanarat[1]*

[1]Department of Orthopaedics, Faculty of Medicine Ramathibodi Hospital, Mahidol University, Bangkok, Thailand, [2]Orthopaedic Unit, Weingsra Crown Prince Hospital, Surat Thani, Thailand

Background: Hip ultrasound screening for DDH provides better sensitivity compared to physical examination. Due to a lower prevalence and limited resources, selective hip ultrasound in newborns at risk could be considered a proper screening protocol in Thailand and Asian countries.
Objective: This study was aimed to evaluate risk factors and define criteria for selective screening.
Methods: A case-control study was conducted in 2020. All newborns with hip ultrasound screening were included. Cases were defined as newborns with abnormal hip ultrasounds, while controls were those with normal studies. Inter and intra-rater reliability were evaluated. All factors were analyzed using univariate and multivariate logistic regression. The model performance was tested by Hosmer-Lemeshow goodness of fit. Internal validity was performed by the split data method. Area under the receiver operating characteristic (ROC) curve was estimated.
Results: Ninety-five newborns (29 cases and 66 controls) were included. Eighty percent of cases and 58% of controls were female. The gestational age was 36.6 and 37.7 weeks in case and control, respectively. Female, breech presentation, positive Ortolani test, positive Barlow test, and limited hip abduction were significant factors with odds ratio of 2.82, 5.12, 34.21, 69.64, and 5.48, respectively. The final model included breech presentation, positive Ortolani test, and positive Barlow test. The model cut-off value 15.02 provided sensitivity (93.10%) and specificity were (80.30%). The area under the ROC curve was 0.9308. The split data remained significant internal validity for all factors with p-value < 0.05.
Conclusion: Careful history taking and physical examination are essential to identify the risk factors for DDH. Newborns with breech presentation, positive Ortolani test and positive Barlow test should be screened by hip ultrasound.

KEYWORDS

Barlow test, breech presentation, hip abduction, Ortolani test, risk

Introduction

Developmental dysplasia of the hip (DDH) is a disorder of abnormal development between the head of the femur and acetabulum, which can result in dysplasia, subluxation, and dislocation (1, 2). Clinical examination is used for DDH screening in many countries; however, this method has had low sensitivity of 28.1% and a specificity of 94.5% (3). Ultrasound screening has a sensitivity of 88.5% and specificity of 96.7% (4), which gained acceptance as the most effective method for early diagnosis of DDH (5–8). Therefore, hip ultrasonography is being used as a universal ultrasound in Europe to screen newborns. Whereas, the USA implements selective ultrasound screening for newborns who has risk factors of DDH i.e., breech and family history of DDH (2, 5, 9).

There is a significant variability in incidence within each racial group by geographic location; the incidence of DDH in the Caucasian population was higher than Asian population (10). In Thailand, the incidence per 1,000 live birth of DDH is 0.5 (10), for which, clinical examination was used as the primary technique for DDH screening. DDH screening is based on physical examination by general practitioners. While hip ultrasonography could not be done in all newborns due to resource scarcity, high cost, and increased workload for limited pediatric orthopaedists, it has resulted in delayed diagnosis of DDH. Late presentation of DDH with hip dislocation in walking age is still a problem. Late diagnosis of DDH is associated with a significant risk of poorer outcomes, including increased likelihood of surgery, more invasive surgical procedures, more extended hospital stays, and early osteoarthritis of the hip, as well as increased healthcare costs (11–13). Therefore, an early diagnosis is essential for an early treatment to reduce the possibility of hip osteoarthritis in young adults (14).

This study aimed to find the risk factors of DDH to create a model to selectively screen Thai newborns. This study will benefit by early diagnosis of DDH and treatment, optimization of the ultrasound screening tool, and reduction of unnecessary costs.

Methods

Study design and setting

We conducted a case-control design to examine the association between various risk factors and DDH in newborns and design clinical criteria for ultrasound screening in Thai newborns. Cases were selected from Ramathibodi hospital's database of Orthopaedics department between 2009 and 2020. Controls were selected from Ramathibodi hospital's database of the Department of Pediatrics between 2009 and 2020. Institutional Review Board (IRB) of faculty of Medicine, Ramathibodi Hospital, Mahidol University approved the study with reference number COA. MURA2021/273.

Participant

Case definition, inclusion,and exclusion

A case was defined as a newborn of any gender diagnosed with DDH by ultrasound techniques in any position of the standard Harcke's techniques (15–17) (within 2 weeks after birth) in Ramathibodi Hospital between 2009 and 2020. We set the criteria to include newborns with hip ultrasound screening within 2 weeks after birth because newborn with hip laxity or mild instability could be spontaneously resolved within 2–3 weeks.

Control definition, inclusion and exclusion

A control was defined as a newborn who was born at our institute between 2009 and 2020 with normal hip ultrasound in all positions of the standard Harcke's technique (15–17) within 2 weeks after birth. Controls were matched with cases for age and nationality.

Hip ultrasound and reliability

The definitive diagnosis of DDH or not DDH was made based on hip ultrasound. Morphology, stability, and laxity was assessed. The ultrasonographic interpretation were normal (stable and normal in all aspects), dysplasia (abnormal morphology with acetabular coverage <50%) (18) laxity (hip incongruency in adduction), subluxable (subluxation in Barlow test), dislocatable (dislocation in Barlow test) and dislocated hip. All the newborns with abnormal hip ultrasound were diagnosed as positive cases for DDH. We assessed the reliability of the ultrasound interpreters in 10 consecutive newborns, using convenient sampling. The inter and intra-rater reliability of hip assessment and ultrasound were performed by two experienced pediatric orthopaedics surgeons (trained for hip ultrasound from Nemours/Alfred I. duPont Hospital for Children, Wilmington, Delaware) using the standard Harcke's techniques (15–17).

Data collection

The baseline characteristics and clinical assessments were obtained from hospital databases. We used the DDH risk factors based on the meta-analysis (19) and previous studies (5, 20–23), such as gestational age, gender, breech presentation, family history, firstborn child, associated anomalies, Ortolani test (5), Barlow test (5), limited hip abduction, Galeazzi sign (23). The outcome was the ultrasound result in any position of the standard Harcke's methods (15–17).

Statistical analysis

The difference between the case and control groups were assessed using t-test and chi-square test. Univariate logistic regression was used to evaluate each risk factor independently – and, variables with p-value <0.05 were included in a multivariate logistic regression model. The multivariate analysis used the forward stepwise method to assess the risk factor. The model performance was tested by Hosmer-Lemeshow goodness of fit, and area under the receiver operating characteristic (ROC) curve. Odds ratio (OR) was used to measure the association. Odds ratios of significant risk factors from the final model was enumerated and summed scores. The model classification (high vs. low risk) was set as at the optimal cutoff value based on the best sensitivity and specificity. Internal validity was assessed using the split data method. All analyses were performed using the STATA software package, version 16.0 (Stata Corp, College Station, Texas, USA). A two-sided p-value of less than 0.05 was considered as the threshold for statistical significance.

Results

Ninety-five newborns (29 cases and 66 controls) were included. Eighty percent of cases and 58% of controls were female. The gestational age was 36.6 and 37.7 weeks in case and control, respectively.

Significant risk factors of DDH included breech presentation (p-value = 0.002), positive Ortolani test (p-value < 0.001), positive Barlow test (p-value < 0.001) and limited hip abduction (p-value = 0.022). No difference was observed for gestational age, sex, family history of DDH, firstborn child, associated anomaly, and positive Galeazzi sign (Table 1). Characteristic of cases was in (Table 2). Fifty percent of them had hip subluxation followed by hip dysplasia, laxity and dislocation.

The quality of ultrasonographic assessment: two pediatric orthopedic surgeons independently did the ultrasound in 10 newborns. The agreement of ultrasound results was 96.3%.

Univariate analysis showed a significant difference of DDH between two groups in five predictors including female gender (p-value = 0.047), breech presentation (p-value = 0.002), positive Ortolani test (p-value < 0.001), positive Barlow, test (p-value < 0.001), and limited hip (p-value = 0.023). Female newborns who had breech presentation, positive Ortolani test, positive Barlow, test, and limited hip were more likely to have DDH (OR [95%CI] = 2.82 [1.02, 7.85], OR [95%CI] = 5.12 [1.79, 14.55], OR [95%CI] = 34.21 [4.11, 284.51], OR [95%CI] = 69.64 [8.49, 571.57], OR [95%CI] = 5.48 [1.26, 23.73], respectively) (Table 3).

Of the initial 10 possible predictors, 5 that remained with high odds ratios were female gender, breech presentation, positive Ortolani test, positive Barlow test, and limited hip abduction. Multivariate analysis showed a significant association with breech presentation, positive Ortolani test, positive Barlow test, and limited hip abduction

TABLE 2 Characteristic of cases with abnormal hip ultrasound.

Characteristic (%)	N = 29 cases
Female	23 (79.31)
Right Side	22 (75.86)
Bilateral	13 (44.83)
Result of Hip Ultrasound	**N = 42 hips**
Laxity	7 (16.67)
Dysplasia	8 (19.05)
Subluxation	21 (50)
Dislocation	6 (14.28)

TABLE 1 Baseline characteristic.

Variable	Cases (n = 29)	Controls (n = 66)	p-value
Gestational ages (mean, SD)	36.6 (7.27)	37.7 (4.84)	0.378
Female gender (n, %)	23 (79.31)	38 (57.58)	0.062
Breech presentation (n, %)	12 (41.38)	8 (12.12)	0.002[a]
Family history of DDH in 1st degrees relatives (n, %)	0 (0)	1 (1.52)	1.000
First born child (n, %)	19 (65.52)	39 (59.09)	0.650
Associated anomalies (n, %)	4 (13.79)	3 (4.55)	0.195
Positive Ortolani test (n, %)	10 (34.48)	1 (1.52)	<0.001[a]
Positive Barlow test (n, %)	15 (51.72)	1 (1.52)	<0.001[a]
Limited hip abduction (n, %)	6 (20.69)	3 (4.55)	0.022[a]
Positive Galeazzi sign (n, %)	2 (6.90)	2 (3.03)	0.583

[a]Significant (p < 0.05), SD = standard deviation, CI = Confidence interval.

TABLE 3 Univariate logistic analysis and odd ratio.

Variables	Odds ratio	95% CI	p-value
Gestational ages (<37 weeks)	0.97	0.90, 1.04	0.397
Female gender	2.82	1.02, 7.85	0.047[a]
Breech presentation	5.12	1.79, 14.55	0.002[a]
Family history of DDH in 1st degrees relatives	1	–	–
First born child	1.32	0.53, 3.26	0.555
Associated anomalies	3.35	0.70, 16.10	0.130
Positive Ortolani test	34.21	4.11, 284.51	0.001[a]
Positive Barlow test	69.64	8.49, 571.57	<0.001[a]
Limited hip abduction	5.48	1.26, 23.73	0.023[a]
Positive Galeazzi sign	2.37	0.32, 17.71	0.400

[a]Significant (p < 0.05), CI = Confidence interval.

(p-value = 0.005, <0.001, <0.001, and 0.009, respectively) (Table 4 and Figure 1).

The final model included breech presentation, positive Ortolani test, positive Barlow test, and limited hip abduction. The best model cut-off value was 15.02. Sensitivity and specificity were 93.10% and 80.30%, respectively. The area under the ROC curve was 0.931 (Tables 5, 6 and Figure 2). Internal validation was done to estimate the potential for optimism and overfitting in model performance. We randomly split data into two sets with a ratio (70:30) for a development sample and a validation sample. The result of the four predictors remained significant (Table 7).

Discussion

Delayed diagnosis of DDH related to a significant morbidity and complexity of the treatments. Screening of the DDH in newborns is important to obtain the early diagnosis. Hip ultrasound screening for DDH provides better sensitivity compared to physical examination. Due to a lower prevalence and limited resources, selective hip ultrasound in newborns at

TABLE 4 Multivariate logistic regression analysis of 4 remaining variables.

Variable	Adjusted odds ratio	95% CI	p-value
Breech presentation	14.99	2.47, 90.94	0.003
Positive Ortolani test	121.03	9.36, 1565.35	<0.001[a]
Positive Barlow test	102.67	8.43, 1250.21	<0.001[a]
Limited hip abduction	19.91	2.14, 184.97	0.009

[a]Significant ($p < 0.05$), CI = Confidence interval.

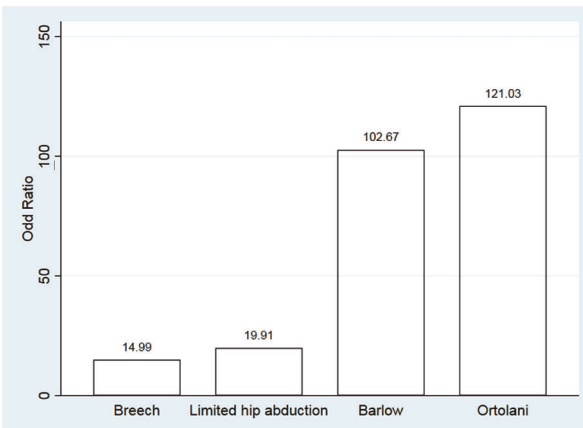

FIGURE 1
Odds ratio of 4 remained variables.

TABLE 5 Cutoff values and diagnostic ability for DDH.

Score	Sensitivity (%)	Specificity (%)	LR+	LR−
≥0.346	100.0	0	1.00	–
≥15.02	93.10	80.30	4.73	0.09
≥19.94	79.31	92.42	10.47	0.22
≥102.7	72.41	96.97	23.89	0.28
≥117.6	62.07	98.48	40.97	0.38
≥121.0	48.28	98.48	31.86	0.52

LR+ = likelihood ratio of positive test, LR− = likelihood ratio of negative test.

TABLE 6 The scoring system.

Breech presentation (14.99)	Ortolani test (121.03)	Barlow test (102.67)	Limited hip abduction (19.91)	Score
No	No	No	No	0
Yes	No	No	No	14.99
Yes	No	No	Yes	34.9
Yes	No	Yes	No	117.66
Yes	No	Yes	Yes	137.57
Yes	Yes	No	No	136.12
Yes	Yes	Yes	No	28.69
Yes	Yes	No	Yes	155.93
Yes	Yes	Yes	Yes	258.87
No	Yes	No	No	121.03
No	Yes	Yes	No	223.7
No	Yes	No	Yes	140.94
No	Yes	Yes	Yes	243.61
No	No	Yes	No	102.67
No	No	No	Yes	19.91
No	No	Yes	Yes	122.58

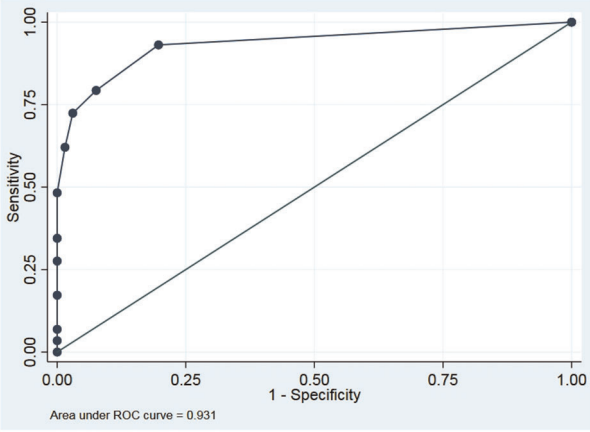

FIGURE 2
Area under the receiver operating characteristic (ROC) curve at cutoff value 15.02.

TABLE 7 Internal validity.

Variable	Coef.	95% CI	*p*-value
Breech presentation	2.85	0.96, 4.74	0.003[a]
Positive Ortolani test	3.83	1.15, 6.51	0.005[a]
Positive Barlow test	3.38	0.71, 6.05	0.013[a]
Limited hip abduction	3.79	1.08, 6.51	0.006[a]

[a]Significant ($p < 0.05$), Coef = Coefficient, CI = Confidence interval.

risk could be considered as a proper screening protocol in Asian countries, including Thailand.

There is an unclear conclusion about the risk factors to identify newborns at risk for DDH (20, 21). Moreover, the screening criteria may be different in each country. From previous studies, the risk factors are prematurity, oligohydramios, positive family history, breech presentation, postnatal traditional swaddling, female, clicking hip, and abnormal physical examination (6). While in this study, the criteria to warrant selective ultrasound included breech presentation, positive Ortolani test, positive Barlow test, and limited hip abduction. Other factors were found insignificant. This might be caused by the incidence of DDH in our study was very low and the other risk factors were rarely positive resulting in inadequate sample size to detect level of significance.

Abnormal physical examination of hip has been found to be a strong factor related to DDH (19, 21), which was similar to our results. Roposch A et al. (21) reported an odds ratio of abnormal physical examination (OR 53.91, 95% CI 31.35, 92.71), but did not specify the physical examination test as they aimed to create a risk prediction tool for maternity ward doctors. Meta-analysis of de Hundt M et al. (19) reported odds ratio of abnormal physical examination of clicking hip (OR 8.6, 95% CI 4.5, 16.6); however, they did not clearly state the criteria of clicking hip. Our study reported odds ratios of each abnormal physical examination including positive Ortolani test (OR 121.03, 95%CI 9.36, 1565.35; $p < 0.001$), positive Barlow test (OR 102.67, 95%CI 8.43, 1250.21; $p < 0.001$), and limited hip abduction (OR 19.91, 95%CI 2.14, 184.97; $p = 0.009$). The ORs of breech presentation in the European population were ranged between (OR 1.90–5.7) (5, 19, 20). Our study found more chance of DDH in Asian population who have a breech presentation (OR 14.99, 95%CI 2.47, 90.94; $p = 0.003$). The explanation might be the proportion of breech presentation in our study was very high (12 out of 29 cases; 41.38%) compared to controls (8 out of 66 newborns, 12.12%), **Table 1**. Moreover, adjusted by other strong risk factors may lead to large magnitude of association (**Table 4**).

Female gender was found as a risk factor for DDH (OR 2.27–5.8) (5, 19, 21) which was similar to our results from univariate analysis (OR 2.82, 95%CI 1.02, 7.85; $p = 0.047$); however, female gender was not significant in the multivariate analysis. In our analysis, family history of DDH was not significantly associated with DDH, which was the difference from previous studies (19–22). The contrast of these results might be because our study had a smaller sample size compared to earlier studies in the European population. DDH is not a common disease in Thailand, and the incidence of DDH in Asian countries is lower than in Europe (10), for which some factors might need a larger sample size.

We did an internal validation by randomly splitting data to correct predictive performance measures for optimism, of which four predictors gave significant results ($p < 0.050$). Our final model demonstrated excellent discrimination (area under ROC = 0.931) with four potential factors.

The strength of our study is that we developed the model with a high degree of precision. Our study used widely-accepted perinatal risk factors of DDH based from meta-analysis (19) and previous studies (5, 19–22). Two well-trained pediatric orthopaedic doctors measured the outcome with an excellent agreement in ultrasound results (96.3%). The limitations of our study include small number of patients, which might have affected the insignificant association of some risk factors such as female and family history of DDH, and imprecise confidence interval. There were 2 cases diagnosed DDH and did not have any risk factors (breech presentation, positive Ortolani test, positive Barlow test, limited hip abduction). One case had right hip subluxation and was treated by Pavlik harness. The other one was female with hip dysplasia. Both of them had neither history of oligohydramnios, family DDH, nor the first born child. It implies that suggested risk factors could miss 2 out of 29 DDH cases (6.9%). While 66 out of 95 newborns (69.5%) avoided unnecessary ultrasound screening. Further newborn recruitment may detect more significant risk factors, and perfectly capture all DDH.

In Thailand, orthopaedic surgeons are not the primary physicians who perform physical examination for detecting DDH. DDH screening is based on physical examination experiences by general practitioners or pediatricians. Only abnormal physical examination cases were referred to specialized hospitals. Although, universal ultrasound cannot be applied for all Thai newborns due to the limited resource and cost. Our model can be used for selective ultrasound screening to prevent the delayed diagnosis of DDH in an individual at-risk newborn. The model includes the clinical variables which used widely-accepted perinatal risk factors of DDH which in-significant factors should be noted as a precaution. However, it is critical to select all newborns having DDH and be treated adequately. We recommended that the high risk patients should be screen by ultrasound, while the patient with some risk factor, for example female, or family history of DDH, should have adequate follow up and

repeat physical examination. Moreover, future studies suggest increasing the sample size to see the robustness of the result.

Conclusion

Careful history taking and physical examination are essential to identify the risk factors for DDH. Newborns with breech presentation, positive Ortolani test and positive Barlow test should be screened by hip ultrasound.

Data availability statement

The original contributions presented in the study are included in the article/Supplementary Material, further inquiries can be directed to the corresponding author/s.

Ethics statement

The studies involving human participants were reviewed and approved by COA. MURA2021/273. Written informed consent to participate in this study was provided by the participants' legal guardian/next of kin.

Author contributions

CA, TP, and PW contributed to research design. CA, WJ, TS, PM, and PW contributed data. CA, TP and KK performed the data collection and analysis. CA and PW proceed data interpretation. CA, TP, and PW writing, and critically revising the manuscript. All authors contributed to the article and approved the submitted version.

Conflict of interest

The authors declare that the research was conducted in the absence of any commercial or financial relationships that could be construed as a potential conflict of interest.

Publisher's note

All claims expressed in this article are solely those of the authors and do not necessarily represent those of their affiliated organizations, or those of the publisher, the editors and the reviewers. Any product that may be evaluated in this article, or claim that may be made by its manufacturer, is not guaranteed or endorsed by the publisher.

References

1. Chan A, McCaul KA, Cundy PJ, Haan EA, Byron-Scott R. Perinatal risk factors for developmental dysplasia of the hip. *Arch Dis Child Fetal Neonatal Ed.* (1997) 76(2):F94–100. doi: 10.1136/fn.76.2.F94

2. Ibrahim S. Tachdjian's pediatric orthopaedics: from the Texas Scottish rite hospital for children. *Malays Orthop J.* (2015) 9(1):53. doi: 10.5704/MOJ.1503.012

3. Arti H, Mehdinasab SA, Arti S. Comparing results of clinical versus ultrasonographic examination in developmental dysplasia of hip. *J Res Med Sci.* (2013) 18(12):1051–5. https://www.ncbi.nlm.nih.gov/pmc/articles/PMC3908525/

4. Woolacott NF, Puhan MA, Steurer J, Kleijnen J. Ultrasonography in screening for developmental dysplasia of the hip in newborns: systematic review. *BMJ (Clin Res ed).* (2005) 330(7505):1413. doi: 10.1136/bmj.38450.646088.E0

5. Kural B, Devecioğlu Karapınar E, Yılmazbaş P, Eren T, Gökçay G. Risk factor assessment and a ten-year experience of DDH screening in a well-child population. *Biomed Res Int.* (2019) 2019:7213681. doi: 10.1155/2019/7213681

6. Graf R. Classification of hip joint dysplasia by means of sonography. *Arch Orthop Trauma Surg.* (1984) 102(4):248–55. doi: 10.1007/BF00436138

7. Krismer M, Klestil T, Morscher M, Eggl H. The effect of ultrasonographic screening on the incidence of developmental dislocation of the hip. *Int Orthop.* (1996) 20(2):80–2. doi: 10.1007/s002640050034

8. Wientroub S, Grill F. Ultrasonography in developmental dysplasia of the hip. *J Bone Joint Surg Am.* (2000) 82-a(7):1004–18. doi: 10.2106/00004623-200007000-00012

9. Weinstein SL, Flynn JM. *Lovell and Winter's Pediatric orthopaedics.* Philadelphia: Lippincott Williams & Wilkins (2013).

10. Loder RT, Skopelja EN. The epidemiology and demographics of hip dysplasia. *ISRN Orthop.* (2011) 2011:238607. https://www.ncbi.nlm.nih.gov/pmc/articles/PMC4063216/

11. Tschauner C, Fürntrath F, Saba Y, Berghold A, Radl R. Developmental dysplasia of the hip: impact of sonographic newborn hip screening on the outcome of early treated decentered hip joints-a single center retrospective comparative cohort study based on Graf's Method of hip ultrasonography. *J Child Orthop.* (2011) 5(6):415–24. doi: 10.1007/s11832-011-0366-y

12. Thallinger C, Pospischill R, Ganger R, Radler C, Krall C, Grill F. Long-term results of a nationwide general ultrasound screening system for developmental disorders of the hip: the Austrian hip screening program. *J Child Orthop.* (2014) 8(1):3–10. doi: 10.1007/s11832-014-0555-6

13. Studer K, Williams N, Antoniou G, Gibson C, Scott H, Scheil WK, et al. Increase in late diagnosed developmental dysplasia of the hip in South Australia: risk factors, proposed solutions. *Med J Aust.* (2016) 204(6):240. doi: 10.5694/mja15.01082

14. Agostiniani R, Atti G, Bonforte S, Casini C, Cirillo M, De Pellegrin M, et al. Recommendations for early diagnosis of developmental dysplasia of the hip (DDH): working group intersociety consensus document. *Ital J Pediatr.* (2020) 46(1):150. doi: 10.1186/s13052-020-00908-2

15. Harcke HT, Clarke N, Lee M, Borns PF, MacEwen GD. Examination of the infant hip with real-time ultrasonography. *J Med Ultrasound.* (1984) 3(3):131–7. doi: 10.7863/jum.1984.3.3.131

16. Harcke HT. Screening newborns for developmental dysplasia of the hip: the role of sonography. *AJR Am J Roentgenol.* (1994) 162(2):395–7. doi: 10.2214/ajr.162.2.8310933

17. Clarke N, Harcke HT, Mchugh P, Lee MS, Borns PF, MacEwen GD, et al. Real-time ultrasound in the diagnosis of congenital dislocation and dysplasia of the hip. *J Bone Jt Surg, Br vol.* (1985) 67(3):406–12. doi: 10.1302/0301-620X.67B3.3889008

18. Harcke HT, Pruszczynski B. Hip ultrasound for developmental dysplasia: the 50% rule. *Pediatr Radiol.* (2017) 47(7):817–21. doi: 10.1007/s00247-017-3802-4

19. de Hundt M, Vlemmix F, Bais JM, Hutton EK, de Groot CJ, Mol BW, et al. Risk factors for developmental dysplasia of the hip: a meta-analysis. *Eur J Obstet Gynecol Reprod Biol.* (2012) 165(1):8–17. doi: 10.1016/j.ejogrb.2012.06.030

20. Ömeroğlu H, Akceylan A, Köse N. Associations between risk factors and developmental dysplasia of the hip and ultrasonographic hip type: a retrospective case control study. *J Child Orthop*. (2019) 13(2):161–6. doi: 10.1302/1863-2548.13.180174

21. Roposch A, Protopapa E, Malaga-Shaw O, Gelfer Y, Humphries P, Ridout D, et al. Predicting developmental dysplasia of the hip in at-risk newborns. *BMC Musculoskelet Disord*. (2020) 21(1):442. doi: 10.1186/s12891-020-03454-4

22. Demir GÜ, Sarı E, Karademir S, Üner Ç, Yıldız YT, Onay U, et al. Ultrasonographic screening and the determination of risk factors involved in developmental dysplasia of the hip. *Pediatr Res*. (2020) 7(1):52–7. doi: 10.4274/jpr.galenos.2019.68095

23. Agarwal A, Gupta N. Risk factors and diagnosis of developmental dysplasia of hip in children. *J Clin Orthop Trauma*. (2012) 3(1):10–4. doi: 10.1016/j.jcot.2011.11.001

frontiers | Frontiers in Surgery

TYPE Original Research
PUBLISHED 02 November 2022
DOI 10.3389/fsurg.2022.1028542

Check for updates

OPEN ACCESS

EDITED BY
Paphon Sa-ngasoongsong,
Mahidol University, Thailand

REVIEWED BY
Wei Chen,
The Third Hospital of Hebei Medical University, China
Jianlin Xiao,
Jilin University, China

*CORRESPONDENCE
Junlin Zhou
junlinzhou_article@outlook.com

†These authors have contributed equally to this work and share first authorship

SPECIALTY SECTION
This article was submitted to Orthopedic Surgery, a section of the journal Frontiers in Surgery

RECEIVED 26 August 2022
ACCEPTED 03 October 2022
PUBLISHED 02 November 2022

CITATION
Diao S, Li J, Zhao J, Wang D, Wang H, Xu X and Zhou J (2022) Risk factors and new inflammatory indicators of deep vein thrombosis after adult patella fractures. Front. Surg. 9:1028542. doi: 10.3389/fsurg.2022.1028542

COPYRIGHT
© 2022 Diao, Li, Zhao, Wang, Wang, Xu and Zhou. This is an open-access article distributed under the terms of the Creative Commons Attribution License (CC BY). The use, distribution or reproduction in other forums is permitted, provided the original author(s) and the copyright owner(s) are credited and that the original publication in this journal is cited, in accordance with accepted academic practice. No use, distribution or reproduction is permitted which does not comply with these terms.

Risk factors and new inflammatory indicators of deep vein thrombosis after adult patella fractures

Shuo Diao[1†], Jingqiao Li[2†], Jianyong Zhao[3], Dong Wang[1], Hanzhou Wang[1], Xiaopei Xu[1] and Junlin Zhou[1*]

[1]Department of Orthopedic Surgery, Beijing Chaoyang Hospital, Capital Medical University, Beijing, China, [2]Department of Orthopedic Surgery, Hebei Jing-Xing Xian Hospital, Shijiazhuang, China, [3]Department of Hand Surgery, Cangzhou Hospital of Integrated Traditional and Western Medicine of Hebei Province, Cangzhou, China

Objective: This study aimed to investigate the association between new inflammatory indicators at admission and the occurrence of preoperative deep vein thrombosis (DVT) in patients with patella fractures.

Methods: A retrospective analysis of the medical records of patients aged 18 years or older who underwent surgical treatment for unilateral closed patella fractures at our hospital between August 2016 and August 2020. The incidence of preoperative DVT was detected by Duplex ultrasound (DUS). Partial blood routine and biochemical indexes were collected at admission, and the neutrophil-to-lymphocyte ratio (NLR), monocyte-to-lymphocyte ratio (MLR), and platelet-to-lymphocyte ratio (PLR) of inflammatory indexes were also calculated. ROC was used to analyze the cut-off value NLR, MLR, and PLR for predicting preoperative DVT, and univariate and multivariate analyses of the risk factors for preoperative DVT of patella fractures, and to verify whether other risk factors affecting the relationship between validation indexes and preoperative DVT.

Results: A total of 500 patients were included, of which 39 patients (7.8%) developed preoperative DVT. After univariate and multivariate analysis, preoperative time (in each day delay), male (vs. female), D-dimer > 0.6 mg/L, total cholesterol (TC) > 5.6 mmol/L, and PLR > 189.8 were the risk factors for preoperative DVT in patients with patella fracture. Inflammation index PLR combined with the other four risk factors significantly improved the predictive efficacy of preoperative DVT compared with PLR ($P = 0.009$).

Conclusion: Inflammatory index PLR is a risk factor for preoperative DVT in patients with patella fracture, and the efficacy of PLR in predicting DVT can be significantly improved when other risk factors (male, D-dimer > 0.6 mg/L, TC > 5.6 mmol/L, and PLR > 189.8 of preoperative time in each day delay) are combined. These data are useful for the clinical identification of patients at high risk of preoperative DVT in patella fractures.

KEYWORDS

risk factor, inflammatory indicators, deep vein thrombosis, patella fracture, platelet-to-lymphocyte ratio (PLR)

Introduction

DVT is a common complication in patients with lower extremity fractures and carries a risk of fatal pulmonary embolism. DVT has been reported in patients with fractures at the time of admission (1). A patella fracture is a common fracture of the lower extremity with an incidence of 1% to 1.5% (2, 3). Although the incidence is not high, but once the occurrence of activities affecting the knee joint. In addition, the pain after fracture leads to the limitation of lower extremity movement, and the slow venous blood flow caused by immobilization of the affected extremity leads to the risk of DVT (4, 5). Previous studies have shown that the incidence of preoperative DVT in the patella fracture is 4.4% to 5.8% (6, 7).

Understanding the high-risk factors of DVT and early identification of high-risk patients are the key to preventing DVT. However, risk factors are inconsistent in different studies (7–9). Recent studies have found that inflammation is involved in the formation of DVT. Post-traumatic inflammatory response activates inflammatory cells and releases inflammatory factors in the body (10), which leads to systemic reaction and disorder of coagulation and anticoagulation mechanism (11). The neutrophil-to-lymphocyte ratio (NLR), monocyte/lymphocyte (MLR), and platelet to lymphocyte ratio (PLR) are brand new biomarkers of the inflammatory response, which can reflect the overall level of inflammation in the body (12–14). In DVT-related studies, NLR is a high-risk factor for death due to acute DVT in cancer patients (15). Peng et al. (16) found that MLR increased in patients with postoperative venous thromboembolism in patients with hip fractures. Moreover, Kuplay et al. (17) also found that PLR in cardiovascular patients increased significantly in proximal DVT. However, at present, it is not clear whether inflammation indicators NLR, MLR, and PLR are related to the occurrence of preoperative DVT after a patella fracture. And that pushed us to explore.

Our objective was to collect data from patients with surgically treated patella fractures in our hospital and analyze whether inflammatory indicators were risk factors for DVT. In addition, when inflammatory indicators are combined with other risk factors, whether the association between inflammatory indicators and DVT is affected.

Methods

Patients

This study retrospectively collected the data of patients with surgically treated patella fracture admitted to our hospital from August 2016 to August 2020. This study was approved by the Ethics Committee of the Hebei Cangzhou Hospital of Integrated Traditional Chinese Medicine and Western Medicine, focusing only on the examination results of patients. All patients enrolled signed informed consent forms. All data are obtained through our electronic medical records system. According to the empirical criteria, the sample size of logistic regression analysis should be 10 to 15 times the number of covariates. There were 36 covariates in this study, and the sample size should not be less than $36 \times 10 = 360$.

Inclusion and exclusion

Inclusion criteria were: patients' age to be 18 years old or older, unilateral patella fracture, and surgical treatment. Exclusion criteria: time >2 weeks from fracture, complicated fractures at other sites, open fractures, pathological fractures, severe autoimmune diseases, infectious diseases at the time of fracture, abnormal coagulation function, use of anticoagulants within 3 months of admission, incomplete medical records.

Data collection

The data collected mainly included the following aspects: demographic data, comorbidities, injuries, blood routine and biochemical test results, and routine DUS test results of DVT.

The demographic data include sex, age, body mass index (BMI), current smoking, alcohol consumption, American Society of Anesthesiologists (ASA). The comorbidities included hypertension, diabetes, chronic heart disease, cerebrovascular disease, and allergies to any medications, all of which were self-reported by patients. Injury-related data included the following: time from injury to hospital admission, mechanism of injury (low or high energy), time from hospital admission to operation, and total length of stay. Low energy injury refers to a fall at a high level while the patient is standing. High energy injury refers to injury caused by traffic accident or position injury higher than their own height.

Blood collection and test results information

Venous blood was collected from the elbow veins on an empty stomach for the first time after admission.Vein blood samples were collected in vacuum tubes containing sodium citrate anticoagulant. Blood samples were sent to the laboratory of our hospital for blood analysis within 6 h after collection. Laboratory tests included measurements of levels of total protein (TP), albumin (ALB), alkaline phosphatase (ALP), total bilirubin (TBIL), γ-glutamyl transferase (GGT), hypersensitive C-reactive protein (HCRP), total bile acid

(TBA), creatine kinase (CK), lactic dehydrogenases (LDH), total cholesterol (TC), triglycerides (TG), high-density lipoprotein (HDL-C) level, low-density lipoprotein (LDL-C) level, very low-density lipoprotein (VLDL) level, glucose (GLU), uric acid (UA), white blood cell (WBC) count, neutrophile (NEUT) count, lymphocyte (LYM) count, monocytes (MON) count, red blood cell (RBC) count, hemoglobin (HGB) level, platelet (PLT) count, D-dimer level. Neutrophile-to-lymphocyte rate (NLR), monocytes-to-lymphocyte rate (MLR), platelet-to-lymphocyte rate (PLR) were calculated according to blood routine indexes.

Diagnosis and prevention of DVT

The patient could not perform off-bed weightbearing exercises because of pain in the injured extremity, but lay in bed until surgery. After admission, all patients were given Low Molecular Weight Heparin Injection (LMWHI) subcutaneous (abdominal subcutaneous) for anticoagulation (4250 I.U., once daily). In addition to drug prophylaxis, the patient underwent physical prophylaxis for DVT with ankle pump exercise in bed (1,000 times, once daily). Drug anticoagulation was discontinued on the day of operation. Patients were screened for DVT by DUS on the first day after admission and every 3 days thereafter, up to the day of operation. If any symptoms of thrombosis (e.g., lower extremity distention, pain, and acute varicose superficial veins) occur in the preoperative time, DUS should be performed immediately to confirm DVT. The occurrence of DVT in patients was detected by the same group of senior ultrasound doctors in our hospital. The "Guidelines for the Diagnosis and Treatment of Deep Vein Thrombosis (2016 3rd Edition)" issued by the Chinese Medical Association was used to diagnose and treat DVTs (18). The veins examined include: femoral common vein, superficial and deep femoral vein, popliteal vein, posterior and anterior tibial vein and peroneal vein. Patients diagnosed with DVT are consulted by vascular surgeons to determine the treatment of thrombosis. The timing of the patient's operation is determined by a senior orthopedic surgeon. The observation period was from the time of fracture to the time of operation, and the time of DVT the first detected by DUS was recorded. Patients were divided into DVT group and non-DVT group according to whether preoperative DVT occurred.

Statistical analysis

SPSS 25.0 (IBM, Armonk, New York) and MedCalc 20.0 (MedCalc Software, Ostend, Belgium) was used for statistical analysis. For biomarker NLR, PLR, MLR, and the plasma D-dimer level, we constructed receiver operating characteristic (ROC) to determine the optimal cutoff value for each variable. On basis of the cutoff values determined, each variable was divided in to two groups. Categorical variables were analyzed by chi-square or Fisher's exact test. Student T test or Mann-Whitney test was performed for continuous variables. Univariate analysis of differences between DVT group and non-DVT group. Multivariate logistic regression model and stepwise backward elimination method were used to investigate the independent risk factors that predicted the occurrence of DVT. The univariate analysis results of $P < 0.10$ were included in the model, and the correlation strength was expressed by odds ratio (OR) and 95% confidence interval (95% CI). Hosmer–Lemeshow test was employed to evaluate the fitting degree of the final model, and a $P > 0.05$ represented the acceptable result. The ability of inflammatory indicators combined with other independent risk factors to predict preoperative DVT was evaluated by ROC curve again. The combination of indicators and individual inflammatory indicators were compared to predict whether there was statistical difference in preoperative DVT. The significance level was set as $P < 0.05$.

Results

In the window period, a total of 612 cases of patella fracture patients. According to the exclusion criteria, fracture over 2 weeks; complicated fractures at other sites, open fractures, a total of 54 cases, pathological fracture, severe autoimmune diseases and infectious diseases at the time of fracture, use of anticoagulants within 3 months of admission, a total of 32 cases, 26 cases of incomplete medical records. A total of 500 patients were included.

They were divided into two groups based on the presence or absence of preoperative DVT: 461 patients in non-DVT group and 39 patients in DVT group, respectively. In the DVT group, there were 32 (82.1%) males and 7 (17.9%) females, with an average age of 57.0 ± 15.3 years (range, 28–84 years). In the non-DVT group, there were 273 (59.2%) males and 188 (40.8%) females, with an average age of 52.1 ± 14.9 years (range, 18–86 years). There were 275 (55%) left patella fractures and 225 (45%) right patella fractures. The mean days from fracture to admission was 0.2 ± 0.4 days (range, 0.02 to 5 days), the mean days from fracture to operation was 4.1 ± 2.1 days (range, 0–14 days), and mean total hospital stay was 11.3 ± 3.8 days (rang, 5–26 days).

DVT patient information

Preoperative DVT was detected in 39 patients 7.8% (39/500). None of the patients had pulmonary embolism. 79.5% (31/39) occurred in the injured lower extremity and 20.5% (8/39) in the uninjuried lower extremity, as shown in **Figure 1**. Among all the thrombus, DVT was found in only 4 deep

veins, namely superficial femoral vein, popliteal vein, posterior tibial meridians and fibular vein. Their specific distribution is shown in Figure 2. There were 67 clots in 39 patients, with an average of 1.7 clots each patient, and 17 patients had only 1 clots. The mean time from fracture to DVT detection was 3.5 ± 2.2 days (range 0.1–11.1 days).

ROC analysis of inflammatory indicators for the diagnosis of DVT optimal cutoff value

According to the ROC curve (Figure 3), the optimal cut off values for predicting DVT of continuous variables NLR, MLR, PLR and D-dimer are selected as follows: NLR, 4.6, AUC, 0.632; MLR, 0.7, AUC, 0.625; PLR, 189.8, AUC, 0.733; D-dimer, 0.6, AUC, 0.701 (as follow Table 1). These inflammatory biomarkers were converted into dichotomous variables based on thresholds.

Univariate analysis of DVT group and non-DVT group

As shown in Table 2, we found statistically that gender, time from fracture to operation, TP < 60 g/L, LDH > 250 U/L, TC > 5.2 mmol/L, PLT > 300*109/L, NLR > 4.6, MLR > 0.7, PLR > 189.8, and D-dimer > 0.6 mg/L was significantly different between DVT group and non-DVT group ($P < 0.05$).

Multivariate analysis predicted the independent risk factors for preoperative DVT and compared the differences after combination.

Multivariate logistic regression model analysis found five independent risk factors for preoperative DVT, which were male(vs. female) ($P = 0.008$), time from fracture to operation (in each day delay) ($P < 0.001$), D-dimer > 0.6 mg/L ($P < 0.001$), TC > 5.2 mmol/L ($P = 0.005$), and PLR > 189.8 ($P < 0.001$), as shown in Table 3. The H-L test of demonstrated The good fitness of The final model (X2 = 5.680, $P = 0.683$; Nagelkerke R2 = 0.289). After PLR was combined with other 4 factors, it was found that AUC, sensitivity and specificity for predicting preoperative DVT were 0.833, 0.641 and 0.883 (Figure 4). Better than PLR alone in predicting DVT efficacy (AUC, 0.833 vs. 0.733, $P = 0.009$).

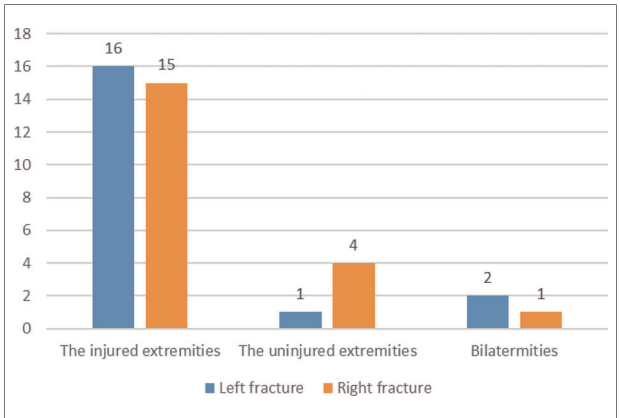

FIGURE 1
The distribution of DVT in the lower extremity.

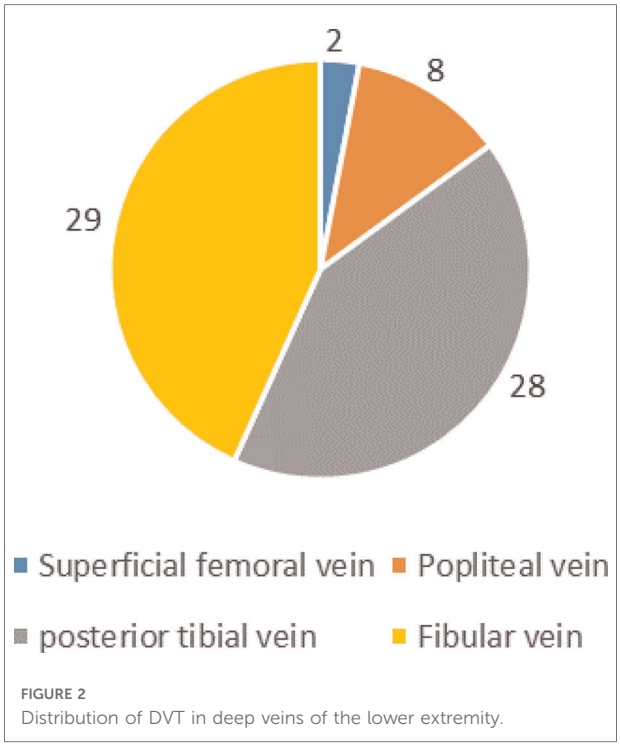

FIGURE 2
Distribution of DVT in deep veins of the lower extremity.

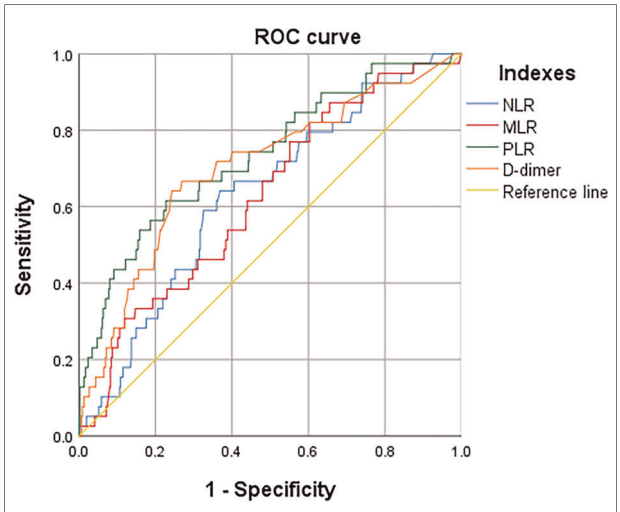

FIGURE 3
ROC to determine the optimal cutoff value for NLR, LMR, PLR, and D-dimer, when in continuous variable.

TABLE 1 The ROC and AUC to determine the optimal cutoff value for each index in continuous variable.

Variable	Optimal cutoff value	AUC	Sensitivity	Specificity	*P* value
NLR	4.6	0.632	0.641	0.631	0.006
MLR	0.7	0.625	0.769	0.449	0.010
PLR	189.8	0.733	0.615	0.772	<0.001
D-dimer	0.6	0.701	0.641	0.757	<0.001

Discussion

Patients with patella fracture were selected for a retrospective analysis of the occurrence of preoperative DVT and related risk factors, and the risk factors were linearized to predict the occurrence of DVT again. In this study, we found that the incidence of preoperative DVT was 7.8%, and identified male, time from fracture to operation (in each day delay), D-dimer > 0.6 mg/L ($P < 0.001$), TC > 5.2 mmol/L ($P = 0.005$), and PLR > 189.8 were risks factor for preoperative DVT in patients with patella fracture. The AUC of preoperative DVT after patella fracture predicted by ROC analysis after PLR combined with other 4 risk factors was 0.833, the sensitivity was 0.883, and the specificity was 0.641.

Data from this study showed that the incidence of preoperative DVT was 7.8% in patients with patella fractures. Previous studies have shown that the incidence of preoperative DVT is between 4.1% to 52.5% in patients with perioperative knee fracture, including fractures of the distal femur, patella, and proximal tibia (6, 7, 19–21). The incidence of DVT in the perioperative period of preoperative patella fracture was 4.1%–5.8% (6, 7), and the results of this study were basically consistent with them. In terms of location, 79.5% of DVT occurred in the affected lower extremities, and 85% of DVT occurred in the posterior tibial vein and fibular vein, which was consistent with Yang et al. (6) and Luo et al. (22).

In this study, male was a risk factor for the occurrence of preoperative DVT in patients, and the risk of male was 2.53 times higher than that of female. In other studies, the risk of DVT in males is 1.29–2.35 times higher than that in females (6, 18, 23). However, females in childbearing age are higher than males, while males are higher than females in non-childbearing age (24, 25). In our sample, 66.7% (26/39) of the DVT group were over 50 years old, which was consistent with the epidemiological statistical results. Some reports indicate that the difference may be related to hormone levels and genetics in women (24, 26, 27). The results of this study also showed that for each additional day before surgery, the risk of developing preoperative DVT increased by 31%. It's also an easy ending to understand. The patient's bed rest after fracture slows down the blood velocity of the lower extremities. On the other hand, the hypercoagulability of

TABLE 2 Univariate analyses of risk factors associated with preoperative DVT after patella fracture.

Variables	Number (%) of DVT ($n = 39$)	Number (%) of non-DVT ($n = 461$)	*P* value
Gender			0.005
Male	32 (82.1)	273 (59.2)	
Female	7 (17.9)	188 (40.8)	
Age (years)	57.0 ± 15.3	52.1 ± 14.9	0.050
BMI (kg/m^2)	22.9 ± 2.5	24.2 ± 3.2	0.235
Diabetes	4 (10.3)	61 (13.2)	0.596
Hypertension	8 (20.5)	105 (22.8)	0.746
Chronic heart disease	11 (28.2)	114 (24.7)	0.630
Allergy to any medications	3 (7.7)	61 (13.2)	0.320
cerebrovascular disease	4 (10.3)	37 (8.0)	0.626
Mechanism (high-energy)	7 (17.9)	74 (12.1)	0.283
Smoking	8 (20.5)	54 (11.7)	0.109
Alcohol	5 (12.8)	37 (8.0)	0.300
ASA			0.442
I - II	33 (84.6)	409 (88.7)	
III - IV	6 (15.4)	52 (11.3)	
Time from fracture to operation (days)	5.8 ± 1.9	4.1 ± 2.2	<0.001
TP (<60 g/L)	27 (69.2)	239 (51.8)	0.037
ALB (<35 g/L)	19 (48.7)	162 (35.1)	0.090
ALP (>upper limit)	2 (5.1)	34 (7.4)	0.602
TBIL (>upper limit)	2 (5.1)	19 (4.1)	0.763
GGT (>upper limit)	5 (12.8)	39 (8.5)	0.356
HCRP (>8 mg/L)	22 (56.4)	188 (40.8)	0.058
TBA (>10 umol/L)	2 (5.1)	37 (8.0)	0.517
CK (> upper limit)	3 (7.7)	29 (6.3)	0.731
LDH (>250 U/L)	6 (15.4)	30 (6.5)	0.039
HBDH (>182 U/L)	4 (10.3)	30 (6.5)	0.372
TC (>5.2 mmol/L)	13 (33.3)	71 (16.5)	0.004
TG (>1.7 mmol/L)	8 (20.5)	90 (19.5)	0.881
HDL-C (<1.1 mmol/L)	14 (35.9)	132 (28.6)	0.338
LDL-C (>3.37 mmol/L)	8 (20.5)	76 (16.5)	0.518
VLDL (>0.78 mmol/L)	8 (20.5)	88 (19.1)	0.828
GLU (>6.1 mmol/L)	18 (46.2)	155 (33.6)	0.114
UA (> upper limit)	3 (7.7)	51 (11.1)	0.515
WBC (>10*10^9/L)	13 (33.3)	110 (23.9)	0.187
NEUT (>6.3*10^9/L)	22 (56.4)	190 (41.2)	0.065
LYM (<1.1*10^9/L)	11 (28.2)	94 (20.4)	0.250
MON (>0.6*10^9/L)	24 (61.5)	246 (53.4)	0.325
RBC < lower limit	15 (38.5)	113 (24.5)	0.055
HGB < lower limit	9 (23.1)	87 (18.9)	0.522
PLT (>300*10^9/L)	17 (43.6)	120 (26.0)	0.018
NLR (>4.6)	24 (61.5)	166 (36.0)	0.002

(*continued*)

TABLE 2 Continued

Variables	Number (%) of DVT ($n = 39$)	Number (%) of non-DVT ($n = 461$)	*P* value
MLR (>0.7)	13 (33.3)	79 (17.1)	0.012
PLR (>189.8)	23 (59.0)	106 (23.0)	<0.001
D-dimer (>0.6 mg/L)	22 (56.4)	104 (22.6)	<0.001

ALP, alkaline phosphatase, reference range: female, 35–100 U/L; male, 45–125 U/L; TBIL, total bilirubin, reference range: female, 0–21 umol/L; male, 0–26 umol/L; GGT, γ-glutamyl transferase, reference range: female, 0–21 umol/L; male, 7–45 U/L, 10–60 U/L; CK, creatine kinase, reference range: female, 40–200 U/L; male, 50–310 U/L; UA, uric acid, reference range: female, 155–357 umol/L; male, 208–428 umol/L; RBC, red blood cell, reference range: Female, 3.5–5.0*1012/L; male, 4.0–5.5*1012/L; HGB, hemoglobin, reference range: Female, 110–150 g/L; male, 120–160 g/L

blood after trauma contributes to the occurrence of DVT, which also conforms to Virchow's Law (28). Similar results have been confirmed in spinal fracture (29), hip fracture (30), patella fracture (6) and foot fracture (8). With the increase of preoperative time, the risk of DVT in patients is 5% to 29%.

D-dimer is a recognized diagnostic index for the occurrence of DVT, which reflects the coagulation and fibrinolysis state of the body (31–33). Our results also show this characteristic of D-dimer. There is evidence that the D-dimer threshold for DVT diagnosis in patients with spinal and tibial fractures is 1.08 mg/L and 1.76 mg/L, respectively (21, 34). In this study, the threshold was 0.6 mg/L by ROC analysis. In terms of risk, we found that patients with D-dimer > 0.6 mg/L were 3.78 times more likely to develop DVT than patients with D-dimer ≤ 0.6 mg/L. It is well known that high plasma TC levels increase the incidence of cardiovascular events and death (35). We found that TC > 5.2 mmol/L increased the incidence of preoperative DVT, and multivariate analysis showed that the risk of DVT increased by 0.8 times. Leiba et al. (36) found that patients with high cholesterol significantly increased in patients with DVT, which was consistent with our research results.

Although NLR and MLR univariate analyses showed differences between the DVT and non-DVT groups. However, multivariate analysis did not identify an independent risk factor for preoperative DVT. We found that the AUC of PLR

TABLE 3 Multivariate analysis of factors associated with preoperative DVT of patella fractures.

Variables	OR and 95% CI	*P* value
Gender (male vs. female)	3.53 (1.39–8.92)	0.008
Time from fracture to operation (in each day delay)	1.31 (1.12–1.52)	<0.001
D-dimer (>0.6 mg/L)	3.78 (1.81–7.89)	<0.001
TC (>5.2 mmol/L)	1.80 (1.20–2.70)	0.005
PLR (>189.8)	3.73 (1.80–7.77)	<0.001

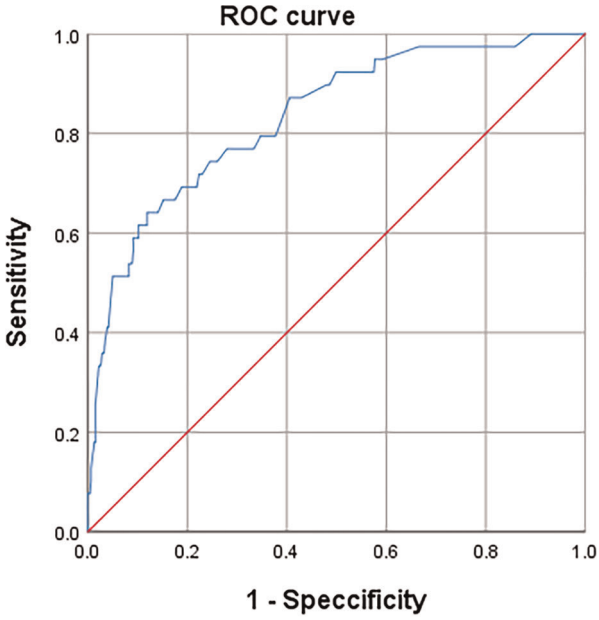

FIGURE 4
The ROC curve of the combined diagnostic index A for the diagnosis of preoperative DVT.

predicting DVT at admission was 0.733, and the sensitivity and specificity were 0.615 and 0.772, respectively. Patients with PLR > 189.8 had a 2.73-fold increased risk of preoperative DVT. Systemic inflammatory response and immunosuppression can be triggered immediately after trauma (37). Platelets, as cellular effector factors of inflammation and thrombosis, can also be activated after trauma (38). It may stimulate this inflammatory response *in vivo* and cause the increase of platelets (39). There is evidence that platelets play an important role in DVT (40). Multiple studies have shown that high PLR is associated with DVT (41–43), and there is also evidence that high PLR is associated with acute DVT (15). Other studies have shown that high PLR increases the risk of venous thrombosis by nearly 3 times (43). The results of this study are consistent with those reported.

Yao et al. (42) found that patients with postoperative DVT had higher preoperative PLR, but lower sensitivity and specificity in predicting DVT. We found similar results. Independent PLR showed low efficacy and low sensitivity and specificity in predicting preoperative DVT (AUC, 0.733, sensitivity, 0.615, specificity, 0.772). We linearized the combination of inflammatory indicator PLR with other 4 independent risk factors at admission, and found that the AUC for predicting DVT was 0.834, and the sensitivity and specificity were 0.641 and 0.839, respectively, which further proved that PLR after combination was highly correlated with the occurrence of preoperative DVT. The predictive efficacy and specificity of DVT were improved ($P = 0.009$). However, the sensitivity is not

high, only 0.641. We analyzed that PLR may be affected by other factors, but this needs further confirmation.

There are some limitations of this study: First, we did not collect anticoagulant and blood drawing time after admission and before fasting venous blood drawing. Second, the amount of intravenous fluids in different patients before surgery may not be completely consistent. Third, none of the patients moved out of bed before surgery. These causes may influence independent factor results or the incidence of DVT.

Conclusions

By collecting data from patients with patella fractures, it was found that the incidence of preoperative DVT for patella fractures was 7.8%. Multivariate analysis showed that male, preoperative time (in each day delay), TC > 5.2 mmol/L, D-dimer > 0.6 mg/L, and PLR > 189.8 were independent risk factors for preoperative DVT of patella fracture. PLR combined with other risk factors improved the ability to predict preoperative DVT. Better than PLR alone ($P = 0.009$). PLR is expected to be a predictor of DVT, especially when other risk factors are combined.

Data availability statement

The original contributions presented in the study are included in the article/Supplementary Material, further inquiries can be directed to the corresponding author/s.

Author contributions

(I) Conception and design: SD, JL; (II) Administrative support: JZ; (III) Provision of study materials or patients: JZ; (IV) Collection and assembly of data: DW; (V) Data analysis and interpretation: HW; (VI) Manuscript writing: All authors; (VII) Final approval of manuscript: All authors. All authors contributed to the article and approved the submitted version.

Conflict of interest

The authors declare that the research was conducted in the absence of any commercial or financial relationships that could be construed as a potential conflict of interest.

Publisher's note

All claims expressed in this article are solely those of the authors and do not necessarily represent those of their affiliated organizations, or those of the publisher, the editors and the reviewers. Any product that may be evaluated in this article, or claim that may be made by its manufacturer, is not guaranteed or endorsed by the publisher.

References

1. Zuo J, Hu Y. Admission deep venous thrombosis of lower extremity after intertrochanteric fracture in the elderly: a retrospective cohort study. *J Orthop Surg Res.* (2020) 1(15):549. doi: 10.1186/s13018-020-02092-9

2. Melvin JS, Mehta S. Patella fractures in adults. *J Am Acad Orthop Surg.* (2011) 4(19):198–207. doi: 10.5435/00124635-201104000-00004

3. Wild M, Windolf J, Flohé S. Fractures of the patella. *Unfallchirurg.* (2010) 5 (113):401–11. quiz 412. doi: 10.1007/s00113-010-1768-x

4. Zee AA, van Lieshout K, van der Heide M, Janssen L, Janzing HM. Low molecular weight heparin for prevention of venous thromboembolism in patients with lower-limb immobilization. *Cochrane Database Syst Rev.* (2017) 8 (8):Cd006681. doi: 10.1002/14651858.CD006681.pub4

5. Matthews JH, Terrill AJ, Barwick AL, Butterworth PA. Venous thromboembolism in podiatric foot and ankle surgery. *Foot Ankle Spec.* (2018) 5(11):444–50. doi: 10.1177/1938640017750256

6. Yang W, Wang H, Wei Q, Ding K, Jia Y, Li C, et al. Preoperative incidence and risk factors of deep vein thrombosis in patients with an isolated patella fracture. *BMC Musculoskelet Disord.* (2022) 1(23):204. doi: 10.1186/s12891-022-05163-6

7. Tan Z, Hu H, Deng X, Zhu J, Zhu Y, Ye D, et al. Incidence and risk factors for deep venous thrombosis of lower extremity after surgical treatment of isolated patella fractures. *J Orthop Surg Res.* (2021) 1(16):90. doi: 10.1186/s13018-021-02240-9

8. Meng H, Zhu Y, Zhang J, Li J, Zhao K, Zhang Y, et al. Incidence and risk factor for preoperative deep vein thrombosis (DVT) in isolated calcaneal fracture, a prospective cohort study. *Foot Ankle Surg.* (2021) 5(27):510–4. doi: 10.1016/j.fas.2020.06.007

9. Zhang W, Huai Y, Wang W, Xue K, Chen L, Chen C, et al. A retrospective cohort study on the risk factors of deep vein thrombosis (DVT) for patients with traumatic fracture at Honghui Hospital. *BMJ Open.* (2019) 3(9):e024247. doi: 10.1136/bmjopen-2018-024247

10. Bortolotti P, Faure E, Kipnis E. Inflammasomes in tissue damages and immune disorders after trauma. *Front Immunol.* (2018) 9:1900. doi: 10.3389/fimmu.2018.01900

11. Borgel D, Bianchini E, Lasne D, Pascreau T, Saller F. Inflammation in deep vein thrombosis: a therapeutic target? *Hematology.* (2019) 1(24):742–50. doi: 10.1080/16078454.2019.1687144

12. Budzianowski J, Pieszko K, Burchardt P, Rzeźniczak J, Hiczkiewicz J. The role of hematological indices in patients with acute coronary syndrome. *Dis Markers.* (2017) 2017:3041565. doi: 10.1155/2017/3041565

13. Ertem AG, Yayla C, Acar B, Kirbas O, Unal S, Uzel Sener M, et al. Relation between lymphocyte to monocyte ratio and short-term mortality in patients with acute pulmonary embolism. *Clin Respir J.* (2018) 2(12):580–6. doi: 10.1111/crj.12565

14. Qin B, Ma N, Tang Q, Wei T, Yang M, Fu H, et al. Neutrophil to lymphocyte ratio (NLR) and platelet to lymphocyte ratio (PLR) were useful markers in assessment of inflammatory response and disease activity in SLE patients. *Mod Rheumatol.* (2016) 3(26):372–6. doi: 10.3109/14397595.2015.1091136

15. Ming L, Jiang Z, Ma J, Wang Q, Wu F, Ping J. Platelet-to-lymphocyte ratio, neutrophil-to-lymphocyte ratio, and platelet indices in patients with acute deep vein thrombosis. *Vasa.* (2018) 2(47):143–7. doi: 10.1024/0301-1526/a000683

16. Peng J, Wang H, Zhang L, Lin Z. Construction and efficiency analysis of prediction model for venous thromboembolism risk in the elderly after hip

fracture. *Zhong Nan Da Xue Xue Bao Yi Xue Ban*. (2021) 2(46):142–8. doi: 10.11817/j.issn.1672-7347.2021.190722

17. Kuplay H, Erdoğan SB, Bastopcu M, Arslanhan G, Baykan DB, Orhan G. The neutrophil-lymphocyte ratio and the platelet-lymphocyte ratio correlate with thrombus burden in deep venous thrombosis. *J Vasc Surg Venous Lymphat Disord*. (2020) 3(8):360–4. doi: 10.1016/j.jvsv.2019.05.007

18. Zhu Y, Chen W, Li J, Zhao K, Zhang J, Meng H, et al. Incidence and locations of preoperative deep venous thrombosis (DVT) of lower extremity following tibial plateau fractures: a prospective cohort study. *J Orthop Surg Res*. (2021) 1(16):113. doi: 10.1186/s13018-021-02259-y

19. Zhang J, Zhao K, Li J, Meng H, Zhu Y, Zhang Y. Age over 65 years and high levels of C-reactive protein are associated with the risk of preoperative deep vein thrombosis following closed distal femur fractures: a prospective cohort study. *J Orthop Surg Res*. (2020) 1(15):559. doi: 10.1186/s13018-020-02089-4

20. Liu D, Zhu Y, Chen W, Li J, Zhao K, Zhang J, et al. Relationship between the inflammation/immune indexes and deep venous thrombosis (DVT) incidence rate following tibial plateau fractures. *J Orthop Surg Res*. (2020) 1(15):241. doi: 10.1186/s13018-020-01765-9

21. Li J, Zhu Y, Chen W, Zhao K, Zhang J, Meng H, et al. Incidence and locations of deep venous thrombosis of the lower extremity following surgeries of tibial plateau fractures: a prospective cohort study. *J Orthop Surg Res*. (2020) 1(15):605. doi: 10.1186/s13018-020-02136-0

22. Luo Z, Chen W, Li Y, Wang X, Zhang W, Zhu Y, et al. Preoperative incidence and locations of deep venous thrombosis (DVT) of lower extremity following ankle fractures. *Sci Rep*. (2020) 1(10):10266. doi: 10.1038/s41598-020-67365-z

23. Zixuan L, Chen W, Li Y, Wang X, Zhang W, Zhu Y, et al. Incidence of deep venous thrombosis (DVT) of the lower extremity in patients undergoing surgeries for ankle fractures. *J Orthop Surg Res*. (2020) 1(15):294. doi: 10.1186/s13018-020-01809-0

24. Roach RE, Lijfering WM, Rosendaal FR, Cannegieter SC, le Cessie S. Sex difference in risk of second but not of first venous thrombosis: paradox explained. *Circulation*. (2014) 1(129):51–6. doi: 10.1161/circulationaha.113.004768

25. Naess IA, Christiansen SC, Romundstad P, Cannegieter SC, Rosendaal FR, Hammerstrøm J. Incidence and mortality of venous thrombosis: a population-based study. *J Thromb Haemost*. (2007) 4(5):692–9. doi: 10.1111/j.1538-7836.2007.02450.x

26. van Hylckama Vlieg A, Helmerhorst FM, Vandenbroucke JP, Doggen CJ, Rosendaal FR. The venous thrombotic risk of oral contraceptives, effects of oestrogen dose and progestogen type: results of the MEGA case-control study. *Br Med J*. (2009) 339:b2921. doi: 10.1136/bmj.b2921

27. Canonico M, Plu-Bureau G, Lowe GD, Scarabin PY. Hormone replacement therapy and risk of venous thromboembolism in postmenopausal women: systematic review and meta-analysis. *Br Med J*. (2008) 7655(336):1227–31. doi: 10.1136/bmj.39555.441944.BE

28. Wolberg AS, Rosendaal FR, Weitz JI, Jaffer IH, Agnelli G, Baglin T, et al. Venous thrombosis. *Nat Rev Dis Primers*. (2015) 1:15006. doi: 10.1038/nrdp.2015.6

29. Wang H, Lv B, Zhang Z, Wang S, Ding W. Prevalence and predictors for preoperative deep vein thrombosis in patients with thoracolumbar fractures caused by high-energy injuries. *World Neurosurg*. (2020) 141:e431–6. doi: 10.1016/j.wneu.2020.05.162

30. Fu YH, Liu P, Xu X, Wang PF, Shang K, Ke C, et al. Deep vein thrombosis in the lower extremities after femoral neck fracture: a retrospective observational study. *J Orthop Surg (Hong Kong)*. (2020) 1(28):2309499019901172. doi: 10.1177/2309499019901172

31. Tran HA, Gibbs H, Merriman E, Curnow JL, Young L, Bennett A, et al. New guidelines from the thrombosis and haemostasis society of Australia and New Zealand for the diagnosis and management of venous thromboembolism. *Med J Aust*. (2019) 5(210):227–35. doi: 10.5694/mja2.50004

32. Imai N, Miyasaka D, Shimada H, Suda K, Ito T, Endo N. Usefulness of a novel method for the screening of deep vein thrombosis by using a combined D-dimer- and age-based index before total hip arthroplasty. *PLoS One*. (2017) 2(12):e0172849. doi: 10.1371/journal.pone.0172849

33. Wells PS, Anderson DR, Rodger M, Forgie M, Kearon C, Dreyer J, et al. Evaluation of D-dimer in the diagnosis of suspected deep-vein thrombosis. *N Engl J Med*. (2003) 13(349):1227–35. doi: 10.1056/NEJMoa023153

34. Ma J, Du P, Qin J, Zhou Y, Liang N, Hu J, et al. Incidence and risk factors predicting deep venous thrombosis of lower extremity following spinal fractures. *Sci Rep*. (2021) 1(11):2441. doi: 10.1038/s41598-021-82147-x

35. Leiherer A, Ulmer H, Muendlein A, Saely CH, Vonbank A, Fraunberger P, et al. Value of total cholesterol readings earlier versus later in life to predict cardiovascular risk. *EBioMedicine*. (2021) 67:103371. doi: 10.1016/j.ebiom.2021.103371

36. Leiba M, Seligsohn U, Sidi Y, Harats D, Sela BA, Griffin JH, et al. Thrombophilic factors are not the leading cause of thrombosis in Behçet's Disease. *Ann Rheum Dis*. (2004) 11(63):1445–9. doi: 10.1136/ard.2003.014241

37. Lord JM, Midwinter MJ, Chen YF, Belli A, Brohi K, Kovacs EJ, et al. The systemic immune response to trauma: an overview of pathophysiology and treatment. *Lancet*. (2014) 9952(384):1455–65. doi: 10.1016/s0140-6736(14)60687-5

38. Morris RS, Schaffer BS, Lundy JB, Pidcoke HF, Chung KK, Darlington DN, et al. Immunopathological response to severe injury: platelet activation and the Th-17 immune response. *Blood Coagul Fibrinolysis*. (2018) 1(29):48–54. doi: 10.1097/mbc.0000000000000665

39. Tekin YK. Are neutrophil-to-lymphocyte and platelet-to-lymphocyte ratios associated with mortality in pediatric trauma patients? A retrospective study. *Rambam Maimonides Med J*. (2019) 4(10):e0022. doi: 10.5041/rmmj.10376

40. Montoro-García S, Schindewolf M, Stanford S, Larsen OH, Thiele T. The role of platelets in venous thromboembolism. *Semin Thromb Hemost*. (2016) 3(42):242–51. doi: 10.1055/s-0035-1570079

41. Xue J, Ma D, Jiang J, Liu Y. Diagnostic and prognostic value of immune/inflammation biomarkers for venous thromboembolism: is it reliable for clinical practice? *J Inflamm Res*. (2021) 14:5059–77. doi: 10.2147/jir.S327014

42. Yao C, Zhang Z, Yao Y, Xu X, Jiang Q, Shi D. Predictive value of neutrophil to lymphocyte ratio and platelet to lymphocyte ratio for acute deep vein thrombosis after total joint arthroplasty: a retrospective study. *J Orthop Surg Res*. (2018) 1(13):40. doi: 10.1186/s13018-018-0745-x

43. Artoni A, Abbattista M, Bucciarelli P, Gianniello F, Scalambrino E, Pappalardo E, et al. Platelet to lymphocyte ratio and neutrophil to lymphocyte ratio as risk factors for venous thrombosis. *Clin Appl Thromb Hemost*. (2018) 5(24):808–14. doi: 10.1177/1076029617733039

frontiers | Frontiers in Surgery

TYPE Original Research
PUBLISHED 08 November 2022
DOI 10.3389/fsurg.2022.1035614

Check for updates

OPEN ACCESS

EDITED BY
Paphon Sa-ngasoongsong,
Mahidol University, Thailand

REVIEWED BY
Feifei Pu,
Huazhong University of Science and Technology, China
Dingjun Hao,
Xi'an Honghui Hospital, China

*CORRESPONDENCE
Baisheng Fu
fbs_1983@163.com

SPECIALTY SECTION
This article was submitted to Orthopedic Surgery, a section of the journal Frontiers in Surgery

RECEIVED 03 September 2022
ACCEPTED 18 October 2022
PUBLISHED 08 November 2022

CITATION
Sun Y, Fu Y, Liu F, Zhang W, Ma H, Li Q, Zhou D and Fu B (2022) Biomechanical tests and finite element analyses of pelvic stability using bilateral single iliac screws with different channels in lumbo-iliac fixation.
Front. Surg. 9:1035614.
doi: 10.3389/fsurg.2022.1035614

COPYRIGHT
© 2022 Sun, Fu, Liu, Zhang, Ma, Li, Zhou and Fu. This is an open-access article distributed under the terms of the Creative Commons Attribution License (CC BY). The use, distribution or reproduction in other forums is permitted, provided the original author(s) and the copyright owner(s) are credited and that the original publication in this journal is cited, in accordance with accepted academic practice. No use, distribution or reproduction is permitted which does not comply with these terms.

Biomechanical tests and finite element analyses of pelvic stability using bilateral single iliac screws with different channels in lumbo-iliac fixation

Yangyang Sun[1], Ying Fu[2], Fanxiao Liu[3], Wen Zhang[4], Huanzhi Ma[3], Qinghu Li[3], Dongsheng Zhou[3] and Baisheng Fu[3]*

[1]Department of Orthopaedic Surgery, Qilu Hospital (Qingdao), Cheeloo College of Medicine, Shandong University, Qingdao, China, [2]Shandong Center for Disease Control and Prevention, Jinan, China, [3]Department of Orthopaedic Surgery, Shandong Provincial Hospital Affiliated to Shandong First Medical University, Jinan, China, [4]Institute of Orthopedics, Soochow University, Suzhou, China

Background: In lumbo-iliac fixation, the iliac screw can be placed in several locations and directions. There is no uniform standard for the placement of a single iliac screw. Biomechanical tests and finite element analyses were used to compare the effect of bilateral single iliac screws with three channels on pelvic stability to determine the best channel.

Methods: Five embalmed adult cadaver pelvic specimens were selected. An unstable Tile C1 pelvic injury model was established. Lumbo-iliac fixation for the treatment of left sacral Denis II fracture includes the following: three channels of bilateral, single iliac screws (channel A from posterior superior iliac spine (PSIS) to anterior inferior iliac spine (AIIS), channel B from 1 cm medial and 1 cm caudal of PSIS to AIIS, and channel C from 2 cm below PSIS to AIIS). Biomechanical testing was performed for stiffness evaluations. A finite element model was established to study the stress distribution of the model and the maximum von Mises stress of internal fixation.

Results: Biomechanical tests revealed that under vertical compression loading. The compressive stiffness fixed by channel B (246.15 $\pm$ 27.85 N/mm) was better than that fixed by channel A and channel C. Under torsional load, the torsional stiffness fixed by channel B (2.234 $\pm$ 0.223 N·m/°) was stronger than that fixed by channel A and channel C. However, there was no significant difference in terms of compressive and torsional stiffness between channel B and channel A ($P > 0.05$). Finite element analyses conformed that the maximum von Mises stress of the internal fixator fixed in channel B under the conditions of vertical, forwards bending, backwards extension, left bending, left rotating, and right bending (213.98 MPa, 338.96 MPa, 100.63 MPa, 297.06 MPa, 200.95 MPa and 284.75 MPa, respectively) was significantly lower than those fixed in channel A and channel C.

Conclusions: The construct stiffness of the channel from 1 cm medial and 1 cm caudal of PSIS to AIIS is better than that of the other two channels. This channel has the advantages of good biomechanical stability, small maximum von Mises stress of internal fixation.

KEYWORDS

lumbo-iliac fixation, biomechanical tests, pelvic, finite element analyses, internal fixation

Introduction

Sacral fractures often caused by high energy injuries, such as car accidents and falls, account for 17%–30% of pelvic fractures (1) and are commonly accompanied by fractures of other bones, nerve injury and internal organ injury (2). The main reason for disability and dysfunction in the later period of patient recovery is lumbosacral plexus injury (3). The treatment of spinal-pelvic separation caused by complex sacral fractures is complicated. Failure to perform adequate fixation will seriously affect the stability of the posterior pelvic ring and lumbosacral region. Iliolumbar fixation has become a reliable fixation method (4). Kách et al. (5) reported for the first time that five patients with unstable longitudinal vertical fractures of the sacrum (Denis II or III fractures) were treated with an L5 pedicle screw combined with iliac screw fixation. The follow-up results showed that the internal fixation was reliable. Schildhauer et al. (6) proposed a triangular fixation technique that combined a spinal-pelvis fixation system with sacroiliac screw fixation.

In lumbo-iliac fixation, the screw-rod connection system is very flexible. The iliac screw can be placed in many locations and directions, and multiple screws can be placed to enhance the fixation effect. There were multiple anchoring channels during iliac screw fixation: from PSIS to the iliac crest (7), from PSIS to AIIS (8, 9), from 1 cm medial and 1 cm caudal of PSIS to AIIS (10), from 2 cm below PSIS to AIIS (11), and from posterior inferior iliac spine (PIIS) to AIIS (12). At present, there is no uniform standard for the placement of iliac screws, nor has the biomechanical effect of bilateral single iliac screws with different channels on pelvic stability been explored.

According to a study of biomechanical conduction and mechanical distribution, the fixation strength of iliac screws in the lower column of iliac bone was higher than that in the upper column of iliac bone (13). The most commonly used channel in the clinic is from PSIS to AIIS. Many scholars believe this channel can insert into the iliac screw with the maximum length and diameter. Biomechanical studies mostly used this channel for experimental research (13, 14). However, the clinical application of iliac screws through this channel is prone to induce complications such as local skin necrosis caused by the protrusion of the implant, which may cause serious consequences, such as incision infection and the exposure of the implant (15). During the operation, part of the bone of the PSIS needs to be removed. Harrop et al. (10) proposed a modified iliac screw fixation technique that used PSIS 1 cm medial and 1 cm caudal to AIIS. It was pointed out that the modified channel was more convenient and practical in clinical application than the "traditional" channel and had fewer complications. It has been suggested that the advantages of this modified iliac screw channel are due to the proximity of the screws to the midline, eliminating the need for additional connectors and special bent rods during surgery, and the safety of the procedure due to its location on the medial side of the iliac crest, which eliminates the need to remove part of the posterior superior iliac spine bone (16). Schwend et al. (11) proposed a channel from 2 cm below PSIS to AIIS. Through autopsy and biomechanics, it was confirmed that the mechanical strength of the iliac screw in this channel was more than three times that of the traditional Galveston system. Tian et al. (12) found that the channel from PIIS to AIIS was below or just on the edge of the sciatic notch in approximately 61.1% of Asian pelvic specimens. There was the possibility of nerve injury. The authors pointed out that iliac screw placement in this channel was not recommended.

This study aimed to compare the effect of bilateral single iliac screws with three channels on pelvic stability in lumbo-iliac fixation using biomechanical tests and finite element analyses. First, a pelvic Tile C1 injury model was constructed: pubic symphysis separation and Denis II fracture of the left sacrum. Second, lumbo-iliac fixation for pelvic instability injuries and bilateral single iliac screws with three channels: channel A from PSIS to AIIS, channel B from 1 cm medial and 1 cm caudal of PSIS to AIIS, channel C from 2 cm below PSIS to AIIS. Third, biomechanical tests and finite element analyses were used to analyse the biomechanical mechanism and determine the best iliac screw placement channel to provide a scientific basis for practical and successful clinical application.

Methods

Preparation of pelvic specimens

The study protocol (2017GSF18112) was approved by the Ethics Committee of Shandong Provincial Hospital. Five adult embalmed cadaveric pelvic specimens (stored in a 10% formalin solution for two weeks and provided by the Department of Anatomy, Shandong First Medical University) were selected, including three males and two females, aged 42–58 years old, with an average age of 48.2 years old. The cadaver was separated at the L2–L3 joint and at 10 cm distal of the acetabulofemoral joint (**Figure 1**). Pelvic fracture, tumour, forced spondylitis, sacroiliac sclerosis, rheumatoid arthritis and other diseases were excluded by examination, and specimens proven to have osteoporosis using an osteocore 3 dual energy x-ray osteodensitometer (Medilink Company, Parc de la Mediterranee, France) were excluded (**Table 1**). Specimens were wrapped in double plastic bags and stored at −20°C. The specimens were thawed at room temperature. Skin, muscle, fat, and other tissues were removed. The complete pelvic bone, ligament structure, and hip joint were retained. The ligament structure mainly included the

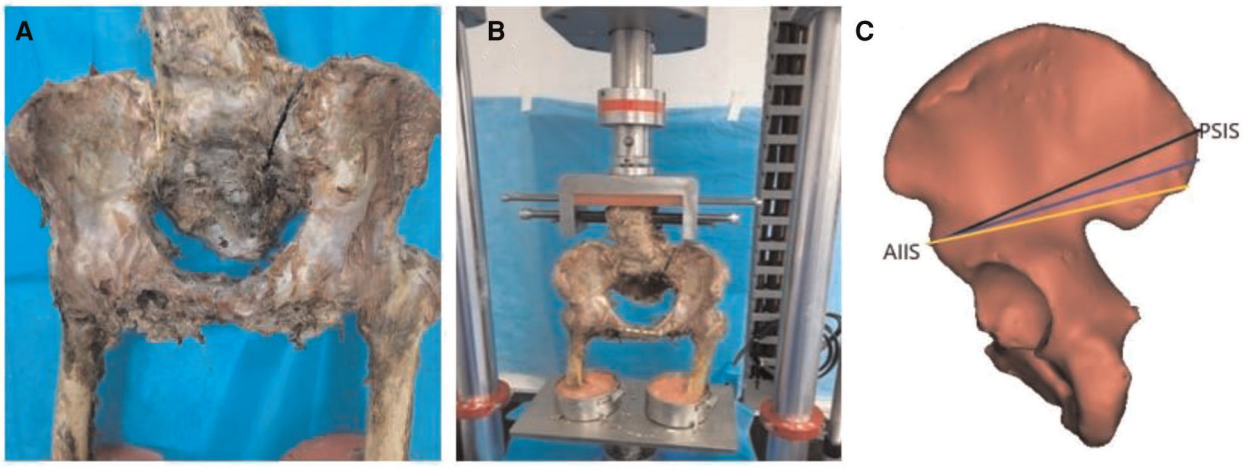

FIGURE 1
(A) An unstable tile C1 type injury (pubic symphysis separation and left sacral Denis II fracture) of pelvis specimen; (B) Frontal view of pelvic injury model (pubic symphysis fixed with a five-hole reconstruction plate and pelvic posterior ring injury treated by lumbo-iliac fixation) and biomechanical testing machine; (C) Three channels of single iliac screws.

suprapubic ligament, pubic arch ligament, posterior sacroiliac ligament, anterior sacroiliac ligament, interosseous sacroiliac ligament, and hip joint accessory ligament. The upper and lower ends of the specimens were embedded with methyl methacrylate-polymer resin to enable fixation to the mechanical testing machine.

Establishment and fixation of the pelvic tile C1 injury model

After cadaver slippage was eliminated, experimental results from biomechanics testers of complete pelvis specimens were used as a control group. Then, the pubic symphysis was cut with an electric saw, and a left sacral Denis II fracture (sacral foramina fracture) (6) was established (Figure 1). Professor Baisheng Fu subsequently performed a series of surgical procedures. Anatomical reduction of the pelvic fracture was performed. A five-hole reconstruction plate was used to fix the separated pubic symphysis. The lumbo-iliac fixation was done for the treatment of unstable posterior pelvic ring injury. Lumbo-iliac fixation was completed with the L4 and L5 pedicle screws (6.5-mm diameter, 45-mm long) and iliac screws (7.5-mm diameter, 80-mm long), Medtronic-WeiGao Inc., WeiHai, China). The pedicle screws were laterally straight and parallel to the vertebral endplate. The bilateral single iliac screws were entering from three channels including channel A from PSIS to AIIS, channel B from 1 cm medial and 1 cm caudal of PSIS to AIIS, and channel C from 2 cm below PSIS to AIIS (Figure 1), and a 7-mm ball tip feeler was inserted into the channel to ensure its completion. Subsequently, 7.5-mm diameter iliac screws were placed. Finally, L4–L5 pedicle screws and iliac screws were connected by a curved rod, and a cross-link was fixed between the L5 pedicle screws and the iliac screws.

TABLE 1 General information on pelvic specimens and sequence of internal fixation.

Sequence number	Age (years)	Bone mineral density (*T* score)	Sequence of fixation
1	42	0.3	Channel A—channel B—channel C
2	50	0.2	Channel A—channel C—channel B
3	46	0.3	Channel B—channel C—channel A
4	58	0.2	Channel C—channel B—channel A
5	45	0.3	Channel B—channel A—channel C

Biomechanical tests

The pelvic specimens were fixed on the special fixture of the American E10000 material mechanics testing machine (provided by the Institute of Orthopaedics, Soochow University) (Figures 1, 2). The L3 vertebral body was kept in a horizontal state during the experiments. The bilateral anterior superior iliac spine and pubic symphysis were placed in the same coronal plane to simulate the force on the pelvis when standing. The compression load of the L3 vertebral segment was 0–500 N (17), and the stress load speed was

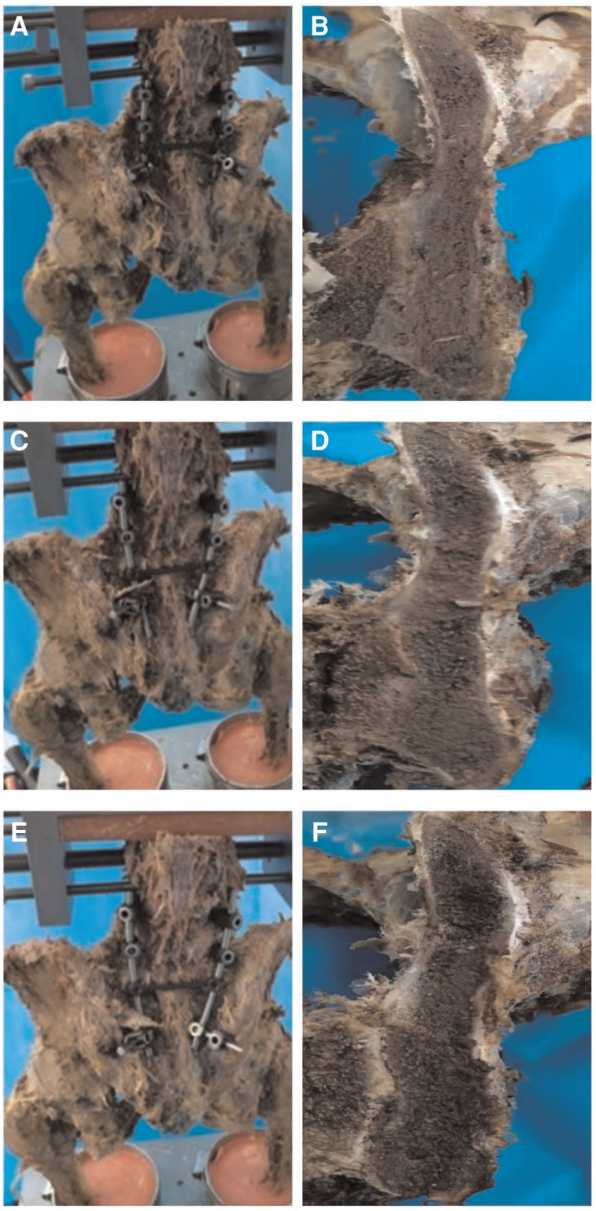

FIGURE 2
(A) Placed iliac screw from PSIS to AIIS. (B) Cross-sectional view of the channel from PSIS to AIIS. (C) Placed iliac screw from 1 cm medial and 1 cm caudal of PSIS to AIIS. (D) Cross-sectional view of the channel from 1 cm medial and 1 cm caudal of PSIS to AIIS. (E) Placed iliac screw from 2 cm below PSIS to AIIS. (F) Cross-sectional view of the channel from 2 cm below PSIS to AIIS.

3 mm/min through the upper loading connector. The analysis software Bluehill 2.0, provided by the mechanical testing machine, automatically recorded the load–displacement curve and calculated the compressive stiffness (N/mm). Three channels needed to be tested on each specimen, one channel was randomly selected for 3 consecutive measurements, and the next channel was also tested 3 times before proceeding until all three channels were measured and the results were averaged. After each test cycle was completed, the pelvic specimen was thoroughly inspected, and we observed that the internal fixators did not loosen or break. The next channel test was randomly carried out. In the torsional load experiment, a 6 N·m torsional load was applied to the specimen through the rotational axis. The torque-torsional angle curve was automatically recorded by WaveMatrix software, and the torsional stiffness (N·m/°) was calculated. Similarly, each specimen was tested three times, and the average rotation angle was calculated. Normal saline was sprayed regularly to keep the specimen moist during the experiment.

Finite element injury models and finite element analyses

One normal adult male volunteer (48 years old, 175 cm, 70 kg) was recruited. The study protocol was approved by the Ethics Committee of Shandong Provincial Hospital. The volunteer agreed with written informed consent. The radiographic data of the lumbar spine, pelvis, and femur were obtained by CT scan (Siemens Spiral CT, Germany, 0.625 mm slice thickness, 0.625 mm the interval and 512 * 512 the pixel) and imported into Mimics 21.0 (Materialise, Belgium) in Dicom format. Then, these files were processed by Geomagic Studio 12.0 (Geomagic, USA). Pro/Engineer 5.0 (PTC, USA) and Hypermesh 2017 (Altair, USA) were used to draw the iliac screw, pedicle screw, longitudinal rod, connector, transverse connecting rod, reconstruction plate, screw, etc. The material properties and characteristics, Young's modulus, and the structure of the model ligament were set. The three-dimensional finite element model of the L4 pelvic-proximal femur, pedicle screw, and iliac screw were imported into Ansys 19.0 (SASI, USA) for finite element analyses (**Figure 3**). The finite element model included the lumbar (L4 and L5), pelvis, and proximal femur. The full pelvis was composed of the left ilium, sacrum, right ilium, and pubic symphysis, and these bones consisted of cortical bone and cancellous bone. The anterior sacroiliac, interosseous sacroiliac, posterior sacroiliac, sacrotuberous, and sacrospinous ligaments were also created to simulate normal conditions. Between the plate-screw, screw-connecting rod was established as a whole, there was no universal movement. The binding constraint between screw and bone was established by coupling. Linear elastic isotropic material properties were used, and the properties of the bones and ligaments are shown in **Table 2** (17–19). To validate the reasonableness of the model, the present model was compared with the experimental data of previous scholars (20–22). Model was subjected to 500 N concentrated force and 10 N·m moment, and its range of motion (ROM) was measured under four

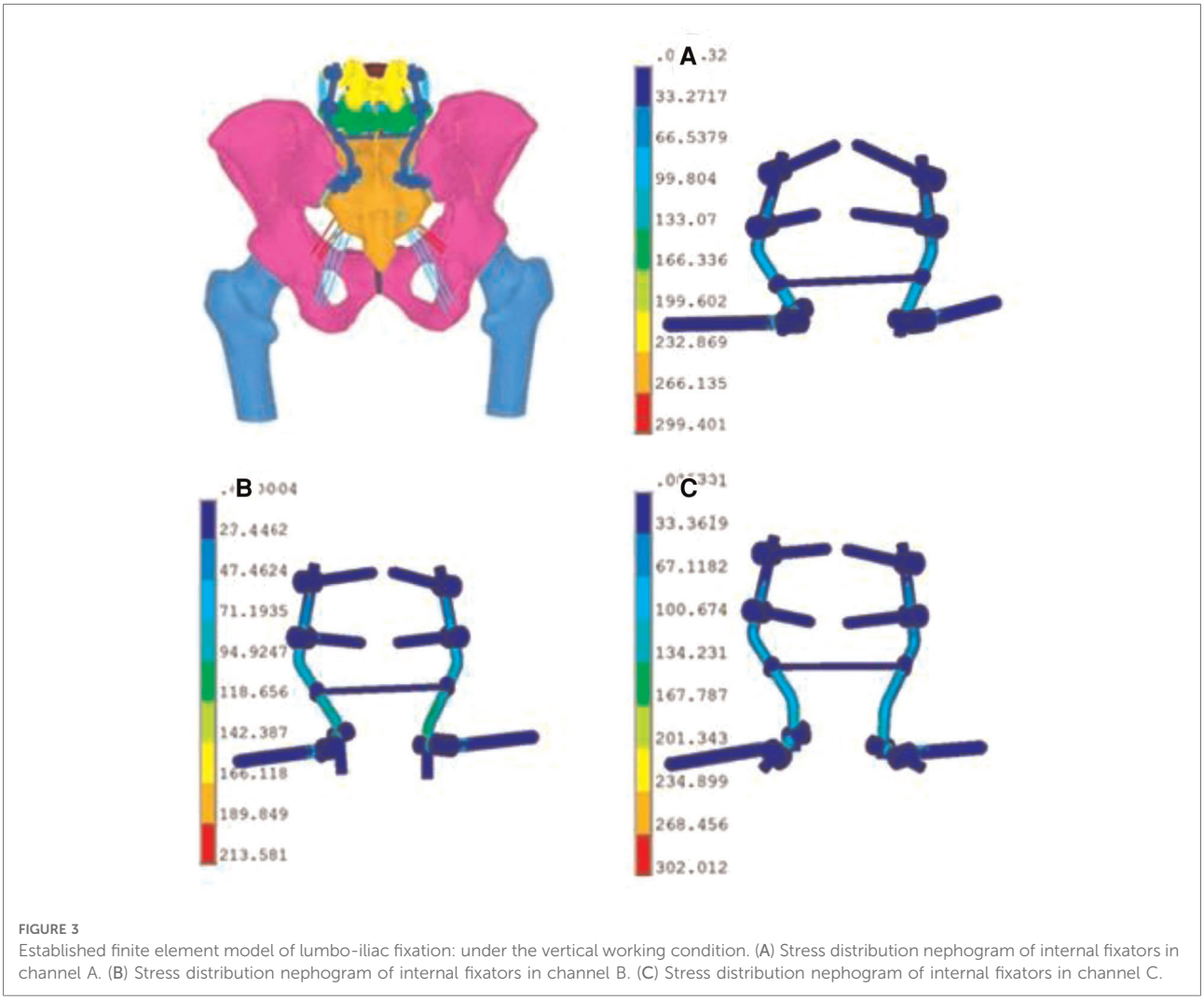

FIGURE 3
Established finite element model of lumbo-iliac fixation: under the vertical working condition. (A) Stress distribution nephogram of internal fixators in channel A. (B) Stress distribution nephogram of internal fixators in channel B. (C) Stress distribution nephogram of internal fixators in channel C.

states of motion: flexion, extension, lateral bending, and axial rotation. It was concluded that the ROM of model was in good agreement with the results of other scholars' studies, which proved the validity of this experimental model. Similarly, the pelvic Tile C1 injury model (pubic symphysis separation, left sacral Denis II fracture) was established. Simultaneous 5-hole reconstruction plate fixation of the pubic symphysis and lumbo-iliac fixation for posterior pelvic ring surgery. Finite element analyses were used to explore the biomechanical characteristics of the bilateral single iliac screws, divided into three channels: channel A from PSIS to AIIS, channel B from 1 cm medial and 1 cm caudal of PSIS to AIIS, channel C from 2 cm below PSIS to AIIS. The number of elements for implants was 1,713,729 for channel A, 1,715,997 for channel B, and 1,713,492 for channel C. The number of nodes for implants was 2,794,487 for channel A, 2,798,784 for channel B, and 2,795,149 for channel C. The standing state of the human body was simulated, and the boundary conditions were set at the bilateral femoral ends. A 500 N vertical downwards load was applied to the upper surface of the L4 vertebral body, and torque in different directions of 10 N·m was applied to simulate the working conditions of flexion, extension, lateral bending, and rotation. Finite element software obtained the stress nephogram, displacement nephogram, and deformation nephogram of the internal fixation, vertebral body, and iliac bone. The maximum von Mises stress of internal fixation and the maximum von Mises stress of the vertebral body and ilium in different channels were then compared.

Statistical methods

The maximal compressive displacement and torsional angle were obtained. The following formulas were used to calculate the compressive and torsional stiffness of the fixation construct:

TABLE 2 The properties of material used in finite element model.

Material	Youngs modulus (MPa)	Poisson's ratio *U*	*K* (N/mm)
Cortical bone (vertebral body)	12,000	0.3	
Cancellus bone (vertebral body)	345	0.2	
Posterior element (vertebral body)	3,500	0.3	
Cortical bone (ilium)	17,000	0.3	
Cancellus bone (ilium)	132	0.2	
Cortical bone (sacrum)	6,140	0.3	
Cancellus bone (sacrum)	1,400	0.3	
Symphysis pubis	5	0.45	
Articular cartilage	100	0.3	
Plates (titanium alloy)	110,000	0.3	
Screws (titanium alloy)	110,000	0.3	
Sacroiliac posterior long ligament			1,000
Sacroiliac posterior short ligament			400
Sacroiliac anterior ligament			700
Sacrotuberous ligament			1,500
Sacrospinous ligament			1,400

Compressive stiffness = 500 (N)/maximum compressive displacement (mm)

Torsional stiffness = 6 (N·m)/maximum torsional angle (°)

SPSS software (version 20.0; Chicago, IL, USA) was used for the statistical description and analysis of the experimental results ($n = 5$). The measurement data are expressed as the mean ± standard deviation (SD). One-way analysis of variance was used for comparisons between groups. The least significant difference method was used for pairwise comparisons. The difference was statistically significant when $P < 0.05$.

Results

Biomechanical tests

After the unstable pelvic ring injury model was fixed with three channels of bilateral single iliac screws, the overall displacement of pelvic specimens under a 500 N vertical load was greater than that of complete pelvic specimens (1.852 ± 0.104 mm), and the difference was statistically significant ($P < 0.05$) (Table 3). The vertical displacement fixed by channel B (2.054 ± 0.248 mm) was smaller than that fixed by channel A and channel C (2.153 ± 0.175 mm and 2.370 ± 0.167 mm, respectively), and the difference in the vertical displacement fixed by channel B and channel A was not statistically significant ($P > 0.05$). The compressive stiffness of the bilateral single iliac screws in the three channels was significantly lower than that of the intact pelvic specimens (270.7 ± 15.38 N/mm), and the difference was statistically significant ($P < 0.05$) (Table 3). The compressive stiffness of channel B (246.15 ± 27.85 N/mm) was greater than that of channel A and channel C (233.43 ± 18.5 N/mm and 211.79 ± 14.58 N/mm, respectively), but there was no significant difference between channel B and channel A ($P > 0.05$). The compressive stiffness of channel A and channel C was significantly different from that of complete pelvic specimens ($P < 0.05$).

The overall torsional angle of pelvic specimens fixed with three channels of bilateral single iliac screws under a 6 N·m torsional load was greater than that of the complete pelvic specimens (2.419 ± 0.176°), and the difference was statistically significant ($P < 0.05$) (Table 4). The torsion angle of pelvic specimens fixed by channel B (2.708 ± 0.280°) was less than that of pelvic specimens fixed by channel A and channel C (2.973 ± 0.274° and 3.411 ± 0.197°, respectively), and there was no significant difference between channel A and channel B. The torsional stiffness of the bilateral single iliac screws with three channels was significantly lower than that of the complete pelvic specimen (2.491 ± 0.184 N·m/°) ($P < 0.05$). The torsional stiffness of channel C (1.764 ± 0.101 N·m/°) was

TABLE 3 Vertical displacement and compressive stiffness of pelvic specimens under 500 N (mean ± SD).

					P Value					
	Control Group	Channel A	Channel B	Channel C	Control Group vs. A	Control Group vs. B	Control Group vs. C	A vs. B	A vs. C	B vs. C
Displacement (mm)	1.852 ± 0.104	2.153 ± 0.175	2.054 ± 0.248	2.370 ± 0.167	0.011*	0.132	<0.01*	0.48	0.079	0.045*
compressive stiffness (N/mm)	270.7 ± 15.38	233.43 ± 18.5	246.15 ± 27.85	211.79 ± 14.58	0.009*	0.123	<0.01*	0.42	0.074	0.04*

*Indicated statistically significant.

TABLE 4 Torsional angle and torsional stiffness of specimens under a torsional load of 6 N·m (mean ± SD).

					P Value					
	Control Group	Channel A	Channel B	Channel C	Control Group vs. A	Control Group vs. B	Control Group vs. C	A vs. B	A vs. C	B vs. C
Torsional angle (°)	2.419 ± 0.176	2.973 ± 0.274	2.708 ± 0.280	3.411 ± 0.197	0.005*	0.086	<0.001*	0.169	0.019*	0.001*
Torsional stiffness (N·m/°)	2.491 ± 0.184	2.032 ± 0.187	2.234 ± 0.223	1.764 ± 0.101	0.004*	0.081	<0.001*	0.159	0.022*	0.003*

*Indicated statistically significant.

smaller than that of channel A and channel B ($P < 0.05$) (Table 4). There was no significant difference in torsional stiffness between channel A (2.032 ± 0.187 N·m/°) and channel B (2.234 ± 0.223 N·m/°) ($P > 0.05$).

Finite element analyses

In terms of the overall stress distribution nephogram, the maximum von Mises stress was shown on the internal fixator. There was a large stress concentration in the iliac screw, connector and longitudinal rod, so that the tail of the iliac screw and the surroundings of the connector were more pronounced (Figure 3). The maximum von Mises stress of the internal fixator fixed in channel B under the working conditions of vertical, forwards bending, backwards extension, left bending, left rotation and right bending (213.98 MPa, 338.96 MPa, 100.63 MPa, 297.06 MPa, 200.95 MPa, 284.75 MPa, respectively) were significantly lower than that fixed in channel A and channel C (Figure 4, Table 5). Similarly, under various working conditions, the maximum von Mises stress of the internal fixator of channel B was less than that of channel A (Figure 4). Under the vertical condition, the maximum von Mises stress of the internal fixator in channel B was 71.4% of that in channel A. Under the left rotation condition, the maximum von Mises stress of the fixator channel B was only 65.9% of that in channel A. This showed that the maximum von Mises stress of the fixator in channel B was the smallest, the fatigue resistance was strong, and the fixator was less prone to broken screws.

Under the working conditions, except extension, the maximum von Mises stress of the vertebral body was as follows: channel A < channel B < channel C. In terms of the maximum von Mises stress of the iliac, under the conditions of upright, forwards bending, and left bending and right rotation, channel A maximum was > channel B. The results showed that the overall stress distribution of channel B was more reasonable.

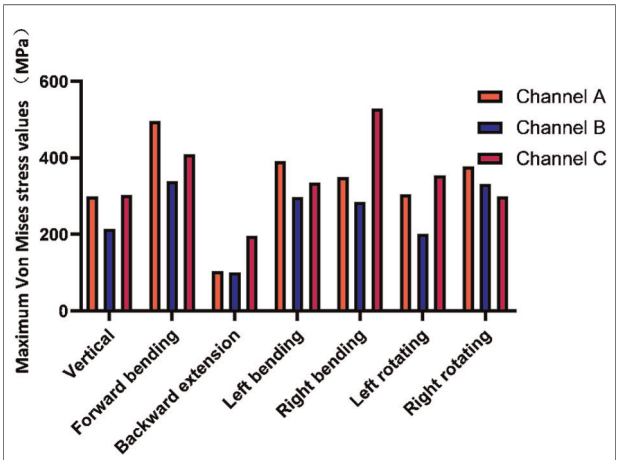

FIGURE 4
Maximum von mises stress of internal fixation with three channels.

TABLE 5 Maximum von mises stress of internal fixation with three channels (MPa).

	Channel A	Channel B	Channel C
Vertical	299.4	213.98	302.01
Forward bending	496.16	338.96	408.96
Backward extension	103.05	100.63	195.73
Left bending	390.56	297.06	335.09
Right bending	349.19	284.75	528.56
Left rotating	304.91	200.95	354.27
Right rotating	377.97	331.35	298.72

Discussion

Spinal-pelvic fixation can treat many complications of trauma surgery and spinal surgery (23) by aiming to rebuild the stability of the spine and pelvis in cases such as traumatic spinal pelvic separation ("H or U"-shaped fractures of the sacrum, etc.), complex sacral comminution fractures, sacrum fracture complicated with nerve injury, spinal protrusion deformity, sacrum tumour, tuberculations of the lumbar and

sacrum, severe lumbar spondylolysis, and scoliosis combined with pelvic tilt. Lumbo-iliac fixation for treating U-type sacral fractures has been reported in many studies, and this treatment can provide multiplanar stability (24, 25). Fujibayashi et al. (26) used iliolumbar fixation for palliative treatment of destructive sacral tumours and achieved satisfactory clinical efficacy. The authors pointed out that this fixation method could increase the stability of the lumbosacral region. Ebata et al. (27) applied the spinal-pelvic fixation system in adult spinal deformity correction and achieved satisfactory results. By finite element analysis, Song et al. (19) compared the biomechanical characteristics between bilateral and unilateral lumbo-iliac fixation in unilateral comminuted sacral fractures. The results revealed that the stability of unilateral lumbo-iliac fixation was insufficient to reconstruct the posterior pelvic ring. Furthermore, unilateral fixation may lead to an imbalance of the lumbar vertebra and pelvis. In contrast, bilateral lumbo-iliac fixation could provide satisfactory stability and lumbar balance. Therefore, bilateral lumbo-iliac fixation was selected in this study, and the finite element results showed that the stress distribution nephograms of L4 and L5 and the acetabulum and femur were balanced. Because the fracture line was on the sacrum, the stress distribution in the sacrum was uneven. The results were consistent with those of Song et al. (19).

Certainly, if we opt for incisional repositioning of the bilateral lumbo-iliac fixation, then there are problems to keep in mind, such as a longer operating time, higher amounts of bleeding and surgical trauma. These problems are also independent risk factors for the occurrence of postoperative infection. In some cases, when we specify the optimal channel for placement of the iliac screw in lumbo-iliac fixation, we can use a smaller incision and minimally invasive techniques to treat the fractures. Futamura et al. (28), Koshimune et al. (29), and Okuda et al. (30) used small incisions and minimally invasive lumbo-iliac fixation to reduce the risk of skin and soft tissue injury and infection and improve the healing rate of fractures.

In lumbo-iliac fixation, L4–L5 fixation was performed with pedicle screws in this study. Long fusion offers better mechanical stability and bone fusion. However, this inhibits the patient's range of motion during the postoperative period. Schildhauer et al. (31) and Shen et al. (32) suggested fusion from L4 to the pelvis. Concerning patients after total sacrectomy, Zhang et al. (33) recommended reconstruction from L3 to the pelvis. In sacral tumour patients, Acharya et al. (34) executed L4-iliac fusion and screw-rod instrumentation using the bilateral dual iliac screw technique. All these reports indicated that patients could achieve a good result after reconstruction.

The iliac screw technique in spine-pelvis fixation has been widely used, and reliable lumbar and pelvis stability has been obtained clinically (9). There are many options for iliac screw placement sites and channels. The iliac screw technique theoretically fixes the length behind the iliac bone to the maximum extent so that the strength of the screw fixation is the strongest, and the prominence of the internal fixation is avoided. At present, it is not clear which channel of the iliac screw is best for fixation. In addition, Miller et al. (35) studied the anatomy of cadaver pelvic specimens. They believed that when the length of the inserted iliac screw located in the channel from PSIS to AIIS reached 100 mm, there was a 25% probability of penetrating the acetabulum and entering the joint. Therefore, they suggested that the length of the iliac screw should be less than 90 mm. Moshirfar et al. (36) performed a retrospective analysis of the literature on the clinical application of iliac screws. They believed that for high effectiveness and safety, the length of iliac screws should be greater than 80 mm, and the diameter should be 7.5 mm. Therefore, the use of iliac screw lengths ranging from 70 mm (above the level of the greater sciatic notch) to 90 mm has become a clinical consensus. In this study, the iliac screw was 80 mm in length and 7.5 mm in diameter, and all iliac screws were within the iliac channel and did not exceed the total length or diameter of the channel.

This study determined the biomechanical differences of three channels of bilateral single iliac screws in the inferior iliac column. Compared with previous biomechanical studies, such as sacroiliac screws, posterior ring tension band plates and sacrum rods (37, 38), this study showed that three channels of bilateral single iliac screws in lumbo-iliac fixation could effectively restore the stability of the reconstructed pelvis. The compressive stiffness of channel A was 86.2% of that of the complete pelvis, the compressive stiffness of channel B was 90.9% of that of the complete pelvis, and the compressive stiffness of channel C was 78.2% of that of the complete pelvis. The biomechanical experimental method of cadaveric specimens could clearly show the displacement of the pelvic specimen model and the structural rigidity of the internal fixator after fixation. However, the experimental results were susceptible to many factors, such as specimen quality, specimen source, specimen difference, theoretical knowledge of the tester, and the operation level of the tester, etc. The choice of specimen damage model has a great influence on biomechanics. Zheng et al. (14) studied the effect of iliac screw insertion depth on the stability and strength of lumbo-iliac fixation constructs and concluded that after total sacrectomy, the lumbo-pelvic reconstruction using short and long iliac screws restored 53.3% and 57.6% of the initial stiffness in compression testing, respectively. Yu et al. (13) studied that in compression, the stiffness of the L3-iliac fixation constructs of Single-Short, Single-Long were 73% and 76% of the intact state, respectively, and more segments of the lumbar spine were selected for fixation. Wu et al. (17) performed biomechanical studies of three kinds of internal fixation for the treatment of sacroiliac joint disruption using

biomechanical test and finite element analysis, and under a vertical load of 500 N, the average displacements of the pelvis fixed with an anterior plate were the largest one (4.704 ± 0.600 mm). The value of the pelvis fixed with two sacroiliac screws was in the middle (3.128 ± 0.519).

According to the pelvic specimens' compressive and torsional stiffness, there was no significant difference between channel B and channel A. Still, the results of channel B fixation were greater than those of channel A fixation. We believe this is due to the fixed distance between channel A and channel B being incredibly close, with both of them being close to the standard mechanical conduction path. The fixed strength of channel B is better than that of channel A. The study also showed that the construct stiffness of channel C was the worst. The fixed position of channel C is lower. When the pelvic specimen is in a standing position, the normal force conduction path is higher than the fixed position of channel C, resulting in a sizable vertical displacement of the pelvis and a weakened fixation strength. When the human body is sitting, the standard mechanical conduction path moves down, making the fixation of channel C close to normal and having a high fixation strength. However, we did not perform a sitting-time biomechanical test, and this interpretation requires further confirmation.

In this study, specimens stored in a 10% formalin solution for two weeks were used. The use of formalin-fixed bones for biomechanical investigations is controversial, because formalin fixation is thought to change the biomechanical properties of bone. No evidence for changes in bone density (39), bone mineral density (40), crystallinity of the bone apatite (41) or the histological structure and quality of soft tissues (42, 43) have been observed as a result of formalin fixation. However, aldehydes (e.g., formaldehyde) affect a significant number of inter- and intrafibrillar crosslinks in collagen molecules (44) and therefore can influence the biomechanical behaviour of bone. A small number of biomechanical studies focusing on the effects of formalin fixation on the biomechanical properties of animal bone have been published. Studies using human bones are rare. Moreover, these studies are hard to compare because of different fixation methods, fixation duration and different test set-ups. Currey et al. (45) found that fixing bovine bone in a 10% formalin solution for 3 h slightly but significantly increased the bending Young's modulus (+2%) and largely decreased the impact energy (−46%). Goh et al. (46) performed torsion tests on cat humeri and four-point bending tests on cat femora. Specimens were stored in a 10% formalin solution for 3 or 21 days. It was found that the formalin preservation did not alter the ultimate load and stiffness, but largely reduced the energy absorption capacity. Furthermore, no significant differences were found between the specimens fixed for 3 and 21 days. Sedlin and Hirsch (47) tested cortical specimens from a human femur in tension. The specimens were elastically tested, then placed in a 10% formalin solution for 3 weeks and thereafter retested. The Young's modulus was determined and no significant difference was found between the two testing occasions. Burkhart et al. (48) compare axial and torsional stiffness and bone mineral density in fresh and embalmed human bones (preserved in 4% formalin solution for 6 weeks). The formalin group showed significant higher stiffness values for torsional and axial loads than the fresh group. These differences were not reflected in bone mineral density values. Therefore, we considered the results of the selected specimens to be credible.

This study simulates the vertical displacement of a specimen in a normal human body in a bipedal stance with a vertical load of 500 N. The vertical load of 500 N is approximately the weight of the upper body (17). A systematic review of the literature found that there was no homogeneous criterion for the magnitude of torsional load. Some researchers used 7.5 Nm (49) and 8 Nm (14), while others applied torsional moments from 0 to 5, 10, 15, and 20 Nm (50). We chose 6 N·m torsional load within a reasonable range. This justified is *via* biomechanics, so 500 N compression load and 6 N·m torsional load can be used for biomechanical studies of pelvic stability in the experiment work. And the experimental results are also plausible. In addition, due to the small number of cadaver specimens, individual differences, and multiple biomechanical tests performed by multiple internal fixation methods in the same specimen, etc, these factors affect the results of biomechanical experiments. And the use of cadaver specimens for biomechanical experiments, the specimen consumption damage. The greater the torque, the greater the damage to the specimen.

Finite element analysis has been widely used in the field of medical research. It is primarily based on the digital model of evaluating the immediate stability of the body's internal fixation stability (overall stability and local stability), the body's stress distribution nephogram and rigid structure, the maximum von Mises stress and stress distribution nephogram of internal fixation and the stress distribution of the adjacent structures (51). Comprehensive and accurate results can be obtained without huge cost and repeatable experiments without wasting injury on samples. Besides, stress changes and stress distribution of internal fixation instruments before and after surgical fixation can also be predicted and analyzed. It has the advantage that traditional cadaver specimen biomechanical experiment does not have. Yamamoto et al. (20) studied three-dimensional movements of the whole lumbar spine and lumbosacral joint. From preliminary experiments, 10 N·m was judged to be sufficient to produce maximum physiologic motions, but small enough not to injury the specimen. Later, many scholars studied torque at 10 N·m (20–22). Therefore, we chose a torque of 10 N·m in the finite element analysis.

In this study, the results showed that the maximum von Mises stress of the model shown on the internal fixation was the largest, followed by the vertebral body, while the

maximum von Mises stress of the iliac bone was the smallest. The stress of the internal fixation device should not be excessively concentrated at a certain point in order to avoid a fracture of the screw rod system due to excessive stress concentration (37). In addition, a standard reflecting the safety performance of the internal fixation device is the maximum stress it bears. After applying the load, the greater the maximum stress of the internal fixation is, the greater the possibility of complications such as broken screws and broken rods and the failure of the fixation device. This study showed that the iliac screw, connector, and longitudinal rod had high stress concentrations. The stress nephogram of the internal fixation showed that the maximum von Mises stress was mainly concentrated on the tail of the iliac screw and around the connector, which was the position where the screw-rod system was prone to fracture in the spine-pelvic fixations. In addition, the maximum von Mises stress of internal fixation in channel B under all the conditions was smaller than that in channel A. The maximum stress value of internal fixation in the C channel was the largest of the three channels. The results showed that the stress distribution of channel B was scattered, the maximum von Mises stress of the internal fixation was small, and the fatigue resistance was strong.

An important criterion for evaluating surgical quality is the stress on the intervertebral disc after the operation. The greater the maximum stress on the intervertebral disc is, the more likely it will lead to degenerative changes of the intervertebral disc and symptoms such as low back pain (52). In all conditions except extension, the maximum von Mises stress of the vertebral body: channel A fixation was less than channel B fixation, and channel B fixation was less than channel C fixation. The maximum stress of the iliac bone fixed by channel A was greater than that of the iliac bone fixed by channel B under the conditions of upright, flexion, left bending and right rotation. The results showed that the overall stress distribution of the channel B fixation model appeared to be more reasonable.

There were some defects in this study. First, cadaver specimens were used for biomechanics, the number of specimens was small, and there were differences among specimens. Multiple fixation devices have been tested on the same specimen. Still, the influence between the fixation devices before and after fixation could not be eliminated, and errors could not be avoided. To avoid specimen destruction from numerous testing steps, 3 cycles of physiologic compression and torsion loading were performed and recorded for each type of channel fixation. At the same time, we analysed the recorded data, and if there was too much difference between the data, we discarded the unreasonable data and conducted the test again. The use of fresh, frozen cadaver specimens can provide first-hand clinical information. However, due to the limitation of sample size, source of cadaver specimens, and research funding, we were unable to use them in this study. We will use fresh, frozen cadaveric specimens in future studies to further validate our conclusions. In addition, the limited conditions in our orthopedic laboratory and the lack of specialized radiological equipment made it impossible to assess preoperative and postoperative pelvic fracture displacement from radiographic images (x-ray) at that time. At the end of the biomechanical experiments, the specimens were osteotomized to observe the integrity of each channel. Second, the establishment of the finite element model involved many aspects, and there was a disparity between the constructed pelvic model and the cadaveric pelvises. The assignment of bone material properties is a complex problem to solve, and at present, the characteristics of bone heterogeneity and anisotropy cannot be well simulated. At the same time, this study did not simulate the muscle structure around the human pelvis, which limited the freedom of the femoral tip in six directions and could not simulate the normal physiological activity of the human body. Third, the biomechanical experiment only verifies the biomechanical properties of a specific fixation method, which can only be used as a reference for clinical application. We should also consider the short-term and long-term clinical effects of the procedures.

Conclusions

Biomechanical tests of pelvic specimens treated with a lumbo-iliac fixation for unstable posterior pelvic ring injury showed that bilateral single iliac screws with three channels could effectively restore the stability of the reconstructed pelvis. The compressive stiffness and torsional stiffness of channel B fixation were better than those of channel A fixation. The compressive stiffness and torsional stiffness of channel C fixation were the worst. Finite element analyses showed that channel B fixation has excellent biomechanical stability, a more reasonable overall stress distribution, a smaller internal fixation maximum stress value, a stronger fatigue resistance, and more resilience to the breakage of nails. These results suggest that for clinical application of lumbo-iliac fixation, the optimal iliac screw channel is 1 cm medial and 1 cm caudal of the posterior superior iliac spine to the anterior inferior iliac spine.

Data availability statement

The original contributions presented in the study are included in the article/Supplementary Material, further inquiries can be directed to the corresponding author/s.

Ethics statement

Written informed consent was obtained from the individual(s) for the publication of any potentially identifiable images or data included in this article.

Author contributions

YS, YF, FL, BF and WZ performed the experiments and wrote this manuscript. YS, FL, WZ, HM and BF collected and analyzed the data. QL, DZ and BF revised and finalized the study. All authors contributed to the article and approved the submitted version.

Funding

This study was supported by Shandong Key R&D Program (Baisheng Fu, No: 2017GSF18112), the incubation fund of Shandong Provincial Hospital (Fanxiao Liu, grant number 2020FY019), Young Scholars Program of Shandong Provincial Hospital, Natural Science Foundation of Shandong Province (Fanxiao Liu, grant number ZR2021QH307), and China Scholarship Council (CSC) (Fanxiao Liu, grant number 201808080126).

Conflict of interest

The authors declare that the research was conducted in the absence of any commercial or financial relationships that could be construed as a potential conflict of interest.

Publisher's note

All claims expressed in this article are solely those of the authors and do not necessarily represent those of their affiliated organizations, or those of the publisher, the editors and the reviewers. Any product that may be evaluated in this article, or claim that may be made by its manufacturer, is not guaranteed or endorsed by the publisher.

References

1. Herman A, Keener E, Dubose C, Lowe JA. Zone 2 sacral fractures managed with partially-threaded screws result in low risk of neurologic injury. *Injury*. (2016) 47(7):1569–73. doi: 10.1016/j.injury.2016.04.004

2. Bydon M, De la Garza-Ramos R, Macki M, Desai A, Gokaslan AK, Bydon A. Incidence of sacral fractures and in-hospital postoperative complications in the United States: an analysis of 2002–2011 data. *Spine*. (2014) 39(18):e1103–1109. doi: 10.1097/BRS.0000000000000448

3. Denis F, Davis S, Comfort T. Sacral fractures: an important problem. Retrospective analysis of 236 cases. *Clin Orthop Relat Res*. (1988) 227(227):67.

4. Quacinella MA, Morrissey PB, Parry JA, Mauffrey C. Spinopelvic dissociation: assessment, reduction strategies, and fixation techniques. *J Am Acad Orthop Surg*. (2020) 28(24):e1086–96. doi: 10.5435/JAAOS-D-19-00863

5. Käch K, Trentz O. Distraction spondylodesis of the sacrum in "vertical shear lesions" of the pelvis. *Unfallchirurg*. (1994) 97(1):28–38.

6. Schildhauer TA, Ledoux WR, Chapman JR, Henley MB, Tencer AF, Routt ML Jr. Triangular osteosynthesis and iliosacral screw fixation for unstable sacral fractures: a cadaveric and biomechanical evaluation under cyclic loads. *J Orthop Trauma*. (2003) 17(1):22–31. doi: 10.1097/00005131-200301000-00004

7. Schildhauer TA, McCulloch P, Chapman JR, Mann FA. Anatomic and lumbopelvic fixation. *J Spinal Disord Tech*. (2002) 15(3):199–205. doi: 10.1097/00024720-200206000-00005

8. Bourghli A, Boissiere L, Obeid I. Dual iliac screws in spinopelvic fixation: a systematic review. *Eur Spine J*. (2019) 28(9):2053–9. doi: 10.1007/s00586-019-06065-3

9. Berber O, Amis AA, Day AC. Biomechanical testing of a concept of posterior pelvic reconstruction in rotationally and vertically unstable fractures. *J Bone Jt Surg, Br Vol*. (2011) 93B(2):237–44. doi: 10.1302/0301-620X.93B2.24567

10. Harrop JS, Jeyamohan SB, Sharan A, Ratliff J, Vaccaro AR. Iliac bolt fixation: an anatomic approach. *J Spinal Disord Tech*. (2009) 22(8):541–4. doi: 10.1097/BSD.0b013e31818da3e2

11. Schwend RM, Sluyters R, Najdzionek J. The pylon concept of pelvic anchorage for spinal instrumentation in the human cadaver. *Spine*. (2003) 28 (6):542–7. doi: 10.1097/01.BRS.0000049925.58996.66

12. Tian X, Li J, Sheng W, Qu D, Ouyang J, Xu D, et al. Morphometry of iliac anchorage for transiliac screws: a cadaver and CT study of the eastern population. *Surg Radiol Anat*. (2010) 32(5):455–62. doi: 10.1007/s00276-009-0589-5

13. Yu BS, Zhuang XM, Zheng ZM, Li ZM, Wang TP, Lu WW. Biomechanical advantages of dual over single iliac screws in lumbo-iliac fixation construct. *Eur Spine J*. (2010) 19(7):1121–8. doi: 10.1007/s00586-010-1343-8

14. Zheng Z, Yu B, Chen H, Aladin DM, Zhang KB, Zhang JF, et al. Effect of iliac screw insertion depth on the stability and strength of lumbo—iliac fixation constructs: an anatomical and biomechanical study. *Spine*. (2009) 34 (16):565–72. doi: 10.1097/BRS.0b013e3181ac8fc4

15. Lindahl J, Mäkinen TJ, Koskinen SK, Söderlund T. Factors associated with outcome of spinopelvic dissociation treated with lumbopelvic fixation. *Injury*. (2014) 45(12):1914–20. doi: 10.1016/j.injury.2014.09.003

16. Sohn S, Chung CK, Kim YJ, Kim CH, Park SB, Kim H. Modified iliac screw fixation: technique and clinical application. *Acta Neurochir*. (2016) 158(5):975–80. doi: 10.1007/s00701-016-2772-x

17. Wu T, Ren X, Cui Y, Cheng X, Peng S, Hou Z, et al. Biomechanical study of three kinds of internal fixation for the treatment of sacroiliac joint disruption using biomechanical test and finite element analysis. *J Orthop Surg Res*. (2018) 13(1):152. doi: 10.1186/s13018-018-0858-2

18. Sohn S, Park TH, Chung CK, Kim YJ, Jang JW, Han IB, et al. Biomechanical characterization of three iliac screw fixation techniques: a finite element study. *J Clin Neurosci*. (2018) 52:109–14. doi: 10.1016/j.jocn.2018.03.002

19. Song W, Zhou D, He Y. The biomechanical advantages of bilateral lumbo-iliac fixation in unilateral comminuted sacral fractures without sacroiliac screw safe channel: a finite element analysis. *Medicine*. (2016) 95(40):e5026. doi: 10.1097/MD.0000000000005026

20. Yamamoto I, Panjabi MM, Crisco T, Oxland T. Three-dimensional movements of the whole lumbar spine and lumbosacral joint. *Spine*. (1989) 14 (11):1256–60. doi: 10.1097/00007632-198911000-00020

21. Campbell JQ, Coombs DJ, Rao M, Rullkoetter PJ, Petrella AJ. Automated finite element meshing of the lumbar spine: verification and validation with 18 specimen-specific models. *J Biomech*. (2016) 49(13):2669–76. doi: 10.1016/j.jbiomech.2016.05.025

22. Wang B, Hua W, Ke W, Lu S, Li X, Zeng X, et al. Biomechanical evaluation of transforaminal lumbar interbody fusion and oblique lumbar interbody fusion on the adjacent segment: a finite element analysis. *World Neurosurg*. (2019) 126:e819–24. doi: 10.1016/j.wneu.2019.02.164

23. Esmende SM, Shah KN, Daniels AH. Spinopelvic fixation. *J Am Acad Orthop Surg*. (2018) 26(11):396–401. doi: 10.5435/JAAOS-D-15-00738

24. Gribnau AJ, van Hensbroek PB, Haverlag R, Ponsen KJ, Been HD, Goslings JC. U-shaped sacral fractures: surgical treatment and quality of life. *Injury*. (2009) 40(10):1040–8. doi: 10.1016/j.injury.2008.11.027

25. Bellabarba C, Schildhauer TA, Vaccaro AR, Chapman JR. Complications associated with surgical stabilization of high-grade sacral fracture dislocations with spino-pelvic instability. *Spine*. (2006) 31(11 Suppl):S80–S104. doi: 10.1097/01.brs.0000217949.31762.be

26. Fujibayashi S, Neo M, Nakamura T. Palliative dual iliac screw fixation for lumbosacral metastasis. Technical note. *J Neurosurg Spine*. (2007) 7(1):99–102. doi: 10.3171/SPI-07/07/099

27. Ebata S, Ohba T, Oba H, Haro H. Bilateral dual iliac screws in spinal deformity correction surgery. *J Orthop Surg Res*. (2018) 13(1):260. doi: 10.1186/s13018-018-0969-9

28. Futamura K, Baba T, Mogami A, Kanda A, Obayashi O, Iwase H, et al. Within ring"-based sacroiliac rod fixation may overcome the weakness of spinopelvic fixation for unstable pelvic ring injuries: technical notes and clinical outcomes. *Int Orthop*. (2018) 42(6):1405–11. doi: 10.1007/s00264-017-3712-y

29. Koshimune K, Ito Y, Sugimoto Y, Kikuchi T, Morita T, Mizuno S, et al. Minimally invasive spinopelvic fixation for unstable bilateral sacral fractures. *Clin Spine Surg*. (2016) 29(3):124–7. doi: 10.1097/BSD.0000000000000090

30. Okuda A, Maegawa N, Matsumori H, Kura T, Mizutani Y, Shigematsu H, et al. Minimally invasive spinopelvic "crab-shaped fixation" for unstable pelvic ring fractures: technical note and 16 case series. *J Orthop Surg Res*. (2019) 14 (1):51. doi: 10.1186/s13018-019-1093-1

31. Schildhauer TA, Bellabarba C, Nork SE, Barei DP, Routt Jr ML, Chapman JR. Decompression and lumbopelvic fixation for sacral fracture-dislocations with spino-pelvic dissociation. *J Orthop Trauma*. (2006) 20(7):447–57. doi: 10.1097/00005131-200608000-00001

32. Shen FH, Harper M, Foster WC, Marks I, Arlet V. A novel "four-rod technique" for lumbo-pelvic reconstruction: theory and technical considerations. *Spine*. (2006) 31(12):1395–401. doi: 10.1097/01.brs.0000219527.64180.95

33. Zhang HY, Thongtrangan I, Balabhadra RS, Murovic JA, Kim DH. Surgical techniques for total sacrectomy and spinopelvic reconstruction. *Neurosurg Focus*. (2003) 15(2):E5. doi: 10.3171/foc.2003.15.2.5

34. Acharya NK, Bijukachhe B, Kumar RJ, Menon VK. Ilio-lumbar fixation–the Amrita technique. *J Spinal Disord Tech*. (2008) 21(7):493–9. doi: 10.1097/BSD.0b013e31815b5cc4

35. Miller F, Moseley C, Koreska J. Pelvic anatomy relative to lumbosacral instrumentation. *J Spinal Disord*. (1990) 3(2):169–73. doi: 10.1097/00002517-199006000-00009

36. Moshirfar A, Rand FF, Sponseller PD, Parazin SJ, Khanna AJ, Kebaish KM, et al. Pelvic fixation in spine surgery. Historical overview, indications, biomechanical relevance, and current techniques. *J Bone Joint Surg Am*. (2005) 87(Suppl 2):89–106. doi: 10.2106/00004623-200511002-00011

37. Zhang L, Peng Y, Du C, Tang P. Biomechanical study of four kinds of percutaneous screw fixation in two types of unilateral sacroiliac joint dislocation: a finite element analysis. *Injury*. (2014) 45(12):2055–9. doi: 10.1016/j.injury.2014.10.052

38. Sahin O, Demirörs H, Akgün RC, Tuncay IC. Internal fixation of bilateral sacroiliac dislocation with transiliac locked plate: a biomechanical study on pelvic models. *Acta Orthop Traumatol Turc*. (2013) 47(6):411–6. doi: 10.3944/AOTT.2013.2840

39. Blanton PL, Biggs NL. Density of fresh and embalmed human compact and cancellous bone. *Am J Phys Anthropol*. (1968) 29:39–44. doi: 10.1002/ajpa.1330290113

40. Edmondston SJ, Singer KP, Day RE, Breidahl PD, Price RI. Formalin fixation effects on vertebral bone density and failure mechanics: an in-vitro study of human and sheep vertebrae. *Clin Biomech*. (1994) 9:175–9. doi: 10.1016/0268-0033(94)90018-3

41. Pleshko NL, Boskey AL, Mendelsohn R. An FT-IR microscopic investigation of the effects of tissue preservation on bone. *Calcif Tissue Int*. (1992) 51:72–7. doi: 10.1007/BF00296221

42. Nicholson HD, Samalia L, Gould M, Hurst PR, Woodroffe M. A comparison of different embalming fluids on the quality of histological preservation in human cadavers. *Eur J Morphol*. (2005) 42:178–84. doi: 10.1080/09243860500473306

43. Viidik A, Lewin T. Changes in tensile strength characteristics and histology of rabbit ligaments induced by different modes of postmortal storage. *Acta Orthop Scand*. (1966) 37:141–55. doi: 10.3109/17453676608993274

44. Boskey AL, Cohen ML, Bullough PG. Hard tissue biochemistry: a comparison of fresh-frozen and formalin-fixed tissue samples. *Calcif Tissue Int*. (1982) 34:328–31. doi: 10.1007/BF02411262

45. Currey JD, Brear K, Zioupos P, Reilly GC. Effect of formaldehyde fixation on some mechanical properties of bovine bone. *Biomaterials*. (1995) 16:1267–71. doi: 10.1016/0142-9612(95)98135-2

46. Goh JC, Ang EJ, Bose K. Effect of preservation medium on the mechanical properties of cat bones. *Acta Orthop Scand*. (1989) 60:465–7. doi: 10.3109/17453678909149321

47. Sedlin ED, Hirsch C. Factors affecting the determination of the physical properties of femoral cortical bone. *Acta Orthop Scand*. (1966) 37:29–48. doi: 10.3109/17453676608989401

48. Burkhart KJ, Nowak TE, Blum J, Kuhn S, Welker M, Sternstein W, et al. Influence of formalin fixation on the biomechanical properties of human diaphyseal bone. *Biomed Tech (Berl)*. (2010) 55(6):361–5. doi: 10.1515/bmt.2010.043

49. Wang W, Zhou C, Guo R, Cha T, Li G. Prediction of biomechanical responses of human lumbar discs—a stochastic finite element model analysis. *Comput Methods Biomech Biomed Engin*. (2021) 24(15):1730–41. doi: 10.1080/10255842.2021.1914023

50. Comstock CP, van der Meulen MC, Goodman SB. Biomechanical comparison of posterior internal fixation techniques for unstable pelvic fractures. *J Orthop Trauma*. (1996) 10(8):517–22. doi: 10.1097/00005131-199611000-00001

51. Hao Z, Wan C, Gao X, Ji T. The effect of boundary condition on the biomechanics of a human pelvic joint under an axial compressive load: a three-dimensional finite element model. *J Biomech Eng*. (2011) 133(10):101006. doi: 10.1115/1.4005223

52. Diwan AD, Parvataneni HK, Khan SN, Sandhu HS, Girardi FP, Cammisa FP Jr. Current concepts in intervertebral disk restoration. *Orthopedic Clinics*. (2000) 31 (3):453–64. doi: 10.1016/s0030-5898(05)70163-2

frontiers | Frontiers in Surgery

TYPE Case Report
PUBLISHED 08 November 2022
DOI 10.3389/fsurg.2022.1015091

Check for updates

OPEN ACCESS

EDITED BY
Paphon Sa-ngasoongsong,
Mahidol University, Thailand

REVIEWED BY
Wenfu Lai,
Taipei Medical University, Taiwan
Osvaldo Mazza,
Bambino Gesù Children's Hospital (IRCCS), Italy

*CORRESPONDENCE
Kang Tian
dmu-tiankang@outlook.com
Weiguo Zhang
dlmedu@outlook.com

†These authors have contributed equally to this work

SPECIALTY SECTION
This article was submitted to Orthopedic Surgery, a section of the journal Frontiers in Surgery

RECEIVED 09 August 2022
ACCEPTED 18 October 2022
PUBLISHED 08 November 2022

CITATION
Wang L, Li H, Cao Y, Song C, Chen Q, Hao J, Zhang W and Tian K (2022) Four cases report: Treatment of knee joint cartilage defects using autologous chondrocyte patch implantation. Front. Surg. 9:1015091. doi: 10.3389/fsurg.2022.1015091

COPYRIGHT
© 2022 Wang, Li, Cao, Song, Chen, Hao, Zhang and Tian. This is an open-access article distributed under the terms of the Creative Commons Attribution License (CC BY). The use, distribution or reproduction in other forums is permitted, provided the original author(s) and the copyright owner(s) are credited and that the original publication in this journal is cited, in accordance with accepted academic practice. No use, distribution or reproduction is permitted which does not comply with these terms.

Four cases report: Treatment of knee joint cartilage defects using autologous chondrocyte patch implantation

Le Wang[1†], Han Li[1†], Yiguo Cao[1†], Cheng Song[2†], Qi Chen[1], Jun Hao[1], Weiguo Zhang[1*] and Kang Tian[1*]

[1]Department of Joint and Sports Medicine, First Affiliated Hospital, Dalian Medical University, Dalian, China, [2]Department of Nuclear Medicine, First Affiliated Hospital, Dalian Medical University, Dalian, China

Introduction: Autologous chondrocyte implantation (ACI) is a crucial method for the treatment of defects in articular cartilage. However, the extant methods for the preparation of autologous chondrocyte patch are relatively complicated and money-consuming. Therefore, an efficient, reliable, easy-to-follow, and cost-effective technique is needed to overcome constraints. This case report aims to introduce an autologous chondrocyte patch fabrication technique to repair knee joint cartilage defects and report our typical cases with a 2-year follow-up.

Case presentation: We described four cases in which patients complained of knee joint pain. According to radiological examination, the patients were diagnosed as knee joint cartilage defect. Arthroscopy and autologous chondrocyte patch implantation were performed as well as a 2-year follow up of patients. The autologous chondrocyte patch for knee joint cartilage repair was fabricated using a "sandwich" technique. The preoperative and postoperative knee function was evaluated by four subjective evaluation systems. MRI was performed for all patients to achieve more intuitionistic observation of the postoperative radiological changes of defect sites. The quality of repaired tissue was evaluated by Magnetic Resonance Observation of Cartilage Repair Tissue (MOCART). Postoperative follow-up showed improvement in clinical and MOCART scores for all patients. However, one patient complained of knee joint pain after walking for a long time or recreational activities from 12- to 18-month postoperatively. The location of pain for this patient was not in accordance with the location of cartilage defect.

Conclusion: The patients undergoing autologous chondrocyte patch implantation demonstrated clinical improvement and good quality of repaired tissue postoperatively. The procedure is an efficient and cost-effective treatment for knee joint cartilage defect in this report. In addition, patients with osteoarthritis carry the risk of a poor outcome after the procedure, and whether to have a procedure should be considered carefully.

KEYWORDS

cartilage defect, autologous chondrocyte patch implantation, sandwich technique, cartilage repair, ACI, MACI

Introduction

A defect in articular cartilage is a common orthopedic problem, especially in the weightbearing areas of lower-extremity joints (e.g., knee). It has a high prevalence of morbidity in the general population (5%) (1, 2). The lack of vascular, nervous, or lymphatic systems hinders articular cartilage from healing. It can trigger pain, swelling, and dysfunction in the joint (3).

Autologous chondrocyte implantation (ACI) is a crucial method for the treatment of defects in articular cartilage. It can be divided into three generations (4). The first generation (ACI-P) was reported first by Brittberg et al. in 1994, and has two steps. During the first step, arthroscopy is undertaken to obtain chondrocytes, and then they are sent for culture. The second step involves injecting a suspension of cultured chondrocytes below a periosteal patch after 14–21 days (5). The second generation (ACI-C) uses a bioabsorbable collagen membrane instead of a periosteal patch. The third generation (which is based on the second generation) involves the creation of cartilage-like tissue in a biodegradable scaffold and is named ACI-M or matrix-induced autologous chondrocyte implantation (MACI) (6, 7). Several studies have revealed that ACI can lead to effective short-, medium-, and long-term outcomes (4, 7–13). However, the extant methods for the preparation of autologous chondrocyte patch are relatively complicated and money-consuming. Therefore, an efficient, reliable, easy-to-follow, and cost-effective technique is needed to overcome constraints. Therefore, we introduce an autologous chondrocyte patch fabrication technique to repair knee joint cartilage defects and report our typical cases with a 2-year follow-up for clinical and radiological outcomes in this report.

Case report

Case 1: A 26-year-old male sustained an injury to his left knee while fishing. He experienced a twisting of his knee, while a varus impaction force was applied to the slightly flexed knee. He visited the outpatient department of other hospital and was treated with conservative treatment. After 1 year, he had left knee sprain again, accompanied by severe knee joint pain and swelling. Case 2: A 36-year-old female suffered discontinuous pain in left knee that continued for at least 16 years. There was no history of obvious trauma. She had frequent knee joint pain and motion restriction in the past 1 month before hospitalisation. Case 3: A 47-year-old male fell while running 14 years ago. The right knee joint pain was worse with activity and decreased with rest. At that time, he was not receiving any examination or therapy. The right knee joint pain was aggravated in recent months before hospitalisation. Case 4: A 37-year-old male fell while running. After that, he suffered from persistent left joint pain. He could not walk up or down stairs and the quality of his life was seriously influenced.

All these four patients were diagnosed as knee joint cartilage defect after physical and MR examination during hospitalization. Demographic information (sex, age, height, weight), medical and previous history, and cartilage defect characteristics of these patients (length, width, depth, shape, localization) were documented (**Supplementary Table S1**).

Surgical treatments were performed for patients. The standard procedure involved two steps. The first step was knee arthroscopy in which healthy cartilage tissue was removed from the intercondylar fossa (non-weightbearing areas) and the characteristics of the cartilage defect (length, width, depth, shape, localization) were checked.

The healthy removed cartilage tissue was stored in Dulbecco's modified Eagle's medium (DMEM, Absin, Shanghai, China) at 4°C and sent immediately to the laboratory for cell cultivation. Chondrocytes were isolated enzymatically after digestion by 1% collagenase II (Absin, Shanghai, China) at 37°C for 4 h. Then, they were expanded using culture conditions for autologous cells. DMEM was supplemented with 10% autologous serum (separated from peripheral blood), L-glutamine, and antibiotics (penicillin and streptomycin). Cells were cultured at 37°C in an atmosphere of 5% CO_2 and 95% relative humidity. The medium was removed, and a fresh medium was added every three days. A maximum of two passages were undertaken for each culture. The cartilage used for fabrication of acellular cartilage sheets was harvested from the ears of adult pigs. First, the cartilage was cut into a cylindrical shape with a diameters of 2 cm. Then, the cylindrical cartilage was cut into sheets (using a freezing microtome) of thickness 10-μm. The sheets were decellularized in 1% sodium dodecyl sulfate (SDS, Coolaber, Beijing, China) for 24 h. After decellularization, the sheets were rinsed thrice in sterile water. A vacuum freeze-drier was used for lyophilization of the sheets. The diameter of sheets was narrowed to be about 1.8 cm. An acellular cartilage sheet was placed in a culture dish, and 5-μl of the chondrocyte suspension was seeded on it. The concentrations of chondrocyte suspension was 20×10^6 cells/ml. Then, another acellular cartilage sheet was superposed on the first acellular cartilage sheet with 5-μl of the chondrocyte suspension seeded on the surface. These procedures were continued until ten sheets were stacked together. The construct was cultured at 37°C in an atmosphere of 5% CO_2 and 95% relative humidity for 4 weeks. After that, the implantation was carried out. **Figure 1** provides a brief summary of the construction process of implantation patch. The implantation patch was about 2 cm × 0.4 cm respectively in diameter and thickness. All constructions made by the same method in order to acquire similar sizes of implantation patches.

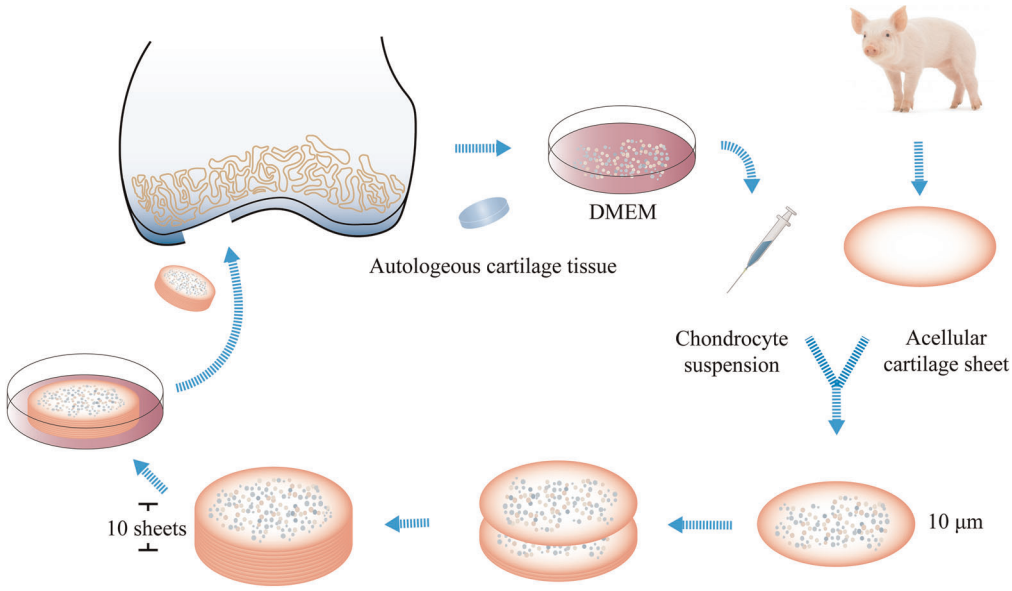

FIGURE 1
Fabrication of the patch. Healthy cartilage was harvested from the intercondylar fossa. Chondrocytes were isolated enzymatically. The cartilage used for the fabrication of acellular cartilage sheets was harvested from the ears of adult pigs. It was cut into sheets, and the sheets were decellularized. Chondrocytes were seeded on the sheet. Then, another acellular cartilage sheet was superposed on the first sheet, and these procedures were continued until ten sheets were stacked together. The construct was cultured at 37°C in an atmosphere of 5% CO_2 and 95% relative humidity for 4 weeks before implantation.

The second step was composed of mini-arthrotomy, curettage, and implantation. During this step (**Figure 2**), the unhealthy cartilage and subchondral bone plate were cleaned carefully to ensure blood exudation was absent and to leave the base smooth. The patch was placed in physiologic (0.9%) saline <5 min before transplantation. It was trimmed carefully to fit the defect exactly before placed onto the defect. Then, fibrin glue was applied to the surface to fix the patch to the defect without suturing. If a subchondral cystic defect occurred, then debridement was done. A contralateral autogenous posterior iliac bone graft was made, and the bone graft was transplanted into the subchondral defect.

Patients accepted routine rehabilitation after arthroscopy. Postoperative rehabilitation after the second step was far more critical. Initially, the patients accepted fixation using a locking hinged knee brace, and the knee was placed in extension for 2–3 days. The purpose was to prevent the patch from dislodging and allow stable adhesion between the patch and subchondral plate. After that, active and passive motions were allowed. First, non-weightbearing quadricep-strengthening exercises on a bed were recommended to patients. Then, a device to ensure continuous passive motion was used for 90–135 min daily until discharge from the hospital. The range of motion (RoM) was from 0° to 30° initially, and the upper-limit RoM was increased 5° per day until 90° (~2 weeks). Afterward, the full RoM was allowed if patients did not feel pain. Partial-weightbearing with a walking aid within 6 weeks was allowed, after which full-weightbearing was allowed.

The preoperative and postoperative knee function was evaluated by four subjective evaluation systems: International Knee Documentation Committee Subjective Knee Evaluation Form (IKDC-SKEF) (14); Lysholm Scale (15); Western Ontario and McMaster Universities Osteoarthritis Index (WOMAC) (16); Knee Injury and Osteoarthritis Outcome Score (KOOS) (17). These systems have been demonstrated to be effective and sensitive for evaluation of the repair of articular cartilage (18–24) and have been used widely for evaluation of outcomes after ACI (25, 26–33). MR examination of the operated knee joint was undertaken on a 3.0-T MR scanner (Ingenia 3.0-T CX, Philips Healthcare, Best, the Netherlands) using a sixteen-channel phased-array coil. The quality of repaired tissue was evaluated by Magnetic Resonance Observation of Cartilage Repair Tissue (MOCART). It is a classification system established by Marlovits et al. in 2004 to analyze repaired tissue (34). Studies have indicated a correlation between the clinical outcome and MOCART score (35, 36). Some researchers consider it to be a reliable way to evaluate repaired tissue (37, 38).

Overall, the patients were all satisfied with the surgical treatments. All patients showed improvements on all clinical outcomes over the time (**Figures 3A,B**). As an exception, the scores of one patient were lower than those of other patients in IKDC-SKEF, Lysholm Scale, and KOOS. Accordingly,

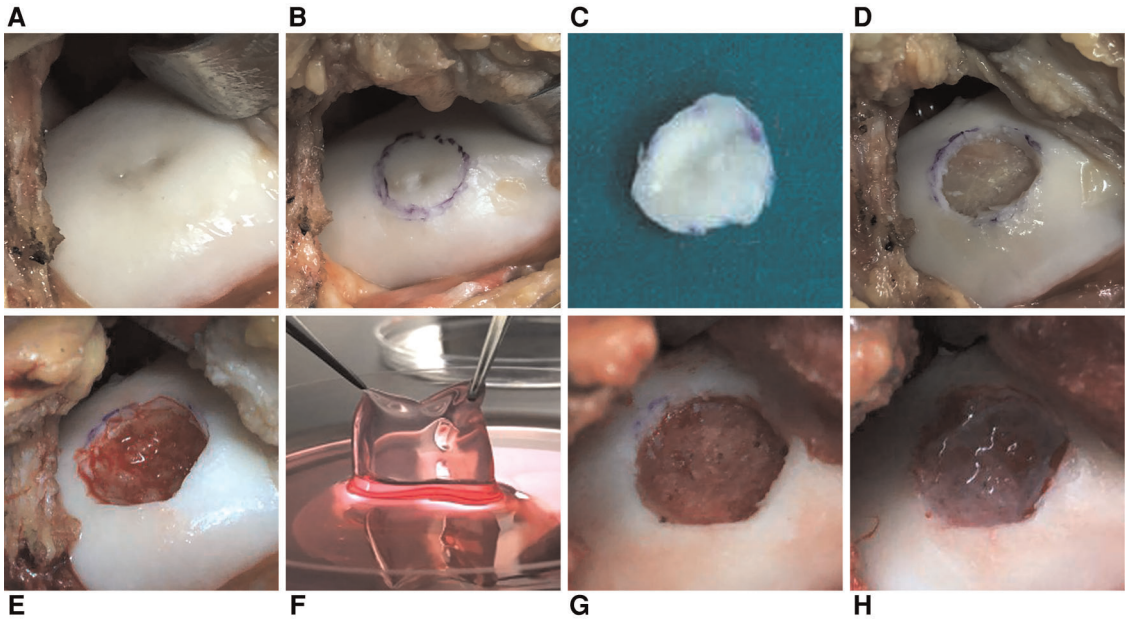

FIGURE 2
Mini-arthrotomy, curettage, and implantation in a patient (female; 36 years; left knee; BMI = 19.05 kg/m^2; other surgery: bone grafting). (A) The cartilage defect was exposed. (B,C) The unhealthy cartilage was marked and removed. (D) The subchondral bone was exposed, and cystic degeneration could be seen. (E) The cystic degeneration in subchondral bone was removed, and blood effusion could be observed. (F) The patch was placed in 0.9% saline <5 min before transplantation. (G) A contralateral autogenous posterior iliac bone graft was made. (H) The patch was placed into the defect. Fibrin glue was applied to the surface to fix the patch to the defect without suturing.

WOMAC scores were higher. His postoperative WOMAC score at 18-month was higher than that at 12-month, and was similar to the score at 6-month. He complained of knee joint pain after walking for a long time or recreational activities. The MOCART scores increased gradually after procedure (**Figure 3C**) for all patients. The MR images of patients are shown in **Figure 4**. As can be seen, the defect area decreased postoperatively, and the signal intensity of the repaired cartilage was close to that of healthy cartilage 12-month postoperatively. There was virtually no sclerosis of subchondral bone or edema 18-month postoperatively.

Discussion

The improvements in IKDC-SKEF, Lysholm Scale, WOMAC, and KOOS were demonstrated postoperatively in all patients. The patients expressed satisfaction with the functional postoperative recovery after autologous chondrocyte patch implantation.

As seen from **Figure 3B**, the function score in sport and recreation (FSR) and quality of life (QoL) were lower than other parts in KOOS at all times. This means that the time needed for patients to return to sports and recreational activities after the procedure was longer than that for returning to activities of daily living. It still needs a long time to return to a higher QoL level. Pestka et al. and Erdle et al. showed that returning to low-intensity and moderate-intensity activities was feasible, but returning to high-intensity or identical-intensity activities to that before surgery was infeasible in 1 year (39, 40). Ebert et al. and Erggelet et al. advised their patients to return to contact and competitive activities 12-month postoperatively (41, 42). Furthermore, Niethammer et al. compared the rehabilitation process postoperatively. They found that patients who returned to sporting activities 12-month postoperatively showed significantly better clinical outcomes than those who returned to sporting activities before 12-month postoperatively (43). However, Kreuz et al. concluded that moderate-intensity sporting activities are an essential component of rehabilitation but should be undertaken at least 2–3 years after the surgical procedure (44). All of the above studies demonstrated that patients should not return to high-intensity activities too earlier. It may help surgeons and patients determine the appropriate time for returning to sporting activities postoperatively.

The MOCART scores increased gradually after the surgical procedure. These data are in accordance with the trend reported by Zak et al. and Niemeyer and colleagues (45, 46). It illustrated that the repaired cartilage tissue progressed towards a healthy morphology. MR examination is a non-invasive way to evaluate articular cartilage and has a sensitivity of ≤96% (47).

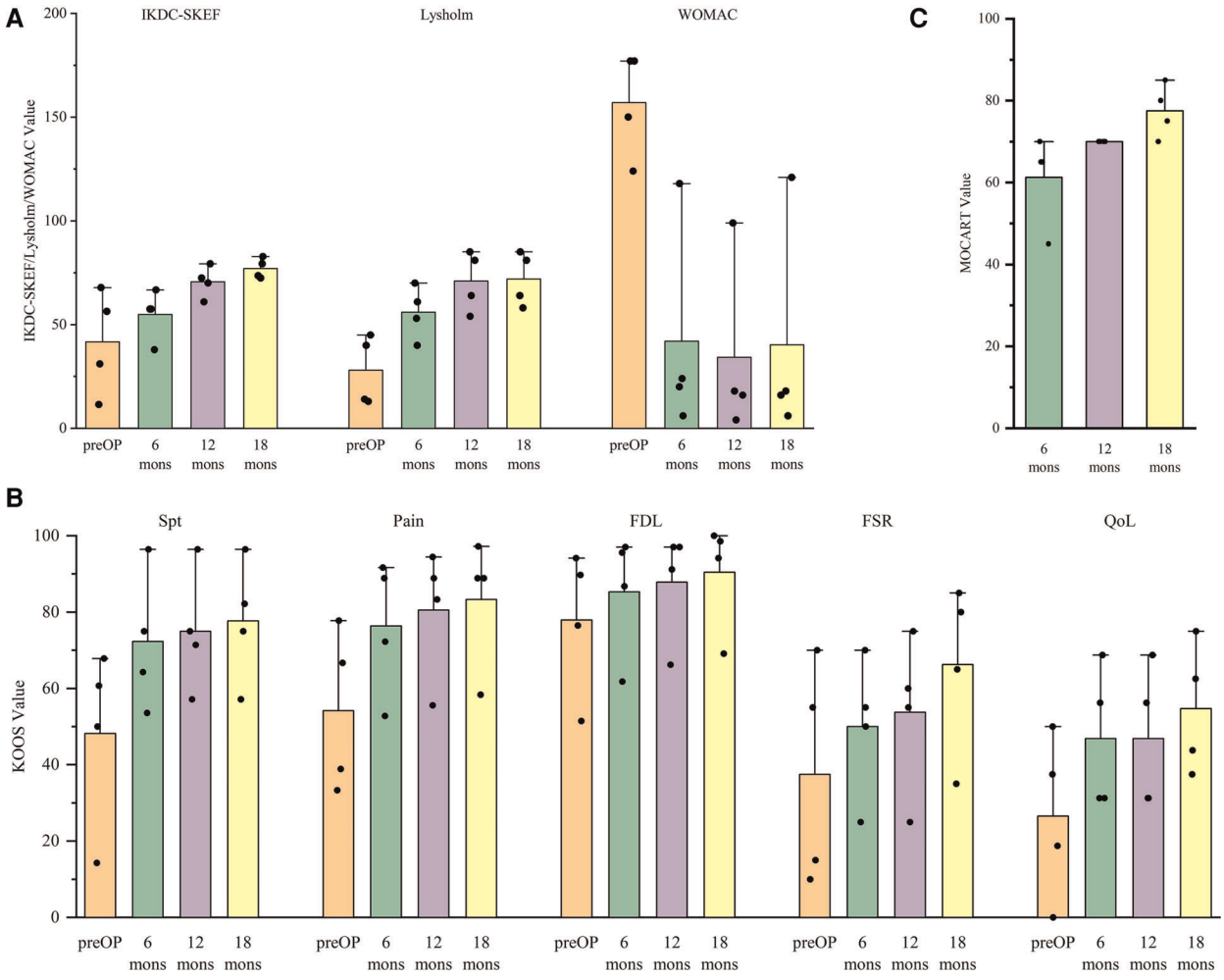

FIGURE 3
Variation in the trend of (A) international knee documentation committee subjective knee evaluation form (IKDC-SKEF), lysholm scale, western Ontario and mcMaster universities osteoarthritis Index (WOMAC), (B) knee injury and osteoarthritis outcome score (KOOS), and (C) magnetic resonance observation of cartilage repair tissue (MOCART) scores.

MR features can show cartilage status directly. The MOCART score is a quantitative indicator to evaluate cartilage. However, Siebold et al. pointed out that a low MOCART score did not denote poor clinical results but, instead, we should not evaluate cartilage status using the MOCART score only (4).

In the present study, the mean total cost of procedure was 57693.2 (range, 55905.2–61644.2) CNY. This figure included the fees for preoperative consultation and preparation, surgical items (anesthesia, surgical supplies, duration of use of the operating room, drugs, and hospital fees), cell processing, and implantation patch fabrication. The costs of this procedure are significantly higher than those of knee arthroscopy (chondroplasty and debridement), microfracture (MFx), osteochondral transplantation (OCT), or osteochondral allograft (OCA) (6, 25, 48). However, arthroscopic chondroplasty and debridement cannot fundamentally tackle the problem. MFx leads to the synthesis of fibrocartilage instead of hyaline cartilage. The biomechanical property of the fibrocartilage is inferior to that of hyaline cartilage, which leads to a worse long-term outcome (4, 8, 9, 49–54). Donor-area complications (e.g., pain, discomfort, and formation of secondary bone defects) cannot be ignored after OCT (55).

Although ACI can lead to the synthesis of hyaline cartilage, the different generation of ACI have different advantages and disadvantages. Samuelson et al. demonstrated that ACI-P and ACI-C are cost-effective, and that the latter is marginally more cost-effective than the former (56). Their results are similar to those of Schrock and colleagues (25). Everhart et al. pointed out that the cost of MACI is similar or slightly higher than that of ACI-C (48). Several studies have pointed out that MACI can lead to satisfactory and reliable clinical outcomes (7, 9, 26, 27, 30, 57). It has other advantages: homogeneous

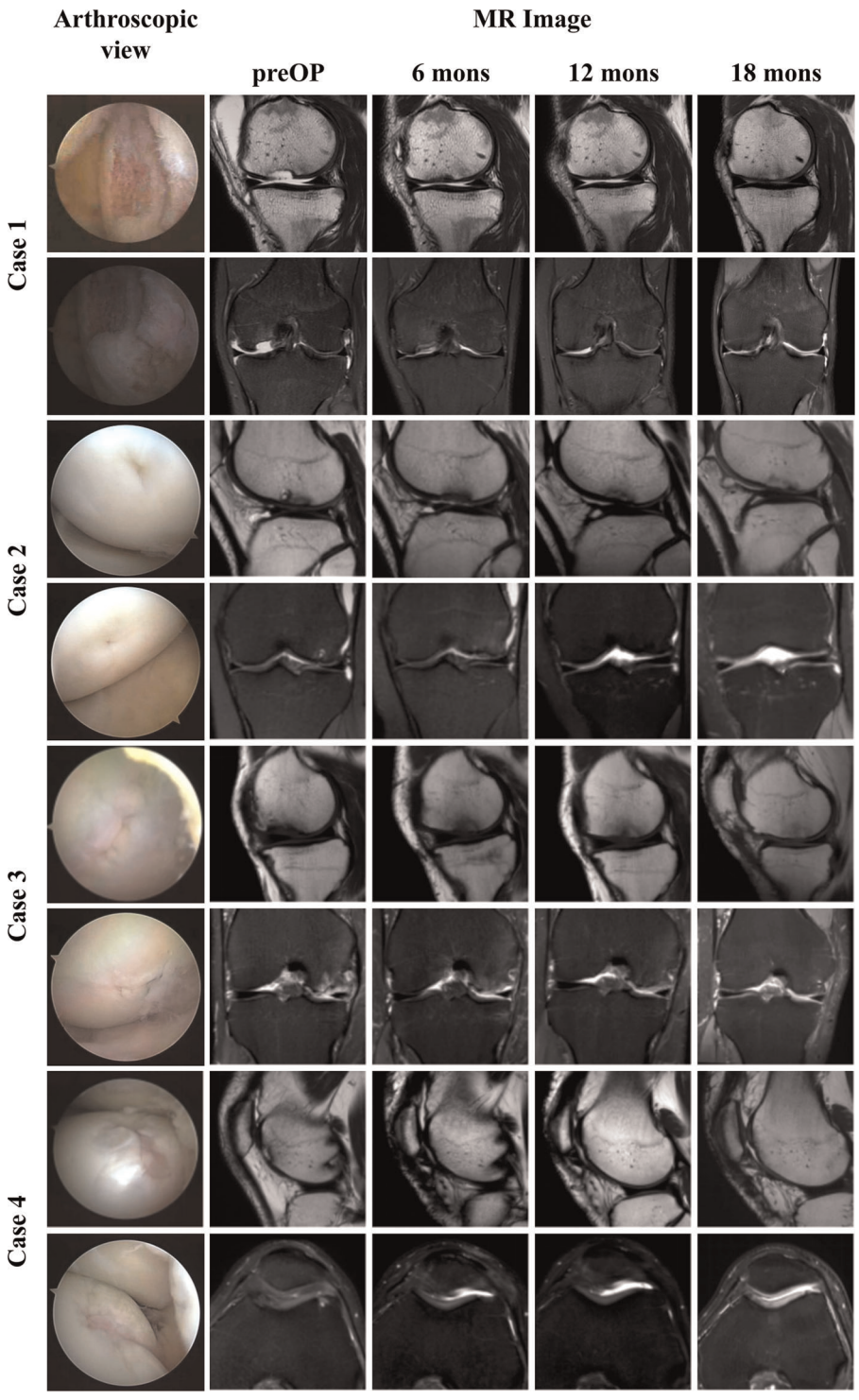

FIGURE 4
Arthroscopic view and MR images of four patients. The first column: arthroscopic view of cartilage defect. The second to fifth columns: Sagittal T2-weighted, coronal, or axial PD-weighted MR images of four patients from pre to 18 months after procedure.

distribution; biocompatibility; appropriateness for large cartilage defects; relatively simple production process; easy to model; can be produced in differently sized and shaped membranes; straightforward surgical procedure; use of fibrin glue instead of suturing (6). Most importantly, it has been approved by the Chinese government. According to the three

generations of ACI, only ACI-P and MACI have been approved in China. The patch in this study was easy to prepare and not technically demanding. Due to the disadvantages of ACI-P (e.g., complex surgical procedure, highly invasive, inhomogeneous distribution, weak biomechanical property), we believe that our procedure is an excellent way to treat patients with a focal articular-cartilage defect in knee joint.

Interestingly, the changes of WOMAC score of one patient were different from those of other patients. He complained of knee joint pain after walking for a long time or recreational activities from 12- to 18-month postoperatively. During a recent follow-up (18-month postoperatively), we undertook a comprehensive examination of the operated knee. We discovered that the location of the knee joint pain for this patient was not in accordance with the location of the cartilage defect. We found hyperosteogeny according to preoperative radiography (**Supplementary Figure S1**). The hyperosteogeny and appearance of osteoarthritis became more marked with time.

There are likely two explanations for this problem. First, the indications for the procedure should be stricter. Even though the patient was aged only 46 years, the appearance of osteoarthritis was present preoperatively. Although the clinical outcome was good, it did not proceed as expected. Niemeyer et al. considered that diffuse lesions (e.g., osteoarthritis) should not be included in the indication for ACI (54). Conversely, Minas and collaborators considered that patients with early-stage osteoarthritis can accept ACI (58). Rosenberger et al. pointed out that the failure rates of ACI in older and younger patient groups are similar if the cartilage defect is focal (59). Second, the progress of intrinsic osteoarthritis for this patient influenced the effect postoperatively. Osteoarthritis progression may be fast in some patients, even if the procedure has been done and the defect has been repaired. A focal cartilage defect is a risk factor for osteoarthritis development (54). The procedure can be a powerful tool for delaying osteoarthritis progression, but intrinsic osteoarthritis cannot be delayed (58). Therefore, patients aged >40 years with osteoarthritis may carry the risk of a poor clinical outcome after the procedure, and whether to have a procedure should be considered carefully.

Conclusion

Patients undergoing autologous chondrocyte patch (fabricated *via* the sandwich technique) implantation demonstrated clinical improvement and good quality of repaired tissue postoperatively. The procedure is an efficient and cost-effective treatment for knee joint cartilage defect in this report. In addition, patients with osteoarthritis carry the risk of a poor outcome after the procedure, and whether to have a procedure should be considered carefully. Large studies with long-term follow-up are also needed.

Data availability statement

The raw data supporting the conclusions of this article will be made available by the authors, without undue reservation.

Ethics statement

The studies involving human participants were reviewed and approved by The ethics committee of First Affiliated Hospital of Dalian Medical University. The patients/participants provided their written informed consent to participate in this study.

Author contributions

All authors contributed to the study conception and design. Design of case report, patients examination, data collection, and analysis were performed by LW, HL, YC, and CS. QC and JH performed follow-up of the patients. The first draft of the manuscript was written by LW. WZ and KT critically reviewed and edited the first draft of the manuscript and all authors commented on previous versions of the manuscript. All authors contributed to the article and approved the submitted version.

Funding

Supported by National Natural Science Foundation of China (No. 81601901); Natural Science Foundation of Liaoning (No. 2019-MS-079, No. 20170540285) for patient's treatment costs and follow-up MR examination charges.

Acknowledgments

Thanks to our operation team WZ, JL, YZ, JZ, and KT, who have been working hard for many years, it is impossible to complete the study without the team.

Conflict of interest

The authors declare that the research was conducted in the absence of any commercial or financial relationships that could be construed as a potential conflict of interest.

Publisher's note

All claims expressed in this article are solely those of the authors and do not necessarily represent those of their

affiliated organizations, or those of the publisher, the editors and the reviewers. Any product that may be evaluated in this article, or claim that may be made by its manufacturer, is not guaranteed or endorsed by the publisher.

Supplementary material

The Supplementary Material for this article can be found online at: https://www.frontiersin.org/articles/10.3389/fsurg.2022.1015091/full#supplementary-material.

References

1. Wu S, Kai Z, Wang D, Tao L, Zhang P, Wang D, et al. Allogenic chondrocyte/osteoblast-loaded β-tricalcium phosphate bioceramic scaffolds for articular cartilage defect treatment. *Artif Cells Nanomed Biotechnol*. (2019) 47:1570–6. doi: 10.1080/21691401.2019.1604534

2. Zhou Y, Li H, Xiang D, Shao J, Fu Q, Han Y, et al. The clinical efficacy of arthroscopic therapy with knee infrapatellar fat pad cell concentrates in treating knee cartilage lesion: a prospective, randomized, and controlled study. *J Orthop Surg Res*. (2021) 16:87. doi: 10.1186/s13018-021-02224-9

3. Niethammer T, Holzgruber M, Gülecyüz M, Weber P, Pietschmann M, Müller P. Matrix based autologous chondrocyte implantation in children and adolescents: a match paired analysis in a follow-up over three years post-operation. *Int Orthop*. (2017) 41:343–50. doi: 10.1007/s00264-016-3321-1

4. Siebold R, Suezer F, Schmitt B, Trattnig S, Essig M. Good clinical and mri outcome after arthroscopic autologous chondrocyte implantation for cartilage repair in the knee. *Knee Surg Sports Traumatol Arthrosc*. (2018) 26:831–9. doi: 10.1007/s00167-017-4491-0

5. Brittberg M, Lindahl A, Nilsson A, Ohlsson C, Isaksson O, Peterson L. Treatment of deep cartilage defects in the knee with autologous chondrocyte transplantation. *N Engl J Med*. (1994) 331:889–95. doi: 10.1056/nejm199410063311401

6. Zhang C, Cai Y, Lin X. Autologous chondrocyte implantation: is it likely to become a saviour of large-sized and full-thickness cartilage defect in young adult knee? *Knee Surg Sports Traumatol Arthrosc*. (2016) 24:1643–50. doi: 10.1007/s00167-015-3643-3

7. Niethammer T, Altmann D, Holzgruber M, Goller S, Fischer A, Müller P. Third generation autologous chondrocyte implantation is a good treatment option for athletic persons. *Knee Surg Sports Traumatol Arthrosc*. (2021) 29:1215–23. doi: 10.1007/s00167-020-06148-5

8. Lopez-Alcorocho J, Aboli L, Guillen-Vicente I, Rodriguez-Iñigo E, Guillen-Vicente M, Fernández-Jaén T, et al. Cartilage defect treatment using high-density autologous chondrocyte implantation: two-year follow-up. *Cartilage*. (2018) 9:363–9. doi: 10.1177/1947603517693045

9. Barié A, Kruck P, Sorbi R, Rehnitz C, Oberle D, Walker T, et al. Prospective long-term follow-up of autologous chondrocyte implantation with periosteum versus matrix-associated autologous chondrocyte implantation: a randomized clinical trial. *Am J Sports Med*. (2020) 48:2230–41. doi: 10.1177/0363546520928337

10. Kim M, Park J, Jeon Y, Jeon Y. Clinical, radiological, and histological outcomes after the fibrin-matrix autologous chondrocyte implantation for chondral lesions of the knee in patients more than 50 years old: a prospective case series with minimum 2-year follow-up. *J Orthop Surg*. (2020) 28:2309499019893509. doi: 10.1177/2309499019893509

11. Sumida Y, Nakamura K, Feil S, Siebold M, Kirsch J, Siebold R. Good healing potential of patellar chondral defects after all-arthroscopic autologous chondrocyte implantation with spheroids: a second-look arthroscopic assessment. *Knee Surg Sports Traumatol Arthrosc*. (2022) 30:1535–42. doi: 10.1007/s00167-021-06584-x

12. Biant L, Bentley G, Vijayan S, Skinner J, Carrington R. Long-term results of autologous chondrocyte implantation in the knee for chronic chondral and osteochondral defects. *Am J Sports Med*. (2014) 42:2178–83. doi: 10.1177/0363546514539345

13. Niemeyer P, Feucht M, Fritz J, Albrecht D, Spahn G, Angele P. Cartilage repair surgery for full-thickness defects of the knee in Germany: indications and epidemiological data from the German cartilage registry (knorpelregister dgou). *Arch Orthop Trauma Surg*. (2016) 136:891–7. doi: 10.1007/s00402-016-2453-5

14. Lysholm J, Gillquist J. Evaluation of knee ligament surgery results with special emphasis on use of a scoring scale. *Am J Sports Med*. (1982) 10:150–4. doi: 10.1177/036354658201000306

15. Osti L, Papalia R, Del Buono A, Amato C, Denaro V, Maffulli N. Good results five years after surgical management of anterior cruciate ligament tears, and meniscal and cartilage injuries. *Knee Surg Sports Traumatol Arthrosc*. (2010) 18:1385–90. doi: 10.1007/s00167-009-1035-2

16. Bellamy N, Buchanan WW, Goldsmith CH, Campbell J, Stitt LW. Validation study of womac: a health status instrument for measuring clinically important patient relevant outcomes to antirheumatic drug therapy in patients with osteoarthritis of the hip or knee. *J Rheumatol*. (1988) 15:1833–40.

17. Roos EM, Roos HP, Lohmander LS, Ekdahl C, Beynnon BD. Knee injury and osteoarthritis outcome score (koos)–development of a self-administered outcome measure. *J Orthop Sports Phys Ther*. (1998) 28:88–96. doi: 10.2519/jospt.1998.28.2.88

18. Mithoefer K, Acuna M. Clinical outcomes assessment for articular cartilage restoration. *J Knee Surg*. (2013) 26:31–40. doi: 10.1055/s-0032-1333308

19. de Windt T, Welsch G, Brittberg M, Vonk L, Marlovits S, Trattnig S, et al. Correlation between magnetic resonance imaging and clinical outcomes after knee cartilage repair: letter to the editor. *Am J Sports Med*. (2013) 41:NP48–50. doi: 10.1177/0363546513510140

20. Engelhart L, Nelson L, Lewis S, Mordin M, Demuro-Mercon C, Uddin S, et al. Validation of the knee injury and osteoarthritis outcome score subscales for patients with articular cartilage lesions of the knee. *Am J Sports Med*. (2012) 40:2264–72. doi: 10.1177/0363546512457646

21. Greco N, Anderson A, Mann B, Cole B, Farr J, Nissen C, et al. Responsiveness of the international knee documentation committee subjective knee form in comparison to the western Ontario and mcmaster universities osteoarthritis index, modified cincinnati knee rating system, and short form 36 in patients with focal articular cartilage defects. *Am J Sports Med*. (2010) 38:891–902. doi: 10.1177/0363546509354163

22. Hambly K, Griva K. Ikdc or koos? Which measures symptoms and disabilities most important to postoperative articular cartilage repair patients? *Am J Sports Med*. (2008) 36:1695–704. doi: 10.1177/0363546508317718

23. Collins N, Prinsen C, Christensen R, Bartels E, Terwee C, Roos E. Knee injury and osteoarthritis outcome score (koos): systematic review and meta-analysis of measurement properties. *Osteoarthr Cartil*. (2016) 24:1317–29. doi: 10.1016/j.joca.2016.03.010

24. Howe T, Dawson L, Syme G, Duncan L, Reid J. Evaluation of outcome measures for use in clinical practice for adults with musculoskeletal conditions of the knee: a systematic review. *Man Ther*. (2012) 17:100–18. doi: 10.1016/j.math.2011.07.002

25. Schrock J, Kraeutler M, Houck D, McQueen M, McCarty E. A cost-effectiveness analysis of surgical treatment modalities for chondral lesions of the knee: microfracture, osteochondral autograft transplantation, and autologous chondrocyte implantation. *Orthop J Sports Med*. (2017) 5:2325967117704634. doi: 10.1177/2325967117704634

26. Marlovits S, Aldrian S, Wondrasch B, Zak L, Albrecht C, Welsch G, et al. Clinical and radiological outcomes 5 years after matrix-induced autologous chondrocyte implantation in patients with symptomatic, traumatic chondral defects. *Am J Sports Med*. (2012) 40:2273–80. doi: 10.1177/0363546512457008

27. Ebert J, Fallon M, Zheng M, Wood D, Ackland T. A randomized trial comparing accelerated and traditional approaches to postoperative weightbearing rehabilitation after matrix-induced autologous chondrocyte implantation: findings at 5 years. *Am J Sports Med*. (2012) 40:1527–37. doi: 10.1177/0363546512445167

28. Kreuz P, Müller S, Freymann U, Erggelet C, Niemeyer P, Kaps C, et al. Repair of focal cartilage defects with scaffold-assisted autologous chondrocyte grafts: clinical and biomechanical results 48 months after transplantation. *Am J Sports Med*. (2011) 39:1697–705. doi: 10.1177/0363546511403279

29. Pascual-Garrido C, Slabaugh M, L'Heureux D, Friel N, Cole B. Recommendations and treatment outcomes for patellofemoral articular cartilage defects with autologous chondrocyte implantation: prospective evaluation at average 4-year follow-up. *Am J Sports Med*. (2009) 37(Suppl 1):33S–41S. doi: 10.1177/0363546509349605

30. Kraeutler M, Belk J, Carver T, McCarty E. Is delayed weightbearing after matrix-associated autologous chondrocyte implantation in the knee associated with better outcomes? A systematic review of randomized controlled trials. *Orthop J Sports Med*. (2018) 6:2325967118770986. doi: 10.1177/2325967118770986

31. Riboh J, Cvetanovich G, Cole B, Yanke A. Comparative efficacy of cartilage repair procedures in the knee: a network meta-analysis. *Knee Surg Sports Traumatol Arthrosc*. (2017) 25:3786–99. doi: 10.1007/s00167-016-4300-1

32. Mundi R, Bedi A, Chow L, Crouch S, Simunovic N, Sibilsky Enselman E, et al. Cartilage restoration of the knee: a systematic review and meta-analysis of level 1 studies. *Am J Sports Med*. (2016) 44:1888–95. doi: 10.1177/0363546515589167

33. DiBartola A, Wright B, Magnussen R, Flanigan D. Clinical outcomes after autologous chondrocyte implantation in adolescents' knees: a systematic review. *Arthroscopy*. (2016) 32:1905–16. doi: 10.1016/j.arthro.2016.03.007

34. Marlovits S, Striessnig G, Resinger CT, Aldrian SM, Vecsei V, Imhof H, et al. Definition of pertinent parameters for the evaluation of articular cartilage repair tissue with high-resolution magnetic resonance imaging. *Eur J Radiol*. (2004) 52:310–9. doi: 10.1016/j.ejrad.2004.03.014

35. de Windt T, Welsch G, Brittberg M, Vonk L, Marlovits S, Trattnig S, et al. Is magnetic resonance imaging reliable in predicting clinical outcome after articular cartilage repair of the knee? A systematic review and meta-analysis. *Am J Sports Med*. (2013) 41:1695–702. doi: 10.1177/0363546512473258

36. Versier G, Dubrana F. Treatment of knee cartilage defect in 2010. *Orthop Traumatol Surg Res*. (2011) 97:S140–53. doi: 10.1016/j.otsr.2011.09.007

37. Schreiner M, Raudner M, Röhrich S, Zalaudek M, Weber M, Kaiser G, et al. Reliability of the mocart (magnetic resonance observation of cartilage repair tissue) 2.0 knee score for different cartilage repair techniques-a retrospective observational study. *Eur Radiol*. (2021) 31:5734–45. doi: 10.1007/s00330-021-07688-1

38. Schreiner M, Raudner M, Marlovits S, Bohndorf K, Weber M, Zalaudek M, et al. The mocart (magnetic resonance observation of cartilage repair tissue) 2.0 knee score and atlas. *Cartilage*. (2021) 13:571S–87S. doi: 10.1177/1947603519865308

39. Erdle B, Herrmann S, Porichis S, Uhl M, Ghanem N, Schmal H, et al. Sporting activity is reduced 11 years after first-generation autologous chondrocyte implantation in the knee joint. *Am J Sports Med*. (2017) 45:2762–73. doi: 10.1177/0363546517716920

40. Kreuz P, Steinwachs M, Erggelet C, Lahm A, Krause S, Ossendorf C, et al. Importance of sports in cartilage regeneration after autologous chondrocyte implantation: a prospective study with a 3-year follow-up. *Am J Sports Med*. (2007) 35:1261–8. doi: 10.1177/0363546507300693

41. Zak L, Kleiner A, Albrecht C, Tichy B, Aldrian S. Third-generation autologous chondrocyte implantation at the knee joint using the igor scaffold: a case series with 2-year follow-up. *Orthop J Sports Med*. (2021) 9:2325967120969237. doi: 10.1177/2325967120969237

42. Niemeyer P, Laute V, Zinser W, Becher C, Kolombe T, Fay J, et al. A prospective, randomized, open-label, multicenter, phase iii noninferiority trial to compare the clinical efficacy of matrix-associated autologous chondrocyte implantation with spheroid technology versus arthroscopic microfracture for cartilage defects of the knee. *Orthop J Sports Med*. (2019) 7:2325967119854442. doi: 10.1177/2325967119854442

43. Azer N, Winalski C, Minas T. MR imaging for surgical planning and postoperative assessment in early osteoarthritis. *Radiol Clin North Am*. (2004) 42:43–60. doi: 10.1016/s0033-8389(03)00157-x

44. Samuelson E, Brown D. Cost-effectiveness analysis of autologous chondrocyte implantation: a comparison of periosteal patch versus type i/iii collagen membrane. *Am J Sports Med*. (2012) 40:1252–8. doi: 10.1177/0363546512441586

45. Saris D, Vanlauwe J, Victor J, Almqvist K, Verdonk R, Bellemans J, et al. Treatment of symptomatic cartilage defects of the knee: characterized chondrocyte implantation results in better clinical outcome at 36 months in a randomized trial compared to microfracture. *Am J Sports Med*. (2009) 37(Suppl 1):10S–9S. doi: 10.1177/0363546509350694

46. Niemeyer P, Uhl M, Salzmann G, Morscheid Y, Südkamp N, Madry H. Evaluation and analysis of graft hypertrophy by means of arthroscopy, biochemical mri and osteochondral biopsies in a patient following autologous chondrocyte implantation for treatment of a full-thickness-cartilage defect of the knee. *Arch Orthop Trauma Surg*. (2015) 135:819–30. doi: 10.1007/s00402-015-2194-x

47. Niemeyer P, Salzmann G, Hirschmüller A, Südkamp N. Factors that influence clinical outcome following autologous chondrocyte implantation for cartilage defects of the knee. *Z Orthop Unfall*. (2012) 150:83–8. doi: 10.1055/s-0030-1270894

48. Everhart J, Campbell A, Abouljoud M, Kirven J, Flanigan D. Cost-efficacy of knee cartilage defect treatments in the United States. *Am J Sports Med*. (2020) 48:242–51. doi: 10.1177/0363546519834557

49. Perera J, Gikas P, Bentley G. The present state of treatments for articular cartilage defects in the knee. *Ann R Coll Surg Engl*. (2012) 94:381–7. doi: 10.1308/003588412×13171221592573

50. Johnson L. Arthroscopic abrasion arthroplasty: a review. *Clin Orthop Relat Res*. (2001) (391 Suppl):S306–17. doi: 10.1097/00003086-200110001-00028

51. Kon E, Gobbi A, Filardo G, Delcogliano M, Zaffagnini S, Marcacci M. Arthroscopic second-generation autologous chondrocyte implantation compared with microfracture for chondral lesions of the knee: prospective nonrandomized study at 5 years. *Am J Sports Med*. (2009) 37:33–41. doi: 10.1177/0363546508323256

52. Nehrer S, Spector M, Minas T. Histologic analysis of tissue after failed cartilage repair procedures. *Clin Orthop Relat Res*. (1999) (365):149–62. doi: 10.1097/00003086-199908000-00020

53. Kreuz P, Kalkreuth R, Niemeyer P, Uhl M, Erggelet C. Treatment of a focal articular cartilage defect of the talus with polymer-based autologous chondrocyte implantation: a 12-year follow-up period. *J Foot Ankle Surg*. (2017) 56:862–4. doi: 10.1053/j.jfas.2017.03.001

54. Niemeyer P, Albrecht D, Andereya S, Angele P, Ateschrang A, Aurich M, et al. Autologous chondrocyte implantation (aci) for cartilage defects of the knee: a guideline by the working group "clinical tissue regeneration" of the German society of orthopaedics and trauma (dgou). *Knee*. (2016) 23:426–35. doi: 10.1016/j.knee.2016.02.001

55. Jia B, Yang H, Zhang Z, Qu X, Jia X, Wu Q, et al. Biodegradable zn-sr alloy for bone regeneration in rat femoral condyle defect model: in vitro and in vivo studies. *Bioact Mater*. (2021) 6:1588–604. doi: 10.1016/j.bioactmat.2020.11.007

56. Siebold R, Karidakis G, Feil S, Fernandez F. Second-look assessment after all-arthroscopic autologous chondrocyte implantation with spheroides at the knee joint. *Knee Surg Sports Traumatol Arthrosc*. (2016) 24:1678–85. doi: 10.1007/s00167-015-3822-2

57. Erggelet C, Kreuz P, Mrosek E, Schagemann J, Lahm A, Ducommun P, et al. Autologous chondrocyte implantation versus aci using 3d-bioresorbable graft for the treatment of large full-thickness cartilage lesions of the knee. *Arch Orthop Trauma Surg*. (2010) 130:957–64. doi: 10.1007/s00402-009-0957-y

58. Rosenberger R, Gomoll A, Bryant T, Minas T. Repair of large chondral defects of the knee with autologous chondrocyte implantation in patients 45 years or older. *Am J Sports Med*. (2008) 36:2336–44. doi: 10.1177/0363546508322888

59. Minas T, Gomoll A, Solhpour S, Rosenberger R, Probst C, Bryant T. Autologous chondrocyte implantation for joint preservation in patients with early osteoarthritis. *Clin Orthop Relat Res*. (2010) 468:147–57. doi: 10.1007/s11999-009-0998-0

frontiers | Frontiers in Surgery

TYPE Original Research
PUBLISHED 11 November 2022
DOI 10.3389/fsurg.2022.955651

Check for updates

OPEN ACCESS

EDITED BY
Paphon Sa-ngasoongsong,
Mahidol University, Thailand

REVIEWED BY
Shiyuan Fang,
The First Affiliated Hospital of University of Science and Technology of China Anhui Provincial Hospital, China
Dehao Fu,
Shanghai General Hospital, China

*CORRESPONDENCE
Gui Wu
wugui_1985@sina.com

†These authors have contributed equally to this work and share first authorship

SPECIALTY SECTION
This article was submitted to Orthopedic Surgery, a section of the journal Frontiers in Surgery

RECEIVED 29 May 2022
ACCEPTED 18 October 2022
PUBLISHED 11 November 2022

CITATION
Lin Z, Chen Y, Wang H, Lan W, Xie Y and Wu G (2022) A minimally invasive bipolar surgical approach for the treatment of patellar fracture using the tension-band wiring technique. Front. Surg. 9:955651. doi: 10.3389/fsurg.2022.955651

COPYRIGHT
© 2022 Lin, Chen, Wang, Lan, Xie and Wu. This is an open-access article distributed under the terms of the Creative Commons Attribution License (CC BY). The use, distribution or reproduction in other forums is permitted, provided the original author(s) and the copyright owner(s) are credited and that the original publication in this journal is cited, in accordance with accepted academic practice. No use, distribution or reproduction is permitted which does not comply with these terms.

A minimally invasive bipolar surgical approach for the treatment of patellar fracture using the tension-band wiring technique

Zhangxiong Lin†, Yaoqing Chen†, Hai Wang, Wenbin Lan, Yun Xie and Gui Wu*

Department of Orthopedics, First Affiliated Hospital, Fujian Medical University, Fuzhou, Fujian

Objective: Minimally invasive surgical techniques are becoming increasingly popular for the treatment of traumatic injuries. Although some minimally invasive techniques in the management of patellar fractures have been reported, the limited exposure in such methods may cause technical difficulties during surgery and restrict their wide application. In this context, this study aims to introduce a bipolar incision and assess the clinical outcomes of patellar fractures treated via this type of incision.

Materials and methods: Patients who suffered patellar fractures and who received surgical treatment via bipolar incision between 2018 and 2020 in our hospital were retrospectively reviewed and included in this study. The clinical and radiological records of all patients were reviewed. A classification of the fractures was done and intraoperative parameters, Visual Analog Scale (VAS) score, knee range of motion, and the Hospital for Special Surgery (HSS) knee score of the patients were evaluated and summarized.

Results: The study included 19 patients who met the inclusion criteria. All patellar fractures were operated through the minimally invasive bipolar surgical approach. The mean time of operation was 69.0 ± 8.5 min. The mean time to union was 12.8 ± 2.1 weeks. The average total knee range of motion was $131.8 \pm 4.4°$, and the average HSS score was 97.1 ± 2.6 at 1-year post-operation. No surgical-related complications were observed.

Conclusions: The knee functional outcomes were favorable when patellar fractures were treated through the minimally invasive bipolar incision method. This bipolar surgical approach was found to be a feasible method for treating patellar fractures.

KEYWORDS

minimally invasive surgical approach, patellar fracture, tension-band wiring, patella, knee scar

Introduction

The patella is located anteriorly to the knee joint and plays a key role in increasing the moment arm of the extensor mechanism. Patellar fractures account for approximately 1% of fractures in adults (1) and may result from direct or indirect injuries. Usually, a direct injury typically causes a comminuted patellar fracture, while an indirect injury may lead to

a transverse patellar fracture. Moreover, patellar fracture can present more fracture patterns due to the mechanism of combined injuries. The main objective behind the treatment of patellar fracture includes a restoration of the following: bone integrity, articular congruity of the patella, and also the function of the extensor mechanism.

The surgical indications for patellar fracture include a fracture separation greater than 2–4 mm, an articular incongruity greater than 2–3 mm, an incompetent extensor mechanism, and intra-articular loose bodies (2). Open reduction with internal fixation via the midline longitudinal incision over the patella is the most common treatment option for patellar fractures (3). Other surgical approaches include the median parapatellar approach and the lateral parapatellar approach (4, 5). Although these open surgical approaches can provide a good visualization of the patella and subsequently minimize the difficulty involved in the technique of reduction of bone fracture, they have some disadvantages such as surgical-related soft tissue injuries, destruction of the patellar blood supply, and reduced patient satisfaction due to the generation of a long surgical scar in front of the knee.

To overcome these drawbacks of open surgeries, minimally invasive surgeries with the advantages of fast recovery, few soft tissue injuries, and smaller surgical scars are being attempted and they are becoming increasingly popular. Some minimally invasive surgeries for patellar fractures have been reported recently. Shao et al. introduced a minimally invasive surgical technique for fixing a transverse patellar fracture by using the Zimmer® Cable-Ready® Cable Pin System (6). They found that minimally invasive surgeries produced better clinical outcomes in terms of knee function and pain in comparison with open surgeries. Akhilesh et al. performed a percutaneous tension-band wiring technique for patellar fractures. Although percutaneous tension-band wiring is a viable option for transverse patellar fractures, it is a technical challenge for the orthopedic surgeon (7).

In this study, we introduce a minimally invasive surgical approach, in which two 2 cm–3 cm paralleled incisions approximately 1 cm above the superior pole and 1 cm below the inferior pole of the patella are made to perform reduction and fixation, respectively, for patellar fractures. As the incision locates in the two poles of the patellar, we would like to call it a "bipolar incision" in brief. This study aims to introduce the bipolar incision method and assess the clinical outcomes of patellar fractures treated via this method.

Materials and methods

Patient selection

Patients who suffered patellar fractures and who received surgical treatment between 2018 and 2020 in our hospital were retrospectively reviewed. The ethics committee of our hospital approved the study protocol (approval number: [2015]084-1). The study was performed according to the principles outlined in the Declaration of Helsinki. Informed consent was obtained from all of the study participants. The indications for the bipolar incision were a transverse patella fracture with a displacement of >2 mm; the fracture could be fixed with a tension band and with Kirschner wires and a reduction of the displacement could be achieved by making an incision, with the surgeon's experience also being a major factor in this. To reflect the true outcome of surgery, only those patients with normal knee function prior to injury and fresh closed fractures were included. Thus, the inclusion criteria were as follows: unilateral patellar fractures that were treated via bipolar incision; the knee function should be normal before the injury, with no other combined injuries; the technique of fixation should be tension-band wiring; there should be at least a 1-year follow-up. The exclusion criteria were as follows: open fracture; old fracture >2 weeks; a previous history of knee surgeries; complications arising from disease conditions, such as liver or renal failure, immunodeficiency or coagulation dysfunction and so on, which may affect the clinical outcomes of patellar fracture surgery.

Surgical procedure and postoperative rehabilitation

The surgical procedures were as follows. After spinal or general anesthesia, the patients were placed on the operating table. A pneumatic tourniquet was routinely applied at the base of the thigh. After sterilization of the leg, two 2 cm–3 cm paralleled incisions approximately 1 cm above the superior pole and 1 cm below the inferior pole of the patella were made to expose the quadriceps and patellar ligament (**Figures 1A,B**). Two two-pointed bone forceps were utilized to close the fracture gap from the medial and lateral sides of the patella. If the articular step-off was not well reduced, a small periosteal elevator was used to facilitate the reduction of bone fracture via insertion through the patellar ligament or the quadriceps to reach the articular surface of the bone fragments (**Figure 2**). After the closed reduction of the fracture, two Kirschner wires were passed through the fracture fragments from the incision. Two longitudinal incisions in the quadriceps were made around the two K-wires and extended to the superior pole of the patella. Also, the other two longitudinal incisions were made in the patella tendon around the K-wires and extended to the inferior pole of the patella, as described by Yan et al. (8). A wire passer or lumbar puncture needle was utilized to introduce the titanium cable subcutaneously. One titanium cable (Cable Grip System, Zimmer) was passed through the quadriceps and patellar tendons and behind the K-wires to form a circle and a figure 8, as shown in **Figures 1C,D** and **Figure 3**. In some non-comminuted transverse patellar fractures, the cable was only

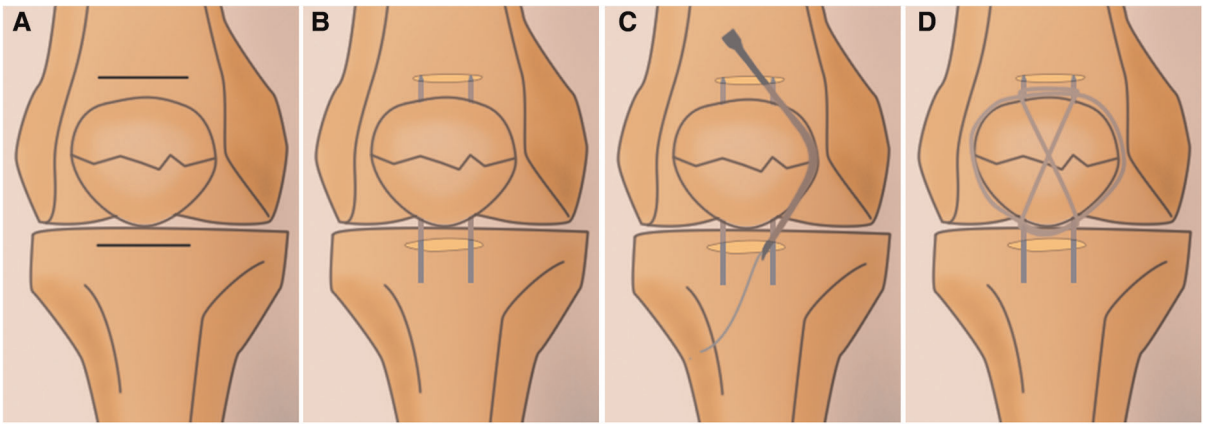

FIGURE 1
Diagrams show the main surgical procedures of the minimally invasive surgical technique. (A) Two paralleled incisions approximately one centimeter above and below the patella are made. (B) After a closed reduction of the fracture, two Kirschner wires are passed through the fracture fragments from the incision. (C) A wire passer or lumbar puncture needle is utilized to introduce the titanium cable subcutaneously. (D) The outcome of the fixation.

crossed over the front of the patella to form a figure 8, while the additional circle was not needed as shown in Figure 4. After the cable was locked, the Kirschner wire was cut and bent. The incisions in the quadriceps, patellar tendons, and skin were closed.

After closed reduction and stable fixation of the patellar fracture, the patients were encouraged to begin progressive exercises. On the first day after surgery, the patients were allowed to do quadriceps isometric exercises and passive flexion of the knee joint at 30°. On postoperative days 2–5, straight-leg-raising exercises were performed by the patients and also active flexion and extension of the knee joint was done to reach a 90° range of motion (ROM). Active knee exercises were continued until the recovery of knee function.

Clinical and radiological assessment

The clinical and radiological records of all patients were reviewed. The mechanisms of injuries were analyzed. The classification of the patellar fracture was done based on the AO/OTA fracture and dislocation classification compendium-2018. The operation time, injured side, and blood loss during the operation were recorded. The Visual Analog Scale (VAS) scores of the knee at 45°and 90° flexion at postoperative day 5 and day 10 were assessed. The ROM and the modified Hospital for Special Surgery (HSS) knee score of the knee joint were assessed 1 year after surgery. At each outpatient visit, the patients were assessed clinically and radiographically. Radiographic union was defined as the disappearance of the fracture line, which was determined by the surgeons. Wound infection, skin flap necrosis, and failure of internal fixation were recorded.

Statistical analysis

Statistical analysis was performed using SPSS (SPSS Inc., Chicago, IL, USA). Data were shown as means ± standard deviation. Owing to the retrospective and observational nature of this study, all data included in the study must be seen as only explorative and descriptive.

Results

Preoperative assessment

A total of 19 patients were included in this study. The demographic data of the patients are given in Table 1. The average age of the patients was 54.9 ± 16.4 years. There were 10 male and 9 female patients. A total of 8 fractures occurred on the left patella, while there were 11 fractures on the right patella. There were 12 cases of falls, while 7 were traffic accident cases. The average time for surgery after fracture was 3.4 ± 1.5 days. According to the AO/OTA fracture and dislocation classification compendium-2018, 11 patellar fractures were classified as 34C1 and 8 were classified as 34C2.

Intraoperative situation

All 19 patients were treated via the minimally invasive surgical approach. Separation of the bone fractures could usually be reduced through a closed reduction technique by using two-pointed forceps. While in some cases, articular step-off could not be reduce with the use of two-pointed

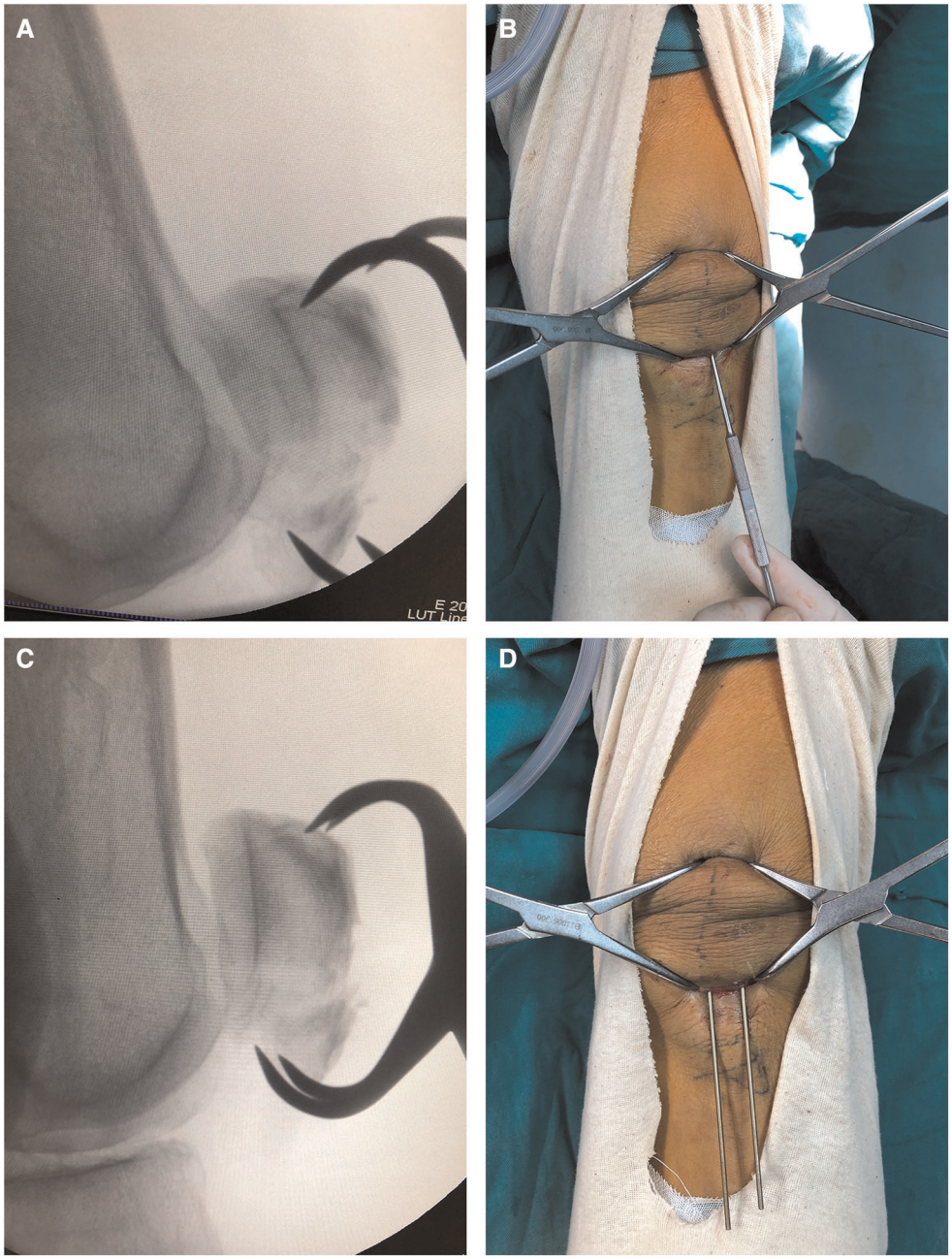

FIGURE 2
Joint application of periosteal elevator and pointed bone forceps helps achieve bone fracture reduction. (A) Radiograph taken after the initial reduction procedure reveals that fracture reduction was not achieved as the articular step-off still presented. (B) Photograph shows that a small periosteal elevator is passed through the patellar tendon to reach the articular surface of the distal bone fragments and elevate it, and then, two-pointed bone forceps were utilized to close the fracture gap. (C) Radiograph taken after the reduction procedure confirmed that the fracture was reduced. (D) Photograph shows two k-wires passing through the fracture to maintain the fracture reduction.

forceps, as shown in Figure 2A, a small periosteal elevator proved helpful in the reduction, as shown in Figures 2B–D. The two transverse incisions could provide sufficient exposure for the fixation of tension-band wiring. The mean time of the operation was 69.0 ± 8.5 min, and the average volume of blood loss was 50.5 ± 11.8 ml.

Radiographic and functional outcomes

All patients underwent a regular follow-up in the clinic. The mean time of the follow-up was 17.1 ± 4.0 months. Postoperative radiographs confirmed that each patellar fracture was well reduced and properly fixed. No implant

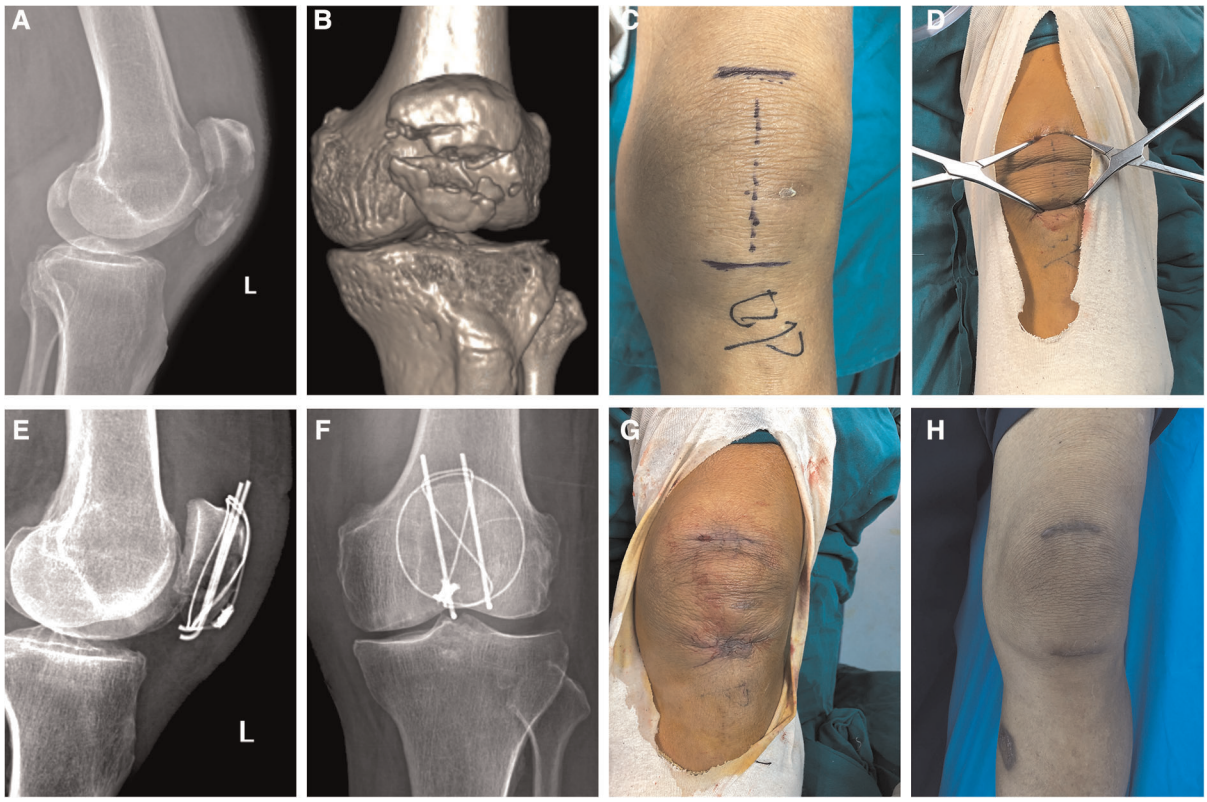

FIGURE 3
Radiographs and photographs of the knee of a 73-year-old male patient who suffered patellar fracture and received surgical treatment via the minimally invasive technique. (A) Lateral view of a preoperative radiograph of the knee joint. (B) 3D reconstruction image of patellar computer tomography scanning. (C) Photograph of an incision mark. (D) Two-pointed bone reduction forceps were applied to reduce the fracture displacement. (E) Lateral view of a postoperative radiograph of the knee joint reveals good bone reduction. (F) Anteroposterior view of a postoperative radiograph of the knee joint. (G) Photograph of an incision taken immediately after surgery. (H) Photograph of an incision taken in the third month after surgery.

failure such as breakage of the titanium cable or loosening of Kirschner wires, was observed at the radiographic follow-up. The radiograph of the last follow-up revealed that bone fractures were healed and the fracture lines disappeared in all patients. The mean time to union was 12.8 ± 2.1 weeks. The VAS score, HSS score, and the knee range of motion assessment are summarized in Table 2.

TABLE 1 Patient demographics and intraoperative data.

Parameter	$N = 19$
Sex	
Male	10
Female	9
Average age (years)	54.9 ± 16.4
Cause of injury	
Fall	12
Traffic accidents	7
Classification	
34C1	11
34C2	8
Mean time of operation (min)	69.0 ± 8.5
Average volume of blood loss (ml)	50.5 ± 11.8

TABLE 2 Postoperative pain and knee function assessment.

Parameter	$N = 19$
[a]VAS score/5 days	
45°	4.3 ± 0.9
90°	5.9 ± 0.8
VAS score/10 days	
45°	3.1 ± 0.8
90°	4.4 ± 0.7
HSS	97.1 ± 2.6
Total Knee [a]ROM (°)	
2 weeks [a]PO	96.1 ± 7.8
12 weeks PO	120.5 ± 5.6
1 years PO	131.8 ± 4.4

[a]ROM, range of motion; VAS, visual analog scale; PO, postoperation.

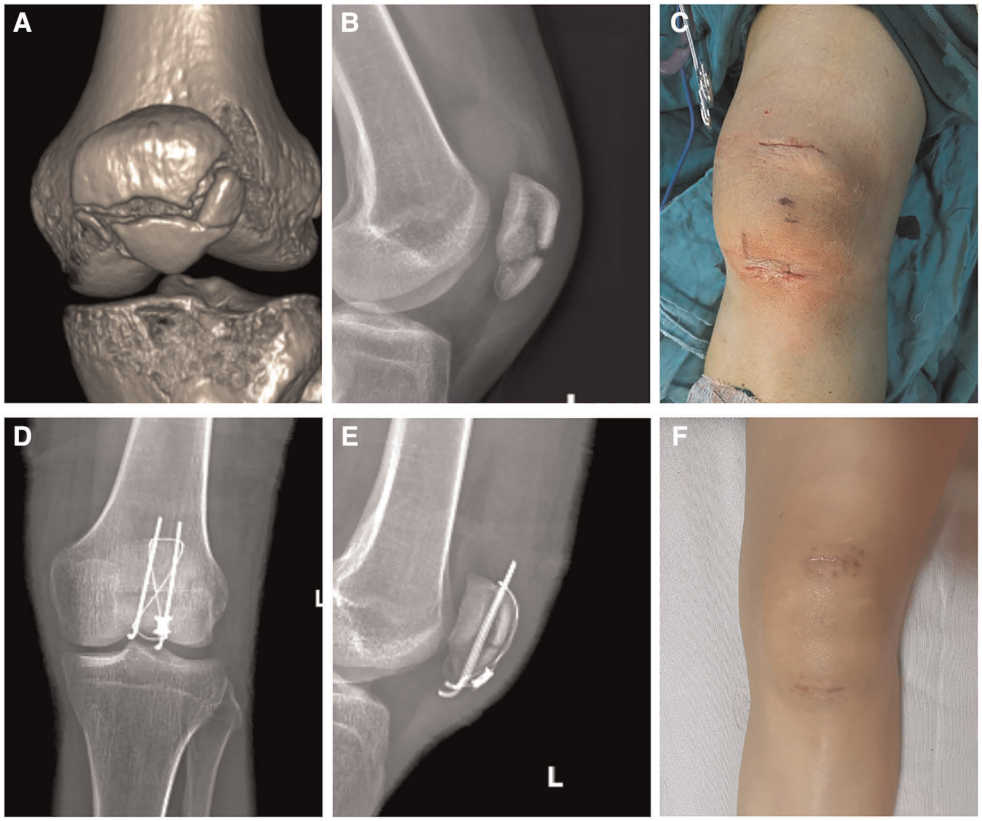

FIGURE 4
A 32-year-old female patient suffered patellar fracture in a traffic accident and was operated by using the minimally invasive technique. (A) 3D reconstruction image of patellar computer tomography scanning shows the patellar fracture. (B) Lateral view of a preoperative radiograph of the patella. (C) Photograph of an incision taken immediately after surgery. (D) Anteroposterior view of a postoperative radiograph of the knee joint. (E) Lateral view of the same radiograph shows anatomic reduction. (F) Photograph of an incision taken in the fourth month after surgery.

Complications

No surgical-related complications such as neurovascular injuries, wound infection, or cutaneous necrosis occurred perioperatively. All fractures healed successfully, and no implant failure was observed.

Discussion

The patella, as the largest sesamoid bone in the body, plays an important role in increasing the lever arm of the quadriceps extensor mechanism. A patellar fracture can be caused by both direct trauma and an indirect traumatic mechanism. Numerous fixation techniques and materials have been applied for patellar fractures that require surgery, such as tension bands, cerclage wiring, suture repair, and osteosynthesis with plates and screws. The most frequent patellar fractures are transverse fractures (6, 9). Open reduction and internal fixation with tension bands and Kirschner wires is still the most widely used technique for repairing transverse fractures (10–12). Nevertheless, the classic open approach may lead to a certain amount of wound complications, which include postoperative adhesions, wound infections, and non-cosmetic scars (13, 14). To overcome these drawbacks of the open approach, we treated the patellar fractures in our patients through a more minimally invasive approach, which was by making two paralleled incisions above and below the patella. We could perform the techniques of reduction of fractures as well as internal fixation by placing a tension band and Kirschner wires on the two skin windows successfully. The incision was in the same direction as the skin texture and was smaller than the classic open approach. Therefore, the incision led to the formation of only small scars in front of the knee, which resulted in improved patient satisfaction. Postoperative pain and knee function assessment revealed that the outcome of the patellar fractures treated via the new approach was favorable.

Minimally invasive surgical techniques are becoming increasingly popular for the treatment of traumatic injuries

(15, 16). These methods have the advantages of causing decreased injuries to the soft tissue, preserving blood supply, producing only cosmetic surgical scars, and ensuring speedy recovery. Many minimally invasive techniques have been reported for the treatment of patellar fractures. Rathi et al. (7) introduced a percutaneous tension-band wiring technique for such fractures. Both reduction and fixation of fractures were performed percutaneously. Although it was a viable option, it was technically challenging, because the procedure of cutting and bending Kirschner wires as well as burying the knot might cause difficulties for the surgeon. Vicenti et al. (13) managed transverse patellar fractures in elderly patients with a minimally invasive osteosynthesis technique. In their surgical procedure, a 1 cm incision was made at the superolateral border of the patella to introduce steel wires, and other procedures were performed percutaneously. The additional incision could reduce the difficulty of surgery. Shao et al. (6) also reported their work on the treatment of patellar fractures via a minimally invasive surgical technique and fixation with the Cable Pin System and found that this surgical technique could provide better clinical results and improved knee function than open surgery. Although many studies concluded that minimally invasive techniques had better clinical outcomes, the limited exposure in such methods usually led to increased technical difficulties during surgery and restricted their wide application. Therefore, it became necessary to find a way to repair fractures with a minimally invasive incision but also with one that caused limited problems. Although the bipolar incision technique resulted in larger scars than the complete percutaneous technique and the semipercutaneous technique introduced by Shao et al. (6), it could expose the inferior and superior poles of the patella and facilitate the reduction procedure with two-pointed forceps. In addition, it could make the process of cutting and bending Kirschner wires easier so as to avoid leaving too long wires in the soft tissue, which may potentially lead to postoperative soft tissue irritation. In this study, none of the patients encountered hardware related complications such as irritation of the skin, as raised by Vicenti et al. (13), who carried out surgery through the percutaneous technique. Two incisions reduced the technical difficulty of the surgery, this incision was applicable for the treatment of a more complicated patellar fracture displacement.

Although the tension-band wiring technique is the most common fixation technique for patellar fracture, the impact of technical issues on the outcome cannot be ignored. The interposition of soft tissue between the patella and the tension band may weaken the compression force and lead to a higher failure rate (17). Additional incision-making in the patellar tendon and the quadriceps tendon of the upper and lower poles of the patella where the Kirschner wire passes through can help eliminate the soft tissue interposition between the titanium cable and the bone, which will subsequently improve the clinical outcomes and knee function (8). In the current surgical approach, the two incisions could provide sufficient exposure to perform the above procedures to place the tension-band wire as close as possible to the bone. Moreover, although a figure-of-8 fashion tension-band wire was adequate for most transverse patellar fractures, the modified tension-band technique, which is a combination of cerclage and the tension band, could provide a greater strength of fixation and allow early mobilization (8, 18, 19). By using a lumbar puncture needle, we could introduce the titanium cable subcutaneously to do the modified tension-band fixation for a comminuted patellar fracture. Thus, this minimally invasive surgical approach was feasible to make an ideal tension-band fixation for patellar fracture.

Bone fractures could not be visualized directly through the minimally invasive surgical approach. Thus, sufficient preoperative assessment of the bone fracture was essential. Anteroposterior x-ray radiograph was of only limited value for making a judgment on bone fracture displacement as the patella is overlapped with the femur. Three-dimensional reconstruction images of computerized tomography could help us understand the patellar fracture better and was useful for preoperative planning. An intraoperative x-ray radiograph was routinely applied to view the reduction and fixation of fractures. Nevertheless, arthroscopy could help make a more precise evaluation of fragment reduction (20). Although in some patients, the primary reduction of the bone fracture using two-pointed forceps failed, the reduction could finally be achieved by using the Kirschner wire joy-stick technique or a mall periosteal elevator.

This study had some limitations. The fracture displacements of all cases were finally reduced successfully. No failed fracture reduction was observed which might be due to the small sample size. Thus, experience in the management of patients with failed fracture reduction could not be provided. Patients with failed fracture reduction might need the assistance of arthroscopy based on literature potentially. No complications could be identified due to the small sample size and short follow-up time. Thus, going forward, longer follow-ups are required. No control group was included in this study. Therefore, we should not attribute the good functional outcome solely to the new surgical approach. Nevertheless, our findings showed that the minimally invasive surgical approach presented in this study was a feasible method for treating patella fractures.

To sum up, the minimally invasive bipolar incision method could decrease the technical difficulties associated with minimally invasive surgery for patellar fractures. This type of incision could provide sufficient exposure for fracture reduction and internal fixation. The favorable clinical outcomes revealed that the bipolar surgical approach was a feasible method for repairing patellar fractures.

Data availability statement

The raw data supporting the conclusions of this article will be made available by the authors without undue reservation.

Ethics statement

The studies involving human participants were reviewed and approved by Ethics Review Form for the Branch for Medical Research and Clinical Technology Application, Ethics. Committee of First Affiliated Hospital of Fujian Medical University. The patients/participants provided their written informed consent to participate in this study.

Author contributions

All authors contributed to the conception and design of the study. Material preparation, data collection, and analysis were done by ZL, YC, HW, WL, and YX. The first draft of the manuscript was written by GW. All authors contributed to the article and approved the submitted version.

Conflict of interest

The authors declare that the research was conducted in the absence of any commercial or financial relationships that could be construed as a potential conflict of interest.

Publisher's note

All claims expressed in this article are solely those of the authors and do not necessarily represent those of their affiliated organizations, or those of the publisher, the editors and the reviewers. Any product that may be evaluated in this article, or claim that may be made by its manufacturer, is not guaranteed or endorsed by the publisher.

References

1. Schuett DJ, Hake ME, Mauffrey C, Hammerberg EM, Stahel PF, Hak DJ. Current treatment strategies for patella fractures. *Orthopedics*. (2015) 38 (6):377–84. doi: 10.3928/01477447-20150603-05

2. Hargett DI, Sanderson BR, Little MTM. Patella fractures: approach to treatment. *J Am Acad Orthop Surg*. (2021) 29(6):244–53. doi: 10.5435/jaaos-d-20-00591

3. Kakazu R, Archdeacon MT. Surgical management of patellar fractures. *Orthop Clin North Am*. (2016) 47(1):77–83. doi: 10.1016/j.ocl.2015.08.010

4. Yoon YC, Sim JA, Hong JH. Surgery of patellar fractures using a medial parapatellar approach. *J Orthop Surg (Hong Kong)*. (2017) 25(2): 2309499017719378. doi: 10.1177/2309499017719378

5. Gardner MJ, Griffith MH, Lawrence BD, Lorich DG. Complete exposure of the articular surface for fixation of patellar fractures. *J Orthop Trauma*. (2005) 19(2):118–23. doi: 10.1097/00005131-200502000-00008

6. Shao J, Wang J, Chen Y, Mao N, Zhang Q, Ni H. Comparison of a minimally invasive surgical technique with open surgery for transverse patella fractures. *Exp Ther Med*. (2019) 18(6):4203–8. doi: 10.3892/etm.2019.8078

7. Rathi A, Swamy MK, Prasantha I, Consul A, Bansal A, Bahl V. Percutaneous tension band wiring for patellar fractures. *J Orthop Surg (Hong Kong)*. (2012) 20 (2):166–9. doi: 10.1177/230949901202000206

8. Yang X, Wu Q, Xie Z, Wang X. Comparison of a modified technique with conventional tension-band using cable grip system for comminuted Patella fractures. *Injury*. (2020) 51(2):457–65. doi: 10.1016/j.injury.2019.09.037

9. Tian QX, Hai Y, Du XR, Xu ZY, Lu T, Shan L, et al. Comparison of tension-band wiring with the cable pin system in Patella fractures: a randomized prospective study. *J Orthop Trauma*. (2015) 29(12):e459–63. doi: 10.1097/bot.0000000000000400

10. Avery MC, Jo S, Chang A, Ricci WM, McAndrew C, Miller AN, et al. Cannulated screw prominence in tension band wiring of Patella fractures increases fracture gapping: a cadaver study. *Clin Orthop Relat Res*. (2019) 477 (5):1249–55. doi: 10.1097/corr.0000000000000683

11. Henrichsen JL, Wilhem SK, Siljander MP, Kalma JJ, Karadsheh MS. Treatment of Patella fractures. *Orthopedics*. (2018) 41(6):e747–e55. doi: 10.3928/01477447-20181010-08

12. Gwinner C, Märdian S, Schwabe P, Schaser KD, Krapohl BD, Jung TM. Current concepts review: fractures of the Patella. *GMS Interdiscip Plast Reconstr Surg DGPW*. (2016) 5:Doc01. doi: 10.3205/iprs000080

13. Vicenti G, Bizzoca D, Nappi VM, Carrozzo M, Miolla MP, Ottaviani G, et al. Minimally invasive osteosynthesis technique in the treatment of transverse patellar fractures in the elderly. *Injury*. (2020) 51(Suppl 3):S50–s5. doi: 10.1016/j.injury.2020.01.012

14. Mao N, Liu D, Ni H, Tang H, Zhang Q. Comparison of the cable pin system with conventional open surgery for transverse Patella fractures. *Clin Orthop Relat Res*. (2013) 471(7):2361–6. doi: 10.1007/s11999-013-2932-8

15. Azar FM. Minimally invasive surgery: is less more? *Orthop Clin North Am*. (2020) 51(3):xiii–xiv. doi: 10.1016/j.ocl.2020.04.001

16. Lin T, Xiao B, Ma X, Fu D, Yang S. Minimally invasive plate osteosynthesis with a locking compression plate is superior to open reduction and internal fixation in the management of the proximal humerus fractures. *BMC Musculoskelet Disord*. (2014) 15:206. doi: 10.1186/1471-2474-15-206

17. Hsu KL, Chang WL, Yang CY, Yeh ML, Chang CW. Factors affecting the outcomes of modified tension band wiring techniques in transverse patellar fractures. *Injury*. (2017) 48(12):2800–6. doi: 10.1016/j.injury.2017.10.016

18. Curtis MJ. Internal fixation for fractures of the Patella. A comparison of two methods. *J Bone Joint Surg Br*. (1990) 72(2):280–2. doi: 10.1302/0301-620x.72b2.2312569

19. Xue Z, Qin H, Ding H, Xu H, An Z. Two-tension-band technique in revision surgery for fixation failure of patellar fractures. *Med Sci Monit*. (2016) 22:2736–41. doi: 10.12659/msm.899753

20. Cerciello S, Cote M, Lustig S, Dyrna F, Pauzenberger L, Neyret P, et al. Arthroscopically assisted fixation is a reliable option for patellar fractures: a literature review. *Orthop Traumatol Surg Res*. (2017) 103(7):1087–91. doi: 10.1016/j.otsr.2017.04.010

frontiers | Frontiers in Surgery

TYPE Case Report
PUBLISHED 11 November 2022
DOI 10.3389/fsurg.2022.994204

Check for updates

OPEN ACCESS

EDITED BY
Paphon Sa-ngasoongsong,
Mahidol University, Thailand

REVIEWED BY
Balaji Zacharia,
Government Medical College, India
Savas Sencan,
Marmara University, Turkey

*CORRESPONDENCE
Xiaoxu Wang
wxx1024.163.com
Mingjun Qiu
904072774@qq.com

†These authors have contributed equally to this work and share first authorship
‡These authors have contributed equally to this work

SPECIALTY SECTION
This article was submitted to Orthopedic Surgery, a section of the journal Frontiers in Surgery

RECEIVED 14 July 2022
ACCEPTED 03 October 2022
PUBLISHED 11 November 2022

CITATION
Guo W, Hui M, Yang Y, Wan T, Zeng Guang-Gui, Huang P, Wang X and Qiu M (2022) Case report of old anterior dislocation of the shoulder joint and review of the literature.
Front. Surg. 9:994204.
doi: 10.3389/fsurg.2022.994204

COPYRIGHT
© 2022 Guo, Wan, Zeng, Yang, Huang, Wang and Qiu. This is an open-access article distributed under the terms of the Creative Commons Attribution License (CC BY). The use, distribution or reproduction in other forums is permitted, provided the original author(s) and the copyright owner(s) are credited and that the original publication in this journal is cited, in accordance with accepted academic practice. No use, distribution or reproduction is permitted which does not comply with these terms.

Case report of old anterior dislocation of the shoulder joint and review of the literature

Weiming Guo[1†], Ming Hui[1†], Yuan Yang[2†], Teng Wan[3], Guang-Gui Zeng[3], Peiguan Huang[2], Xiaoxu Wang[2*‡] and Mingjun Qiu[2*‡]

[1]Sports Medicine Department, Huazhong University of Science and Technology Union Shenzhen Hospital; the 6th Affiliated Hospital of Shenzhen University Health Science Center, Shenzhen, China, [2]The Second Affiliated Hospital, Department of Orthopaedic Surgery, Hengyang Medical College, University of South China, Hengyang, Hunan, China, [3]Hengyang Medical College, University of South China, Hengyang, China

Background: Dislocation of the shoulder joint is the most common type of joint dislocation. It is rare to be in a persistent dislocation that has not been reset. Successful arthroscopic treatment of the obsolete shoulder is relatively uncommon.
Case report: We report a rare case of persistent anterior dislocation of the old shoulder joint in a 30-year-old female patient. The patient underwent an emergency shoulder dislocation at a local hospital after a traumatic injury and re-dislocated persistently after surgery. 26 days later, she was admitted to our department for treatment, mainly because of joint deformity and limitation of motion. We adopted arthroscopic release and repositioning surgery. The patient was followed up for 1 year after surgery. Functional recovery was satisfactory.
Conclusion: The state of obsolete shoulder dislocation rarely occurs after shoulder dislocation and the prognosis of the patient is good after complete arthroscopic release and repositioning. It provides a reference for clinical arthroscopic treatment of old shoulder dislocations.

KEYWORDS
anterior shoulder dislocation, arthroscopy, traumatic, surgery, case

Introduction

The shoulder joint mainly includes the glenohumeral, acromioclavicular, sternoclavicular and scapulothoracic brachial joints; and shoulder dislocation mainly refers to the glenohumeral joint and is the most common joint dislocation seen by orthopaedic surgeons in emergency situations, reported to occur in 8.2–23.9 per 100,000 people per year (1–4). And anterior dislocations account for 98% of all shoulder dislocations (5, 6). Shoulder dislocations are more common in younger age groups who are active in sports and daily activities (7). The diagnosis of acute dislocation is uncomplicated in patients who have obvious symptoms associated with the dislocated joint with significant deformity and are able to be seen promptly. However, patient negligence in seeking post-traumatic care and patient failure to present promptly result in rare old undisplaced shoulder dislocations. They are often

difficult to reposition by closed resetting and usually require surgical intervention to reposition and stabilise the joint. The treatment options for old anterior shoulder dislocations are unclear (8). In the case described here, a patient with a traumatic old unresolved anterior shoulder dislocation was presented. The patient did not receive further treatment as multiple resetting after the injury had failed, however, prolonged pain, deformity and dysfunction led to admission to our hospital for further consultation. We therefore report this and review the relevant literature.

Case reports

A 30-year-old female patient complained of right shoulder deformity and pain with limited movement for 26 days, and it affected his appearance. The patient suffered a painful deformity and limited movement of the right shoulder as a result of a motorcycle fall 26 days ago. He was admitted to the local hospital as an emergency. x-ray showed anterior dislocation of the right shoulder joint and fracture of the greater tuberosity of the humerus. Totally, he was admitted to the local hospital for three times of intermittent and consecutive manipulation and repositioning of the right shoulder joint (**Figures 1A,B**). The patient was in good health with no history of chronic disease. Physical examination found a square shoulder deformity, subacromial hollowing and slight pressure pain on the lateral aspect of the shoulder peak. Joint mobility was examined with active abduction of up to 45°, anterior flexion of about 60°, posterior extension of about 5°, lateral external rotation of about 0°, and internal rotation flat at the level of the greater tuberosity. Passive activity range is the same as active. The patient had a flexible fixed shoulder joint, Dugas sign (+) and could not cooperate with special examinations. The preoperative VAS score was 4 and the ASES score was 7 (**Figure 2**). Laboratory tests revealed no abnormalities. x-ray showed anterior subluxation of the right humeral head and fracture of the greater

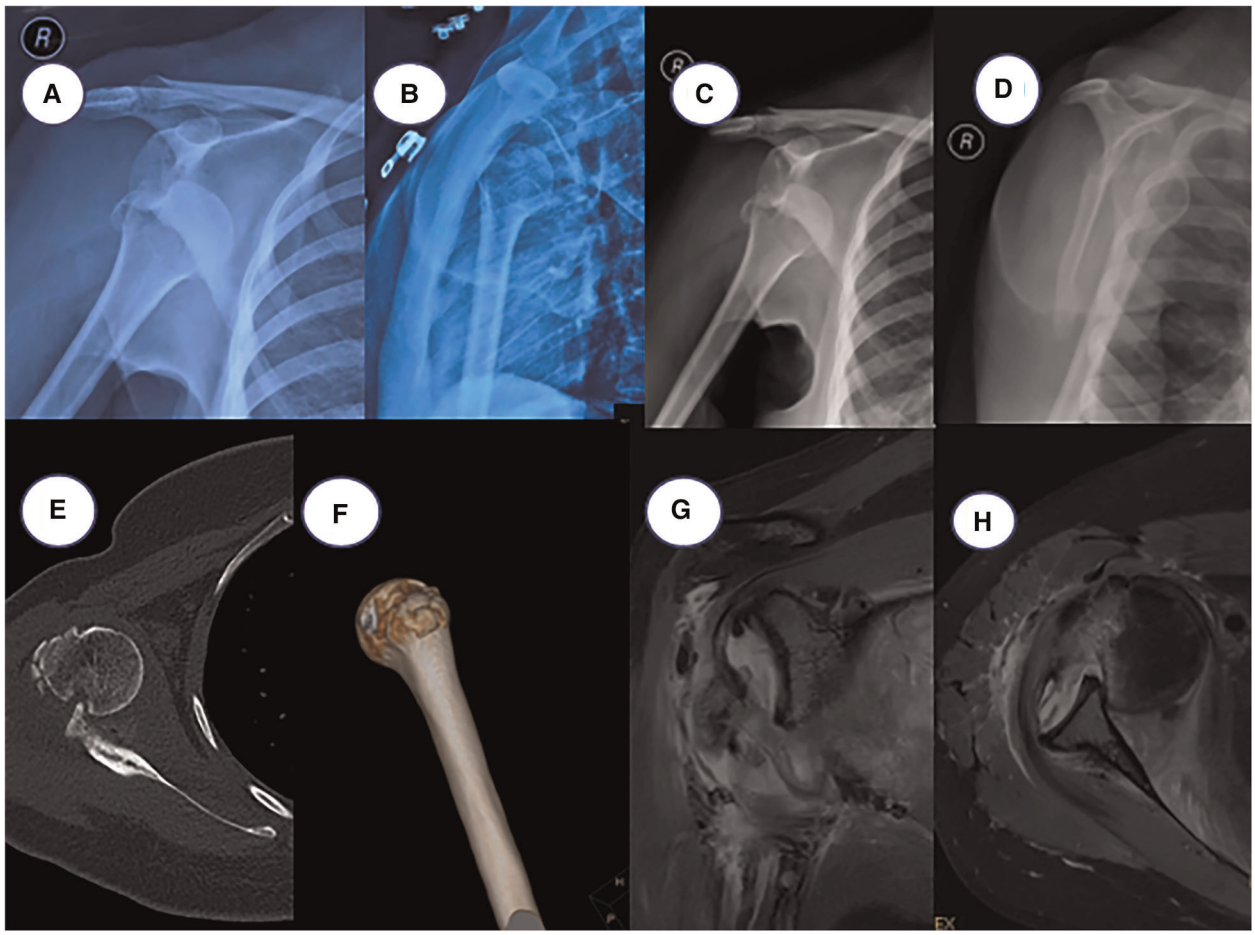

FIGURE 1
(A,B) postoperative x-ray after external emergency repositioning, (C,D) preoperative x-ray, (E,F) preoperative CT film, (G,H) preoperative MRI.



FIGURE 2
Preoperative physical examination for shoulder joint mobility in all directions.

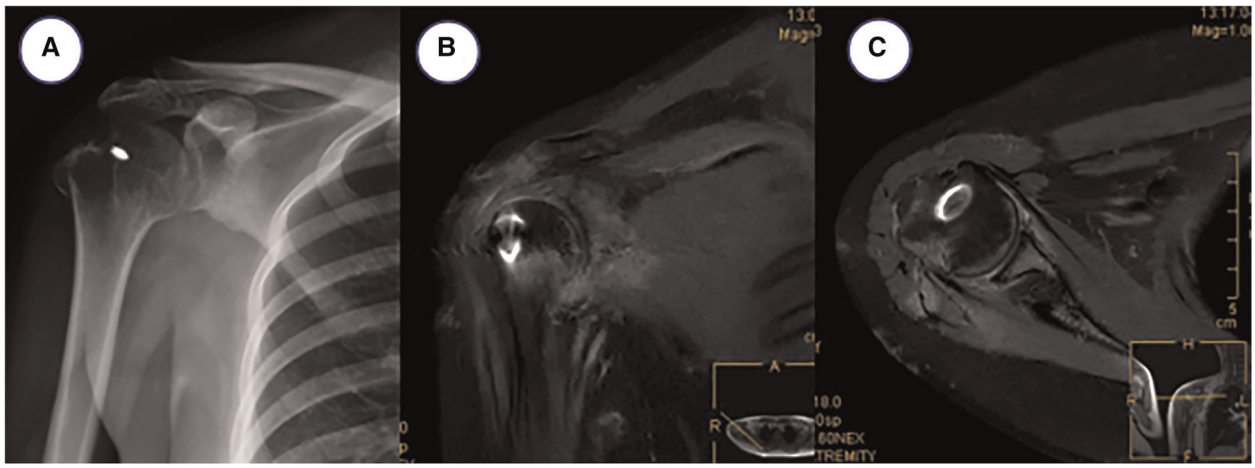

FIGURE 3
Postoperative reexamination. (A) x-ray orthopantomogram, (B,C) MRI images.

tuberosity of the humerus (Figures 1C,D). CT showed additional Hill-Sachs injury of the humeral head (Figures 1E, F). MRI showed continuous supraspinatus and infraspinatus tendons and injury of the anterior inferior glenoid lip (Figures 1G,H). The neuromyogram was normal. Vascular ultrasound of the upper extremity showed no abnormalities.

In view of the rare clinical reports of old shoulder dislocations, there is no uniform treatment plan. After preoperative discussion in the whole department, a decision was made to adopt limited duration surgical treatment (Table 1). After general anesthesia, manual repositioning was attempted, and minimally invasive arthroscopic treatment was adopted after repositioning failed. The joint was released in the order of intra-articular-subacromial-intra-articular. Intraoperatively, scar tissue filling of the humeral glenoid joint was seen and the shoulder joint was unsuccessfully repositioned after cleaning.

The posterior defect of the humeral head was seen to be embedded with the anterior glenoid, then the subacromial crest was entered arthroscopically and the subacromial bursa tissue was removed, the supraspinatus and infraspinatus tendons were continuous and in satisfactory tension, the greater humeral tuberosity was stable and no further treatment was undertaken. The rotator cuff gap and subscapularis were then released subacromially, and the humeral head was gradually repositioned after satisfactory release under anterior surveillance. The arthroscope was reentered into the joint cavity, the subscapularis muscle was

TABLE 1 Pre-operative discussion options.

Period of surgery	a. limited-term surgery? b. elective surgery
Surgical approach	a. Minimally invasive treatment attempted first? b. Minimally invasive failure and incisional repositioning?
How to loosen and reset	a. Why did all 3 resetting attempts fail? b. What are the factors that prevent reset? c. Release sequence: intra-articular? Subacromial space? Other?
How Hill-Sachs injuries are treated.	a. Sub-ganglionic tendon filling? b. Bone grafting?
Are large nodules fixed.	a. Reset and fixation? b. Conservative treatment?
How to stabilise the joint after release.	a. Anchor nailing for joint capsule repair? b. Clinically fixed? c. Soft tissue balance?

released posteriorly, the injured glenoid lip was repaired and the humeral head was repositioned to the centre of the articular glenoid without external force. the Hill-Sachs injury was filled with the infraspinatus tendon. The final anterior and posterior rotator cuff tension of the shoulder was satisfactory and the shoulder was fixed with a postoperative abduction pack. The postoperative rehabilitation program included brace-assisted immobilization on the second day after surgery and the initiation of passive functional exercises, including anterior flexion and external rotation. 6 weeks later the brace was removed and active functional exercises were initiated. Regular outpatient follow-up. At 1 year post-operative follow-up, the right shoulder joint showed no difference in morphology from the contralateral shoulder joint, with activity levels: abduction 90°, adduction 30°, anterior flexion 85°, posterior extension 30°, external rotation 60° and internal rotation 65°, which were essentially normal. VAS score was 0 and ASES score was 9 (**Figure 3**). The patient was also informed of the study and he agreed to publish his treatment.

Discussion

Shoulder dislocations are relatively common in clinical joint dislocations. There is no unified standard consensus on the management of shoulder dislocations in all age groups: whether shoulder dislocations should be treated conservatively or surgically is still under discussion. Manual repositioning under emergency care is routinely recommended. There is no consensus on the method of repositioning, with Kocher's method recommended, foot stirrups not recommended, and brachial plexus anaesthesia or intra-articular local anaesthesia for repositioning in elderly patients with osteoporosis. There is also no agreement on the type of braking and there is still discussion on whether to immobilise the shoulder joint in internal or external rotation (9–11). A study has reported no difference between these two types of braking in terms of recurrence rates and healing outcomes of joint dislocation and return to activity levels (12). Negligent and untimely access to medical care after trauma results in rare old undisplaced shoulder dislocations that are challenging to treat, and the patients in this paper were primarily untimely for further consultation. The success rate of resetting under general anaesthesia for old shoulder dislocations is low (40%) because the risk of resetting is greatly increased the longer the joint is not resetting under emergency care following traumatic dislocation, contracture of the joint capsule, development of surrounding scar tissue, entrapment of surrounding injured tissue and formation of fibrotic soft tissue (13).

Also related literature has found many terms and durations used to describe obsolete shoulder dislocations. While most authors define a delayed diagnosis of shoulder dislocation of more than 3 weeks as obsolete shoulder dislocation, some experts consider the cut-off point for the division between acute and obsolete cases to be 24 h after to 1 month (14). In addition, there are various terms used to describe this condition, including chronic, unrecognised, missed, old unreset, chronic unreduced and old dislocation (14). Although the relevant literature expresses the same concept, these terms may cause some confusion within the specialty; and in order to understand the disease itself, they are not understood as the same concept within the relevant specialty books and in the clinic, posing difficulties for article searching and writing, and they are not the same as each other. Therefore, they need to be standardised to avoid long-term confusion. Strategies for managing this issue are also controversial and remain a challenge. The patient in this article has been unsuccessfully diagnosed and treated since the injury and has remained in dislocation. We therefore refer to this as an obsolete non-repositioning.

At present, there is no uniform protocol for treatment, based on this article in that treatment is experimental or more empirical than evidence-based. Of course, with the development of multimedia, a combination of relevant specialist books and literature is available on the various methods of treatment of old dislocations. These include conservative treatment, resetting, incisional repositioning and resection arthroplasty, as well as the development of minimally invasive techniques, arthroscopic repositioning and related repair methods. In this paper, however, the patient first attempted a manipulative resurfacing even after general anaesthesia, which ultimately failed. Although the literature suggests that attempts at resetting should be abandoned if the dislocation is more than 6 weeks old. If resetting fails, the next step is surgical repositioning (8). Because of the extensive

fibrosis in a long-dislocated shoulder joint, adequate release of the joint capsule, excision of the entrapment and scar tissue and balancing of the soft tissue tension of the joint are required to reposition the joint; otherwise, the abnormal soft tissue blocks repositioning of the joint and at the same time the soft tissue tension is not balanced and the stability of the joint cannot be maintained after repositioning. In addition, scar tissue and laxity covering the surface of the pelvis must be removed prior to repositioning. For this, we take an arthroscopic, minimally invasive release and reposition. On entering the humeral glenoid joint, the humeral head could not be seen within the joint due to the large amount of scar tissue covering the surrounding area, so the joint was cleared of scar tissue. The long head of the biceps tendon was dislocated and seized. The joint capsule was released after severing the long head tendon, but was found to be difficult to reset. The subacromial crest was then entered and explored to see the rostroscapular ligament entrapment, so the rostroscapular ligament was cleared. The glenohumeral joint was then accessed to release the anterior joint capsule and gradually reposition the humeral glenoid joint.

Depending on the humeral head bone defect, the Hill-Sachs injury was filled using the infraspinatus tendon. For stabilisation of the joint after release, most reports recommend a direct approach of internal fixation through the shoulder joint after repositioning. Neviaser recommended screw fixation for 3–4 weeks and Wilson and Mckeever recommended steel pin fixation between the acromioclavicular humerus (15, 16). Goga reported on a group of 10 cases with incisional repositioning across the acromioclavicular humeral pin fixation for 4 weeks, with three excellent, five good and two fair results according to the Rowe and Zarin system (14). However, consider that internal fixation additionally increases damage to the humeral head and articular glenoid and tends to lead to joint adhesions and stiffness. If early shoulder movement improves the nutrition of the articular cartilage and reduces damage to the articular surface. In our case, the Hill-Sach injury was small, the greater humeral tuberosity had partially healed and the dislocation time was relatively short. In our case, the anterior shoulder contracture was extensively released and the posterior Hill-Sach injury was repaired by filling the sub-gonadal tendon to enhance the soft tissue balance anteriorly and posteriorly, with a short period of early abduction brace fixation, which is more effective than internal fixation with a metal object. This allows intermittent passive movement within a safe range several times a day, morning, noon and night, without fear of re-dislocation and to avoid stiffness.

The most common injuries accompanying old anterior shoulder dislocations are Bankart and Hill-Sachs injuries, with Bankart injuries referring to injuries to the anterior aspect of the joint capsule and the labrum of the glenoid and Hill-Sachs injuries referring to injuries to the posterior lateral aspect of the humeral head, with a reported correlation of 90%–97% and CT and MRI examinations emerging as the gold standard for their diagnosis (17, 18). The advantage of arthroscopic management is that it allows direct access and examination of these intra-articular problems within the joint. In addition, arthroscopic repair of the ligamentous structures can provide the initial stability required to prevent postoperative subluxation or re-dislocation. Thus, allowing the possibility of early post-operative rehabilitation, it has the potential benefit of better functional outcomes.

For the treatment of shoulder dislocations, the goal is to prevent further dislocation and to restore a satisfactory range of motion and strength to the limb for life. For most patients with shoulder dislocations, pain and dysfunction severely interfere with activities of daily living. Although some articles show that pain in old shoulder dislocations is very mild and range of motion is quite satisfactory, over time, dysfunction and symptoms can eventually develop, potentially to a degree that is intolerable for the patient (14). Most importantly, the best treatment option for old shoulder dislocations is to prevent acute dislocations from developing into old ones in the first place through prompt and accurate diagnosis. It is imperative that patients at risk of underdiagnosis are given and visual attention and that a thorough whole-body examination is performed when there is a high degree of suspicion. In addition to standard simple imaging, as equipment technology improves and becomes more widely available, CT can be considered to assess the joint more accurately if necessary. In patients with a diagnosis of old shoulder dislocation, a closed manipulative repositioning can still be attempted in the first instance. Although in most cases this is difficult and unsuccessful, closed resetting is still recommended as it can still have a positive effect on improving joint function and relieving symptoms. When this fails, surgical repositioning is recommended. However, when choosing a surgical approach, the presence of comorbidities, the patient's pre-injury functional needs and their expectations must also be taken into account, along with their own skills and experience, such as arthroscopic release of the joint and repair of the glenoid labrum. In some patients, excessive and unnecessary treatment, whether by arthroscopic or open techniques, may cause more harm than good. In some patients of advanced age, a very small number of patients with old shoulder dislocations remain asymptomatic and reasonably functional (19), and this article should remind us that in a very small number of patients, no treatment may be the best treatment.

In conclusion, arthroscopic release and repair is an alternative option for the treatment of old anterior shoulder dislocations. The anterior and inferior joint capsule is the main factor blocking repositioning; the capsule can develop secondary contractures that further block repositioning; and soft tissue balancing can achieve joint stabilisation.

Data availability statement

The original contributions presented in the study are included in the article/Supplementary Material, further inquiries can be directed to the corresponding author/s.

Ethics statement

Ethical review and approval was not required for the study on human participants in accordance with the local legislation and institutional requirements. The patients/participants provided their written informed consent to participate in this study. Written informed consent was obtained from the individual(s) for the publication of any potentially identifiable images or data included in this article.

Author contributions

WG, MH and TW wrote the first draft. YY and PH collects relevant information and materials. GZ, XW and MQ critically revised and edited successive drafts of the manuscript. All authors contributed to the article and approved the submitted version.

Conflict of interest

The authors declare that the research was conducted in the absence of any commercial or financial relationships that could be construed as a potential conflict of interest.

Publisher's note

All claims expressed in this article are solely those of the authors and do not necessarily represent those of their affiliated organizations, or those of the publisher, the editors and the reviewers. Any product that may be evaluated in this article, or claim that may be made by its manufacturer, is not guaranteed or endorsed by the publisher.

References

1. Kazár B, Relovszky E. Prognosis of primary dislocation of the shoulder. *Acta Orthop Scand.* (1969) 40(2):216–24. doi: 10.3109/17453676908989501

2. Nordqvist A, Petersson CJ. Incidence and causes of shoulder girdle injuries in an urban population. *J Shoulder Elbow Surg.* (1995) 4(2):107–12. doi: 10.1016/s1058-2746(05)80063-1

3. Owens BD, Duffey ML, Nelson BJ, DeBerardino TM, Taylor DC, Mountcastle SB. The incidence and characteristics of shoulder instability at the United States Military Academy. *Am J Sports Med.* (2007) 35(7):1168–73. doi: 10.1177/0363546506295179

4. Simonet WT, Melton 3rd LJ, Cofield RH, Ilstrup DM. Incidence of anterior shoulder dislocation in Olmsted County, Minnesota. *Clin Orthop Relat Res.* (1984) 186:186–91. doi: 10.1097/00003086-198406000-00030

5. Bishop JY, Flatow EL. Pediatric shoulder trauma. *Clin Orthop Relat Res.* (2005) 432:41–8. doi: 10.1097/01.blo.0000156005.01503.43<

6. Cutts S, Prempeh M, Drew S. Anterior shoulder dislocation. *Ann R Coll Surg Engl.* (2009) 91(1):2–7. doi: 10.1308/003588409x359123

7. Maier M, Geiger EV, Ilius C, Frank J, Marzi I. Midterm results after operatively stabilised shoulder dislocations in elderly patients. *Int Orthop.* (2009) 33(3):719–23. doi: 10.1007/s00264-008-0578-z

8. Jerosch J, Riemer R, Schoppe R. Asymptomatic chronic anterior posttraumatic dislocation in a young male patient. *J Shoulder Elbow Surg.* (1999) 8(5):492–4. doi: 10.1016/s1058-2746(99)90082-4

9. Minkus M, Königshausen M, Maier D, Mauch F, Stein T, Greiner S, et al. Immobilization in external rotation and abduction versus arthroscopic stabilization after first-time anterior shoulder dislocation: a multicenter randomized controlled trial. *Am J Sports Med.* (2021) 49(4):857–65. doi: 10.1177/0363546520987823

10. Boffano M, Mortera S, Piana R. Management of the first episode of traumatic shoulder dislocation. *EFORT Open Rev.* (2017) 2(2):35–40. doi: 10.1302/2058-5241.2.160018

11. Polyzois I, Dattani R, Gupta R, Levy O, Narvani AA. Traumatic first time shoulder dislocation: surgery vs non-operative treatment. *Arch Bone Jt Surg.* (2016) 4(2):104–8.

12. Handoll HH, Hanchard NC, Goodchild L, Feary J. Conservative management following closed reduction of traumatic anterior dislocation of the shoulder. *Cochrane Database Syst Rev.* (2006) 1:Cd004962. doi: 10.1002/14651858.CD004962.pub2

13. Rouhani A, Navali A. Treatment of chronic anterior shoulder dislocation by open reduction and simultaneous bankart lesion repair. *Sports Med Arthrosc Rehabil Ther Technol.* (2010) 2:15. doi: 10.1186/1758-2555-2-15

14. Goga IE. Chronic shoulder dislocations. *J Shoulder Elbow Surg.* (2003) 12 (5):446–50. doi: 10.1016/s1058-2746(03)00088-0

15. Neviaser JS. The treatment of old unreduced dislocations of the shoulder. *Surg Clin North Am.* (1963) 43:1671–8. doi: 10.1016/s0039-6109(16)37160-2

16. Wilson JC, Mc KF. Traumatic posterior dislocation of the humerus. *J Bone Joint Surg Am Vol.* (1949) 31a(1):160–72 doi: 10.2106/00004623-194931010-00018

17. Pancione L, Gatti G, Mecozzi B. Diagnosis of Hill-Sachs lesion of the shoulder. Comparison between ultrasonography and arthro-CT. *Acta Radiol.* (1997) 38(4 Pt 1):523–6. doi: 10.1080/02841859709174380

18. Kirkley A, Litchfield R, Thain L, Spouge A. Agreement between magnetic resonance imaging and arthroscopic evaluation of the shoulder joint in primary anterior dislocation of the shoulder. *Clin J Sport Med.* (2003) 13(3):148–51. doi: 10.1097/00042752-200305000-00004

19. Chung H, Yoon YS, Shin JS, Shin JJ, Kim D. Chronic irreducible anterior dislocation of the shoulder without significant functional deficit. *Clin Orthop Surg.* (2016) 8(3):333–8. doi: 10.4055/cios.2016.8.3.333

frontiers | Frontiers in Surgery

TYPE Original Research
PUBLISHED 05 January 2023
DOI 10.3389/fsurg.2022.1047168

Check for updates

OPEN ACCESS

EDITED BY
Paphon Sa-ngasoongsong,
Ramathibodi Hospital, Mahidol University, Thailand

REVIEWED BY
Changjun Guo,
Shanghai Jiao Tong University, China
Hui Zhang,
West China Hospital, Sichuan University, China

*CORRESPONDENCE
Fan Yang
✉ yynd8908@163.com
Zhongmin Shi
✉ szm1972@sjtu.edu.cn

†These authors have contributed equally to this work and share first authorship

SPECIALTY SECTION
This article was submitted to Orthopedic Surgery, a section of the journal Frontiers in Surgery

RECEIVED 17 September 2022
ACCEPTED 12 December 2022
PUBLISHED 05 January 2023

CITATION
Li X, Zhang J, Fu S, Wang C, Yang F and Shi Z (2023) First metatarsal single-screw minimally invasive chevron-akin osteotomy: A cost effective and clinically reliable technique. Front. Surg. 9:1047168. doi: 10.3389/fsurg.2022.1047168

COPYRIGHT
© 2023 Li, Zhang, Fu, Wang, Yang and Shi. This is an open-access article distributed under the terms of the Creative Commons Attribution License (CC BY). The use, distribution or reproduction in other forums is permitted, provided the original author(s) and the copyright owner(s) are credited and that the original publication in this journal is cited, in accordance with accepted academic practice. No use, distribution or reproduction is permitted which does not comply with these terms.

First metatarsal single-screw minimally invasive chevron-akin osteotomy: A cost effective and clinically reliable technique

Xueqian Li†, Jieyuan Zhang†, Shaoling Fu, Cheng Wang, Fan Yang* and Zhongmin Shi*

Department of Orthopedic Surgery, Shanghai Sixth People's Hospital, Shanghai Jiao Tong University, Shanghai, China

Purpose: The common disease hallux valgus results in foot discomfort and dysfunction. Less soft tissue damage and faster wound healing have made minimally invasive surgery (MIS) more popular. However, little research has compared the fixation results of minimally invasive chevron-akin (MICA) osteotomy thus far. In this study, the clinical and radiographic results of MICA with first metatarsal single- or dual-screw fixation are being examined.
Methods: A total of 107 feet of 103 patients with mild to moderate symptomatic hallux valgus treated MICA from January 2018 to June 2020 were retrospective evaluated, with at least 12-months follow-up. 51 patients underwent single-screw fixation procedures and 52 patients received dual-screw fixation procedures. Patients were assessed preoperatively and at the final follow-up with radiographic measurements [hallux valgus angle (HVA), intermetatarsal angle (IMA) and distal metatarsal articular angle (DMAA)] and clinical scores (american orthopaedic foot and ankle society (AOFAS) forefoot score, visual analog scale (VAS) and Manchester-Oxford Foot Questionnaire (MOxFQ) scores). The coughlin satisfaction scores were also obtained.
Results: Both groups showed significantly improved HVA, IMA and DMAA at the final follow-up ($P < 0.001$). Regarding clinical outcomes, the AOFAS, VAS and MOxFQ in two categories also significantly improved postoperatively ($P < 0.001$). There was no obvious difference in the clinical and radiographic outcomes between the two groups (HVA, $P = 0.833$; IMA, $P = 0.073$; DMAA, $P = 0.35$; AOFAS, $P = 0.48$; VAS, $P = 0.86$; MOxFQ, $P = 0.87$). However, the single-screw fixation group showed significantly lower operation time and less number of intraoperative fluoroscopy ($P < 0.001$). No serious complications were observed in either group. The single-screw fixation technique saves at least $1,086 compared with the dual-screw group.
Conclusion: At the final follow-up, both the single- and dual-screw fixation groups had comparable good to excellent clinical and radiographic outcomes, as well as a similar incidence of complications. Additionally, the single-screw fixation group reduces overall surgical costs, number of intraoperative fluoroscopy and operational time.

KEYWORDS
hallux valgus, minimally invasive osteotomy, chevron, AKIN, cost-effectiveness

Introduction

Hallux valgus is a common forefoot deformity that usually presents as an exostosis of the first metatarsophalangeal joint and an inversion of the first metatarsal, with a prevalence of approximately 23%–35.7% (1), causing medial pain of the first metatarsophalangeal joint and even metastatic metatarsalgia. There are several surgical options available for hallux valgus treatment, but open surgery is still the predominant approach (2). In recent years, hallux valgus minimally invasive surgery (MIS) has been increasingly used in clinical practice due to its less invasive nature, faster recovery and comparable surgical results (3, 4). Hallux valgus MIS techniques are now in their third generation. The first and second generation techniques do not involve screws as internal fixation devices (5) and have a higher incidence of postoperative complications (6). The core of the third-generation hallux valgus MIS consists of a percutaneous osteotomy of the first metatarsal head and internal fixation with the fully threaded hollow screw.

The minimally chevron-akin (MICA) osteotomy is currently the most commonly used technique for third-generation (3G) hallux valgus MIS. Drs. Redfern and Vernois popularized and improved this procedure in Europe in 2008 (7). Compared to the open technique, the MICA has a lower incidence of postoperative stiffness and lessens postoperative discomfort (8, 9). Noteworthy, metalwork is most frequently used to hold and fix the osteotomy. Although these methods have been demonstrated to be successful, they do also have some drawbacks. In particular, there is a described incidence of subsequent implant removal due to irritation of surrounding tissues and migration of the implanted metalwork, which may need the use of additional equipment (10). The desired outcome is therefore to apply sufficient fixation with the least amount of implant.

The aims of this retrospective study were to compare the results of single- and dual-screw MICA for hallux valgus by evaluating the radiographic and clinical outcomes. Furthermore, a cost-effectiveness comparison between the two fixation types was also conducted.

Methods

This was a retrospective comparative study carried from January 2018 to June 2020, 103 patients (107 feet) with mild to moderate hallux valgus that had been treated with MICA by the senior surgeon were included. The study was approved by the institutional review board of our institution, and written informed consent was obtained from all patients prior to the study.

Two case series were reviewed and compared in this study. One series was that of a surgeon who performs MICA using the first metatarsal single-screw fixation technique. The second series was that of using the first metatarsal dual-screw fixation technique. The inclusion criteria were as follows: (1) $18 < \text{age} < 65$; (2) $15° < \text{Hallux valgus angle (HVA)} \leq 40°$; (3) $9° < \text{Intermetatarsal angle (IMA)} \leq 16°$ (11); (4) Patients have been well compliant, accept the MICA technique and sign an informed consent form; (5) complete a minimum 2-year follow up; (6) No combined severe cardiopulmonary dysfunction, and able to tolerate surgery and anaesthesia. The exclusion criteria were as follows: (1) HVA > 40° or IMA > 16°; (2) Degenerative disease of the first metatarsophalangeal joint with severe restriction of joint movement; (3) Akin osteotomy only; (4) Patients with combined cardiovascular and cerebrovascular disease who cannot tolerate surgery; (5) Combined autoimmune disease or diabetes mellitus with poor glycaemic control; (6) Those with psychiatric disorders who are unable to cooperate.

Operative technique and postoperative rehabilitation

The patient is placed in a supine position with three-quarters of the lower leg extended at the end of the bed and the foot resting on the mini C-arm (Mobile C-arm fluoroscopic x-ray system, SIEMENS). A combination of ultrasound-guided local nerve block combined with laryngeal mask anaesthesia is used and a tourniquet is tied and padded on the thigh.

A 5-mm incision was made at the first metatarsal head/neck junction, then a miniature periosteal stripper was used to separate the soft tissue. A low-speed, high-torsional minimally invasive power (Shanghai Bojin, 5,000 rmp) was selected to reduce thermal damage to the skin and soft tissues, and a 2*8 mm milling drill was used to perform a V-shaped osteotomy toward the second metatarsal head under image control. After the osteotomy was finished, the first metatarsal head was displaced laterally and assisted reset using a specially designed minimally invasive tool. A 5-mm incision was made at the slightly distal end of the first tarsometatarsal joint, a guidewire was inserted obliquely through this incision under image control. The wire penetrates the medial and lateral cortices of the proximal end of the osteotomy to reach the lateral cortex of the metatarsal head. Then a 4.0 mm fully threaded hollow screw (In2bones, French) is inserted under the guidance of the guidewire. In the dual-screw fixation group, the second screw is placed in the same manner and parallel to the distal end of the first screw **Figure 1**. The projection of the bone at the end of the osteotomy is cleaned with a grinding drill. A minimally invasive Akin osteotomy is performed on the first phalanx and a 3.0 mm screw is placed, if metatarsal osteotomy failed to completely correct the metatarsophalangeal joint match. Moreover, in patients with lateral tension and difficult repositioning of the first metatarsophalangeal joint, a 50 ml syringe needle was used to

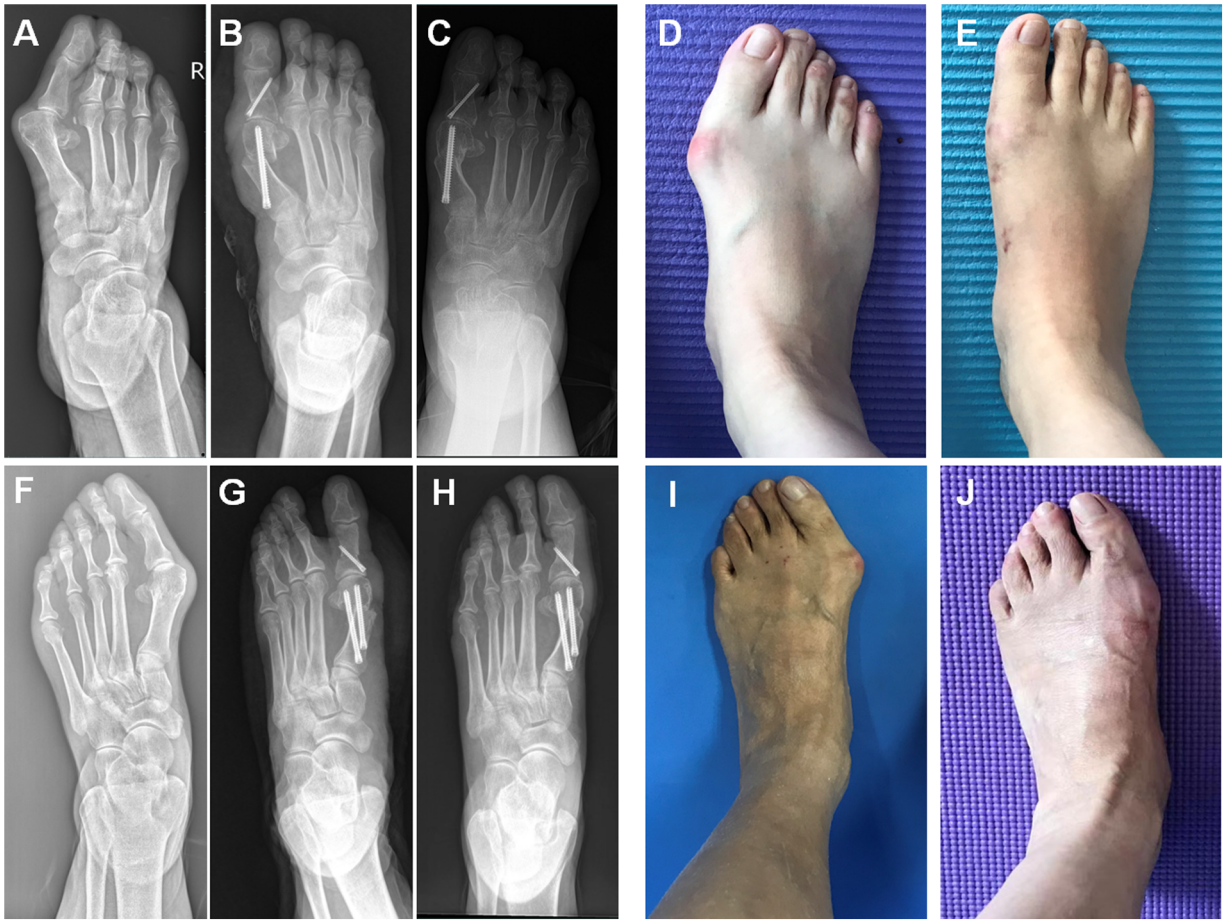

FIGURE 1
(A,F) Radiography showed moderate hallux valgus deformity. (D,I) Corresponding clinical photo. Radiography showed the correction of hallux valgus deformity after the single-screw fixation MICA (B) and the dual-screw fixation MICA (G). (C,H) 24 months after the operation and corresponding clinical photo (E,J).

release the joint capsule and adductor hallucis on the lateral side of the first metatarsophalangeal joint prior to MICA. In patients with metastatic metatarsalgia, a minimally invasive distal metatarsal minimal osteotomy (DMMO) was performed with minimally invasive power without internal fixation. For patients with combined flexible flatfoot, minimally invasive subtalar joint arthroereisis is used. Minimally invasive gastrocnemius recession was performed in patients with partial gastrocnemius tendon tension.

A postoperative bandage is essential to maintain the position of the hallux and prevent chronic complications such as recurrence. A coil of bandage is placed between the flippers of the first and second toes, and another bandage is placed between the flippers of the 1st and 2nd toes through the ankle joint to hold the hallux in a neutral position for 6 weeks. Two weeks postoperative, the stitches are removed, and walking with walkers or forefoot decompression shoes is permitted. To avoid stiffness of the first metatarsophalangeal joint, full weight bearing is permitted if tolerated, and walking is encouraged. To progressively recover joint motion, light plantarflexion activities can be started. After 1 month, walking in sports shoes is permitted, followed by jogging after 3 months, and intense sports after four to 6 months. Patients are recommended to be reviewed and followed up at 6 weeks, 3 months, 6 months, 12 months and 24 months after surgery.

Assessments

The visual analogue scale (VAS), the american orthopaedic foot and ankle society (AOFAS) forefoot scoring system and Manchester-Oxford Foot Questionnaire (MOxFQ) scores were used preoperatively and postoperatively respectively (5, 12), with the latter evaluating the clinical efficacy in terms of pain, function and strength lines, with a full score of a total score of 90–100 is considered excellent, 75–89 is considered good,

50–74 is fair and below 50 is considered poor. At the final follow-up, the mobility of the first metatarsophalangeal joint was assessed for joint stiffness. The Coughlin rating system was used to determine patient satisfaction levels (13). Patients who experienced few to no issues, little to no pain, ambulated without much difficulty, and were satisfied with the outcomes received a good to exceptional score. Radiographic assessment were as follows: HVA, IMA and DMAA. All radiographic parameters and clinical outcomes were measured by two orthopaedic surgeons.

Statistical analysis

The Shapiro-Wilk method was applied to test for normality using SPSS 26.0 statistical software. Measures that conformed to a normal distribution were described as mean ± standard deviation (±s), and *t*-tests were performed between normally distributed data. The differences between the two groups of qualitative data such as sex and laterality were tested by chi-square test. Differences were indicated as statistically significant at $P < 0.001$.

Results

The mean duration of follow-up was 20.98 ± 5.14 months in single-screw fixation group and 21.44 ± 4.10 months in dual-screw fixation group. The comparison of the baseline characteristics of the two groups was statistically insignificant (Table 1). The proportion of the release the joint capsule; distal metatarsal minimal osteotomy; minimally invasive subtatar joint arthrodesis and minimally invasive gastrocnemius recession in the two groups were 88.7% vs. 85.2%; 100% vs. 100%; 11.3% vs. 13.0% and 13.2% vs. 14.8%. At the end of follow-up, both groups had statistically significant improvements in the HVA, the first-second IMA and DMAA as compared to preoperative radiography ($P < 0.001$). The mean preoperative HVA, IMA and DMAA for the single-screw fixation MICA group were 33.98 ± 6.9°, 10.51 ± 3.0°and 13.99 ± 4.1°, respectively. At final follow-up, this improved to a mean HVA of 10.28 ± 5.11°, IMA of 4.72 ± 2.6° and DMAA of 4.79 ± 3.46° ($P < 0.001$). The mean preoperative HVA, IMA and DMAA for the dual-screw fixation MICA group were 34.15 ± 8.83°, 10.54 ± 3.0° and 16.16 ± 6.11°, respectively. At final follow-up, this improved to a mean HVA of 10.07 ± 5.18°, IMA of 3.9 ± 2.0° and DMAA of 5.73 ± 4.2° ($P < 0.001$). Both HVA, IMA and DMAA had comparable ultimate outcomes at the final follow-up when groups were compared ($P = 0.833$, $P = 0.073$ and $P = 0.35$, respectively). Table 2 lists the results of radiographic analysis. Figure 1 shows the postoperative radiographs of patients from each group at 2-year follow-up.

TABLE 1 Patient characteristics.

Characteristics	Single-screw	Dual-screw	*P* value
Age, mean ± SD, years	43.87 ± 17.80	44.58 ± 13.88	0.79
Gender			
Female	45	44	0.592
Male	6	8	
Side of hallux vaglus			
Right	28	25	0.499
Left	25	29	

TABLE 2 Comparison of patients based on the degree of preoperative deformity.

Characteristics	Single-screw	Dual-screw	*P* value
Preoperative HVA (°)	33.98 ± 6.9	34.15 ± 8.83	0.912
Postoperative HVA (°)	10.28 ± 5.11	10.07 ± 5.18	0.833
P value	<0.001	<0.001	
Difference	23.7 ± 7.5	24.08 ± 7.55	0.794
Preoperative IMA (°)	10.51 ± 3.0	10.54 ± 3.0	0.952
Postoperative IMA (°)	4.72 ± 2.6	3.9 ± 2.0	0.073
P value	<0.001	<0.001	
Difference	5.78 ± 3.33	6.64 ± 2.68	0.147
Preoperative DMAA (°)	13.99 ± 4.1	16.16 ± 6.11	0.12
Postoperative DMAA (°)	4.79 ± 3.46	5.73 ± 4.2	0.35
P value	<0.001	<0.001	
Difference	9.19 ± 4.7	10.42 ± 4.97	0.34
Preoperative AOFAS	56.49 ± 10.29	54.94 ± 11.74	0.53
Final AOFAS	90.25 ± 6.15	89.15 ± 8.58	0.48
P value	<0.001	<0.001	
Preoperative VAS	5.75 ± 1.63	5.20 ± 1.41	0.08
Final VAS	0.62 ± 0.56	0.65 ± 0.55	0.86
P value	<0.001	<0.001	
Preoperative MOxFQ	50.09 ± 13.28	51.94 ± 13.08	0.47
Final MOxFQ	12.85 ± 8.28	13.15 ± 11.03	0.87
P value	<0.001	<0.001	
Patient satisfaction, No.			0.175
Excellent	35	34	
Good	18	19	
Fair	0	1	
Poor	0	0	

HVA, hallux valgus angle; IMA, intermetatarsal angle; DMAA, distal metatarsal articular angle; VAS, visual analog scale.

Between the two groups, the preoperative ratings were comparable. Both groups had significantly better clinical results at the final follow-up ($P < 0.001$). AOFAS scores of two groups rising from 56.49 ± 10.29 to 90.25 ± 6.15 and 54.94 ± 11.74 to 89.15 ± 8.58, respectively. In the single-screw fixation group, the VAS and MOxFQ score decreased from 5.75 ± 1.63 to 0.62 ± 0.56 and 50.09 ± 13.28 to 12.85 ± 8.28; in the dual-screw fixation group, it decreased from 5.20 ± 1.41 to 0.65 ± 0.55 and 51.94 ± 13.08 to 13.15 ± 11.03. Clinical outcomes between the two groups were not substantially different ($P > 0.05$, **Table 2**). 53 feet in the single-screw fixation group reported excellent (66%) and good (34%) patient satisfaction, whereas 54 feet in the dual-screw fixation group reported excellent (62.9%), good (35.2%), and fair (1.9%) satisfaction.

In either group, there were no wound complications recorded. Stiffness of the first metatarsophalangeal joint was noted in 2 patients in single-screw fixation group (3.8%) and 3 in dual-screw fixation group (5.6%). Hallux valgus recurrence rates (5.7% and 3.7%) were comparable between groups receiving single or dual-screw fixation. Two patients in the single-screw fixation group (3.8%) and 3 patients in the dual-screw fixation group (5.6%) also reported numbness. One additional patient had persistent dysesthesias over the dorsomedial foot in dual-screw fixation group. One foot in the dual-screw fixation group had skin irritation which improved after screw removal. In neither group were any cases of avascular necrosis, nonunion, or dorsal malunion of the distal fragment described.

A cost analysis was also performed comparing the material costs of two different types of surgical fixation. The average cost of a screw was $1,085 and the single-screw fixation technique was found to be more cost-effective. the single-screw fixation group required an average of 15.42 ± 3.00 numer of intraoperative fluoroscopy and took 46.87 ± 5.23 min on average to complete, both of which were significantly less than the average for the dual-screw fixation group (**Table 3**, $P < 0.001$).

Discussion

Being the first comparison results of single/dual-screw fixation for MICA technique in our region, our study offers a novel viewpoint on third-generation MICA procedures in the Asian population. A minimum follow-up period of 2 years was successfully attained, allowing examination of short- to medium-term outcomes and complications. All surgeries were performed by same two surgeons using the same method in an effort to minimize the impact of intersurgeon technique variability on our outcomes. Standardization was also applied to postoperative treatment, procedure, and follow-up.

TABLE 3 Perioperative outcomes.

Characteristic	Single-screw	Dual-screw	*P* value
Operative time (min)	46.87 ± 5.23	56.59 ± 5.20	<0.001
Number of intraoperative fluoroscopy	15.42 ± 3.00	18.72 ± 2.06	<0.001

The demand for MIS has recently surged. There are some suggested advantages, such as a quicker healing time and a lower chance of infection. We do believe that the high union rate and stability of the MICA osteotomy are largely attributable to the bicortical structure of the proximal metatarsal screw, which was first mentioned by Redfern et al. (7), and the minimal soft tissue disturbance caused by the percutaneous operation. However, there are few to no articles on the subject of comparative outcomes of single/dual-screw fixation for MICA.

At the final follow-up in the current study, there were no differences in postoperative HVA, IMA or DMAA between the two groups. It has been established that patient satisfaction following hallux valgus surgery is inversely correlated with angular correction. Recurrence is linked to inadequate DMAA correction, especially in adolescents with hallux valgus (14). The average IMA correction served as a gauge for the potential of metatarsal osteotomy correction. The sesamoids should be completely repositioned as a consequence of a full decrease of the IMA. A correlation between the IMA and sesamoid location has been established in recent research in both hallux deformity and after hallux valgus treatment (15). In our investigation, we discovered that IMA corrections in both groups were good (**Table 2**). Analysis of the HVA also revealed a similar correction with barely any loss of correction in both groups, similar to the IMA. The HVA is affected directly by a phalangeal osteotomy and indirectly by the quality of the lateral release and the metatarsal osteotomy. The HVA correction in our study (**Table 2**) is in good agreement with the results that have been reported in the literature (16). Additionally, these findings suggest that one screw fixation would be adequate to ensure the stability of the osteotomy site, and the clinical outcomes dramatically improved. It is commonly recognized that clinical scores significantly improve following hallux valgus surgery (17). Using the MICA approach, the midterm findings of Hernandez et al. had promising clinical results. At 59.1 months following surgery, the AOFAS score went from 62.5 to 97.1 (18). Additionally, this discovery was also revealed during retrospective analyses of MIS hallux valgus operations. Our statistical findings support this assertion even more (**Table 2**). The British Orthopaedic Foot & Ankle Society has approved MOxFQ as a way to assess surgical results in foot and ankle surgeries. Significant improvement was seen in both groups when VAS and MOxFQ was evaluated (**Table 2**), which may be related to the slight irritation of soft tissue. Overall, similar to the earlier study

(19), there was no appreciable difference between the two groups in clinical and radiological outcomes.

Recurrence rates following surgery for hallux valgus have been estimated to reach 16% (20). Recurrent hallux deformity can be very difficult to treat since there is a lot of scar tissue left over and there are more problems than with primary surgery (21). This rate may be further decreased by the current MICA technique, which has a better screw fixation in the bone, although it has not yet been well researched in revision surgery. The recurrence rate in our study was essentially the same for both groups. The preservation of soft tissue is the fundamental technical benefit of MIS. In MICA, insufficient joint and work area cleaning may leave behind bone fragments that trigger an inflammatory reaction, leading to discomfort, fibrosis, and stiffness (22). In this study, compared to the single-screw fixation group, the dual-screw fixation group entailed greater soft tissue and bone manipulation and had a higher incidence of joint stiffness. The most frequent complication following MICA in the earlier trials was screw irritation. Our 1.9% screw removal rate in the dual-screw fixation group wasn't exceptionally high compared to earlier MICA experiments. Holme et al. reported a 10% complication rate, comprised of 4 patients who needed to have hardware removed because it had inflamed their soft tissues. It was proposed that the usage of oblique headless screws was the cause of their hardware removal rate being lower than previously observed (24%). Screw irritation was not found within the single-screw fixation group. Nerve discomfort is a rare consequence following this surgery because of the percutaneous aspect of the technique, which raises concerns about possible damage to the dorsal medial cutaneous nerve. Jowett and Bedi (23) did note two patients who exhibited scar sensitivity (24, 25). Less than 3% of nerve injuries were reported by Redfern et al. (7). In this study, both of our groups experienced the same rate of postoperative nerve paresthesias. Problems with wound healing and infections are also infrequently discussed in the MICA literature. In their research of 120 patients, Jowett and Bedi (23) identified 2 incidences of wound infections. Such complications did not originate in either group in our series.

The first metatarsal single-screw fixation group strategy had the lowest proportion of implants, which was a measure of the overall cost of the surgery, compared to dual- screw fication group, it is even more cost-effective than other approaches (26). MIS is reported to be faster than open scarf-Akin (27, 28). This study has demonstrated that clinical and radiological results are comparable with two groups. However, Operation time and number of intraoperative fluoroscopy were considerably reduced in the single-screw fixation group compared to the dual-screw fixation group (**Table 3**, $P < 0.001$).

This study has several limitations. To start, since the study only included mild to moderately patients, it is not impossible to draw conclusions about the effectiveness of treating severely patients. Second, our study population involves a small number of subjects. This was caused by a number of factors, e.g., patients who were excluded for missing follow-up appointments or having follow-up periods that were shorter than 2-years were deemed to have incomplete data sets. Third, our overall patient follow-up time is another drawback because this study only looked at short- to medium-term patient outcomes. As a result, we are unable to make any judgments on the long-term effects of this approach. At last, fully threaded hollow screws were used in this study. It is not clear whether other screws, such as double-headed compression screws, can also achieve stability. These restrictions should be considered in future study, and mitigating strategies should ideally be included.

Conclusion

In addition to offering outcomes that are equivalent to those of dual-screw MICA for the first metatarsal, the single-screw technique also offers the benefit of lowering overall surgical costs, fluoroscopy number during surgery and operational time. We recommend single-screw MICA as a viable treatment option.

Data availability statement

The raw data supporting the conclusions of this article will be made available by the authors, without undue reservation.

Ethics statement

The studies involving human participants were reviewed and approved by Shanghai Jiao Tong University Affiliated Sixth People's Hospital's institutional review board. The patients/participants provided their written informed consent to participate in this study.

Author contributions

All the authors have made appropriate contributions to this review. XL and JZ designed the study and wrote the manuscript. ZS and FY revised manuscript and approved article submission. SF and CW searched and collected the literature. All authors contributed to the article and approved the submitted version.

Funding

This study was supported by the Ningxia Hui Autonomous Region Key R&D Program, 2020 (2020BCH01001); Shanghai "Science and Technology Innovation Action Plan" Domestic Science and Technology Cooperation Project, 2020 (20025800200); Shanghai Municipal Technical and Scientific Commission (19441902400); and Clinical Research Program of Shanghai Municipal Health Commission (201940367).

Conflict of interest

The authors declare that the research was conducted in the absence of any commercial or financial relationships that could be construed as a potential conflict of interest. The reviewer CG declared a shared parent affiliation with the authors to the handling editor at the time of review.

Publisher's note

All claims expressed in this article are solely those of the authors and do not necessarily represent those of their affiliated organizations, or those of the publisher, the editors and the reviewers. Any product that may be evaluated in this article, or claim that may be made by its manufacturer, is not guaranteed or endorsed by the publisher.

References

1. Nix S, Smith M, Vicenzino B. Prevalence of hallux valgus in the general population: a systematic review and meta-analysis. *J Foot Ankle Res*. (2010) 27 (3):21. doi: 10.1186/1757-1146-3-21

2. Curtin M, Murphy E, Bryan C, Moroney P. Scarf osteotomy without internal fixation for correction of hallux valgus: a clinical and radiographic review of 148 cases. *Foot Ankle Surg*. (2018) 24(3):252–8. doi: 10.1016/j.fas.2017.02.014

3. Kaufmann G, Mortlbauer L, Hofer-Picout P, Dammerer D, Ban M, Liebensteiner M. Five-year follow-up of minimally invasive distal metatarsal chevron osteotomy in comparison with the open technique: a randomized controlled trial. *J Bone Joint Surg Am*. (2020) 102(10):873–9. doi: 10.2106/JBJS.19.00981

4. Lewis TL, Ray R, Miller G, Gordon DJ. Third-generation minimally invasive chevron and akin osteotomies (MICA) in hallux valgus surgery: two-year follow-up of 292 cases. *J Bone Joint Surg Am*. (2021) 103(13):1203–11. doi: 10.2106/JBJS.20.01178

5. Biz C, Fosser M, Dalmau-Pastor M, Corradin M, Roda MG, Aldegheri R, et al. Functional and radiographic outcomes of hallux valgus correction by mini-invasive surgery with reverdin-isham and akin percutaneous osteotomies: a longitudinal prospective study with a 48-month follow-up. *J Orthop Surg Res*. (2016) 11(1):157. doi: 10.1186/s13018-016-0491-x

6. Malagelada F, Sahirad C, Dalmau-Pastor M, Vega J, Bhumbra R, Manzanares-Cespedes MC, et al. Minimally invasive surgery for hallux valgus: a systematic review of current surgical techniques. *Int Orthop*. (2019) 43(3):625–37. doi: 10.1007/s00264-018-4138-x

7. Redfern D, Vernois J, Legre BP. Percutaneous surgery of the forefoot. *Clin Podiatr Med Surg*. (2015) 32(3):291–332. doi: 10.1016/j.cpm.2015.03.007

8. Kaufmann G, Dammerer D, Heyenbrock F, Braito M, Moertlbauer L, Liebensteiner M. Minimally invasive versus open chevron osteotomy for hallux valgus correction: a randomized controlled trial. *Int Orthop*. (2019) 43 (2):343–50. doi: 10.1007/s00264-018-4006-8

9. Altenberger S, Kriegelstein S, Gottschalk O, Dreyer F, Mehlhorn A, Roser A, et al. The minimally invasive chevron and akin osteotomy (MICA). *Oper Orthop Traumatol*. (2018) 30(3):148–60. doi: 10.1007/s00064-018-0541-0

10. Kerr HL, Jackson R, Kothari P. Scarf-akin osteotomy correction for hallux valgus: short-term results from a district general hospital. *J Foot Ankle Surg*. (2010) 49(1):16–9. doi: 10.1053/j.jfas.2009.07.024

11. Chan JY, Noori N, Chen S, Pfeffer GB, Charlton TP, Thordarson DB. Distal chevron osteotomy increases anatomic intermetatarsal angle in hallux valgus. *Foot Ankle Orthop*. (2020) 5(4):2473011420960710. doi: 10.1177/2473011420960710

12. Teoh KH, Tan WT, Atiyah Z, Ahmad A, Tanaka H, Hariharan K. Clinical outcomes following minimally invasive dorsal cheilectomy for hallux rigidus. *Foot Ankle Int*. (2019) 40(2):195–201. doi: 10.1177/1071100718803131

13. Coughlin M. Treatment of bunionette deformity with lon- gitudinal diaphyseal osteotomy with distal soft tissue repair. *Foot Ankle*. (1991) 11 (4):195–203. doi: 10.1177/107110079101100402

14. George HL, Casaletto J, Unnikrishnan PN, Shivratri D, James LA, Bass A, et al. Outcome of the scarf osteotomy in adolescent hallux valgus. *J Child Orthop*. (2009) 3(3):185–90. doi: 10.1007/s11832-009-0177-6

15. Mahadevan D, Lines S, Hepple S, Winson I, Harries W. Extended plantar limb (modified) chevron osteotomy versus scarf osteotomy for hallux valgus correction: a randomised controlled trial. *Foot Ankle Surg*. (2016) 22(2):109–13. doi: 10.1016/j.fas.2015.05.012

16. Brogan K, Lindisfarne E, Akehurst H, Farook U, Shrier W, Palmer S. Minimally invasive and open distal chevron osteotomy for mild to moderate hallux valgus. *Foot Ankle Int*. (2016) 37(11):1197–204. doi: 10.1177/1071100716656440

17. Faour-Martin O, Martin-Ferrero MA, Valverde Garcia JA, Vega-Castrillo A, de la Red-Gallego MA. Long-term results of the retrocapital metatarsal percutaneous osteotomy for hallux valgus. *Int Orthop*. (2013) 37(9):1799–803. doi: 10.1007/s00264-013-1934-1

18. Lucas y Hernandez J, Golano P, Roshan-Zamir S, Darcel V, Chauveaux D, Laffenetre O. Treatment of moderate hallux valgus by percutaneous, extra-articular reverse-L chevron (PERC) osteotomy. *Bone Joint J*. (2016) 98-B (3):365–73. doi: 10.1302/0301-620X.98B3.35666

19. Chan CX, Gan JZ, Chong HC, Rikhraj Singh I, Ng SYC, Koo K. Two year outcomes of minimally invasive hallux valgus surgery. *Foot Ankle Surg*. (2019) 25 (2):119–26. doi: 10.1016/j.fas.2017.09.007

20. Lee KT, Park YU, Jegal H, Lee TH. Deceptions in hallux valgus: what to look for to limit failures. *Foot Ankle Clin*. (2014) 19(3):361–70. doi: 10.1016/j.fcl.2014.06.003

21. Magnan B, Negri S, Maluta T, Dall'Oca C, Samaila E. Minimally invasive distal first metatarsal osteotomy can be an option for recurrent hallux valgus. *Foot Ankle Surg*. (2019) 25(3):332–9. doi: 10.1016/j.fas.2017.12.010

22. Frigg A, Zaugg S, Maquieira G, Pellegrino A. Stiffness and range of motion after minimally invasive chevron-akin and open scarf-akin procedures. *Foot Ankle Int*. (2019) 40(5):515–25. doi: 10.1177/1071100718818577

23. Jowett CRJ, Bedi HS. Preliminary results and learning curve of the minimally invasive chevron akin operation for hallux valgus. *J Foot Ankle Surg*. (2017) 56 (3):445–52. doi: 10.1053/j.jfas.2017.01.002

24. Holme TJ, Sivaloganathan SS, Patel B, Kunasingam K. Third-generation minimally invasive chevron akin osteotomy for hallux valgus. *Foot Ankle Int*. (2020) 41(1):50–6. doi: 10.1177/1071100719874360

25. Maffulli N, Longo UG, Marinozzi A, Denaro V. Hallux valgus: effectiveness and safety of minimally invasive surgery. A systematic review. *Br Med Bull*. (2011) 97:149–67. doi: 10.1093/bmb/ldq027

26. Wagner E, Ortiz C, Torres K, Contesse I, Vela O, Zanolli D. Cost effectiveness of different techniques in hallux valgus surgery. *Foot Ankle Surg*. (2016) 22(4):259–64. doi: 10.1016/j.fas.2015.11.004

27. Lam P, Lee M, Xing J, Di Nallo M. Percutaneous surgery for mild to moderate hallux valgus. *Foot Ankle Clin*. (2016) 21(3):459–77. doi: 10.1016/j.fcl.2016.04.001

28. Trnka HJ, Krenn S, Schuh R. Minimally invasive hallux valgus surgery: a critical review of the evidence. *Int Orthop*. (2013) 37(9):1731–5. doi: 10.1007/s00264-013-2077-0

frontiers | Frontiers in Surgery

TYPE Case Report
PUBLISHED 05 January 2023
DOI 10.3389/fsurg.2022.1039785

Check for updates

OPEN ACCESS

EDITED BY
Paphon Sa-ngasoongsong,
Mahidol University, Thailand

REVIEWED BY
Odion Binitie,
Moffitt Cancer Center, United States
Aly Fayed,
University of Iowa, United States

*CORRESPONDENCE
JianFeng Xue
✉ drxuejf@163.com
ZhongMin Shi
✉ liuyuanzuhuai@163.com

†These authors have contributed equally to this work and share first authorship

SPECIALTY SECTION
This article was submitted to Orthopedic Surgery, a section of the journal Frontiers in Surgery

RECEIVED 08 September 2022
ACCEPTED 29 November 2022
PUBLISHED 05 January 2023

CITATION
Chen C, Li Z, Xue J and Shi Z (2023) Posterior ankle arthroscopic treatment of a talar chondroblastoma with allograft and a platelet-rich plasma-fibrin glue: A case report and literature review.
Front. Surg. 9:1039785.
doi: 10.3389/fsurg.2022.1039785

COPYRIGHT
© 2023 Chen, Li, Xue and Shi. This is an open-access article distributed under the terms of the Creative Commons Attribution License (CC BY). The use, distribution or reproduction in other forums is permitted, provided the original author(s) and the copyright owner(s) are credited and that the original publication in this journal is cited, in accordance with accepted academic practice. No use, distribution or reproduction is permitted which does not comply with these terms.

Posterior ankle arthroscopic treatment of a talar chondroblastoma with allograft and a platelet-rich plasma-fibrin glue: A case report and literature review

Cheng Chen†, ZhenDong Li†, JianFeng Xue* and ZhongMin Shi*

Foot & Ankle Section, Department of Orthopaedics, Shanghai Jiao Tong University Affiliated Sixth People's Hospital, Shanghai, China

Talar chondroblastoma, which is a benign tumor of immature cartilage cells, is an uncommon but easily missed diagnosis of foot pain. Arthroscopic treatment for this condition is a safe, powerful, and promising technique with definitive advantages of visualization and minimal invasion. Here, we report a case of a talar chondroblastoma treated by posterior ankle arthroscopic curettage, allograft bone graft, and platelet-rich plasma-fibrin glue (PRP-FG) application. **Level of evidence:** Case Report. Level IV.

KEYWORDS

arthroscopy, chondroblastoma, talus, benign bone tumor, platelet-rich plasma-fibrin glue, allograft

Introduction

Chondroblastoma accounts for 1% of all bone tumors (1), which primarily affect a patient population aged 10–30 years old. Chondroblastoma is generally classified as a benign but "intermediate, rarely metastasizing" category of tumor with a recurrence rate of 4.8%–39.5% (2–4). The first case of chondroblastoma was reported in the year 1928 and the first talar chondroblastoma was reported in 1947 (5, 6). Typically, chondroblastoma occurs in the epiphysis of a long bone, but less than 10% affects the talus (7, 8). The talar chondroblastoma reported in literature were mainly located at the body of the talus, which uncommonly causes cortical erosion. Surgery is the main treatment modality for chondroblastoma, including curettage, resection, and radiofrequency ablation alone or in combination with other procedures (2, 9). Surgery for talar chondroblastoma is technically challenging due to the risk of joint surfaces breaking or fracture of the talus. Given the small size of the talus with the deep and complicated location of the tumor, it is very difficult to expose the operative field and excise it if open surgery is performed. Compared with open surgery, arthroscopic treatment has obvious advantages of visualization and minimal invasion, allowing for early mobilization and superior postsurgical functional and cosmetic results.

To the best of our knowledge, only one case of a patient who underwent posterior ankle arthroscopic treatment for a talar chondroblastoma has been reported (10). Here, we report a talar chondroblastoma patient treated by posterior ankle arthroscopic curettage, allograft bone graft, and platelet-rich plasma-fibrin glue (PRP-FG) application.

Case presentation

A 32-year-old man presented with pain and swelling in his right ankle on bearing weight and walking for 7 months. The only remarkable clinical finding was diffuse tenderness over the posterior ankle and deep-seated pain at maximal plantar flexion, which could not be exactly pinpointed. The Visual Analogue Scale (VAS) score was 6 points and the American Orthopedic Foot and Ankle Society (AOFAS) score was 71 points.

Preoperative x-ray and CT images showed a well-demarcated lytic lesion in the posterior half of the talar body. Preoperative MRI images showed a lesion with no cortical and articular surface breakage, measuring 2.5*2.2*2.2 cm (Figure 1). An x-ray-guided punch biopsy was performed and both histopathology and immunohistochemical results confirmed the diagnosis of chondroblastoma (Figure 2).



FIGURE 1
Preoperative imagological data. (A,B) AP and Lateral x-ray before operation show a well-demarcated and lytic lesion in the posterior talus. (C–E) Preoperative CT images show a lesion. (F–H) Preoperative MRI images show a lesion with no cortical and articular surface breakthrough, measuring 2.5*2.2*2.2 cm.

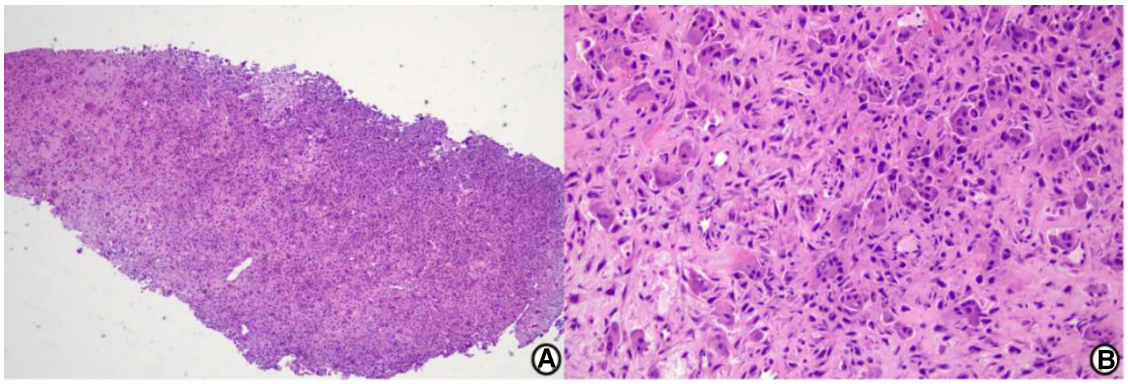

FIGURE 2
Histological image. Histological examination shows chondroblastoma cells and foci of the eosinophilic chondroid matrix. The immunohistochemical results show KI67(5% +), H3F3A(–), Kp1(+), CD163(partial +), H3F3B(+), P16(partial +), P63(partial +), and SATB2(+). The findings are consistent with chondroblastoma. (A) Low-power view (hematoxylin and eosin stain, origin magnification ×40). (B) High-power view (hematoxylin and eosin stain, origin magnification ×200).

After careful evaluation and discussion with the patient, we finally chose the posterior ankle arthroscopic treatment option. Arthroscopy was conducted 2 weeks after the biopsy procedure. The conditions are described in Figure 3.

After spinal anesthesia, the patient was placed in a prone position with a thigh tourniquet. All bony prominences were protected with cushion jelly to prevent pressure sore. A total of 40 ml blood was collected from his arm vessel. PRP was

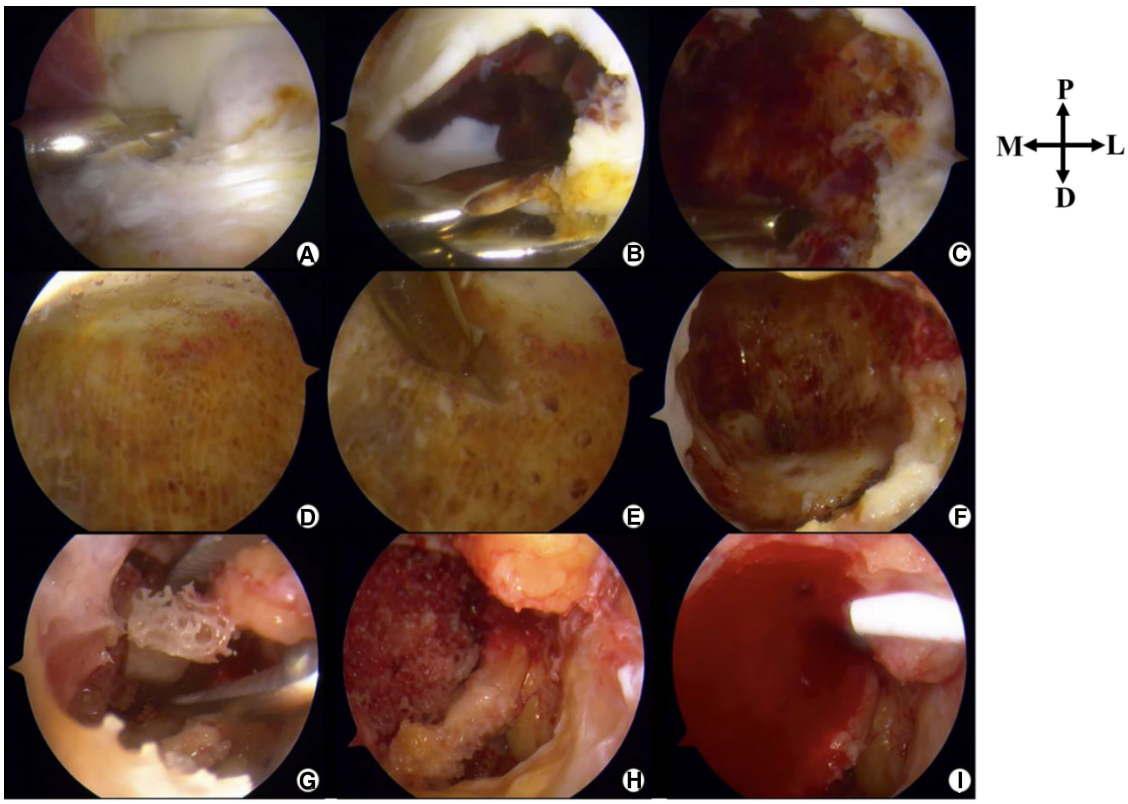

FIGURE 3
Intraoperative photographs (posterior ankle arthroscopy). P, Proximal; D, Distal; M, Medial; L, Lateral. (A) The lesion is located anterior to the posterior intermalleolar ligament. (B) Parts of the cartilage are removed to disclose the lesion. (C) Surgical debridement of the lesion followed by curettage. (D) Healthy cancellous bone after curettage. (E) Microfracture. (F) "Dry" arthroscopic view showing the cavity. (G) Allograft bone graft. (H) A photograph after the completion of implantation of allograft bone. (I) PRP-FG (platelet rich-plasma-fibrin glue) was injected.

prepared using the package produced by the Shandong Weigao Group Medical Polymer Company. A quantity of 4 ml of concentrated PRP was prepared by the double centrifugation method at 2,000 r/min for 10 min with a centrifugation radius of 15 cm. Concentrated PRP was set aside.

The 2-portal posterior ankle arthroscopy technique, first introduced by Van Dijk (11), was used with a saline gravity irrigation system. A 4.0-mm, 30° arthroscope was inserted via the posterolateral portal and a shaver was placed in the posteromedial portal. By identifying the flexor hallucis longus by protecting its medial aspect, the neurovascular bundle was kept safe. After debridement of the posterior ankle capsule and posterior intermalleolar ligament, the surface of the lesion with overlying soft cartilage was identified. The soft cartilage at the most posterior part of the talar dome (avoiding the weight-bearing area) was removed to expose the lesion, which was soft and friable and grey in color, mixed with a dark red–stained hematoma. It was curetted until the healthy cancellous bone was exposed. Microfracture was conducted on the wall of the cavity. After thorough lavage, the saline inflow was stopped and the intra-articular fluid was drained out. Then, we switched to "dry" transosseous arthroscopy. Under direct vision, 30 g allograft granular cancellous bone was packed into the lesion and gently tamped down. Once the bone graft was done, concentrated PRP fibrinogen and thrombin (Zhejiang Hangkang Pharmaceutical Co., Ltd.) were mixed. Then, the injection was applied to the surface defect and fibrin glue (Harbin Pacific Biopharmaceutical Co., Ltd.) was used for sealing. The portals were closed with a suture, and a dry, sterile compression dressing was applied. The foot and ankle were immobilized with a splint.

The suture was removed 2 weeks after the surgery. From the first day to postoperative 2 weeks, the patient remained on non-weight-bearing crutches with the ankle was placed in 90° dorsiflexion. Active muscle contraction was encouraged, and the range of motion was restricted within the first 2 weeks. Ankle plantar flexion and dorsiflexion exercises were started after 2 weeks, with the number increased by 30 times a day until it reached 150 times a day. Then, the partial weight-bearing process with a postoperative walking boot and crutch was gradually increased from 2 to 6 weeks. This process started from a weight of 20 lbs, with the weekly weight increased by 20 lbs. At the postoperative 6 weeks (the first follow-up visit), an x-ray revealed an initially incorporated bone graft. We encouraged the patient to increase his weight-bearing walking exercise and activities as tolerated. Instructions on rehabilitation exercises were given to the patient during follow-up visits.

We found that there were no postoperative complications. The first follow-up was conducted at 6 weeks. Since then, follow-ups have been conducted every 3 months. The most recent follow-up was performed one year after the surgery. The patient was satisfied with their full motor function recovery and pain-free condition. The VAS score was 0 points, and the AOFAS score was 100 points. Ankle flexion and extension range of motion was 70°. One-year postoperative CT images showed good bone remodeling and osteointegration with no tumor recurrence (**Figure 4**).

Discussion

To the best of our knowledge, only one case of a patient with posterior ankle arthroscopic treatment for a talar chondroblastoma has been reported. Yonter et al. (10) reported a patient with a $1.3*2.0*0.8 = 2.08\ cm^3$

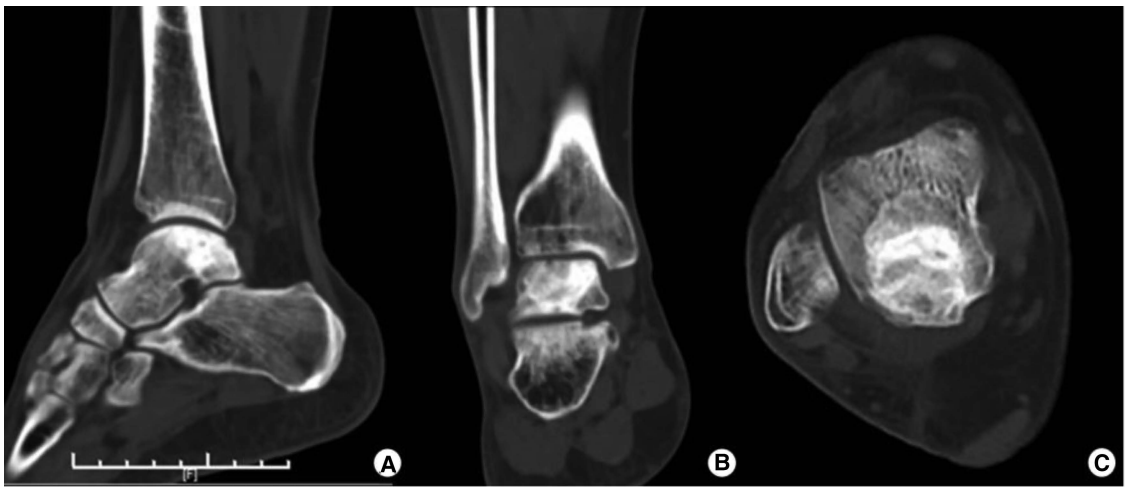

FIGURE 4
One-year postoperative CT images showing good bone remodeling and osteointegration with no tumor recurrence.

TABLE 1 Treatment and outcome of talar chondroblastoma previously reported in the literature.

Ref	Patient	Side	Lesion	Treatment	Follow-up time (month)	Outcome
Breck (5) 1956	A 21-year-old female	R	N[a]	Astragalectomy	24	A little, but not much pain; slight calcaneus deformity; no recurrence
Hull (13) 1977	A 14-year-old male	R	Talus and subsequently involving the calcaneus, tibiotalar joint, and the adjacent soft tissue	Curettage	21	Recurrence in the talus and calcaneus at 9 months. A talectomy, a wedge resection of the posterior calcaneus, and excision of involved soft tissue were performed
Moore (14) 1977	A 14-year-old male	L	N[a]	Curettage and allogeneic frozen-bone graft	36	No symptom; no recurrence
Ochsner (15) 1988	A 15-year-old male	R	2 cm	Curettage and cancellous bone graft from the distal tibia	27	No symptom; a full range of movement in his ankle and subtalar joint; no recurrence
Yu (16) 1996	An 18-year-old male	L	2.8 cm in maximal diameter	Curettage, autogenous bone grafting, and subtalar joint arthrodesis	27	The patient has resumed all activities without any difficulty; no recurrence
Sterling (17) 2002	A 20-year-old male	R	N[a]	Curettage and cancellous iliac crest bone graft	24	Some lateral ankle pain after heavy prolonged mechanical work; 15° dorsiflexion and 40° plantarflexion at both ankle joints; 75% normal eversion/inversion at the subtalar joint on the right compared with the left; no recurrence
Anderson (18) 2003	A 23-year-old male	R	2.5*2.0 cm, with the erosion of articular cartilage	Curettage, high-speed burring, and osteochondral autograft transfer from the lateral femoral condyle	24	No pain or swelling; a full range of motion of his ankle; no recurrence
Hassenpflug (19) 2007	A 18-year-old male	L	N[a]	Curettage and vascularized bone graft from the iliac crest	54	The patient was satisfied with the outcome; The range of motion of his left ankle was reduced to 5° dorsal extension and 20° plantar flexion; no recurrence
Zhang (20) 2012	A 22-year-old male	L	3.2*2.2 cm	Curettage and allogenic cancellous bone chip grafting	24	A little, but not much pain; no symptoms of instability; good mobility; no recurrence
Ningegowda (21) 2013	A 13-year-old male	L	N[a]	Curettage and fibular bone grafting	18	A full range of motion at the ankle, subtalar, and midtarsal joints; no recurrence
Sun (22) 2015	A 21-year-old male	L	3.0*2.0 cm	Curettage, high-speed burring, and bone cement implantation	6	No pain; The patient was satisfied with the functional outcome; no recurrence
Bahamonde (23) 2017	A 21-year-old male	R	Extending outside of bone boundaries and with a huge soft tissue mass and invasion of the adjacent calcaneus	En bloc talectomy, curettage, bone cement implantation, and tibiocalcaneal arthrodesis	132	The AOFAS hindfoot score was 83, with limitations regarding only hindfoot motion; no recurrence
Ryu (24) 2018	A 18-year-old female	L	2.5 * 4.1 * 2.9 cm	Curettage, burring, and fill as much of the body centrally with the cement and supporting the cortices with the autogenous cancellous bone graft from the ipsilateral iliac crest	12	No pain; the AOFAS hindfoot score was 100; no recurrence

(*continued*)

TABLE 1 Continued

Ref	Patient	Side	Lesion	Treatment	Follow-up time (month)	Outcome
Wagener (25) 2019	A 15-year-old male	L	4.0*3.0 cm	Debridement and microvascular iliac crest bone graft	60	The patient was very satisfied with the result and is playing soccer again; no recurrence
	A 20-year-old male	R	2.5*3.4*2.3 cm	Debridement and vascularized graft from the medial femoral condyle	72	The patient reported having no pain and no limitation in daily life activities, was highly satisfied; no recurrence
	A 33-year-old male	R	2.0*1.5*1.0 cm	Debridement and vascularized graft from the medial femoral condyle	36	Residual pain resolved after the screw was removed; no recurrence

Only references that reported clear outcomes of patients with talar chondroblastoma.
[a]N, not mentioned.

chondroblastoma in the posterior talus via arthroscopic curettage, allograft bone graft, and augmentation with a cell-free matrix. Our case presented a challenging larger-sized talar chondroblastoma ($2.5*2.2*2.2 = 12.1\ cm^3$), and we combined posterior ankle arthroscopy, including wet and "dry" transosseous arthroscopy, with curettage, allograft bone graft, and PRP-FG. Our patient showed satisfactory results without any recurrence at a 1-year follow-up.

Although talar chondroblastoma is uncommon, almost 50% of foot chondroblastoma occurs in the talus (12). Interestingly, Angelini et al. (12) suggested that the recurrence rate of chondroblastoma in the foot was even lower than that in other body locations. There are few reports about appropriate treatments and clear outcomes for talar chondroblastoma. Therefore, we review and summarized the literature in **Table 1**. We found that most of the cases reported a generally good prognosis, except the case of a patient who had a massive tumor with local invasion (talus, calcaneus, tibiotalar joint, and the adjacent soft tissue).

Shears et al. (26) claimed that it is unnecessary to do a bone graft after benign talar tumor excision. However, in this small number of case series, we note that only two out of eight patients had a tumor volume larger than $10\ cm^3$. Thus, this triggered concern about whether such findings also hold for those with relatively large-size lesions. In addition, it took 6–12 months for us to fully consolidate the defect, which delayed the recommendation of rehabilitation exercises to our patient. Moreover, early weight-bearing walking without the reconstruction of bony defects might cause talar collapse or fracture. Therefore, caution must be exercised because our patient had a large-sized talar chondroblastoma with a bony defect of $12.1\ cm^3$. If a talar collapse or fracture happens, management would become much more difficult. Among multiple bone graft materials, autograft bone has the advantages of osteoconductivity, osteoinductivity, and potential osteogenicity (27–29). Therefore, it remains the gold standard for bone defect reconstruction. Similarly, autologous bone transplantation is the most widely used procedure in bone defect repair for talar chondroblastoma (10, 15–18, 21). Furthermore, a study reported that vascularized bone autograft was used to construct larger defects of the talar caused by bone tumor (19, 25). Although all these procedures are effective, potential pain and complications at the donor sites are worrying (30). Under such conditions, an allograft bone graft may be a good alternative (14, 20). Moreover, artificial bone graft substitutes such as the demineralized bone matrix or platelet-derived growth factor augmented ceramic granules showed good results compared with autologous grafts (31). In addition, bone cement implantation has been reported (22, 23). However, the major disadvantages of this procedure are the occurrence of thermal injury, secondary fracture, and osteoarthritis (32). It is of note that joint degeneration tends to be the case when the tumor is in close proximity to the articular cartilage (33). Van et al. (34) found that if the tumor–cartilage distance was ≤ 3 mm, the use of bone cement was more likely to result in joint degeneration. Thus, we did not use bone cement in our patient, as the remainder of the subchondral bone was extremely thin. We chose an allograft bone graft after considering the patient's apprehensions about extra donor site surgery and the resultant morbidities. On this basis, we combined allograft bone with PRP-FG to enhance tissue regeneration and repair (35). PRP-FG offsets the drawbacks of PRP, which lacks fixation and has poor tissue adhesive ability (36, 37). The final follow-up results of our case demonstrate the effectiveness of this procedure. However, a more prolonged observational follow-up is required to assess long-term results.

The technical difficulty of treating a talar chondroblastoma is that it lies in a deep and complicated position and is occluded by the tibial mortise and soft tissue of the posterior ankle. Open surgery, sometimes requiring osteotomy for better exposure of the lesion, may cause more trauma and induces subsequent

TABLE 2 Application of arthroscopic treatment in chondroblastoma previously reported in the literature.

Ref	Patient	Location	Follow-up time (month)	Recurrence	Complication
Cohen (43) 1992	1	Proximal tibia	12	No	No
Thompson (44) 1995	1	Femoral head	6	No	No
Stricker (45) 1995	3	Femoral head	4–38	No	No
Bal (46) 1995	1	Medial femoral condyle	60	No	No
Otsuka (47) 2002	1	Calcaneus	24	No	No
Prado (48) 2010	1	Dorsal medial cortex of the talar neck	3	No	No
Zoccali (49) 2012	1	Tibial spine area of the proximal tibia	12	No	No
Miyazaki (50) 2013	1	Medial femoral condyle	12	No	No
Errani (51) 2014	1	Lateral femoral condyle	12	No	No
Choi (42) 2014	1	N[a]	19	No	No
Farouk (41) 2018	3	Distal femur	26–45	No	No
Kellish (52) 2021	3	Distal femur	7–43	No	No
Acharya (53) 2022	1	Distal femur	84	No	No

[a]N, not accessible.

tissue adhesions. In our case, posterior ankle arthroscopy offered a direct visualization of the surgical field, allowing for subsequent refined operation. At 2 weeks after arthroscopy, our patient was given the freedom of early partial weight-bearing and early mobilization. The patient was allowed to carry out the full weight-bearing activities of daily living at an earlier stage than that of open surgery. Our experience demonstrated the technical feasibility and superiority of arthroscopy. Arthroscopy is a safe, powerful, and minimally invasive technique offering good postoperative results. Studies have shown that arthroscopy has produced inspiring outcomes in benign bone tumors (38–42). More importantly, full functional recovery after a period of 8–12 weeks after arthroscopy has been observed. The application of arthroscopic treatment in chondroblastoma is listed in **Table 2**. In our case, we are pleased to report that arthroscopic treatment in talar chondroblastoma yielded good initial results. However, there is insufficient evidence of whether arthroscopic treatment of chondroblastoma won't decrease the tumor recurrence rate. Therefore, orthopedic surgeons must remain vigilant. A larger number of studies and a higher level of evidence are warranted to support this potential indication.

Conclusion

Posterior ankle arthroscopy with allograft bone graft and PRP-FG is a secure, motivating, and promising technique to treat chondroblastoma in the posterior talus, offering clinicians an excellent alternative to open surgery.

Data availability statement

The original contributions presented in the study are included in the article/Supplementary Material; further inquiries can be directed to the corresponding authors.

Ethics statement

Written informed consent was obtained from the individual (s) for the publication of any potentially identifiable images or data included in this article.

Author contributions

CC and ZL conceptualized the study. JX collected patient information and reviewed the literature. CC and ZL drafted the manuscript. ZS and JX revised the manuscript. All authors contributed to the article and approved the submitted version.

Funding

The study was sponsored by the Key Research and Development Program of National Ministry of Science and Technology (2018YFC2001504), Bio-medical Engineering Program of "Shanghai Jiao Tong University Star" Plan (YG2022ZD018), Shanghai Artificial Intelligence Innovation and Development Program (2020-RGZN-02006), and

Biomedicine Supporting Program of Shanghai "Science and Technology Innovation Plan" (19441902400).

Conflict of interest

The authors declare that the research was conducted in the absence of any commercial or financial relationships that could be construed as a potential conflict of interest.

Publisher's note

All claims expressed in this article are solely those of the authors and do not necessarily represent those of their affiliated organizations, or those of the publisher, the editors and the reviewers. Any product that may be evaluated in this article, or claim that may be made by its manufacturer, is not guaranteed or endorsed by the publisher.

References

1. Chen W, Difrancesco LM. Chondroblastoma: an update. *Arch Pathol Lab Med*. (2017) 141(6):867–71. doi: 10.5858/arpa.2016-0281-RS

2. Xu H, Nugent D, Monforte HL, Binitie OT, Ding Y, Letson GD, et al. Chondroblastoma of bone in the extremities: a multicenter retrospective study. *J Bone Joint Surg Am*. (2015) 97(11):925–31. doi: 10.2106/jbjs.N.00992

3. Suneja R, Grimer RJ, Belthur M, Jeys L, Carter SR, Tillman RM, et al. Chondroblastoma of bone: long-term results and functional outcome after intralesional curettage. *J Bone Joint Surg Br*. (2005) 87(7):974–8. doi: 10.1302/0301-620x.87b7.16009

4. Choi JH, Ro JY. The 2020 WHO classification of tumors of bone: an updated review. *Adv Anat Pathol*. (2021) 28(3):119–38. doi: 10.1097/pap.0000000000000293

5. Breck LW, Emmett JE. Chondroblastoma of the talus: a case report. *Clin Orthop*. (1956) 7:132–5.

6. Coley BL, Santoro AJ. Chondromas and chondroblastoma of bone. *Surgery*. (1947) 22:411–23.

7. Ramappa AJ, Lee FY, Tang P, Carlson JR, Gebhardt MC, Mankin HJ. Chondroblastoma of bone. *J Bone Joint Surg Am*. (2000) 82(8):1140–5. doi: 10.2106/00004623-200008000-00011

8. Laitinen MK, Stevenson JD, Evans S, Abudu A, Sumathi V, Jeys LM, et al. Chondroblastoma in pelvis and extremities – a single centre study of 177 cases. *J Bone Oncol*. (2019) 17:100248. doi: 10.1016/j.jbo.2019.100248

9. Xie C, Jeys L, James SL. Radiofrequency ablation of chondroblastoma: long-term clinical and imaging outcomes. *Eur Radiol*. (2015) 25(4):1127–34. doi: 10.1007/s00330-014-3506-1

10. Yonter SN, Aslan L, Can A, Ogut T. A case of arthroscopic treatment of chondroblastoma-induced chondropathy situated at the posterior talus. *J Am Podiatr Med Assoc*. (2021) 111(5). doi: 10.7547/20-125

11. Van Dijk CN. Hindfoot endoscopy. *Foot Ankle Clin*. (2006) 11(2):391–414, vii. doi: 10.1016/j.fcl.2006.03.002

12. Angelini A, Arguedas F, Varela A, Ruggieri P. Chondroblastoma of the foot: 40 cases from a single institution. *J Foot Ankle Surg*. (2018) 57(6):1105–9. doi: 10.1053/j.jfas.2018.05.005

13. Hull MT, Gonzalez-Crussi F, Derosa GP, Graul RS. Aggressive chondroblastoma. Report of a case with multiple bone and soft tissue involvement. *Clin Orthop Relat Res*. (1977) 126:261–5.

14. Moore TM, Roe JB, Harvey Jr JP. Chondroblastoma of the talus: a case report. *J Bone Joint Surg Am*. (1977) 59(6):830–1. doi: 10.2106/00004623-197759060-00020

15. Ochsner PE, Von Hochstetter AR, Hilfiker B. Chondroblastoma of the talus: natural development over 9.5 years. Case report. *Arch Orthop Trauma Surg (1978)*. (1988) 107(2):122–5. doi: 10.1007/bf00454501

16. Yu GV, Sellers CS. Chondroblastoma of the talus. *J Foot Ankle Surg*. (1996) 35(1):72–7. doi: 10.1016/s1067-2516(96)80016-0

17. Sterling G, Wilson A. Chondroblastoma of the talus: a case report. *J Foot Ankle Surg*. (2002) 41(3):178–82. doi: 10.1016/s1067-2516(02)80068-0

18. Anderson AF, Ramsey JR. Chondroblastoma of the talus treated with osteochondral autograft transfer from the lateral femoral condyle. *Foot Ankle Int*. (2003) 24(3):283–7. doi: 10.1177/107110070302400315

19. Hassenpflug J, Ulrich HW, Liebs T, Lankes JM, Terheyden H, Kreusch T, et al. Vascularized iliac crest bone graft for talar defects: case reports. *Foot Ankle Int*. (2007) 28(5):633–7. doi: 10.3113/fai.2007.0633

20. Zhang K, Gao Y, Dai H, Zhang S, Li G, Yu B. Chondroblastoma of the talus: a case report and literature review. *J Foot Ankle Surg*. (2012) 51(2):262–5. doi: 10.1053/j.jfas.2011.10.006

21. Ningegowda RV, Subramanian K, Suresh I. Chondroblastoma of the talus. *J Foot Ankle Surg*. (2013) 52(5):673–7. doi: 10.1053/j.jfas.2013.02.020

22. Sun B, Li XY, Zhao XY, Feng W, Liu JG. Chondroblastoma with associated aneurysmal bone cyst of the talus: a case report and review of relative literatures. *Zhongguo Gu Shang*. (2015) 28(7):657–9.

23. Bahamonde Munoz L, Escudero Heldt M. Massive chondroblastoma of the talus: treatment with en bloc talectomy and tibiocalcaneal arthrodesis: long-term follow-up of a case. *Foot Ankle Spec*. (2017) 10(3):274–7. doi: 10.1177/1938640016676339

24. Ryu JJ, Kim W, Lee JS, Kim YK, Lee HS, Seo SG. Combined autograft and bone cement for painful chondroblastoma: a case report. *J Foot Ankle Surg*. (2018) 57(2):396–400. doi: 10.1053/j.jfas.2017.08.019

25. Wagener J, Schweizer C, Horn Lang T, Zwicky L, Schaefer DJ, Hintermann B. Vascularized bone autograft for the treatment of chondroblastoma of the talus at imminent risk of joint breakdown: three case reports. *J Foot Ankle Surg*. (2019) 58(2):363–7. doi: 10.1053/j.jfas.2018.08.053

26. Shears E, Dehne K, Murata H, Abudu A, Grimer RJ, Tillman RM, et al. Healing of ungrafted bone defects of the talus after benign tumour removal. *Foot Ankle Surg*. (2008) 14(3):161–5. doi: 10.1016/j.fas.2008.01.006

27. Bow A, Anderson DE, Dhar M. Commercially available bone graft substitutes: the impact of origin and processing on graft functionality. *Drug Metab Rev*. (2019) 51(4):533–44. doi: 10.1080/03602532.2019.1671860

28. Danilkowicz R, Murawski C, Pelligrini M, Walther M, Valderrabano V, Angthon C, et al. Nonoperative and operative soft-tissue and cartilage regeneration and orthopaedic biologics of the foot and ankle: an orthoregeneration network (ON) foundation review. *Arthroscopy*. (2022) 38(7):2350–8. doi: 10.1016/j.arthro.2022.04.018

29. Gillman CE, Jayasuriya AC. FDA-approved bone grafts and bone graft substitute devices in bone regeneration. *Mater Sci Eng C Mater Biol Appl*. (2021) 130:112466. doi: 10.1016/j.msec.2021.112466

30. Younger EM, Chapman MW. Morbidity at bone graft donor sites. *J Orthop Trauma*. (1989) 3(3):192–5. doi: 10.1097/00005131-198909000-00002

31. Müller MA, Frank A, Briel M, Valderrabano V, Vavken P, Entezari V, et al. Substitutes of structural and non-structural autologous bone grafts in hindfoot arthrodeses and osteotomies: a systematic review. *BMC Musculoskelet Disord*. (2013) 14:59. doi: 10.1186/1471-2474-14-59

32. Benevenia J, Rivero SM, Moore J, Ippolito JA, Siegerman DA, Beebe KS, et al. Supplemental bone grafting in giant cell tumor of the extremity reduces nononcologic complications. *Clin Orthop Relat Res*. (2017) 475(3):776–83. doi: 10.1007/s11999-016-4755-x

33. Jamshidi K, Bagherifard A, Mohaghegh MR, Mirzaei A. Fibular strut allograft or bone cement for reconstruction after curettage of a giant cell tumour of the proximal femur: a retrospective cohort study. *Bone Joint J*. (2022) 104-b(2):297–301. doi: 10.1302/0301-620x.104b2.Bjj-2021-1322.R1

34. Van Der Heijden L, Van De Sande MA, Heineken AC, Fiocco M, Nelissen RG, Dijkstra PD. Mid-term outcome after curettage with polymethylmethacrylate for giant cell tumor around the knee: higher risk of radiographic osteoarthritis? *J Bone Joint Surg Am*. (2013) 95(21):e159. doi: 10.2106/jbjs.M.00066

35. Fang J, Wang X, Jiang W, Zhu Y, Hu Y, Zhao Y, et al. Platelet-rich plasma therapy in the treatment of diseases associated with orthopedic injuries. *Tissue Eng Part B Rev*. (2020) 26(6):571–85. doi: 10.1089/ten.TEB.2019.0292

36. Wang M, Gao W. Fixation of platelet-rich plasma and fibrin gels on knee cartilage defects after microfracture with arthroscopy. *Int Orthop*. (2022) 46 (8):1761–6. doi: 10.1007/s00264-022-05377-2

37. Kaplonyi G, Zimmerman I, Frenyo AD, Farkas T, Nemes G. The use of fibrin adhesive in the repair of chondral and osteochondral injuries. *Injury*. (1988) 19(4):267–72. doi: 10.1016/0020-1383(88)90043-5

38. Khapchik V, O'donnell RJ, Glick JM. Arthroscopically assisted excision of osteoid osteoma involving the hip. *Arthroscopy*. (2001) 17(1):56–61. doi: 10.1053/jars.2001.8022

39. Dai L, Zhang X, Mei Y, Gao G, Huang H, Wang C, et al. Arthroscopic excision of intra-articular osteoid osteoma of the hip: a case series. *Arthroscopy*. (2021) 37(10):3104–12. doi: 10.1016/j.arthro.2021.03.060

40. Mastboom MJL, Staals EL, Verspoor FGM, Rueten-Budde AJ, Stacchiotti S, Palmerini E, et al. Surgical treatment of localized-type tenosynovial giant cell tumors of large joints: a study based on a multicenter-pooled database of 31 international sarcoma centers. *J Bone Joint Surg Am*. (2019) 101(14):1309–18. doi: 10.2106/jbjs.18.01147

41. Farouk HA, Saladin M, Senna WA, Ebeid W. All-endoscopic management of benign bone lesions; a case series of 26 cases with minimum of 2 years follow-up. *SICOT J*. (2018) 4:50. doi: 10.1051/sicotj/2018041

42. Choi Y, Kwak JM, Chung SH, Jung GH, Kim JD. Tumor treated by endoscopy. *Clin Orthop Surg*. (2014) 6(1):72–9. doi: 10.4055/cios.2014.6.1.72

43. Cohen B, Khan TH, Dandy DJ. Arthroscopic resection of chondroblastoma of the knee. *Arthroscopy*. (1992) 8(3):370–2. doi: 10.1016/0749-8063(92)90071-i

44. Thompson MS, Woodward Jr JS. The use of the arthroscope as an adjunct in the resection of a chondroblastoma of the femoral head. *Arthroscopy*. (1995) 11 (1):106–11. doi: 10.1016/0749-8063(95)90097-7

45. Stricker SJ. Extraarticular endoscopic excision of femoral head chondroblastoma. *J Pediatr Orthop*. (1995) 15(5):578–81. doi: 10.1097/01241398-199509000-00005

46. Bal BS, Jones Jr L. Arthroscopic resection of a chondroblastoma in the knee. *Arthroscopy*. (1995) 11(2):216–9. doi: 10.1016/0749-8063(95)90070-5

47. Otsuka T, Kobayashi M, Yonezawa M, Kamiyama F, Matsushita Y, Matsui N. Treatment of chondroblastoma of the calcaneus with a secondary aneurysmal bone cyst using endoscopic curettage without bone grafting. *Arthroscopy*. (2002) 18(4):430–5. doi: 10.1053/jars.2002.31967

48. Prado MP, Mendes AA, Amodio DT. Benign bone tumors subperiosteal on the talar neck resected anthroscopically: case reports. *Einstein (Sao Paulo)*. (2010) 8(3):354–7. doi: 10.1590/s1679-45082010rc1530

49. Zoccali C, Teori G, Salducca N, Di Paola B, Adriani E. Arthroscopic guided biopsy and radiofrequency thermoablation of a benign neoplasm of the tibial spines area: a treatment option. *BMC Musculoskelet Disord*. (2012) 13:52. doi: 10.1186/1471-2474-13-52

50. Miyazaki T, Uchida K, Yayama T, Nakajima H, Honjoh K, Itoh H, et al. Chondroblastoma of the distal femur resected through a small fenestra via computed tomography navigation and endoscopy: a case report. *J Med Case Rep*. (2013) 7:164. doi: 10.1186/1752-1947-7-164

51. Errani C, Traina F, Chehrassan M, Donati D, Faldini C. Minimally invasive technique for curettage of chondroblastoma using endoscopic technique. *Eur Rev Med Pharmacol Sci*. (2014) 18(22):3394–8.

52. Kellish AS, Qureshi M, Mostello A, Kim TW, Gutowski CJ. "Dry arthroscopy" is a valuable tool in the excisional curettage of chondroblastoma: a case series. *J Orthop Case Rep*. (2021) 11(1):82–6. doi: 10.13107/jocr.2021.v11.i01.1974

53. Acharya PU, Mirza K. Arthroscopic management of Juxta-articular chondroblastoma with bone substitutes - A case report. *J Clin Orthop Trauma*. (2022) 29:101895. doi: 10.1016/j.jcot.2022.101895

frontiers | Frontiers in Surgery

TYPE Case Report
PUBLISHED 06 January 2023
DOI 10.3389/fsurg.2022.1025650

Check for updates

OPEN ACCESS

EDITED BY
Paphon Sa-ngasoongsong,
Mahidol University, Thailand

REVIEWED BY
Yaodong Gu,
Ningbo University, China
Ismail Hadisoebroto Dilogo,
University of Indonesia, Indonesia

*CORRESPONDENCE
Bin Sheng
shengbin2009@163.com

SPECIALTY SECTION
This article was submitted to Orthopedic Surgery, a section of the journal Frontiers in Surgery

RECEIVED 23 August 2022
ACCEPTED 25 November 2022
PUBLISHED 06 January 2023

CITATION
Yang Z, Sheng B, Liu D, Wang Y, Liu C and Xiao R (2023) Sacroiliac screws fixation navigated with three-dimensional printing personalized guide template for the treatment of posterior pelvic ring injury: A case report. Front. Surg. 9:1025650.
doi: 10.3389/fsurg.2022.1025650

COPYRIGHT
© 2023 Yang, Sheng, Liu, Wang, Liu and Xiao. This is an open-access article distributed under the terms of the Creative Commons Attribution License (CC BY). The use, distribution or reproduction in other forums is permitted, provided the original author(s) and the copyright owner(s) are credited and that the original publication in this journal is cited, in accordance with accepted academic practice. No use, distribution or reproduction is permitted which does not comply with these terms.

Sacroiliac screws fixation navigated with three-dimensional printing personalized guide template for the treatment of posterior pelvic ring injury: A case report

Zhanyu Yang[1,2], Bin Sheng[1,2]*, Delong Liu[1,2], Yiwei Wang[1], Chao Liu[1] and Rui Xiao[1]

[1]Department of Orthopedics, Hunan Provincial People's Hospital (the First Affiliated Hospital of Hunan Normal University), Changsha, China, [2]Department of Orthopedics, Hunan Emergency Center, Changsha, China

Objective: Pelvic injuries refer to the disruption of the inherent structural and mechanical integrity of the pelvic ring. Sacroiliac screw fixation technique is often used for the treatment of posterior pelvic ring injury, which is prone to the iatrogenic injury. Various attempts were proposed to avoid iatrogenic injuries, while the executing processes are usually too cumbersome. The patient-personalized guide template based on 3D printing technology has been considered as a promising method, which can achieve lower deviation and higher accuracy in a simple and convenient way. We reported the first case of posterior pelvic ring injury using 3D printing personalized guide template with the verification of intraoperative CT.

Methods: The subject was a 74-year-old female with posterior pelvic ring injury. Two patient-specific guide templates were customized based on 3D printing technology, one for S1 and the other for S2. We used the guide templates for navigation to place the sacroiliac screws. The placement of screws was verified by intraoperative CT. Intraoperative and postoperative variables were collected.

Results: The technique helped us successfully insert the sacroiliac screws into the safe zone. The intraoperative blood loss was 23.03 ml, and the duration of operation was 62 min. The exposure dose during CT scanning was 7.025 mSv. The assessment of screws position was excellent. Furthermore, there was no sign of any functional impairment postoperatively.

Conclusion: Sacroiliac screws fixation with the assistance of 3D printing personalized guide template under the verification of intraoperative CT may be a promising method to treat posterior pelvic ring injuries.

KEYWORDS

posterior pelvic ring injury, sacroiliac screw fixation, 3D printing technology, guide template, case report

Introduction

Pelvic injuries refer to the disruption of the inherent structural and mechanical integrity of the pelvic ring, accounting for 3% of all skeletal fractures (1, 2). Despite the lack of bony synostosis, the pelvic ring is highly stable due to the presence of numerous strong and extensive attachments of muscles, tendons, and ligaments (3). Therefore, the pelvic injuries raise more attention since it is most occurred in the setting of high energy and is frequently complicated with additional injuries elsewhere in the body (4). It is reported that the injury of the posterior pelvic ring is significantly associated with the increased morbidity, mainly related to hemorrhagic shock caused by venous plexus injury (5).

With the development and practical application of minimally invasive techniques, percutaneous insertion of cannulated screws into the sacroiliac joint has been applied to the injuries of posterior pelvic ring. Compared to traditional fixation, percutaneous screw fixation technique presents an excellent result, allowing a shorter duration of surgery, a smaller incision, less soft tissue damage and less bleeding (6). There is a safe zone between the neuroforamen and the cortex of the sacrum, which is often wide enough to place sacroiliac screws. However, some patients accompanied with atypical anatomy have narrow corridors so that it is difficult to locate the safe zone during operation. The conventional 2D imaging with mobile C-arm cannot obtain the view of the safe area directly (7). As a result, although the frequency of fluoroscopy exposure is often increased, the incidence of complications cannot be significantly reduced. Under conventional fluoroscopy, the misplacement rate of screws has been reported at 2%–16% (8–10). Sacroiliac screw fixation technique is prone to the iatrogenic complication of vascular and nerve injury, with an incidence of 0.5%–7.7% (11, 12). Because of the limitations of the current percutaneous sacroiliac screw fixation, it is not only the improvement of surgical skills, but also the innovative guidance methods and newly implements have been introduced to increase the accuracy of screws position. Various attempts have been proposed to avoid the misposition of internal plants, such as intraoperative CT, 3D fluoroscopy and computer-assisted techniques (13–16).

These methods may decrease the incidence of iatrogenic injuries and raise the success rate of surgery, while the executing processes are too cumbersome and limited by expensive imaging devices. Recently, a patient-personalized guide template based on 3D printing technology for precise navigation of sacroiliac screws has been considered as a promising method to improve security, which can achieve lower deviation and higher accuracy in a simple and convenient way (17, 18). Moreover, Intraoperative CT can provide vivid and complete three-dimensional imaging and facilitate the location of safe area accurately, which has become a reliable tool for assessing the malposition of internal plants, especially in spine surgery (19).

Here we report a 74-year-old female patient, the first case of posterior pelvic ring injury using 3D printing personalized guide template with the verification of intraoperative CT.

Case presentation

Participant

A 74-year-old, previously healthy female patient (weight 62.3 kg, BMI = 25.60 kg/m^2) was injured in a traffic accident, presented to Department of Orthopedics of our hospital. She sustained a rotationally unstable pelvic posterior ring injury (Tile B2-1) consisting of a right sacroiliac joint fracture, an ipsilateral fracture of upper and lower ramus of pubis and an ipsilateral L5 transverse process fracture (**Figure 1**). There were no symptoms of sacral nerve injury such as perineum numbness and fecal incontinence. The patient had no previous history of severe trauma and no specific family history. Physical examination revealed the peripheral nervous system was normal, but the involved parts had tenderness and limited hip movement. The laboratory examination demonstrated that there was a mild anemia, and the rest had no obvious abnormality. The imaging examination showed a fracture of upper and lower ramus of right pubis, an ipsilateral sacral crescent fracture and an ipsilateral L5 transverse process fracture.

L5 transverse process fracture indicates the iliolumbar ligament injury, while sacral crescent fracture indicates the interosseous sacroiliac ligament injury. All evidence suggested that this was a partially stable injury of the posterior pelvic ring caused by lateral compression. Given the patient's complaints and examination, percutaneous sacroiliac screws fixation, a minimally invasive technique, was adopted for the treatment. We informed the patient of the potential hazard of such a procedure to blood vessels and nerves. Subsequently, with the consent and request of the patient and his legal guardian, a supplementary plan consisting of percutaneous sacroiliac screws fixation, navigation with three-dimensional printing personalized guide template and verification with intraoperative CT was proposed and accepted.

Materials preparation

CT scanning of pelvis was preoperatively performed to obtain the three-dimensional reconstruction data. Then, the findings were used for modelling *via* computer-aided design (CAD) and computer-aided manufacture (CAM) technology. The duplicate of the pelvis and the personalized guide template were manufactured with 3D printing technology.

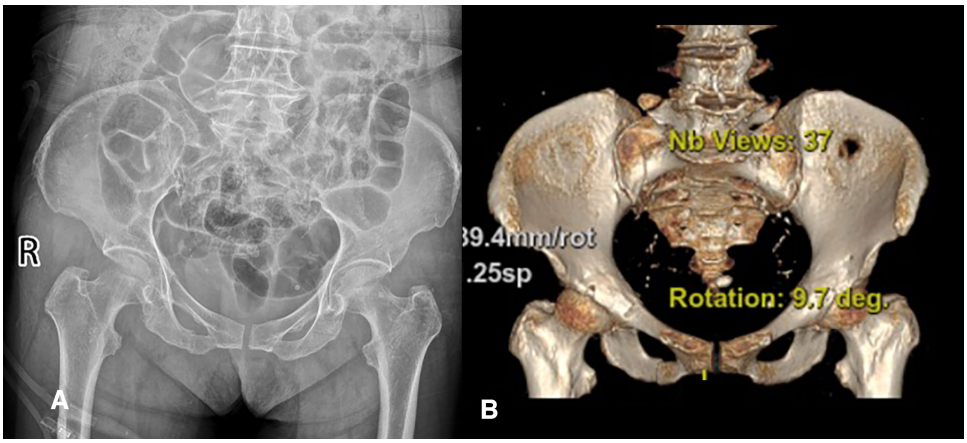

FIGURE 1
The imaging examination before surgery. (A) The anteroposterior radiograph of pelvis. (B) Three-dimensional reconstruction of pelvis.

Alistone C3850, a 3D printer produced in Guiyang, China, was committed to model manufacturing with a printing accuracy of 0.05–0.4 mm and a printing speed of 20–300 mm/s. The duration of printing this guide template was approximately 42 h. It was intended to navigate the guidewires into the safe zone between the neuroforamen and the cortex of the sacrum accurately (Figure 2). The guide template is composed of three parts (Figure 3): anchoring surface, bridging rod, and positioning hole. The anchoring surface is used to fix the template next to the anterior superior iliac spine, and the bridging rod is a connection between the anchoring surface and the positioning hole outside the body. The positioning hole is used for percutaneous insertion of the guidewire.

The Siemens SOMATOM Conficence® RT Pro was used for intraoperative scanning. The device, a standard 64-slice dual-energy photon large-aperture CT, with the Direct Density™ technique, greatly broadens the selection of scanning voltage, maintains the accuracy of dose measurement, and obtains more accurate image quality.

Surgery process

The patient positioned supine on a radiolucent table in an operating room integrated with mobile intraoperative CT scanner, and the standard posture was shown in the Figure 4. Make an incision on the body surface next to the anterior superior iliac spine, anchor the S1 and S2 screw guide templates at the iliac spine respectively, and place the guidewires along the positioning hole (Figure 5). After the placement was verified with rail-bound CT, cannulated screws were inserted for fixation (Figure 6). The operation workflow was shown in Figure 7. If the position of the guidewires was not good under intraoperative CT verification, the differences

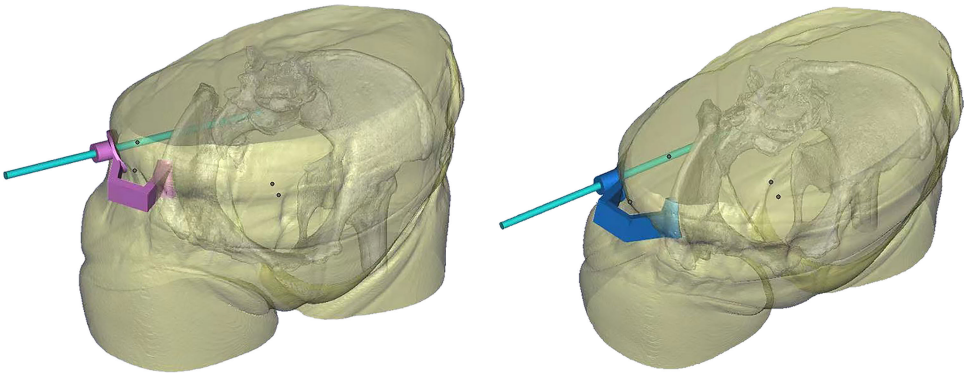

FIGURE 2
Design of the guide template. (A) Example of preoperative planning for S1 screw placement. (B) Example of preoperative planning for S2 screw placement.

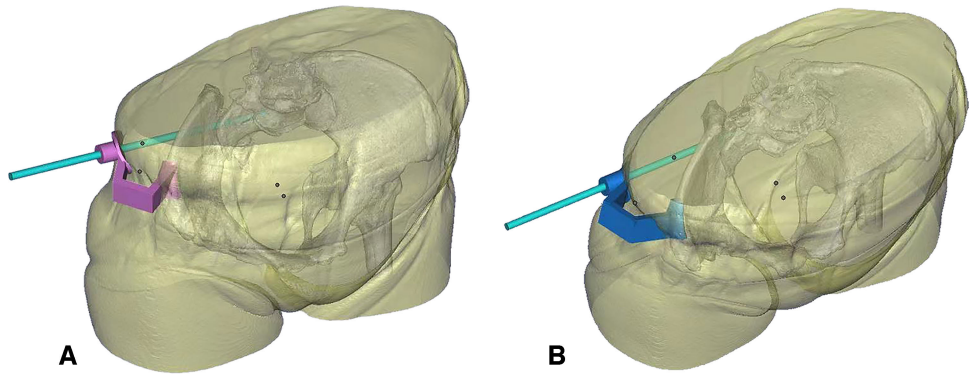

FIGURE 3
3D printing model of this case. (A) The anchoring surface is used to fix the template next to the anterior superior iliac spine. (B) The bridging rod is a connection between the anchoring surface and the positioning hole outside the body. The positioning hole is used for percutaneous insertion of the guidewire.



FIGURE 4
Standard posture of the patients with sacroiliac screw fixation assisted by intraoperative CT.

of the angle and distance would been measured *via* computing technology and would make timely and accurate adjustment during operation. The screws were accurately placed in the safe zone as shown in the **Figure 8**. In addition, during the operation, it is necessary to peel the soft tissue at the attachment of the guide template and completely cut the fascia with obvious tension, so as not to affect the accuracy of the guide template.

Data analysis

The blood loss (ml) calculated by weighing the blood-soaked gauze. The amount of blood loss (g) = the weight of gauze after wiping all blood loss—the weight of dry gauze (1 g = 1 ml). The intraoperative blood loss was 23.03 ml, and the duration of operation was 62 min. The volume computed tomography dose index (CTDlvol) refers to the average dose of slice in the whole spiral scanning volume. Dose length product (DLP) is used to evaluate the total exposure dose during CT scanning. DLP (mGy·cm) = CTDlvol (mGy) * L (cm), L is the length of scanning. mSv = mGy * k, k is a constant and the value of k for the pelvis is 0.015. The exposure dose during CT scanning was 7.025 mSv. The assessment of screws position was excellent based on the criteria of Gras et al. (20). No signs of iatrogenic vascular and nerve injury and other complications were found after operation.

All authors declare that all methods were carried out in accordance with relevant guidelines and regulations and all experimental protocols were approved by Hunan Provincial People's Hospital ethics committee. Written informed consent was obtained from the subject and legal guardian for the publication of any potentially identifiable images or data included in this article.

Discussion

The structure of pelvic ring is crucial for weight-bearing and mobilization, which is so firm that the disruption of pelvic ring is most frequently occurred in high-energy events (21). The pelvic ring injury is complex since it is commonly accomplished with multiple injuries and may process to dramatic and uncontrolled multiple organ dysfunction syndrome (22). The conventional fixation methods are subjected to more blood loss, longer procedure time, and higher risk of infection, which hinders the recovery and may lead to secondary injury. The minimally invasive method, sacroiliac screws fixation, is gradually substitute for conventional methods in the treatment of posterior pelvic ring

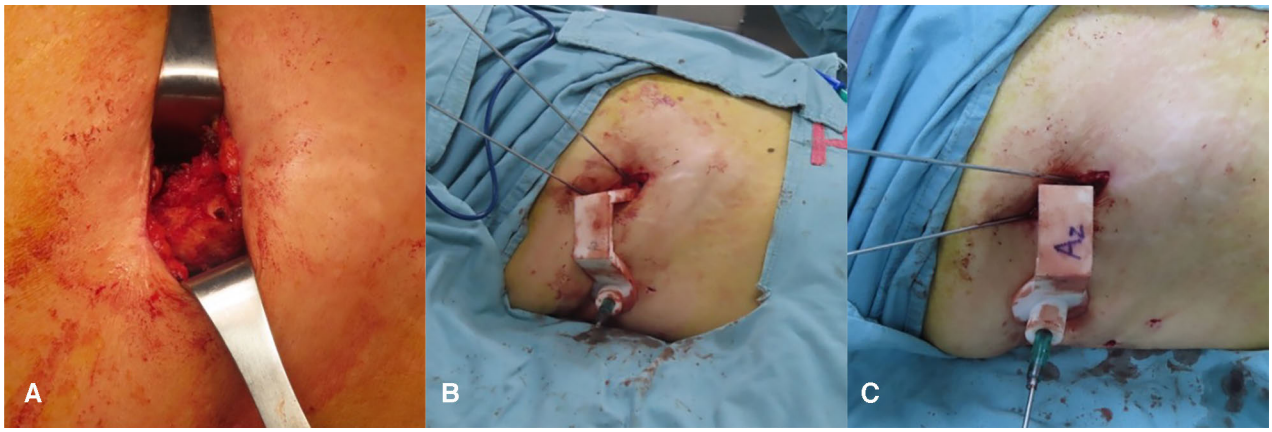

FIGURE 5
The processes in inserting guidewires with 3D printing guide template. (**A**) Make an incision on the body surface next to the anterior superior iliac spine. (**B**,**C**) Anchor the S1 and S2 screw guide templates at the iliac spine respectively and place the guidewires along the positioning hole.

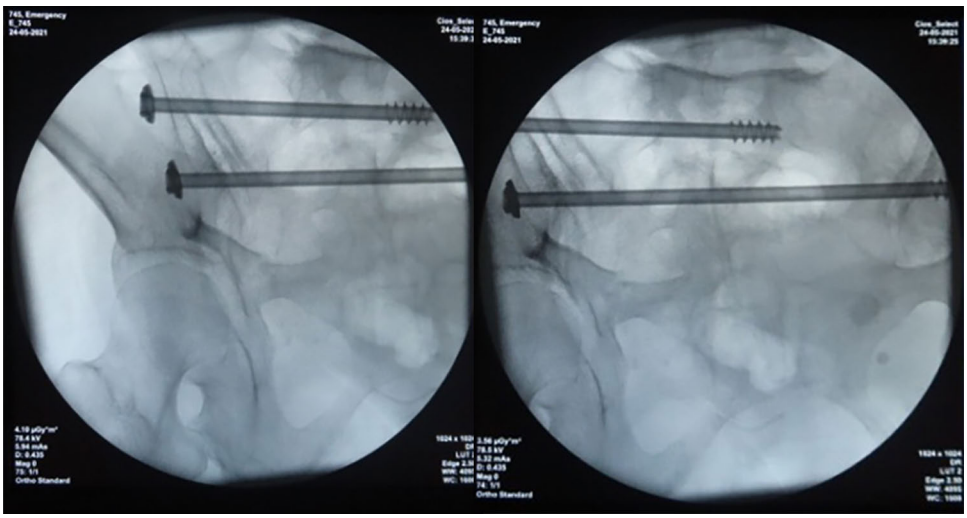

FIGURE 6
Radiographic imaging with C-arm.

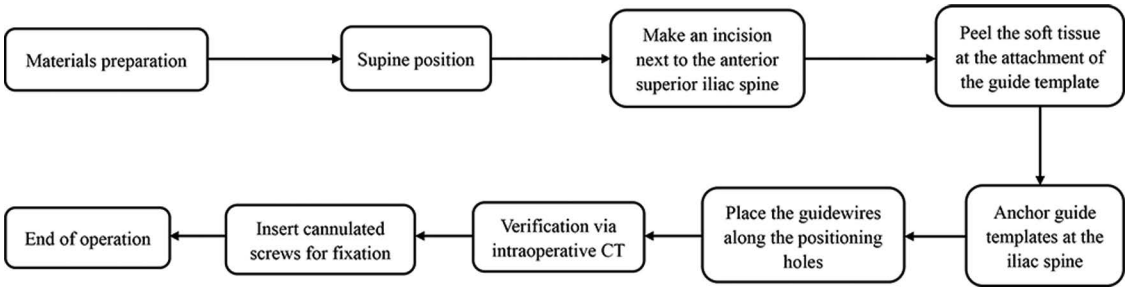

FIGURE 7
The operation workflow.

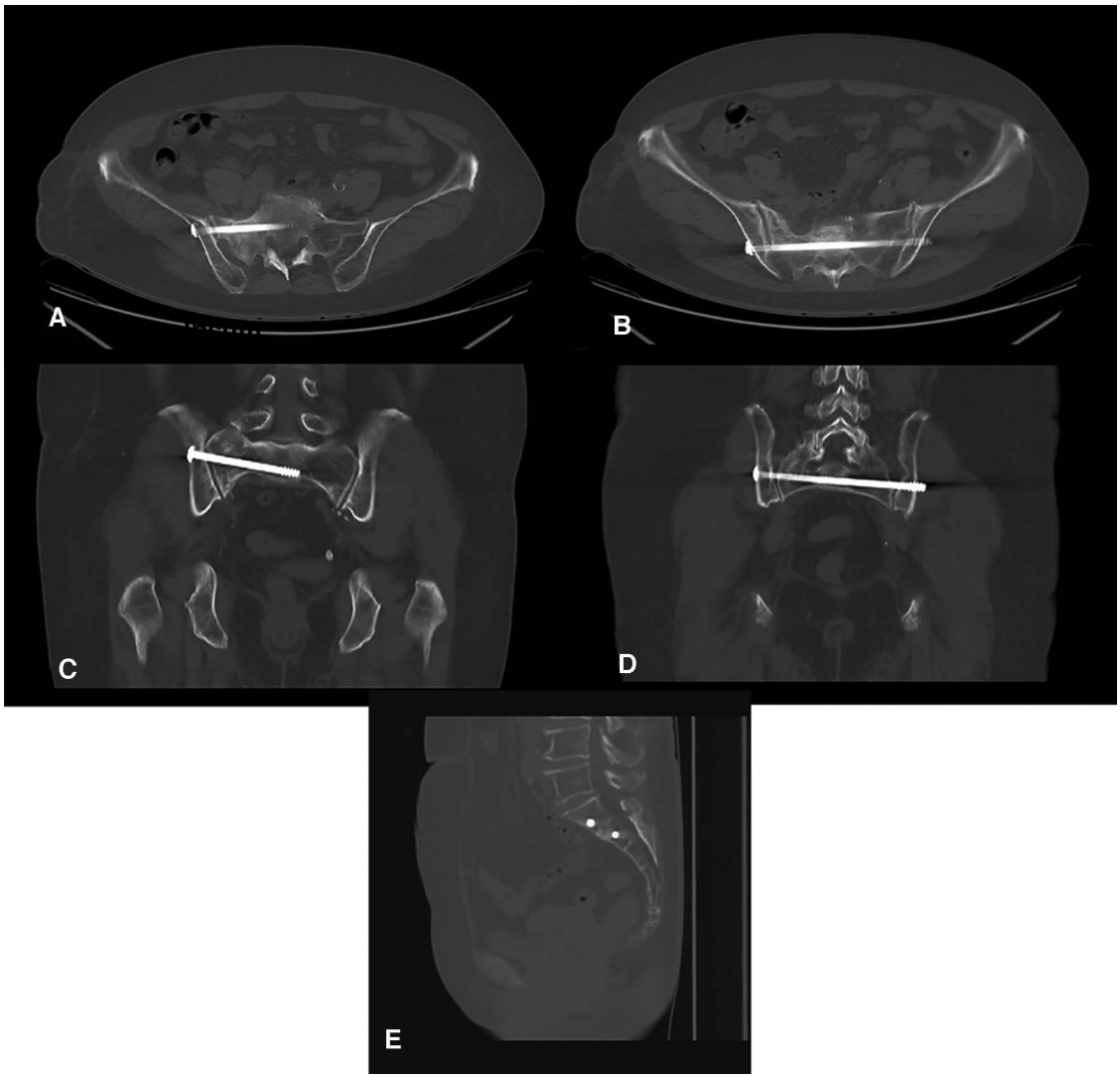

FIGURE 8
Imaging verification with rail-bound CT during operation. (A,B) Horizontal view. (C,D) Coronal view. (E) Sagittal view.

injuries (23). However, the method is challenging, necessitates precise placement of implants to avoid serious complications (24). Only a minimal deviation can cause an accurate penetration of the S1 foramina or the presacral cortex when fixed with the sacroiliac screws (25).

3D printing personalized guide template, a rising and precise minimally invasive technology, is gradually being introduced to assist the surgery (17, 18). Personalized guide templates can be customized according to specific injuries. It is expected to navigate the insertion of sacroiliac screws, diminish deviation, and avoid complications. However, at present, there is no study on the application of 3D printing guide template in the sacroiliac screw fixation. We tried to use 3D printing guide template to navigate sacroiliac screw insertion to evaluate the possibility of applying this technique in patients with posterior pelvic ring injury. We report for the first time that 3D printing personalized guide template is used for treatment of posterior pelvic ring injuries with sacroiliac screws under the intraoperative rail-bound CT verification and assistance. In this case, 3D printing personalized guidance template was successfully assist sacroiliac screws in the treatment of posterior pelvic ring injury.

The volume of bleeding in this patient was 23.03 ml, which was better than our usual data. Percutaneous sacroiliac screws fixation usually requires only a smaller incision than plate fixation, allowing a minimal blood loss (26). With the assistance of 3D printing guide template, the insertion point of guidewires can be directly located to reduce the chances of extending the incision. The vascular damage also can be prevented, which may lead to catastrophic bleeding and

hemorrhagic shock. In term of the operative duration, previous studies have shown that the application of a new assistive technique in the navigation of internal fixation often leads to a potential increase in the length of operation due to the additional preparation and execution (27, 28). However, in this case, we found that the time of sacroiliac screw implantation can be shortened with the aid of guide template. On the one hand, redundant surgical steps in the surgical process can be avoided. On the other hand, the times of repeatedly adjusting the fluoroscopy to evaluate the screw direction can be reduced. Even the hidden gaining of averting unexpected anesthesia and surgery to correct screw dislocation have not been considered. If the technique is skilled enough, the surgical time would be further shortened. After all, this is only our first attempt.

Perhaps another issue that needs more attention is radiation dosage. It is well known that radiation exposure in medicine is by no means benign. It can cause diseases and injuries, whether to patients or surgeons, accounting for approximately 0.6%–3% of the cancer cases (29). It is reported that the radiation exposure of minimally invasive techniques is higher than that of open surgery (30). In this case, the intraoperative CT was used to verify the effect of the guide template and ensure the safety of patient during operation. And the intraoperative CT showed that the orientation of the guide template was almost accurate. Traditional procedures of sacroiliac screws require more fluoroscopy and time, in contrast there are less times with the assistance of guide template. Furthermore, the surgeons are closest to the radiation source during the conventional procedures of sacroiliac screws, whereas for guide template, they are not. Potential damage from radiation exposure can also be minimized by guide template.

As for complications, the frequency of intraoperative fluoroscopy and the possibility of prolonging the incision due to poor positioning can be reduced through the navigation of the guide template. Secondary traumatic bleeding caused by surgery was also reduced. There were no screws loosening or failure postoperatively. Intraoperative CT could provide a better image quality in the critical anatomical regions of the pelvis. And according to Gras et al. (20), the quality of screws position in this case is excellent. Revision surgery is usually occurs in screws misplacement under conventional approach. An obviously increased risk of adjacent nerves and blood vessels would occur when the displacement was larger than 10 mm (31). Moreover, there was no iatrogenic vascular nerve injury in this case. Up to 8% of patients receiving sacroiliac screw fixation have nerve-related injuries and symptoms (32). When using sacroiliac screw fixation to treat pelvic posterior ring injury, surgeons must be more careful to avoid iatrogenic injury (33–35). In sum, it suggested that the use of 3D printing guide template technology can facilitate intraoperative navigation and reduce the possibility of screws placement into the sacral foramens and the occurrence of iatrogenic injury.

Finally, as far as the economic cost is concerned, the current cost of 3D printer system is between 50,000 and 100,000 RMB. The treatment requires an additional payment for 3D printing, which is about 1,000 to 2,000 RMB, depending on the size of the printing model and the number of customized guide templates. Although a part of the economic burden is increased, the expected benefits must be considered. The estimated cost of revision surgery is approximately 30,000 to 40,000 RMB. This potential risk expenditure is 15–40 times of the cost of 3D printing technology. The time in the operation and the cost of revision surgery for symptomatic screw misplacement can be saved *via* 3D printing guide template, which can be regarded as the return on investment of 3D printing technology purchase. The use of 3D printer by multiple disciplines further increases the return on investment. Finally, the use of such a device is conducive to improve patient safety, which is what we are pursuing. Taking all these factors into account, the benefits of 3D printing guide templates for sacroiliac screws far outweigh the disadvantages from an economic perspective.

There are also several limitations in current study. Firstly, these are just conjectures obtained from a common case, in nature, which was prone to random variations and uncontrolled bias. Secondly, only one device can be relied on, and more data originated from other similar systems is required. Thirdly, there is a limiting factor in the implementation and development of such an intraoperative CT and 3D printer, which requires high investment, so that it is relatively rare in general hospitals. Fourth, there is no follow-up data for this case currently. The research subject will continue be followed up. If feasible, a multicenter study will be performed, and more cases will be included in the future. Fifth, this treatment may only apply to pelvic fractures within type B of Tile classification. Finally, obesity may pose some risk of bias between the 3D template and actual condition when performing percutaneous sacroiliac screw, affecting the accuracy of the guide template. In view of the above problems, trials with larger samples and higher quality can be carried out in the future to better control confounding variables and improve the reliability of findings. Furthermore, separate radiation protection guidelines should be proposed and followed to better protect patients.

Conclusion

To summarize, we believe that a reduction of surgical duration and blood loss with intraoperative assistance of 3D printing personalized guide template could be obtained. Less misposition and functional impairment could be achieved, and a more satisfactory curative effect could be developed. Therefore, sacroiliac screws fixation with the assistance of 3D printing personalized guide template may be a promising

method to treat posterior pelvic ring injuries. Of course, in view of the sample size, more cases, more practice, and more frequent use are needed to further study the existence of this difference.

Data availability statement

The original contributions presented in the study are included in the article/Supplementary Material, further inquiries can be directed to the corresponding author.

Ethics statement

The studies involving human participants were reviewed and approved by Hunan Provincial People's Hospital ethics committee. The patients/participants provided their written informed consent to participate in this study. Written informed consent was obtained from the subject and legal guardian for the publication of any potentially identifiable images or data included in this article.

Author contributions

ZY and BS conceived and designed the study. ZY, DL analyzed the data and wrote the manuscript. CL and RX collected the related data. The original text was drafted and modified by YW. All authors contributed to the article and approved the submitted version. All authors agree to be accountable for the content of the work.

Acknowledgments

The authors would like to acknowledge and thank the individual patient involved who agreed to the publication of this article.

Conflict of interest

The authors declare that the research was conducted in the absence of any commercial or financial relationships that could be construed as a potential conflict of interest.

Publisher's note

All claims expressed in this article are solely those of the authors and do not necessarily represent those of their affiliated organizations, or those of the publisher, the editors and the reviewers. Any product that may be evaluated in this article, or claim that may be made by its manufacturer, is not guaranteed or endorsed by the publisher.

References

1. Coccolini F, Stahel PF, Montori G, Biffl W, Horer TM, Catena F, et al. Pelvic trauma: WSES classification and guidelines. *World J Emerg Surg*. (2017) 12:5. doi: 10.1186/s13017-017-0117-6

2. Cullinane DC, Schiller HJ, Zielinski MD, Bilaniuk JW, Collier BR, Como J, et al. Eastern association for the surgery of trauma practice management guidelines for hemorrhage in pelvic fracture–update and systematic review. *J Trauma*. (2011) 71(6):1850–68. doi: 10.1097/TA.0b013e31823dca9a

3. Perry K, Mabrouk A, Chauvin BJ. Pelvic ring injuries. In: *Statpearls*. Treasure Island (FL): StatPearls Publishing (2022).

4. Davis DD, Foris LA, Kane SM, Waseem M. Pelvic fracture. In: *Statpearls*. Treasure Island (FL): StatPearls Publishing (2022).

5. McLaren AC, Rorabeck CH, Halpenny J. Long-term pain and disability in relation to residual deformity after displaced pelvic ring fractures. *Can J Surg*. (1990) 33(6):492–4. doi: 10.1016/0305-4179(90)90081-7

6. Ruatti S, Kerschbaumer G, Gay E, Milaire M, Merloz P, Tonetti J. Technique for reduction and percutaneous fixation of U- and H-shaped sacral fractures. *Orthop Traumatol Surg Res*. (2013) 99(5):625–9. doi: 10.1016/j.otsr.2013.03.025

7. Matityahu A, Kahler D, Krettek C, Stöckle U, Grutzner PA, Messmer P, et al. Three-dimensional navigation is more accurate than two-dimensional navigation or conventional fluoroscopy for percutaneous sacroiliac screw fixation in the dysmorphic sacrum: a randomized multicenter study. *J Orthop Trauma*. (2014) 28(12):707–10. doi: 10.1097/BOT.0000000000000092

8. Tonetti J, van Overschelde J, Sadok B, Vouaillat H, Eid A. Percutaneous ilio-sacral screw insertion. Fluoroscopic techniques. *Orthop Traumatol Surg Res*. (2013) 99(8):965–72. doi: 10.1016/j.otsr.2013.08.010

9. Hinsche AF, Giannoudis PV, Smith RM. Fluoroscopy-based multiplanar image guidance for insertion of sacroiliac screws. *Clin Orthop Relat Res*. (2002) 395:135–44. doi: 10.1097/00003086-200202000-00014

10. Zwingmann J, Konrad G, Kotter E, Südkamp NP, Oberst M. Computer-navigated iliosacral screw insertion reduces malposition rate and radiation exposure. *Clin Orthop Relat Res*. (2009) 467(7):1833–8. doi: 10.1007/s11999-008-0632-6

11. van den Bosch EW, van Zwienen CM, van Vugt AB. Fluoroscopic positioning of sacroiliac screws in 88 patients. *J Trauma*. (2002) 53(1):44–8. doi: 10.1097/00005373-200207000-00009

12. Giannoudis PV, Tzioupis CC, Pape HC, Roberts CS. Percutaneous fixation of the pelvic ring: an update. *J Bone Joint Surg Br*. (2007) 89(2):145–54. doi: 10.1302/0301-620X.89B2.18551

13. Andrade NS, Okafor L, Neuman BJ. Novel technique for sacral alar-iliac (S2AI) fixation. *Clin Spine Surg*. (2018) 31(9):373–6. doi: 10.1097/BSD.0000000000000574

14. Jost GF, Walti J, Mariani L, Cattin P. A novel approach to navigated implantation of S-2 alar iliac screws using inertial measurement units. *J Neurosurg Spine*. (2016) 24(3):447–53. doi: 10.3171/2015.6.SPINE1594

15. Bederman SS, Hahn P, Colin V, Kiester PD, Bhatia NN. Robotic guidance for S2-alar-iliac screws in spinal deformity correction. *Clin Spine Surg*. (2017) 30(1):E49–e53. doi: 10.1097/BSD.0b013e3182a3572b

16. Shillingford JN, Laratta JL, Park PJ, Lombardi JM, Tuchman A, Saifi C, et al. Human versus robot: a propensity-matched analysis of the accuracy of free hand versus robotic guidance for placement of S2 alar-iliac (S2AI) screws. *Spine*. (2018) 43(21):E1297–E304. doi: 10.1097/BRS.0000000000002694

17. Lamartina C, Cecchinato R, Fekete Z, Lipari A, Fiechter M, Berjano P. Pedicle screw placement accuracy in thoracic and lumbar spinal surgery with a patient-matched targeting guide: a cadaveric study. *Eur Spine J*. (2015) 24(Suppl 7):937–41. doi: 10.1007/s00586-015-4261-y

18. Matsukawa K, Kaito T, Abe Y. Accuracy of cortical bone trajectory screw placement using patient-specific template guide system. *Neurosurg Rev*. (2020) 43(4):1135–42. doi: 10.1007/s10143-019-01140-1

19. Hecht N, Kamphuis M, Czabanka M, Hamm B, König S, Woitzik J, et al. Accuracy and workflow of navigated spinal instrumentation with the mobile AIRO(®) CT scanner. *Eur Spine J*. (2016) 25(3):716–23. doi: 10.1007/s00586-015-3814-4

20. Gras F, Marintschev I, Wilharm A, Klos K, Mückley T, Hofmann GO. 2D-fluoroscopic navigated percutaneous screw fixation of pelvic ring injuries–a case series. *BMC Musculoskelet Disord*. (2010) 11:153. doi: 10.1186/1471-2474-11-153

21. Pereira GJC, Damasceno ER, Dinhane DI, Bueno FM, Leite JBR, Ancheschi BDC. Epidemiology of pelvic ring fractures and injuries. *Rev Bras Ortop*. (2017) 52 (3):260–9. doi: 10.1016/j.rbo.2016.07.021

22. Vardon F, Harrois A, Duranteau J, Geeraerts T. The initial management in intensive care of pelvic ring injury patients. *Ann Fr Anesth Reanim*. (2014) 33 (5):344–52. doi: 10.1016/j.annfar.2014.03.008

23. Banaszek D, Starr AJ, Lefaivre KA. Technical considerations and fluoroscopy in percutaneous fixation of the pelvis and acetabulum. *J Am Acad Orthop Surg*. (2019) 27(24):899–908. doi: 10.5435/JAAOS-D-18-00102

24. Eastman JG, Routt Jr ML. Correlating preoperative imaging with intraoperative fluoroscopy in iliosacral screw placement. *J Orthop Traumatol*. (2015) 16(4):309–16. doi: 10.1007/s10195-015-0363-x

25. Templeman D, Schmidt A, Freese J, Weisman I. Proximity of iliosacral screws to neurovascular structures after internal fixation. *Clin Orthop Relat Res*. (1996) 329:194–8. doi: 10.1097/00003086-199608000-00023

26. Ayoub MA, Gad HM, Seleem OA. Standalone percutaneous transiliac plating of vertically unstable sacral fractures: outcomes, complications, and recommendations. *Eur Spine J*. (2016) 25(4):1153–62. doi: 10.1007/s00586-015-3976-0

27. Wang JQ, Wang Y, Feng Y, Han W, Su YG, Liu WY, et al. Percutaneous sacroiliac screw placement: a prospective randomized comparison of robot-assisted navigation procedures with a conventional technique. *Chin Med J*. (2017) 130(21):2527–34. doi: 10.4103/0366-6999.217080

28. Zhu ZD, Xiao CW, Tan B, Tang XM, Wei D, Yuan JB, et al. TiRobot-assisted percutaneous cannulated screw fixation in the treatment of femoral neck fractures: a minimum 2-year follow-up of 50 patients. *Orthop Surg*. (2021) 13(1):244–52. doi: 10.1111/os.12915

29. Berrington de González A, Darby S. Risk of cancer from diagnostic x-rays: estimates for the UK and 14 other countries. *Lancet*. (2004) 363(9406):345–51. doi: 10.1016/S0140-6736(04)15433-0

30. Wang E, Manning J, Varlotta CG, Woo D, Ayres E, Abotsi E, et al. Radiation exposure in posterior lumbar fusion: a comparison of CT image-guided navigation, robotic assistance, and intraoperative fluoroscopy. *Global Spine J*. (2021) 11(4):450–7. doi: 10.1177/2192568220908242

31. Reilly MC, Bono CM, Litkouhi B, Sirkin M, Behrens FF. The effect of sacral fracture malreduction on the safe placement of iliosacral screws. *J Orthop Trauma*. (2003) 17(2):88–94. doi: 10.1097/00005131-200302000-00002

32. Liu HS, Duan SJ, Xin FZ, Zhang Z, Wang XG, Liu SD. Robot-assisted minimally-invasive internal fixation of pelvic ring injuries: a single-center experience. *Orthop Surg*. (2019) 11(1):42–51. doi: 10.1111/os.12423

33. Moon SW, Kim JW. Usefulness of intraoperative three-dimensional imaging in fracture surgery: a prospective study. *J Orthop Sci*. (2014) 19(1):125–31. doi: 10.1007/s00776-013-0475-1

34. Theologis AA, Burch S, Pekmezci M. Placement of iliosacral screws using 3D image-guided (O-arm) technology and stealth navigation: comparison with traditional fluoroscopy. *Bone Joint J*. (2016) 98-b(5):696–702. doi: 10.1302/0301-620X.98B5.36287

35. Khan JM, Lara DL, Marquez-Lara A, Rosas S, Hasty E, Pilson HT. Intraoperative CT and surgical navigation for iliosacral screws: technique for patients with sacral dysmorphism. *J Orthop Trauma*. (2018) 32(Suppl 1): S24–S5. doi: 10.1097/BOT.0000000000001213

frontiers | Frontiers in Surgery

TYPE Original Research
PUBLISHED 06 January 2023
DOI 10.3389/fsurg.2022.1014844

Check for updates

OPEN ACCESS

EDITED BY
Paphon Sa-ngasoongsong,
Mahidol University, Thailand

REVIEWED BY
Mati Pääsuke,
University of Tartu, Estonia
Balaji Zacharia

*CORRESPONDENCE
Wen-qiang Zhang
qfszwq@sina.com

SPECIALTY SECTION
This article was submitted to Orthopedic Surgery, a section of the journal Frontiers in Surgery

RECEIVED 09 August 2022
ACCEPTED 25 November 2022
PUBLISHED 06 January 2023

CITATION
Liu Y, Liu Y-f, Meng H-z, Sun T, Gao P, Li Z-z and Zhang W-q (2023) Total knee arthroplasty exhibits satisfactory long-term clinical efficacy in the treatment of hemophilia patients with stiff knees.
Front. Surg. 9:1014844.
doi: 10.3389/fsurg.2022.1014844

COPYRIGHT
© 2023 Liu, Liu, Meng , Sun, Gao, Li and Zhang. This is an open-access article distributed under the terms of the Creative Commons Attribution License (CC BY). The use, distribution or reproduction in other forums is permitted, provided the original author(s) and the copyright owner(s) are credited and that the original publication in this journal is cited, in accordance with accepted academic practice. No use, distribution or reproduction is permitted which does not comply with these terms.

Total knee arthroplasty exhibits satisfactory long-term clinical efficacy in the treatment of hemophilia patients with stiff knees

Yi Liu[1,2], Yi-fan Liu[1,2], Hong-zheng Meng[2], Tao Sun[2], Ping Gao[2], Zhao-zhi Li[2] and Wen-qiang Zhang[2]*

[1]Postgraduate Department, Shandong First Medical University, Jinan, China, [2]Department of Orthopaedic Surgery, The First Affiliated Hospital of Shandong First Medical University & Shandong Provincial Qianfoshan Hospital, Shandong Key Laboratory of Rheumatic Disease and Translational Medicine, Jinan, China

Objective: This study aimed to (1) determine the long-term clinical efficacy of total knee arthroplasty (TKA) in the treatment of hemophilia patients with stiff knessknees, (2) assess the 5- and 10-year prosthesis survival in hemophilia, and (3) determine whether the severity of preoperative stiffness would affect postoperative clinical outcomes and complication rates.

Methods: The clinical data of 71 patients (78 knees) with hemophilia and concomitant knee stiffness who had undergone TKA between September 2007 and June 2018 were retrospectively analyzed. All patients were male, their mean age at the time of surgery was 38.4. ± 7.9 years (range: 21–63 years), and the mean follow-up time was 8.7 years. To determine the effect of stiffness severity on clinical outcomes, the participants were categorized into two groups: severe [preoperative range of motion (ROM): <50°, 34 knees] and moderate (preoperative ROM: 50–90°, 44 knees). At preoperative and final follow-up, patients' post-TKA clinical and radiological outcomes, quality of life, complications, and long-term survival were assessed.

Results: Flexion contracture improved from 23.2 ± 10.8° before surgery to 5.9 ± 7.5° upon final follow-up, the Knee Society Score (KSS) increased from 31.4 ± 12.4 to 74.9 ± 11.5, and the KSS functional score increased from 37.6 ± 9.3 to 81.4 ± 12.8. The mean ROM improved from 54.6 ± 32.6° preoperatively to 80.9 ± 34.5° postoperatively. The 36-Item Short Form Survey physical and mental scores also improved significantly. All these differences were statistically significant before and after surgery ($P < 0.001$). The following postoperative complications occurred in 10 knees (12.8%): hemarthrosis ($n = 3$), stiffness ($n = 4$), superficial infection ($n = 1$), skin necrosis ($n = 1$), and periprosthetic infection ($n = 2$), and revision TKA was performed on two knees. The 5- and 10-year survival rates of the prostheses were 98.5% and 93.7%, respectively. The mean ROM in the severe group increased from 30.7 ± 18.7° preoperatively to 70.5 ± 28.3° postoperatively ($p < 0.001$). The mean flexion contracture decreased from 27.3 ± 10.8° to 6.4 ± 12.0° ($p < 0.001$). The mean KSS improved from 27.0 ± 7.8 to 68.3 ± 9.6 ($p < 0.001$). The mean ROM in the moderate group improved from 84.3 ± 22.7 to 92.9 ± 28.8 ($p < 0.001$), while the mean flexion contracture decreased from 12.8 ± 11.0° to 4.8 ± 5.0° ($p < 0.001$) and the mean KSS improved from 41.3 ± 11.5 to

81.3 ± 12.2 ($p < 0.001$). The severe group had worse postoperative ROM and functional scores than the moderate group. Furthermore, the severe group used varus-valgus constrained or hinged prostheses more frequently (52.8% vs. 18.1%) and had more complications (18.9% vs. 9.0%) than the moderate group.

Conclusion: TKA exhibits satisfactory long-term efficacy in patients with hemophilic knee joint disease involving preoperative stiffness, thus potentially providing a significant improvement in function and reducing pain. Furthermore, severely stiff knee joints have worse clinical outcomes and more complications than moderately stiff knee joints.

KEYWORDS

hemophilia, stiff knee, total knee arthroplasty, outcomes, complication, survival

Introduction

Hemophilia is a hereditary bleeding disorder caused by a deficiency of clotting factors. Hemophilia A is the most common type of the disease and often manifests as repeated spontaneous bleeding in the joints and muscles, predominantly occurring in the knee, elbow, and ankle joints. Repeated intra-articular hemorrhage leads to hemosiderin deposition; synovial hyperplasia; articular cartilage destruction; and eventually joint pain, deformity, and dysfunction, which seriously affect patients' quality of life (1).

Owing to repeated bleeding and swelling of the knee joint, patients are forced to adopt the knee joint flexion position, resulting in knee joint flexion deformity, joint stiffness, and difficulty in surgical treatment. TKA in patients with hemophilia remains challenging to treat, with failure rates as high as 20% having been reported in the literature (2). Preoperative range of motion (ROM) is usually considered to be the most important predictor of functional outcome after TKA. Preoperative knee stiffness (defined as a preoperative ROM of 50 or less) has been shown to significantly impair overall clinical outcomes (3). In addition, a higher complication rate due to difficulty in knee exposure, soft tissue balance, and iatrogenic injury to extensors or patellar tendons has been reported (4).

Several studies involving short-to-medium-term follow-up have demonstrated that TKA for hemophilic knee arthritis can effectively relieve pain and improve joint mobility and patient satisfaction. However, the post-TKA prosthetic survival rate for patients with hemophilia is reported to be lower than that of patients without hemophilia, such as older patients with primary osteoarthritis (5–7). Possible reasons include younger age at the time of surgery, higher activity, heavy wear of the prosthesis, and higher incidence of postoperative infection. To date, studies have included only a few hemophilia cohorts with postoperative long-term TKA performed at multiple centers, and there are few available data reporting long-term outcomes in hemophilia patients. Therefore, this study aimed to (1) determine the long-term clinical efficacy of TKA in the treatment of hemophilia patients with stiff knees, (2) assess the 5- and 10-year prosthesis survival in hemophilia, and (3) determine whether the severity of preoperative stiffness would affect postoperative clinical outcomes and complication rates.

Materials and methods

Inclusion and exclusion criteria

The inclusion criteria were as follows: (1) hemophilia patients with stiff knees treated with TKA between September 2007 and June 2018, (2) Arnold–Hilgartner stage IV and V hemophilic arthropathy (8) (**Figure 1**), and (3) gait disorders and dysfunction due to severe pain and limited range of motion (ROM) as well as ineffective conservative treatment (**Figure 2**). The exclusion criteria were as follows: (1) lack of follow-up or incomplete radiological data and (2) other simultaneous surgical interventions, including total hip replacement, ankle replacement, or elbow replacement.

Patient data and study design

During this period, 85 patients (94 knees) with rigid hemophilia were treated at our hospital. Six patients (seven knees) were excluded due to loss to follow-up by 4 years, five patients (five knees) underwent total hip or ankle replacement during the same period, and the imaging data of three patients (four knees) were incomplete. Finally, 71 patients (78 knees) with hemophilia were included in this study. All patients were male, their mean age at the time of surgery was 38.4. ± 7.9 years (range: 21–63 years), and the mean follow-up time was 8.7 years. General patient information is shown in **Table 1**. All patients provided informed consent, and the study design was approved by the ethics committee of The First Affiliated Hospital of Shandong First Medical University (2022-S523).

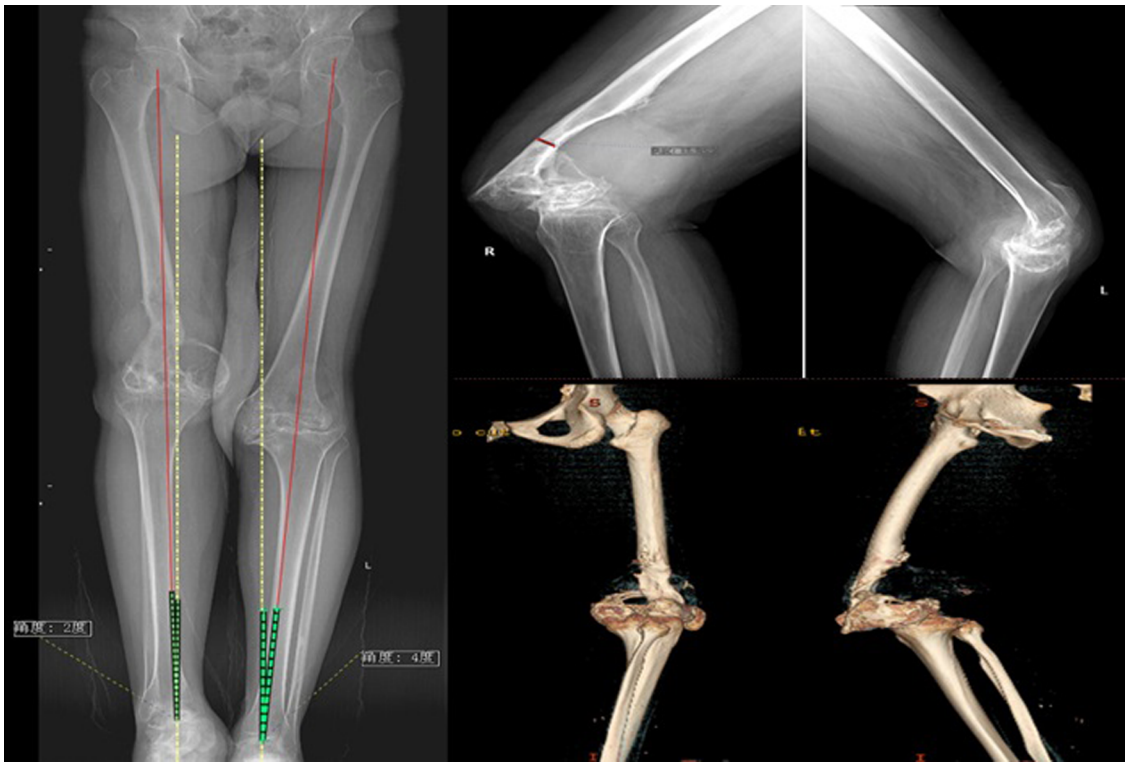

FIGURE 1
Preoperative roentgenograms and CT reconstruction of hemophilic arthropathy of the knee.

Perioperative management

All patients were treated based on the World Hemophilia Foundation guidelines, and treatments were adjusted based on clinical experience and economic status. Under normal circumstances, the concentration of coagulation factors was maintained at approximately 100% on the day of surgery, 80% in the first 3 postoperative days, 60% on days 4–6 after surgery, 40% on days 7–14 after surgery, and gradually decreased to 20%–30% thereafter. In addition to ensuring coagulation factor infusion, blood preparation was routinely performed preoperatively, and the dosage of coagulation factors was adjusted based on intraoperative blood loss and hemoglobin monitoring.

Operative technique

Standard radiographs (AP view, lateral view, and long-leg standing radiographs) were taken before surgery. Bone destruction was visualized on 3D CT bone reconstruction. Patients received intravenous tranexamic acid (TXA) 10 min before the skin incision (15 mg/kg) and topical TXA (1 g) was applied intra-articularly to each operated joint after articular capsule closure. We regularly administered prophylactic antibiotics *via* intravenous injection (cefazolin 2.0 g) 30 min before surgery and once afterward. Suction drains were not used to reduce postoperative bleeding and prevent infection. Intraoperative periarticular injections of ropivacaine and postoperative oral tramadol (50 mg twice daily) were administered to relieve pain. Surgeries were performed under general anesthesia with a tourniquet, and the procedure was similar to that of routine TKA (**Figure 3**). Most patients underwent the medial parapatellar approach (**Table 2**). The V–Y quadriceps femoris approach was used for 18 (23.1%) stiff knee joints with exposure and flexion difficulties. If flexion deformity could not be completely corrected during surgery, plaster braking and skin traction were implemented postoperatively. Different types of prostheses were used based on the degree of flexion deformity, ligament stability, and bone defects (**Table 2**).

Postoperative rehabilitation

None of the patients received anticoagulants. Physical methods, such as ankle pump and lower-limb elastic bandage, were used to prevent lower-limb deep venous thrombosis, and patients were instructed to perform straight leg lifting and



FIGURE 2
Clinical photograph showing preoperative deformity in patients with hemophilia.

TABLE 1 Patient demographics.

Patient demographics	
Number of patients (*n*)	71
Number of knees (*n*)	78
Age (y)[a] (range)	38.4 ± 7.9, (21–63)
20–39 (%)	23 (32.4)
30–39 (%)	25 (35.2)
40–49 (%)	18 (25.3)
50–59 (%)	4 (5.6)
60–69 (%)	1 (1.4)
Follow-up period (y)[a] (ranges)	8.7 ± 1.97, (4.3–15.2)
Hemophilia type (A/B)	62/9
ROM (<50°/50–90°)	34/37
HIV/HCV	0/6
Factor VIII inhibitor positive (%)	5 (7.0)

[a]Values are presented as the mean ± standard deviation.
ROM, range of motion; HIV, human immunodeficiency virus; HCV, hepatitis C virus.

ankle flexion as well as extension exercises. Lower-limb continuous-passive-motion training and lower-limb functional exercises assisted by walking aids were gradually performed. Personalized family rehabilitation and factor replacement programs were provided after discharge.

Clinical evaluation

Patients were followed up by telephone or at the outpatient clinic at 3 months, 6 months, and 1 year postoperatively. Patients were followed up annually thereafter. The Knee Society score (KSS) and KSS function score were used to evaluate knee function, the Short Form-36 score (SF-36) was used to evaluate quality of life, and the visual analysis scale (VAS) was used to evaluate the degree of pain. According to the KKS functional score, the overall results of greater than 85 points were regarded as excellent, those of 70–84 points as good, those of 60–69 points as general, and those of less than

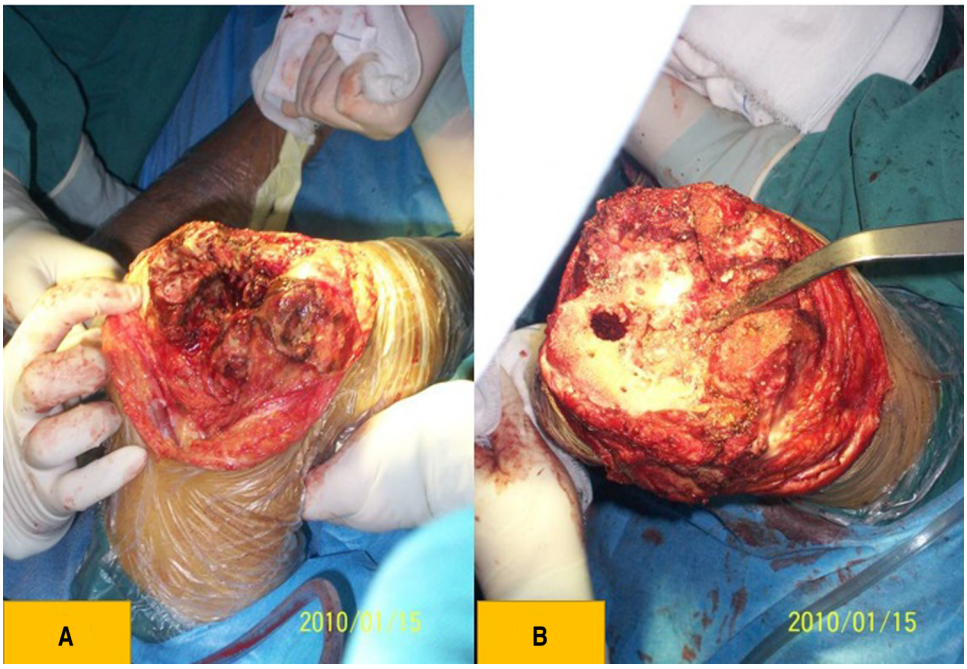

FIGURE 3
(A) clinical photograph showing that the bone structure was dysplastic, the patella was thin, and the femur was golf-club like and severely worn. (B) Clinical photograph showing tibial plateau dysplasia and bone defects.

TABLE 2 Surgical procedures.

Surgical procedures	Severe group ($n = 34$)	Moderate group ($n = 44$)	p-value
Medial parapatellar approach	21 (61.7)	39 (88.6)	<0.001
V–Y quadricepsplastya	13 (38.3)	5 (11.4)	
PS prosthesis	16 (47.1)	36 (81.8)	<0.001
VVC prosthesis	15 (44.1)	7 (15.9)	
Hinged prosthesis	3 (8.8)	1 (2.2)	
Patellar resurfacing	26 (76.4)	34 (77.2)	0.893
Patellar non-resurfacing	8 (23.6)	10 (22.8)	

Data are presented as numbers and percentages in the parentheses.
PS, posterior stabilized; VVC, varus-valgus constrained.

59 points as poor (9). Flexion contracture and ROM were measured using a long-arm goniometer (QK-JDC-1, China). The measurements were made based on the angle between the line from the greater trochanter to the lateral femoral condyle and the line from the lateral condyle to the tip of the lateral malleolus, centered on the most convex point of the lateral femoral condyle. Postoperative complications were recorded, and prosthesis survival rates at 5 and 10 years were evaluated.

Most previous studies defined preoperative stiffness as when the ROM was less than 50°, whereas other studies used 90° to define preoperative stiffness (10, 11). Therefore, we divided the subjects into two groups: a severe group (preoperative ROM, 50°; 34 knees) and a moderate group (preoperative ROM, 50°—90°; 44 knees) (Table 4). Clinical function and complication rates were compared between the two groups.

Statistical analysis

SPSS statistical software (version 26.0; IBM SPSS, Armonk, NY, USA) was used for statistical analyses. An independent-samples t-test was used to compare preoperative and postoperative KSS, SF-36, VAS, ROM, and flexion deformity scores. Student's t-test was used to compare the postoperative flexion deformity, ROM, and KSS scores between the severe and moderate groups. To determine whether our sample had sufficient power to detect a significant difference, we performed *post hoc* power analysis with a significance level for Student's t-tests and independent t-tests set to an alpha of .05. Power >80% was considered adequate, and all significantly different variables met the criteria.

Results

Clinical evaluation

The mean follow-up time was 8.7 ± 1.97 years. At the final follow-up, flexion contracture improved from 23.2 ± 10.8°

TABLE 3 Clinical outcomes between the preoperative stage and final follow-up.

Functional outcome	Preoperative	Final follow-up	*p*-value
Range of motion (∘)	54.6 ± 32.6	80.9 ± 34.5	<0.001
Flexion contracture (∘)	23.2 ± 10.8	5.9 ± 7.5	<0.001
KSS	31.4 ± 12.4	74.9 ± 11.5	<0.001
KSS function	37.6 ± 9.3	81.4 ± 12.8	<0.001
SF-36 physical score	27.3 ± 13.9	69.13 ± 14.2	<0.001
SF-36 mental score	31.48 ± 6.53	60.4 ± 7.12	<0.001
Overall result:			
Excellent, *n* (%)	–	49 (62.8)	<0.001
Good, *n* (%)	–	25 (32.0)	<0.001
Fair, *n* (%)	59 (75.6)	2 (2.5)	<0.001
Poor, *n* (%)	19 (24.3)	2 (2.5)	<0.001

KSS, American Knee Society score; SF-36, Short Form-36 score.

TABLE 4 Clinical outcomes between the severe and moderate groups.

	Severe group ($n = 34$)	Moderate group ($n = 44$)	*p*-value
Flexion contracture (°)			
Preoperative	27.3 ± 10.8	12.8 ± 11.0	<0.001
Final follow-up	6.4 ± 12.0	4.8 ± 5.0	<0.426
Range of motion (°)			
Preoperative	30.7 ± 18.7	84.3 ± 22.7	<0.001
Last follow-up	70.5 ± 28.3	92.9 ± 28.8	<0.001
KSS function (points)			
Preoperative	27.0 ± 7.8	41.3 ± 11.5	<0.001
Last follow-up	68.3 ± 9.6	81.3 ± 12.2	<0.001

KSS, American Knee Society score.

before surgery to 5.9 ± 7.5° at final follow-up ($p < 0.001$) (Table 3), the KSS score increased from 31.4 ± 12.4 to 74.9 ± 11.5 ($p < 0.001$), and the KSS function score increased from 37.6 ± 9.3 to 81.4 ± 12.8($p < 0.001$). The mean ROM increased from 54.6 ± 32.6° before surgery to 80.9 ± 34.5° after surgery ($p < 0.001$). The average VAS score decreased from 8.5 points before surgery to 2.1 points after surgery. The SF-36 physical and mental scores also significantly improved, and the differences before and after surgery were statistically significant; According to the KSS function scores, the overall result was excellent in 62.8% (49/78) and good in 32.0% (25/78), respectively.

The mean ROM in the severe group increased from 30.7 ± 18.7° preoperatively to 70.5 ± 28.3° postoperatively ($p < 0.001$). The mean flexion contracture decreased from 27.3 ± 10.8° to 6.4 ± 12.0° ($p < 0.001$). The mean KSS improved from 27.0 ± 7.8 to 68.3 ± 9.6 ($p < 0.001$). The mean ROM in the moderate group improved from 84.3 ± 22.7 to 92.9 ± 28.8 ($p < 0.001$). The mean flexion contracture decreased from 12.8 ± 11.0° to 4.8 ± 5.0° ($p < 0.001$). The mean KSS improved from 41.3 ± 11.5 to 81.3 ± 12.2 ($p < 0.001$). The severe group had worse postoperative ROM and functional scores than the moderate group, and recurrent postoperative stiffness was more common than in the moderate group (8.8% vs. 2.0%) (Table 4). Furthermore, the severe group used varus-valgus constrained or hinged prostheses more frequently (52.8% vs. 18.1%) and had more complications (18.9% vs. 9.0%) than the moderate group.

Radiographic evaluation

The radiograph of the knee joint after prosthetic position evaluation demonstrated that the prosthetic position was favorable, and the force line of the lower limbs was completely restored (Figures 4, 5). One patient (one knee) had a light transmission line around the femoral prosthesis 13 months after the operation, and it was considered a periprosthetic infection; no loosening, sinking, or osteolysis of the prosthesis was found in other cases.

Complications and survival rate

Postoperative complications occurred in 11 knees (14.1%) (Table 5). The rehospitalization rate 3 months after TKA was 10.2% (8/78 knees). The reasons for rehospitalization were joint hemorrhage, joint stiffness, superficial infection, and skin necrosis. Two knees (2.5%) underwent TKA due to periprosthetic joint infection 2 and 2.4 years after surgery. With prosthetic revision as the endpoint, the 5- and 10-year survival rates of the prosthesis were 98.5% and 93.7%, respectively.

Discussion

The most important finding of this study is that the long-term, clinical TKA results for the treatment of rigid hemophilic knee arthritis were satisfactory, thus indicating that TKA can significantly improve the postoperative function of patients, correct joint flexion deformity, and improve quality of life. Preoperative stiffness has been proven to be an important factor affecting the post-TKA function of patients with osteoarthritis. Few studies have examined the influence of stiffness on the clinical outcomes and complication rates of patients with hemophilia. Alpaslan et al. followed up 14 patients (21 knees) with hemophilia for 5.7 years and found that the degree of preoperative flexion spasm determined the clinical function of TKA in the treatment of hemophilic arthropathy (12). Straus et al. followed up 21 patients



FIGURE 4
The deformity was completely corrected 6 weeks after surgery.

TABLE 5 Postoperative complications between the severe and moderate groups.

	Severe group ($n = 34$)	Moderate group ($n = 44$)	p-value	Treatment
Complications, n (%)	7 (18.9)	4 (9.0)	<0.001	
Hemarthrosis, n	2	1		Incision and drainage of hematoma
Stiffness, n	3	1		Manipulation under anesthesia
Superficial infection, n	1	0		Anti-infection
Skin necrosis, n	0	1		Flap transplantation
PJI, n	1	1		Two-stage revision TKA

PJI, periprosthetic joint infection.

(23 knees) with hemophilia who had had a preoperative ROM ≤ 50° for 8.3 years, and their joint ROM increased from 26.7° before surgery to 73.0° after surgery. Flexion contracture decreased from 21.7° to 8.3°. The KSS score increased from 22.9 to 72.9 (5). Our study found that although the severe group (preoperative ROM: <50°) had more severe stiffness than the moderate group (preoperative ROM: 50–90°), it exhibited a greater ROM increase; however, the final joint ROM and clinical score in the severe group were poor, and the incidence of complications was higher than that in the moderate group. Even in the case of severe preoperative stiffness, TKA can effectively improve the joint mobility and functional scores of patients with hemophilia; however, surgeons should be aware of the poor clinical outcomes of patients with severe preoperative stiffness.

Long-term survival following TKA in nonhemophilic patients is well reported; higher rates of sterile mechanical failure of implants and shorter survival periods have been reported following TKA, especially in patients ≤50 years of age. Meanwhile, studies evaluating the post-TKA long-term survival of patients with hemophilia are limited (7, 13, 14). Generally, the implant survival rate of patients with hemophilia is considered to be lower than that of patients without hemophilia (15). Possible reasons include a younger age at the time of surgery, high activity, heavy wear of the prosthesis, and a high incidence of postoperative infection. In recent years, with the development of coagulation factor replacement therapy and improvements in prosthetic design, the survival rate of prostheses in patients with hemophilia after joint replacement has greatly improved. With prosthetic revision as the endpoint, the 10-year survival rate of prostheses in patients with hemophilia can exceed 80% (7). In this study, 71 patients (78 knees) were followed for an average of 8.7 years. The prosthesis survival rate was 98.5% at 10 years after surgery, a result that is superior to that reported in previous studies.



FIGURE 5
Radiograph of the anterior and lateral post-TKA positions after TKA, indicating that the position of the prosthesis was favorable.

The post-TKA infection rate of patients with hemophilia is reportedly 6.5%–16%, which is significantly higher than that of patients without hemophilia (16). The reasons for the high infection rate may include combined hepatitis C or immunodeficiency virus infection as well as bacteremia infection during the import of coagulation factors (1, 12). In this study, two patients developed periprosthetic joint infection, which was diagnosed 4.8 and 8.5 years after surgery, with an incidence of 2.5%. Although no definite etiology related to post-TKA periprosthetic infection in hemophilia exists, most patients undergo factor replacement on demand, thus potentially increasing the risk of bacterial contamination through the puncture point. Therefore, for hemophilia patients, more emphasis on aseptic surgery and the prophylactic application of antibiotics before invasive operation can still reduce the incidence of infection (10).

The post-TKA incidence of hemarthrosis in patients with hemophilia is reportedly significantly higher than that in patients without hemophilia (16). Studies have revealed that as the most common complication of hemophilia, the incidence of joint hemorrhage ranges from 12.5% to 25.6% (11). The main reasons include a low concentration of coagulation factors, the presence of coagulation factor inhibitors, synovial hemorrhage, and improper postoperative functional exercise (16). The risk of bleeding was highest within 1 week after surgery. Adequate replacement of coagulation factors and complete removal of the synovium during surgery are important measures for reducing bleeding. Mortazavi et al. (1) suggested that injecting tranexamic acid into the articular cavity and closely suturing the wound after surgery potentially reduce postoperative bleeding. All patients in this group underwent coagulation factor replacement before surgery. The synovium was completely removed, and tranexamic acid was injected into the articular cavity intraoperatively. In the present study, the incidence of postoperative joint bleeding was 5.1%, which is lower than the previously reported incidence of hemophilia. We believe that careful surgical techniques combined with specific rehabilitation and appropriate factor replacement schemes can reduce the incidence of postoperative joint bleeding.

This study had certain limitations. First, this was a retrospective study, with non-flexible knees constituting the control group. Considering the rare incidence of hemophilia, it is difficult to conduct such a prospective study in a single institution. Second, the 5-year follow-up time for some patients was relatively short. Hence, we could not determine the occurrence of late complications, such as aseptic loosening of the prosthesis or late prosthetic joint infection, which potentially develops over a long period after surgery. Third, all surgeries were performed by two senior surgeons, and different surgeons may be associated with an increased risk of infection or failure. Moreover, we used different implants according to the patient's condition. Fourth, we did not evaluate radiological outcomes for lower limb alignment. Finally, the age range of the participants in this study was large (21–63 years), and we did not investigate whether clinical efficacy and complications were associated with age in our analysis. Since TKA for hemophilia is a technically demanding procedure, we reviewed 78 knees from 71 hemophilia patients, which is a large number for a single institution. Despite the aforementioned limitations, the strengths of this study include the successful long-term results and good prosthesis survival, which has not been previously reported in a large-scale population from a single research institute.

Conclusion

TKA yields satisfactory mid-to-long-term results in the treatment of rigid hemophilic arthropathy, with significant improvements in function and pain relief. Furthermore, severely stiff knee joints have worse clinical outcomes and more complications than do moderately stiff knee joints.

Data availability statement

The raw data supporting the conclusions of this article will be made available by the authors, without undue reservation.

Ethics statement

The studies involving human participants were reviewed and approved by the study design was approved by the ethics committee of The First Affiliated Hospital of Shandong First Medical University.. The ethics committee waived the requirement of written informed consent for participation.

Author contributions

YL designed the study and wrote this article, which was substantially modified by WZ. All authors contributed to the article and approved the submitted version.

Funding

This work was supported by Shandong Provincial Key Research and Development Program (SPKR & DP) (No. 2019GSF108112).

Conflict of interest

The authors declare that the research was conducted in the absence of any commercial or financial relationships that could be construed as a potential conflict of interest.

Publisher's note

All claims expressed in this article are solely those of the authors and do not necessarily represent those of their affiliated organizations, or those of the publisher, the editors and the reviewers. Any product that may be evaluated in this article, or claim that may be made by its manufacturer, is not guaranteed or endorsed by the publisher.

References

1. Mortazavi SM, Haghpanah B, Ebrahiminasab MM, Baghdadi T, Toogeh G. Functional outcome of total knee arthroplasty in patients with haemophilia. *Haemophilia*. (2016) 22:919–24. doi: 10.1111/hae.12999

2. Rodriguez-Merchan EC. Total knee replacement in haemophilic arthropathy. *J Bone Joint Surg Br*. (2007) 89:186–8. doi: 10.1302/0301-620X.89B2.18682

3. Winemaker M, Rahman WA, Petruccelli D, de Beer J. Preoperative knee stiffness and total knee arthroplasty outcomes. *J Arthroplasty*. (2012) 27:1437–41. doi: 10.1016/j.arth.2011.12.015

4. Massin P, Petit A, Odri G, Ducellier F, Sabatier C, Lautridou C, et al. Total knee arthroplasty in patients with greater than 20 degrees flexion contracture. *Orthop Traumatol Surg Res*. (2009) 95:S7–S12. doi: 10.1016/j.otsr.2009.04.001

5. Strauss AC, Schmolders J, Friedrich MJ, Pflugmacher R, Müller MC, Goldmann G, et al. Outcome after total knee arthroplasty in haemophilic patients with stiff knees. *Haemophilia*. (2015) 21:e300–5. doi: 10.1111/hae.12698

6. Zingg PO, Fucentese SF, Lutz W, Brand B, Mamisch N, Koch PP. Haemophilic knee arthropathy: long-term outcome after total knee replacement. *Knee Surg Sports Traumatol Arthrosc*. (2012) 20:2465–70. doi: 10.1007/s00167-012-1896-7

7. Ernstbrunner L, Hingsammer A, Catanzaro S, Sutter R, Brand B, Wieser K, et al. Long-term results of total knee arthroplasty in haemophilic patients: an 18-year follow-up. *Knee Surg Sports Traumatol Arthrosc*. (2017) 25:3431–8. doi: 10.1007/s00167-016-4340-6

8. Srivastava A, Brewer AK, Mauser-Bunschoten EP, Key NS, Kitchen S, Llinas A, et al. Guidelines for the management of hemophilia. *Haemophilia*. (2013) 19:e1–e47. doi: 10.1111/j.1365-2516.2012.02909.x

9. Silva M, Luck Jr JV. Long-term results of primary total knee replacement in patients with hemophilia. *J. Bone Joint Surg. Am*. (2005) 87:85–91. doi: 10.2106/00004623-200501000-00012

10. Fosco M, Filanti M, Amendola L, Savarino LM, Tigani D. Total knee arthroplasty in stiff knee compared with flexible knees. *Musculoskelet Surg*. (2011) 95:7–12. doi: https://doi.org/10.1007/s12306-011-0099-6

11. Debette C, Lustig S, Servien E, Lording T, Villa V, Demey G, et al. Total knee arthroplasty of the stiff knee: three hundred and four cases. *Int Orthop*. (2014) 38:285–9. doi: https://doi.org/10.1007/s00264-013-2252-3

12. Atilla B, Caglar O, Pekmezci M, Buyukasik Y, Tokgozoglu AM, Alpaslan M. Pre-operative flexion contracture determines the functional outcome of haemophilic arthropathy treated with total knee arthroplasty. *Haemophilia*. (2012) 18:358–63. doi: 10.1111/j.1365-2516.2011.02695.x

13. Santos-Silva M, Rodrigues-Pinto R, Rodrigues C, Morais S, Costa E, Castro J. Long-term results of total knee arthroplasty in hemophilic arthropathy. *J Orthop Surg (Hong Kong)*. (2019) 27:2309499019834337. doi: 10.1177/2309499019834337

14. Bae JK, Kim KI, Lee SH, Yoo MC. Mid- to long-term survival of total knee arthroplasty in hemophilic arthropathy. *J Clin Med*. (2020) 9:3247. doi: 10.3390/jcm9103247

15. Jämsen E, Varonen M, Huhtala H, Lehto MUK, Lumio J, Konttinen YT, et al. Incidence of prosthetic joint infections after primary knee arthroplasty. *J Arthroplasty*. (2010) 25:87–92. doi: 10.1016/j.arth.2008.10.013

16. Feng B, Weng XS, Lin J, Qian W, Wei W, Sheng L, et al. Outcome of total knee arthroplasty combined patelloplasty for end-stage type A hemophilic arthropathy. *Knee*. (2012) 19:107–11. doi: 10.1016/j.knee.2011.01.002

frontiers | Frontiers in Surgery

TYPE Original Research
PUBLISHED 06 January 2023
DOI 10.3389/fsurg.2022.968535

Check for updates

OPEN ACCESS

EDITED BY
Paphon Sa-ngasoongsong,
Mahidol University, Thailand

REVIEWED BY
Desheng Wu,
Tongji University, China
Wanbo Zhu,
Shanghai Jiao Tong University, China

*CORRESPONDENCE
Pengtao Chen
18051061516@163.com
Jingcheng Wang
wangjcyangzhou@163.com

†These authors have contributed equally to this work

SPECIALTY SECTION
This article was submitted to Orthopedic Surgery, a section of the journal Frontiers in Surgery

RECEIVED 14 June 2022
ACCEPTED 25 November 2022
PUBLISHED 06 January 2023

CITATION
Liang Y, Hu J, Zhang P, Zhang J, Yang L, Zhang W, Chen J, He J, Fang Y, Zhou Y, Chen P and Wang J (2023) Clinical application of Kirschner wires combined with 5-Ethibond fixation for patella fractures.
Front. Surg. 9:968535.
doi: 10.3389/fsurg.2022.968535

COPYRIGHT
© 2023 Liang, Hu, Zhang, Zhang, Yang, Zhang, Chen, He, Fang, Zhou, Chen and Wang. This is an open-access article distributed under the terms of the Creative Commons Attribution License (CC BY). The use, distribution or reproduction in other forums is permitted, provided the original author(s) and the copyright owner(s) are credited and that the original publication in this journal is cited, in accordance with accepted academic practice. No use, distribution or reproduction is permitted which does not comply with these terms.

Clinical application of Kirschner wires combined with 5-Ethibond fixation for patella fractures

Yuan Liang†, Jinlong Hu†, Pei Zhang, Jiale Zhang, Lixun Yang, Wendong Zhang, Jiaxin Chen, Jinshan He, Yongchao Fang, Yuelai Zhou, Pengtao Chen* and Jingcheng Wang*

Department of Orthopedics, Clinical Medical College of Yangzhou University, Northern Jiangsu People's Hospital, Yangzhou, China

Background: Patella fractures that require surgery are conventionally treated using Kirschner wires (K-wires) and stainless steel wires. In recent years, the nonabsorbable polyester has been reported to have excellent outcomes clinically. Therefore, the goal of our study was to evaluate the effects of Kirschner wires combined with 5-Ethibond on treating patellar fractures.
Methods: From July 2018 to January 2022, 22 patella fracture patients were treated with Kirschner wires combined with 5-Ethibond. Radiographs of the knees were used to evaluate fracture healing and hardware complications. The clinical results were evaluated through the functional score, knee joint range of motion (ROM), and Bostman patella fracture functional score.
Results: The average age of patients was 57.4 ± 11.9 (range 33–74) years. The mean follow-up time was 15.2 ± 7.6 (range 4–36) months. The mean operation time was 56.8 ± 8.7 (range 45–80) min. The entire patients had bony union at an average of 10.5 ± 1.9 (range 8–14) weeks. At the final follow-up, the mean range of postoperative ROM was 123.4° ± 14.6° (range 95°–140°), and the functional score was 28.7 ± 1.2 (range 26–30) points. No patient exhibited internal fixation failure, and no symptomatic implants or skin complications were recorded.
Conclusions: The fixation approach using K-wires combined with 5-Ethibond has a lower complication rate and delivers superior clinical results. This research reveals that such technology is a safe and prospective substitute for conventional metal fixation approaches.

KEYWORDS
patella fracture, suture, tension band, Kirschner wire, 5-Ethibond

Introduction

Patella fractures account for approximately 1% of all skeletal fractures (1, 2) and are usually caused by the forceful contraction of the quadriceps femoris. These fracture features can be transverse, perpendicular, or stellate. Open reduction and internal fixation (ORIF) is necessary for fractures that have fragment displacement >3 mm, joint incongruence >2 mm, or a disrupted extensor mechanism. The aims of surgical treatment are to achieve the stable fixation of fragments, anatomical reduction of the articular surface, and early restoration of range of motion (ROM) (3, 4).

There are numerous methods for the internal fixation of patella fractures, and tension band wiring (TBW) technology is the most extensively utilized approach.

Such technology contains longitudinal Kirschner wires (K-wires) inserted across the fracture and a stainless steel wires (SSW) looped in an eight-like fashion over the anterior patella. Nevertheless, various SSW-related complications have been reported, including wire fatigue failure, wire irritation, and delayed wound healing (5, 6).

Consequently, several modifications have been introduced to avoid steel wire-related complications by using strong suture materials along with other tension band suture techniques (7).

At our department, our team used a modified tension band technology for treating patella fractures with K-wires combined with 5-Ethibond. This retrospective research is intended to clinically investigate the radiographic outcomes of K-wires combined with 5-Ethibond in the therapy of patella fractures.

Materials and methods

Patient characteristics

This research was approved by the Ethical Committee of the Clinical Medical College of Yangzhou University, and every patient offered informed consent. We collected retrospective data from all patients with displaced intra-articular patella fractures between July 2018 and January 2022. Preoperative x-ray and three-dimensional computed tomography (CT) scanning images were acquired to assess patella fractures. The inclusive criteria were as follows: all patients were older than 18 years; the individual with an acute closed patella fracture featuring an articular incongruity >2 mm or a separation of fragment fracture >3 mm; the general physical condition of the patient could withstand the anesthesia and operation; and fractures without any deep infection. The exclusion criteria were individuals who were younger than 18 years, simple or nondisplaced fractures with indications for conservative treatments; patients with open fractures, periprosthetic fractures, and pathologic fractures; patients who were followed up for less than 3 months; the general physical condition of the patients could not withstand the anesthesia and operation; patients receiving revision procedures; patients with knee function limitation or other severe medical conditions before injury; and individuals with multiple concomitant injury of the ipsilateral leg or other systems. Patients were treated with TBW with K-wires and 5-Ethibond. Patients' demographic information and operational information were obtained and analyzed based on the database of our hospital.

Surgical procedures

Every patient was treated with a single dosage of cefazolin (50 mg/kg, a maximal dosage of 2 g) antibiotic for antimicrobial prophylaxis within the 30-min incision. After anesthesia, the patient was put on the operation table in the dorsal position. Then, a longitudinal midline incision was made over the knee to expose the fractured site. Following that, the intra-articular hematoma and blood clots were cleaned; afterwards, a 5-Ethibond was introduced in a Krackow manner up and down the medial and lateral edges of the patellar tendon, during which two sharp reduction clamps were used to temporarily maintain reduction. The two or three 1.6-mm K-wires (Youke, Shanghai, China) were introduced in parallel by inserting them from the upper pole to the lower pole of the patella. The remaining four suture limbs passed through the patella. The sutures were afterwards tied at the superior pole with the knee in extension. The remaining 5-Ethibond was then passed through the front of the patella to form an eight-like shape (**Figure 1**); then, the retinaculum was repaired. During the surgery, the active knee joint displayed stable fracture, and x-ray fluoroscopic results demonstrated an excellent decrease in the fracture.

Postoperative management and evaluation

Postoperatively, x-ray examinations were completed the day after surgery. Generally, flexion in-brace (0°–90°) was allowed for 0–2 weeks postoperatively. Patients were regularly followed up every 4–6 weeks. Before the patient discharged from hospital, we told the patient that the rehabilitation plan was as follows: the knee ROM was progressively elevated, and patients exercised themselves with the objectives of realizing 90° flexion by the 28th day, 120° flexion by the 42nd day, and full ROM eventually. The demographic data of patients includes age, sex, trauma mechanisms, fracture types, and length of follow-up. Follow-up records includes fracture union time, knee joint ROM, Bostman score, and complications.

Radiographic images were analyzed to evaluate the original fracture types, displacements, implant positions, and treatment time.

Statistics

All data were described as the averages ± *SD*, and our statistic assay was completed *via* SPSS 26.0.

Results

The 22 patients were enrolled in the present research (7 males and 15 females). The average age of the patients was 57.4 ± 11.9 (range 33–74) years. The mean operation time was 56.8 ± 8.7 (range 45–80) min. The mean follow-up time was

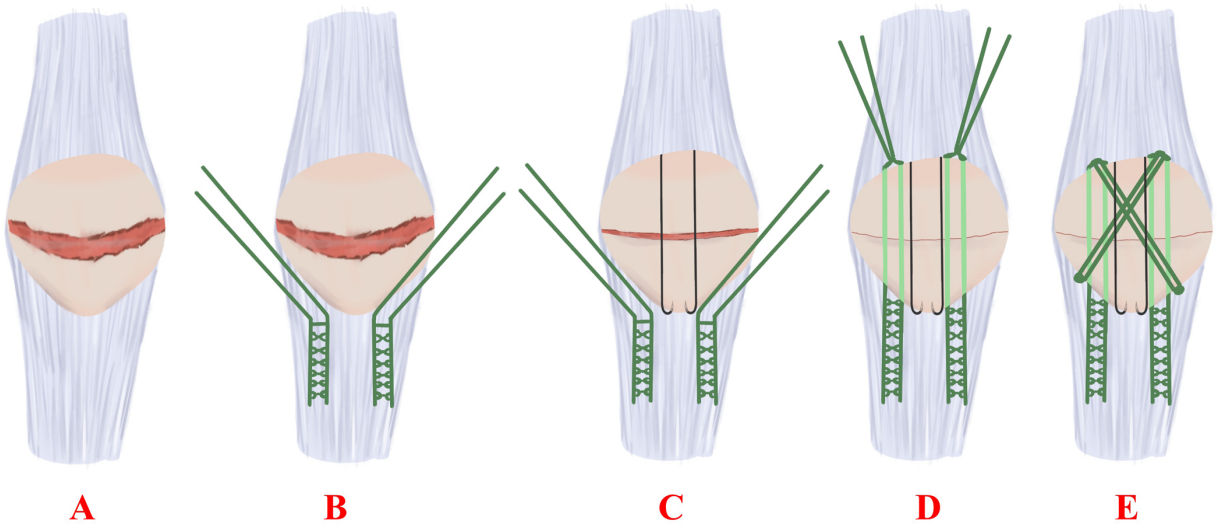

FIGURE 1
(A–E) Illustrations: surgical technique.

15.2 ± 7.6 (range 4–36) months. The demographic information is further demonstrated in Table 1.

All patients had bony union at an average of 10.5 ± 1.9 (range 8–14) weeks. There was no loss of reduction during follow-up. No breakage, loosening, migration, and skin irritation of the inner fixation were observed during the follow-up (Figures 2, 3). At the eventual follow-up, the mean postoperative ROM was 123.4° ± 14.6° (range 95°–140°) (Figure 4); we have not observe the K-wire slippage in all cases so far. The Bostman patella fracture function score was

TABLE 1 Patients demographic.

Case No.	Age	Sex	Mechanism of injury	Fracture type	Operation time (min)	Follow-up (months)
1	64	Female	Fall	Comminuted displaced	60	22
2	40	Male	Fall	Comminuted displaced	80	12
3	51	Female	Fall	Transverse with inferior pole comminution	70	10
4	41	Male	Fall	Simple transverse	50	13
5	73	Female	Fall	Comminuted displaced	60	5
6	50	Male	Fall	Comminuted displaced	55	18
7	66	Female	Fall	Simple transverse	50	23
8	52	Female	Fall	Simple transverse	55	26
9	57	Female	Fall	Transverse with inferior pole comminution	60	18
10	51	Male	Fall	Transverse lower 1/3	55	14
11	73	Female	Fall	Comminuted displaced	60	18
12	62	Female	Fall	Simple transverse	50	15
13	57	Female	Fall	Simple transverse	45	7
14	33	Male	Fall	Transverse lower one-third	45	15
15	38	Female	Fall	Comminuted displaced	60	12
16	53	Female	Fall	Comminuted displaced	70	36
17	64	Female	Fall	Comminuted displaced	45	18
18	65	Male	Fall	Comminuted displaced	55	17
19	64	Female	Fall	Comminuted displaced	60	10
20	68	Male	Fall	Comminuted displaced	55	18
21	66	Female	Fall	Simple transverse	50	4
22	74	Female	Fall	Comminuted displaced	60	4

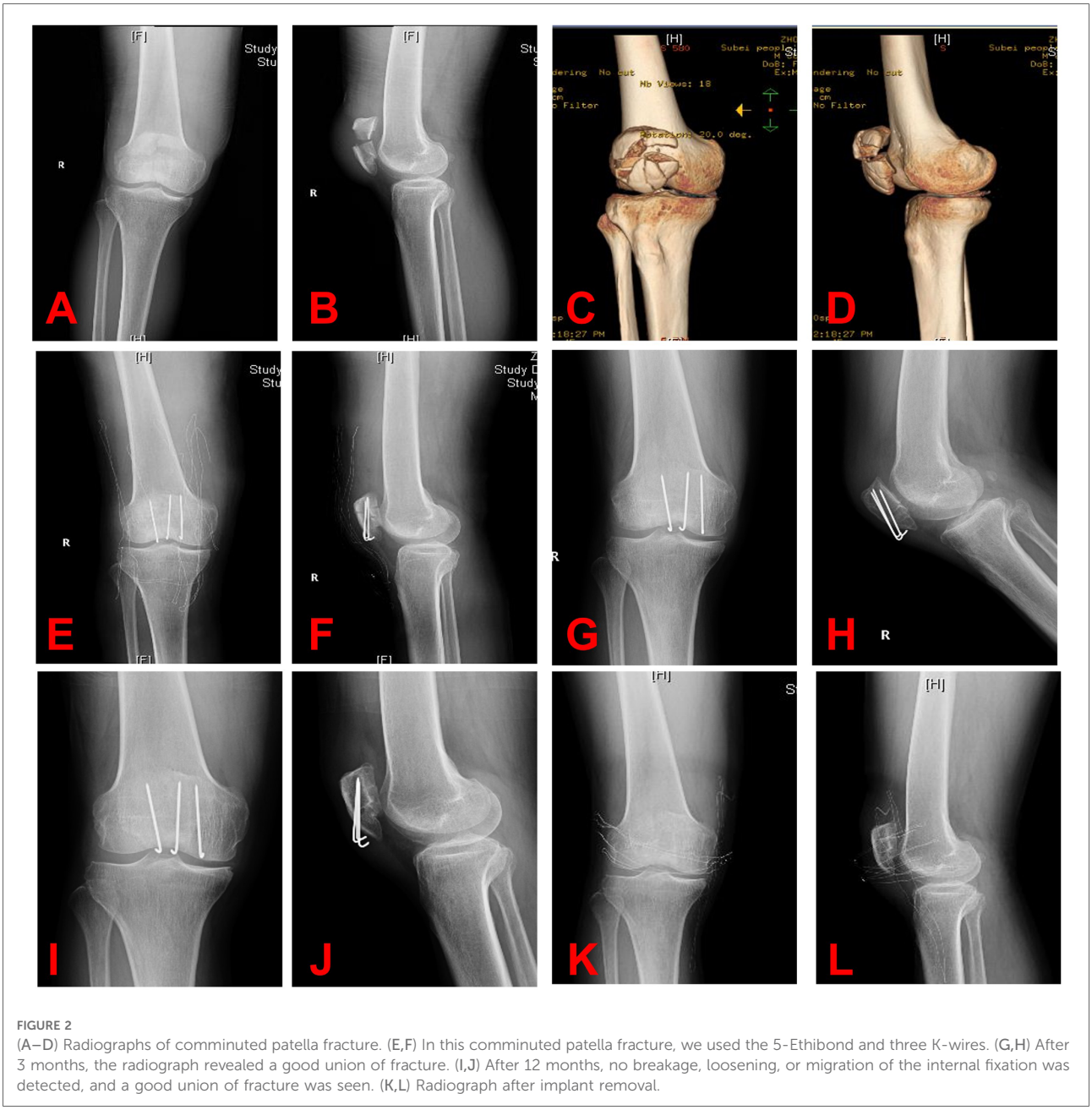

FIGURE 2
(A–D) Radiographs of comminuted patella fracture. (E,F) In this comminuted patella fracture, we used the 5-Ethibond and three K-wires. (G,H) After 3 months, the radiograph revealed a good union of fracture. (I,J) After 12 months, no breakage, loosening, or migration of the internal fixation was detected, and a good union of fracture was seen. (K,L) Radiograph after implant removal.

28.7 ± 1.2 (range 26–30). The clinical outcomes of patients are displayed in Table 2.

Discussion

The main aim of operative treatment is to reduce the anatomic articular surface, achieve stable patella fixation, and facilitate early knee mobilization (8). The TBW technology is the most extensively utilized surgical fixation approach to stabilize patella fractures. Traditional tension band construction uses two K-wires and a metal low-gauge wire tension band. After fracture reduction, the K-wires were introduced into the fracture fragments along the subchondral surface *via* insertion. Then, the stainless steel wire was placed in an eight-like fashion to realize fracture compression. Although stainless steel wires can provide stable fixation, these wires are usually associated with hardware-induced symptoms and other complications (9–11). Meena et al. discovered three probable factors that might break wires: (1) repeated stress on the wires because of a remarkable ROM of knee joints; (2) utilization of thin wires; and (3) utilization of low-quality hardware (12). As a result, it is imperative to explore sutures in the fixation techniques instead of investigating stainless steel wires.

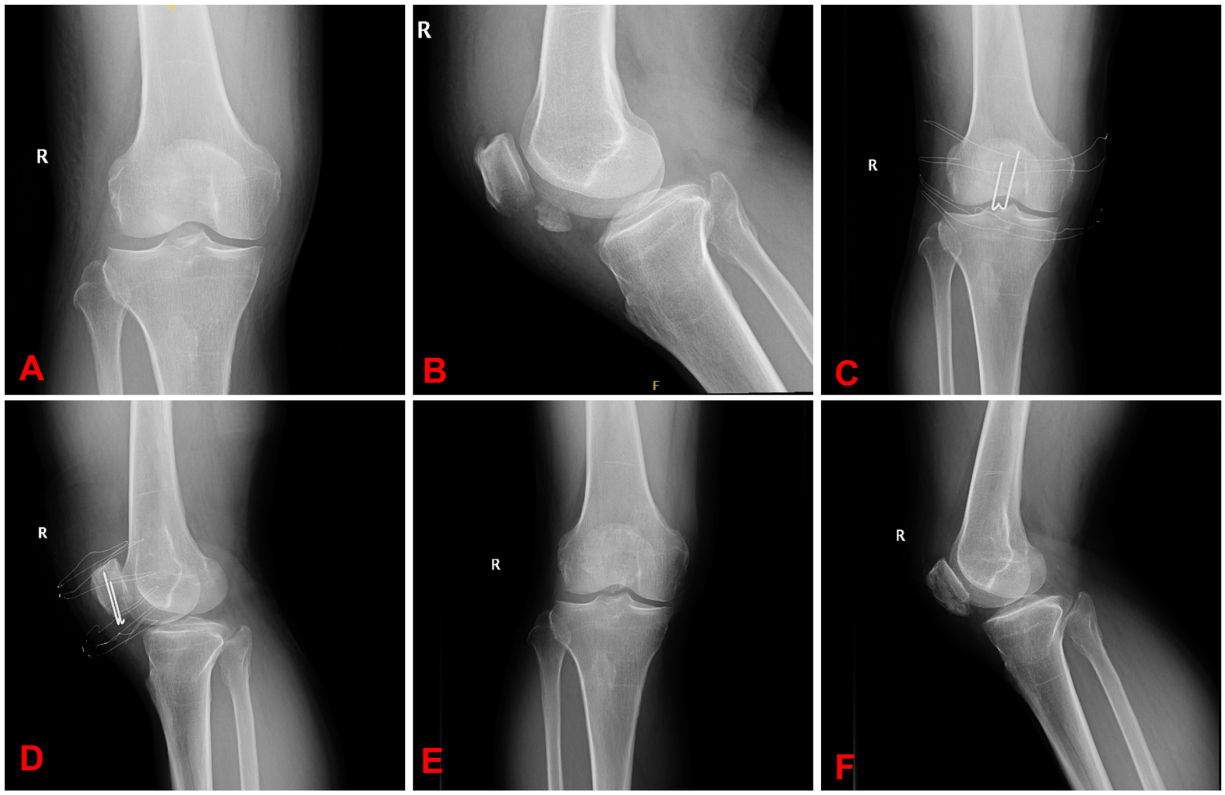

FIGURE 3
(A,B) Radiographs of distal patellar fracture. (C,D) In this distal patella fracture, we used the 5-Ethibond and three K-wires. (E,F) Radiograph after implant removal.

Using sutures can deliver several advantages compared with stainless steel wires (9, 13). Harrell et al. concluded that several loops of Ethibond could replace SSWs, but such a method might not be good for the tension band fixation of fractures (14). Patel et al. compared 5-Ethibond with SSWs in the treatment of patella fractures *via* the adjusted tension band technology and the Lotke technology in a biomechanical study. The result revealed that the 5-Ethibond was able to withstand loads comparable to those of SSWs for patella fractures (15).

In 2001, Gosal et al. compared patellar fracture fixation based on metal wires or 5-Ethibond. They recorded a 38%



FIGURE 4
Final follow-up clinical photographs showing satisfactory extension and flexion.

TABLE 2 The clinical outcomes.

No. of patients	22
Fracture union time (weeks)	10.5 ± 1.9
Final ROM (°)	123.4 ± 14.6
Functional score	28.7 ± 1.2
Complications	No

hardware removal rate due to pain and hardware failures when metallic implants were utilized, and they did not record any symptoms associated with the utilization of heavy sutures. The suture fixation group, nevertheless, displayed a 6% failure rate, which indicated that the substance and approach utilized could induce fixation failures prior to the use of traditional metal implants (16). This is probably the reason why sutures are not usually suggested for treating patellar fractures. We proposed that the failures of suture fixation were due to the lack of metallic parallel longitudinal intraosseous fixation.

Hence, instead of stainless steel wires, we selected K-wires combined with 5-Ethibond to treat patella fractures in this study.

Lee et al. reported that using the adjusted tension band technology with FiberWire and retaining metal parallel implants like K-wires could achieve good results (17). No patient had broken wires, and nonunion with deformity was observed in one individual. Bryant et al. contrasted fracture fixation technologies with the anterior tension band through cannulated screws by virtue of FiberWire and SSWs. The research outcomes presented no remarkable diversity between the FiberWire group and the SSW group (18).

In our study, to obtain a better stability of fracture fixation, the remaining suture limbs were passed through the patella. Then, sutures were tied at the superior pole with the knee in extension. The remaining 5-Ethibond was then passed through the front of the patella to form a certain shape. The most important discovery of our study was that using K-wires combined with 5-Ethibond was a valid, secure, and easy therapeutic method for patella fractures. The average operation time was 56.8 minutes, which indicated that such a surgical approach might not bring additional technological challenges or tissular injuries. Hence, this method is quite prospective and can be utilized extensively. In the present research, patients received recovery training and full weight bearing training as early as the second day after surgery. Clinically and radiologically, the outcomes revealed that such technology could deliver satisfactory results for patients. No patient experienced the loss of reduction and inner fixation failures, and no patient received a remedial operation. Those outcomes coincide with previously completed research that revealed that nonabsorbable sutures could substitute for metallic wires due to their strength. Hence, the 5-Ethibond can offer similar protective effects as steel wires in antagonizing displacements and improving strength in knee extensor loading.

We believe that the adjusted tension band techniques based on 5-Ethibond are simple and can decrease irritation and the quantity of broken wires. Moreover, these methods may be more valid in contrast to the single use of nonabsorbable polyester due to the probability of early recovery and better life quality.

Nevertheless, there are certain flaws in the present research. First, our study was finished retrospectively. Second, the number patients was insufficient. Third, our team did not complete the biomechanical analysis of our construct to evaluate its biomechanical strength. Fourth, during the research, many patients, even asymptomatic patients, wished to remove implants owing to culture-related reasons. Hence, more high-quality, double-blinded randomized clinical trials with larger sample sizes are warranted to substantiate the benefits of fixation using K-wires combined with 5-Ethibond.

Conclusions

Patella fracture patients treated with K-wires combined with 5-Ethibond presented favorable clinical outcomes. This technique may be a valid fixation approach for healing displaced and comminuted patella fractures.

Data availability statement

The original contributions presented in the study are included in the article/Supplementary Material, further inquiries can be directed to the corresponding authors.

Ethics statement

The studies involving human participants were reviewed and approved by Ethics Committee of Northern JiangSu People's Hospital. The patients/participants provided their written informed consent to participate in this study.

Author contributions

YL, JHu, JW, and PC performed the surgery. PZ, JZ, and LY contributed significantly to analysis and manuscript preparation. WZ, JC, JHe, YF, and YZ performed the data analyses. YL and JHu wrote the manuscript. All authors contributed to the article and approved the submitted version.

Conflict of interest

The authors declare that the research was conducted in the absence of any commercial or financial relationships that could be construed as a potential conflict of interest.

Publisher's note

All claims expressed in this article are solely those of the authors and do not necessarily represent those of their affiliated organizations, or those of the publisher, the editors and the reviewers. Any product that may be evaluated in this article, or claim that may be made by its manufacturer, is not guaranteed or endorsed by the publisher.

References

1. Zhan Y, Zhang Y, Xie X, Luo C. Three-dimensional fracture mapping of multi-fragmentary patella fractures (AO/OTA 34C3). *Ann Transl Med*. (2021) 9 (17):1364. doi: 10.21037/atm-21-1814

2. Kumar S, Mittal S, Manhas V, Sharma V. Functional and radiological outcomes following plating for displaced fractures of patella: a pilot study. *Injury*. (2022) 53(2):691–7. doi: 10.1016/j.injury.2021.11.053

3. Carpenter JE, Kasman R, Matthews LS. Fractures of the patella. *Instr Course Lect*. (1994) 43:97–108.

4. Adjal J, Ban I. Patella fractures treated with suture tension band fixation. *J Orthop Surg Res*. (2021) 16(1):179. doi: 10.1186/s13018-021-02309-5

5. Ma XY, Liu B, Zhou DP, Xiang LB. Treatment for transverse patella fractures with minimally invasive techniques (review). *Exp Ther Med*. (2022) 23(3):192. doi: 10.3892/etm.2022.11115

6. Brusalis CM, Gruskay JA, Bornes TD, Langhans MT, Ricci WM. Open reduction and internal fixation of patella fracture with contoured dorsal plating. *J Orthop Trauma*. (2021) 35(Suppl 2):S34–5. doi: 10.1097/BOT.0000000000002171

7. Hughes SC, Stott PM, Hearnden AJ, Ripley LG. A new and effective tension-band braided polyester suture technique for transverse patellar fracture fixation. *Injury*. (2007) 38(2):212–22. doi: 10.1016/j.injury.2006.07.013

8. Yao SH, Lin SF, Lin CH, Chen CH. Loop anchor tension band technique for patella fractures lowers the rate of Kirschner migration. *Injury*. (2021) 52 (6):1556–62. doi: 10.1016/j.injury.2020.11.057

9. Jirangkul P, Kosiyatrakul A. Abstaining from symptomatic implants of modified tension band wiring by nonabsorbable suture fixation for transverse patella fractures. *J Orthop Surg Res*. (2021) 16(1):367. doi: 10.1186/s13018-021-02494-3

10. Huang PH, Hsu CH, Hsu SL, Liu HC. Treatment of displaced fractures of the patella: tension band wiring technique with the one-end or both-ends K-wire bending fixation method. *J Orthop Surg (Hong Kong)*. (2021) 29 (1):2309499020988179. doi: 10.1177/2309499020988179

11. Yao C, Sun J, Wu J, Zhou Z, Liu F, Tao R, et al. Clinical outcomes of Ti-Ni shape-memory patella concentrator combined with cannulated compression screws in the treatment of C2 and C3 patella fracture: a retrospective study of 54 cases. *BMC Musculoskelet Disord*. (2020) 21(1):506. doi: 10.1186/s12891-020-03536-3

12. Meena S, Nag HL, Kumar S, Barwar N, Mittal S, Singla A. Delayed migration of K-wire into popliteal fossa used for tension band wiring of patellar fracture. *Chin J Traumatol*. (2013) 16(3):186–8. doi: 10.3760/cma.j.issn.1008-1275.2013.03.012

13. Chatakondu SC, Abhaykumar S, Elliott DS. The use of non-absorbable suture in the fixation of patellar fractures: a preliminary report. *Injury*. (1998) 29(1):23–7. doi: 10.1016/S0020-1383(97)00114-9

14. Harrell RM, Tong J, Weinhold PS, Dahners LE. Comparison of the mechanical properties of different tension band materials and suture techniques. *J Orthop Trauma*. (2003) 17(2):119–22. doi: 10.1097/00005131-200302000-00007

15. Patel VR, Parks BG, Wang Y, Ebert FR, Jinnah RH. Fixation of patella fractures with braided polyester suture: a biomechanical study. *Injury*. (2000) 31 (1):1–6. doi: 10.1016/S0020-1383(99)00190-4

16. Gosal HS, Singh P, Field RE. Clinical experience of patellar fracture fixation using metal wire or non-absorbable polyester–a study of 37 cases. *Injury*. (2001) 32(2):129–35. doi: 10.1016/S0020-1383(00)00170-4

17. Lee BJ, Chon J, Yoon JY, Jung D. Modified tension band wiring using FiberWire for patellar fractures. *Clin Orthop Surg*. (2019) 11(2):244–8. doi: 10.4055/cios.2019.11.2.244

18. Bryant TL, Anderson CL, Stevens CG, Conrad BP, Vincent HK, Sadasivan KK. Comparison of cannulated screws with FiberWire or stainless steel wire for patella fracture fixation: a pilot study. *J Orthop*. (2015) 12(2):92–6. doi: 10.1016/j.jor.2014.04.011

frontiers | Frontiers in Surgery

TYPE Review
PUBLISHED 06 January 2023
DOI 10.3389/fsurg.2022.1063170

Check for updates

OPEN ACCESS

EDITED BY
Paphon Sa-ngasoongsong,
Mahidol University, Thailand

REVIEWED BY
Junlin Zhou,
Capital Medical University, China
Fei Wang,
Third Hospital of Hebei Medical University, China

*CORRESPONDENCE
Ming Li
liming891215@163.com
Jianheng Liu
jianhengliu@126.com

†These authors share first authorship

SPECIALTY SECTION
This article was submitted to Orthopedic Surgery, a section of the journal Frontiers in Surgery

RECEIVED 06 October 2022
ACCEPTED 07 November 2022
PUBLISHED 06 January 2023

CITATION
Gao J, Liu X, Wu X, Li X, Liu J and Li M (2023) A brief review and clinical evidences of teriparatide therapy for atypical femoral fractures associated with long-term bisphosphonate treatment.
Front. Surg. 9:1063170.
doi: 10.3389/fsurg.2022.1063170

COPYRIGHT
© 2023 Gao, Liu, Wu, Li, Liu and Li. This is an open-access article distributed under the terms of the Creative Commons Attribution License (CC BY). The use, distribution or reproduction in other forums is permitted, provided the original author(s) and the copyright owner(s) are credited and that the original publication in this journal is cited, in accordance with accepted academic practice. No use, distribution or reproduction is permitted which does not comply with these terms.

A brief review and clinical evidences of teriparatide therapy for atypical femoral fractures associated with long-term bisphosphonate treatment

Jianpeng Gao[1,2†], Xiao Liu[1,2†], Xiaoyong Wu[1], Xiaoya Li[1], Jianheng Liu[1,2*] and Ming Li[1,2*]

[1]Department of Orthopaedics, Chinese PLA General Hospital, Beijing, China, [2]National Clinical Research Center for Orthopedics, Sports Medicine & Rehabilitation, Beijing, China

The risk of bisphosphonate (BP)-associated atypical femur fracture (AFF) has markedly increased over recent decades due to suppression of bone turnover, accumulation of structural micro-damage and reduction of bone remodeling consequent to long-term BP treatment. These medications further delay bone union and result in challenging clinical management. Teriparatide (TPTD), a synthetic human parathyroid hormone, exhibits unique anabolic effects and can increase bone remodeling and improve bone microarchitecture, further promoting fracture healing and reducing the rate of bone non-union. In this study, we briefly define AFF as well as the effects of BPs on AFFs, detailed the role of TPTD in AFF management and the latest clinical therapeutic findings. We have confirmed that TPTD positively promotes the healing of AFFs by reducing the time to bone union and likelihood of non-union. Thus, teriparatide therapy could be considered as an alternative treatment for AFFs, however, further research is required for the establishment of effective clinical guidelines of TPTD use in the management of AFF.

KEYWORDS
teriparatide, atypical femoral fractures, bisphosphonate, subtrochanteric fracture, therapy

Background

As the mainstay of osteoporosis treatment, bisphosphonates (BPs) can significantly decrease the risk of hip and vertebral fractures in osteoporosis in that these medications effectively increase bone mass and enhance bone strength (1, 2). However, an increasing number of studies have suggested that AFFs are closely associated with BP therapy due to consequent suppression of bone turnover, reduced remodeling and ultimately impaired healing capacity in the setting of long-term treatment (>5 years) (3–6). Despite a low incidence of AFFs (3.0–9.8 per 100,000 person-years) (7), such fractures are often resistant to therapy, result in poor bone union and high implant failure rates due to hardened bone and complete medullary canal obliteration (8–10). The mean healing time of AFFs postoperatively was 7.3 months (2–31 months) reported in literature;

nearly a tenth of patients required revision surgery due to bone non-union or implant failure and approximately half of patients conservatively managed for incomplete fractures were eventually treated surgically (11). Furthermore, younger patients (aged <65 years) have tended to be more affected as compared to the older population (aged>65 years) (12). AFFs thus not only represent a serious health issue and enormous economic burden for patients, but also present a challenging clinical situation to manage for orthopedic surgeons.

Although the guidelines on the treatment of AFF have not been established, clinical trials have suggested that optimal AFF treatment includes surgical (intramedullary nailing and plate) and medical therapy. Medical management of AFF was summarized in the original task force report (American Society for Bone and Mineral Research, ASBMR) in 2010 and updated in the second task force report in 2014 (13, 14). In addition to cessation of BPs and supplementation of adequate calcium and vitamin D, a parathyroid hormone analogue termed teriparatide (TPTD) is likely to promote fracture healing. TPTD, the only US FDA-approved anabolic bone agent, has been reported by numerous studies to stimulate bone formation and remodeling, thus accelerating typical fracture healing (15, 16). The application of TPTD in the treatment of AFFs has also been reported. Several descriptive analyses have revealed TPTD could improve osteal micro-architecture and reduce bone non-union, exerting mechanisms of action opposite to BPs (17–19). Although a number of animal and clinical studies have reported beneficial effects of TPTD on AFFs associated with long-term BP therapy (20–23), lacking of integrated, effective treatment guidelines for the management of BP-associated AFF remains an orthopedic dilemma. Here, we briefly define AFF as well as detail the pathogenic mechanisms of AFFs in the setting of long-term BP therapy, the role of TPTD in AFF management and the latest therapeutic advances in order to provide more effective guidelines for successful clinical AFF management.

Methods

A search of PUBMED, EMBASE, and the Cochrane Central Register of Controlled Trials databases was conducted from 2001 to 2021. The search strategy was developed using MeSH terms and keywords associated with terms relevant to "Atypical femur fracture", "Atypical femur fractures", "femur fracture", "femur fractures", "Subtrochanteric fractures", "Subtrochanteric fracture", "Bisphosphonate", "Bisphosphonates", "BPS", "BP", "Teriparatide", "Teriparatides", "TPTD" and "TPTDS" in various combinations. A total of 704 articles were searched and the results were screened using the following inclusion and exclusion criteria. Inclusion criteria were available for all articles. Exclusion criteria included: (1) Duplicate results were excluded. (2) Editorials, conference abstract and letters were excluded. Two authors independently extracted information from the articles, which they read and reviewed the titles and abstracts and then the full text of the retrieved articles. 82 articles were deemed appropriate for our study. In addition, These included 3 articles from a prospective study, 7 articles from retrospective case series, and 20 case reports. These articles were then analyzed in detail of clinical outcome of TPTD therapy for AFFs (**Figure 1**).

Results

Definition of AFF

Since the publication of the article suggesting an association between BPs and AFFs in 2005 (24), a growing number of case reports and series have revealed a high correlation between BP therapy and AFFs. Fractures were reported to be primarily located along the femoral diaphysis from just distal to the lesser trochanter to just proximal to the supracondylar flare (**Figure 2**) (13). These fractures were characterized as spontaneous and resulting from low-energy injury. They were usually not comminuted and fractured in the subtrochanteric area, or the proximal one-third of the femoral shaft. In order to clearly define AFF, the American Society for Bone and Mineral Research (ASBMR) established 5 major and 7 minor features of AFFs in the original 2010 task force report. All major features are required to satisfy the case definition of an AFF; none of the minor features are required, but occasionally some have been associated with such fractures. The 5 major features included: (1) fracture location anywhere along the femur from just distal to the lesser trochanter to just proximal to the supracondylar flare; (2) lack of association with trauma, or association with minimal trauma, as in a fall from a standing height or less; (3) transverse or short oblique fracture configuration; (4) non-comminuted nature; (5) fracture extension through both cortices and association with a medial spike; incomplete fractures involve only the lateral cortex. The 7 minor features included: (1) Localized periosteal reaction of the lateral cortex, often referred to in literature as beaking or flaring; (2) generalized cortical thickness increase of the diaphysis; (3) presence of prodromal symptoms such as dull or aching pain in the groin or thigh; (4) bilateral fractures and symptoms; (5) delayed healing; (6) comorbid conditions (e.g., vitamin D deficiency, RA, hypophosphatasia); (7) use of pharmaceutical agents (e.g., BPs, glucocorticoids, proton pump inhibitors). In order to standardize and improve diagnostic criteria, the definition of AFFs was revised in the second 2014 task force report. The major alterations were the establishment of clearly defined transverse or short oblique AFFs configurations, inclusion of minimal comminuted fractures, and the changing of the periosteal or endosteal

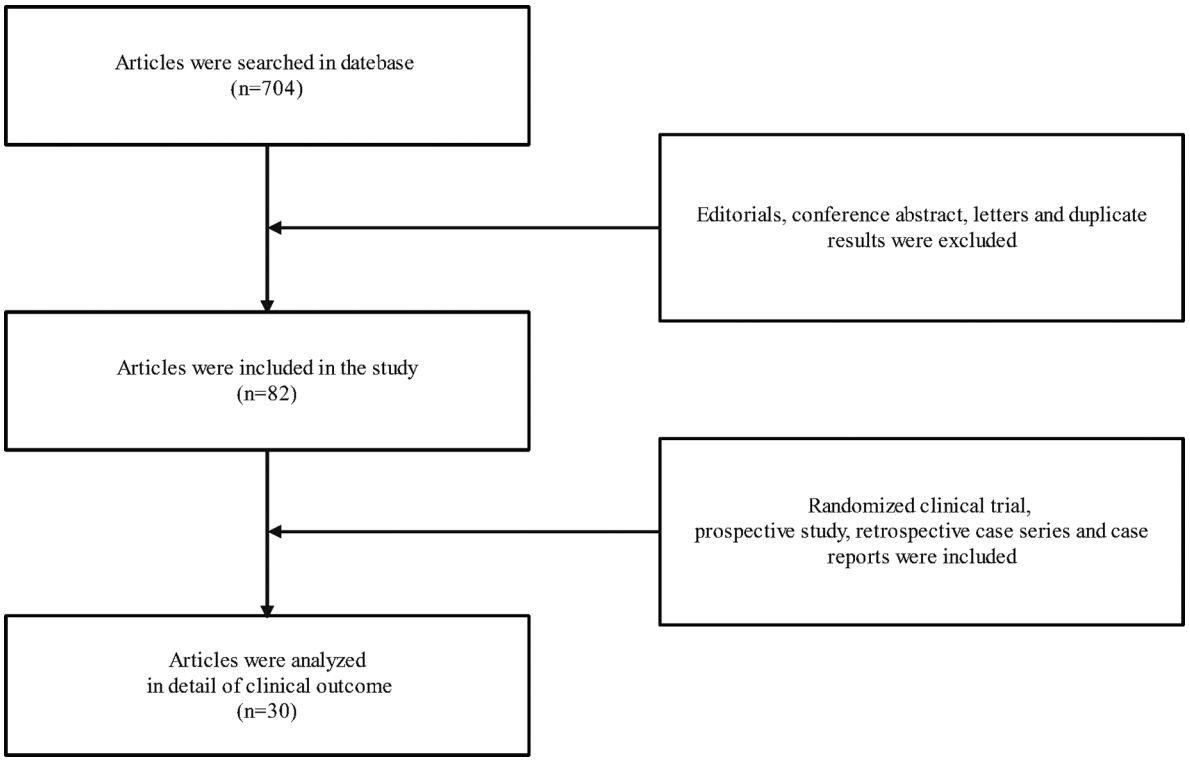

FIGURE 1
The flow chart of Information retrieval.

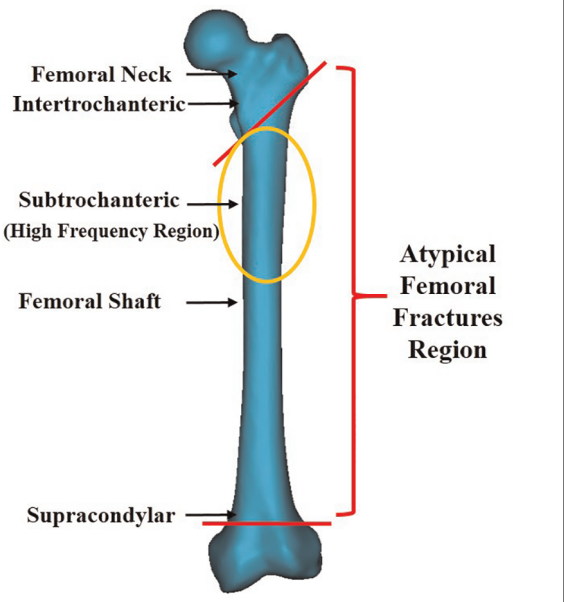

FIGURE 2
The region of atypical femur fractures, yellow circles denote areas of high incidence.

lateral cortex stress reaction at the fracture site from minor to major categories(13, 14). Based on it, we classified AFFs into 5 types (**Figure 3**) according to their characteristics, providing further clarification.

BP influences on AFFs

BP, consisting of P-C-P bonds, not only imbues strong affinity for hydroxyapatite (HAP) binding and in turn prevents both HAP crystal growth and dissolution, but also directly or indirectly inhibits osteoclast-mediated resorption and remodeling of bone (25–28). Via these pathways, BP can prevent bone loss, reduce bone turnover and increase overall mineralization (29), and widely used in the management of osteoprosis, pagets disease of the bone and osteocarcinomas. Throughout treatment, BPs are incorporated into newly formed bone and persist there for long time. In addition, a continuous decrease in chronic bone turnover likely leads to greater bone fragility (30). The research had proved that the risk of atypical femur fracture increased with longer duration

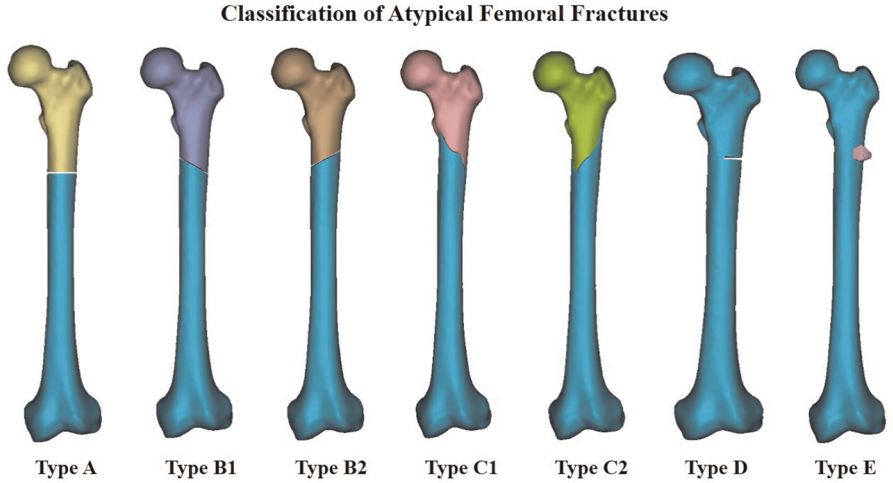

FIGURE 3
Classification of atypical femoral fractures; Type A implies transverse fracture, Type B implies short oblique fracture (which itself has2 subtypes), Type C implies spiral fracture associated with a medial spike (which itself has 2 subtypes), Type D implies incomplete fractures involving only the lateral cortex, Type E implies localized periosteal reaction in the lateral cortex.

of BP use and rapidly decreased after BP discontinuation. In addition, Asians had a higher risk than Whites.

Table 1 details how BP treatment predisposes to AFFs development. Due to the high affinity of BP to HAP binding and long-term effects on bone resorption, a marked decrease in bone remodeling delays prompt micro-fracture healing (31). As micro-fractures accumulate, a greater stress reaction results. This is the reason x-ray imaging reveals these fractures to exhibit focal lateral cortical thickening, or transverse, short oblique fracture lines as the stress reaction develops. Moreover, BPs decrease both crystal formation and dissolution, thereby narrowing crystal distribution without affecting mean crystal size and increasing overall mineralization (32). As bone turnover is reduced, BPs prevent maturation of collagen and increase levels of advanced glycation end products (33). Due to alteration in the properties of the HAP and bone matrix, bone tissue homogenizes and is less able to reduce local stress. This enhances energy distribution that makes the bone more brittle and predisposes to fracture (34). Studies have confirmed BP to directly suppress vasculogenesis and retard the remodeling of calcified cartilage calluses into mature bone during fracture healing (35, 36). AFFs healing is thus typically prolonged and may even result in bone non-union. Appropriate treatment strategies are essential for successful AFFs management, and TPTD, with its unique bone-forming effects, is likely a good choice.

TABLE 1 Influences of BPs on AFF and the role of TPTD in AFF management.

Atypical Femoral Fractures: Likely Pathogenesis and Therapeutic Strategy
BPs predispose to AFF
• Chronically decrease bone remodeling
• Results in accumulation of minor damage and fractures
• Alter the distribution and size of hydroxyapatite crystals and result in excessive mineralization
• Inhibit collagen maturation and increase glycosylated product content
• Reduce bone heterogeneity
• Directly inhibit angiogenesis and delay callus calcification
The Role of Teriparatide in AFF
• Promotes remobilization and redistribution of BPs within bone tissue
• Decrease BP content within calluses during fracture healing
• Replaces fully mineralized bone matrix with newly synthesized and less completely mineralized matrix
• Decreases glycated collagen production and increases expression of new type II and X collagen
• Increases bone heterogeneity
• Anabolism promotes bone formation and decreases adipogenesis in cancellous bone

The role of teriparatide in AFFs

TPTD has mainly been used to treat osteoporosis in postmenopausal women and older men since 2002 after its approval by the FDA for this purpose (37). It is manufactured using a genetically modified strain of E. coli and consists of a 1–34 N-terminal amino acid sequence of the intact human parathyroid hormone while maintaining whole parathyroid hormone (PTH) biological activities (38). The current recommended dose is 20 μg once daily by subcutaneous injection in a sustained treatment cycle for no greater than 2 years. Numerous studies have reported TPTD to directly

activate osteoblast *via* binding to their PTH receptors, thus increasing osteoblast genesis and reducing osteoblast apoptosis (39). TPTD increases production of growth factors and cytokines, such as IGF-1 and TGF-β, resulting in pre-osteoblast recruitment from marrow stromal cells (40, 41). TPTD also positively affects cell-signaling pathways, such as IHH, Wnt/β-catenin and AC/cAMP-PKA and promotes osteoblast proliferation and differentiation (42–44). TPTD was furthermore confirmed to reduce sclerostin, an inhibitor of bone formation in both rodents and humans (45, 46). TPTD thus possesses significant advantages in the promotion of bone formation and is considered a good choice for the treatment of fractures (47, 48).

Fractures are understood to undergo primary and secondary healing. Primary healing or direct bone healing is characterized by fractured bone cortex ends directly uniting and results in restoration of anatomy and rigid internal fixation. Secondary healing, or indirect bone healing, is similar to embryonic bone formation and includes intramembranous and endochondral ossification *via* callus formation. Fractures typically heal *via* secondary healing which the processes involved are indeed complex (49). A better physiological environment decreases chances of delayed union or non-union occurring. In the setting of osteoporosis, poor osteoblast function and inappropriate callus maturity, coupled with the effects of BPs, result in frequent complications of bone injury. However, TPTD, exerting anabolic effects as opposed to BP (**Table 1**) has been confirmed to significantly redistribute BPs within fracture sites in some studies, even reduce BP content with prolonged use of this drug (50). Moreover, because of anabolism leading to increased bone turnover and remodeling, TPTD not only replaces fully mineralized bone matrix with newly synthesized and less completely mineralized matrix but also decreases production of glycated collagen while increasing expression of new type II and X collagen (51, 52). Such alterations in mineralized bone and matrix result in preferable osseous heterogeneity. Furthermore, fracture callus size, density and volume become significantly increased (51). Interestingly, intermittent TPTD administration was found to promote osteoblast genesis and decrease adipogenesis at the site of cancellous bone, resulting in better bone union (53). Dobnig et al. (54) found that changes in iliac crest microdamage in previously treatment-naive patients managed with TPTD, or in patients switched from alendronate to TPTD, entailed decreased crack density (Cr.Dn), crack surface density (Cr.S.Dn) and crack length (Cr.Le) when compared to patients previously treated with alendronate after 24 months of TPTD administration. These findings demonstrate that TPTD reduces accumulation of bone microdamage in postmenopausal women previously treated with alendronate. Similarly, Paul et al. (21) studied 15 patients referred to The Colorado Center for Bone Research (CCBR) after they suffered BP-associated AFF using quantitative iliac crest histomorphometry both before and after 12 months of TPTD (20 μg SQ/day). Results revealed that discontinuation of BPs and administration of TPTD was associated with improvement in bone turnover and an increase in all 3 dynamic histomorphometric parameters; including bone formation, mineralized surface, and mineral apposition. Although a number of studies have verified the beneficial effects of TPTD on AFF healing, the mechanism of TPTD action in the setting of AFFs remains unknown. Based on prior research, TPTD has unique potential in the treatment of AFFs. Also a large number of clinical evidence has additionally found that TPTD therapy can be considered as an alternative treatment for AFF.

Clinical outcome of TPTD therapy for AFFs

The management of BP-associated AFFs varies due to AFF type (i.e., stress reaction; stress fracture; incomplete or complete subtrochanteric or femoral shaft fracture). On account of high rates of poor union and surgical difficulties, neither conservative nor operative management are capable of achieving good treatment outcomes. TPTD supplementation, however, reducing the time to bone union and likelihood of non-union, positively affects AFF healing (55, 56). Several case reports as well as retrospective (**Table 2**) and prospective studies (**Table 3**) have demonstrated the efficacy of TPTD in the treatment of AFFs (17–19, 21, 57–82).

Gomberg et al. (68) initially reported TPTD use in AFF management. The patient was a postmenopausal woman treated with a BP for 13 years. Obvious reduction of edema, pain and appearance of faint cortical bridging at fracture sites after 6 months of continuous TPTD treatment was noted. Then, a number of case reports or series subsequently found TPTD use for AFF treatments could reduce periosteal reaction and promote microdamage repair in the setting of conservative or surgical treatment. In addition to pain reduction and minimization of dysfunction, alkaline phosphatase levels in AFF patients who suffered hypophosphatasia were effectively restored with TPTD administration (74). Treatment of TPTD is usually started for diagnosis or after surgery. The dose is usually 20 μg/d and the treatment cycle ranges from 3 to 24 months. Calcium and vitamin D were often used in combination. It is worth emphasizing that TPTD combined with stable fixation results in satisfactory AFF outcomes in most cases. Almost all patients had clinical outcomes of bone healing, and the healing time was between 1 and 6 months.

Saleh et al. (57) first retrospectively investigated 10 patients that suffered a total of 14 incomplete AFFs. 5 of 14 fractures did not manifest with a radiolucent fracture line and were healed conservatively with TPTD. Radiolucent fracture lines across

TABLE 2 Summary of the retrospective studies of TPTD therapy for AFF.

First author/ reference/date/ country	Patients (n)	TPTD therapy (n)	Age/ mean age	Gender	BP duration/ mean time	Fractures (n)	Location	Initiation of TPTD	Treatment dose	Duration of treatment	surgery (n)	Union rate (%)	Time to union/ mean time
Anas Saleh, 2012, USA (57)	10	9	50–85 years/67 years	F	4–17 years/10 years	IF	ST (4)/FD (11)	NS	NS	24 months	NS	50	3 months
Paul D. Miller, 2015, USA (21)	15	13	57–87 years/67 years	F	6–11 years/7 years	CF	B, FD (n = 6)/l or R FD (n = 9)	After the first bone biopsy	20 μg/d	12 months	IN	NS	NS
Naohisa Miyakoshi, 2015, Japan (58)	34	NS	66–88 years	F	1–11.6 years/5 years	NS	NS	NA	20 μg/d, 56.5 μg/w	NS	IN (33)/P (4)	93.7	2–7 months/ 5.4 months
Basmah K. Alwahhabi, 2017, Saudi Arabia (59)	34	23	46–89 years	F (n = 33)/ M (n = 1)	4 years and more	NS	FD (n = 16)/ TD (n = 4)/ PF (n = 1)	NS	20 μg/d	18–24 months (n = 16)	IN/P	52.4	NS
Wen-Ling Yeh, 2017, Taiwan (60)	13	NS	58–79 years/ 70.2 years	F	2.5–6 years	CF	ST (10)/FD (6)	Postoperation immediately	20 μg/d	NS	IN	75%	2.3–8.2 months/4.4 months
H. Tsuchie, 2018, Japan (61)	43	43	57–88 years/ 78.8 years	F (42)/M (1)	1–12 years/5.2 years	CF (n = 30)/ IF (15)	ST (n = 3)/ FD 42	NS	20 μg/d (n = 32), 56.5 μg/w (n = 13)	NS	IN (35)/P (7)	100%	6.1 ± 4.1 months (daily)/ 10.1 ± 4.2 months (weekly)
HiroyukiTsuchie, 2021, Japan (62)	113	99	79.2 years	F	NS	IF (1)/CF (12)	NS	Postoperation immediately (n = 7)/6 months (n = 6)	20 μg/d	12 months	NS	NS	NS

AFF, atypical femur fracture; AR, antiresorptive; NS, not stated; TPTD, teriparatide; F, female; M, male; ST, subtrochanteric; FD, femoral diaphysis; PF, pelvic fracture; CF, complete fracture; IF, incomplete fracture; IN, intramedullary nail; P, plate; IM, immediately; B, bilateral; R, right; F, left.

10.3389/fsurg.2022.1063170

10.3389/fsurg.2022.1063170

TABLE 3 Summary of Prospective Studies of TPTD Therapy for AFF

First author/ reference/date/ country	Patients (n)	TPTD therapy (n)	Age/ mean age	Gender	BP duration/ mean time	Fractures (n)	Location	Initiation of TPTD	Treatment dose	Duration of treatment	surgery (n)	Union rate (%)	Time to union/ mean time
Cherie Ying Chiang, 2013, Australia (63)	14	5	76 years	F (13)/M (1)	4–10 years	IF (8)/CF (6)	NS	NS	20 μg/d	6 months	NS	NS	NS
Nelson B Watts, 2017, USA (64)	14	14	52–83 years/68.3 years	F	3–14.5 years/ 8.8 years	IF (5)/CF (9)	NS	NS	NS	24 months	NS	64.3	NS
S. L. Greenspan, 2017, USA (65)	13	13	74.2 years	F	NS	IF (1)/CF (12)	NS	Postoperation immediately (n = 7)/6 months (n = 6)	20 μg/d	12 months	NS	NS	NS

AFF, atypical femur fracture; AR, antiresorptive; NS, not stated; TPTD, teriparatide; F, female; M, male; SF, subtrochanteric; FD, femoral diaphysis; PF, pelvic fracture; CF, complete fracture; IF, incomplete fracture; IN, intramedullary nail; P, plate; IM, immediately; B, bilateral; R, right; F, left.

thickened cortices were noted in 9 fractures. Two of these fractures responded to 3 months of conservative therapy with TPTD and were found to have completely healed on radiography. Six of these fractures chose surgical prophylaxis after 3 months of conservative management, whereas 1 patient underwent surgical prophylaxis without a trial of conservative management. Miyakoshi et al. (58) retrospectively reviewed the medical records of 45 consecutive AFFs in 34 Japanese patients who had been treated with oral BPs for osteoporosis prior to their AFFs and followed for a period of 12 months. A total of 37 complete or incomplete AFFs were treated surgically and 8 incomplete AFFs were treated conservatively. Patients were non-randomly divided into non-TPTD ($n = 24$) and TPTD ($n = 21$) groups. Results revealed the healing time of all surgically-treated AFFs to have been significantly shorter in the TPTD group and the frequency of delayed healing or non-union to have been significantly lower in the TPTD group as well. Although similar findings were noted in surgically treated complete AFFs, sub-analyses of incomplete AFFs treated conservatively revealed no significant differences between groups. Hence, TPTD was found to markedly accelerate fracture healing postoperatively that would otherwise have been delayed. Chiang et al.'s (63) prospective study involved 14 patients that consecutively presented with AFFs over a course of 2 years. Of these, 5 were offered TPTD therapy while the remaining 9 were not due to contraindications. The 5 patients who had undergone TPTD therapy were found to have a 2–3 folds increase in bone remodeling markers and more rapid fracture healing. Of the 9 patients managed conservatively or surgically, 7 suffered poor fracture healing with ongoing pain, 1 sustained a contralateral atypical fracture and 1 experienced fracture union only after 1 year. Similar results were reported in Yeh's (60) study, 13 patients who suffered AFFs were all treated with intramedullary fixation, 6 patients underwent TPTD treatment initially for at least 6 months while others did not. The mean time to bone union was 4.4 months in the TPTD treatment group and 6.2 months in the non-TPTD treatment group. The means of the modified Harris Hip Score and Numerical Rating Scale were significantly better in the TPTD group at 6 months postoperatively. TPTD was thus confirmed to greatly assist in fracture healing, hip function recovery, and pain relief. A randomized pilot clinical trial confirmed immediate therapy with TPTD to be superior for fracture healing in the setting of AFFs compared to a 6-month delay in TPTD therapy and effectively prevented a decrease in bone density (65).

Although TPTD was found to initially promote rapid healing of AFF, the development of new, contralateral AFFs highlights that TPTD does not indefinitely protect against future AFF occurrence. TPTD may thus be limited in its ability to reverse skeletal side effects of long term BP therapy. Anti-resorptive therapies have also been implicated in the

development of contralateral AFFs in the setting of adjunctive strontium ranelate therapy (77). Moreover, Watts et al. (64) conducted a prospective and open-label study involving 14 AFF patients who were previously treated with BPs, examining changes in bone mineral density, trabecular bone score, bone turnover markers, and fracture healing, as well as quantitative histomorphometry, after a 24-month TPTD treatment period. At 24 months, 6 patients were found to have healed fractures, 3 to have partially healed fractures, 2 with unchanged fractures and 1 with nonunion. However, in a patient who suffered 2 successive fractures, the fracture that occurred prior to TPTD treatment was reported as healed while the fracture that occurred during TPTD treatment was found to be only partially healed. No significant effects of TPTD on hip bone mineral density, mineralizing surface to bone surface ratio, or trabecular bone score were noted. In addition, no consistent effect on fracture healing was noted, implying that sole use of TPTD is likely not reliable for rapid healing of AFFs. TPTD should, however, be understood as exerting beneficial effects on AFF healing. A greater amount of high level of evidence, in particular randomized controlled trials, should be performed to further confirm the efficacy of TPTD in AFF management.

Discussion

Long-term application of BPs, affecting bone mass and resulting in AFF, made the treatment of AFFs difficult. Due to its unique biological effects, TPTD has been demonstrated in basic experiments to reverse the effect of BP on bone and promote the healing of AFFs, and has achieved good results in clinical application. Based on the articles we reviewed, it is not difficult to find that TPTD has certain advantages in promoting the healing of complete or incomplete AFFs, especially in combination with strong internal fixation and medical supplement with calcium, cholecalciferol and vitamin D.

Based on the existing clinical evidences, especially the prospective and RCT studies, it provides certain clinical basis for the TPTD treatment of AFFs. Hence, we have developed a preliminary diagnosis and treatment process based on the latest clinical findings to assist AFF treatment. Firstly, regular imaging examinations (MRI is recommended) are recommended for patients who have been using BPs for a long time (especially those who have been using BPs for more than 5 years), regardless of whether they have symptoms of thigh pain, for the purpose of early detection and treatment. Secondly, BPs therapy should be stopped immediately after AFF diagnosis, and conservative or surgical treatment should be given according to fracture type. Thirdly, it is recommended to apply TPTD (20 μg/day, 12–24 months) immediately after diagnosis for patients receiving conservative treatment and patients receiving surgery, and calcium, cholecalciferol and vitamin D should be combined. Fourthly, surgical intervention is recommended as soon as possible for patients with ineffective conservative treatment, and preventive surgical treatment is also recommended for patients with initial symptoms or incomplete fractures. Fifth, regular monitoring of blood calcium after the application of TPTD is recommended, and the treatment cycle depends on the time of fracture healing condition, and it is recommended that the application should not exceed 24 months. Replacement of other drugs such as Denosumab is recommended after the cessation of TPTD treatment. We hope that AFFs can be easily treated through the above treatment process.

But so far, even though AFF has been studied a lot, it still has some shortcomings. In general, the mechanism by which TPTD promotes AFF healing is unclear. In addition, we found that most of the current clinical studies were case reports and retrospective studies with low level of evidence. The specific time of TPTD initiation, dose and cycle of application, and the difference between conservative and surgical treatment were not clear. Therefore, more high-level clinical studies are needed to confirm the efficacy of TPTD in treating AFFs.

Conclusion

BP-associated AFFs present numerous difficulties to both clinicians and patients. An effective treatment is thus urgently needed. Basic and clinical research has revealed TPTD to exert a unique anabolic effect in AFF healing and underscores its importance as an alternative treatment for this condition. Further research, however, is required for the establishment of effective clinical guidelines of TPTD use in the management of AFFs.

Author contributions

JG initial concept, data collection and analysis, initial draft and edited the paper. XL data collection and analysis, initial draft and edited the paper. XW participated in data collection and analysis. XL participated in data collection and analysis. JL helped to draft the manuscript, reviewed and edited the paper. ML helped to draft the manuscript, reviewed and edited the paper. All authors contributed to the article and approved the submitted version.

Funding

This work was supported by grants from the PLA Major Project (AWS17J004), the National Natural Science Foundation of China (82002317), Sub-topic of Key Basic Research Project of Army Basic Strengthening Program

(2020-JCJQ-ZD-264-*) and Military Training Injury Prevention and Treatment Project (20XLS30).

Conflict of interest

The authors declare that the research was conducted in the absence of any commercial or financial relationships that could be construed as a potential conflict of interest.

Publisher's note

All claims expressed in this article are solely those of the authors and do not necessarily represent those of their affiliated organizations, or those of the publisher, the editors and the reviewers. Any product that may be evaluated in this article, or claim that may be made by its manufacturer, is not guaranteed or endorsed by the publisher.

References

1. Black DM, Delmas PD, Eastell R, Reid IR, Boonen S, Cauley JA, et al. Once-yearly zoledronic acid for treatment of postmenopausal osteoporosis. *N Engl J Med*. (2007) 356:1809–22. doi: 10.1056/NEJMoa067312

2. Reinsdorf S, Habermann B, Hochmuth K, Kurth AA. Bisphosphonates in osteoporosis therapy. Standards and perspectives. *Orthopade*. (2007) 36:110–7. doi: 10.1007/s00132-006-1035-6

3. Capeci CM, Tejwani NC. Bilateral low-energy simultaneous or sequential femoral fractures in patients on long-term alendronate therapy. *J Bone Joint Surg Am*. (2009) 91:2556–61. doi: 10.2106/jbjs.h.01774

4. Park-Wyllie LY, Mamdani MM, Juurlink DN, Hawker GA, Gunraj N, Austin PC, et al. Bisphosphonate use and the risk of subtrochanteric or femoral shaft fractures in older women. *JAMA*. (2011) 305:783–9. doi: 10.1001/jama.2011.190

5. Geada N, Mafra I, Barroso R, Franco J. Atypical femoral fractures and bisphosphonates treatment: is it a risk factor. *Acta Med Port*. (2014) 27:704–9. doi: 10.20344/amp.5118

6. Schilcher J, Koeppen V, Aspenberg P, Michaëlsson K. Risk of atypical femoral fracture during and after bisphosphonate use. *N Engl J Med*. (2014) 371:974–6. doi: 10.1056/NEJMc1403799

7. Abrahamsen B. Older women who use bisphosphonate for longer than 5 years may have increased odds of a subtrochanteric or femoral shaft fracture, but absolute risk is low. *Evid Based Med*. (2011) 16:168–9. doi: 10.1136/ebm.2011.000013

8. Weil YA, Rivkin G, Safran O, Liebergall M, Foldes AJ. The outcome of surgically treated femur fractures associated with long-term bisphosphonate use. *J Trauma*. (2011) 71:186–90. doi: 10.1097/TA.0b013e31821957e3

9. Egol KA, Park JH, Rosenberg ZS, Peck V, Tejwani NC. Healing delayed but generally reliable after bisphosphonate-associated complete femur fractures treated with IM nails. *Clin Orthop Relat Res*. (2014) 472:2728–34. doi: 10.1007/s11999-013-2963-1

10. Chun-Man M, Man-Hong C, Wah-Bong W. Surgical difficulties and complications in the treatment of bisphosphonate-related proximal femur fractures. *J Orthop*. (2015) 19:83–8. doi: 10.1016/j.jotr.2014.06.002

11. Koh A, Guerado E, Giannoudis PV. Atypical femoral fractures related to bisphosphonate treatment: issues and controversies related to their surgical management. *Bone Joint J*. (2017) 99-b:295–302. doi: 10.1302/0301-620x.99b3.bjj-2016-0276.r2

12. Khow KS, Shibu P, Yu SC, Chehade MJ, Visvanathan R. Epidemiology and postoperative outcomes of atypical femoral fractures in older adults: a systematic review. *J Nutr Health Aging*. (2017) 21:83–91. doi: 10.1007/s12603-015-0652-3

13. Shane E, Burr D, Ebeling PR, Abrahamsen B, Adler RA, Brown TD, et al. Atypical subtrochanteric and diaphyseal femoral fractures: report of a task force of the American Society for Bone and Mineral Research. *J Bone Miner Res*. (2010) 25:2267–94. doi: 10.1002/jbmr.253

14. Shane E, Burr D, Abrahamsen B, Adler RA, Brown TD, Cheung AM, et al. Atypical subtrochanteric and diaphyseal femoral fractures: second report of a task force of the American Society for Bone and Mineral Research. *J Bone Miner Res*. (2014) 29:1–23. doi: 10.1002/jbmr.1998

15. Haas AV, LeBoff MS. Osteoanabolic agents for osteoporosis. *J Endocr Soc*. (2018) 2:922–32. doi: 10.1210/js.2018-00118

16. Anagnostis P, Gkekas NK, Potoupnis M, Kenanidis E, Tsiridis E, Goulis DG. New therapeutic targets for osteoporosis. *Maturitas*. (2019) 120:1–6. doi: 10.1016/j.maturitas.2018.11.010

17. Carvalho NN, Voss LA, Almeida MO, Salgado CL, Bandeira F. Atypical femoral fractures during prolonged use of bisphosphonates: short-term responses to strontium ranelate and teriparatide. *J Clin Endocrinol Metab*. (2011) 96:2675–80. doi: 10.1210/jc.2011-0593

18. Fukuda F, Kurinomaru N, Hijioka A. Weekly teriparatide for delayed unions of atypical subtrochanteric femur fractures. *Biol Ther*. (2014) 4:73–9. doi: 10.1007/s13554-014-0013-5

19. Mastaglia SR, Aguilar G, Oliveri B. Teriparatide for the rapid resolution of delayed healing of atypical fractures associated with long-term bisphosphonate use. *Eur J Rheumatol*. (2016) 3:87–90. doi: 10.5152/eurjrheum.2015.0010

20. Gopal GK, Tam KL, Krishnan SP, Maddern IL. Bisphosphonate-associated atypical subtrochanteric femur fractures in the older patient. *N Z Med J*. (2014) 127:81–5.

21. Miller PD, McCarthy EF. Bisphosphonate-associated atypical subtrochanteric femur fractures: paired bone biopsy quantitative histomorphometry before and after teriparatide administration. *Semin Arthritis Rheum*. (2015) 44:477–82. doi: 10.1016/j.semarthrit.2014.09.005

22. Collinge C, Favela J. Use of teriparatide in osteoporotic fracture patients. *Injury*. (2016) 47(Suppl 1):S36–8. doi: 10.1016/s0020-1383(16)30009-2

23. Kim JT, Jeong HJ, Lee SJ, Kim HJ, Yoo JJ. Adjuvant teriparatide therapy for surgical treatment of femoral fractures; does it work. *Hip Pelvis*. (2016) 28:148–56. doi: 10.5371/hp.2016.28.3.148

24. Odvina CV, Zerwekh JE, Rao DS, Maalouf N, Gottschalk FA, Pak CY. Severely suppressed bone turnover: a potential complication of alendronate therapy. *J Clin Endocrinol Metab*. (2005) 90:1294–301. doi: 10.1210/jc.2004-0952

25. Frith JC, Mönkkönen J, Auriola S, Mönkkönen H, Rogers MJ. The molecular mechanism of action of the antiresorptive and antiinflammatory drug clodronate: evidence for the formation in vivo of a metabolite that inhibits bone resorption and causes osteoclast and macrophage apoptosis. *Arthritis Rheum*. (2001) 44:2201–10. doi: 10.1002/1529-0131(200109)44:9<2201::aid-art374>3.0.co;2-e

26. Lawson MA, Xia Z, Barnett BL, Triffitt JT, Phipps RJ, Dunford JE, et al. Differences between bisphosphonates in binding affinities for hydroxyapatite. *J Biomed Mater Res B Appl Biomater*. (2010) 92:149–55. doi: 10.1002/jbm.b.31500

27. Nancollas GH, Tang R, Phipps RJ, Henneman Z, Gulde S, Wu W, et al. Novel insights into actions of bisphosphonates on bone: differences in interactions with hydroxyapatite. *Bone*. (2006) 38:617–27. doi: 10.1016/j.bone.2005.05.003

28. Rogers MJ, Crockett JC, Coxon FP, Mönkkönen J. Biochemical and molecular mechanisms of action of bisphosphonates. *Bone*. (2011) 49:34–41. doi: 10.1016/j.bone.2010.11.008

29. Fratzl P, Roschger P, Fratzl-Zelman N, Paschalis EP, Phipps R, Klaushofer K. Evidence that treatment with risedronate in women with postmenopausal osteoporosis affects bone mineralization and bone volume. *Calcif Tissue Int*. (2007) 81:73–80. doi: 10.1007/s00223-007-9039-8

30. Durchschlag E, Paschalis EP, Zoehrer R, Roschger P, Fratzl P, Recker R, et al. Bone material properties in trabecular bone from human iliac crest biopsies after 3- and 5-year treatment with risedronate. *J Bone Miner Res*. (2006) 21:1581–90. doi: 10.1359/jbmr.060701

31. Karim L, Vashishth D. Role of trabecular microarchitecture in the formation, accumulation, and morphology of microdamage in human cancellous bone. *J Orthop Res*. (2011) 29:1739–44. doi: 10.1002/jor.21448

32. Adele B. Bone mineral crystal size. *Osteoporos Int*. (2003) 14(Suppl 5):S16–S20; discussion S20–1. doi: 10.1007/s00198-003-1468-2

33. Saito M, Marumo K. [Roles of collagen enzymatic and advanced glycation end products associated crosslinking as a determinant of bone quality]. *Nihon Rinsho*. (2011) 69:1189–97.

34. Donnelly E, Meredith DS, Nguyen JT, Gladnick BP, Rebolledo BJ, Shaffer AD, et al. Reduced cortical bone compositional heterogeneity with bisphosphonate treatment in postmenopausal women with intertrochanteric and subtrochanteric fractures. *J Bone Miner Res*. (2012) 27:672–8. doi: 10.1002/jbmr.560

35. Einhorn TA. Can an anti-fracture agent heal fractures? *Clin Cases Miner Bone Metab*. (2010) 7:11–4.

36. Ziebart T, Pabst A, Klein MO, Kämmerer P, Gauss L, Brüllmann D, et al. Bisphosphonates: restrictions for vasculogenesis and angiogenesis: inhibition of cell function of endothelial progenitor cells and mature endothelial cells in vitro. *Clin Oral Investig*. (2011) 15:105–11. doi: 10.1007/s00784-009-0365-2

37. Neer RM, Arnaud CD, Zanchetta JR, Prince R, Gaich GA, Reginster JY, et al. Effect of parathyroid hormone (1-34) on fractures and bone mineral density in postmenopausal women with osteoporosis. *N Engl J Med*. (2001) 344:1434–41. doi: 10.1056/nejm200105103441904

38. Kraenzlin ME, Meier C. Parathyroid hormone analogues in the treatment of osteoporosis. *Nat Rev Endocrinol*. (2011) 7:647–56. doi: 10.1038/nrendo.2011.108

39. Hanley DA, Watson PH, Hodsman AB, Dempster DW. Chapter 78 - pharmacological mechanisms of therapeutics: parathyroid hormone A2. In: JP Bilezikian, LG Raisz, TJ Martin, editors. *Principles of bone biology*. 3rd ed. Amsterdam, London: Elsevier (2008). p. 1659–95. doi: 10.1016/B978-0-12-373884-4.00085-9

40. Hock JM, Gera I. Effects of continuous and intermittent administration and inhibition of resorption on the anabolic response of bone to parathyroid hormone. *J Bone Miner Res*. (1992) 7:65–72. doi: 10.1002/jbmr.5650070110

41. Papapoulos SE. Anabolic bone therapies in 2014: new bone-forming treatments for osteoporosis. *Nat Rev Endocrinol*. (2015) 11:69–70. doi: 10.1038/nrendo.2014.214

42. Friedl G, Turner RT, Evans GL, Dobnig H. Intermittent parathyroid hormone (PTH) treatment and age-dependent effects on rat cancellous bone and mineral metabolism. *J Orthop Res*. (2007) 25:1454–64. doi: 10.1002/jor.20433

43. Canalis E. Update in new anabolic therapies for osteoporosis. *J Clin Endocrinol Metab*. (2010) 95:1496–504. doi: 10.1210/jc.2009-2677

44. Esbrit P, Alcaraz MJ. Current perspectives on parathyroid hormone (PTH) and PTH-related protein (PTHrP) as bone anabolic therapies. *Biochem Pharmacol*. (2013) 85:1417–23. doi: 10.1016/j.bcp.2013.03.002

45. Canalis E, Giustina A, Bilezikian JP. Mechanisms of anabolic therapies for osteoporosis. *N Engl J Med*. (2007) 357:905–16. doi: 10.1056/NEJMra067395

46. Jilka RL. Molecular and cellular mechanisms of the anabolic effect of intermittent PTH. *Bone*. (2007) 40:1434–46. doi: 10.1016/j.bone.2007.03.017

47. Choi HS, Park SY, Kim YM, Kim SH, Kim KM, Chung YS. Medical treatment of severe osteoporosis including new concept of advanced severe osteoporosis. *Osteoporos Sarcopenia*. (2016) 2:13–9. doi: 10.1016/j.afos.2016.02.003

48. Huang TW, Chuang PY, Lin SJ, Lee CY, Huang KC, Shih HN, et al. Teriparatide improves fracture healing and early functional recovery in treatment of osteoporotic intertrochanteric fractures. *Medicine (Baltimore)*. (2016) 95:e3626. doi: 10.1097/md.0000000000003626

49. Webb JCJ, Tricker J. A review of fracture healing. *Curr Orthop*. (2000) 14:457–63. doi: 10.1054/cuor.2000.0145

50. Murphy CM, Schindeler A, Cantrill LC, Mikulec K, Peacock L, Little DG. PTH(1-34) treatment increases bisphosphonate turnover in fracture repair in rats. *J Bone Miner Res*. (2015) 30:1022–9. doi: 10.1002/jbmr.2424

51. Kakar S, Einhorn TA, Vora S, Miara LJ, Hon G, Wigner NA, et al. Enhanced chondrogenesis and Wnt signaling in PTH-treated fractures. *J Bone Miner Res*. (2007) 22:1903–12. doi: 10.1359/jbmr.070724

52. Jobke B, Muche B, Burghardt AJ, Semler J, Link TM, Majumdar S. Teriparatide in bisphosphonate-resistant osteoporosis: microarchitectural changes and clinical results after 6 and 18 months. *Calcif Tissue Int*. (2011) 89:130–9. doi: 10.1007/s00223-011-9500-6

53. Nozaka K, Miyakoshi N, Kasukawa Y, Maekawa S, Noguchi H, Shimada Y. Intermittent administration of human parathyroid hormone enhances bone formation and union at the site of cancellous bone osteotomy in normal and ovariectomized rats. *Bone*. (2008) 42:90–7. doi: 10.1016/j.bone.2007.08.041

54. Dobnig H, Stepan JJ, Burr DB, Li J, Michalská D, Sipos A, et al. Teriparatide reduces bone microdamage accumulation in postmenopausal women previously treated with alendronate. *J Bone Miner Res*. (2009) 24:1998–2006. doi: 10.1359/jbmr.090527

55. Pietrogrande L, Raimondo E. Teriparatide in the treatment of non-unions: scientific and clinical evidences. *Injury*. (2013) 44(Suppl 1):S54–7. doi: 10.1016/s0020-1383(13)70013-5

56. Borges JL, Freitas A, Bilezikian JP. Accelerated fracture healing with teriparatide. *Arq Bras Endocrinol Metabol*. (2013) 57:153–6. doi: 10.1590/s0004-27302013000200010

57. Saleh A, Hegde VV, Potty AG, Schneider R, Cornell CN, Lane JM. Management strategy for symptomatic bisphosphonate-associated incomplete atypical femoral fractures. *Hss j*. (2012) 8:103–10. doi: 10.1007/s11420-012-9275-y

58. Miyakoshi N, Aizawa T, Sasaki S, Ando S, Maekawa S, Aonuma H, et al. Healing of bisphosphonate-associated atypical femoral fractures in patients with osteoporosis: a comparison between treatment with and without teriparatide. *J Bone Miner Metab*. (2015) 33:553–9. doi: 10.1007/s00774-014-0617-3

59. Alwahhabi BK, Alsuwaine BA. Long-term use of bisphosphonates in osteoporosis. *Saudi Med J*. (2017) 38:604–8. doi: 10.15537/smj.2017.6.19793

60. Yeh WL, Su CY, Chang CW, Chen CH, Fu TS, Chen LH, et al. Surgical outcome of atypical subtrochanteric and femoral fracture related to bisphosphonates use in osteoporotic patients with or without teriparatide treatment. *BMC Musculoskelet Disord*. (2017) 18:527. doi: 10.1186/s12891-017-1878-5

61. Tsuchie H, Miyakoshi N, Iba K, Kasukawa Y, Nozaka K, Dohke T, et al. The effects of teriparatide on acceleration of bone healing following atypical femoral fracture: comparison between daily and weekly administration. *Osteoporos Int*. (2018) 29:2659–65. doi: 10.1007/s00198-018-4658-7

62. Tsuchie H, Miyakoshi N, Kasukawa Y, Nozaka K, Saito K, Kinoshita H, et al. Evaluation of factors affecting the occurrence of second atypical fracture after bone union of the first atypical fracture. *Bone*. (2021) 143:115671. doi: 10.1016/j.bone.2020.115671

63. Chiang CY, Zebaze RM, Ghasem-Zadeh A, Iuliano-Burns S, Hardidge A, Seeman E. Teriparatide improves bone quality and healing of atypical femoral fractures associated with bisphosphonate therapy. *Bone*. (2013) 52:360–5. doi: 10.1016/j.bone.2012.10.006

64. Watts NB, Aggers D, McCarthy EF, Savage T, Martinez S, Patterson R, et al. Responses to treatment with teriparatide in patients with atypical femur fractures previously treated with bisphosphonates. *J Bone Miner Res*. (2017) 32:1027–33. doi: 10.1002/jbmr.3081

65. Greenspan SL, Vujevich K, Britton C, Herradura A, Gruen G, Tarkin I, et al. Teriparatide for treatment of patients with bisphosphonate-associated atypical fracture of the femur. *Osteoporos Int*. (2018) 29:501–6. doi: 10.1007/s00198-017-4286-7

66. Huang HT, Kang L, Huang PJ, Fu YC, Lin SY, Hsieh CH, et al. Successful teriparatide treatment of atypical fracture after long-term use of alendronate without surgical procedure in a postmenopausal woman: a case report. *Menopause*. (2012) 19:1360–3. doi: 10.1097/gme.0b013e318260143d

67. Holm J, Eiken P, Hyldstrup L, Jensen JE. Atypical femoral fracture in an osteogenesis imperfecta patient successfully treated with teriparatide. *Endocr Pract*. (2014) 20:e187–90. doi: 10.4158/ep14141.cr

68. Gomberg SJ, Wustrack RL, Napoli N, Arnaud CD, Black DM. Teriparatide, vitamin D, and calcium healed bilateral subtrochanteric stress fractures in a postmenopausal woman with a 13-year history of continuous alendronate therapy. *J Clin Endocrinol Metab*. (2011) 96:1627–32. doi: 10.1210/jc.2010-2520

69. Zhang HY, Weng HL, Li M, Zhang J. Different surgical outcomes in a patient with bilateral atypical femoral fracture related to bisphosphonate use with or without teriparatide treatment. *Osteoporos Int*. (2019) 30:2349–54. doi: 10.1007/s00198-019-05131-2

70. Uppin R, Gupta S, Prakash S. A case report of bisphosphonate-induced bilateral osteoporotic subtrochanteric fracture femurii: review of literature. *J Orthop Case Rep*. (2016) 6:31–4. doi: 10.13107/jocr.2250-0685.558

71. Tsuchie H, Miyakoshi N, Nishi T, Abe H, Segawa T, Shimada Y. Combined effect of a locking plate and teriparatide for incomplete atypical femoral fracture: two case reports of curved femurs. *Case Rep Orthop*. (2015) 2015:213614. doi: 10.1155/2015/213614

72. Tarazona-Santabalbina FJ, Aguilella-Fernández L. Bisphosphonate long-term treatment related bilateral subtrochanteric femoral fracture. Can teriparatide be useful? *Aging Clin Exp Res*. (2013) 25:605–9. doi: 10.1007/s40520-013-0137-3

73. Tan J, Sano H, Poole K. Antiresorptive-associated spontaneous fractures of both tibiae, followed by an atypical femur fracture during the sequential treatment with alendronate, denosumab then teriparatide. *BMJ Case Rep*. (2019) 12:e229366. doi: 10.1136/bcr-2019-229366

74. Righetti M, Wach J, Desmarchelier R, Coury F. Teriparatide treatment in an adult patient with hypophosphatasia exposed to bisphosphonate and revealed by bilateral atypical fractures. *Joint Bone Spine*. (2018) 85:365–7. doi: 10.1016/j.jbspin.2017.12.001

75. Ramchand SK, Chiang CY, Zebaze RM, Seeman E. Recurrence of bilateral atypical femoral fractures associated with the sequential use of teriparatide and denosumab: a case report. *Osteoporos Int*. (2016) 27:821–5. doi: 10.1007/s00198-015-3354-0

76. Ramani A, Wagner R. Periprosthetic femoral stress fracture after bisphosphonate treatment resulting in nonunion successfully treated with teriparatide: a case report. *JBJS Case Connect*. (2016) 6:e37. doi: 10.2106/jbjs.cc.15.00172

77. Nguyen HH, Milat F, Ebeling PR. A new contralateral atypical femoral fracture despite sequential therapy with teriparatide and strontium ranelate. *Bone Rep*. (2017) 6:34–7. doi: 10.1016/j.bonr.2017.01.002

78. Lampropoulou-Adamidou K, Tournis S, Balanika A, Antoniou I, Stathopoulos IP, Baltas C, et al. Sequential treatment with teriparatide and strontium ranelate in a postmenopausal woman with atypical femoral fractures after long-term bisphosphonate administration. *Hormones (Athens)*. (2013) 12:591–7. doi: 10.14310/horm.2002.1448

79. Blum L, Cummings K, Goulet JA, Perdue AM, Mauffrey C, Hake ME. Atypical femur fractures in patients receiving bisphosphonate therapy: etiology and management. *Eur J Orthop Surg Traumatol*. (2016) 26:371–7. doi: 10.1007/s00590-016-1742-6

80. Asano Y, Tajiri K, Yagishita S, Nakanishi H, Ishii T. Bilateral atypical ulnar fractures occurring after long-term treatment with bisphosphonate for 7 years and with teriparatide for 2 years: a case report. *Osteoporos Int*. (2020) 31:2473–6. doi: 10.1007/s00198-020-05618-3

81. Takahashi Y, Hatashita S, Shinden Y, Ito M, Kaneuchi Y, Hakozaki M, et al. Periprosthetic fracture resembling atypical femoral fracture after fixation with retrograde intramedullary nail in elderly women: a report of two cases. *In Vivo*. (2021) 35:1837–42. doi: 10.21873/invivo.12445

82. Miura T, Kijima H, Tani T, Ebina T, Miyakoshi N, Shimada Y. Two cases of periprosthetic atypical femoral fractures in patients on long-term bisphosphonate treatment. *Case Rep Surg*. (2019) 2019:9845320. doi: 10.1155/2019/9845320

frontiers | Frontiers in Surgery

TYPE Review
PUBLISHED 06 January 2023
DOI 10.3389/fsurg.2022.1049534

Check for updates

OPEN ACCESS

EDITED BY
Paphon Sa-ngasoongsong,
Mahidol University, Thailand

REVIEWED BY
Osama Farouk,
Assiut University Hospital, Egypt
Jian Wang,
Southern Medical University, China
Hanbin Ouyang,
Affiliated Hospital of Guangdong Medical College Hospital, China

*CORRESPONDENCE
Jing Juehua
jjhhu@sina.com
Li Jun
efylijunpaper@163.com

†These authors share last authorship

SPECIALTY SECTION
This article was submitted to Orthopedic Surgery, a section of the journal Frontiers in Surgery

RECEIVED 20 September 2022
ACCEPTED 02 November 2022
PUBLISHED 06 January 2023

CITATION
Shuai L, Huiwen W, Shihao D, Fangyuan W, Juehua J and Jun L (2023) A comparison of different surgical approaches to hemiarthroplasty for the femoral neck fractures: A meta-analysis.
Front. Surg. 9:1049534.
doi: 10.3389/fsurg.2022.1049534

COPYRIGHT
© 2023 Shuai, Huiwen, Shihao, Fangyuan, Juehua and Jun. This is an open-access article distributed under the terms of the Creative Commons Attribution License (CC BY). The use, distribution or reproduction in other forums is permitted, provided the original author(s) and the copyright owner(s) are credited and that the original publication in this journal is cited, in accordance with accepted academic practice. No use, distribution or reproduction is permitted which does not comply with these terms.

A comparison of different surgical approaches to hemiarthroplasty for the femoral neck fractures: A meta-analysis

Liang Shuai[1,2], Wu Huiwen[1,2], Deng Shihao[1,2], Wang Fangyuan[1,2], Jing Juehua[1,2†*] and Li Jun[1,2†*]

[1]Department of Orthopedics, The Second Hospital of Anhui Medical University, Hefei, China, [2]Institute of Orthopedics, Research Center for Translational Medicine, The Second Hospital of Anhui Medical University, Hefei, China

There are three traditional surgical approaches to hemiarthroplasty (HA) for femoral neck fractures, respectively, the anterior approach (AA), the lateral approach (LA) and the posterior approach (PA). However, the optimum approach is still controversial, the purpose of this meta-analysis is to identify the merits and demerits of all three approaches. All clinical published studies in PubMed, Web of Science, Embase, and the Cochrane Library from January 2000 to April 2022 were searched which compared different surgical approaches and covered surgery-related outcomes and frequent complications. Five randomized controlled trials and 26 cohort studies for a total of 31 clinical trials were included in the meta-analysis. The dislocation of PA was significantly higher than LA (OR: 3.00 95% CI: 2.25–4.01 $I^2 = 27\%$ $P < 0.00001$) and AA (OR: 6.61 95% CI: 2.28–19.13 $I^2 = 0\%$ $P = 0.0005$); PA was substantially more than LA in terms of risk of postoperative reoperation ($P < 0.05$); meanwhile, AA has markedly shorter hospital length of stays than LA. The remaining items showed no significant differences in the results.The results of this meta-analysis demonstrated that the risk of PA dislocation and reoperation is higher with hemiarthroplasty, and AA has markedly shorter hospital length of stays than LA.

KEYWORDS
hemiarthroplasty (HA), anterior approach (AA), lateral approach (LA), posterior approach (PA), dislocation, meta-analysis

Introduction

Femoral neck fractures are a common type of fracture in elderly individuals, accounting for approximately 57%~64% of hip fractures, with projections estimating the total number of hip fractures worldwide to be approximately 4 million in 2025 (1, 2). Hip arthroplasty is a clinically widespread surgical procedure for the therapy of severely aged femoral neck fractures (3). However, patients with a combination of multiple underlying illnesses, poor health conditions and lower functional demands are more appropriate for artificial femoral head hemiarthroplasty, which can reduce the operation time and allow patients to move early after surgery (4–6).

There are various approaches to hemiarthroplasty, such as the direct anterior approach (DAA) (7), the lateral approach (8), and the true posterior approach (9).

Different approaches impact the patient's early postoperative mobility and the occurrence of complications (10). We took van's categorization methodology and classified all the diverse approaches inductively as the anterior approach (AA), the lateral approach (LA) and the posterior approach (PA) (11). Some clinical research has compared two or three of these approaches, but the specific approach with absolute superiority remains indistinguishable, and some authors have tried to perform an analysis using meta-analysis (11, 12), but the number of reports is low and not exhaustive, and the current evidence needs to be updated. Therefore, we performed a meta-analysis comparing the three approaches to examine their possible advantages in terms of complications, postoperative functional outcomes, and surgical outcomes.

Materials and methods

Methodology

This systematic review adhered to the preferred reporting items for systematic reviews and meta-analyses (PRISMA) statement. The literature search strictly followed the PICO (Participant, Intervention, Comparison, Outcome) principles. All personnel in this study were involved in designing the search strategy and were trained in search knowledge. A comprehensive search of known databases was conducted to find suitable articles for analysis.

We performed a literature search for studies published in PubMed ($n = 233$), EMBASE ($n = 474$), Web of Science ($n = 181$), and the Cochrane Central Register of Controlled Trials ($n = 63$),

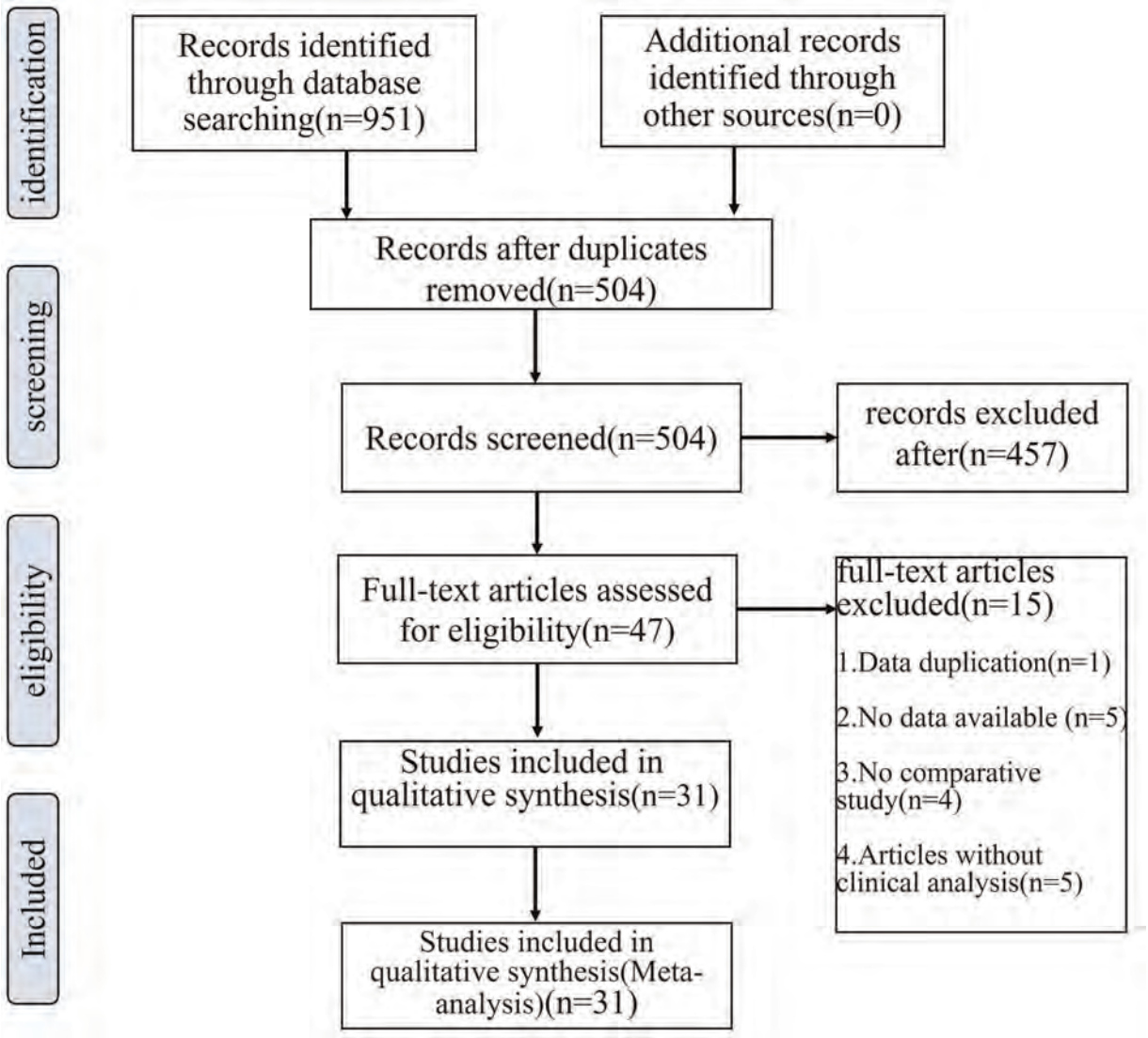

FIGURE 1
Literature screening flow chart in detail.

finding relevant research published from January 2000 to April 2022, regardless of language. Search for their subject terms and free words of "hemiarthroplasty", "approach" and "hip", and various combinations of related words, with the exact search formula referenced to van der Sijp (11). Through the combination of subject words and free words, the articles were screened comprehensively.

Data abstraction

Two separate writers entered data taken from the included research. Any differences were settled by consensus or dialog with the senior author. Titles and abstracts were reviewed, and inconsistencies were subjected to a full-text search to determine eligibility and settle conflicts by consensus. Sample size, research design, patient age, kind of operation, follow-up data, and outcome data were all retrieved (i.e., surgical outcomes, complications, clinical outcomes).

Quality assessment

Two writers independently assessed the risk of bias in the papers that were included; if there was a disagreement

TABLE 1 Characteristics of the included studies.

Author (Year)	Type of study	Approach (Sample Size)			Mean Age (y)	Sex (M/F)	Journal
		AA	LA	PA			
Abram (21) (2015)	RCS	–	753	54	83	232/575	Injury
Auffarth (20) (2011)	RCT	24	24	–	82.6/83.7	10/38	J Trauma
Baba (22) (2013)	PCS	40	–	39	76.7/74.9	15/64	World J Orthop
Bibber (23) (2012)	RCS	–	217	487	80.4/80.3	212/492	Int Orthop
Bűcs (24) (2021)	RCS	51	43	–	79.39/79.26	35/59	Injury
Bush (25) (2007)	RCS	186	–	199	78.34/80.34	102/273	Orthopedics
Carlson (26) (2017)	RCS	85	75	–	82.7/82.9	63/97	Orthopedics
de Vries (27) (2020)	RCS	–	493	516	87/86	NA	Eur J Orthop Surg Traumatol
Enocson (28) (2008)	PCS	–	431	308	84/84	241/929	Acta Orthop
Gursoy (29) (2019)	RCS	–	64	48	87.1/86.5	34/78	Clin Interv Aging
Hongisto (30) (2018)	PCS	–	151	118	82.9/82.5	57/212	Scand J Surg
Kristensen (31) (2017)	RCS	–	18,918	1990	83/83	5,714/15,194	Acta Orthop
Ladurner (10) (2021)	RCS	79	158	–	85.5/86.0	68/196	Arch Orthop Trauma Surg
Lakhani (32) (2022)	RCS	40	54	–	85.34/85.83	30/64	Eur J Orthop Surg Traumatol
Langlois (33) (2015)	PCS	38	–	44	86/85	21/61	Acta Orthop
Leonardsson (34) (2016)	RCS	–	1,140	978	85/85	149/1,569	Bone Joint J
Mansouri (35) (2021)	RCS	–	99	55	77.97/75.43	63/91	Int J Burns Trauma
Mukka (36) (2016)	PCS	–	102	83	83.5/85.51	56/129	Traumatol Surg Res
Neyisci (37) (2020)	RCS	56	–	54	83/82	59/51	Med Sci Monit
Ozan (38) (2016)	RCS	–	86	147	78.3/78.7	97/136	Int J Clin Exp Med
Pala (39) (2016)	RCS	55	–	54	89/87.6	21/88	Eur J Orthop Surg Traumatol
Parker (19) (2015)	RCT	–	108	108	84.3/83.6	20/198	Injury
Renken (18) (2012)	RCT	30	27	–	84/87.5	7/50	BMC Musculoskelet Disord
Saxer (5) (2018)	RCT	99	82	–	84.4/84.0	52/129	BMC Geriatr
Sayed-Noor (40) (2016)	PCS	–	24	24	83.4/82.7	9/39	J Orthop Trauma
Sierra (41) (2006)	RCS	–	1,657	245	63	NA	Clin Orthop Relat Res
Svenøy (42) (2017)	PCS	–	397	186	82.6/83.2	149/434	Injury
Tsailas (43) (2021)	RCS	–	50	50	80.8/82.3	29/71	Injury
Tsukada (44) (2010)	PCS	44	–	39	80.4/81.9	15/68	J Orthop Sci
Verzellotti (17) (2020)	RCT	42	–	44	85.3/85.0	30/70	Hip Int
Yazdanpanah (45) (2020)	PCS	20	–	40	79.27	27/33	Rev Latinoam Hiperte

RCT, randomized controlled trials; PCS, prospective cohort studies; RCS, retrospective cohort studies; NA, not available.

regarding the results, it was addressed through conversation or with the help of a third investigator. The quality of the methodology of the enrolled research was assessed on the basis of the Cochrane Quality Assessment Form provided by Review Manager (RevMan) 5.4 software in six main areas: selection bias, performance bias, detection bias, attrition bias, reporting bias, and other biases (13). Each type of bias was judged as low risk, high risk, or unclear risk, and a risk of bias map was generated.

Statistical analysis

Review Manager (RevMan) [Computer program]. Version 5.4.1, The Cochrane Collaboration, 2020, was used to analyze the selected studies. For data extraction, the basic information mainly included study type, follow-up time, sample size of control and intervention groups, age, body mass index (BMI), etc. Specific indicators were surgical outcomes, complications, and clinical outcomes.

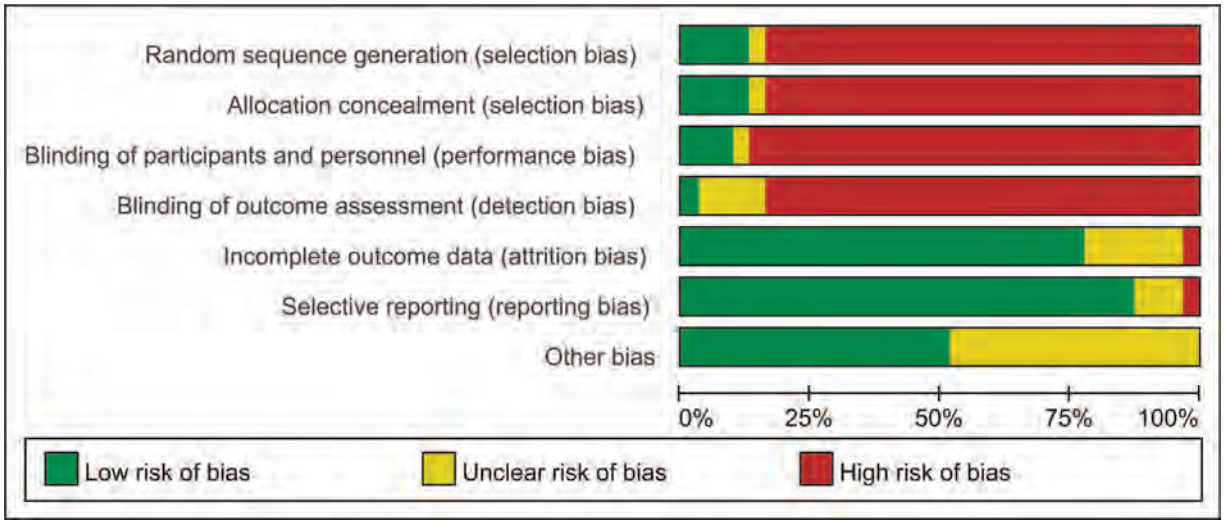

FIGURE 2
Risk of bias graph.

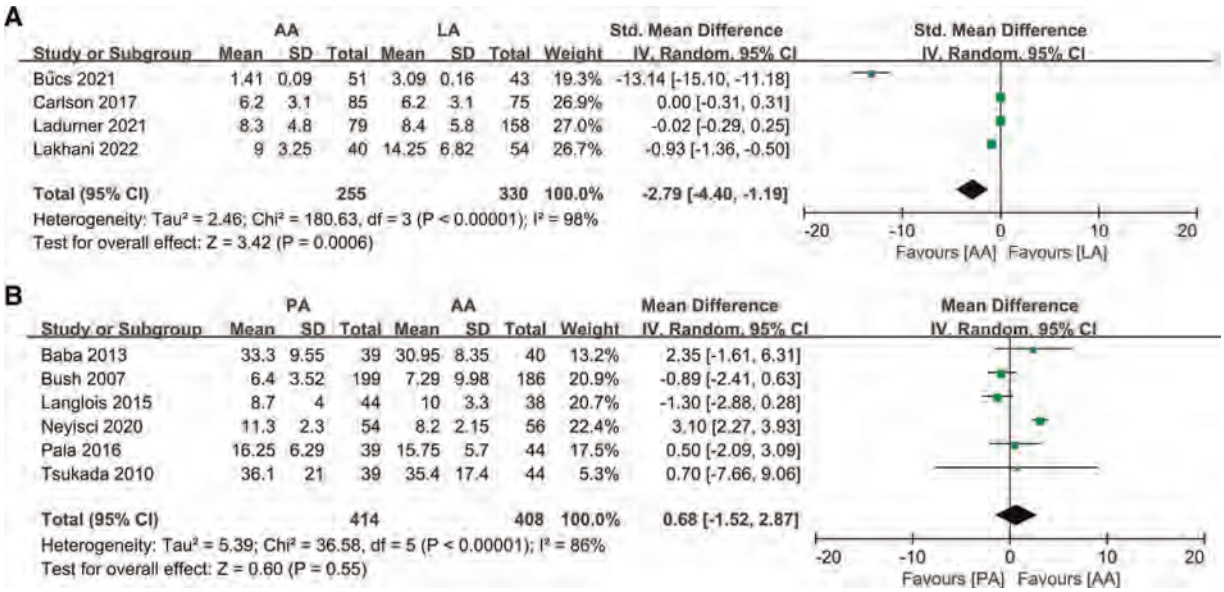

FIGURE 3
Forest plot comparison of length of hospitalization. (A) Anterior approach and lateral approach, (B) Anterior approach and posterior approach.

The standard deviation (SD) was utilized to compute the mean difference (MD) or Std. mean difference (SMD) and 95 percent confidence interval for continuous data such as length of hospitalization, operation time and surgical blood loss. The odds ratio (OR) and 95% confidence interval (CI) were used for dichotomous data. The χ^2 test result and the value of I^2 were used to examine statistical heterogeneity.

Different authors provide various figures, including medians, ranges or quartiles, and we converted the desired results into means and standard deviations by referring to the statistical method introduced by Wan (14), which is an improvement on the one provided by Hozo and Bland (15, 16), thus bringing the individual values closer to the true value of the data itself and minimizing errors.

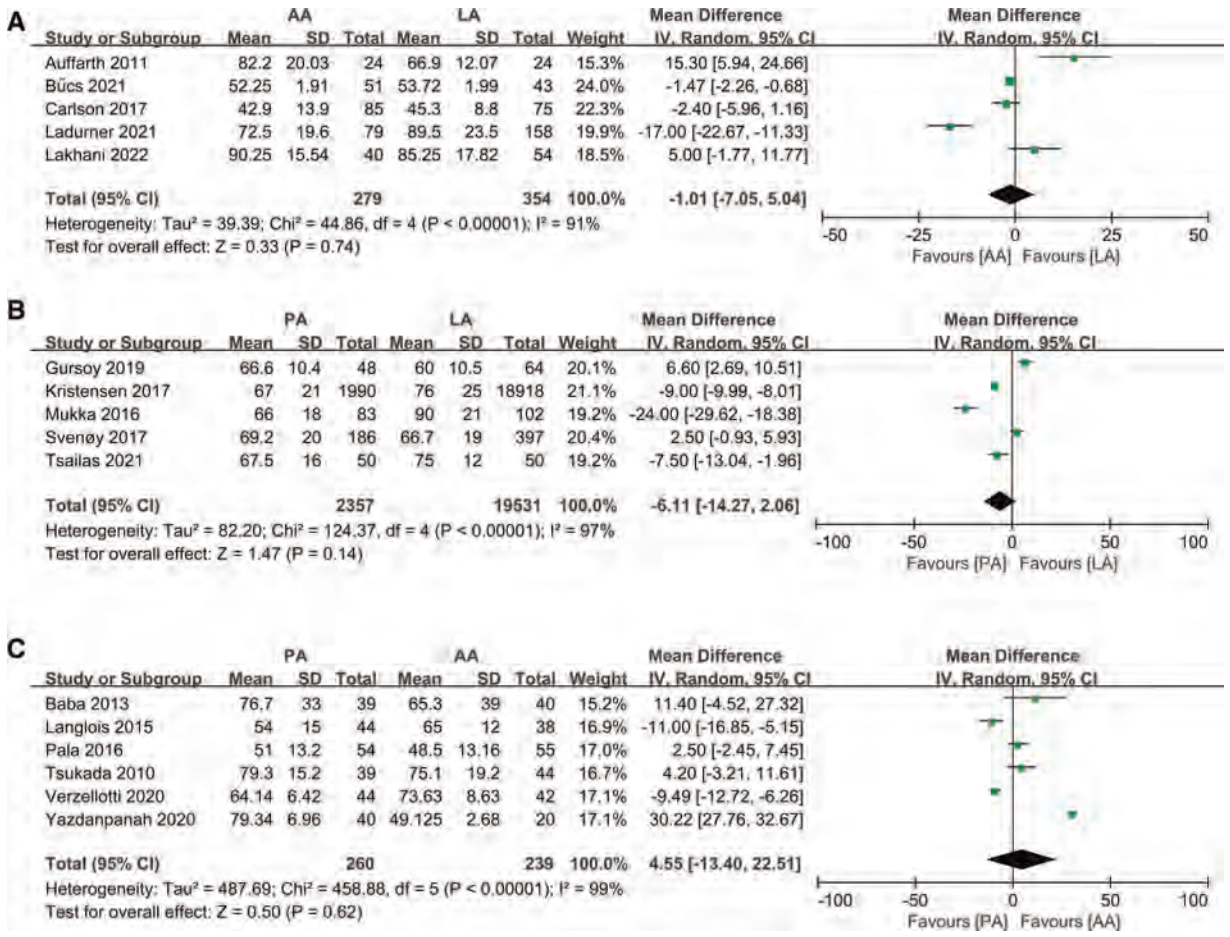

FIGURE 4
Forest plot comparison of operation time. (A) Anterior approach and lateral approach, (B) Posterior approach and lateral approach, (C) Posterior approach and anterior approach.

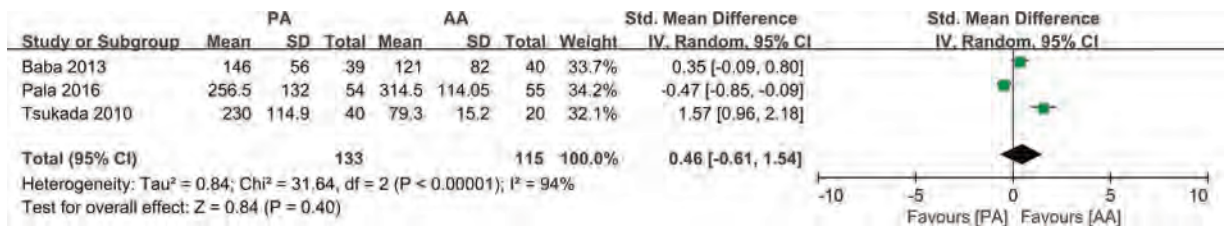

FIGURE 5
Forest plot comparison of surgical blood loss.

To begin, I^2 was used to test the heterogeneity of the results of the included literature; if $I^2 > 50\%$, $P < 0.1$, which means that there is a large heterogeneity in the included studies; we will explore the reasons for the heterogeneity and conduct sensitivity analysis. In case it is still impossible to eliminate the heterogeneity of the literature, providing clinical consistency, then use the random effect model. If the heterogeneity of the literature was low, a fixed effects model was used.

Results

A series of 951 relevant articles were accessed in the search database for this research, and after analysis of titles, abstracts, and full text, 31 studies involving the hip were qualified and incorporated into the definitive meta-analysis **Figure 1**. Detailed descriptions of the characteristics and patient demographics for each study are listed in **Table 1**. Five were randomized controlled trials (5, 17–20) (RCTs) including 588 hips and the others were cohort studies.

The danger of selection bias was considerable since just five of the included studies were assigned randomly, accounting for approximately 16% of the total. Because there were so few participants and personnel blinding procedures were used, performance and detection biases were very substantial. The risk of attrition and reporting bias was low, but the risk of other biases was moderate, as shown in **Figure 2**.

Length of hospitalization

Regarding patient length of stay, four studies (10, 24, 26, 32) reported results comparing AA with LA as well as six studies (22, 25, 33, 37, 39, 44) showed results for PA and AA. The meta-analysis showed a statistically significant difference in length of stay when comparing AA with LA (SMD: −2.79

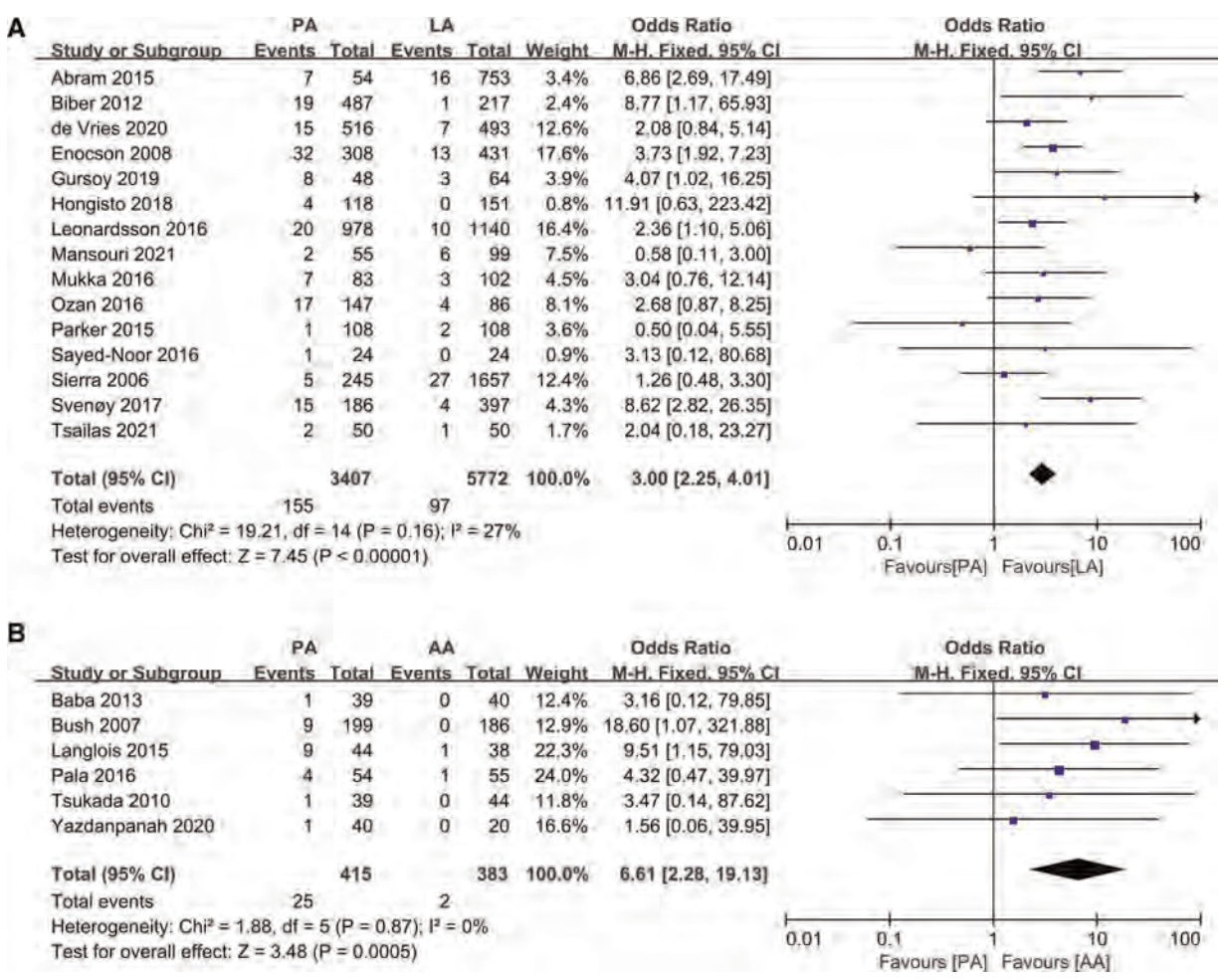

FIGURE 6
Forest plot comparison of dislocation. (A) Anterior approach and lateral approach, (B) Posterior approach and anterior approach.

95% CI: −4.40–1.19 $I^2 = 98\%$ $P = 0.0006$ Figure 3A). There was no significant difference between PA and AA (MD: 0.68 95% CI: −1.52–2.87 $I^2 = 86\%$ $P = 0.55$ Figure 3B). Nevertheless, the number of reported cases for PA and LA was too small, and only de Vries (27) ($P = 0.58$) and Tsailas (43) ($P = 0.25$) were compared, both without differences.

Operation time

Sixteen studies reported the operation time of the 2 methods. The analysis showed no statistically significant differences in all comparisons of operative times: AA vs. LA (10, 20, 24, 26, 32) (MD: −1.01 95% CI: −7.05–5.04 $I^2 = 91\%$ $P = 0.74$ Figure 4A); PA vs. LA (29, 31, 36, 42, 43) (MD: −6.11 95% CI: −14.27–2.06 $I^2 = 97\%$ $P = 0.14$ Figure 4B); PA vs. AA (17, 22, 33, 39, 44, 45) (MD: 4.55 95% CI: −13.40–22.51 $I^2 = 99\%$ $P = 0.62$ Figure 4C). All $I^2 \geq 50\%$ and there was statistical heterogeneity, hence the random effects model was used for analysis.

Surgical blood loss

Numerous reports have compared surgical blood loss in different methods, including intraoperative blood loss or transfusion in different units, changes in preoperative and postoperative hemoglobin levels, transfusion rates, and hematoma formation. However, only comparative studies of AA and PA could be converted to uniform units for analysis (22, 39, 44). The outcome demonstrated no significant difference in surgical blood loss between the PA and AA groups (SMD: −0.46 95% CI: −0.61–1.54 $I^2 = 94\%$ $P = 0.40$ Figure 5).

Dislocation

Postoperative dislocation rates were reported in all 15 papers (19, 21, 23, 27–30, 34–36, 38, 40–43), and heterogeneity analysis showed no significant heterogeneity with $I^2 = 27\%$ $P = 0.16$, and meta-analysis was conducted using a fixed effects model. The data showed a statistically significant difference in the dislocation rate between the PA and LA groups (OR: 3.00 95% CI: 2.25–4.01 $I^2 = 27\%$ $P < 0.00001$ Figure 6A). Simultaneously, after analyzing the data provided by the six articles comparing PA and AA (22, 25, 33, 39, 44, 45), a statistically significant difference was found (OR: 6.61 95% CI: 2.2819.13 $I^2 = 0\%$ $P = 0.0005$ Figure 6B). As can be seen, the rate of dislocation was significantly higher in the PA group than in the other two groups. Carlson (26) and Lakhani (32) reported complications

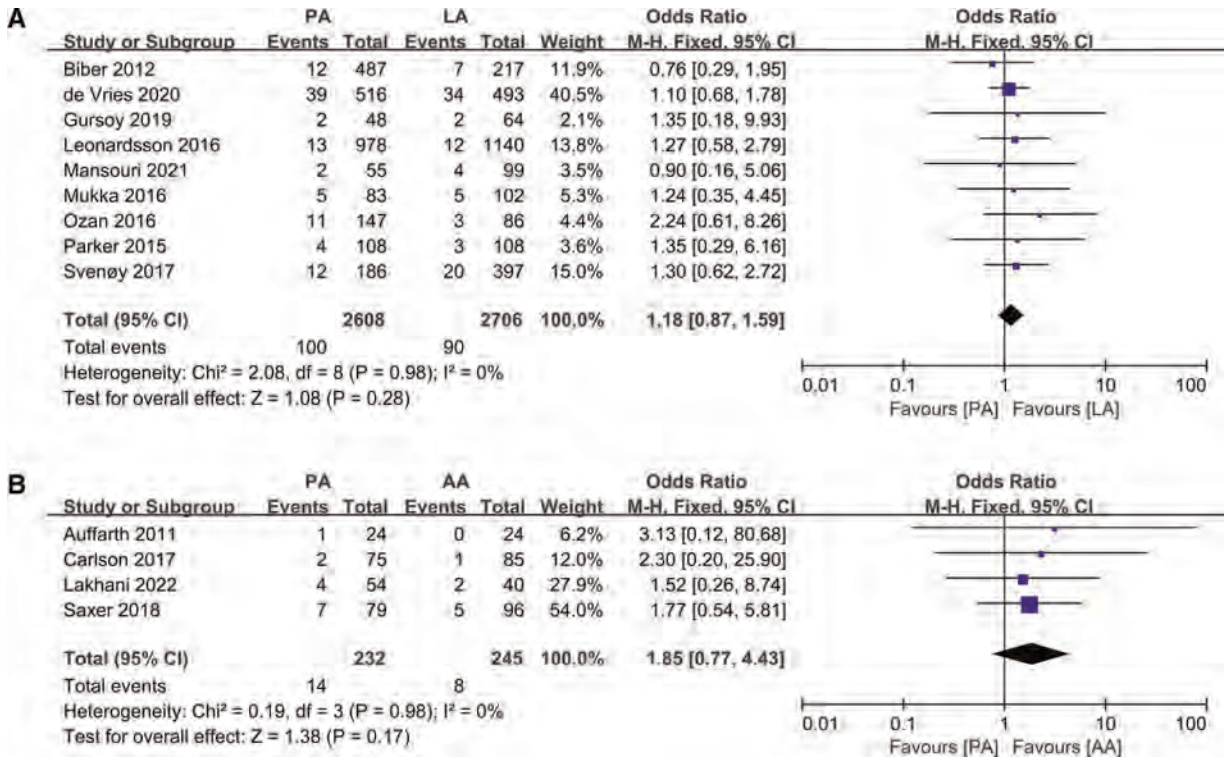

FIGURE 7
Forest plot comparison of wound infections. (A) Posterior approach and lateral approach, (B) Posterior approach and anterior approach.

of DA and LA dislocation, and although statistical analysis could not be performed, no significant differences were detected on either side.

Wound infections

All four studies (5, 20, 26, 32) concluded that no statistically significant difference in the risk of infection was observed between PA and AA, and we did not detect a statistically significant difference when we performed an aggregate analysis (OR: 1.85 95% CI: 0.77–4.43 $I^2 = 0\%$ $P = 0.17$ **Figure 7A**). We obtained the same conclusion in the PA and LA studies (19, 23, 27, 29, 34–36, 38, 42) (OR: 1.18 95% CI: 0.87–1.59 $I^2 = 0\%$ $P = 0.28$ **Figure 7B**).

Fractures

A series of 15 studies investigating surgery-related fracture complications were reported. Pooling data from 3 studies (20, 26, 32) comparing LA and AA did not reveal statistically significant differences (OR: 0.56 95% CI: 0.16–1.98 $I^2 = 0\%$ $P = 0.37$ **Figure 8A**), while 8 studies (19, 23, 27, 29, 34, 36, 42, 43) analyzed PA and LA (OR: 0.87 95% CI: 0.55–1.36 $I^2 = 0\%$ $P = 0.53$ **Figure 8B**), and another 4 (22, 39, 44, 45) compared LA with AA (OR: 0.71 95% CI: 0.18–2.79 $I^2 = 0\%$ $P = 0.62$ **Figure 8C**).

Reoperations

Six papers (5, 10, 18, 20, 26, 32) reported reoperation rates for AA and LA, with no significant heterogeneity between

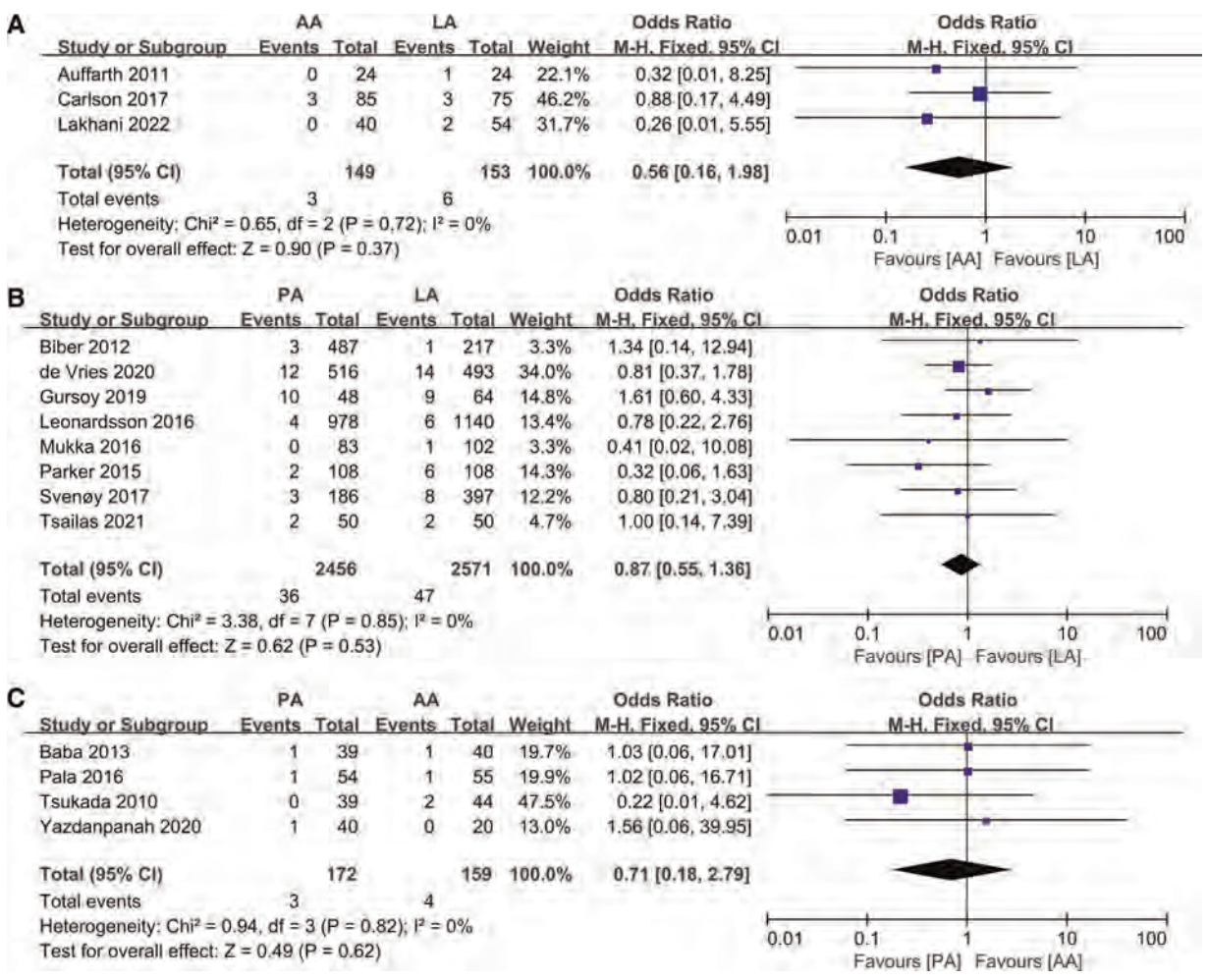

FIGURE 8
Forest plot comparison of fractures. (A) Anterior approach and lateral approach, (B) Posterior approach and lateral approach, (C) Posterior approach and anterior approach.

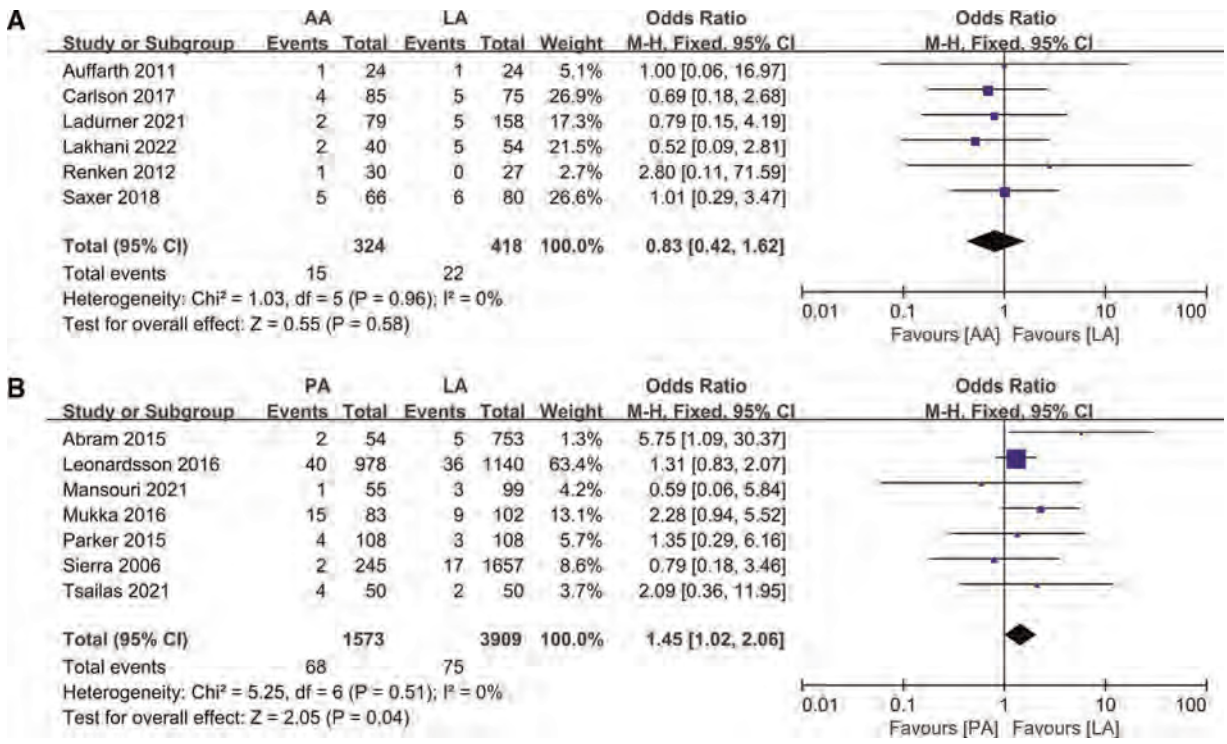

FIGURE 9
Forest plot comparison of reoperation. (A) Anterior approach and lateral approach, (B) Posterior approach and lateral approach.

them, and meta-analysis was conducted using a fixed-effects model. The data revealed no statistically significant differences (OR: 0.83 95% CI: 0.42–1.62 $I^2 = 0\%$ $P = 0.58$ **Figure 9A**). Nevertheless, 8 articles (19, 21, 31, 34–36, 41, 43) offered data on PA and LA reoperation, of which Kristensen (31) et al. provided only the rate of postoperative dislocation, without clarifying whether surgical treatment or conservative management was taken after dislocation, and they were excluded from the analysis. The results showed a significant discrepancy (OR: 1.45 95% CI: 1.02–2.06 $I^2 = 0\%$ $P = 0.04$ **Figure 9B**), which may be impacted by the rate of surgical dislocation. Only Langlois (33) et al. compared reoperation rates for PA vs. AA, but no significant difference was reported.

Mortality

Mortality was examined in 17 studies with a total of 7,496 patients and 1,584 deaths. Numerous studies had variable follow-up times for mortality, including 1 month, 3 months, 6 months, 12 months and final mortality, and we adopted the use of most data with 1 year of follow-up for the analysis. There was no significant difference between the groups. The details are as follows, (OR: 0.78 95% CI: 0.52–1.17 $I^2 = 41\%$ $P = 0.24$ **Figure 10A**), (OR: 0.95 95% CI: 0.53–1.71 $I^2 = 0\%$ $P = 0.87$ **Figure 10B**), (OR: 1.00 95% CI: 0.88–1.13 $I^2 = 0\%$ $P = 0.99$ **Figure 1C**), respectively.

Clinical outcomes

For perioperative pain results, researchers have applied several kinds of scores, including the VAS score (5, 18, 20, 31, 34, 37), a modified Charnley pain score (19), pain numeric rating scale (PNRS) (36), and mean pain postop (NRS) (39) but none of the data could be analyzed in aggregate. In both the AA and PA studies, Pala and Neyisci concluded that the AA group was less painful and that the difference was statistically significant, but Langlois concluded that there was no difference between the groups. Renken (18) et al. and Saxer (5) et al. found that patients in the AA group suffered less pain at all time points than those in the LA group, which may be related to less surgical trauma in the AA group. The difference was that Renken derived a significant difference in pain late (16 days, 40 days), while Saxer considered it to be early (5 days). More importantly, Auffarth (20) arrived at the opposite idea from the two formers.

Hip function was evaluated with the Harris Hip Score (HHS) (20, 36, 45) and the Western Ontario and

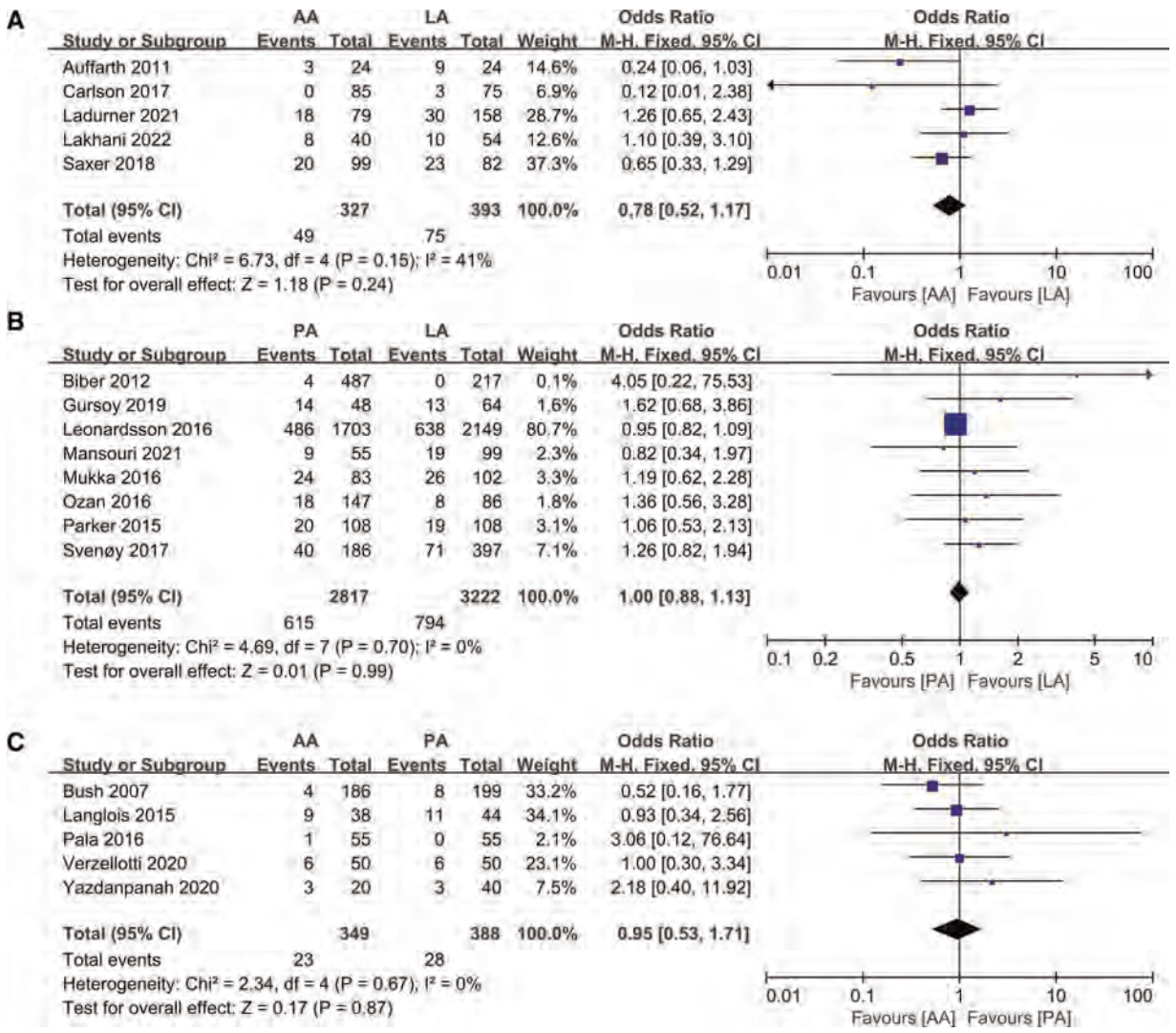

FIGURE 10
Forest plot comparison of mortality. (A) Anterior approach and lateral approach, (B) Posterior approach and lateral approach, (C) Posterior approach and anterior approach.

McMaster Universities Arthritis (WOMAC) (36) index, the University of California, Los Angeles (UCLA) (38) hip scoring assessment, but the number of available databases is insufficient and a meta-analysis of these results is also not feasible. In conclusion, no statistically significant differences were found in all studies, regardless of the functional scores. Lakhani (32) and Sayed-Noor (40) reported the problem of Trendelenburg gait after surgery, Lakhani found no cases of Trendelenburg gait in the DAA group after surgery, while three cases of Trendelenburg gait in the DLA group. Sayed-Noor et al. saw that Trendelenburg sign occurred in 37.5% (9/24) of patients after DL approach and 4% (1/24) of patients after PL approach, further analyzing the DL approach as a factor contributing to Trendelenburg gait.

Discussion

The different approaches of hemiarthroplasty for femoral neck fractures are used routinely in clinical situations, but their risks and benefits have been controversial. This review is aimed at providing objective theoretical evidence for clinical diagnosis and treatment through meta-analysis of their data. The outcomes revealed that the time of hospitalization was shorter in AA than in LA, and regarding complications, PA had a significantly higher subluxation hazard in comparison to LA and AA, and PA increased the incidence of reoperation than AA, all of which were statistically significant, with no significant differences seen in the remaining outcomes in all aspects that allowed for data analysis.

Heavy heterogeneity existed in clinical data regarding operative time, intraoperative blood loss, and length of

hospital stay ($I^2 > 75\%$), and we used a random-effects model analysis and discovered that AA had a longer length of stay than LA, which may be relevant to the surgical approach.

The AA operation is mostly carried out using the minimally invasive direct anterior approach (DAA), which reduces postoperative pain and allows for faster recovery by preserving the muscles during the approach to the hip joint (46–48), with minimal postoperative impact on hip mobility and daily life (39). Nevertheless, many reports have found a prolonged duration of surgery, although we did not analyze a significant difference (20, 32).

Dislocation was the most disparate outcome in the meta-analysis and an essential indicator for evaluating the results of the surgery. The PA is at greater risk of dislocation than the other two approaches and may be related to surgical incision of soft tissue anatomy such as the capsule, short external rotators, and piriformis (49).There may also be a relationship with patient cognitive status and sex, with some findings of higher dislocation rates in women and patients with cognitive impairment (29).

Patient reoperation was also statistically significant, and one of the major factors was dislocation of the hip on the patient's side of surgery. Some of the surgeries involved repair of the short external rotators with the posterior capsule to reduce the incidence of dislocation, but the efficacy is conflicting (29, 50). This is a shortcoming of PA and may lead the operator to prefer other modalities when choosing a surgical approach.

We did not undertake a meaningful statistical analysis to demonstrate which approach had less postoperative pain (5, 18, 37, 39), but the literature screened generally concluded that AA had better outcomes than PA and LA, which was related to surgical trauma. However, differently, Renken (18) et al. yielded a significant difference in pain between groups at the late stages (16 days, 40 days), whereas Saxer (5) found that the difference occurred at the early stage (5 days).

We can see that PA has more risk of dislocation and reoperation rate, which may be the primary factor for clinicians to avoid. Less of the length of hospitalization is beneficial for AA to be promoted in clinical practice, in addition, whether it can reduce postoperative pain, need to be validated and supported by more clinical trial data in the future.

Limitations

Although there are more data analyzed in this paper, the randomized controlled trials included in it are only 5, the rest are cohort studies, the quality of evidence is not high level. The double-blind control of these surgical randomization groups and investigators, patients, is comparatively weak, and the likelihood of breaching the blind is higher. Second, different types and manufacturers of prostheses were used for the surgery, and according to the patients' demand, cemented and noncemented prostheses were also employed, all of which had an impact on the experimental results, whereas we were unable to perform a statistical analysis. Third, we only searched common databases and failed to provide comprehensive coverage of published articles, and there were subjective influences of researchers in the selection process of articles, which may lead to the omission of any literature. Furthermore, the included literature reported data for the three approaches, and the number of some indicators was too limited for analysis. For common postoperative hip scores and pain, various scoring criteria used in different studies failed to be analyzed effectively, which is pivotal to the evaluation of the trial, and more literature reporting and unification of routine scoring scales would be more helpful for the study in the future.

Conclusion

Generally, the risk of dislocation was higher in PA than in the other two approaches, the odds of complications requiring reoperation were also higher in PA than in LA, and PA was not found to be superior to the other two approaches in other aspects. In terms of hospitalization time, AA was shorter than LA, and there was no difference between both in operation time, intraoperative blood loss, all sorts of complications, postoperative pain, and hip function. At present, AA is seemingly more successful, but its literature is limited and has higher heterogeneity. More qualitative literature and postoperative data reported in the future will facilitate the final determination of which approach is superior. The ultimate choice of the operation mode should be considered by the surgical operators based on a combination of factors.

Author contributions

LS: collected the data and completed the article. WH and DS: performed the data analysis. WF: made the graphs and tables. JJ and LJ: provided the topic selection and article review. All authors contributed to the article and approved the submitted version.

Funding

Basic and Clinical Cooperative Research Promotion Plan of Anhui Medical University (grant no.

2020xkjT040); Clinical Research cultivation Program of the Second Affiliated Hospital of Anhui Medical University (grant no. 2020LCZD20).

Acknowledgments

Thanks to LJ and JJ for their helpful suggestions on the article.

Conflict of interest

The authors declare that the research was conducted in the absence of any commercial or financial relationships that could be construed as a potential conflict of interest.

Publisher's note

All claims expressed in this article are solely those of the authors and do not necessarily represent those of their affiliated organizations, or those of the publisher, the editors and the reviewers. Any product that may be evaluated in this article, or claim that may be made by its manufacturer, is not guaranteed or endorsed by the publisher.

References

1. Veronese N, Maggi S. Epidemiology and social costs of hip fracture. *Injury*. (2018) 49(8):1458–60. doi: 10.1016/j.injury.2018.04.015

2. Cooper C, Campion G, Melton 3rd LJ. Hip fractures in the elderly: a world-wide projection. *Osteoporos Int*. (1992) 2(6):285–9. doi: 10.1007/bf01623184

3. Cha YH, Yoo JI, Kim JT, Park CH, Ahn YS, Choy WS, et al. Dual mobility total hip arthroplasty in the treatment of femoral neck fractures. *Bone Joint J*. (2020) 102(11):1457–66. doi: 10.1302/0301-620x.102b11.Bjj-2020-0610.R2

4. Li X, Luo J. Hemiarthroplasty compared to total hip arthroplasty for the treatment of femoral neck fractures: a systematic review and meta-analysis. *J Orthop Surg Res*. (2021) 16(1):172. doi: 10.1186/s13018-020-02186-4

5. Saxer F, Studer P, Jakob M, Suhm N, Rosenthal R, Dell-Kuster S, et al. Minimally invasive anterior muscle-sparing versus a transgluteal approach for hemiarthroplasty in femoral neck fractures-a prospective randomised controlled trial including 190 elderly patients. *BMC Geriatr*. (2018) 18(1):222. doi: 10.1186/s12877-018-0898-9

6. Chang JD, Kim IS, Lee SS, Yoo JH, Hwang JH. Unstable intertrochanteric versus displaced femoral neck fractures treated with cementless bipolar hemiarthroplasty in elderly patients; a comparison of 80 matched patients. *Orthop Traumatol Surg Res*. (2016) 102(6):695–9. doi: 10.1016/j.otsr.2016.04.007

7. Kain MS, Willier 3rd D. Hemiarthroplasty through a direct anterior approach for femoral neck fractures. *J Orthop Trauma*. (2020) 34:S25–s6. doi: 10.1097/bot.0000000000001820

8. Skowronek P, Wojciechowski A, Wypniewski K, Sibiński M, Polguj M, Maksymiuk-Kłos A, et al. Time efficiency of direct anterior hip arthroplasty compared to postero-lateral approach in elderly patients. *Arch Med Sci*. (2021) 17(1):106–12. doi: 10.5114/aoms/86185

9. Nakamura T, Yamakawa T, Hori J, Goto H, Nakagawa A, Takatsu T, et al. Conjoined tendon preserving posterior approach in hemiarthroplasty for femoral neck fractures: a prospective multicenter clinical study of 322 patients. *J Orthop Surg*. (2021) 29(3):23094990211063963. doi: 10.1177/23094990211063963

10. Ladurner A, Schöfl T, Calek AK, Zdravkovic V, Giesinger K. Direct anterior approach improves in-hospital mobility following hemiarthroplasty for femoral neck fracture treatment. *Arch Orthop Trauma Surg*. (2021):1–10. doi: 10.1007/s00402-021-04087-5

11. van der Sijp MPL, van Delft D, Krijnen P, Niggebrugge AHP, Schipper IB. Surgical approaches and hemiarthroplasty outcomes for femoral neck fractures: a meta-analysis. *J Arthroplasty*. (2018) 33(5):1617–27.e9. doi: 10.1016/j.arth.2017.12.029

12. Kunkel ST, Sabatino MJ, Kang R, Jevsevar DS, Moschetti WE. A systematic review and meta-analysis of the direct anterior approach for hemiarthroplasty for femoral neck fracture. *Eur J Orthop Surg Traumatol*. (2018) 28(2):217–32. doi: 10.1007/s00590-017-2033-6

13. Higgins JP, Altman DG, Gøtzsche PC, Jüni P, Moher D, Oxman AD, et al. The cochrane collaboration's tool for assessing risk of bias in randomised trials. *Br Med J*. (2011) 343:d5928. doi: 10.1136/bmj.d5928

14. Wan X, Wang W, Liu J, Tong T. Estimating the sample mean and standard deviation from the sample size, median, range and/or interquartile range. *BMC Med Res Methodol*. (2014) 14(1):1–13. doi: 10.1186/1471-2288-14-135

15. Hozo SP, Djulbegovic B, Hozo I. Estimating the mean and variance from the median, range, and the size of a sample. *BMC Med Res Methodol*. (2005) 5(1):13. doi: 10.1186/1471-2288-5-13

16. Bland M. Estimating mean and standard deviation from the sample size, three quartiles, minimum, and maximum. *Int J Stat Med Res*. (2015) 4(1):57–64. doi: 10.6000/1929-6029.2015.04.01.6

17. Verzellotti S, Candrian C, Molina M, Filardo G, Alberio R, Grassi FA. Direct anterior versus posterolateral approach for bipolar hip hemiarthroplasty in femoral neck fractures: a prospective randomised study. *Hip Int*. (2020) 30(6):810–7. doi: 10.1177/1120700019872117

18. Renken F, Renken S, Paech A, Wenzl M, Unger A, Schulz AP. Early functional results after hemiarthroplasty for femoral neck fracture: a randomized comparison between a minimal invasive and a conventional approach. *BMC Musculoskelet Disord*. (2012) 13:141. doi: 10.1186/1471-2474-13-141

19. Parker MJ. Lateral versus posterior approach for insertion of hemiarthroplasties for hip fractures: a randomised trial of 216 patients. *Injury*. (2015) 46(6):1023–7. doi: 10.1016/j.injury.2015.02.020

20. Auffarth A, Resch H, Lederer S, Karpik S, Hitzl W, Bogner R, et al. Does the choice of approach for hip hemiarthroplasty in geriatric patients significantly influence early postoperative outcomes? A randomized-controlled trial comparing the modified smith-petersen and hardinge approaches. *J Trauma*. (2011) 70(5):1257–62. doi: 10.1097/TA.0b013e3181eded53

21. Abram SG, Murray JB. Outcomes of 807 thompson hip hemiarthroplasty procedures and the effect of surgical approach on dislocation rates. *Injury*. (2015) 46(6):1013–7. doi: 10.1016/j.injury.2014.12.016

22. Baba T, Shitoto K, Kaneko K. Bipolar hemiarthroplasty for femoral neck fracture using the direct anterior approach. *World J Orthop*. (2013) 4(2):85–9. doi: 10.5312/wjo.v4.i2.85

23. Biber R, Brem M, Singler K, Moellers M, Sieber C, Bail HJ. Dorsal versus transgluteal approach for hip hemiarthroplasty: an analysis of early complications in seven hundred and four consecutive cases. *Int Orthop*. (2012) 36(11):2219–23. doi: 10.1007/s00264-012-1624-4

24. Bűcs G, Dandé Á, Patczai B, Sebestyén A, Almási R, Nöt LG, et al. Bipolar hemiarthroplasty for the treatment of femoral neck fractures with minimally invasive anterior approach in elderly. *Injury*. (2021) 52:S37–s43. doi: 10.1016/j.injury.2020.02.053

25. Bush JB, Wilson MR. Dislocation after hip hemiarthroplasty: anterior versus posterior capsular approach. *Orthopedics*. (2007) 30(2):138–44. doi: 10.3928/01477447-20070201-05

26. Carlson VR, Ong AC, Orozco FR, Lutz RW, Duque AF, Post ZD. The direct anterior approach does not increase return to function following hemiarthroplasty

for femoral neck fracture. *Orthopedics*. (2017) 40(6):e1055–e61. doi: 10.3928/01477447-20170925-08

27. de Vries EN, Gardenbroek TJ, Ammerlaan H, Steenstra F, Vervest A, Hogervorst M, et al. The optimal approach in hip hemiarthroplasty: a cohort of 1,009 patients. *Eur J Orthop Surg Traumatol*. (2020) 30(4):569–73. doi: 10.1007/s00590-019-02610-4

28. Enocson A, Tidermark J, Tornkvist H, Lapidus LJ. Dislocation of hemiarthroplasty after femoral neck fracture: better outcome after the anterolateral approach in a prospective cohort study on 739 consecutive hips. *Acta Orthop*. (2008) 79(2):211–7. doi: 10.1080/17453670710014996

29. Gursoy S, Simsek ME, Akkaya M, Dogan M, Bozkurt M. Transtrochanteric approach can provide better postoperative care and lower complication rate in the treatment of hip fractures. *Clin Interv Aging*. (2019) 14:137–43. doi: 10.2147/cia.S194880

30. Hongisto MT, Nuotio MS, Luukkaala T, Väistö O, Pihlajamäki HK. Lateral and posterior approaches in hemiarthroplasty. *Scand J Surg*. (2018) 107(3):260–8. doi: 10.1177/1457496917748226

31. Kristensen TB, Vinje T, Havelin LI, Engesæter LB, Gjertsen JE. Posterior approach compared to direct lateral approach resulted in better patient-reported outcome after hemiarthroplasty for femoral neck fracture. *Acta Orthop*. (2017) 88(1):29–34. doi: 10.1080/17453674.2016.1250480

32. Lakhani K, Mimendia I, Porcel JA, Martín-Domínguez LA, Guerra-Farfán E, Barro V. Direct anterior approach provides better functional outcomes when compared to direct lateral approach in hip hemiarthroplasty following femoral neck fracture. *Eur J Orthop Surg Traumatol*. (2022) 32(1):137–43. doi: 10.1007/s00590-021-02941-1

33. Langlois J, Delambre J, Klouche S, Faivre B, Hardy P. Direct anterior hueter approach is a safe and effective approach to perform a bipolar hemiarthroplasty for femoral neck fracture: outcome in 82 patients. *Acta Orthop*. (2015) 86(3):358–62. doi: 10.3109/17453674.2014.1002987

34. Leonardsson O, Rolfson O, Rogmark C. The surgical approach for hemiarthroplasty does not influence patient-reported outcome: a national survey of 2118 patients with one-year follow-up. *Bone Joint J*. (2016) 98(4):542–7. doi: 10.1302/0301-620x.98b4.36626

35. Mansouri-Tehrani MM, Yavari P, Pakdaman M, Eslami S, Nourian SMA. Comparison of surgical complications following hip hemiarthroplasty between the posterolateral and lateral approaches. *Int J Burns Trauma*. (2021) 11(5):406–11.

36. Mukka S, Mahmood S, Kadum B, Sköldenberg O, Sayed-Noor A. Direct lateral vs posterolateral approach to hemiarthroplasty for femoral neck fractures. *Orthop Traumatol Surg Res*. (2016) 102(8):1049–54. doi: 10.1016/j.otsr.2016.08.017

37. Neyisci C, Erdem Y, Bilekli AB, Bek D. Direct anterior approach versus posterolateral approach for hemiarthroplasty in the treatment of displaced femoral neck fractures in geriatric patients. *Med Sci Monit*. (2020) 26:e919993. doi: 10.12659/msm.919993

38. Ozan F, Oncel ES, Koyuncu S, Gurbuz K, Dogar F, Vatansever F, et al. Effects of hardinge versus moore approach on postoperative outcomes in elderly patients with hip fracture. *Int J Clin Exp Med*. (2016) 9(2):4425–31.

39. Pala E, Trono M, Bitonti A, Lucidi G. Hip hemiarthroplasty for femur neck fractures: minimally invasive direct anterior approach versus postero-lateral approach. *Eur J Orthop Surg Traumatol*. (2016) 26(4):423–7. doi: 10.1007/s00590-016-1767-x

40. Sayed-Noor AS, Hanas A, Sköldenberg OG, Mukka SS. Abductor muscle function and trochanteric tenderness after hemiarthroplasty for femoral neck fracture. *J Orthop Trauma*. (2016) 30(6):e194–e200. doi: 10.1097/bot.0000000000000532

41. Sierra RJ, Schleck CD, Cabanela ME. Dislocation of bipolar hemiarthroplasty: rate, contributing factors, and outcome. *Clin Orthop Relat Res*. (2006) 442:230–8. doi: 10.1097/01.blo.0000183741.96610.c3

42. Svenøy S, Westberg M, Figved W, Valland H, Brun OC, Wangen H, et al. Posterior versus lateral approach for hemiarthroplasty after femoral neck fracture: early complications in a prospective cohort of 583 patients. *Injury*. (2017) 48(7):1565–9. doi: 10.1016/j.injury.2017.03.024

43. Tsailas PG, Argyrou C, Valavanis A. Management of femoral neck fractures with the almis approach in elderly patients: outcomes compared to posterior approach. *Injury*. (2021) 52(12):3666–72. doi: 10.1016/j.injury.2021.06.036

44. Tsukada S, Wakui M. Minimally invasive intermuscular approach does not improve outcomes in bipolar hemiarthroplasty for femoral neck fracture. *J Orthop Sci*. (2010) 15(6):753–7. doi: 10.1007/s00776-010-1541-6

45. Yazdanpanah P, Mohammadi H. Short-term complications of hip bipolar hemiarthroplasty with anterior approach in patients with femoral neck fracture admitted to the emergency department of yasuj shahid beheshti hospital in 2016–2018. *Rev Latinoam*. (2020) 14(2):150–3. doi: 10.5281/zenodo.4074702

46. Alecci V, Valente M, Crucil M, Minerva M, Pellegrino CM, Sabbadini DD. Comparison of primary total hip replacements performed with a direct anterior approach versus the standard lateral approach: perioperative findings. *J Orthop Traumatol*. (2011) 12(3):123–9. doi: 10.1007/s10195-011-0144-0

47. Zawadsky MW, Paulus MC, Murray PJ, Johansen MA. Early outcome comparison between the direct anterior approach and the mini-incision posterior approach for primary total hip arthroplasty: 150 consecutive cases. *J Arthroplasty*. (2014) 29(6):1256–60. doi: 10.1016/j.arth.2013.11.013

48. Moskal JT, Capps SG, Scanelli JA. Anterior muscle sparing approach for total hip arthroplasty. *World J Orthop*. (2013) 4(1):12–8. doi: 10.5312/wjo.v4.i1.12

49. Kwon MS, Kuskowski M, Mulhall KJ, Macaulay W, Brown TE, Saleh KJ. Does surgical approach affect total hip arthroplasty dislocation rates? *Clin Orthop Relat Res*. (2006) 447:34–8. doi: 10.1097/01.blo.0000218746.84494.df

50. Macaulay W, Colacchio ND, Fink LA. Modified enhanced posterior soft tissue repair results in a negligible dislocation rate after hip resurfacing. *Oper Tech Orthop*. (2009) 19(3):163–8. doi: 10.1053/j.oto.2009.07.005

frontiers | Frontiers in Surgery

TYPE Original Research
PUBLISHED 06 January 2023
DOI 10.3389/fsurg.2022.885669

Check for updates

OPEN ACCESS

EDITED BY
Paphon Sa-ngasoongsong,
Mahidol University, Thailand

REVIEWED BY
Lin Zheng,
Zhejiang University, China
Freeman Miller,
Alfred I. duPont Hospital for Children, United States

*CORRESPONDENCE
Wendan Cheng
sunyccc@126.com
Chang Liu
32213241@qq.com

†These authors have contributed equally to this work and share first authorship

SPECIALTY SECTION
This article was submitted to Orthopedic Surgery, a section of the journal Frontiers in Surgery

RECEIVED 28 February 2022
ACCEPTED 02 November 2022
PUBLISHED 06 January 2023

CITATION
Guo H, Zhao Y, Gao L, Wang C, Shang X, Fan H, Cheng W and Liu C (2023) Treatment of avulsion fracture of posterior cruciate ligament tibial insertion by minimally invasive approach in posterior medial knee.
Front. Surg. 9:885669.
doi: 10.3389/fsurg.2022.885669

COPYRIGHT
© 2023 Guo, Zhao, Gao, Wang, Shang, Fan, Cheng and Liu. This is an open-access article distributed under the terms of the Creative Commons Attribution License (CC BY). The use, distribution or reproduction in other forums is permitted, provided the original author(s) and the copyright owner(s) are credited and that the original publication in this journal is cited, in accordance with accepted academic practice. No use, distribution or reproduction is permitted which does not comply with these terms.

Treatment of avulsion fracture of posterior cruciate ligament tibial insertion by minimally invasive approach in posterior medial knee

Huihui Guo[1,2†], Yao Zhao[2†], Liang Gao[3], Chen Wang[2], Xianbo Shang[2], Haitao Fan[4], Wendan Cheng[2*] and Chang Liu[5*]

[1]Fuyang People's Hospital, Fuyang, China, [2]Department of Orthopedics, The Second Affifiliated Hospital of Anhui Medical University, Hefei, China, [3]Center for Clinical Medicine, Huatuo Institute of Medical Innovation (HTIMI), Berlin, Germany, [4]Anhui Medical University, Fuyang, China, [5]Anhui Armed Police General Hospital, Hefei, China

Objective: The study aims to explore the feasibility and clinical effect of posterior minimally invasive treatment of cruciate ligament tibial avulsion fracture.

Methods: Posterior knee minimally invasive approach was used to treat avulsion fracture of posterior cruciate ligament (PCL) tibia in 15 males and 11 females. The length of the incision, intraoperative blood loss, operation time, postoperative hospital stay, residual relaxation, and fracture healing time were analyzed to evaluate the curative effect, learning curve, and advantages of the new technology. Neurovascular complications were recorded. During the postoperative follow-up, the International Knee Joint Documentation Committee (IKDC), Lysholm knee joint score, and knee joint range of motion were recorded to evaluate the function.

Results: All 26 patients were followed up for 18–24 months, with an average of 24.42 ± 5.00 months. The incision length was 3–6 cm, with an average of 4.04 ± 0.82 cm. The intraoperative blood loss was about 45–60 ml, with an average of 48.85 ± 5.88 ml. The operation time was 39–64 min, with an average of 52.46 ± 7.64 min. The postoperative hospital stay was 2–5 days, with an average of 2.73 ± 0.87 days. All incisions healed grade I without neurovascular injury. All fractures healed well with an average healing time of 9.46 ± 1.33 weeks (range, 8–12 weeks). The Lysholm score of the affected knee was 89–98 (mean, 94.12 ± 2.49) at 12-month follow-up. The IKDC score was 87–95 with an average of 91.85 ± 2.19, and the knee range of motion was 129–148° with an average of 137.08 ± 5.59°. The residual relaxation was 1–3 mm, with an average of 1.46 ± 0.65 mm.

Conclusion: This minimally invasive method provides sufficient exposure for internal fixation of PCL tibial avulsion fractures without the surgical complications associated with traditional open surgical methods. The process is safe, less invasive, and does not require a long learning curve.

KEYWORDS

minimally invasive, posterior cruciate ligament, avulsion fracture, clinical effects, technique

Background

As the most complicated joint of human body, the stability of knee joint depends on the surrounding ligaments to a great extent. Posterior cruciate ligament (PCL) is the necessary ligament to maintain the stability of the knee joint, and it is also the main limiting factor to prevent excessive posterior tibial movement. Its fracture and injury will greatly affect the stability of the knee joint (1).

PCL injury accounts for 3%–44% of acute knee joint injuries and is often accompanied by other ligament injuries (2–4). The avulsion fracture of PCL is a kind of knee joint injury, which can easily lead to instability of knee joint and accelerate the long-term degeneration of knee joint. The avulsion fracture of the tibia is usually caused by high-energy injuries, which are common in motorcycle accidents (5, 6). At this time, the knee joint is in a bent position or in an overextended position. If the upper end of the tibia is subjected to violence from front to back, the tension on the PCL will easily exceed its tolerance limit, which will lead to injuries such as PCL fracture. Due to the anatomical characteristics of PCL tibial attachment points, some of them are located outside the joint cavity. When the avulsion fracture of PCL tibial insertion occurs, the fracture end is often embedded in the joint capsule and surrounding soft tissues, which makes it difficult to reduce the fracture by manipulation. If the torn pieces are not displaced, nonsurgical treatment can be recommended. At present, it is considered that the main treatment for avulsion fracture of displaced PCL tibial insertion is surgical treatment to restore PCL function and knee stability (7, 8), and avulsion fracture of PCL tibial attachment is considered an indication of surgical reduction and internal fixation (9). The main surgical treatments include open reduction and internal fixation (10–13) and arthroscopic reduction and internal fixation (14–16). Although there are many case series published on the management and outcomes of PCL avulsion fractures, no optimal surgical management has been suggested (5, 17). This paper attempts to find a simpler and minimally invasive method to treat PCL tibial avulsion fracture, which does not need to dissect the surrounding soft tissues layer by layer, and at the same time better protect the surrounding muscles and blood vessels and nerves. We intend to use this new minimally invasive approach to fix PCL tibial avulsion fracture, which has been successfully applied to 26 patients. The effectiveness, safety, and advantages of this method are analyzed by using the results measurement method of clinician's specialist evaluation and patient report.

Clinical data

General information

From January 2015 to January 2020, 26 cases of PCL tibial avulsion fracture were studied retrospectively at the orthopaedics departments of both Second Affiliated Hospital of Anhui Medical University and Anhui Armed Police General Hospital, Hefei, China. After all patients were admitted to the hospital, routine biochemical and physical examinations were completed, and their physical condition and surgical tolerance were fully evaluated. Lachman test and back drawer test were positive before operation; and x-ray, computed tomography (CT) scanning + three-dimensional reconstruction, and magnetic resonance imaging (MRI) (**Figure 1**) examination of the knee joint of the affected limb were improved, so as to facilitate the evaluation of fracture size and the selection of internal fixation devices during operation. The consent of patients and their families was obtained before operation.

Inclusion criteria

(1) Fresh PCL tibial avulsion fracture (fracture within 3 weeks);
(2) Lachman test and back drawer test were positive before operation;
(3) Meyers–McKeever II and III, and preoperative CT measurements of fracture block size can be fixed by hollow lag screws;
(4) Knee joint function was good before injury;
(5) Follow-up for more than 12 months, complete imaging data; and
(6) The images obtained showed that the mean fracture displacement of PCL was ≥6.7 mm (18).

Exclusion criteria

(1) Patients with anterior cruciate ligament, collateral ligament, and meniscus injury;
(2) Preoperative MRI showed PCL rupture;
(3) Osteoarthritis with previous joint dysfunction, history of knee joint trauma or Kellgren–Lawrence grade ≥2;
(4) Patients with distal femur or proximal tibia fracture; and
(5) Preoperative surgical evaluation, patients with severe heart, respiratory, and other medical diseases who cannot be operated on.

Surgical technique

All of the patients were operated on by three senior orthopedic surgeons of the same team. General anesthesia was used as the anesthesia method. After satisfactory anesthesia, an electric pneumatic tourniquet was tied in the prone position at the root of the thigh of the affected limb. The pressure of the tourniquet was set at 280 mmHg, and the knee joint was flexed from 30° to 45° to fully relax the medial gastrocnemius muscle.

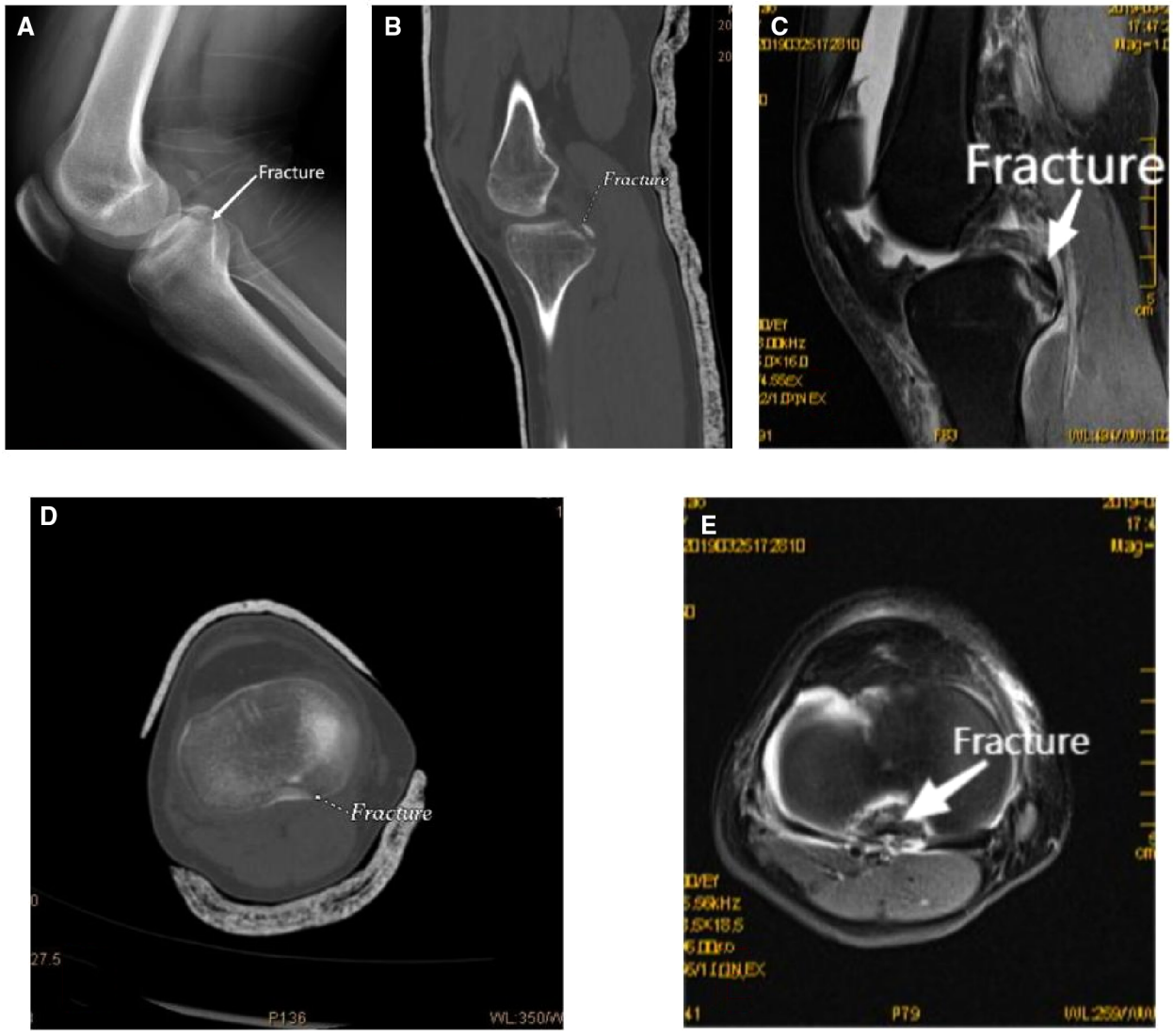

FIGURE 1
Preoperative x-ray, CT, and MRI of the patient [(B,C) sagittal view; (D,E) transverse view]. CT, computed tomography; MRI, magnetic resonance imaging.

Before the operation, a 3–4 cm surgical mark was made along the medial margin of the gastrocnemius muscle from 1 to 2 cm above the popliteal stria; routine disinfection and towel laying were performed. A 3–4 cm incision was performed from the medial side of the popliteal stria along with the preoperative surgical incision mark. The medial margin of the medial head of the gastrocnemius muscle was determined. The anatomical gap between the medial head of the gastrocnemius muscle and the semitendinosus muscle was bluntly dissected with fingers, and the lateral margin of the medial head of the gastrocnemius muscle was bluntly separated from the semitendinosus muscle. The medial head of the gastrocnemius muscle and the vascular nerve in popliteal fossa were pulled outward with a thyroid hook, and the semimembrane muscle and semitendinosus muscle were pulled medially. At this time, the thick muscle belly could play a role in protecting the vascular nerve structure, and no pressure was directly applied to the vascular nerve during the operation. Therefore, dissection of the protected medial popliteal fossa is relatively safe. Until the posterior congestion and swelling of the joint capsule are exposed, the avulsion fracture fragment could be seen by a longitudinal incision of the joint capsule, and the fracture fragment was lifted along with the PCL. The surgical site was fully washed with normal

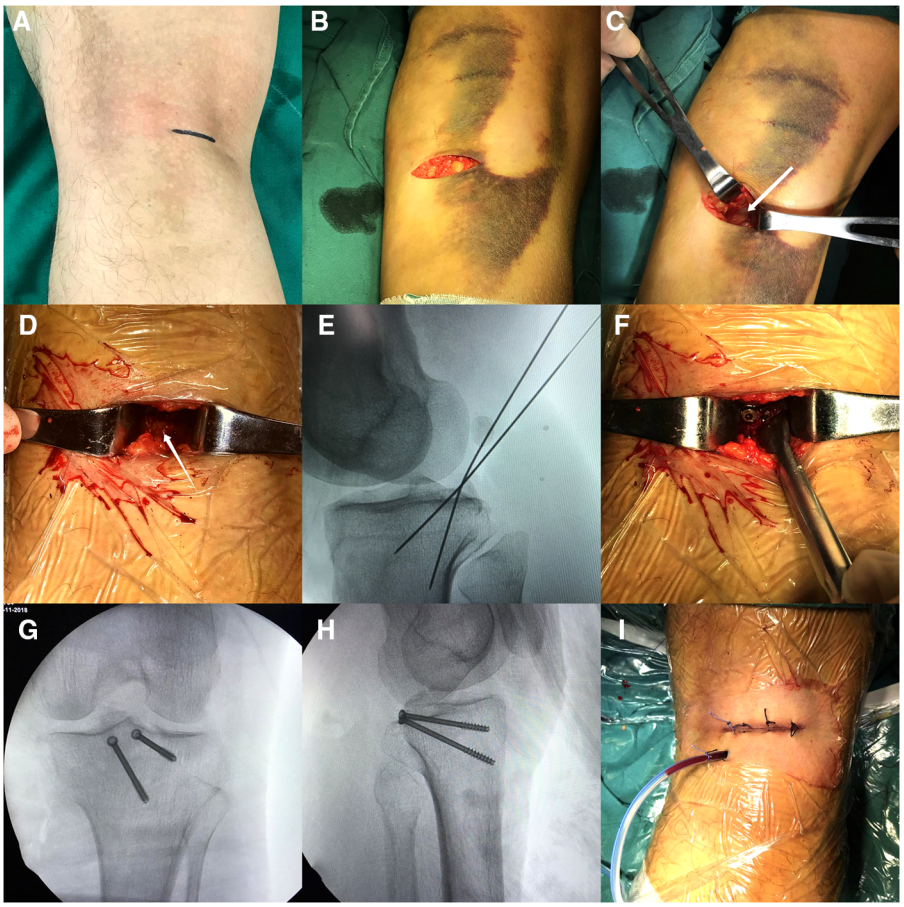

FIGURE 2
(A–C) A 3–4 cm surgical incision was performed along the preoperative marker, the gastrocnemius muscle's medial head was separated, and the joint capsule was fully exposed by pulling outward. (D–F) The joint capsule was cut open, washed, the fracture block was reduced, and the Kirschner wire was used for temporary fixation. Cannulated lag screws were used for fixation after the fracture was well positioned in fluoroscopic position. (G–I) The intraoperative fluoroscopic anterolateral x-ray film was satisfactory, and the incision was closed layer by layer after rinsing and inserting the drainage tube.

saline, the surrounding soft tissue embedded in the fracture fragment was cleaned, and the fracture fragment was reduced to the bone bed. 1–2 Kirschner wires were vertically placed at the upper edge of the bone bed, and the direction and depth of the Kirschner wires were visualized to avoid damage to the surrounding articular cartilage. When the direction and position were good, 1–2 hollow lag screws with a diameter of 4.0 mm and partial thread were used for fixation according to the size of the fracture block during the operation. Spacers can be used according to the intraoperative conditions. After the fluoroscopic position and depth of the C-arm machine were good during the operation, the incision was sutured layer by layer after a drainage tube was inserted (Figure 2). An illustration of surgical anatomy of PCL tibial avulsion fracture is shown in Figure 3. The knee joint of the affected limb was fixed at a flexion position of 30°–45° using a functional adjustable knee brace.

Postoperative treatment and rehabilitation

Antibiotics were routinely used once within 24 h after operation to prevent infection. A functional adjustable knee brace was used to fix the knee joint of the affected limb at a flexion position of 30°–45°, and a cotton pad was used to prevent posterior displacement of the tibia. After returning to the ward, the patient was encouraged to start ankle pump exercise, quadriceps femoris contraction, and other functional exercises, and straight leg elevation training was performed 1 day after surgery. Passive knee flexion range of motion (0°–60°) was completed within 3 weeks after operation. At 4–6 weeks after surgery, the patient was in active flexion (0°–90°) in the prone position. After 8 weeks, normal knee movement can be restored, and the knee brace of the affected limb can be removed. During the first 4 weeks after surgery,

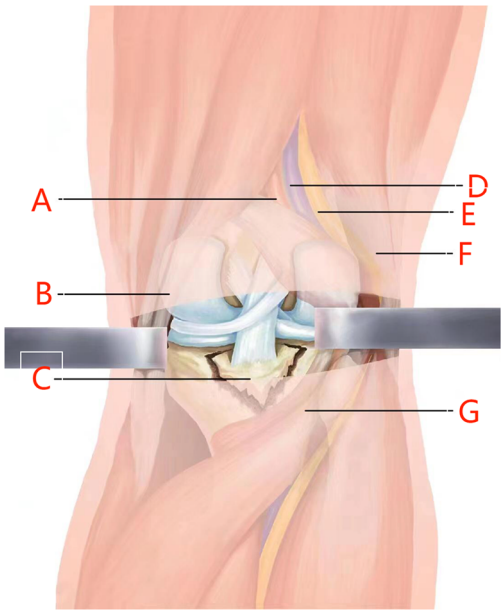

FIGURE 3
Illustration of surgical anatomy of PCL tibial avulsion fracture. [(A) Popliteal artery; (B) semitendinosus muscle; (C) avulsion fracture of posterior cruciate ligament; (D) popliteal vein; (E) tibial nerve; (F) long head of biceps femoris; (G) medial head of gastrocnemius muscle]. PCL, posterior cruciate ligament.

toe contact or partial weight bearing on the leg was allowed, and physical therapy for knee mobility was initiated. Full weight bearing was permitted only after radiographs showed good evidence of bone healing. After 2–3 months, when sufficient strength, knee joint range of motion (KROM), and proprioceptive skills are restored, return to heavy strength or competitive physical activity is limited. The minimally invasive approach group could be exercised as early as the patient could tolerate. A regular monthly x-ray examination was performed to observe whether avulsion fracture of the affected limb reached the clinical healing standard. IKDC score, Lysholm score, and KROM score were recorded for the first time and each time after operation to evaluate the improvement of knee joint function and stability of the affected limb.

Observation index

The Lachman test and posterior drawer test were observed after limb surgery. Patients were followed up at 4 weeks, 6 weeks, 2 months, 3 months, and every month thereafter, during which the affected limb was evaluated using the IKDC form and the Lysholm scale. The range of motion and residual relaxation of the knee were measured. All clinical evaluations were performed by two independent observers who were blinded to the surgical procedure. The IKDC score, Lysholm score, knee range of motion, and residual relaxation of the affected limb at 1 year after operation were analyzed to evaluate the recovery of the affected limb.

Statistical methods

For data analysis, the statistical software Spss23.0 was used. Measurement data with a normal distribution were expressed as mean standard deviation, and the *t*-test was used to compare the Lysholm score, IKDC score, and residual relaxation between preoperative and postoperative patients. $P < 0.05$ indicates statistical significance between the two groups, which is used to assess the clinical efficacy of surgery.

Results

All the operations were successfully completed, and the incision was healed at stage I. There were no complications such as incision infection, intra-articular infection, joint fibrosis, deep vein thrombosis, and fracture nonunion. The drawer test after Lachman test was negative, and the knee stability recovered well after operation. All 26 patients were followed up 18–24 months, with an average of 24.42± 5.01 months. The incision length was 3–6 cm, with an average of 4.04 ± 0.82 cm. The intraoperative blood loss was about 45–60 ml, with an average of 48.85 ± 5.88 ml. The operation time was 39–64 min, with an average of 52.46 ± 7.64 min. The postoperative hospital stay was 2–5 days, with an average of 2.73 ± 0.87 days. All fractures healed 8–12 weeks, with an average healing time of 9.46 ± 1.33 weeks (**Table 1**).

The Lysholm score of the affected knee was 89–98 (mean 94.12 ± 2.49) at 1 year follow-up. The IKDC score was 87–95 with an average of 91.85 ± 2.19, and the KROM was 129°–148° with an average of 137.08 ± 5.59°, which was statistically significant compared with that before surgery ($P < 0.05$) (**Table 2**).

Discussion

The aim of this study was to explore a new, minimally invasive, and safe surgical method for tibial PCL avulsion fracture that could fully expose the field of vision in a safer way without requiring large incisions, reduce the dissection and treatment of the surrounding muscle tissue, and avoid damage to the surrounding vascular and nerve systems.

The strength of the PCL is about twice that of the ACL, and it is considered to be the strongest ligament in the knee joint, which plays an important role in the stability of the joint (19). The incidence of PCL rupture is lower than that of other

TABLE 1 Summary of general patient characteristics

Parameter	
Numbers of male: female patients	15:11
Age (years)	32.12 (22–55)
Interval from injury to surgery (day)	4.92 ± 1.32 (3–7)
Postoperative hospital stay	2.73 ± 0.87 (2–5)
Surgery time (min)	54.46 ± 7.64 (39–64)
Follow-up (months)	24.42 ± 5.01 (18–36)
Postoperative KROM (°)	137.08 ± 5.59 (129–148)
Fracture union time (week)	9.46 ± 1.33 (8–12)
Intraoperative blood (ml)	48.85 ± 5.88 (45–60)

KROM, knee joint range of motion.

TABLE 2 Comparison of preoperative and postoperative knee function in minimally invasive approach.

Parameter	Preoperative	1 year postoperative	*T*-value	*P*-value
Lysholm	35.85 ± 1.22	94.12 ± 2.49	−53.402	0.000
IKDC	40.58 ± 4.41	91.85 ± 2.19	−128.760	0.000
Instability	10.73 ± 3.33	1.46 ± 0.65	14.300	0.000

IKDC, International Knee Joint Documentation Committee.

ligaments, which is related to its strong fibrous structure (20). PCL tibial avulsion fracture is a special form of PCL injury that is relatively rare compared with typical PCL tear (17, 21). The treatment of PCL tibial avulsion fracture is mainly divided into conservative treatment and surgical treatment. Zhao et al. believed that nonsurgical treatment can be successfully used for fractures with displacement less than 5 mm (22). Yoon et al. found that conservative treatment could achieve satisfactory results when the displacement of a simple PCL avulsion fracture was less than 6.7 mm (18). Although these conservative treatments have achieved good results, there are many complications in the late stages of the conservative treatment of displaced PCL tibial avulsion fractures, which are easy to lead to knee instability, severe mobility limitation, and knee degeneration. In order to prevent instability and further degenerative changes, early operation should be performed (23–25).

At present, the surgical options for PCL tibial avulsion fracture mainly include arthroscopic repair and open reduction and internal fixation. According to certain studies, the clinical efficacy of open approach and arthroscopic fixation of PCL tibial avulsion fractures is comparable (23, 26, 27). Since the use of arthroscopic surgery was first reported in 1995, with the progress of arthroscopic technology, arthroscopic treatment of PCL tibial avulsion fractures has been widely concerned (4, 28, 29). Although arthroscopic technology provides a minimally invasive technique and can be used in the same environment to handle any accompanying advantage of the meniscus, the synovial membrane and the surrounding ligament injury (14, 29–31), on the contrary, in addition to the requirements of technical and logical reasoning, it shows a higher rate of arthrofibrosis, longer operation time, high technical requirements, a long learning curve, the need for a specific device. In contrast to the open technique, it is not possible to see the avulsion fragment directly. In addition, arthroscopic reduction and fixation are more challenging than open surgery (32, 33).

Previous studies have reported a variety of surgical methods for tibial PCL avulsion fractures. Burks and Schaffer first described in 1990 a simplified retrogenicular inverted "L" approach that has become the standard open surgical approach for avulsion fractures of the PCL. The incision of this surgical approach is large and easy to damage the blood vessels and nerves (34). Nicandri et al. describe the "S" shape incision, this is a kind of improved after into the road, intraoperative do not need to remove gastrocnemius. However, this operation requires the separation and ligation of popliteal nerves, blood vessels, and muscles to find the fracture end, which increases the difficulty of the operation and postoperative complications (35).

This study's clinical results are comparable with those of recent studies that used different methods and techniques. The average operation time in this study was 54.46 ± 7.34 min, the average fracture union time was 9.46 ± 1.33 weeks, average Lysholm score was 94.12 ± 2.49, and average IKDC score was 91.85 ± 2.19. All patients' functional knee range of motion was restored, including full extension with a flexion of 137.08 ± 5.59° and an average residual relaxation of 1.46 ± 0.65 mm. Khalifa et al. described 31 cases involving a small set plate and plate fixation *via* an open "S" approach. Lysholm score was 93.4 ± 3.9. The knee flexion was 120.7°, which allowed for full extension. The incision was large, and there was significant vascular and nerve damage in the popliteal fossa (10). Bi et al. reported 15 cases of three-channel arthroscopic surgery involving autologous tendon transplantation, TightRope, and interference screw fixation. Lysholm's score was 94.25 ± 3.32. The residual relaxation was 1.08 ± 0.86 mm, and IKDC score was 91.13 ± 3.78. This arthroscopic surgery causes little trauma and can repair joint tissue damage. However, the operation is difficult and requires special instruments, which are difficult to obtain in primary care hospitals (36). Among the 36 patients described by Hao et al., 20 were treated with a self-made hook plate posterior medial inverted "L" approach and 16 with an EndoButton under arthroscopy. The inverted "L" approach took 57.80 ± 5.60 min to complete. Fracture union took 11.05 ± 2.21 weeks, Lysholm score was 95.50 ± 3.19, and the knee flexion was 134.80 ± 4.94°. The arthroscopic operation took 67.81 8.69 min, the fracture union time was 11.88 ± 2.25 weeks, Lysholm score was 95.19 ± 2.61, and the knee flexion was

131.44 ± 7.30°. The clinical efficacy of the traditional approach and arthroscopy were compared in this study. There were no significant differences in fracture healing time, Lysholm score, or knee flexion between the two groups at the last follow-up, but the operation time of the traditional approach group was significantly shorter than that of the arthroscopy group, and the difference was statistically significant. In this study, there was no significant difference in fracture healing time, Lysholm score, or knee flexion operation time when compared with the traditional inverted "L" approach. However, in our study, the surgical incision was smaller, the postoperative appearance was more attractive, the damage to the surrounding soft tissues was less severe, and the patients were able to exercise sooner (12). Gavaskar et al. described 22 patients whose surgical methods were similar to those used in this study, including the use of a small incision behind the knee. The difference was that Gavaskar et al. used a C-arm machine for fluoroscopic positioning prior to surgery to improve the accuracy of the incision position. The use of a 2-cm-wide Langenbeck retractor to separate the popliteal vascular and nerve bundles during surgery resulted in better visual field exposure and a shorter operation time (mean, 40 min), which is worth learning. However, the researchers separated the vascular and nerve bundles from the popliteal fossa, which could cause damage (37).

In this study, through a small transverse incision, the natural muscle gap between the medial head of the gastrocnemius muscle and the semitendinosus muscle was separated, and the vascular nerve bundle at the popliteal fossa was pulled to the lateral side together, thus avoiding the injury of the vascular nerve during operation. The operation can be performed under direct vision, which is beneficial to the reduction of the fracture block. In this study, the length of the incision and the degree of satisfaction with the scar after the operation are obviously better than those of a traditional operation. The operation time was not obviously prolonged (10), and the operation time may be further shortened for senior orthopedic surgeons as the operation progresses. Compared with arthroscopy, the operation time was significantly reduced (38). As with other surgical approaches, after operation, IKDC score, Lysholm score, knee joint mobility, and residual relaxation were significantly improved (31, 39).

In the treatment of PCL tibial avulsion fracture by minimally invasive small incision behind the knee, the following experiences are obtained in combination with literature and clinical practice: (1) for the displaced PCL tibial avulsion fracture, the operation should be performed as soon as possible, the limb swelling is light, the hierarchy is clear, and the reduction is easy. (2) The surgical incision should be 3–4 cm, which is too small for exposure, easy to cause tissue damage when pulling, and difficult to adjust the direction when inserting guide wire. (3) It is difficult to detect the meniscus, anterior cruciate ligament, and other structural injuries in this incision, so x-ray, CT, MRI, and other related examinations should be completed before operation. (4) Hollow screws were used for fixation, and three-dimensional CT reconstruction was performed as far as possible to determine the size and displacement direction of the avulsion bone block. Postoperatively, adjustable chuck knee brace was used for fixation. (5) When separating deep soft tissue, blunt separation with fingers was used to avoid injury to the popliteal vascular and nerve bundles, and the level and deep structure of separation could be sensed at the same time. (6) When inserting the guide wire, the operation should be strictly standardized, and the protective coat should be used to prevent tissue involvement and damage to the blood vessels and nerves; the direction of screw placement should be perpendicular to the fracture surface, so as to make the pressure between bone blocks. (7) The bone should be anatomically repositioned, and the PCL should be anatomically repositioned to prevent ligament relaxation. (8) Screw into the need to grasp the strength, enough; if the bone is broken, the tooth gasket can be used to transform the crushed bone into a whole for processing and increase the fixed holding force.

There are numerous flaws in this study, including a short patient follow-up period and a lack of clinical data on the long-term prognosis of this treatment regimen. The research sample is small, and the evidence level of the present study is too low to provide specific clinical treatment guidance. The lack of a control group makes it difficult to explain the technique's benefits and drawbacks; this incision makes it difficult to complete the exploration and repair of other knee structures. Because the size of the fracture fragment was not taken into account during fixation, some smaller bone pieces were unable to be fixed with cannulated lag screws. Smaller fracture pieces can be repaired and reduced using anchors (40), sutures (41, 42), steel wires (11), and specific plates (12, 43).

In addition, the procedure can be difficult for obese or muscular patients because the technique requires the surgeon to open the gastrocnemius muscle to expose the fractured end. If exposure is difficult, the incision may need to be widened or the traditional procedure changed.

Conclusion

This study describes a technique that can be used to complete the internal fixation of tibial PCL avulsions. It uses a minimally invasive approach to the knee joint's posteromedial interval that does not involve separation of the popliteal nerve or blood vessels. In addition, the technique can be applied in source-constrained or smaller hospitals that are not equipped with arthroscopy technology.

Data availability statement

The original contributions presented in the study are included in the article/**Supplementary Material**, further inquiries can be directed to the corresponding author.

Ethics statement

The studies involving human participants were reviewed and approved by Ethics Committee and the review board of the Second Affiliated Hospital of Anhui Medical University. The patients/participants provided their written informed consent to participate in this study. Written informed consent was obtained from the individual(s) for the publication of any potentially identifiable images or data included in this article.

Author contributions

HG is responsible for writing the thesis. HG and YZ are responsible for the main operation. WC and HF put forward surgical ideas. WC and XS are responsible for collecting and processing data. LG polish the paper. LC put forward a lot of suggestions for the later article modification, the deficiencies of the surgical methods and the places to be improved. All authors contributed to the article and approved the submitted version.

Funding

This study was supported by the Hefei independent innovation policy "Borrow-transfersupplement" project (J2020Y07), Functional limb salvage of diabetic foot (2020byzd347), Masquelet technique combined with transverse bone transfer technique for the treatment of refractory Wagner III and IV diabetic foot (FY2021-027) and tibial periosteum lateral extension for Wagner III and IV diabetic foot in a multidisciplinary collaborative mode (2022xkj225). The funders had no role in the study design, data collection and analysis, in the decision to publish, or in the preparation of the manuscript.

Conflict of interest

The authors declare that the research was conducted in the absence of any commercial or financial relationships that could be construed as a potential conflict of interest.

Publisher's note

All claims expressed in this article are solely those of the authors and do not necessarily represent those of their affiliated organizations, or those of the publisher, the editors and the reviewers. Any product that may be evaluated in this article, or claim that may be made by its manufacturer, is not guaranteed or endorsed by the publisher.

Supplementary material

The Supplementary Material for this article can be found online at: https://www.frontiersin.org/articles/10.3389/fsurg.2022.885669/full#supplementary-material.

References

1. Schuttler KF, Ziring E, Ruchholtz S, Efe T. Posterior cruciate ligament injuries. *Unfallchirurg*. (2017) 120:55–68. doi: 10.1007/s00113-016-0292-z

2. Fontbote CA, Sell TC, Laudner KG, Haemmerle M, Allen CR, Margheritini F, et al. Neuromuscular and biomechanical adaptations of patients with isolated deficiency of the posterior cruciate ligament. *Am J Sport Med*. (2005) 33:982–9. doi: 10.1177/0363546504271966

3. Barros MA, Cervone GL, Costa AL. Surgical treatment of avulsion fractures at the tibial insertion of the posterior cruciate ligament: functional result. *Rev Bras Ortop*. (2015) 50:631–7. doi: 10.1016/j.rboe.2015.09.005

4. Tao T, Yang W, Tao X, Li Y, Zhang K, Jiang Y, et al. Arthroscopic direct anterior-to-posterior suture suspension fixation for the treatment of posterior cruciate ligament tibial avulsion fracture. *Orthop Surg*. (2022) 14:2031–41. doi: 10.1111/os.13401

5. Hooper PR, Silko C, Malcolm TL, Farrow LD. Management of posterior cruciate ligament tibial avulsion injuries: a systematic review. *Am J Sport Med*. (2018) 46:734–42. doi: 10.1177/0363546517701911

6. Bali K, Prabhakar S, Saini U, Dhillon MS. Open reduction and internal fixation of isolated PCL fossa avulsion fractures. *Knee Surg Sport Traumatol Arthrosc*. (2012) 20:315–21. doi: 10.1007/s00167-011-1618-6

7. Jang KM, Lee SH. Delayed surgical treatment for tibial avulsion fracture of the posterior cruciate ligament in children. *Knee Surg Sport Traumatol Arthrosc*. (2016) 24:754–9. doi: 10.1007/s00167-015-3929-5

8. Guimaraes TM, Helito P, Angelini FJ, Demange MK, Pecora JR, Helito CP. Delayed treatment of a posterior cruciate ligament tibial insertion avulsion fracture in a child with open physis: a case report with a 4-year follow-up. *J Pediatr Orthop B*. (2017) 26:477–81. doi: 10.1097/BPB.0000000000000432

9. Keyhani S, Soleymanha M, Salari A. Treatment of posterior cruciate ligament tibial avulsion: a new modified open direct lateral posterior approach. *J Knee Surg*. (2022) 35:862–7. doi: 10.1055/s-0040-1721093

10. Khalifa AA, Elsherif ME, Elsherif E, Refai O. Posterior cruciate ligament tibial insertion avulsion, management by open reduction and internal fixation using plate and screws through a direct posterior approach. *Injury*. (2021) 52:594–601. doi: 10.1016/j.injury.2020.09.058

11. Li L, Tian W. Displaced avulsion fractures of the posterior cruciate ligament: treated by stellate steel plate fixation. *Indian J Orthop*. (2015) 49:171–5. doi: 10.4103/0019-5413.152454

12. Liu H, Liu J, Wu Y, Ma Y, Gu S, Mi J, et al. Outcomes of tibial avulsion fracture of the posterior cruciate ligament treated with a homemade hook plate. *Injury*. (2021) 52:1934–8. doi: 10.1016/j.injury.2021.04.042

13. Qi H, Lu Y, Li M, Ren C, Xu Y, Ma T, et al. Open reduction and internal fixation of the tibial avulsion fracture of the posterior cruciate ligament: which is better, a hollow lag screw combined with a gasket or a homemade hook plate? *Bmc Musculoskel Dis*. (2022) 23:143. doi: 10.1186/s12891-022-05096-0

14. Kan H, Nakagawa S, Hino M, Komaki S, Arai Y, Inoue H, et al. Arthroscopic fixation technique for avulsion fracture of the posterior cruciate ligament from the tibia. *Arthrosc Tech*. (2020) 9:e1819–24. doi: 10.1016/j.eats.2020.08.006

15. Tang J, Zhao J. Arthroscopic suture-to-loop fixation of posterior cruciate ligament tibial avulsion fracture. *Arthrosc Tech*. (2021) 10:e1595–602. doi: 10.1016/j.eats.2021.02.029

16. Yoon JR, Park CD, Lee DH. Arthroscopic suture bridge fixation technique with multiple crossover ties for posterior cruciate ligament tibial avulsion fracture. *Knee Surg Sport Traumatol Arthrosc*. (2018) 26:912–8. doi: 10.1007/s00167-016-4339-z

17. Katsman A, Strauss EJ, Campbell KA, Alaia MJ. Posterior cruciate ligament avulsion fractures. *Curr Rev Musculoskelet Med*. (2018) 11:503–9. doi: 10.1007/s12178-018-9491-2

18. Yoon KH, Kim SG, Park JY. The amount of displacement can determine non-operative treatment in posterior cruciate ligament avulsion fracture. *Knee Surg Sport Traumatol Arthrosc*. (2021) 29:1269–75. doi: 10.1007/s00167-020-06175-2

19. Fanelli GC. Knee dislocation and multiple ligament injuries of the knee. *Sports Med Arthrosc*. (2018) 26:150–2. doi: 10.1097/JSA.0000000000000220

20. Hesse E, Bastian L, Zeichen J, Pertschy S, Bosch U, Krettek C. Femoral avulsion fracture of the posterior cruciate ligament in association with a rupture of the popliteal artery in a 9-year-old boy: a case report. *Knee Surg Sport Traumatol Arthrosc*. (2006) 14:335–9. doi: 10.1007/s00167-005-0677-y

21. Sonin AH, Fitzgerald SW, Friedman H, Hoff FL, Hendrix RW, Rogers LF. Posterior cruciate ligament injury: MR imaging diagnosis and patterns of injury. *Radiology*. (1994) 190:455–8. doi: 10.1148/radiology.190.2.8284399

22. Zhao J, He Y, Wang J. Arthroscopic treatment of acute tibial avulsion fracture of the posterior cruciate ligament with suture fixation technique through Y-shaped bone tunnels. *Arthroscopy*. (2006) 22:172–81. doi: 10.1016/j.arthro.2005.10.020

23. Pache S, Aman ZS, Kennedy M, Nakama GY, Moatshe G, Ziegler C, et al. Posterior cruciate ligament: current concepts review. *Arch Bone Jt Surg*. (2018) 6:8–18. doi: 10.1177/3259671221114820

24. Huang W, Gong X, Rahul M, Priyanka S, Wang C, Liang X, et al. Anterior arthroscopic-assisted fixation of posterior cruciate ligament avulsion fractures. *Eur J Med Res*. (2015) 20:88. doi: 10.1186/s40001-015-0177-6

25. Montgomery SR, Johnson JS, McAllister DR, Petrigliano FA. Surgical management of PCL injuries: indications, techniques, and outcomes. *Curr Rev Musculoskelet Med*. (2013) 6:115–23. doi: 10.1007/s12178-013-9162-2

26. Song JG, Nha KW, Lee SW. Open posterior approach versus arthroscopic suture fixation for displaced posterior cruciate ligament avulsion fractures: systematic review. *Knee Surg Relat Res*. (2018) 30:275–83. doi: 10.5792/ksrr.17.073

27. Sundararajan SR, Joseph JB, Ramakanth R, Jha AK, Rajasekaran S. Arthroscopic reduction and internal fixation (ARIF) versus open reduction internal fixation (ORIF) to elucidate the difference for tibial side PCL avulsion fixation: a randomized controlled trial (RCT). *Knee Surg Sport Traumatol Arthrosc*. (2021) 29:1251–7. doi: 10.1007/s00167-020-06144-9

28. Kim SJ, Shin SJ, Choi NH, Cho SK. Arthroscopically assisted treatment of avulsion fractures of the posterior cruciate ligament from the tibia. *J Bone Joint Surg Am*. (2001) 83:698–708. doi: 10.2106/00004623-200105000-00008

29. Wu L, Xu H, Li B, Xu B. Improved arthroscopic high-strength suture fixation for the treatment of posterior cruciate ligament avulsion fracture. *J Orthop Surg*. (2022) 30:10225536221101701. doi: 10.1177/10225536221101701

30. Zhao D, Zhong J, Zhao B, Li Y, Shen D, Gui S, et al. Clinical outcomes of acute displaced posterior cruciate ligament tibial avulsion fracture: a retrospective comparative study between the arthroscopic suture and EndoButton fixation techniques. *Orthop Traumatol Surg Res*. (2021) 107:102798. doi: 10.1016/j.otsr.2020.102798

31. Rhee SJ, Jang JH, Choi YY, Suh JT. Arthroscopic reduction of posterior cruciate ligament tibial avulsion fracture using two cross-linked pull-out sutures: a surgical technique and case series. *Injury*. (2019) 50:804–10. doi: 10.1016/j.injury.2018.11.022

32. Abdallah AA, Arafa MS. Treatment of posterior cruciate ligament tibial avulsion by a minimally-invasive open posterior approach. *Injury*. (2017) 48:1644–9. doi: 10.1016/j.injury.2017.05.032

33. Reverte-Vinaixa MM, Nunez JH, Muneton D, Joshi N, Castellet E, Minguell J. Outcomes of posterior cruciate ligament tibial avulsion treated with staple fixation: stress TELOS x-ray evaluation. *Eur J Orthop Surg Traumatol*. (2019) 29:883–91. doi: 10.1007/s00590-019-02371-0

34. Burks RT, Schaffer JJ. A simplified approach to the tibial attachment of the posterior cruciate ligament. *Clin Orthop Relat Res*. (1990):216–9. doi: 10.1097/00003086-199005000-00031

35. Nicandri GT, Klineberg EO, Wahl CJ, Mills WJ. Treatment of posterior cruciate ligament tibial avulsion fractures through a modified open posterior approach: operative technique and 12- to 48-month outcomes. *J Orthop Trauma*. (2008) 22:317–24. doi: 10.1097/BOT.0b013e31817279d1

36. Bi M, Zhao C, Chen J, Hong Z, Wang Z, Gan K, et al. Arthroscopic suture fixation with autograft augmentation reconstruction for delayed tibial avulsion fractures of the posterior cruciate ligament. *Orthop J Sports Med*. (2020) 8:2325967120944047. doi: 10.1177/2325967120944047

37. Gavaskar AS, Karthik B, Gopalan H, Srinivasan P, Tummala NC. A novel MIS technique for posterior cruciate ligament avulsion fractures. *Knee*. (2017) 24:890–6. doi: 10.1016/j.knee.2017.03.014

38. Chen LB, Wang H, Tie K, Mohammed A, Qi YJ. Arthroscopic fixation of an avulsion fracture of the tibia involving the posterior cruciate ligament: a modified technique in a series of 22 cases. *Bone Joint J*. (2015) 97-B:1220–5. doi: 10.1302/0301-620X.97B9.35765

39. Hermanowicz K, Goralczyk A, Danowska K, Galazka D, LaPrade RF, Malinowski K. All-Arthroscopic posterior cruciate ligament distal reattachment with extracortical fixation. *Arthrosc Tech*. (2019) 8:e1425–30. doi: 10.1016/j.eats.2019.07.019

40. Forkel P, Imhoff AB, Achtnich A, Willinger L. All-arthroscopic fixation of tibial posterior cruciate ligament avulsion fractures with a suture-button technique. *Oper Orthop Traumatol*. (2020) 32:236–47. doi: 10.1007/s00064-019-00626-x

41. Willinger L, Imhoff AB, Schmitt A, Forkel P. Fixation of bony avulsions of the posterior cruciate ligament by a suture-bridge technique. *Oper Orthop Traumatol*. (2019) 31:3–11. doi: 10.1007/s00064-018-0582-4

42. Zhu W, Lu W, Cui J, Peng L, Ou Y, Li H, et al. Treatment of tibia avulsion fracture of posterior cruciate ligament with high-strength suture fixation under arthroscopy. *Eur J Trauma Emerg Surg*. (2017) 43:137–43. doi: 10.1007/s00068-015-0606-9

43. Chen W, Luo W, Chen Z, Jiang Y. Treatment of posterior cruciate ligament avulsion fractures of the tibia using a toothed plate and hollow lag screw. *Singapore Med J*. (2016) 57:39–44. doi: 10.11622/smedj.2016010

frontiers | Frontiers in Surgery

TYPE Case Report
PUBLISHED 06 January 2023
DOI 10.3389/fsurg.2022.1009975

Check for updates

OPEN ACCESS

EDITED BY
Paphon Sa-ngasoongsong,
Mahidol University, Thailand

REVIEWED BY
Cem Albay,
Baltalimanı Kemik Hastalıkları Hastanesi, Turkey
Odion Binitie,
Moffitt Cancer Center, United States

*CORRESPONDENCE
Chengxue Wang
chengxue@jlu.edu.cn

SPECIALTY SECTION
This article was submitted to Orthopedic Surgery, a section of the journal Frontiers in Surgery

RECEIVED 02 August 2022
ACCEPTED 24 October 2022
PUBLISHED 06 January 2023

CITATION
Zhang M, Zhang D, Yu W and Wang C (2023) Liposclerosing myxofibrous tumor of the distal femur: A case report.
Front. Surg. 9:1009975.
doi: 10.3389/fsurg.2022.1009975

COPYRIGHT
© 2023 Zhang, Zhang, Yu and Wang. This is an open-access article distributed under the terms of the Creative Commons Attribution License (CC BY). The use, distribution or reproduction in other forums is permitted, provided the original author(s) and the copyright owner(s) are credited and that the original publication in this journal is cited, in accordance with accepted academic practice. No use, distribution or reproduction is permitted which does not comply with these terms.

Liposclerosing myxofibrous tumor of the distal femur: A case report

Mingyang Zhang, Daguang Zhang, Wenjiang Yu and Chengxue Wang*

Department of Orthopedics, The First Hospital of JilinUniversity, Changchun, China

Introduction: Liposclerosing myxofibrous tumor (LSMFT) is a rare benign fibro-osseous tumor that most frequently occurs in the proximal femur. The reported literature shows that the proximal femur, ilium, tibia, humerus, rib, and skull have occurred, but so far, the female distal femur has not been characterized in detail. This, we think, is the first single comprehensive case report of the female distal femur. To prevent misdiagnosis and overtreatment of this illness, it is critical for us to continue strengthening our knowledge of it and to add it to the differential diagnosis of the space-occupying lesion of the female distal femur.

Case summary: Two months ago, a 55-year-old female patient was found to have a space-occupying lesion of the left distal femur and the pain symptom was aggravated. She underwent thorough curettage and bone grafting without additional treatment to relieve the current symptoms and determine the nature of the lesion in our hospital. The intraoperative specimens were submitted to the pathology laboratory for analysis, and the result was reported as LSMFT. And six months after the operation, the patient returned to our hospital for another x-ray examination and we found that she had recovered well without any signs of recurrence. The patient self-reported that she had now resumed her daily life without any uncomfortable symptoms.

Conclusion: The incidence of LSMFT itself is relatively low, and the occurrence of the distal femur is even rarer. However, it is recommended to add LSMFT into the differential diagnosis of the occupying lesions of the distal femur. Once the diagnosis is made, thorough curettage and bone grafting without additional special treatment can achieve better postoperative outcomes. The patient gave her agreement after learning that information about the case will be submitted for publication.

KEYWORDS

liposclerosing myxofibrous tumor, LSMFT, bone tumor, the distal femur, case report

Introduction

Liposclerosing myxofibrous tumor (LSMFT) was first described by Ragsdale and Sweet in 1986 (1). It is a relatively uncommon benign bone tumor that may arise in the proximal femur and other parts such as the ilium, humerus, tibia, ribs, and skull (1–5). The condition generally manifests itself around 40 years old, and the reported onset age is between 15 and 80 years old, with no notable gender difference (1–3, 6).

The tumor is usually discovered by accident on radiology or with the painful symptom, and very rarely as a result of a pathological fracture (1).

In this rare case report, we document in detail a female patient who was found to have a space-occupying lesion in the distal femur and was diagnosed with LSMFT. She was treated only by complete curettage, and bone grafting and recovered satisfactorily. We think this may be the first case of LSMFT in the female distal femur that has been described in detail. We document the clinical, radiological, and pathological features as well as a retrospective discussion and summary of the case report.

Case report

A 55-year-old female patient went to a local hospital for a magnetic resonance imaging (MRI) examination of her left knee 2 months ago because she felt swelling and dull pain in her left knee after daily walking. The result showed a space-occupying lesion in the left distal femur. The local doctor suggested conservative treatment and regular assessment. Conservative therapy lasted for one month, during which the symptoms did not improve, but the distension and pain of the left distal femur became more apparent, so she went to the orthopedic clinic in our hospital. She was found to have pain on the lateral side of her left distal femur by pressing, without touching the mass during the physical examination. The skin temperature of the left distal femur was normal and the skin could move freely. Anteroposterior and lateral radiographs of the left knee showed a patchy high-density shadow of the left distal femur without fracture or bone destruction (Figure 1). MRI of the left thigh showed an isolated patchy abnormal signal of the left distal femur, with low signal intensity on T1-weighted images (Figures 2A,B), as well as a heterogeneous lesion of the left distal femur with high signal intensity on T2-weighted images (Figures 2C,D), with uneven internal signal, and no clear abnormal signal in the muscle and subcutaneous soft tissue of the left thigh. We comprehensively considered it as a benign tumor initially and suspected it was endogenous chondrosarcoma. Nevertheless, there was no clear diagnostic foundation. In order to alleviate her current symptoms and ascertain the nature of the lesion, we admitted her to the hospital and began preparing her for surgery. Before the surgery, we carried out some examinations for her and found that all indicators of her hemoglobin, total white blood cell count and various specific indicators contained in white blood cell, platelets, coagulation function, calcium ions, potassium ions, antistreptolysin O, rheumatoid factor, hypersensitive c-reactive protein, fasting blood sugar, erythrocyte sedimentation rate, and renal function were normal. In addition to a slightly lower albumin index (37.3g/L, normal



FIGURE 1
Anteroposterior and lateral radiographs of the left knee showing a patchy high-density shadow of the left distal femur without fracture or bone destruction.



FIGURE 2
Representative coronal (Figure 2A) and axial (Figure 2B) T1-weighted images showing an isolated patchy abnormal signal of the left distal femur, with low signal intensity. Representative coronal (Figure 2C) and axial (Figure 2D) T2-weighted images showing a heterogenous lesion of the left distal femur with high signal intensity, with uneven internal signal, and no clear abnormal signal in the muscle and subcutaneous soft tissue of the left thigh.

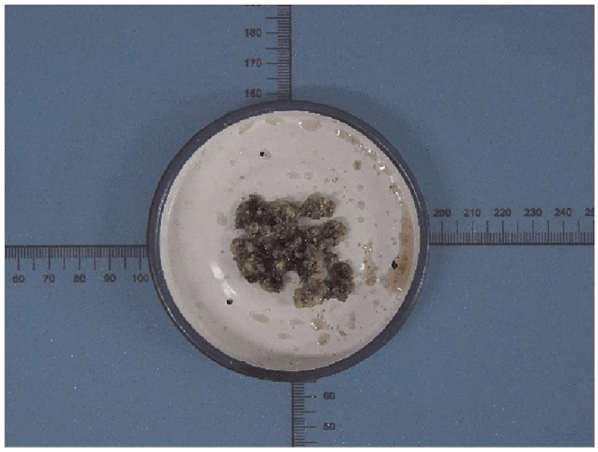

FIGURE 3
Histopathological examination of the specimens revealed that a pile of yellow broken bone tissues were visible to the naked eye.

range: 40–55g/L) and a higher alkaline phosphatase index (174.8U/L, normal range: 50–135U/L), other indicators of hepatic function were normal. After a comprehensive analysis of preoperative examinations, no contraindications were found. We conducted surgical treatment for her on the third day in the hospital. An incision was performed on the lateral side of the left distal femur, and a long strip of the bone block with a size of 2 cm*8 cm was removed at the location of the tumor to expose the tumor. Additionally, the lesion in the medullary cavity was found to be fibrous-like and bone marrow-like in appearance. The lesion in the medullary cavity and on the bone block was thoroughly curetted until the normal bone was visible and all specimens were sent for histopathological analysis. The bleeding was thoroughly stopped, then the incision was rinsed with distilled water and normal saline. The artificial bone matrix was filled in the defect and the removed bone block is put in place. We did not perform plate fixation for her, which saved money for her, but increased the risk of postoperative fracture and the risk of thrombosis due to early failure of functional exercise. Histopathological examination of the specimens revealed that a pile of yellow broken bone tissues were visible to the naked eye, with a total volume of 4 cm*3 cm*1 cm (Figure 3). And in some typical microscopic images, myxoid degeneration, calcified bone tissue, fat necrosis, cystic degeneration, irregular calcification, and collagen degeneration of fibrous tissue are seen (Figure 4). LSMFT was confirmed after consulting with the pathology professors. We didn't give her follow-up radiation and chemotherapy because it's a benign lesion reported in the literature. The patient recovered well after the surgery. The alkaline phosphatase index decreased on the 1st day after the surgery and remained normal after the 3rd

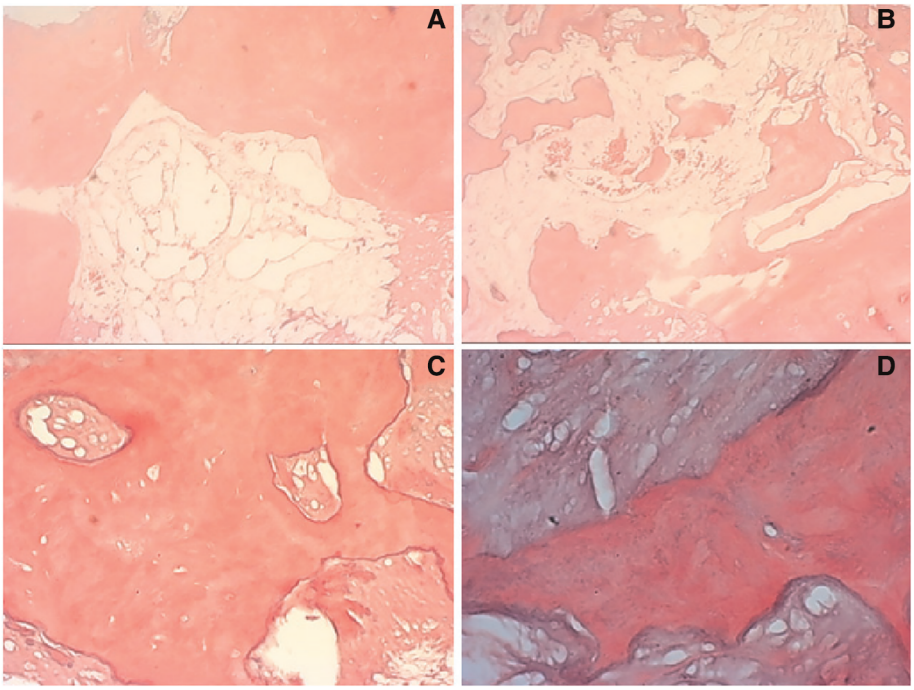

FIGURE 4
In some typical microscopic images, myxoid degeneration, calcified bone tissue, fat necrosis, cystic degeneration, irregular calcification, and collagen degeneration of fibrous tissue are seen (original magnifications of ×4 in (A,B, ×10 in (C), ×40 in D).



FIGURE 5
Anteroposterior and lateral radiographs of the left femur showing no abnormal signal at the left distal femur on the 3rd day after the surgery.

postoperative day. Anteroposterior and lateral radiographs of the left femur showed no aberrant signal at the left distal femur on the 3rd day after the surgery (**Figure 5**). On the fifth day after the operation, she was discharged from the hospital in good condition and returned home. During the routine follow-up evaluations for six months, she was found to have returned to normal daily life with no symptoms of discomfort. Six months later, anteroposterior and lateral radiographs of the left knee showed good recovery of the left distal femur, consistent with the postoperative change of the left distal femur (**Figure 6**). During the six months of follow-up, the symptoms of her affected limb showed no signs of recurrence, nor was there the indication of a recurrence of her imaging. We will continue to follow her up for a long period time and pay close attention to her life after surgery.



FIGURE 6
Follow-up anteroposterior and lateral radiographs of the left knee 6 months after the surgery showing good recovery of the left distal femur, consistent with postoperative changes of the left distal femur.

Discussion

Liposclerosing myxofibrous tumor (LSMFT) was first described in 1986 and is most likely to occur in the proximal femur, accounting for 80%–90% of the cases (1, 2, 7). Some authors report that 48% of patients have pain at the site of onset, 40% are asymptomatic, and 10% have a pathological fracture (8). The age range of onset of this tumor is broad. According to the published literature, the age of onset is between 15 and 80 years old, the typical age is about 40 years old, and the incidence rate is equal between males and females (1). And this lesion is frequently a well-defined geographic lytic lesion with a sclerotic boundary (1). There is no conclusive explanation for the origin of the tumor. Some report that LSMFT is not a distinct lesion, but rather a traumatic variant of fibrous dysplasia or secondary degenerative changes of the lipoma (9–11). In addition, the Gs α mutation is also reported in two patients who are diagnosed with LSMFT, which is the similar mutation found in cases of fibrous dysplasia. Therefore, the authors of this paper believe that LSMFT is closely related to fibrous dysplasia (12). But some argue that the histological structure of LSMFT exceeds the range of histological structures currently reported for fibrous dysplasia and the tumor should therefore be treated as a distinct lesion (4, 7, 13, 14). Several authors even suggest that LSMFT should be classified as a true clinicopathological entity and included in textbooks of orthopedic pathology (14). It has been reported that the imaging manifestations of LSMFT are varied due to the complexity and diversity of histology. The imaging features of such lesion are usually the well-defined geographic lesion with extensive sclerosis of the margins, expansive remodeling, and mineralized matrix, which is inhomogeneous in density. Such features indicate an indolent pattern of growth. On T1-weighted images, the signal intensity of the lesion was comparable to that of skeletal muscle. On T2-weighted images, the signal intensity is greater than that of fat owing to the presence of myxoid tissue, which can be easily distinguished from intraosseous lipoma (3, 4, 15). The histological compositions of this tumor are complex and may consist of a variety of histological structures in varying proportions, including lipoma, fibroxanthoma, myxoma, myxofibroma, fibrous tissue, cyst formation, fat necrosis, ischemic bone tissue, and rarely cartilaginous tissue (1, 2, 4, 5, 7). Due to the diversity of histological forms, this tumor may easily be mistaken for fibrous dysplasia, intraosseous lipoma and other diseases (1, 16). Although LSMFT is a benign bone tumor, it has been reported to deteriorate into osteosarcoma, fibrosarcoma, telangiectatic osteosarcoma, malignant fibrous histiocytoma, malignant fibroxanthomas, and high-grade spindle cell tumor with a malignant transformation rate of 10% to 16%, which is significantly higher than the 0.5%

malignant transformation rate of FD (4, 6, 7, 13, 16–18). The mechanisms of malignant transformation for LSMFT are unclear, but some authors suggest that the mechanisms are alterations in lipoma degeneration, changes in proliferative events in adipogenic lesions, and mechanical stress associated with ischemic damage (17, 19). The current consensus, however, is that LSMFT is a benign lesion, and its association with malignant transformation is controversial (3, 9, 15). According to the presently available literature, the asymptomatic patients with LSMFT usually do not require treatment and regular review is sufficient. If the patients have unpleasant symptoms such as pain, limping and pathological fracture, they can be treated by complete curettage, bone grafting, and orthopedic internal fixation, which depended on the specific situation. At the moment, the treatment of LSMFT is generally the surgical intervention without additional treatments such as radiation and chemotherapy, and the overall prognosis is wonderful. On the other hand, Regado et al. describe a patient with LSMFT who presented with pain and deformity and underwent transtibial amputation after the pathological biopsy with malignant cells. No recurrence or metastasis was found during the long-term follow-up (2). Campbell et al. described a patient with LSMFT who underwent the postoperative malignant transformation, tumor recurrence, and death in a short period after surgical treatments (6). The reports of malignant cases remind us to pay more attention to the postoperative recovery of the patients diagnosed with LSMFT.

Conclusion

LSMFT has exhibited a considerable preference for the proximal femur. At the same time, ilium, humerus, ribs, and skull have also been reported. On the other hand, we have not found any literature detailing the occurrence of LSMFT in the female distal femur. This lesion often has a sclerotic border and is often a well-defined geographic lytic lesion. However, anteroposterior and lateral radiographs of the left knee showed a patchy high-density shadow of the left distal femur without fracture or bone destruction in this case. The diagnosis of this rare disease depends on a comprehensive analysis of clinical, radiological, and histopathological findings. The tumor may be readily mistaken for other lesions with possibly overlapping characteristics because of the diversity of its tissue structure. This rare case report is used to expand our awareness of LSMFT in the distal femur and to remind us to add LSMFT to the differential diagnosis before making a diagnosis of the space-occupying lesions of the female distal femur, with the final pathological diagnosis as the gold standard. Once the diagnosis is confirmed, thorough curettage and bone grafting are carried out without additional treatments. x-ray or MRI examinations are regularly ordered after the operation, and the patient's recovery status is closely followed. Generally, the postoperative recovery is excellent without affecting daily life.

Data availability statement

The original contributions presented in the study are included in the article/Supplementary Material, further inquiries can be directed to the corresponding author/s.

Ethics statement

Written informed consent was obtained from the individual(s) for the publication of any potentially identifiable images or data included in this article.

Author contributions

Surgery was carried out by DZ, MZ, and WY. MZ and CW were involved in the patient's data collecting. MZ read the literature and helped with the manuscript's preparation. CW was in charge of the manuscript's revision. The paper has been reviewed and approved by all authors. All authors contributed to the article and approved the submitted version.

Conflict of interest

The authors declare that the research was conducted in the absence of any commercial or financial relationships that could be construed as a potential conflict of interest.

Publisher's note

All claims expressed in this article are solely those of the authors and do not necessarily represent those of their affiliated organizations, or those of the publisher, the editors and the reviewers. Any product that may be evaluated in this article, or claim that may be made by its manufacturer, is not guaranteed or endorsed by the publisher.

References

1. Deel C, Hassell L. Liposclerosing myxofibrous tumor: a review. *Arch Pathol Lab Med*. (2016) 140(5):473–6. doi: 10.5858/2014-0503-RS

2. Regado ER, Garcia PB, Caruso AC, de Almeida AL, Aymoré IL, Meohas W, et al. Liposclerosing myxofibrous tumor: a series of 9 cases and review of the literature. *J Orthop*. (2016) 13(3):136–9. doi: 10.1016/j.jor.2016.03.003

3. Ploof J, Shaikh H, Melli J, Jour G, Turtz A. Liposclerosing myxofibrous tumor of the cranial vault: a case report. *Neurosurg*. (2019) 84(3):E207–10. doi: 10.1093/neuros/nyy071

4. Kransdorf MJ, Murphey MD, Sweet DE. Liposclerosing myxofibrous tumor: a radiologic-pathologic-distinct fibro-osseous lesion of bone with a marked predilection for the intertrochanteric region of the femur. *Radiol*. (1999) 212 (3):693–8. doi: 10.1148/radiology.212.3.r99se40693

5. Choi JW, Lee YS, Lee JH, Kim HK, Yeom BW, Choi JS, et al. Liposclerosing Myxofibrous Tumor in Tibia: A Case Report and Review of the Literature. 2005.

6. Campbell K, Wodajo F. Case report: two-step malignant transformation of a liposclerosing myxofibrous tumor of bone. *Clin Orthop Relat Res*. (2008) 466 (11):2873–7. doi: 10.1007/s11999-008-0362-9

7. Ragsdale BD. Polymorphic fibro-osseous lesions of bone: an almost site-specific diagnostic problem of the proximal femur. *Human Pathl*. (1993) 24 (5):505–12. doi: 10.1016/0046-8177(93)90162-A

8. Tecualt-Gomez R, Atencio-Chan A, Cario-Mendez AG, Amaya-Zepeda RA, Balderas-Martinez J, Gonzalez-Valladares JR. Bone liposclerosing myxofibrous tumor. Case presentation and literature review. *Acta Ortop Mex*. (2015) 29 (3):191–5. PMID: 26999973

9. Dattilo J, McCarthy EF. Liposclerosing myxofibrous tumor (LSMFT), a study of 33 patients: should it be a distinct entity? *Iowa Orthop J*. (2012) 32:35–9. PMID: 23576919

10. Corsi A, De Maio F, Ippolito E, Cherman N, Gehron Robey P, Riminucci M, et al. Monostotic fibrous dysplasia of the proximal femur and liposclerosing myxofibrous tumor: which one is which? *J Bone Miner Res*. (2006) 21 (12):1955–8. doi: 10.1359/jbmr.060818

11. Heim-Hall JM, Williams RP. Liposclerosing myxofibrous tumour: a traumatized variant of fibrous dysplasia? Report of four cases and review of the literature. *Histopathol*. (2004) 45(4):369–76. doi: 10.1111/j.1365-2559.2004.01951.x

12. Matsuba A, Ogose A, Tokunaga K, Kawashima H, Hotta T, Urakawa S, et al. Activating gs alpha mutation at the Arg201 codon in liposclerosing myxofibrous tumor. *Hum Pathol*. (2003) 34(11):1204–9. doi: 10.1016/S0046-8177(03)00430-1

13. Beytemür O, Tetikkurt Ü S, Albay C, Kavşut G, Güleç A. Liposclerosing myxofibrous tumor: a rare tumor of proximal femur. *Eklem Hastalik Cerrahisi*. (2017) 28(3):210–3. doi: 10.5606/ehc.2017.48394

14. Gilkey FW. Liposclerosing myxofibrous tumor of bone. *Hum Pathol*. (1993) 24(11):1264. doi: 10.1016/0046-8177(93)90226-7

15. O'Dwyer H, Al-Nakshabandi NA, Saliken J, Munk PL, Nielsen TO, Masri B, et al. Liposclerosing myxofibrous tumour. *Eur. J. Radiol*. 2005, 55 (3), 83–7. doi: 10.1016/j.ejrex.2005.07.009

16. Kheok SW, Ong KO. Benign periarticular, bone and joint lipomatous lesions. *Singapore Med J*. (2017) 58(9):521–7. doi: 10.11622/smedj.2017087

17. Bahk WJ, Seo KJ. Malignant transformation of liposclerosing myxofibrous tumour. *Pathol*. (2021) 53(5):660–3. doi: 10.1016/j.pathol.2020.09.032

18. Illac C, Delisle MB, Bonnevialle P, Chiavassa-Gandois H, de Pinieux G, Gomez-Brouchet A. [Telangiectatic osteosarcoma secondary to a liposclerosing myxofibrous tumor: a case report]. *Ann Pathol*. (2012) 32(4):259–62. doi: 10.1016/j.annpat.2012.06.003

19. Murphey MD, Carroll JF, Flemming DJ, Pope TL, Gannon FH, Kransdorf MJ. From the archives of the AFIP: benign musculoskeletal lipomatous lesions. *Radiographics*. (2004) 24(5):1433–66. doi: 10.1148/rg.245045120

frontiers | Frontiers in Surgery

TYPE Case Report
PUBLISHED 10 January 2023
DOI 10.3389/fsurg.2022.1045307

Check for updates

OPEN ACCESS

EDITED BY
Paphon Sa-ngasoongsong,
Mahidol University, Thailand

REVIEWED BY
Dejin Yang,
Beijing Jishuitan Hospital, China
Manveen Kaur,
Government Medical College and Hospital, India

*CORRESPONDENCE
Juehua Jing
jjh_hu@163.com

†These authors have contributed equally to this work and share first authorship

SPECIALTY SECTION
This article was submitted to Orthopedic Surgery, a section of the journal Frontiers in Surgery

RECEIVED 15 September 2022
ACCEPTED 16 December 2022
PUBLISHED 10 January 2023

CITATION
Wu Z, Cheng L, Cao Q, Ye S, Yu S, Sun M and Jing J (2023) Case report and literature review: Primary leiomyosarcoma of the bone in the trochanteric region of the femur.
Front. Surg. 9:1045307.
doi: 10.3389/fsurg.2022.1045307

COPYRIGHT
© 2023 Wu, Cheng, Cao, Ye, Yu, Sun and Jing. This is an open-access article distributed under the terms of the Creative Commons Attribution License (CC BY). The use, distribution or reproduction in other forums is permitted, provided the original author(s) and the copyright owner(s) are credited and that the original publication in this journal is cited, in accordance with accepted academic practice. No use, distribution or reproduction is permitted which does not comply with these terms.

Case report and literature review: Primary leiomyosarcoma of the bone in the trochanteric region of the femur

Zhonghan Wu[1,2†], Li Cheng[1,2†], Qiliang Cao[1,2], Shuming Ye[1,2], Shuisheng Yu[1,2], Min Sun[2] and Juehua Jing[1,2*]

[1]Department of Orthopaedics, The Second Hospital of Anhui Medical University, Hefei, China, [2]Institute of Orthopaedics, Research Center for Translational Medicine, The Second Hospital of Anhui Medical University, Hefei, China

Background: Primary leiomyosarcoma of the bone (LMSB) is an extremely rare, invasive, and highly destructive primary osteosarcoma with limited treatment options and poor prognosis. Only a few case reports of LMSB have been described because of its rarity. Therefore, clinicians have a limited understanding of its diagnosis, treatment, and prognosis, and the final diagnosis depends on histopathological findings. In this report, we describe a rare case of primary LMSB in the trochanteric region of the femur. Reporting this case may increase the dissemination and understanding of information regarding LMSB and provide a reference for the diagnosis and treatment of similar cases.

Case presentation: A 63-year-old woman presented with pain and limited movement of the left hip, which had lasted for 3 months, with no history of trauma or illness. Plain radiography and computed tomography revealed a solitary osteolytic lesion in the trochanteric area of the left femur with focal cortical destruction. Magnetic resonance imaging findings suggested invasion of the lesion into the bone cortex, forming a soft tissue mass, although no distant positive findings were observed on a whole-body bone scan. A bone tumor puncture biopsy was performed to obtain a final diagnosis, and histopathological evaluation revealed left femoral intertrochanteric leiomyosarcoma, classified as G1T2M0 and staged as IB (extracompartmental low-grade malignant) according to the Enneking staging system. Thus, we performed extensive debridement and left hip arthroplasty. Postoperative chemotherapy was administered, and the patient was followed up for 4 years. Four years later, the patient's left hip pain had resolved, joint activity was good, and no signs of recurrence or distant metastasis of the bone tumor were noted.

Conclusion: For proximal femoral Enneking stage IB LMSB, extensive tumor resection combined with tumor prosthesis replacement may be an effective treatment method to prolong the patient's lifespan and to restore joint function.

KEYWORDS

leiomyosarcoma, bone neoplasms, femur, invasive, surgical treatment, joint replacement, case report

Introduction

Primary leiomyosarcoma of the bone (LMSB) is a rare bone tumor first reported by Evans and Sanerkin in 1965 and accounts for approximately 0.06% of all primary bone tumors (1). Primary LMSB lesions comprise <0.7% of all primary bone malignancies (2). They are thought to originate from small vascular smooth muscle cells in the bone cortex or pluripotent mesenchymal stem cells in the bone. They are pathologically characterized as osteosarcomas with smooth muscle-like differentiation (3). Leiomyosarcoma commonly occurs in the retroperitoneum, subcutaneous tissue of the extremities, intraabdominal space, and gastrointestinal, uterine, and other deep soft tissues (4). LMSB usually occurs in the long tubular bones of the lower extremities (tibia and femur), and approximately 70% of cases occur in the knee joint (distal femur and proximal tibia) (5). Its occurrences in the hip joint, spine, and trochanteric area of the femur have been rarely reported, especially in the last 10 years (**Supplementary Table S1**).

The early diagnosis and treatment of LMSB are difficult (6). LMSB mostly affects middle-aged and older patients and is usually characterized by pain and swelling of the affected limbs (7). Moreover, pathological fractures may occur in 30% of cases (7). The findings on magnetic resonance imaging (MRI) are easily confused with those of osteolytic osteosarcoma and metastatic leiomyosarcoma, and diagnosing LMSB depends on pathological methods (7). The tumor has high metastatic and recurrence rates (8, 9). From the perspective of Enneking surgical staging, high tumor grade, tumor diameters exceeding 5 cm, and early metastasis increase the long-term mortality of LMSB (10). Therefore, early diagnosis can improve the survival prognosis. As a malignant bone tumor, the most basic treatment method for LMSB is surgical resection, which can be classified into two types: limb salvage and amputation, both of which aim to completely remove the pathological tissue (11). For malignant bone tumors near joints, patients often undergo tumor prosthesis replacement surgery (12, 13). Tumor prosthesis replacement meets the marginal requirements of an extensive resection of tumor tissue and retains joint function (11). These tumors are relatively resistant to radiotherapy and chemotherapy, and their prognosis is complicated (14).

There have only been a few detailed reports of LMSB in the hip joint. Herein, we present a rare case of an older female patient with primary leiomyosarcoma in the trochanter of the left femur with a good prognosis.

Case description

Chief complaints

A 63-year-old woman who complained of pain and limited left hip movement for the previous 3 months was hospitalized in November 2017. In the early stages of the disease (August 2017), the patient experienced non-specific, intractable hip pain and limited movement without external trauma or injury. The pain was aggravated by exercise and was more severe at night, accompanied by claudication and difficulty turning over in bed. Radiography performed at a local county hospital showed a bone tumor in the left proximal femur; hence, the patient was referred to our hospital for treatment.

Medical history

The patient had a history of grade 2 hypertension accompanied by deep venous thrombosis of the left lower extremity (intermuscular venous thrombosis of the left leg), bilateral carotid arteriosclerosis, and arteriosclerosis of both lower extremities.

Physical and laboratory examinations

Physical examination revealed swelling of the upper left thigh, with no palpable mass or tenderness in the inguinal area. Local tenderness and knocking pain were present on the outside of the left hip joint. Further examination showed a positive Patrick's sign and a negative Thomas' sign. The active and passive movements of the hip joint were limited, especially external rotation, and the patient displayed normal muscle tension and strength.

Routine laboratory tests, including blood, urine, and biochemical tests, yielded normal results. Regarding hematological and oncological indexes, the neuron-specific enolase level was slightly elevated at 15.40 μg/ml, the cancer antigen 72–4 level was 26.83 U/ml, and the ferritin level had increased to 230.90 ng/ml, which was a high value but still within the normal range. After excluding other lesions, these laboratory results were considered related to a malignant tumor's invasion of the bone marrow.

Imaging examinations

On November 26, 2017, a plain radiograph showed an osteolytic lesion with cystic destruction in the left femur's intertrochanteric region, and the lesion's boundary was clear without periosteal reaction (**Figures 1A,B**). Computed tomography (CT) showed that the tumor broke through the bone cortex and formed a significant soft tissue mass (**Figures 1C–E**). MRI revealed that the intertrochanteric medullary cavity of the left femur was occupied by short T1 and long T2 signals (**Figures 1G–J**). T1-weighted images showed that the tumor signal was similar to that of the muscle tissue, and the lesion included some parts of the femoral neck, trochanter, and subtrochanter. A whole-body bone scan showed that the intertrochanteric nuclides of the left femur were

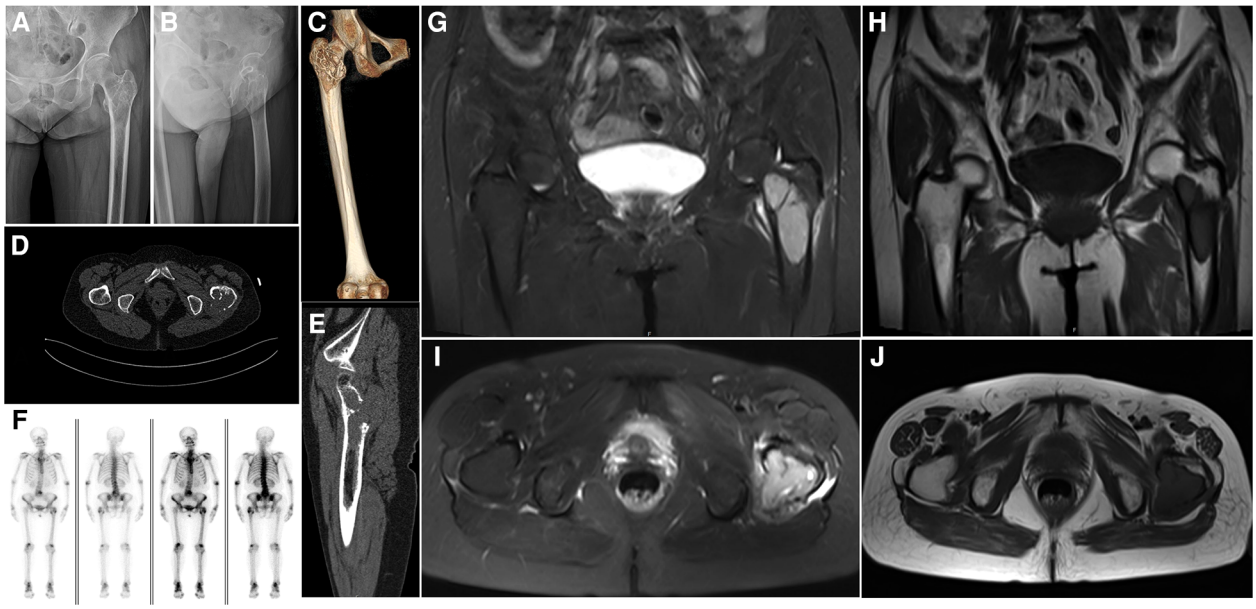

FIGURE 1
Preoperative imaging. (A,B) A radiograph of the left hip joint shows the extension of the tumor from the proximal femur to the subtrochanter of the femur; osteolytic lesions invading the bone cortex and proximal bone marrow cavity, as well as local osteosclerosis, can be observed. (C) Three-dimensional computed tomography (CT) reconstruction shows that the tumor is mainly located in the trochanteric area of the femur, with obvious bone erosion and insect erosion appearance. (D,E) A CT scan of the left hip shows that the tumor's lower and upper boundaries are clear and unclear, respectively, and osteolytic bone destruction can be observed. (F) A whole-body bone scan shows no other obvious positive areas. (G) A sagittal view of a T2-weighted image shows that the tumor is well-bounded and multilocular, with lytic destruction and the tumor extending outside the bone. (H) A sagittal view of a T1-weighted image illustrates that the tumor has a low signal shadow, similar to the muscle signal, and the area is larger than the plain film area. (I) A transverse view of a T2-weighted image shows uneven hypersignal shadows in the left trochanteric area with soft tissue infiltration on the posterolateral side of the trochanter. (J) A transverse view of a T1-weighted image shows that low signal shadows dominate the entire trochanteric area.

enriched and that bone salt metabolism had increased significantly; however, the bone salt metabolism of other parts of the body had not significantly increased (Figure 1F). Preoperatively, a CT scan of the head, neck, abdomen, and pelvis and a gynecological B-mode ultrasound revealed no metastasis in the gastrointestinal tract or uterus, and no signs of recent cerebral infarctions were present.

After obtaining informed consent from the patient and her family, a puncture biopsy of the left intertrochanteric bone tumor was performed on December 5, 2017. The pathological evaluation demonstrated a left femoral intertrochanteric leiomyosarcoma.

Diagnostic assessment

Final diagnosis

Histopathological analysis revealed a myogenic tumor showing characteristics consistent with those of LMSB. The results revealed a low-grade malignant tumor. Imaging showed an invasive growth breaking through the compartment, although there were no metastases. Therefore, the tumor was classified as G1T2M0 and staged as IB (extracompartmental low-grade malignant) according to the Enneking staging system. In this case, the final preoperative diagnosis was stage IB LMSB in the femur's trochanteric region. Extensive resection of the proximal femoral lesion was needed based on the above results.

Treatment

We monitored the patient's general condition for 1 week preoperatively and performed detumescence, anticoagulation, and placement of a lower limb thrombus filter while monitoring heart, lung, and brain functions. We customized the prosthesis and performed extensive resection of the femoral intertrochanteric leiomyosarcoma and tumor prosthesis replacement under general anesthesia (Figure 2).

A 15-cm incision was made on the posterior side of the left hip joint. The tumor was located in the greater trochanter of the femur, infiltrating the external circumflex muscle group. We resected the normal part of the external circumflex muscle group and incised the iliopsoas muscle downward at the lesser trochanter to expose the joint capsule. Next, we exposed the region below the lesser trochanter and peeled the gluteus minimus muscle upward to completely expose the incised articular capsule. Since the articular cartilage was in good

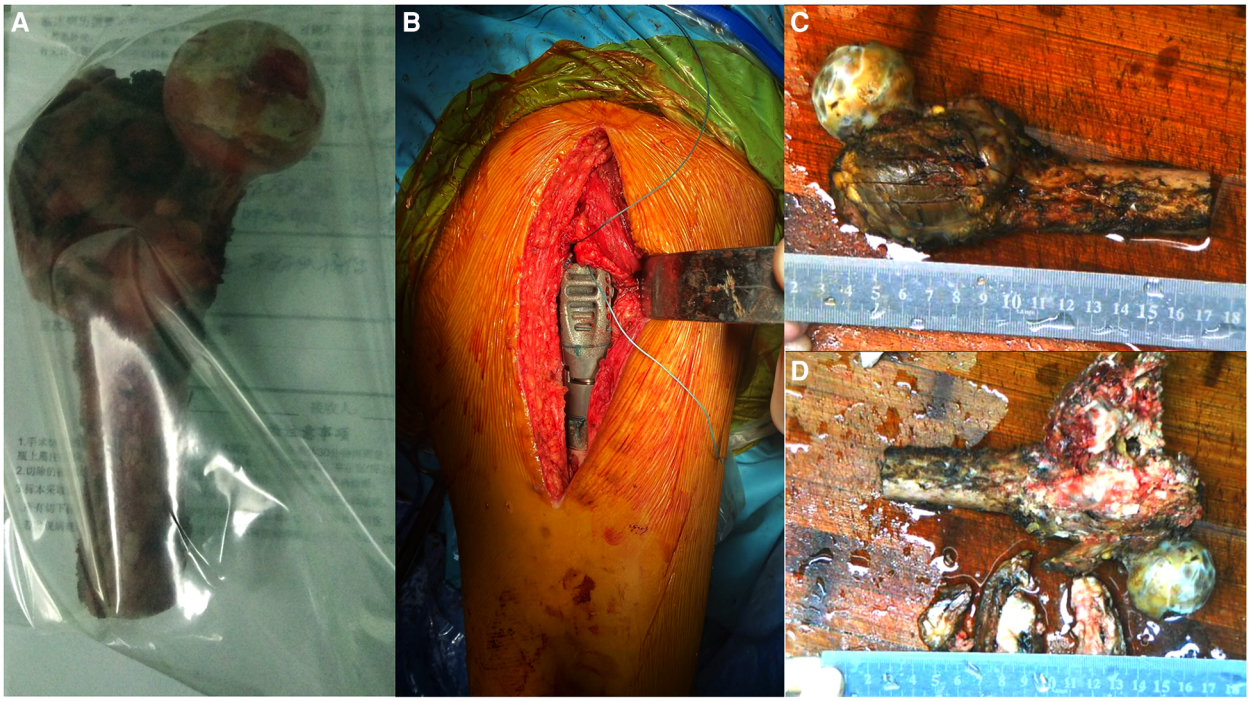

FIGURE 2
Intraoperative imaging and postoperative gross specimen. (A,B) The proximal femur is completely resected, and the tumor prosthesis is successfully implanted. (C) The gross specimen shows an uneven mass in the trochanter of the femur, with a size of approximately 6.0 cm × 6.0 cm × 4.0 cm. (D) The section of the specimen shows that the center of the mass is gray-white, with bleeding and necrotic areas invading the bone cortex.

condition and showed no infiltration, it was preserved. Based on the tumor involvement observed on the MRI scan, the femoral shaft was amputated 5 cm distal to the tumor, which was 16 cm from the apex of the greater trochanter. The attached muscle and proximal femur were completely removed. The cutting edge was subsequently found to be negative for tumor cells. Meanwhile, the size of the femoral head was 41 mm, and we selected an implant with a 40-mm bipolar femoral head. We sutured the joint capsule, reconstructed the muscles adjoining the proximal femur, and placed a drainage tube. The postoperative resected specimens were then sent for pathological examination (**Figure 3**).

Outcome and follow-up

Two months postoperatively, the patient underwent five cycles of adjuvant chemotherapy. The chemotherapy regimen comprised cisplatin (30 mg/day) for 2 days, pirarubicin (50 mg/day) on the first day, and cisplatin (20 mg/day) on the third day. Routine clinical and radiological evaluations were performed every 3–4 months. Currently, 4 years postoperatively, the patient is in good physical condition and remains active, with no obvious pain in the hip joint or evident signs of tumor recurrence or metastasis (**Figure 4**). The patient's whole treatment and follow-up process is summarized in the timeline (**Supplementary Figure S1**).

Discussion

LMSB is a rare and highly-invasive leiomyosarcoma that is difficult to diagnose and treat (7). The incidence of LMSB is slightly lower in men than in women (12), and the 5-year disease-specific survival rate of limb LMSB is 55%, while the median disease-specific survival after diagnosis is 61 months (95% confidence interval: 36–85 months) (15). Patients with metastasis at the initial diagnosis have worse prognoses (8). A previous study showed that the average age of patients with LMSB was 46 years (range: 9–88 years) (12). The optimal treatment for LMSB is unclear, and surgery, including tumor resection and limb salvage or hip amputation, is a widely-accepted treatment modality (15, 16). After successful limb salvage, the patient in this report was monitored for more than 50 months and showed no local recurrence or metastasis and satisfactory joint function. This case can serve as a reference for diagnosing and treating proximal femoral LMSB.

LMSB has a non-specific clinical presentation, as hip pain and pathological fractures shown by imaging are often the first symptoms (14). On plain radiographs, LMSB can appear as

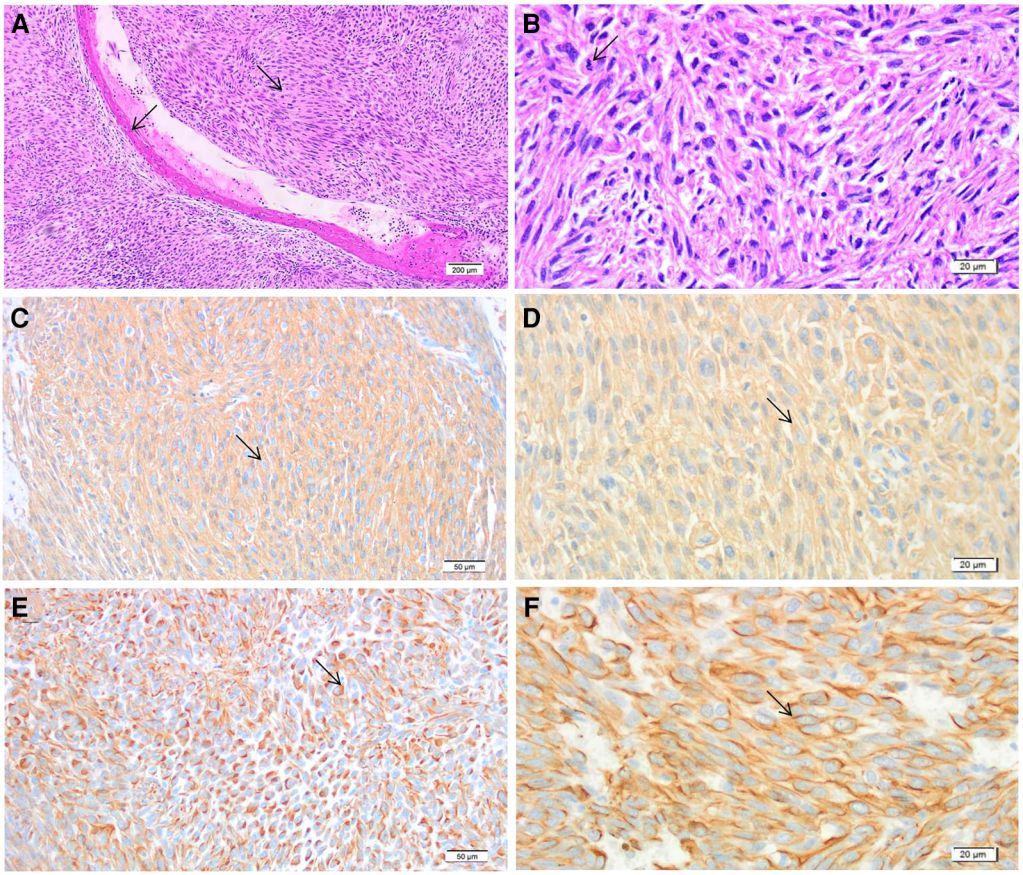

FIGURE 3
Results of postoperative pathological examination of the bone tumor. (A) Hematoxylin and eosin staining 40×: fusiform cell diffuse hyperplasia and tumor cells infiltrate adjacent bone trabeculae, as indicated by the arrow. Inflammation is observed around the bone trabeculae. (B) Hematoxylin and eosin staining 400×: fusiform cell diffuse hyperplasia with a myxohyaline matrix pervading the intercellular space, as indicated by the arrow. (C) Smooth muscle actin 200×: cytoplasmic staining is diffuse and strongly positive, as indicated by the arrow. (D) Smooth muscle actin 400×: cytoplasmic staining is diffuse and strongly positive, as indicated by the arrow. (E) Desmin 200×: some cytoplasmic staining is positive, as indicated by the arrow. (F) Desmin 400×: some cytoplasmic staining is positive, as indicated by the arrow.

osteolytic, cystic, or mixed lesions and may include trabecular infiltration and periosteal reactions (17). Small bone infarctions are observed more clearly on CT scans than on radiographs and indicate small intraosseous vascular embolisms (18). The actual space occupation of LMSB lesions is larger than that observed *via* plain radiography, and the bone trabecula is disordered, which can be observed more clearly on MRI (19). LMSB tumors generally have low-signal shadows on T1-weighted images and high-signal shadows on T2-weighted images (19). LMSB occurs mostly in the long bones of the lower limbs and should be differentiated from other common bone tumors after the exclusion of metastases (7). LMSB commonly occurs in the same locations as osteosarcoma with more obvious bone destruction and periosteum reactions observed using radiography and CT, which are specific manifestations (20). However, the periosteal reactions of LMSB are not obvious. Myelomas may also present with lytic bone destruction, though osteoporosis can be observed on radiography and CT, and a myeloma includes multiple lesions with irregular shapes (21). LMSB, osteosarcoma, and myeloma appear as low-intensity lesions on T1-weighted images and high-intensity lesions T2-weighted images on MRI (7, 20, 21). Therefore, the specificity of the imaging results of LMSB is relatively low, and the diagnosis is dependent on pathological examination (8, 22).

The pathological examination of LMSB includes observing microscopic morphology and immunohistochemistry (19). Within LMSB lesions, long, narrow, spindle-shaped tumor cells form bundles within eosinophilic-rich cytoplasm and have cigar-shaped nuclei (23, 24). Immunohistochemistry is of unique value in diagnosing myogenic tumors and must be conducted to accurately diagnose LMSB (24).

Most LMSB lesions are positive for smooth muscle actin (SMA), approximately half are positive for intermediate filament

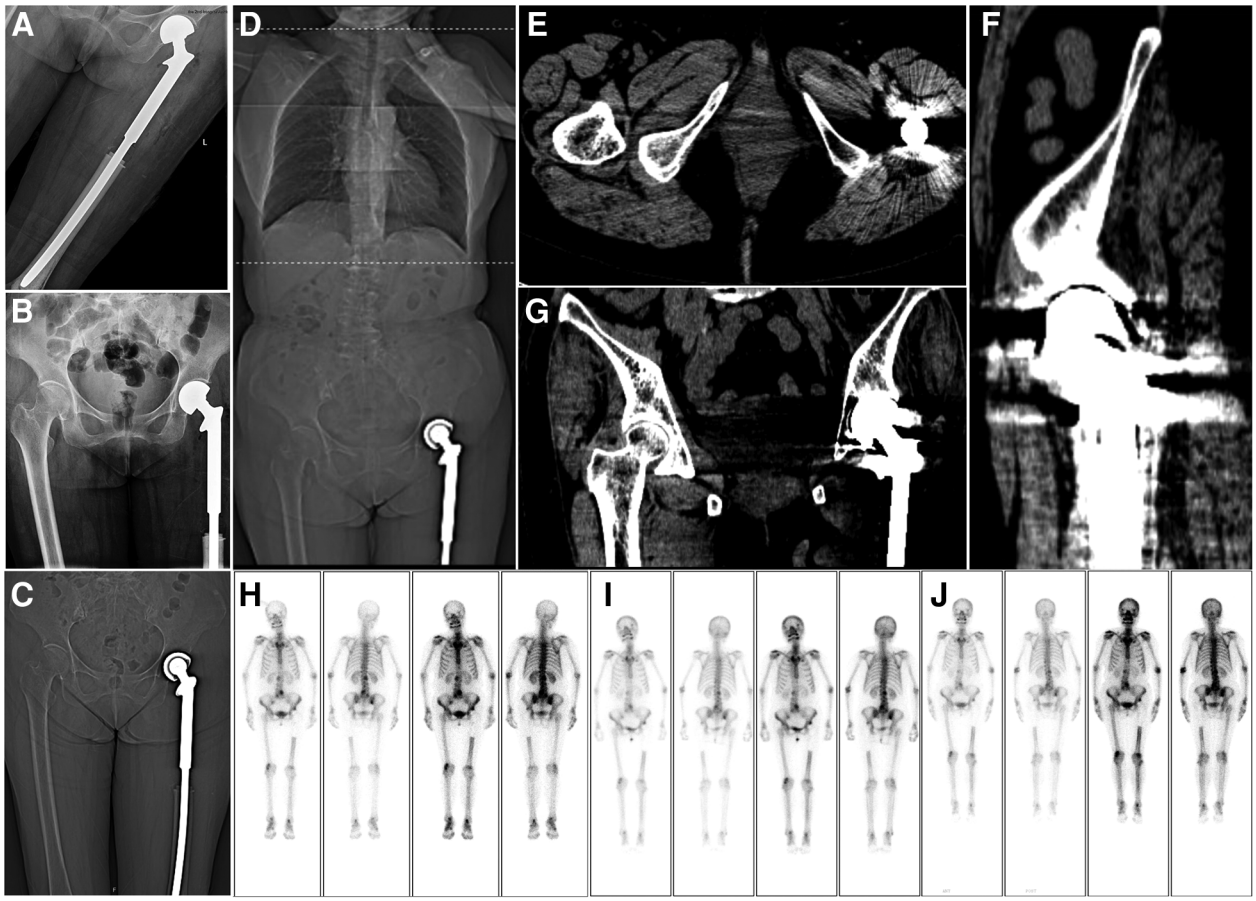

FIGURE 4
Postoperative imaging. (**A**,**B**) A radiograph of the left hip joint shows that the joint prosthesis is in place 1 week after the operation. (**C**) Coronal view of a computed tomography (CT) scan performed 1 week postoperatively. (**D**–**G**) Chest, abdominal, and pelvic CT examinations at 42 months postoperatively show no obvious metastasis in the lungs. Meanwhile, the joint prosthesis is in place, and there is no obvious recurrence in the local area. (**H**–**J**) After 13, 24, and 32 months postoperatively, whole-body bone scan findings show no obvious recurrence.

protein (desmin), and some are positive for calmodulin (h-caldesmon). These important features of myogenic tumors have important auxiliary value for the diagnosis of LMSB (9, 14). LMSB is often misdiagnosed as metastatic bone leiomyosarcoma, undifferentiated pleomorphic sarcoma (UPS), fibroblastic osteosarcoma, and metastatic sarcomatoid carcinoma (7). Metastatic bone leiomyosarcoma is ruled out by the absence of primary lesions in the gastrointestinal tract or uterus *via* imaging (7, 15). The diagnosis of UPS, also known as high-grade malignant fibrous histiocytotumor, is typically exclusionary. UPS has no fixed morphologic arrangement and is positive for vimentin, CD68, and several other indicators as per immunohistochemistry (25). Therefore, the morphological characteristics and immunohistochemical results of UPS are not specific, though the malignancy of UPS is higher (26). Fibroblastic osteosarcoma tissues are arranged as fibrosarcomatoid structures and appear similar to UPS tissues under light microscopy, as a spindle cell sarcoma. However, focal malignant osteogenesis is observed in fibroblastic osteosarcoma lesions, and bone morphogenetic protein, osteocalcin, and osteoponectin positivity is observed on immunohistochemistry. No markers of myogenic tumors are observed in fibroblastic osteosarcoma lesions, distinguishing them from LMSB (7, 27). And SATB2 is a relatively specific marker of osteosarcoma which is also helpful in differentiating between LMSB and osteosarcoma (7, 27). Metastatic sarcomatoid carcinoma has a unique immunohistochemical feature as it expresses p63 and PAX8 and lacks the markers of myogenic tumors such as SMA and desmin. These characteristics distinguish metastatic sarcomatoid carcinoma from LMSB (7, 28). Previous studies have indicated the absence of malignant osteogenesis in LMSB, though calcification foci may be present, which can be used to distinguish LMSB from other conditions. In this patient, the sections of each part of the tumor were examined carefully, and no malignant osteogenesis was observed, which is consistent with the results of previous studies (7, 10). The lesion reported in this

study presented as a spindle cell sarcoma under microscopy. The patients' immunohistochemistry showed positive staining for SMA, desmin, vimentin, and p53. Metastatic tumors were excluded based on the patient's medical history and imaging results, and osteosarcoma was excluded based on the absence of malignant osteogenesis and positive immunohistochemical myogenic markers. The positive myogenic tumor markers also ruled out the diagnosis of metastatic sarcomatoid carcinoma. As the lesion appeared as a spindle cell sarcoma under light microscopy, the patient was diagnosed with LMSB.

Owing to the extremely low incidence of LMSB, effective treatments and prognostic factors remain unclear (7). Metastasis, delayed operations, and insufficient surgical margins are significantly associated with low overall survival rates (9). Early extensive surgical resection is necessary to overcome these challenges and has been proven to be an effective and radical cure for LMSB (15, 29). Active limb reconstruction can be performed following the extensive debridement of lesions (10). Mori et al. reported that negative surgical margins were associated with 2- and 5-year overall survival rates of 88.5% and 83.6%, respectively, highlighting the importance of surgical treatment and indicating that the clinical results of LMSB are affected by surgical margins (8). In another study, radiotherapy had no significant effects on the patients' postoperative survival (30).

The choice of the surgical method is the primary focus when treating malignant bone tumors. Traditionally, amputation is combined with postoperative chemotherapy (31, 32). Amputation is considered when the tumor involves important vascular and nerve bundles and invades multiple compartments, when a severe pathological fracture is present, when the effect of simple chemotherapy is poor, or when the soft tissue is extensively involved (12). However, in recent years, limb salvage has been conducted more often (12). Currently, clinicians commonly use limb salvage surgical methods, including prosthesis reconstruction with tumor resection and prosthesis replacement and conventional internal fixation with a series of surgical procedures including lesion resection, bone cement filling, and implant fixation (12, 15, 32–38).

However, the revision of internal fixation surgery and prosthesis replacement for patients with malignant bone tumors may be necessary. The reoperation rate following custom-made tumor prosthesis replacement for metastatic bone tumors of the proximal femur may be lower than the reoperation rate following internal fixation. In a previous study, the quality of life of these patients who underwent prosthesis replacement was significantly improved, though the most common complication was prosthetic dislocation (11). The choice of the surgical method requires further studies assessing primary tumors of the proximal femur. The surgical margin is an important factor affecting the survival and prognosis in patients undergoing surgery without evidence of metastasis at the time of diagnosis (8). The purpose of surgery is to completely remove the gross and microscopic tumor tissue lesions, and limb salvage can be considered without reducing the survival rate (12). The incidences of re-fracture, bone nonunion, joint instability, and osteoarthritis are lower after prosthesis replacement than after allogenic bone and joint grafting (13).

The survival rate and prognosis of patients with LMSB are closely related to the diagnostic stage of the disease (12). The 5-year survival rate of patients with stage 1, 2A, and 2B tumors was as high as 60%, and the 10-year survival rate was 43% in a previous study. However, the prognosis of patients with stage 3 tumors was relatively poor, with a survival time of no more than 4 years and a median survival time of only 2 years (12). Therefore, timely diagnoses improve the patients' prognoses (7, 8). The patient in this report had a good prognosis based on the tumor's low stage, a timely diagnosis, and active surgical resection of the tumor.

In conclusion, this report presents a rare case of grade IB LMSB in the trochanteric region of the femur in an older woman. Over the course of this patient's diagnosis and treatment, the pathological diagnosis was confirmed *via* puncture biopsy, and the tumor was graded and staged *via* imaging. The patient's joint function was successfully restored after an expanded tumor resection with negative margins and prosthesis replacement followed by postoperative chemotherapy. At the time of writing this report, the patient remained in a good physical condition with no apparent limitation of her hip functions and no obvious signs of local recurrence or distant metastasis of the tumor. This case report may serve as a reference for the clinical diagnosis and treatment of patients with Enneking grade IB LMSB of the proximal femur.

Patient perspective

At first, the symptoms were too severe, and the pain in my left hip joint was quite unbearable. After the operation, my pain was relieved, and my joint activity improved significantly. However, there were some adverse reactions in the process of postoperative chemotherapy, which were fortunately resolved. I am very satisfied with the effect of the operation, and so far, there has been no recurrence or metastasis. My goal is to live for another 20 years.

Data availability statement

The original contributions presented in the study are included in the article/**Supplementary Material**, further inquiries can be directed to the corresponding author.

Ethics statement

Written informed consent was obtained from the individual(s) for the publication of any potentially identifiable images or data included in this article.

Author contributions

JJ was responsible for project guidance and final review. JJ and LC developed the study design. ZW and LC wrote this article. SYu and MS assisted with data collection and manuscript editing. SYe and QC drafted the manuscript summary and helped with the associated analysis. All authors contributed to the article and approved the submitted version.

Funding

This work was supported by the National Natural Science Foundation of China (No. A81702656).

Acknowledgments

We would like to thank the clinicians at the Department of Orthopedics and the Department of Pathology at The Second Hospital of Anhui Medical University. All authors sincerely appreciate Editage for helping with language polishing and editorial assistance.

Conflict of interest

The authors declare that the research was conducted in the absence of any commercial or financial relationships that could be construed as a potential conflict of interest.

Publisher's note

All claims expressed in this article are solely those of the authors and do not necessarily represent those of their affiliated organizations, or those of the publisher, the editors and the reviewers. Any product that may be evaluated in this article, or claim that may be made by its manufacturer, is not guaranteed or endorsed by the publisher.

Supplementary material

The Supplementary Material for this article can be found online at: https://www.frontiersin.org/articles/10.3389/fsurg.2022.1045307/full#supplementary-material.

References

1. Evans DM, Sanerkin NG. Primary leiomyosarcoma of bone. *J Pathol Bacteriol.* (1965) 90:348–50. doi: 10.1002/path.1700900145

2. Siegel RL, Miller KD, Jemal A. Cancer statistics, 2016. *CA Cancer J Clin.* (2016) 66:7–30. doi: 10.3322/caac.21332

3. Rigopoulou A, Vlychou M, Ostlere SJ, Gibbons CLMH, Athanasou NA. A primary leiomyosarcoma of bone containing pseudoepithelial plexiform elements. *Skeletal Radiol.* (2007) 36:791–6. doi: 10.1007/s00256-007-0301-y

4. Potsi M, Stavrinou P, Patsinakidis N, Hatzibougias D, Foroglou N, Karayanopoulou G, et al. Primary osseous leiomyosarcoma of the spine: a rare entity—case report and review of the literature. *J Neurol Surg A Cent Eur Neurosurg.* (2012) 73:238–42. doi: 10.1055/s-0032-1313588

5. Adelani MA, Schultenover SJ, Holt GE, Cates JMM. Primary leiomyosarcoma of extragnathic bone: clinicopathologic features and reevaluation of prognosis. *Arch Pathol Lab Med.* (2009) 133:1448–56. doi: 10.5858/133.9.1448

6. Recine F, Bongiovanni A, Casadei R, Pieri F, Riva N, De Vita A, et al. Primary leiomyosarcoma of the bone: a case report and a review of the literature. *Medicine.* (2017) 96:e8545. doi: 10.1097/MD.0000000000008545

7. Wang GY, Lucas DR. Primary leiomyosarcoma of bone: review and update. *Arch Pathol Lab Med.* (2019) 143:1332–7. doi: 10.5858/arpa.2019-0375-RA

8. Mori T, Nakayama R, Endo M, Hiraga H, Tomita M, Fukase N, et al. Forty-eight cases of leiomyosarcoma of bone in Japan: a multicenter study from the Japanese musculoskeletal oncology group. *J Surg Oncol.* (2016) 114:495–500. doi: 10.1002/jso.24322

9. Hanafy M, Schwonzen M, Kuhnen C, Schley B, Wilke A. Primary leiomyosarcoma of the distal fibula: a case report and review of the literature. *Orthop Rev.* (2018) 9:7236. doi: 10.4081/or.2017.7236

10. Zumárraga JP, Arouca MM, Baptista AM, Caiero MT, Rubio DE, de Camargo OP. Primary leiomyosarcoma of bone: clinicopathologic and prognostic factors analysis in a single institution. *Acta Ortop Bras.* (2019) 27:152–5. doi: 10.1590/1413-785220192703215676

11. Di Martino A, Martinelli N, Loppini M, Piccioli A, Denaro V. Is endoprosthesis safer than internal fixation for metastatic disease of the proximal femur? A systematic review. *Injury.* (2017) 48:S48–54. doi: 10.1016/S0020-1383(17)30658-7

12. Brewer P, Sumathi V, Grimer RJ, Carter SR, Tillman RM, Abudu A, et al. Primary leiomyosarcoma of bone: analysis of prognosis. *Sarcoma.* (2012) 2012:636849. doi: 10.1155/2012/636849

13. Grinberg SZ, Posta A, Weber KL, Wilson RJ. Limb salvage and reconstruction options in osteosarcoma. *Adv Exp Med Biol.* (2020) 1257:13–29. doi: 10.1007/978-3-030-43032-0_2

14. Rekhi B, Kaur A, Puri A, Desai S, Jambhekar NA. Primary leiomyosarcoma of bone—a clinicopathologic study of 8 uncommon cases with immunohistochemical analysis and clinical outcomes. *Ann Diagn Pathol.* (2011) 15:147–56. doi: 10.1016/j.anndiagpath.2010.11.006

15. Gusho CA, Blank AT, Gitelis S. Comparison of clinicopathological features and outcomes in patients with primary leiomyosarcoma of bone and soft tissue. *J Surg Oncol.* (2021) 123:1274–83. doi: 10.1002/jso.26404

16. Frings A, Leithner A, Liegl-Atzwanger B. Leiomyosarcoma of bone: a case report. *Case Rep Med.* (2011) 2011:980257. doi: 10.1155/2011/980257

17. Bao RX. Radiologic-pathologic diagnosis of primary leiomyosarcoma of bone (a report of 7 cases). *Zhonghua Fang She Xue Za Zhi.* (1987) 21:82–5. PMID: 2961527

18. Petra M, Gibbons CLMH, Athanasou NA. Leiomyosarcoma of bone arising in association with a bone infarct. *Sarcoma.* (2002) 6:47–50. doi: 10.1080/13577140220127558

19. Goto T, Ishida T, Motoi N, Yokokura S, Kawano H, Yamamoto A, et al. Primary leiomyosarcoma of the femur. *J Orthop Sci.* (2002) 7:267–73. doi: 10.1007/s007760200045

20. Nguyen JC, Baghdadi S, Pogoriler J, Guariento A, Rajapakse CS, Arkader A. Pediatric osteosarcoma: correlation of imaging findings with histopathologic features, treatment, and outcome. *Radiographics*. (2022) 42:1196–213. doi: 10.1148/rg.210171

21. Weber M-A, Baur-Melnyk A. Radiological diagnosis of multiple myeloma: role of imaging and the current S3 guideline. *Radiologe*. (2022) 62:35–43. doi: 10.1007/s00117-021-00943-y

22. Atalar H, Gunay C, Yildiz Y, Saglik Y. Primary leiomyosarcoma of bone: a report on three patients. *Clin Imaging*. (2008) 32:321–5. doi: 10.1016/j.clinimag.2007.10.022

23. Sakumoto M, Takahashi M, Oyama R, Takai Y, Kito F, Shiozawa K, et al. Establishment and proteomic characterization of NCC-LMS1-C1, a novel cell line of primary leiomyosarcoma of the bone. *Jpn J Clin Oncol*. (2017) 47:954–61. doi: 10.1093/jjco/hyx096

24. Yang Y, Ma L, Li L, Liu H. Primary leiomyosarcoma of the spine: a case report and literature review. *Medicine*. (2017) 96:e6227. doi: 10.1097/MD.0000000000006227

25. Matushansky I, Charytonowicz E, Mills J, Siddiqi S, Hricik T, Cordon-Cardo C. MFH classification: differentiating undifferentiated pleomorphic sarcoma in the 21st century. *Expert Rev Anticancer Ther*. (2009) 9:113544. doi: 10.1586/era.09.76

26. Goldblum JR. An approach to pleomorphic sarcomas: can we subclassify, and does it matter? *Mod Pathol*. (2014) 27:S39–46. doi: 10.1038/modpathol.201.174

27. Yoshikawa H, Nakase T, Myoui A, Ueda T. Bone morphogenetic proteins in bone tumors. *J Orthop Sci*. (2004) 9:334–40. doi: 10.1007/s00776-004-0764-9

28. Yu W, Yang L, Wang J, Gui L, Li W, Liu Z, et al. Case report: first case of consolidation immunotherapy after definitive chemoradiotherapy in mediastinal lymph node metastatic sarcomatoid carcinoma. *Front Oncol*. (2021) 11:788856. doi: 10.3389/fonc.2021.788856

29. Gootee J, Sioda N, Aurit S, Curtin C, Silberstein P. Important prognostic factors in leiomyosarcoma survival: a national cancer database (NCDB) analysis. *Clin Transl Oncol*. (2020) 22:860–9. doi: 10.1007/s12094-019-02196-7

30. Antonescu CR, Erlandson RA, Huvos AG. Primary leiomyosarcoma of bone: a clinicopathologic, immunohistochemical, and ultrastructural study of 33 patients and a literature review. *Am J Surg Pathol*. (1997) 21:1281–94. doi: 10.1097/00000478-199711000-00003

31. Lapica H, Ozery M, Raju H, Castro G, de la Vega P R, Barengo NC. The associations between racial disparities, health insurance, and the use of amputation as treatment for malignant primary bone neoplasms in the US: a retrospective analysis from 1998 to 2016. *Int J Environ Res Public Health*. (2022) 19:6289. doi: 10.3390/ijerph19106289

32. Gaillard J, Fouasson-Chailloux A, Eveno D, Bokobza G, Da Costa M, Heidar R, et al. Rotationplasty salvage procedure as an effective alternative to femoral amputation in an adult with a history of osteosarcoma: a case report and review. *Front Surg*. (2021) 8:820019. doi: 10.3389/fsurg.2021.820019

33. Feng H, Wang J, Xu J, Chen W, Zhang Y. The surgical management and treatment of metastatic lesions in the proximal femur: a mini review. *Medicine*. (2016) 95:e3892. doi: 10.1097/MD.0000000000003892

34. Liu T, Guo X, Zhang X, Li Z, Zhang Q. Reconstruction with pasteurized autograft for primary malignant bone tumor of distal tibia. *Bull Cancer*. (2012) 99:87–91. doi: 10.1684/bdc.2012.1626

35. Wang S, Luo Y, Zhang Y, Wang Y, Zheng C, Tu C, et al. Case report: reconstruction of medialis malleolus (1/4 of the ankle joint) after resection of distal tibia tumor with an uncemented three-dimensional-printed prosthesis. *Front Surg*. (2022) 9:844334. doi: 10.3389/fsurg.2022.844334

36. Kameda N, Kagesawa M, Hiruta N, Akima M, Ohki M, Matsumoto T. Primary leiomyosarcoma of bone. A case report and review of the literature. *Acta Pathol Jpn*. (1987) 37:291–303. PMID: 3300160

37. Bouaziz MC, Chaabane S, Mrad K, Oueslati S, Bellassoued A, Ladeb MF, et al. Primary leiomyosarcoma of bone: report of 4 cases. *J Comput Assist Tomogr*. (2005) 29:254–9. doi: 10.1097/01.rct.0000159581.54555.08

38. Miura K, Hatori M, Hosaka M, Kokubun S, Watanabe M, Ehara S. Primary leiomyosarcoma with the invasion into the intertrabecular space of bone: a case report and the review of the literatures. *Clin Imaging*. (2001) 25:209–14. doi: 10.1016/s0899-7071(01)00249-2

frontiers | Frontiers in Surgery

TYPE Original Research
PUBLISHED 10 January 2023
DOI 10.3389/fsurg.2022.954517

Check for updates

OPEN ACCESS

EDITED BY
Paphon Sa-ngasoongsong,
Mahidol University, Thailand

REVIEWED BY
Rui He,
Army Medical University, China
Lin Zheng,
Zhejiang University, China

*CORRESPONDENCE
Bin Yang
✉ yangbin@pkuih.edu.cn

SPECIALTY SECTION
This article was submitted to Orthopedic Surgery, a section of the journal Frontiers in Surgery

RECEIVED 27 May 2022
ACCEPTED 16 December 2022
PUBLISHED 10 January 2023

CITATION
Wang J, Wang X, Sun B, Yuan L, Zhang K and Yang B (2023) 3D-printed patient-specific instrumentation decreases the variability of patellar height in total knee arthroplasty. Front. Surg. 9:954517. doi: 10.3389/fsurg.2022.954517

COPYRIGHT
© 2023 Wang, Wang, Sun, Yuan, Zhang and Yang. This is an open-access article distributed under the terms of the Creative Commons Attribution License (CC BY). The use, distribution or reproduction in other forums is permitted, provided the original author(s) and the copyright owner(s) are credited and that the original publication in this journal is cited, in accordance with accepted academic practice. No use, distribution or reproduction is permitted which does not comply with these terms.

3D-printed patient-specific instrumentation decreases the variability of patellar height in total knee arthroplasty

Junfeng Wang, Xiaohua Wang, Bin Sun, Liang Yuan, Ke Zhang and Bin Yang*

Department of Orthopedics, Peking University International Hospital, Beijing, China

Objective: Three-dimensionally (3D) printed patient-specific instrumentation (PSI) might help in this regard with individual design and more accurate osteotomy, but whether the utility of such instrumentations minimizes the variability of patellar height in total knee arthroplasty (TKA) and the reasons for this effect are unknown. Our aim is to compare and analyze the variability of patellar height with PSI and conventional instrumentation (CI) in TKA.

Methods: Between March 2018 and November 2021, 215 patients with severe knee osteoarthritis who were treated with primary unilateral TKA were identified for this observational study. The patients were divided into the CI-TKA group and PSI-TKA group according to the osteotomy tools used in TKA. Preoperative and postoperative radiographic parameters including hip–knee–ankle angle (HKA), posterior tibial slope (PTS), Insall–Salvati ratio, modified Caton–Deschamps (mCD) ratio, anterior condylar offset (ACO), and posterior condylar offset (PCO) were evaluated.

Results: The groups were similar in patients' demographic data, clinical scores, and radiographic parameters preoperatively. Overall, according to the results of the Insall–Salvati ratio, postoperative patellar height reduction was noted in 140 patients (65.1%). Interestingly, the variability of patellar height was smaller in the PSI-TKA group. Radiographic evaluation revealed that the Insall–Salvati ratio after TKA had a minor change in the PSI-TKA group ($p = 0.005$). Similarly, the mCD ratio after TKA also had a minor change in the PSI-TKA group ($p < 0.001$). Compared to those in the CI-TKA group, the ACO ($p < 0.001$) and PCO ($p = 0.011$) after TKA had a minor change in the PSI-TKA group, but no minor PTS change ($p = 0.951$) was achieved in the PSI-TKA group after TKA. However, even with 3D-printed patient-specific instrumentation, there were still significant reductions in patellar height, ACO, PCO, and PTS after TKA ($p < 0.001$).

Conclusion: The variability of patellar height was sufficiently minimized with more accurate anterior and posterior femoral condyle osteotomy when 3D printed PSI was used. Furthermore, there was a trend in over-resection of the femoral anterior and posterior condyle and a marked reduction in PTS during TKA, which could lead to a change in patellar height and might result in more patellofemoral complications following TKA.

Level of evidence: Level II.

KEYWORDS

total knee arthroplasty, patient-specific instrumentation, anterior condylar offset, posterior condylar offset, posterior tibial slope

Introduction

The patella is an essential component of the biomechanics of the knee joint; optimal patellar position improves quadriceps efficiency by increasing the moment arm of the knee extensor mechanism (1). Patella baja or alta can cause an alteration in the normal biomechanics of the knee joint and can give rise to anterior knee pain, limited range of movement (ROM), knee extensor lag, and reduced functional scores (2–4).

Total knee arthroplasty (TKA) is a relatively common operation. Although beneficial to the well-being of the patient, it may cause biomechanical changes and complications in the patellofemoral joint (5). During TKA, the patellar height may be changed due to abnormal femoral or tibial cuts made during the operation, excessive soft tissue release, abnormal placement of prosthetic components, and excessive resection of the infrapatellar fat pad (5, 6). Therefore, minimizing the variation of patellar height after TKA is crucial for better postoperative satisfaction and fewer patellofemoral joint complications.

Computer tomography (CT)-based three-dimensionally (3D) printed patient-specific instrumentation (PSI) is an innovative alternative to conventional instrumentation (CI) for TKA (7). Based on the reconstructed 3D images, surgeons can determine the size and position of the implant, which is helpful for an individual design according to patient's anatomical characteristics in the femur and tibia, to adapt to the patient's special anatomical shape and variation and increase the accuracy of osteotomy (8–11). These results suggest that there might be some clinical value of 3D printed patient-specific instrumentation for reducing the difference between the prosthesis position and patient's preoperative anatomy in TKA. However, to our best knowledge, there are no studies on the additional value of 3D printed patient-specific instrumentation for decreasing the variability of patellar height in TKA. Furthermore, to our knowledge, there are no studies evaluating and analyzing the reasons for reducing the variability of patellar height for 3D printed patient-specific instrumentation.

While comparing 3D printed patient-specific instrumentation with conventional instrumentation in TKA, we aimed to answer three main study questions: (1) Does the overall patellar height change after TKA? (2) Does the variability of patellar height vary between 3D printed patient-specific instrumentation and conventional instrumentation in TKA? (3) Does the reduction in the variability of patellar height stem from restraining the variation in the anterior condylar offset (ACO), posterior condylar offset (PCO), and posterior tibial slope (PTS) with 3D printed patient-specific instrumentation in TKA?

Patients and methods

Study design

A case–control study design was utilized. From March 2018 to November 2021, 215 patients diagnosed with severe knee osteoarthritis who were treated with primary unilateral TKA were identified for this observational study. Patients with inflammatory arthritis, post-traumatic arthritis, knee valgus deformities, severe extra-articular deformities, or poor imaging quality were excluded. There were 27 men and 188 women. The mean age of patients was 67.7 ± 6.0 years (range 51–81 years), and the mean body mass index (BMI) was 27.2 ± 3.8 kg/m^2 (range 18.0–38.0 kg/m^2). All patients received and accepted informed consent to participate in this study, which was approved by the medical ethics committee of Peking University International Hospital [2020-036(BMR)].

This was a real-world study, and the surgical grouping was at the discretion of the patient. The patients were divided into the conventional instrumentation (CI) group and the patient-specific instrumentation (PSI) group according to the osteotomy tools used in TKA. The CI-TKA group was performed using a GII fixed-bearing PS total knee system (Smith & Nephew, USA), and PSI-TKA group was performed using an A3 fixed-bearing PS total knee system (AK Medical, China).

Preoperative clinical variables including age, sex, affected side, body mass index, range of motion (ROM), Knee Society score (KSS), Knee Society function score (KSFS) (12), and Western Ontario and McMaster Universities Osteoarthritis Index (WOMAC) (13) were recorded.

Radiographic assessment

All patients underwent radiographic assessment before and after surgery, and the radiographic technique was performed following standardized procedures (14). A full-length weight-bearing anteroposterior radiograph of the lower extremity was taken in full extension with the patient standing, the leg extended, and the knee ensured not to be rotated. For lateral radiographs, the medial and lateral femoral condyles were overlapped at approximately 30° of knee flexion to indicate an adequately rotated radiograph. The variables were all measured by two orthopedic surgeons who were blinded to patients' information using a PACS system (Centricity; General Electric, USA), and the average of the two measurements was used for the analysis. Preoperative and postoperative radiographic parameters including hip–knee–ankle angle (HKA), posterior tibial slope (PTS) (15), Insall–Salvati ratio (16), modified Caton–Deschamps (mCD) ratio (17), anterior condylar offset (ACO), and posterior condylar offset (PCO) (18) were evaluated according to the method in the previous literature (**Figure 1**).

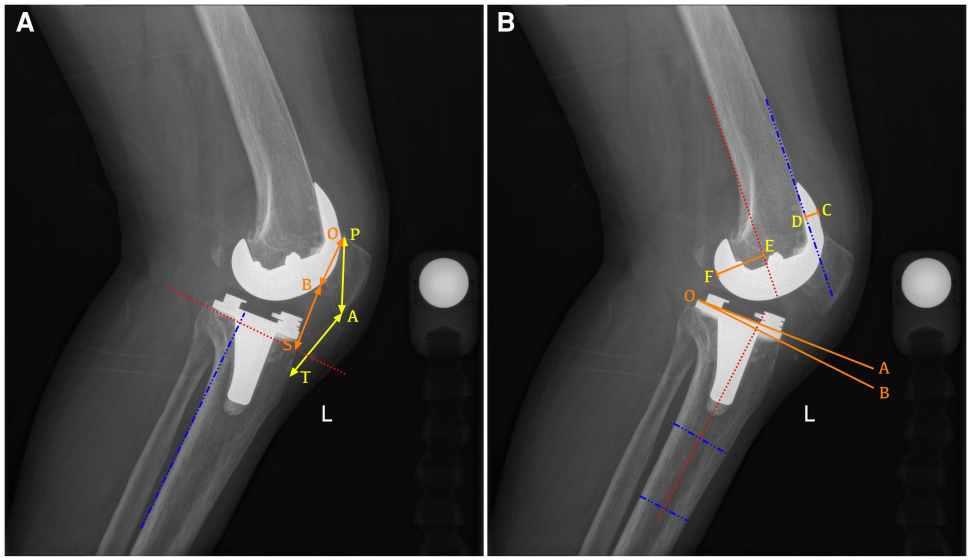

FIGURE 1
Radiographic measurement of the lateral view after PS-TKA. (A) Example of a radiograph demonstrating how to measure the Insall–Salvati ratio (AT/AP) and modified Caton–Deschamps ratio (BS/BO). AT, length of the patellar tendon; AP, longest diagonal length of the patella; B0, length of the articular surface of the patella; BS, distance from the distal portion of the articular surface of the patella (B) to the intersection between the line perpendicular to the tibial posterior cortex elevated at the tip of the fibular head and the tibial anterior cortex (S). (B) Example of a radiograph demonstrating how to measure the proximal anatomic axis posterior tibial slope (the angle between lines AO and BO), the anterior condylar offset (CD, the distance between the anterior femoral cortical margin and the anterior margin of the femoral condyles), and posterior condylar offset (EF, the distance between the posterior femoral cortical margin and the posterior margin of the femoral condyles).

3D printed patient-specific instrumentation

In the PSI-TKA group, prior to surgery, all enrolled patients underwent full-length lower extremity thin-slice CT scanning (SOMATOM Definition AS128, Siemens, Germany) on the affected side, with the scan thickness ≤1 mm. During CT scanning, the affected side leg was in a neutral position, and the patella was upward. The scanning range was from the femoral head to the ankle. Then, the CT scanning data were imported into Mimics 20.0 (Materialise, Belgium) in the DICOM format to reconstruct the model of the femur, tibia, and lower extremity alignment. All 3D models were exported as standard tessellation language files into Unigraphics NX software (Siemens, Germany). The alignment was measured based on anatomic landmarks, and the simulated osteotomy was performed in this software. The osteotomy surfaces of the distal femoral and proximal tibia were designed to be perpendicular to the mechanical axis of the lower extremity, and the coronal osteotomy surfaces of the femoral were designed to be parallel to the anatomical transepicondylar axis. During simulated osteotomy, the medical–engineering interaction was carried out according to patient's individual anatomical characteristics and pathological changes, and the parameters such as the osteotomy volume, prosthesis size, and prosthesis position were repeatedly adjusted until the final prosthesis adaptation was completed. After that, the intraoperative PSI osteotomy guide was printed with an industrial-grade 3D printer (EOS P110, Germany) according to the final preoperative design (**Figures 2A–G**). The printed material for PSI in this study was biocompatible polyamide (PA12) (19).

Surgical procedures

All procedures were performed by one group of experienced surgeons using a fixed-bearing PS total knee system. Patients had combined spinal–epidural anesthesia unless contraindicated by a medical issue. Tourniquet was used for the entire procedure. The incision was adopted with a medial parapatellar approach, the patella was not inverted during the operation, the infrapatellar fat pad was minimally removed, and the patella replacement was not performed. The postoperative analgesia regimens were a cocktail of periarticular injection combined with femoral nerve block analgesia, and the rehabilitation training was completed by the same rehabilitation team.

In the CI-TKA group, distal femoral resection was performed using the intramedullary technique according to the femoral valgus angle. Femoral rotation was determined by the posterior femoral condylar axis with a 3° external rotation combined with double-checking with Whiteside's line and patient's soft tissue balance. The proximal tibial resection was performed by the extramedullary technique. The tibial



FIGURE 2
Design and intraoperative application of 3D printed patient-specific instrumentations. (**A–D**) CT-based preoperative planning of femoral and tibial prosthetic implant for anatomic reconstruction. (**E**) Reconstructed models of the patient's distal femur and proximal tibia, including markers for the location of the intraoperative osteotomy. (**F,G**) Confirming the good fit of 3D printed patient-specific instrumentations. (**H,I**) Intraoperative positioning and application of 3D printed patient-specific instrumentations. (**J**) Real-time comparison of preoperative designed osteotomy volume and actual osteotomy volume.

component with an asymmetric tibial tray was rotated by the functional alignment method. After osteotomy, flexion and extension gap balancing was performed using spacer blocks to obtain equally symmetric gaps.

In the PSI-TKA group, after the femoral condyle was exposed, a custom curette was used to remove the cartilage on the anterior surface of the femoral condyle at the positioning point of the osteotomy guide so that the osteotomy guide was close to the subchondral bone. When the osteotomy guide was confirmed to be in good fit with the femoral condyle, positioning nails were implanted through the holes and then completed the distal femur osteotomy. The positioning nails in the distal femur were parallel to the anatomical transepicondylar axis (Figure 2H). The external rotatory osteotomy of the distal femur with the 5-in-1 metal cutting block was fixed according to the positioning of nails previously implanted on the distal femur. Then, the cartilage at the positioning point of the tibial plateau was removed, and the osteotomy guide was placed close to the subchondral bone to complete the proximal tibia osteotomy (Figures 2I,J). The remaining procedures were then carried out like the CI-TKA group.

Statistical analysis

All data were analyzed using GraphPad Prism (version 9; GraphPad Software, USA). Continuous data were presented as a mean ± standard deviation. The Shapiro–Wilk test was used to test continuous variables for normal distribution. For continuous variables with a normal distribution, the comparison between groups was conducted using independent samples *t*-test or paired samples *t*-test; for continuous variables with non-normal distribution, the comparison between groups was performed using the Mann–Whitney *U* test. Categorical variables were compared between groups using Fisher's exact test. The values were considered significant when the two-tailed *p*-value of the difference was less than 0.05.

Results

General features of patients preoperatively

A total of 215 patients were enrolled in this study, including 76 patients (35.3%) in the CI-TKA group and 139 patients (64.7%) in the PSI-TKA group. Patients' demographics and clinical scores preoperatively are summarized in Table 1. Preoperative radiological data are summarized in Table 2. The patients' demographic data, clinical scores, and radiographic parameters preoperatively revealed no statistically significant differences between the two groups (Tables 1, 2), suggesting that the two groups were similar without significant differences in the baseline characteristics.

TABLE 1 Patients' demographics and clinical scores preoperatively.

Variable	CI-TKA group ($n = 76$)	PSI-TKA group ($n = 139$)	*p* value
Age (years)	67.3 ± 6.1	68.0 ± 6.0	0.396
Gender (male/female)	10/66	17/122	0.844
Affected side (left/right)	36/40	68/71	0.828
BMI (kg/m^2)	27.4 ± 3.8	27.1 ± 3.8	0.718
Preoperative ROM (°)	99.2 ± 23.8	99.5 ± 22.3	0.841
Preoperative KSS	51.4 ± 22.0	52.2 ± 19.4	0.796
Preoperative KSFS	52.4 ± 17.5	52.4 ± 18.4	0.824
Preoperative WOMAC	45.8 ± 20.0	48.6 ± 18.4	0.302

CI-TKA, total knee arthroplasty with traditional instruments; PSI-TKA, total knee arthroplasty with patient-specific instrumentation; BMI, body mass index; ROM, range of motion; KSS, American Knee Society knee score; KSFS, American Knee Society function score; WOMAC, Western Ontario and McMaster Universities Osteoarthritis Index.

Variability of patellar height after TKA

Overall, the patellar height after TKA was significantly lower than the preoperative patellar height (Figures 3A,B). According to the results of the Insall–Salvati ratio, the postoperative patellar height reduction was noted in 140 patients (65.1%). Among them, 87 patients (62.6%) in the PSI-TKA group and 53 patients (69.7%) in the CI-TKA group showed postoperative patellar height reduction. There was no statistical difference in the composition ratio of patellar height reduction between the two groups ($p = 0.369$). The Insall–Salvati ratio was 1.11 ± 0.12 preoperatively and reduced to 1.08 ± 0.12 after TKA ($p < 0.001$, Figure 3A). Similarly, the mCD ratio was 1.39 ± 0.14 preoperatively and reduced to 1.34 ± 0.16 after TKA ($p < 0.001$, Figure 3B).

Interestingly, the variability of patellar height in the PSI-TKA group was smaller (Figures 3C,D). Radiographic

TABLE 2 Preoperative radiographic parameters.

Parameters	CI-TKA group ($n = 76$)	PSI-TKA group ($n = 139$)	*p* value
Preoperative HKA angle (°)	168.4 ± 5.5	169.0 ± 5.1	0.539
Preoperative PTS (°)	11.0 ± 4.4	10.9 ± 3.6	0.816
Preoperative ACO (mm)	8.2 ± 2.0	8.1 ± 2.0	0.611
Preoperative PCO (mm)	33.2 ± 5.1	32.7 ± 4.0	0.406
Preoperative Insall–Salvati ratio	1.1 ± 0.1	1.1 ± 0.1	0.955
Preoperative mCD ratio	1.4 ± 0.1	1.4 ± 0.1	0.957

CI-TKA, total knee arthroplasty with traditional instruments; PSI-TKA, total knee arthroplasty with patient-specific instrumentation; HKA, hip–knee–ankle angle; PTS, posterior tibial slope; ACO, anterior condylar offset; PCO, posterior condylar offset; mCD, modified Caton–Deschamps.

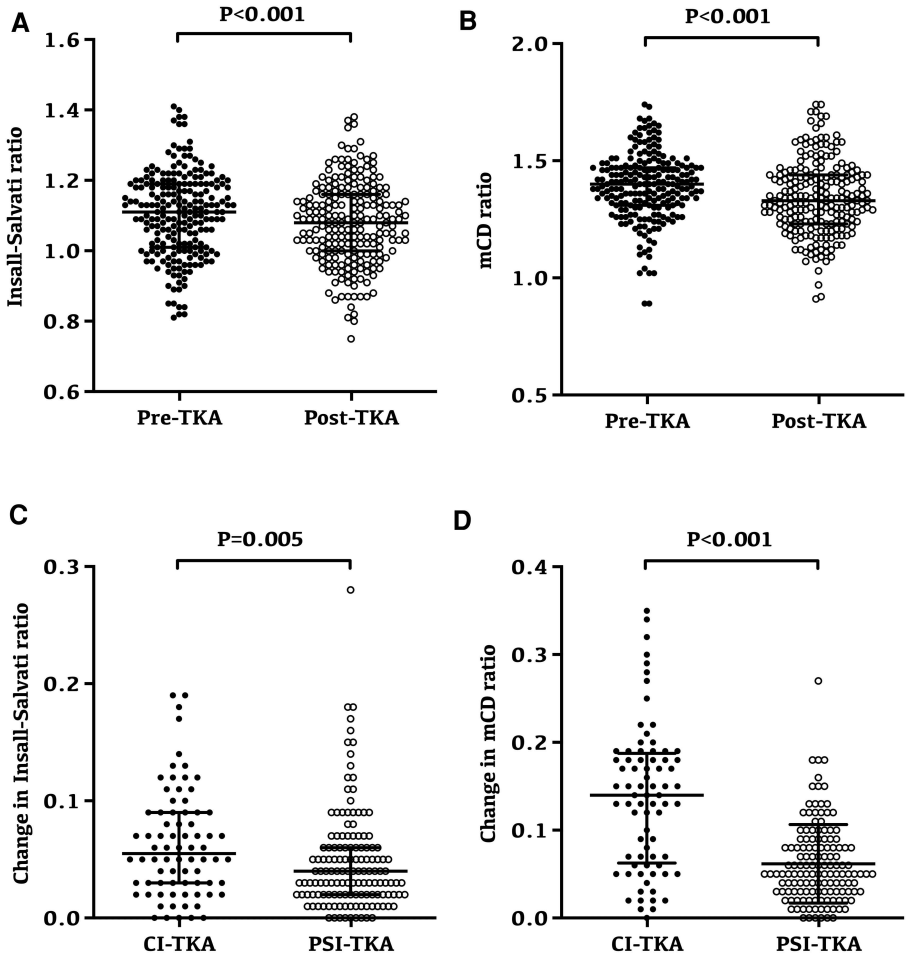

FIGURE 3
Changes and variability of patellar height following TKA. (**A**) Preoperative and postoperative Insall–Salvati ratio for all patients; the Insall–Salvati ratio was 1.11 ± 0.12 preoperatively and reduced to 1.08 ± 0.12 after TKA ($p < 0.001$). (**B**) Preoperative and postoperative modified Caton–Deschamps ratio for all patients; the modified Caton–Deschamps ratio was 1.39 ± 0.14 preoperatively and reduced to 1.34 ± 0.16 after TKA ($p < 0.001$). (**C**) Insall–Salvati ratio after TKA had a minor change in the PSI-TKA group ($p = 0.005$). (**D**) Modified Caton–Deschamps ratio after TKA also had a minor change in the PSI-TKA group ($p < 0.001$).

evaluation revealed that the Insall–Salvati ratio after TKA had a minor change in the PSI-TKA group ($p = 0.005$, Figure 3C), which was 0.05 ± 0.04 in the PSI-TKA group and 0.06 ± 0.05 in the CI-TKA group. Similarly, the mCD ratio after TKA also had a minor change in the PSI-TKA group ($p < 0.001$, Figure 3D), which was 0.06 ± 0.04 in the PSI-TKA group and 0.14 ± 0.08 in the CI-TKA group.

Changes of ACO and PCO after TKA

Overall, both ACO and PCO were significantly reduced after TKA (Figures 4A,B). The ACO was 8.14 ± 2.01 mm preoperatively and reduced to 7.29 ± 2.21 mm after TKA ($p < 0.001$, Figure 4A). Similarly, the PCO was 32.87 ± 4.40 mm preoperatively and reduced to 30.39 ± 3.60 mm after TKA ($p < 0.001$, Figure 4B).

Radiographic evaluation revealed that the ACO after TKA had a minor change in the PSI-TKA group ($p < 0.001$, Figure 4C), which was 1.67 ± 1.37 mm in the PSI-TKA group and 2.50 ± 1.78 mm in the CI-TKA group. Moreover, the PCO after TKA also had a smaller change in the PSI-TKA group ($p = 0.011$, Figure 4D), which was 3.64 ± 2.88 mm in the PSI-TKA group and 4.89 ± 3.43 in the CI-TKA group.

Change of PTS after TKA

Overall, the PTS after TKA was significantly lower than that before the surgery, which was 10.92° ± 3.88° preoperatively and reduced to 3.78° ± 2.79° after TKA ($p < 0.001$, Figure 5A).

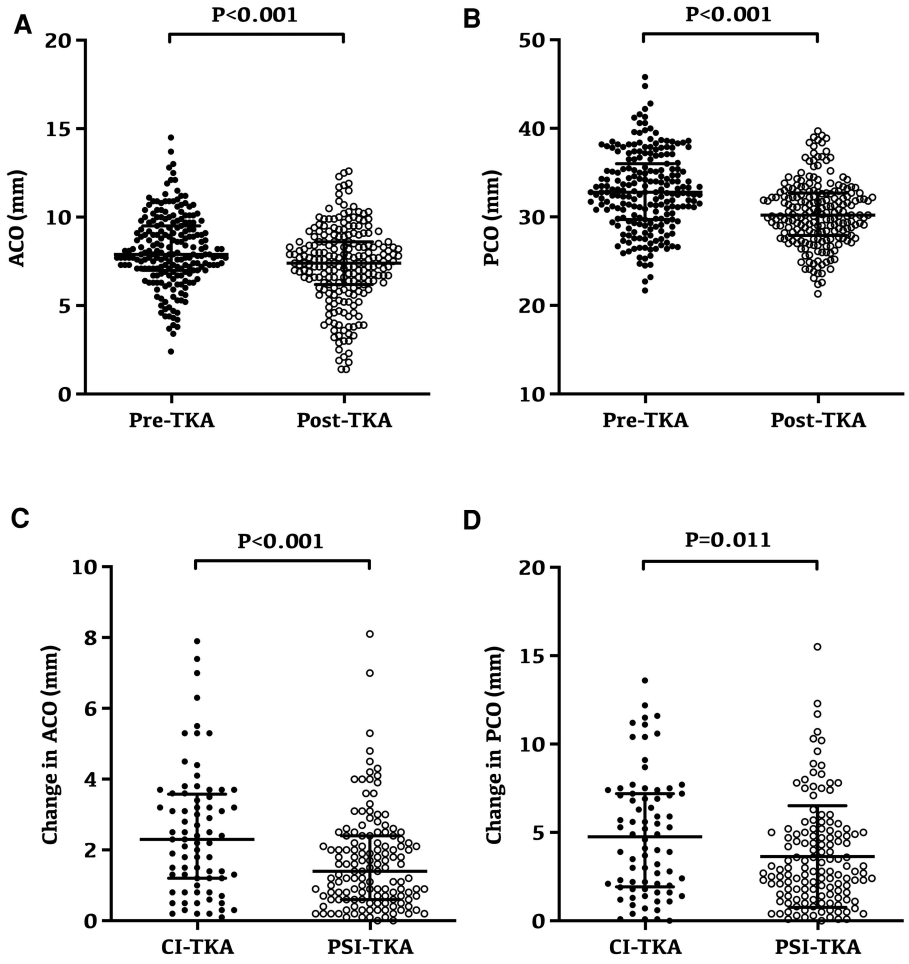

FIGURE 4
Changes and variability of anterior condylar offset and posterior condylar offset following TKA. (**A**) Preoperative and postoperative anterior condylar offset for all patients; the anterior condylar offset was 8.14 ± 2.01 mm preoperatively and reduced to 7.29 ± 2.21 mm after TKA ($p < 0.001$). (**B**) Preoperative and postoperative posterior condylar offset for all patients; the posterior condylar offset was 32.87 ± 4.40 mm preoperatively and reduced to 30.39 ± 3.60 mm after TKA ($p < 0.001$). (**C**) Anterior condylar offset after TKA had a minor change in the PSI-TKA group ($p < 0.001$). (**D**) Posterior condylar offset after TKA had a minor change in the PSI-TKA group ($p = 0.011$).

However, the radiographic evaluation revealed no significant difference in the change of PTS after TKA between the two groups ($p = 0.951$, Figure 5B).

Discussion

The most important finding of this study was that the variability of patellar height was sufficiently minimized with accurate anterior and posterior femoral condyle osteotomy in the PSI-TKA group; this replied to our second and third study questions. However, although the variability of patellar height was less in the PSI-TKA group, the postoperative Insall–Salvati ratio and mCD ratio declined in both groups; this replied to our first study question. The reduction in the variability of patellar height stemmed from restraining the variation of the ACO and PCO in the PSI-TKA group but had no correlation to the PTS; this also replied to our third study question.

Many previous studies have proved that the maintenance of patella height was very important in TKA. The change of patella height could cause abnormal patella trajectory; cause a series of symptoms related to the patellofemoral joint after TKA; affect the ROM of the knee, postoperative satisfaction, and functional scores; and even require knee revision surgery in severe cases (2–4, 20). In TKA, there is a tendency to vary the patella height due to three main reasons: The first is overstuffing or understuffing in the patellofemoral joint, usually due to the inappropriate size of femoral components, artificially changing the position of femoral components (anterior-posterior position or flexion angle) to prevent notching in the anterior femoral cortex, so that the ACO after TKA is

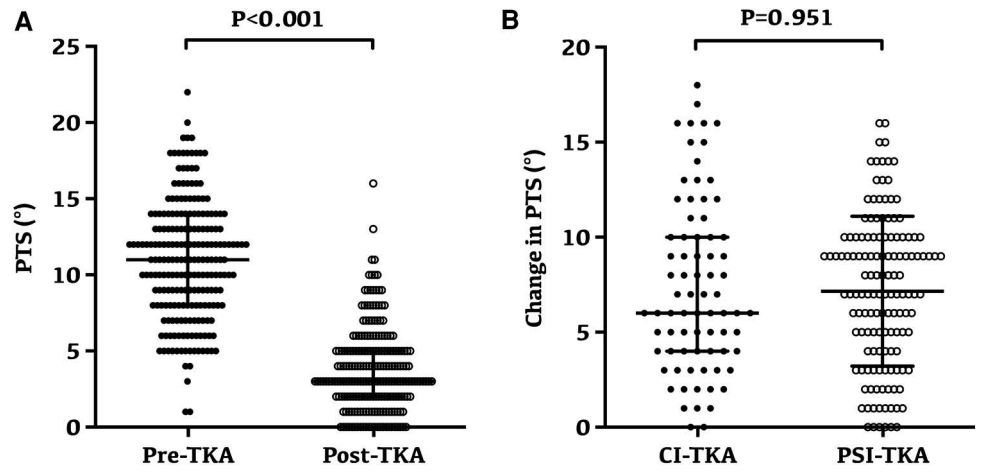

FIGURE 5
Changes and variability of posterior tibial slope following TKA. (**A**) Preoperative and postoperative posterior tibial slope for all patients; the posterior tibial slope was 10.92° ± 3.88° preoperatively and reduced to 3.78° ± 2.79° after TKA ($p < 0.001$). (**B**) No significant difference in the change of PTS after TKA between the two groups ($p = 0.951$).

inconsistent with the original size before surgery (21). Second, surgeons have a subjective tendency to overly aggressive distal femoral resection to correct severe preoperative flexion contractures (5). The third is the relatively larger flexion space compared to the extension space when postoperative PCO is decreased or postoperative PTS is increased due to design or intraoperative manipulation issues (3).

3D printed patient-specific instrumentation provides a new solution for achieving neutral alignment in TKA (7). Surgeons can determine the size and position of the implant based on the reconstructed 3D images of full-length lower extremities preoperatively; also, patient-specific cutting blocks can be designed and printed to assist TKA (10). Numerous studies have compared TKA using PSI to TKA performed with CI, proved that PSI could acquire an equivalent or more favorable alignment than CI, such as HKA, alpha, and beta angles (22–24), and improved the accuracy of implant size, positioning, and rotational alignment (25, 26). Whether 3D printed patient-specific instrumentation can reduce the change of patella height while improving the implant accuracy in TKA is still unclear. To the best of our knowledge, none have studied the additional value of 3D printed patient-specific instrumentation for maintaining patella height in TKA.

This study found that the variability of patellar height was sufficiently minimized with accurate anterior and posterior femoral condyle osteotomy when 3D printed patient-specific instrumentation was used. This result suggests that the 3D printed patient-specific instrumentation has the advantage of reducing the change of patellar height after TKA, which is helpful for maintaining patellar height after TKA. However, it is important to note that, even with the 3D printed patient-specific instrumentation, the overall patellar height after TKA was lower than that before the surgery. Therefore, in the preoperative planning and design of TKA, we should not only focus on correcting the alignment of the femoral and tibial components but also pay attention to maintaining the original anatomy of the patients; the latter is very important to maintain the balance of the patient's bone and soft tissue and to get a more natural and original joint feeling after surgery.

ACO is an important factor affecting the stuffing of the patellofemoral joint in TKA. Previous studies showed that femoral components larger or smaller than the anterior condyle resected might lead to the overstuffing or understuffing in the patellofemoral joint and contribute to the alteration in the patellar height (27, 28). This study found a reduced trend in ACO after TKA in both groups. A smaller ACO after TKA might lead to the understuffing in the patellofemoral joint, cause shortening of the patellar tendon and lower patellar height, decrease contact forces in the patellofemoral joint, decrease the moment arm of the knee-extensor mechanism, and ultimately result in a reduction in the moment arm of the knee extensor. Interestingly, this study also found that ACO had a significantly smaller change when 3D printed patient-specific instrumentations were used. It is likely that the reduction in the variability of patellar height might stem from smaller postoperative ACO changes. When 3D printed patient-specific instrumentations were used, based on the patient's preoperative CT data, surgeons could adjust the anteroposterior position of the femoral component during preoperative planning and osteotomy guide design, minimize the ACO changes in TKA, and ultimately reduce its impact on the patellofemoral joint.

PCO is defined as the maximum thickness of the posterior condyle projecting to the tangent of the posterior cortex of the

femoral shaft, which can affect knee ROM during flexion. A 1 mm decrease of PCO may reduce knee flexion by 3.3°–6.2° (29). To avoid impingement of the posterior border between the tibial plateau and femur, PCO should be restored to avoid over-resecting the posterior femoral condyle in TKA (30, 31). However, PCO is not restored using standard instrumentation of different manufacturers, impairing the functional improvements after TKA (32). Consistent with previous studies, our study found a trend in over-resection of the posterior femoral condyle in TKA. Fortunately, compared with conventional instrumentation, this study detected that 3D printed patient-specific instrumentations could achieve a significantly smaller change in the PCO. According to previous studies, a smaller PCO can increase the flexion space of the knee joint, which indirectly affects the patella height after TKA (3). It is likely that the smaller change in the PCO with 3D-printed patient-specific instrumentations during TKA might also contribute to minimizing the variability of patellar height after TKA.

PTS is also an important variable during TKA procedures, which is the posterior inclination of the tibial plateau in the sagittal plane (33). An appropriate PTS is a bony factor contributing to anteroposterior (AP) stability and also provides sufficient space to avoid a tight knee in flexion (34). In TKA, an inappropriate cutting angle of the PTS results in polyethylene wear, component loosening, and posterior cruciate ligament (PCL) strain and even affects the patellofemoral joint (3, 35–37). Previous studies reported a significant correlation between PCO and PTS in the medial compartment, probably serving as a sagittal balance between flexion and stability (38, 39). It is also well known that standard TKA alignment techniques and current prosthetic designs of the knee universally ignore the asymmetry of the articular surface and would not reproduce the anatomy in a high percentage of native knees, which may be the reasons for nonphysiologic, paradoxical kinematics after TKA (40, 41). However, the application of 3D printed patient-specific instrumentations during TKA makes it possible to restore the anatomical structures in PCO and PTS of native knees. However, due to the design characteristics of the prosthesis, it is still necessary to appropriately reduce the PTS during preoperative planning and osteotomy guide design to compensate for the PCO reduction caused by matching the balance of the distal condyle and posterior condyle during femoral osteotomy. Consistent with previous studies, our study demonstrated that the PTS and PCO after TKA were significantly lower than those before the surgery in both groups, which served as a sagittal balance between flexion and stability (decreased PCO, decreased PTS). The results replied to our first hypothesis but only partly. The reduction of PCO and PTS may be mainly to balance the flexion and stability of the knee, but the reduction of ACO is one of the main reasons for the change in patellar height after TKA. These also imply that the medial-pivot concept has a great advantage in reconstructing the proper morphology of the posterior part of the knee joint and obtaining a full range of motion in flexion after TKA (39, 42). Furthermore, this study did not detect a significant difference in PTS between the PSI-TKA group and the CI-PSA group. Therefore, it is likely that the reduction in the variability of patellar height in the PSI-TKA group was not due to restraining the change in PTS.

The present study has several limitations: First, our research was a real-world study not a strictly randomized controlled trial. Although surgeons responsible for imaging measurements were blinded to study design and patients' information, some selection bias might still exist. Second, although we overlapped the medial and lateral femoral condyles on sagittal planes at approximately 30° of knee flexion to standardize the lateral radiographs, the measurement errors by a difference in the rotational position in plain radiographs were inevitable. Third, this study compared two different prostheses, although both were posteriorly stabilized knee prostheses, and previous studies did not find differences in the effects of the two prostheses on ACO, PCO, and PTS. However, the impact of the prosthesis on the patella height cannot be ignored.

Conclusion

This study demonstrated that the variability of patellar height was sufficiently minimized with more accurate anterior and posterior femoral condyle osteotomy when 3D printed patient-specific instrumentation was used. Furthermore, in this study, we also demonstrated a trend in over-resection of the femoral anterior and posterior condyle and a marked reduction in PTS during TKA, which could lead to the change in patellar height and might result in more patellofemoral complications following TKA. These suggest that even with the addition of 3D printed patient-specific instrumentation, the asymmetry of the articular surface would be universally ignored and could not reproduce the anatomy in a high percentage of native knees, which may be the reasons for nonphysiologic, paradoxical kinematics after TKA.

Data availability statement

The raw data supporting the conclusions of this article will be made available by the authors without undue reservation.

Ethics statement

The studies involving human participants were reviewed and approved by the medical ethics committee of Peking University International Hospital [2020-036(BMR)]. The

patients/participants provided their written informed consent to participate in this study.

Author contributions

JW: conception and design, acquisition and analysis of data, and drafting the article. XW: analysis and interpretation of data and drafting the article. BS: image reconstruction. LY: analysis and interpretation of data. KZ: acquisition of data. BY: designed the study and critical review of the manuscript. All authors contributed to the article and approved the submitted version.

Funding

This study was supported by the National Natural Science Foundation of China (81802233) and the Scientific Research Fund of Peking University International Hospital (YN2019ZD05).

Conflict of interest

The authors declare that the research was conducted in the absence of any commercial or financial relationships that could be construed as a potential conflict of interest.

Publisher's note

All claims expressed in this article are solely those of the authors and do not necessarily represent those of their affiliated organizations, or those of the publisher, the editors and the reviewers. Any product that may be evaluated in this article, or claim that may be made by its manufacturer, is not guaranteed or endorsed by the publisher.

References

1. Lenhart RL, Brandon SC, Smith CR, Novacheck TF, Schwartz MH, Thelen DG. Influence of patellar position on the knee extensor mechanism in normal and crouched walking. *J Biomech*. (2017) 51:1–7. doi: 10.1016/j.jbiomech.2016.11.052

2. Bugelli G, Ascione F, Cazzella N, Franceschetti E, Franceschi F, Dell'Osso G, et al. Pseudo-patella baja: a minor yet frequent complication of total knee arthroplasty. *Knee Surg Sports Traumatol Arthrosc*. (2018) 26:1831–7. doi: 10.1007/s00167-017-4828-8

3. Figgie 3rd HE, Goldberg VM, Heiple KG, Moller 3rd HS, Gordon NH. The influence of tibial-patellofemoral location on function of the knee in patients with the posterior stabilized condylar knee prosthesis. *J Bone Joint Surg Am*. (1986) 68:1035–40. doi: 10.2106/00004623-198668070-00009

4. Petersen W, Ellermann A, Gosele-Koppenburg A, Best R, Rembitzki IV, Bruggemann GP, et al. Patellofemoral pain syndrome. *Knee Surg Sports Traumatol Arthrosc*. (2014) 22:2264–74. doi: 10.1007/s00167-013-2759-6

5. Chonko DJ, Lombardi Jr. AV, Berend KR. Patella baja and total knee arthroplasty (TKA): etiology, diagnosis, and management. *Surg Technol Int*. (2004) 12:231–8. PMID: 15455331

6. Gromov K, Korchi M, Thomsen MG, Husted H, Troelsen A. What is the optimal alignment of the tibial and femoral components in knee arthroplasty? *Acta Orthop*. (2014) 85:480–7. doi: 10.3109/17453674.2014.940573

7. Camarda L, D'Arienzo A, Morello S, Peri G, Valentino B, D'Arienzo M. Patient-specific instrumentation for total knee arthroplasty: a literature review. *Musculoskelet Surg*. (2015) 99:11–8. doi: 10.1007/s12306-014-0339-7

8. Chotanaphuti T, Wangwittayakul V, Khuangsirikul S, Foojareonyos T. The accuracy of component alignment in custom cutting blocks compared with conventional total knee arthroplasty instrumentation: prospective control trial. *Knee*. (2014) 21:185–8. doi: 10.1016/j.knee.2013.08.003

9. Hamid KS, Matson AP, Nwachukwu BU, Scott DJ, Mather 3rd RC, DeOrio JK. Determining the cost-savings threshold and alignment accuracy of patient-specific instrumentation in total ankle replacements. *Foot Ankle Int*. (2017) 38:49–57. doi: 10.1177/1071100716667505

10. Kwon OR, Kang KT, Son J, Suh DS, Heo DB, Koh YG. Patient-specific instrumentation development in TKA: 1st and 2nd generation designs in comparison with conventional instrumentation. *Arch Orthop Trauma Surg*. (2017) 137:111–8. doi: 10.1007/s00402-016-2618-2

11. Maus U, Marques CJ, Scheunemann D, Lampe F, Lazovic D, Hommel H, et al. No improvement in reducing outliers in coronal axis alignment with patient-specific instrumentation. *Knee Surg Sports Traumatol Arthrosc*. (2018) 26:2788–96. doi: 10.1007/s00167-017-4741-1

12. Insall JN, Dorr LD, Scott RD, Scott WN. Rationale of the Knee Society clinical rating system. *Clin Orthop Relat Res*. (1989) 248:13–4. PMID: 2805470

13. Bellamy N, Buchanan WW, Goldsmith CH, Campbell J, Stitt LW. Validation study of WOMAC: a health status instrument for measuring clinically important patient relevant outcomes to antirheumatic drug therapy in patients with osteoarthritis of the hip or knee. *J Rheumatol*. (1988) 15:1833–40. PMID: 3068365

14. Colebatch AN, Hart DJ, Zhai G, Williams FM, Spector TD, Arden NK. Effective measurement of knee alignment using AP knee radiographs. *Knee*. (2009) 16:42–5. doi: 10.1016/j.knee.2008.07.007

15. Hashemi J, Chandrashekar N, Gill B, Beynnon BD, Slauterbeck JR, Schutt Jr. RC, et al. The geometry of the tibial plateau and its influence on the biomechanics of the tibiofemoral joint. *J Bone Joint Surg Am*. (2008) 90:2724–34. doi: 10.2106/JBJS.G.01358

16. Insall J, Salvati E. Patella position in the normal knee joint. *Radiology*. (1971) 101:101–4. doi: 10.1148/101.1.101

17. Caton JH, Prudhon JL, Aslanian T, Verdier R. Patellar height assessment in total knee arthroplasty: a new method. *Int Orthop*. (2016) 40:2527–31. doi: 10.1007/s00264-016-3256-6

18. Beldman M, Breugem SJ, van Jonbergen HP. Overstuffing in total knee replacement: no effect on clinical outcomes or anterior knee pain. *Int Orthop*. (2015) 39:887–91. doi: 10.1007/s00264-014-2548-y

19. Hafez MA, Hamza H, Nabeel A. Hospital-based patient-specific templates for total knee arthroplasty: a proof of concept clinical study. *Tech Orthop*. (2018) 33:258–63. doi: 10.1097/BTO.0000000000000253

20. Matsuda S, Miura H, Nagamine R, Urabe K, Hirata G, Iwamoto Y. Effect of femoral and tibial component position on patellar tracking following total knee arthroplasty: 10-year follow-up of Miller-Galante I knees. *Am J Knee Surg*. (2001) 14:152–6. PMID: 11491425

21. Matz J, Lanting BA, Howard JL. Understanding the patellofemoral joint in total knee arthroplasty. *Can J Surg*. (2019) 62:57–65. doi: 10.1503/cjs.001617

22. Lee SH, Song EK, Seon JK, Seol YJ, Prakash J, Lee WG. A comparative study between patient-specific instrumentation and conventional technique in TKA. *Orthopedics*. (2016) 39:S83–7. doi: 10.3928/01477447-20160509-09

23. Sorin G, Pasquier G, Drumez E, Arnould A, Migaud H, Putman S. Reproducibility of digital measurements of lower-limb deformity on plain radiographs and agreement with CT measurements. *Orthop Traumatol Surg Res*. (2016) 102:423–8. doi: 10.1016/j.otsr.2016.02.009

24. Vaishya R, Vijay V, Birla VP, Agarwal AK. Computerized tomography based "patient specific blocks" improve postoperative mechanical alignment in primary total knee arthroplasty. *World J Orthop*. (2016) 7:426–33. doi: 10.5312/wjo.v7.i7.426

25. Aman ZS, DePhillipo NN, Peebles LA, Familiari F, LaPrade RF, Dekker TJ. Improved accuracy of coronal alignment can be attained using 3D printed PSI for knee osteotomies: a systemic review of level III and IV studies. *Arthroscopy*. (2022) S0749-8063:143–8. doi: 10.1016/j.arthro.2022.02.023

26. Sun ML, Zhang Y, Peng Y, Fu DJ, Fan HQ, He R. Accuracy of a novel 3D-printed patient-specific intramedullary guide to control femoral component rotation in total knee arthroplasty. *Orthop Surg*. (2020) 12:429–41. doi: 10.1111/os.12619

27. Kandhari VK, Desai MM, Bava SS, Wade RN. Digging deeper into the patello-femoral joint: patello-femoral composite – A new dimension for overstuffing of patello-femoral joint. *J Clin Diagn Res*. (2017) 11:RC04–7. doi: 10.7860/JCDR/2017/23192.9546

28. Kawahara S, Matsuda S, Fukagawa S, Mitsuyasu H, Nakahara H, Higaki H, et al. Upsizing the femoral component increases patellofemoral contact force in total knee replacement. *J Bone Joint Surg Br*. (2012) 94:56–61. doi: 10.1302/0301-620X.94B1.27514

29. Malviya A, Lingard EA, Weir DJ, Deehan DJ. Predicting range of movement after knee replacement: the importance of posterior condylar offset and tibial slope. *Knee Surg Sports Traumatol Arthrosc*. (2009) 17:491–8. doi: 10.1007/s00167-008-0712-x

30. Arabori M, Matsui N, Kuroda R, Mizuno K, Doita M, Kurosaka M, et al. Posterior condylar offset and flexion in posterior cruciate-retaining and posterior stabilized TKA. *J Orthop Sci*. (2008) 13:46–50. doi: 10.1007/s00776-007-1191-5

31. Bellemans J, Banks S, Victor J, Vandenneucker H, Moemans A. Fluoroscopic analysis of the kinematics of deep flexion in total knee arthroplasty. Influence of posterior condylar offset. *J Bone Joint Surg Br*. (2002) 84:50–3. doi: 10.1302/0301-620X.84B1.0840050

32. Wuertele N, Beckmann J, Meier M, Huth J, Fitz W. Posterior condylar resections in total knee arthroplasty: current standard instruments do not restore femoral condylar anatomy. *Arch Orthop Trauma Surg*. (2019) 139:1141–7. doi: 10.1007/s00402-019-03221-8

33. Ahmad R, Patel A, Mandalia V, Toms A. Posterior tibial slope: effect on, and interaction with, knee kinematics. *JBJS Rev*. (2016) 4:e31–6. doi: 10.2106/JBJS.RVW.O.00057

34. Giffin JR, Vogrin TM, Zantop T, Woo SL, Harner CD. Effects of increasing tibial slope on the biomechanics of the knee. *Am J Sports Med*. (2004) 32:376–82. doi: 10.1177/0363546503258880

35. Hofmann AA, Bachus KN, Wyatt RW. Effect of the tibial cut on subsidence following total knee arthroplasty. *Clin Orthop Relat Res*. (1991) 269:63–9. PMID: 1864058

36. Singerman R, Dean JC, Pagan HD, Goldberg VM. Decreased posterior tibial slope increases strain in the posterior cruciate ligament following total knee arthroplasty. *J Arthroplasty*. (1996) 11:99–103. doi: 10.1016/S0883-5403(96)80167-7

37. Waelchli B, Romero J. Dislocation of the polyethylene inlay due to anterior tibial slope in revision total knee arthroplasty. *Knee Surg Sports Traumatol Arthrosc*. (2001) 9:296–8. doi: 10.1007/s001670100203

38. Bao L, Rong S, Shi Z, Wang J, Zhang Y. Measurement of femoral posterior condylar offset and posterior tibial slope in normal knees based on 3D reconstruction. *BMC Musculoskelet Disord*. (2021) 22:486. doi: 10.1186/s12891-021-04367-6

39. Cinotti G, Sessa P, Ripani FR, Postacchini R, Masciangelo R, Giannicola G. Correlation between posterior offset of femoral condyles and sagittal slope of the tibial plateau. *J Anat*. (2012) 221:452–8. doi: 10.1111/j.1469-7580.2012.01563.x

40. Calek AK, Hochreiter B, Hess S, Amsler F, Leclerq V, Hirschmann MT, et al. High inter- and intraindividual differences in medial and lateral posterior tibial slope are not reproduced accurately by conventional TKA alignment techniques. *Knee Surg Sports Traumatol Arthrosc*. (2022) 30:882–9. doi: 10.1007/s00167-021-06477-z

41. Ranawat CS, Komistek RD, Rodriguez JA, Dennis DA, Anderle M. In vivo kinematics for fixed and mobile-bearing posterior stabilized knee prostheses. *Clin Orthop Relat Res*. (2004) 418:184–90. doi: 10.1097/00003086-200401000-00030

42. Fitch DA, Sedacki K, Yang Y. Mid- to long-term outcomes of a medial-pivot system for primary total knee replacement: a systematic review and meta-analysis. *Bone Joint Res*. (2014) 3:297–304. doi: 10.1302/2046-3758.310.2000290

frontiers | Frontiers in Surgery

TYPE Original Research
PUBLISHED 16 January 2023
DOI 10.3389/fsurg.2022.1043822

Check for updates

OPEN ACCESS

EDITED BY
Paphon Sa-ngasoongsong,
Mahidol University, Thailand

REVIEWED BY
Elif Nedret Keskinöz,
Acıbadem University, Turkey
Mirjam Neumann – Langen,
Klinikum Konstanz, Germany

*CORRESPONDENCE
Rongguang Ao
✉ yxt-2008@163.com
Baoqing Yu
✉ doctorybq@126.com

†These authors have contributed equally to this work

SPECIALTY SECTION
This article was submitted to Orthopedic Surgery, a section of the journal Frontiers in Surgery

RECEIVED 14 September 2022
ACCEPTED 16 December 2022
PUBLISHED 16 January 2023

CITATION
Jian Z, Jia J, Zeng L, Li D, Zhang X, Zhou J, Yi C, Yu B and Ao R (2023) Ring-Pins combined with cable cerclage for the fixation of displaced inferior patellar pole fractures.
Front. Surg. 9:1043822.
doi: 10.3389/fsurg.2022.1043822

COPYRIGHT
© 2023 Jian, Jia, Li, Zhang, Zhou, Yi, Yu and Ao. This is an open-access article distributed under the terms of the Creative Commons Attribution License (CC BY). The use, distribution or reproduction in other forums is permitted, provided the original author(s) and the copyright owner(s) are credited and that the original publication in this journal is cited, in accordance with accepted academic practice. No use, distribution or reproduction is permitted which does not comply with these terms.

Ring-Pins combined with cable cerclage for the fixation of displaced inferior patellar pole fractures

Zhen Jian[1†], Jianbo Jia[1†], Langqing Zeng[2,3†], Dejian Li[1], Xu Zhang[1], Jianhua Zhou[1], Chengqing Yi[1], Baoqing Yu[4*] and Rongguang Ao[1,2*]

[1]Department of Orthopedics, Shanghai Pudong Hospital, Fudan University Pudong Medical Center, Shanghai, China, [2]Department of Orthopedics, Shanghai East Hospital, Tongji University School of Medicine, Shanghai, China, [3]Department of Orthopedics, Zhuhai People's Hospital, Zhuhai Hospital Affliated with Jinan University, Zhuhai, China, [4]Department of Orthopedics, Shanghai Pudong New Area People's Hospital, Shanghai, China

Objective: The study aimed to present the clinical results and complication rates of ring-pins with cable cerclage for treating the inferior pole of patella fracture.
Method: A study that retrospectively reviewed consecutive patients of the displaced inferior pole of patella fracture (AO/OTA 34-A1) operated with a ring-pin tension band using cable cerclage between October 2015 and October 2017 was performed. The duration of surgery, motion range of the knee, function outcomes, and complications were recorded.
Results: The average follow-up of 31 patients was 21 months. The mean operation time was 50 min. Fractures in all 31 patients healed at a mean duration of 8 weeks. There was no infection, no withdrawing of ring-pins, no implant breakage, and no loss of fracture reduction. The mean range of motion was 120°, and no patient complained of implant irritation at the final follow-up. The average Bostman score was 29.0 points, and 28 patients graded clinical outcomes excellent and 3 patients graded clinical outcomes good at the last follow-up.
Conclusions: Ring-pin combined with cable cerclage for treating the displaced inferior pole of patellar fracture is simple, and the postoperative internal fixation-related complication rate is low. It is a good choice for treating the displaced inferior pole of the patellar fracture.

KEYWORDS
ring-Pin, inferior patellar pole, fixation, cable cerclage, fracture

Introduction

The inferior pole of patella fracture is not very common and accounts for 5% of all patellar fractures (1, 2). The inferior patella pole fracture is usually small comminuted fragments and is always associated with a rupture of the extensor mechanism of the knee. The aim of the operation is to restore the continuity of the extensor mechanism by fixing the fracture fragment and to allow early movement of the knee.

The most widely adopted method for treating displaced patellar fractures is to operate with internal fixation using a tension band (3, 4), which could transform the anterior tension force into compressive force on the posterior surface of the patella. The tension band techniques provide good fracture healing and functional recovery. Xu et-al. (5) reported that the modified tension band technique combined Kirschner wires (K-wires) with cable cerclage for the displaced inferior pole of patella fracture to provide firm fixation with satisfying clinical outcomes in knee function. However, K-wires are usually associated with possible loss of reduction and irritation of the bursa suprapatellaris and skin due to migration. Patients with symptomatic hardware often have to receive secondary operation to remove the fixation.

Ring-pins may avoid such problems. It was reported that the ring-pin fixation was first developed in 2000 by Nakashima Medical Co. Ltd. (Okayama, Japan) (6, 7). The special pin is composed of three parts: a sharp wire in the distal part, a ring-end as the connection section, and a proximal part for securing the grip over the power tool. The operators can fold the proximal section above the ring-end and remove the part after inserting the pin into the bone correctly. The ring was used across the cable, which benefits fraping the cable and compressing the fractures. What is more, the ring-pins were scarcely possible to withdrawing because they were fixed by the cable through the ring. Theoretically speaking, the ring-pin combined with cable cerclage would avoid withdrawing the K-wire, providing more stable fixation compared with K-wires. The objective of the retrospective study was to present the clinical results and complication rates of ring-pins with cable cerclage for treating the inferior pole of patella fracture.

Patients and methods

A retrospective study that reviewed consecutive patients of the displaced inferior pole of patella fracture (AO/OTA 34-A1) operated with a ring-pin tension band using cable cerclage between October 2015 and October 2017 was performed. Institutional review board approval for the study was obtained. All surgeries were operated by orthopedic surgeons with the same experience and qualifications.

Thirty-six patients suffering from displaced inferior patellar pole fractures and treated with ring-pins combined with cable cerclage were chosen as candidate participants. The medical records of all participants were reviewed. Exclusion criteria were the loss of follow-up within 1 year after surgery ($n = 1$), the presence of concomitant fractures ($n = 1$), and the presence of open fractures ($n = 3$). Therefore, the study comprised 31 patients who sustained displaced inferior patellar pole fractures and underwent open reduction and internal fixation with ring-pin tension bands with cable cerclage. The average age of the patients was 56 years (range 32–78 years). In our study, 13 patients were men and 18 were women. The average duration from surgery to initial injury was 3 days (range 1–4 days).

All patients in our department were asked to follow up monthly after surgery until fracture union. The duration of surgery during the procedure was recorded. The Bostman score was used to assess functional recovery postoperation. The overall score is 30 points: 28–30 points meant excellent; 20–27 points meant good; and less than 20 points meant poor (8). Postoperative complications that were documented included infection, nonunion, implant breakage, ring-pin withdrawal, and implant irritation.

Surgical techniques

The patient was placed in a supine position after anesthesia, and a pneumatic tourniquet was conventionally applied. A midline incision from the proximal patella to the tibial tubercle was made vertically over the knee, and full-thickness lateral and medial skin flaps were developed. The inferior pole patella fragment was exposed, and soft tissue detached from the fragment was preserved. Hematoma and soft tissue from the fracture and knee joint were removed. After full extension of the knee, the fracture was reduced with two reduction forceps with gentle force. Two 1.6-mm ring-pins were inserted from the proximal to the inferior pole in an axial direction. The main fragment of the inferior pole should be threaded by the two ring-pins (**Figure 1A**). The configuration of the pins could be either parallel or nonparallel according to the size of the main fragment of the inferior pole. The parallel configuration of pins was commonly used for noncomminuted inferior patellar pole fractures; the nonparallel configuration of pins, which was slightly wide at the top and slightly narrow at the inferior, was usually used for comminuted inferior patellar pole fractures because of the smaller size of the main fragment. Then, anteroposterior and lateral view fluoroscopy was applied to confirm the position of the ring-pin and the reduction of fracture. One 1.3-mm-diameter titanium cable (Zimmer Inc., USA) was passed through the rings, followed by knocking on the ring-pin end closed to the proximal patella bone to avoid irritation of the suprapatellar bursa. It was ensured that the titanium cable could slide through the rings. Then, the cable was crossed over the front of the patella to form a figure-8 (**Figure 1B,C**). A tension lever was tightened up and locked. To stabilize the fracture further, the surgeons could insert another titanium cable close to the edge of the patella, and the cerclage cable was tightened by the tension lever (**Figure 1D**). The proximal parts of the ring pins were removed. The distal ring pings were cut as close to the osseous border of the inferior patellar pole as possible to avoid irritating the skin.

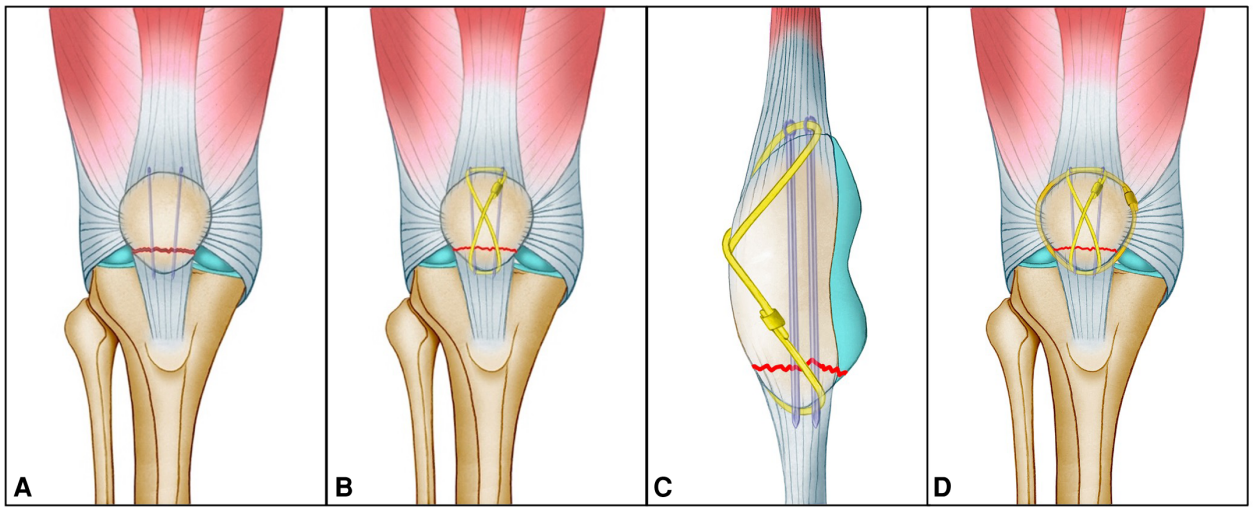

FIGURE 1
Diagrams showing that the displaced inferior patellar pole fracture was reduced and fixed by a ring-pin combined with cable cerclage. (A) Main fragment of the inferior pole threaded by the two ring-pins. (B) Anteroposterior and (C) lateral views showing insertion of the cable over the front of the patella to form a figure-8. (D) Final fixation of the inferior patellar pole fracture.

The number-0 absorbable sutures were routinely used to repair the retinaculum and ligamentum patellae. Before operations were completed, the surgeons fully flexed the knee to 130° to test the stability of internal fixation. Fluoroscopy was applied to confirm the reduction and fixation before closuring the wound. Standard wound closure was applied layer by layer using number-2 absorbable sutures for the subcutaneous tissue and a subcuticular stitch for the skin.

Postoperative rehabilitation

The knee was placed in a hinged knee brace. All patients were allowed to initiate muscle strengthening exercises postoperation and passive flexion of the knee 2–3 days after surgery. Partial weight-bearing began 2–3 weeks after surgery and gradually went to full weight-bearing by 4–6 weeks. The range of flexion motion of the knee was also increased gradually. Stages of active knee flexion started at 30°, then expanded to 60° in 2–4 weeks, and changed to 90° in 4–6 weeks.

Results

The average follow-up duration of the 31 patients was 21 months (18–35 months). The average operation duration was 50 min (40 to 75 min). The fractures healed at an average time of 8 weeks (7–11 weeks). A typical case is shown in Figure 2.

There was no infection, no withdrawing of ring-pins, no implant breakage, and no loss of fracture reduction. At the final follow-up, no patient complained of irritation of internal fixation. The mean range of motion was 120° (115°–130°). The average Bostman score at the final follow-up was 29.0 points (26.5–30). Additionally, 28 patients graded clinical outcomes excellent and 3 patients graded clinical outcomes good.

Discussion

Inferior patellar pole fractures are a distinct group of completely extra-articular avulsion injuries, usually measuring less than 15 mm in vertical length (2, 9). The key point of operation is to effectively fix the main fragment of the inferior pole fracture to allow early movement of the knee. Treatment for displaced inferior pole of patella fractures is challenging because it is usually with small fragments and too comminuted to fix and maintain reduction.

Several surgical methods are used for the treatment of the displaced inferior pole of patella fracture, including separate vertical wiring, rim-plate-augmented separate vertical wiring (2), fixed with a basket plate (10) or augmented with Krachow sutures (11), K-wires combined with cable cerclage (5), or anchor suture fixation (12). However, there are no widely accepted methods that have been identified for treating displaced inferior patellar pole fractures until now.

Separate vertical wiring is easy to perform with satisfactory clinical results. Kim et al. (13) reported 18 patients who received separate vertical wirings for the extra-articular fracture of the inferior patella pole. The ultimate mean flexion motion of the knee was 127.6°, and the mean Bostman score was 27.5

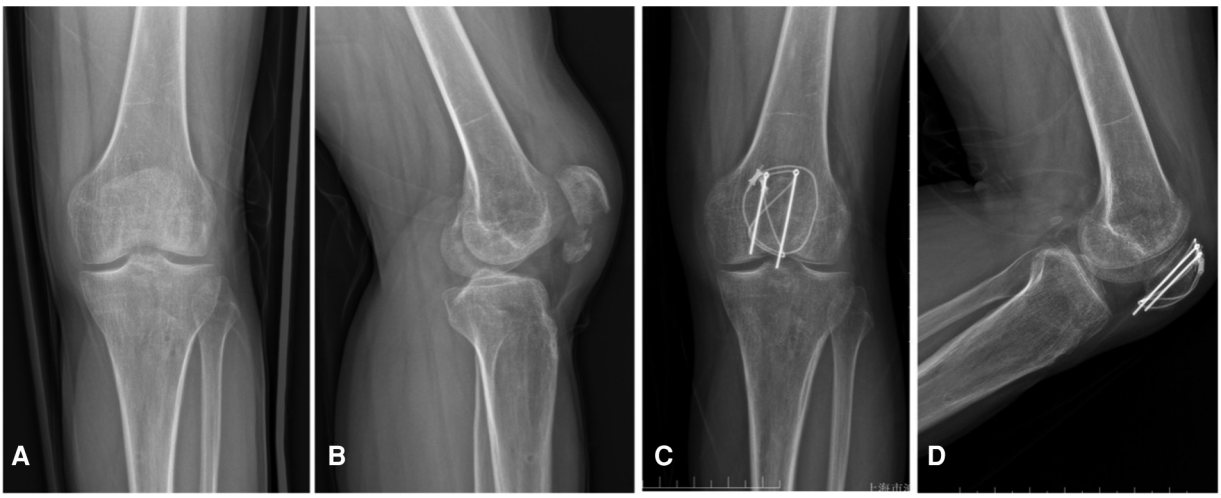

FIGURE 2
Case example of displaced inferior patellar pole fracture (Male, 36 years, left knee) using the ring-pin combined with cable cerclage. Preoperative radiographs in anteroposterior (A) and lateral (B) views showing a displaced inferior patellar pole fracture. Radiographs in anteroposterior (C) and lateral (D) views at 3 months follow-up, which show that the fracture was healed and the implants were in position without failure.

points. A biomechanical study (2) confirmed that the ultimate load to failure when using separate vertical wiring was 250 N and the stiffness was 280 N/mm, which was not strong enough to allow carrying out knee joint function exercises gradually under the extra protection of braces after surgery.

The final failure load of the basket plate for the fixation of the distal patella pole was the highest, achieving 421.66 ± 45.90 N (2). Matejcic et al. (14) reported that passive activities could be started on the first day after surgery in patients with basket plates. However, injury to the patellar tendon and the relative bulk of the plate with the thin, soft tissue layer over the anterior patella are the main drawbacks of the basket plate (15). The biomechanical study by Krkovic et al. (16) found that the basket plate was bond to cause significant shortening and rupture of the patellar tendon. Furthermore, this specific plate is not available in all institutions (15).

Anchor suture fixation has the advantages of definite clinical effects and avoiding secondary removal (12). Sixty patients with distal pole patellar fracture were retrospectively studied by Kadar et al. (17), and they found that the anchor suturing technique was not inferior compared with partial patellectomy for pain after displaced inferior pole of patella fracture and functional recovery and was superior with regard to operative time. The reoperation rate of 14.8% was also recorded in the anchor suture group. The most frequent complications of the technique are infections and implant failure. To ensure the fixation strength, it is usually recommended to fix the knee with plaster or brace in an extended position for 4–6 weeks after surgery (17, 18). Long-term embolization may lead to knee joint adhesion, quadriceps muscle atrophy, deep vein thrombosis, and limited knee flexion function.

Ideal operation methods should be sufficient fixation stability, a relatively simple surgical procedure, and early motion of the injured knee. K-wire fixation with tension band wiring is still the most frequent method to treat transverse patellar fractures, and it can provide sufficient fixation stability according to the theory of tension band (3, 9). However, there is an inherent disadvantage for conventional K-wires, such as migration and breakage, with the subsequent painful and prominent implant in the knee. Lazaro et al. (19) claimed a rate of 37% hardware removal due to symptomatic and prominent hardware as a result of continuous soft tissue irritation or fixation breakage. Hung et al. (20) reported that the rate of complications associated with stainless steel wire loops was 47% and 15% of patients had related symptoms that needed wire removal. Meanwhile, it is more difficult to fix the inferior patellar pole fracture than transverse patellar fractures because the inherent weakness of the inferior pole fragments and the small size of the fracture fragments prevent sufficient stabilization by common wiring.

Kirschner wires combined with cable cerclage may still be a good choice. The modified tension band technique connected Kirschner wires with cable cerclage using a Cable Grip System and can provide an effective alternative to reduce the rate of hardware loosening, wire breakage, and soft tissue irritation caused by stainless steel wires (5). Compared to stainless steel wires, titanium cables can provide more reliable stability and decrease complications such as loosening and breakage. Stainless steel wires are easy to break and loosen in fixation that usually lead to a high incidence of prominent hardware,

accounting for almost 50% of all risk of secondary surgical removal of tension band fixation (21, 22).

Ring-pins are designed to lock the pin with the cable through the ring-end that is bonded to prevent postoperative migration (7). A large cohort of 334 comminuted patellar fracture cases reported by Zhu et al. (6) demonstrated that ring-pin tension band fixation is superior to cannulated-screw tension band and Kirschner wire tension band fixation due to a lower rate of hardware failure and secondary removal surgery, respectively. In our study, there was also no implant failure or loss of fracture reduction. At the last follow-up, no patient complained of uncomfortableness due to implant irritation. At the final follow-up, 28 patients graded clinical outcomes excellent and three patients graded clinical outcomes good according to the Bostman score.

Conclusions

Ring-pins combined with cable cerclage for treating displaced inferior pole fractures of the patella are simple and facilitate early functional exercise due to firm fixation. In addition, the postoperative internal fixation-related complication rate is low. In conclusion, it is a good choice for treating displaced inferior patellar pole fractures.

Data availability statement

The raw data supporting the conclusions of this article will be made available by the authors without undue reservation.

Ethics statement

The study involving human participants was reviewed and approved by Shanghai Pudong Hospital. The patients/participants provided their written informed consent to participate in this study.

Author contributions

ZJ: research design, acquisition, analysis, interpretation, and manuscript drafting and revision; RGA: research design, analysis, and manuscript revision; BQY: research design, interpretation, and manuscript revision; JBJ: research design, analysis, interpretation, and manuscript revision; LQZ: research design, analysis, interpretation, and manuscript drafting and revision; DJL: analysis, interpretation, and manuscript revision; XZ: analysis, interpretation, and manuscript revision; JHZ: research design and manuscript revision. All authors have read and approved the final submitted manuscript. All authors contributed to the article and approved the submitted version.

Funding

This study was funded by Key Subpecialty Construction Project of Pudong Health and Family Planning Commission of Shanghai (No. PWZy2020-03), Youth Scientific Research Foundation provided by Shanghai Municipal Health Commission (No. 20204Y0121).

Conflict of interest

The authors declare that the research was conducted in the absence of any commercial or financial relationships that could be construed as a potential conflict of interest.

Publisher's note

All claims expressed in this article are solely those of the authors and do not necessarily represent those of their affiliated organizations, or those of the publisher, the editors and the reviewers. Any product that may be evaluated in this article, or claim that may be made by its manufacturer, is not guaranteed or endorsed by the publisher.

References

1. Lu M, Zhan S, Zhang C, Chen D, Liu S, Xu J. "Fishing net" suture augmenting tension-band wiring fixation in the treatment of inferior pole fracture of the patella. *Arch Orthop Trauma Surg*. (2021) 141(11):1953–61. doi: 10.1007/s00402-021-04089-3

2. Yang KH, Byun YS. Separate vertical wiring for the fixation of comminuted fractures of the inferior pole of the patella. *J Bone Joint Surg Br*. (2003) 85 (8):1155–60. doi: 10.1302/0301-620x.85b8.14080

3. Steinmetz S, Brügger A, Chauveau J, Chevalley F, Borens O, Thein E. Practical guidelines for the treatment of patellar fractures in adults. *Swiss Med Wkly*. (2020) 150:w20165. doi: 10.4414/smw.2020.20165

4. Henrichsen JL, Wilhem SK, Siljander MP, Kalma JJ, Karadsheh MS. Treatment of patella fractures. *Orthop*. (2018) 41(6):e747–55. doi: 10.3928/01477447-20181010-08

5. Yang X, Wu Q, Lai CH, Wang X. Management of displaced inferior patellar pole fractures with modified tension band technique combined with cable cerclage using cable grip system. *Injury*. (2017) 48(10):2348–53. doi: 10.1016/j.injury.2017.07.013

6. Zhu XZ, Huang TL, Zhu HY, Bao BB, Gao T, Li XW, et al. A retrospective cohort study on prevalence of postoperative complications in comminuted patellar fractures: comparisons among stabilized with cannulated-screw,

kirschner-wire, or ring-pin tension bands. *BMC Musculoskelet Disord*. (2021) 22 (1):60. doi: 10.1186/s12891-020-03936-5

7. Liu J, Ge Y, Zhang G, Zheng X, Gao L, Xing E, et al. Clinical outcomes of cannulated screws versus ring pin versus K-wire with tension band fixation techniques in the treatment of transverse patellar fractures: a case-control study with minimum 2-year follow-up. *Biomed Res Int*. (2022) 2022:5610627. doi: 10.1155/2022/5610627

8. Böstman O, Kiviluoto O, Nirhamo J. Comminuted displaced fractures of the patella. *Injury*. (1981) 13(3):196–202. doi: 10.1016/0020-1383(81)90238-2

9. Poutoglidou F, Krkovic M. A modified tension band fixation technique for the management of patellar fractures using crossed pins and a lateral parapatellar approach. *Cureus*. (2022) 14(4):e24546. doi: 10.7759/cureus.24546

10. Cho JW, Kim J, Cho WT, Gujjar PH, Oh CW, Oh JK. Comminuted inferior pole fracture of patella can be successfully treated with rim-plate-augmented separate vertical wiring. *Arch Orthop Trauma Surg*. (2018) 138(2):195–202. doi: 10.1007/s00402-017-2807-7

11. Oh HK, Choo SK, Kim JW, Lee M. Internal fixation of displaced inferior pole of the patella fractures using vertical wiring augmented with Krachow suturing. *Injury*. (2015) 46(12):2512–5. doi: 10.1016/j.injury.2015.09.026

12. Zhu L, Wang H, Song L, Wang B. Clinical application of suture anchor combined with Kirschner wires fixation for patella inferior-pole fractures. *Asian J Surg*. (2022) 45(7):1418–9. doi: 10.1016/j.asjsur.2022.02.029

13. Kim YM, Yang JY, Kim KC, Kang C, Joo YB, Lee WY, et al. Separate vertical wirings for the extra-articular fractures of the distal pole of the Patella. *Knee Surg Relat Res*. (2011) 23(4):220–6. doi: 10.5792/ksrr.2011.23.4.220

14. Matejcić A, Smiljanić B, Bekavac-Beslin M, Ledinsky M, Puljiz Z. The basket plate in the osteosynthesis of comminuted fractures of distal pole of the patella. *Injury*. (2006) 37(6):525–30. doi: 10.1016/j.injury.2004.09.020

15. Huang HC, Su JY, Cheng YM. Modified basket plate for inferior patellar pole avulsion fractures: a report of three cases. *Kaohsiung J Med Sci*. (2012) 28 (11):619–23. doi: 10.1016/j.kjms.2012.04.029

16. Krkovic M, Bombac D, Balazic M, Kosel F, Hribernik M, Senekovic V, et al. Modified pre-curved patellar basket plate, reconstruction of the proper length and position of the patellar ligament – a biomechanical analysis. *Knee*. (2007) 14 (3):188–93. doi: 10.1016/j.knee.2007.03.004

17. Kadar A, Sherman H, Drexler M, Katz E, Steinberg EL. Anchor suture fixation of distal pole fractures of patella: twenty seven cases and comparison to partial patellectomy. *Int Orthop*. (2016) 40(1):149–54. doi: 10.1007/s00264-015-2776-9

18. Xie J, Fu Y, Li J, Yu H, Zhang Y, Jing J. Anchor and krackow-"8" suture for the fixation of distal pole fractures of the Patella: comparison to kirschner wire. *Orthop Surg*. (2022) 14(2):374–82. doi: 10.1111/os.13124

19. Lazaro LE, Wellman DS, Sauro G, Pardee NC, Berkes MB, Little MT, et al. Outcomes after operative fixation of complete articular patellar fractures: assessment of functional impairment. *J Bone Joint Surg Am*. (2013) 95(14): e96 91–98. doi: 10.2106/jbjs.L.00012

20. Hung LK, Chan KM, Chow YN, Leung PC. Fractured patella: operative treatment using the tension band principle. *Injury*. (1985) 16(5):343–7. doi: 10.1016/0020-1383(85)90144-5

21. Dickens AJ, Salas C, Rise L, Murray-Krezan C, Taha MR, DeCoster TA, et al. Titanium mesh as a low-profile alternative for tension-band augmentation in patella fracture fixation: a biomechanical study. *Injury*. (2015) 46(6):1001–6. doi: 10.1016/j.injury.2015.02.017

22. LeBrun CT, Langford JR, Sagi HC. Functional outcomes after operatively treated patella fractures. *J Orthop Trauma*. (2012) 26(7):422–6. doi: 10.1097/BOT.0b013e318228c1a1

frontiers | Frontiers in Surgery

TYPE Original Research
PUBLISHED 25 January 2023
DOI 10.3389/fsurg.2023.1033830

Check for updates

OPEN ACCESS

EDITED BY
Paphon Sa-ngasoongsong,
Mahidol University, Thailand

REVIEWED BY
Lin Zheng,
Zhejiang University, China
Prabhudevprasad Purudappa,
VA Boston Healthcare System, United States

*CORRESPONDENCE
Xia Zhao
✉ Zhaoxia3020@163.com
Tengbo Yu
✉ ytb8912@163.com

†These authors have contributed equally to this work

SPECIALTY SECTION
This article was submitted to Orthopedic Surgery, a section of the journal Frontiers in Surgery

RECEIVED 01 September 2022
ACCEPTED 06 January 2023
PUBLISHED 25 January 2023

CITATION
Ma J, Zhang L, Wang C, Xu K, Ren Z, Wang T, Zhang Y, Zhao X and Yu T (2023) The mid-term outcomes of mobile bearing unicompartmental knee arthroplasty versus total knee arthroplasty in the same patient.
Front. Surg. 10:1033830.
doi: 10.3389/fsurg.2023.1033830

COPYRIGHT
© 2023 Ma, Zhang, Wang, Xu, Ren, Wang, Zhang, Zhao and Yu. This is an open-access article distributed under the terms of the Creative Commons Attribution License (CC BY). The use, distribution or reproduction in other forums is permitted, provided the original author(s) and the copyright owner(s) are credited and that the original publication in this journal is cited, in accordance with accepted academic practice. No use, distribution or reproduction is permitted which does not comply with these terms.

The mid-term outcomes of mobile bearing unicompartmental knee arthroplasty versus total knee arthroplasty in the same patient

Jinlong Ma[1], Liang Zhang[2†], Cui Wang[1†], Kuishuai Xu[1†], Zhongkai Ren[1], Tianrui Wang[3], Yingze Zhang[1], Xia Zhao[1*] and Tengbo Yu[1*]

[1]Department of Sports Medicine, The Affiliated Hospital of Qingdao University, Qingdao, China, [2]Department of Abdominal Ultrasound, Affiliated Hospital of Qingdao University, Qingdao, China, [3]Department of Traumatology, The Affiliated Hospital of Qingdao University, Qingdao, China

Objective: To compare the mid-term outcomes of unicompartmental knee arthroplasty (UKA) that was performed in one knee and total knee arthroplasty (TKA) performed in the other knee in the same stage.
Methods: This is a retrospective study. A total of 63 patients (126 knees) scheduled for one-stage knee surgery due to osteoarthritis of both knees were selected, and all patients underwent one-stage mobile platform UKA and TKA of the other knee. Differences in general clinical data, functional recovery, complications, and prosthesis revision rates were assessed after UKA and TKA, respectively. The evaluation indicators for knee joint function recovery included the hospital for special surgery knee score (HSS), Joint Forgotten Score (JFS), Knee Injury and Osteoarthritis Outcome Score (KOOS), and Visual analog scale (VAS). Patient preference between UKA and TKA was also recorded.
Results: During a mean follow-up of 76.95 months (range, 65.00 to 87.00 months), there were no significant differences in postoperative complications between the two groups ($P = 0.299$); however, the prosthesis revision rate was higher in the UKA group than in the TKA group ($P = 0.023$). The incision length, operation time, blood loss, and postoperative drainage volume in the UKA group were significantly ($P < 0.001$) lower than those in the TKA group: JFS, ROM, and VAS in the UKA group were higher than those in the TKA group ($P < 0.001$, $P = 0.023$, $P = 0.032$), HSS and KOOS in TKA group were significantly ($P < 0.001$) higher than those in UKA group. At the last follow-up, 40% and 24% of patients preferred TKA and UKA, respectively.
Conclusions: TKA was found to be superior to UKA in terms of HSS, KOOS, and VAS, while UKA had more significant advantages in terms of less surgical trauma, better ROM, and higher JFS. Complications were not different between groups, but UKA had a higher rate of prosthesis revision. After a follow-up of at least 5 years, more patients preferred TKA.

KEYWORDS
unicompartmental knee arthroplasty, total knee arthroplasty, outcome, complication, revision

Introduction

Total knee arthroplasty is an effective treatment for advanced knee osteoarthritis with pain associated with loss of function (1). Approximately one-third of patients experience knee-related symptoms, and approximately 20% require total knee arthroplasty (2). At the same time, differences were found in the location and degree of knee joint degeneration in some patients, where one side involved multiple compartments while the other involved unicompartmental degeneration. However, numerous studies investigated potential differences in the recovery of the knee joint after TKA combined with UKA in the treatment of knee arthritis, and the comparison of the clinical efficacy between the two remains controversial (3).

Previous studies have found some advantages of UKA over TKA, including less surgical trauma as well as preservation of the anterior cruciate ligament (4), with survival rates of 98% and 95% at 10 and 20 years, respectively (5). Simultaneous comparison of UKA and TKA revealed that UKA resulted in earlier recovery, less postoperative pain, and higher quality of life. Unicompartmental knee arthroplasty was associated with a better gait pattern compared to total knee arthroplasty (6), and patients reported feeling more like a normal knee after UKA (7, 8). Compared with TKA, UKA has fewer perioperative complications but a higher revision rate (3). After adjusting the preoperative flexion angle, UKA can achieve a postoperative flexion angle compared with TKA (8). UKA has been associated with better JFS and KOOS and is otherwise comparable to TKA, thus potentially presenting the preferable option (9). Yet, there are other studies with different findings, where UKA did not achieve good clinical efficacy 2 years after surgery (10).

Most previous studies have used a mutually controlled approach to eliminate the influence of demographic variables such as age, gender, and body mass index between the control and study groups. However, some factors, such as lifestyle, limb movements, and conditions for rehabilitation, are difficult to control and quantify. In addition, previous reports were limited by a small sample size, which we overcame in the present study by increasing the sample size. Also, the duration of follow-up time was more than 5 years for all patients.

In order to improve the study design, all patients included in this study underwent UKA in one knee, while TKA was performed in the other knee in one stage. We compared the mid-term clinical outcomes, complications, and revision rates after primary TKA with UKA in patients.

Methods

Study design and patients

This study is a retrospective study that evaluated KOA patients who received concurrent knee arthroplasty in the Affiliated Hospital of Qingdao University between June 2013 and August 2016. The Inclusion criteria were patients who underwent UKA in one knee and simultaneous TKA in the other knee. Exclusion criteria referred to patients with previous rheumatoid arthritis, history of knee arthritis infection or osteomyelitis, history of previous knee surgery, those lost to follow-up or who refused to join the experiment.

Our retrospective study was approved by the Ethics Institutional Review Board of the Affiliated Hospital of Qingdao University (Approval No.: QYFYWZLL26915), and all patients provided informed consent.

Surgical methods and perioperative management

Both groups were operated by the same group of physicians, UKA was performed using Oxford III (mobile platform) prosthesis from Biomet, USA, and TKA was performed using Advance knee prosthesis (Wright, USA) or Scorpio NRG knee prostheses (Stryker, USA). All the procedures started with the left knee, and all patients were treated with conventional anterior midline knee incision and medial para-articular capsule incision. The patients in the UKA group were treated using the standard Oxfordphase3 minimally invasive unicompartmental knee arthroplasty operating manual. The TKA group was operated on according to conventional total knee arthroplasty. Anticoagulation was continued for 2 weeks after surgery in all patients, antibiotics were used to prevent infection for 24 h, and analgesia was continued until the patient's function returned to normal. The patients were started on partial weight-bearing and active assisted knee exercises and instructed to begin ankle pump exercises and quadriceps exercises as soon as possible. All patients underwent physical rehabilitation by the same rehabilitation technologist.

Follow-up and data collection

A single assessor, who was not involved in the study design but was familiar with the assessment tools, was responsible for data collection, which was performed using standard case record forms. General clinical data included incision length, operation time, blood loss, and postoperative drainage volume. The knee function scores included: HSS (11), JFS (12), and KOOS (13). KOOS has 42 items that are divided across 5 categories, with 0~4 points assigned for each item. The scores for each part of item are individually calculated and converted into a percentage system. Knee ROM was measured using a telescopic goniometer. The evaluation of pain was performed using a visual analog scale (VAS) score (14) ranging from 0 to 10, with 0 indicating no pain and 10 representing the maximum pain. We defined a complication as the presence of any of the following: lower extremity deep venous thrombosis, pulmonary embolism, infection, prosthesis loosening, periprosthetic fracture, and insert dislocation. Removal, replacement, or addition of any component of the prosthesis was considered as a revision, including exchange of the insert and change to TKA.

Statistical analysis

All statistical analyses were performed using SPSS 25.0 software. Measurement data were expressed as mean and standard deviation ($x \pm s$), and categorical data were expressed as numbers (percentage). The differences in the measurement data of patients in the UKA TKA group were analyzed using the independent sample t-test, and the differences in the categorical data between the two groups were analyzed using the chi-square test or Fisher's exact test. Revisions were analyzed using Kaplan-Meier survival curves. Test level $\alpha = 0.05$. A P value < 0.05 indicates statistical significance.

Results

Study flowchart, demographic characteristics, and the operation result

Among a total of 86 patients with degenerative arthritis who were assessed for possible inclusion in the study, 23 did not meet the

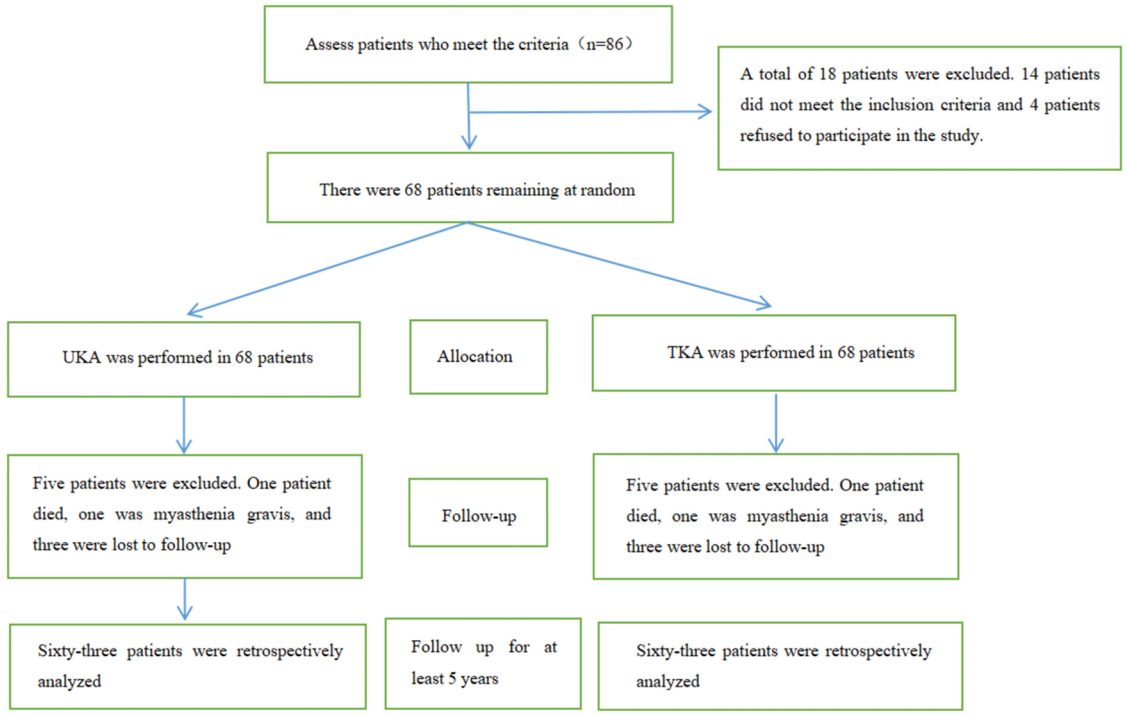

FIGURE 1
Study flowchart.

inclusion criteria and thus were excluded. Finally, 63 patients (126 knees), 14 males and 49 females, with a mean age of 63.71 ± 6.65 years (range, 50~80 years) and a mean BMI of 27.21 ± 2.98 kg/m^2 (range, 20.9~35.2 kg/m2) were included in the final analysis. The flowchart scheme of this study is shown in Figure 1; the baseline characteristics of all patients are summarized in Table 1; procedure-related outcomes for all patients are presented in Table 2.

HSS, JFS, and KOOS

In the functional outcome, the mean JFS was significantly ($p < 0.001$) higher in the UKA group than in the TKA group, while the HSS and KOOS were significantly ($p < 0.001$) higher in the TKA group than in the UKA group (Table 3).

ROM and VAS

The mean ROM was 124.06 ± 8.58 in the UKA group and 120.16 ± 10.43 in the TKA group, revealing a significant difference between the two groups ($p = 0.023$). The mean VAS was 1.89 ± 0.83 in the UKA group and 1.57 ± 0.82 in the TKA group, revealing a significant difference between the two groups ($P = 0.032$) (Table 4).

Complications

There was no significant difference in postoperative complications between the two groups at the last follow-up ($p = 0.299$) (Table 5).

TABLE 1 Demographic characteristics.

	Mean ± SD/*n* (%)	Range
***N* = 63**		
Age (years)	63.71 ± 6.65	50–80
Gender, *n* (%)		
Male	14 (22.22%)	-
Female	49 (77.78%)	-
BMI (kg/m^2)	27.21 ± 2.98	20.1–35.2
Pre-operative Kellgren-Lawrence classification		
III	47 (37.3%)	-
IV	79 (62.7%)	-
Follow-up (months)	76.95 ± 5.72	65–87

BMI, body mass index.

TABLE 2 Intra-operative features.

	UKA (*N* = 63)	TKA (*N* = 63)	*t*	*P*
Length of the incision (cm)	11.3 ± 1.76	16.9 ± 2.12	−16.175	<0.001
Operative time (mins)	55.92 ± 11.31	64.97 ± 13.32	−4.109	<0.001
Blood loss (ml)	115.08 ± 42.15	223.02 ± 53.96	−12.512	<0.001
Postoperative drainage (ml)	188.41 ± 56.37	255.24 ± 62.24	−6.316	<0.001

UKA, Unicompartmental knee arthroplasty; TKA, Total knee arthroplasty.

TABLE 3 HSS, JFS and KOOS scores in two groups.

		UKA ($N = 63$)	TKA ($N = 63$)	t	P
HSS	Preoperation	40.35 ± 5.74	38.78 ± 5.05	1.631	0.105
	Last follow-up	87.98 ± 4.36	90.89 ± 3.9	3.940	<0.001
KOOS					
	Preoperation	44.67 ± 6.75	39.73 ± 5.56	4.481	<0.001
	Last follow-up	90.25 ± 4.48	93.14 ± 2.6	−4.427	<0.001
JFS	Last follow-up	94.57 ± 2.58	88.1 ± 4.81	9.418	<0.001

UKA, Unicompartmental knee arthroplasty; TKA, Total knee arthroplasty; HSS, Hospital for special surgery knee score; JFS, Joint Forgotten Score; KOOS, Knee Injury and Osteoarthritis Outcome Score.

Revision situation

The prosthesis survival rate was 100% during follow-up in the TKA group, and a total of 5 revisions occurred in the UKA group, with a prosthesis survival rate of 92.06%. The difference in prosthesis revision between the two groups was statistically significant ($P = 0.023$) (Table 6). From the Kaplan-Meier prosthesis survival curves of the two groups, it can be observed that the prosthesis survival rate in the TKA group was 100% and gradually decreased in the UKA group with a longer follow-up time (Figure 2).

Patient satisfaction

During follow-up, 15 (23.81%) patients chose UKA, and 25 (39.68%) patients chose TKA as a preferential approach, and 23 (36.51%) patients expressed no preference at least 5 years after surgery.

Representative case

A 65-year-old woman with osteoarthritis of the knee underwent UKA for the left knee and TKA for the right knee. Five months after surgery, a radiographic examination of the left knee revealed a dislodged polyethylene bearing, and the patient underwent removal of the left knee prosthesis and conversion to TKA, with good recovery after revision (Figures 3,4).

TABLE 4 ROM and VAS scores in two groups.

		UKA ($N = 63$)	TKA ($N = 63$)	t	P
ROM (°)	Preoperation	116.67 ± 9.89	113.89 ± 9.27	1.709	0.09
	Last follow-up	124.06 ± 8.58	120.16 ± 10.43	2.294	**0.023**
VAS					
	Preoperation	6.4 ± 0.55	6.52 ± 0.82	−1.018	0.311
	Last follow-up	1.89 ± 0.83	1.57 ± 0.82	2.169	**0.032**

UKA, Unicompartmental knee arthroplasty; TKA, Total knee arthroplasty; ROM, Range of motion; VAS, Visual analog scale.

TABLE 5 Local complications.

	UKA ($N = 63$)	TKA ($N = 63$)	χ^2	P
Complications				
Deep vein thrombosis	0	1		
Prosthetic joint infection	0	0		
Poor healing of the incisn	1	1		
Gasket dislocation	3	0		
Aseptic loosening	2	0		
Periprosthetic fracturs	0	0		
Stiffness	0	1		
Total	5	3	1.077	0.299

UKA, Unicompartmental knee arthroplasty; TKA, Total knee arthroplasty.

Discussion

This retrospective clinical study compared UKA and TKA. All patients were followed up for at least 5 years. TKA had better clinical efficacy than UKA, while UKA had better ROM and JFS than TKA. There was no significant difference in complications between the two groups, but UKA had a higher rate of prosthesis revision. Also, more patients expressed their preference for the TKA approach.

Considering surgical results, UKA offers significant advantages in achieving smaller surgical incisions, reduced operative time, and lower intraoperative bleeding and drainage volume, which may lead to faster recovery, reduced morbidity, shorter hospital stays, and the need for rehabilitation. This conclusion is consistent with previous studies (15), which argued that UKA preserves the anterior cruciate ligament, preserves femoral and tibial bone reserves, reduces intraoperative and postoperative blood loss, shortens hospital stay and preserves normal biomechanics of the knee joint compared to TKA. Then again, we compared UKA and TKA clinical results, finding some differences between the two surgical modalities, with HSS and KOOS being significantly ($p < 0.001$) higher in the TKA group than in the UKA group. In their study, Boonchana et al. (9) found that UKA was associated with better JFS and KOOS and was otherwise comparable to TKA. In a previous comparison of TKA and UKA, the function was assessed according to the HSS and function scores, revealing the same efficacy between the two groups (16). Furthermore, Dalury et al. also found that the knee social score increased from 45.9 to 89.7 for UKA and from 42.4 to 90.3 for TKA, with little or no difference in results between the two procedures (17).

TABLE 6 Comparison of knee prosthesis revision between two groups.

	UKA ($N = 63$)	TKA ($N = 63$)	χ^2	P
Revision for any reason, n (%)	5 (7.94%)	0	5.207	**0.023**

UKA, Unicompartmental knee arthroplasty; TKA, Total knee arthroplasty.

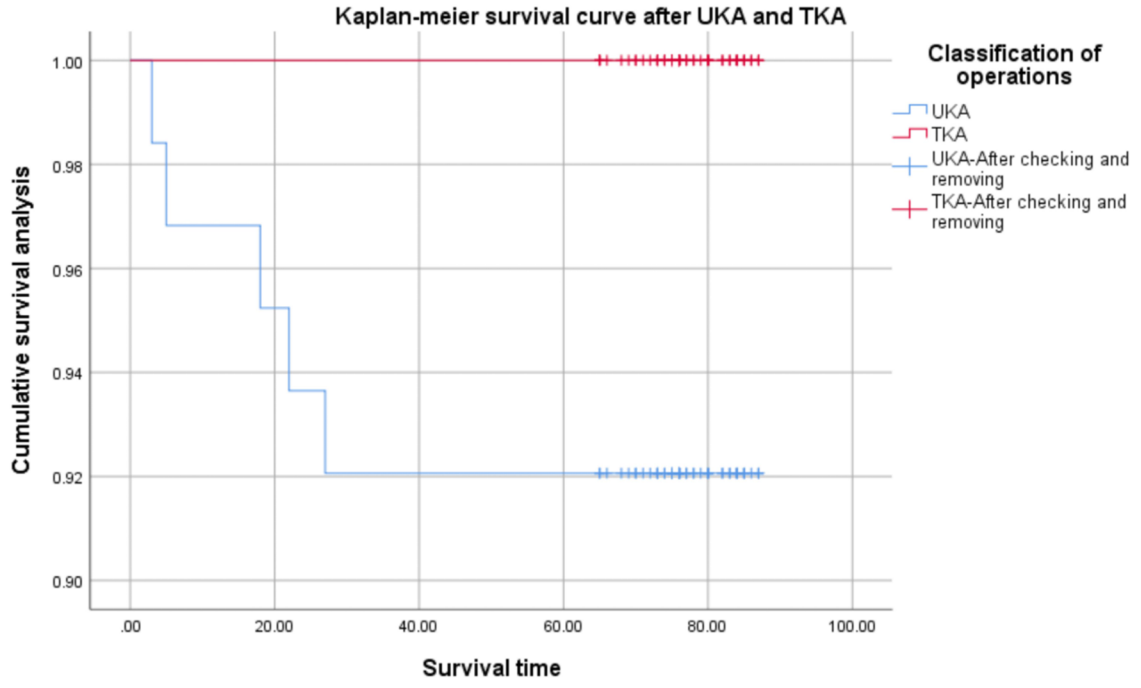

FIGURE 2
Survival curves of kaplan-Meier prosthesis in two groups.

Considering subjective preference, 15 (23.81%) patients chose UKA, 25 (39.68%) patients chose TKA, and 23 (36.51%) patients had no preference after at least 5 years after surgery, which was not consistent with previous studies. According to existing literature, the vast majority of patients prefer UKA because of shorter hospital stays and faster rehabilitation (15). In the present study, patients were followed up for 5 years or more after surgery, and the subjective preference of the patients was directed more towards the assessment of clinical efficacy and pain, which is one of the reasons for the inconsistency with previous studies. However, we did not include studies for systematic assessment of patient satisfaction, which is also a limitation of the present study. Other studies reported that of 23 patients, 11 knees had no preference, 12 preferred UKA, and none preferred TKA (16). Dalury et al. (17) conducted a similar study that included 23 patients who underwent surgery, none of whom expressed preferred TKA at a mean follow-up of 42 months. In another similar study, 11 patients preferred UKA over TKA, 3 preferred TKA, while 9 said they felt the same about the two approaches (18). One of the possible reasons that patients in previous studies preferred UKA might be shorter hospital stays and greater postoperative range of motion. However, that study had a relatively shorter follow-up, with significantly more knee pain and higher revision rates in UKA and significantly less pain after TKA in patients at longer postoperative follow-up, which may be related to wear of the lateral cartilage in some patients in UKA. In the present study, we found that more patients preferred TKA.

A previous study showed that UKA had better ROM, and there was no difference in preoperative and postoperative pain ($P > 0.05$) (17). Takafumi et al. (8) designed a more precise study, and after adjusting for the preoperative flexion angle, UKA could achieve the postoperative flexion angle compared with TKA. In our study, the ROM of the UKA group was higher than that of the TKA group, which is consistent with previous literature suggesting that UKA provides higher ROM, lower incidence of stiffness, and lower need for rehabilitation as it preserves the anterior cruciate ligament and maintains normal knee structure (19, 20). In addition, we found that patients in the UKA group had a higher VAS than those in the TKA group. This is not consistent with previous studies (17, 18) and may be related to asymmetric rehabilitation exercises of the knee joint, asynchronous recovery of lower extremity function, or the revision rate and wear of the lateral compartment in the UKA group. Further follow-up observations are needed to establish whether the VAS will change with a longer follow-up time.

There was no difference between the two groups in terms of complications, which is consistent with the results of previous studies (16–18). However, we found that the survival rate of the prosthesis was 100% in the TKA group and only 92.06% in the UKA group during follow-up. As shown by the Kaplan-Meier prosthesis survival curve of the two groups, the survival rate of prosthesis in the UKA group gradually decreased with the increase in follow-up time. The main reason for the revision was the dislocation of the insert (60%). The used polyethylene tibial design may lead to a higher failure rate. Previous studies have also revealed that the survival rate in the UKA group was 85%, while that of the TKA group was 100%. These results suggest that UKA may not provide similar survival rates compared with TKA (16). In their study, Saenz et al. (21) reported on 113 patients (144

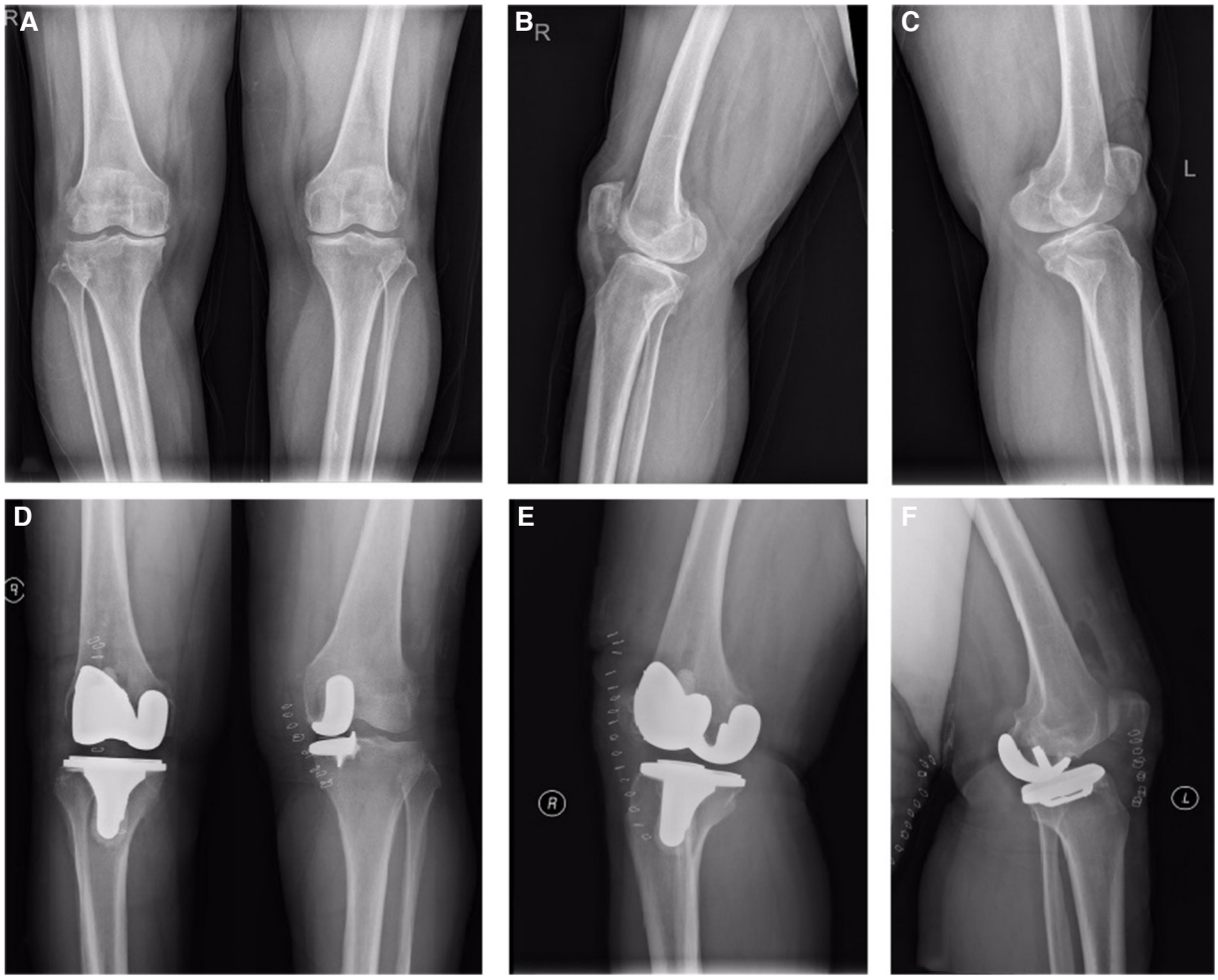

FIGURE 3
pre-operative (10 days) and post-operative (2 days) X-ray examinations of a 68-year-old women with bilateral osteoarthritis. (A) Anteroposterior position 10 days before operation. (B) Lateral position of right knee joint 10 days before operation. (C) Lateral position of left knee joint 10 days before operation. (D) Anteroposterior position 2 days after operation. (E) Lateral position of right knee joint 2 days after operation. (F) Lateral position of left knee joint 2 days after operation.

knees) who underwent UKA with an all-polyethylene tibial component and observed an implant survival rate of 89% at a mean follow-up of 36 months. Another study that used the Swedish registry evaluated 8,793 UKAs performed between 1998 and 2007, where 24% of UKAs were revised compared with 9% of all TKAs performed in the same time period (22). A study in 2017 reached a different conclusion, retrospectively analyzing all patients aged 75 years and older who were treated with UKA or TKA between 2002 and 2012, revealing no significant difference between UKA and TKA in the comparison of 5-year prosthesis survival (23). In the past 20 years, the increased survival rate of UKA may be related to the design of the prosthesis and the improvement of surgical techniques. In addition, since the requirement of UKA may be very high, the inexperience of surgeons may lead to the incidence of technical errors and early failure.

The present study has some limitations: (1) it is a single-center clinical trial, and other institutions should conduct similar surveys to confirm the reported results; (2) due to the limited number of patients suitable for simultaneous knee replacement surgery, the number of patients is still relatively small; (3) in this work, only preoperative and follow-up investigation studies were performed; the differences in the early stage of surgery were not compared, and no continuous dynamic follow-up was performed; (4) only HSS, JFS, and KOOS were compared, while other clinical scores were not considered. Despite these limitations, we compared the same patients and followed them for at least 5 years, thus increasing the credibility of the presented results.

Conclusion

By comparing UKA with TKA, we found that TKA was superior to UKA in terms of HSS, KOOS, and VAS, while UKA had more significant advantages in obtaining less surgical trauma and achieving better ROM and higher JFS. Complications were not different between groups, but UKA had a higher rate of prosthesis revision. After a follow-up of at least 5 years, more patients preferred TKA.



FIGURE 4
X-rays 5 months after UKA of the left knee and 3 days after conversion to TKA in a 65-year-old woman, White arrow: Poly backed out (**A**) Anteroposterior position of left knee joint 5 months after UKA, Poly backed out. (**B**) Lateral position of left knee joint 5 months after UKA. (**C**) The prosthesis of left knee joint was removed, and the surgical method was changed to TKA, anteroposterior position of left knee joint 3 days after TKA. (**D**) Lateral position of left knee joint 3 days after TKA.

Data availability statement

The raw data supporting the conclusions of this article will be made available by the authors, without undue reservation.

Ethics statement

The studies involving human participants were reviewed and approved by Ethics Committee of Affiliated Hospital of Qingdao University. The patients/participants provided their written informed consent to participate in this study. Written informed consent was obtained from the individual(s) for the publication of any potentially identifiable images or data included in this article.

Author contributions

Authors KSX, XZ, CW, and TBY designed the study; LZ and ZKR analyzed the data; KSX and TRW wrote the manuscript; YEZ and TBY supervised the study. All authors approved the final manuscript as submitted and agree to be accountable for all aspects of the work. All authors contributed to the article and approved the submitted version.

Acknowledgments

We would like to thank all the staff in the Department of Orthopedic, Affiliated Hospital of Qingdao University, for their contribution to our research.

Conflict of interest

The authors declare that the research was conducted in the absence of any commercial or financial relationships that could be construed as a potential conflict of interest.

Publisher's note

All claims expressed in this article are solely those of the authors and do not necessarily represent those of their affiliated organizations, or those of the publisher, the editors and the reviewers. Any product that may be evaluated in this article, or claim that may be made by its manufacturer, is not guaranteed or endorsed by the publisher.

References

1. Haddad B, Khan W, Mehta V, Mbubaegbu C, Qamar A. Bilateral simultaneous total knee arthroplasty: a patient-matched retrospective observational study. *Open Orthop J*. (2015) 9:499–503. doi: 10.2174/1874325001509010499

2. Douglas PM, Peter AD, Geoffrey H. Bilateral total knee arthroplasty: indications and complications. *Curr Opin Orthop*. (2003) 14(1):52–7. doi: 10.1097/00001433-200302000-00012

3. Di Martino A, Bordini B, Barile F, Ancarani C, Digennaro V, Faldini C. Unicompartmental knee arthroplasty has higher revisions than total knee arthroplasty at long term follow-up: a registry study on 6453 prostheses. *Knee Surg Sports Traumatol Arthrosc*. (2021) 29(10):3323–9. doi: 10.1007/s00167-020-06184-1

4. Brown NM, Sheth NP, Davis K, Berend ME, Lombardi AV, Berend KR, et al. Total knee arthroplasty has higher postoperative morbidity than unicompartmental knee arthroplasty: a multicenter analysis. *J Arthroplasty*. (2012) 27(8 Suppl):86–90. doi: 10.1016/j.arth.2012.03.022

5. Seo SS, Kim CW, Lee CR, Kwon YU, Oh M, Kim OG, et al. Long-term outcomes of unicompartmental knee arthroplasty in patients requiring high flexion: an average 10-year follow-up study. *Arch Orthop Trauma Surg*. (2019) 139(11):1633–9. doi: 10.1007/s00402-019-03268-7

6. Çankaya D, Aktı S, Ünal ŞB, Sezgin EA. Unicompartmental knee arthroplasty results in a better gait pattern than total knee arthroplasty: gait analysis with a smartphone application. *Jt Dis Relat Surg*. (2021) 32(1):22–7. doi: 10.5606/ehc.2021.79635

7. Hauer G, Sadoghi P, Bernhardt GA, Wolf M, Ruckenstuhl P, Fink A, et al. Greater activity, better range of motion and higher quality of life following unicompartmental knee arthroplasty: a comparative case-control study. *Arch Orthop Trauma Surg*. (2020) 140(2):231–7. doi: 10.1007/s00402-019-03296-3

8. Hiranaka T, Tanaka T, Fujishiro T, Anjiki K, Nagata N, Kitazawa D, et al. Is postoperative flexion angle genuinely better in unicompartmental knee arthroplasty than in total knee arthroplasty? A comparison between the knees in the same patients. *Knee*. (2020) 27(6):1907–13. doi: 10.1016/j.knee.2020.09.011

9. Pongcharoen B, Timjang J. The outcomes of mobile bearing unicompartmental knee arthroplasty and total knee arthroplasty on anteromedial osteoarthritis of the knee in the same patient. *Arch Orthop Trauma Surg*. (2020) 140(11):1783–90. doi: 10.1007/s00402-020-03527-y

10. Knifsund J, Niinimaki T, Nurmi H, Toom A, Keemu H, Laaksonen I. Functional results of total-knee arthroplasty versus medial unicompartmental arthroplasty: two-year results of a randomised, assessor-blinded multicentre trial[J]. *BMJ Open*. (2021) 11(6):e046731. doi: 10.1136/bmjopen-2020-046731

11. Insall JN, Dorr LD, Scott RD, Scott WN. Rationale of the knee society clinical rating system. *Clin Orthop Relat Res*. (1989) 248:13–4. doi: 10.1097/00003086-198911000-00004

12. Tan MWP, Ng SWL, Chen JY, Liow MHL, Lo NN, Yeo SJ. Long-Term functional outcomes and quality of life at Minimum 10-year follow-up after fixed-bearing unicompartmental knee arthroplasty and total knee arthroplasty for isolated medial compartment osteoarthritis. *J Arthroplasty*. (2021) 36(4):1269–76. doi: 10.1016/j.arth.2020.10.049

13. American Journal of physical medicine & rehabilitation. *Am J Phys Med Rehabil*. (2009) 88(11):884–6. doi: 10.1097/01.phm.0000363254.05054.91

14. Roos EM, Lohmander LS. The knee injury and osteoarthritis outcome score (KOOS): from joint injury to osteoarthritis. *Health Qual Life Outcomes*. (2003) 1:64. doi: 10.1186/1477-7525-1-64

15. Longo UG, Loppini M, Trovato U, Rizzello G, Maffulli N, Denaro V. No difference between unicompartmental versus total knee arthroplasty for the management of medial osteoarthritis of the knee in the same patient: a systematic review and pooling data analysis. *Br Med Bull*. (2015) 114(1):65–73. doi: 10.1093/bmb/ldv009

16. Costa CR, Johnson AJ, Mont MA, Bonutti PM. Unicompartmental and total knee arthroplasty in the same patient. *J Knee Surg*. (2011) 24(4):273–8. doi: 10.1055/s-0031-1280970

17. Dalury DF, Fisher DA, Adams MJ, Gonzales RA. Unicompartmental knee arthroplasty compares favorably to total knee arthroplasty in the same patient. *Orthopedics*. (2009) 32(4). orthosupersite.com/view.asp?rID=38057.

18. Laurencin CT, Zelicof SB, Scott RD, Ewald FC. Unicompartmental versus total knee arthroplasty in the same patient. A comparative study. *Clin Orthop Relat Res*. (1991) 273:151–6. doi: 10.1097/00003086-199112000-00023

19. Deshmukh RV, Scott RD. Unicompartmental knee arthroplasty: long-term results. *Clin Orthop Relat Res*. (2001) 392:272–8. doi: 10.1097/00003086-200111000-00035

20. Lombardi AV Jr, Berend KR, Walter CA, Aziz-Jacobo J, Cheney NA. Is recovery faster for mobile-bearing unicompartmental than total knee arthroplasty? *Clin Orthop Relat Res*. (2009) 467(6):1450–7. doi: 10.1007/s11999-009-0731-z

21. Saenz CL, McGrath MS, Marker DR, Seyler TM, Mont MA, Bonutti PM. Early failure of a unicompartmental knee arthroplasty design with an all-polyethylene tibial component. *Knee*. (2010) 17(1):53–6. doi: 10.1016/j.knee.2009.05.007

22. W-Dahl A, Robertsson O, Lidgren L. Surgery for knee osteoarthritis in younger patients. *Acta Orthop*. (2010) 81(2):161–4. doi: 10.3109/17453670903413186

23. Siman H, Kamath AF, Carrillo N, Harmsen WS, Pagnano MW, Sierra RJ. Unicompartmental knee arthroplasty vs total knee arthroplasty for medial compartment arthritis in patients older than 75 years: comparable reoperation, revision, and complication rates. *J Arthroplasty*. (2017) 32(6):1792–7. doi: 10.1016/j.arth.2017.01.020

frontiers | Frontiers in Surgery

TYPE Original Research
PUBLISHED 25 January 2023
DOI 10.3389/fsurg.2023.1003022

Check for updates

OPEN ACCESS

EDITED BY
Paphon Sa-ngasoongsong,
Mahidol University, Thailand

REVIEWED BY
Hong Chen,
First Affiliated Hospital of Chongqing Medical University, China
Lin Zheng,
Zhejiang University, China
Yan Wu,
Zhejiang Provincial Key Laboratory of Diagnosis and Treatment of Sports System Diseases, China

*CORRESPONDENCE
Yusheng Li
liyusheng@csu.edu.cn
Wenfeng Xiao
xiaowenfeng@csu.edu.cn

†These authors have contributed equally to this work and share first authorship

SPECIALTY SECTION
This article was submitted to Orthopedic Surgery, a section of the journal Frontiers in Surgery

RECEIVED 25 July 2022
ACCEPTED 02 January 2023
PUBLISHED 25 January 2023

CITATION
Cai Z, Yang Y, Liu D, Lu W, Pan L, He M, Xie W, Yu D, Li H, Jin H, Li Y and Xiao W (2023) The effect of hamstring donor-site block for functional outcomes and rehabilitation after anterior cruciate ligament reconstruction. Front. Surg. 10:1003022. doi: 10.3389/fsurg.2023.1003022

COPYRIGHT
© 2023 Cai, Yang, Liu, Lu, Pan, He, Xie, Yu, Li, Jin, Li and Xiao. This is an open-access article distributed under the terms of the Creative Commons Attribution License (CC BY). The use, distribution or reproduction in other forums is permitted, provided the original author(s) and the copyright owner(s) are credited and that the original publication in this journal is cited, in accordance with accepted academic practice. No use, distribution or reproduction is permitted which does not comply with these terms.

The effect of hamstring donor-site block for functional outcomes and rehabilitation after anterior cruciate ligament reconstruction

Zijun Cai[1,2†], Yuntao Yang[1,2†], Di Liu[1,2], Wenhao Lu[1,2], Linyuan Pan[1,2], Miao He[1,2], Wenqing Xie[1,2], Dengjie Yu[1,2], Hengzhen Li[1,2], Hongfu Jin[1,2], Yusheng Li[1,2*] and Wenfeng Xiao[1,2*]

[1]Department of Orthopedics, Xiangya Hospital, Central South University, Changsha, China, [2]National Clinical Research Center for Geriatric Disorders, Xiangya Hospital, Central South University, Changsha, China

Purpose: To determine the effect of local infiltration anesthesia (LIA) at the donor site combined with a femoral nerve block (FNB) on short-term postoperative pain, functional outcomes, and rehabilitation after arthroscopic hamstring tendon autograft anterior cruciate ligament reconstruction (ACLR).
Methods: This study was a single center, randomized controlled trial. Seventy-three subjects with ACL rupture were enrolled. Participants were randomly allocated to two groups, 47 in the experimental group (Group A) and 26 in the control group (Group B). All operations were performed under FNB. In Group A, 10 ml of 1% ropivacaine was injected precisely at the hamstring donor site. Patients in Group B were treated with the same amount of saline. Preoperatively and postoperatively, pain scores based on the numerical rating scale (NRS) and consumption of opioids were recorded. In addition, knee functions were assessed by the International Knee Documentation Committee Subjective Knee Form (IKDC), the Lysholm score, and the Knee injury and Osteoarthritis Outcome Score (KOOS) preoperatively and postoperatively at 1 and 3 months. In addition, we applied the KNEELAX3 arthrometer to evaluate the stability of the knee preoperatively and postoperatively so that subjective and objective knee conditions were obtained to help us assess knee recovery in a comprehensive manner.
Results: The hamstring donor-site block reduced pain within the first 12 postoperative hours. There were no significant differences between two groups in pain intensity preoperatively and equal to or greater than 24 hours postoperatively. Furthermore, there were no differences between the groups concerning knee functions preoperatively or in the short-term follow-up at 1 and 3 months.
Conclusion: LIA at the donor site can effectively improve the early postoperative pain of patients after ACLR and reduce the use of opioids without affecting the functional outcomes of the surgery.

KEYWORDS
anterior cruciate ligament, pain, post-operative rehabilitation, arthroscopy, femoral nerve block, local infiltration analgesia

Introduction

ACL injuries may account for 50% of sports-related injuries in high school athletes (1). Although there is not a single epidemiological survey that summarizes populations around the world, we can be certain, based on several local studies, that the incidence rate of ACL injuries is high worldwide. In the United States, it affects more than two hundred thousand people each year, with direct and indirect costs greater than $7 billion annually (1). In

Sweden, the overall incidence of ACL injury was 78 per 100,000 (2). In Finland, the total ACL injury incidence was about 23.3 per 100,000 person-years (3). Currently, ACLR is standard practice for athletes that wish to return to high-level activities. Hamstring tendon graft ACLR is one of the most common and effective orthopedic procedures. The all-inside technique (AIT) for ACLR is becoming increasingly popular because of its anatomical adaptability, low invasiveness, and rapid rehabilitation (4).

With the progress of modern medicine, the patient's comfort during the treatment process has been continuously considered. The pain has been recognized the fifth vital sign and it has received increasing attention in clinical diagnosis and treatment practice (5). Pain is one of the prominent complaints in patients after ACLR. Compared with other types of orthopedic sports surgery, ACLR causes not only more significant but also longer-lasting pain to patients, often throughout the entire rehabilitation process (6). Reasonable pain management can improve outcomes and a higher pain is often associated with more difficulties during rehabilitation, even in daily activities (7). Pain, together with other factors, are related to knee function.

A reasonable perioperative analgesia approach is necessary for faster rehabilitation and satisfaction. Currently, intravenous or oral opioids are frequently prescribed for postoperative pain control following ACLR (8). However, if the use of these drugs is not strictly controlled, it may not only increase the risk of various complications but also increase the possibility of drug dependence, abuse, and overdose (8). In the USA, it is estimated that opioid-related complications cost $78.5 billion every year (8, 9). There were approximately 49,680 deaths caused by opioid overdose in 2019, accounting for 70.6% of all drug overdose deaths (8, 10). There has been an increasing call to strengthen the management of opioid use and to take into account their possible harm to patients (8, 10). It is urgent to develop a novel and suitable approach to reduce postoperative pain in patients after ACLR that does not rely on opioids.

According to our clinical experience, the main sources of pain after ACLR include the following three points: the skin incision, the graft fixation positions, and the graft donor site. The former two cannot be avoided, so we focused on relieving the pain at the donor site. FNB has been shown to be an effective method for relieving postoperative pain (11). We believe that combining analgesia at the donor site with FNB may result in better outcomes. To date, there have been several relevant studies in favor of our perspective (12–15). However, few studies have compared the effect of injecting or not injecting local anesthesia to perform donor-site block on the postoperative condition of patients. With this study, we hope to fill the gap in knowledge in this area.

Pain assessment is usually derived from subjective statements rather than objective measurements (16). Thus, it is conceivable that the same level of pain may be described as different subjective feelings by different individuals. This problem does exist, but few scholars have suggested that it needs to be addressed in regard to pain-related research. To obtain a more objective pain assessment, a new preoperative evaluation program was introduced. The cold pressor test (CPT) is a research tool that can induce pain perception in humans (17). In this way, we were able to obtain the pain threshold and pain tolerance of each patient before the operation, which helped eliminate the influence of individual differences in pain perception on the study findings (17).

We aimed to determine the effect of LIA at the donor site combined with a FNB on short-term postoperative pain and the functional outcomes and rehabilitation after arthroscopic hamstring tendon autograft ACLR. We hypothesized that the combination of FNB and LIA can achieve better analgesic effect, but it is not enough to directly impact the postoperative rehabilitation speed.

Materials and methods

This research was designed as a randomized controlled trial. Patients were designed to be randomized to undergo either a hamstring donor-site block or isotonic sterile water of equal volume, in an around 2:1 ratio. A permuted block randomization scheme was used with block sizes of 3. All operations were performed by the same experienced orthopedic surgeon in our hospital. The study protocol was approved by the institutional ethics committee. Informed consent for participation in the study was obtained from all patients before randomization.

Patients

Patients 15–50 years of age who were diagnosed with ACL rupture, usually confirmed by means of history, physical examination, and magnetic resonance imaging, were screened for eligibility. Participants were randomly allocated to two groups (**Figure 1**). Baseline data were collected. A total of 73 (originally 76) patients with an American Society of Anesthesiologists (ASA) physical status classification of I–III who satisfied the inclusion criteria of our study underwent arthroscopic ACLR using hamstring tendon autografting for ACL tears. Among them, 47 (excluding 3 withdrawing from the study) patients in Group A were given a 1% 10 ml ropivacaine injection right at the donor site, while the other 26 patients in Group B were given the same volume of saline.

The inclusion criteria were primary ACLR and a healthy contralateral knee. Exclusion criteria included refusal of surgical treatment; severe concomitant injuries; concurrently performed other different surgical procedures; weight less than 35 kg; body mass index (BMI) greater than 45 kg/m^2; ASA physical class greater than 4; allergy to local anesthetics; preexisting neurologic deficit; undergoing revision surgery; any opioid use within the previous 3 months; inability to understand the NRS; or suffering from serious or chronic conditions that may have an impact on surgical treatment, postoperative recovery or regular follow-up. After returning to the ward after surgery, tramadol was orally administered if the pain at rest exceeded 3 on NRS. A unified analgesic scheme and postoperative rehabilitation plan were adopted during the perioperative period.

Evaluations

The IKDC, the Lysholm score, and the KOOS were used to examine the functional outcomes preoperatively, at the 1-month

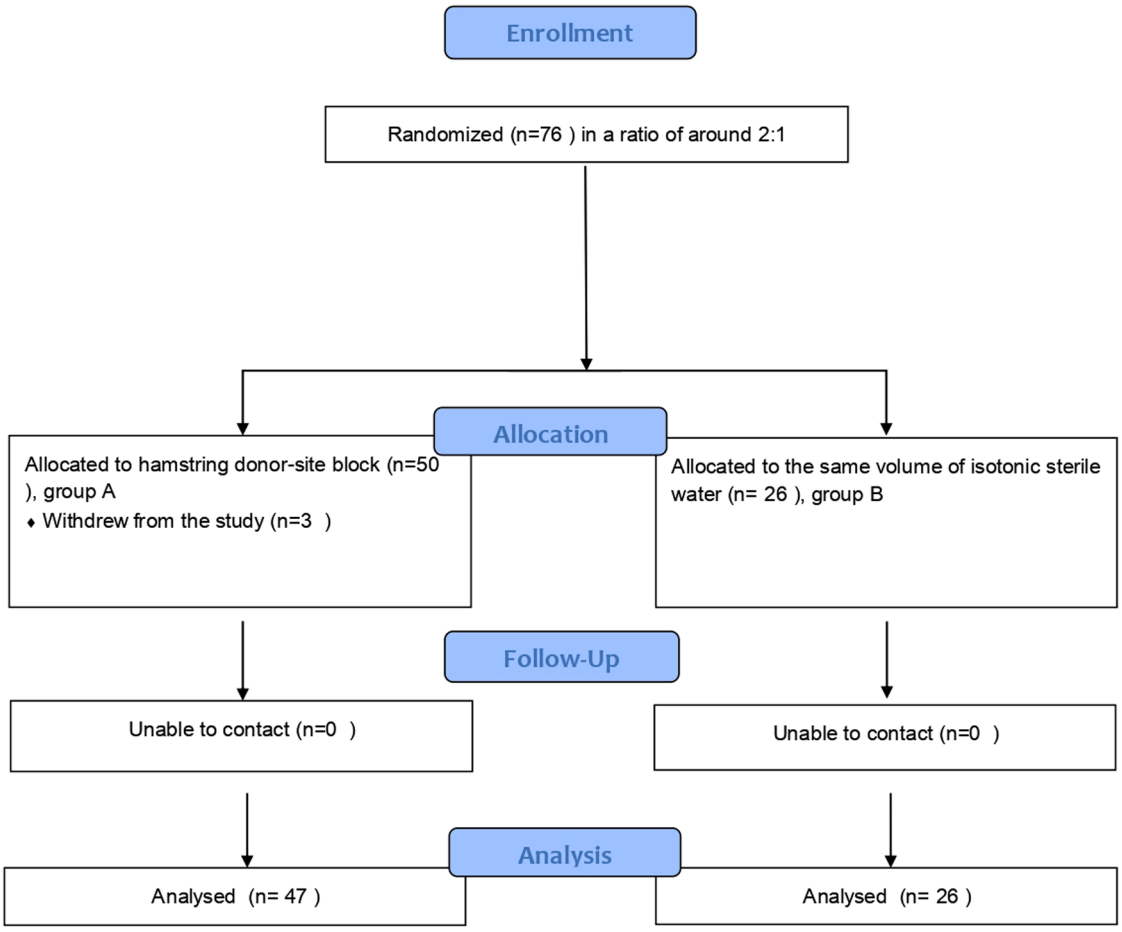

FIGURE 1
Flowchart of study participants.

follow-up, and at the 3-month follow-up. In addition, the degree of anterior tibial translocation was measured with a KNEELAX3 arthrometer (Monitored Rehab Systems, Haarlem, The Netherlands) (18) preoperatively, at the 1-month follow-up, and at the 3-month follow-up. As KT-1000/2000, it was also considered valid and reliable, with very similar operating process (19, 20). Both knees were measured with different anterior force with the maximum of 132 N applied to the proximal tibia at 20° of knee flexion in a supine position. Actually, this helped quantify the Lachman test as a result. The difference in the degree of anterior translocation between the nonaffected side and affected side was expressed as in millimeters (18). To minimize any susceptibility bias, all evaluations were performed by the same person. According to the KNEELAX3 instructions, it is recommended that patients be measured within grade 3 within 6 months after surgery.

Pain management success was assessed by the consumption of opioids (tramadol) during the patient's hospitalization and pain scores on an NRS, an 11-point scale where 0 indicates no pain and 10 indicates the worst imaginable pain (21), which is considered comparable to the visual analog scale (VAS) (22). Opioids were provided only if the patient made a strong request and the NRS score was higher than 3. Patients were asked to give a score based on NRS preoperatively and at 2, 4, 6, 12, 24, 48 h, 1 month, and 3 months postoperatively. CPT was performed before surgery.

Surgical technique

AIT for ACLR is becoming increasingly popular and it has been described extensively in previous papers (23, 24). Here, only those parts relevant to the research topic are retained.

All patients received a preoperative FNB using an ultrasound-guided technique. One of the highlights of this study is the process of harvesting the hamstring tendon and subsequent local anesthesia. The medial tibial tuberosity incision was made where the hamstring tendon is removed with our self-developed tendon retriever. The surgeon initially obtained the tendon, while not moving the retriever, and slowly inject the 10 ml of ropivacaine. Then, the analgesic continued to be injected while withdrawing the retriever, and finally, the ropivacaine would fill the entire donor site (**Figure 2**).

A brief introduction to our novel tendon retriever

We designed a novel tendon retriever capable of precisely injecting local anesthetics, as shown in **Figure 3**. The outer tube body has a hollow channel and a positioning wire perforation

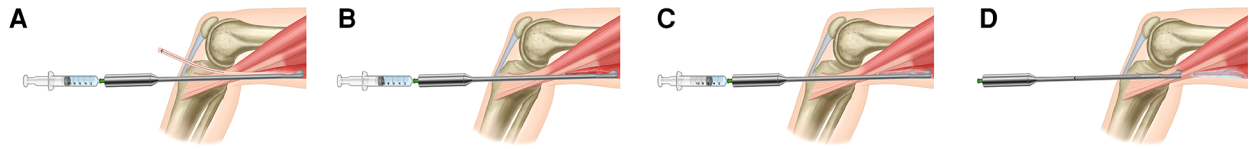

FIGURE 2
Precise donor-site block steps; (A) ready to retrieve tendon, (B) tendon removed, (C) ropivacaine injected right at the deepest point of tendon removal site, (D) the whole tendon removal site full of ropivacaine.

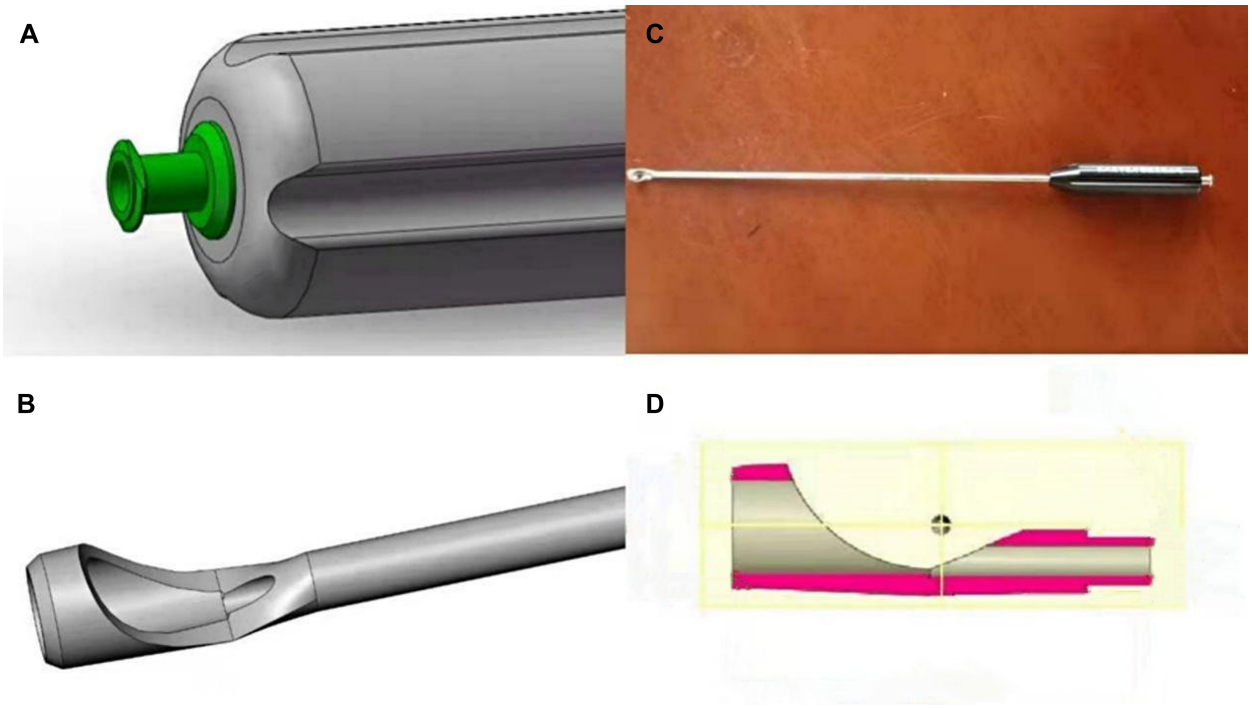

FIGURE 3
Our novel tendon retriever; (A) end of tendon retriever, (B) top of tendon retriever, (C) overall view, (D) internal structure..

along the axis and a plurality of anesthesia channels extending along the axis and with outlets located at different heights of the outer tube body. The inner end of the tendon collection rod body has an opening ring that can form a closed ring with the outer tube body, and the tendon collection rod body has a penetration hole extending along the axis. The inner end of the positioning member has a C-shaped positioning ring, a flexible cross-file is provided inside the C-shaped positioning ring. One set of rings is fixed to the C-shaped positioning ring, and the other set of rings is set on the C-shaped positioning ring. The restriction structure set in the perforation of the positioning wire is used to clamp or release the positioning member, and the C-shaped positioning ring is fixed to the end of the positioning rod.

Cold pressor test

The CPT was first created and utilized as a tool by Edgar A. Hines, Jr. to study blood pressure variability (17). During the test, the patient needs to put the whole palm of their hand into cold water that is constantly circulating through ice. Since this test is based on hemodynamic response to peripheral cold stimulation, it doesn't matter which hand people would use. The experience is made more painful by the presence of the circulating pump that prevents the buildup of a warmer layer of water around the forearm. With the extension of time, the pain in the palm of the hand will become more intense until the patient cannot tolerate it and pulls their hand out of the water. Previous studies have shown that the CPT can be used to help surgeons better cope with pain problems in patients (25). CPT can be used not only to predict the degree of postoperative pain, but also to help standardize the obtained pain data (25).

The general flow of this test is as follows. A bucket full of cold water with ice should be prepared to keep the temperature constant. The water temperature was monitored (maintained at 4°C), as a 2°C difference in temperature can affect tolerance time and pain intensity (25). In addition, the bucket needs to be equipped with a device that allows the water to circulate continuously to avoid the water temperature in the area near the

palm of the hand being slightly higher than the preset water temperature. In a word, as the ice melted, the surface temperature of the water was maintained, and in addition the circulating pump could make the temperature anywhere in the water the same. The participant would be briefed by the observer on how to take the test in advance. The patient will be asked to extend their hand into the ice water to ensure that the water floods the straight wrist transverse striae while the observer starts timing. The participant informs the observer immediately when their hand sensation changes from cold to pain, and the time difference between the beginning of the test and the first report of pain is recorded as that participant's "pain threshold" (25, 26). They are instructed to voluntarily withdraw their hand at the point at which the pain becomes "unbearable"—the time between the beginning of the test and this voluntary withdrawal is recorded as that participant's "pain tolerance" (25, 26). To ensure safety, the test is forcibly terminated if the participant does not remove their hand within 3 min.

Postoperative rehabilitation

Within 1 week after surgery, complete knee extension was required during bed rest, quadriceps contraction and straight leg raising training were performed, ankle flexion and extension activities were performed, and passive knee flexion was performed. Partial weight-bearing with crutches when walking on the ground; passive flexion of the knee joint to 90 degrees was started on the 8th day, and full weight-bearing standing and walking with detached crutches were trained; at the end of the 2nd week, passive flexion of the knee joint to 120 degrees and full weight-bearing walking were required; fixed bicycle exercises, terminal extension and balance exercises were performed at 3–6 weeks; at 7–12 weeks, active and passive knee flexion, range of motion consistent with the unaffected side, knee extension and resistance knee extension, and full squatting were performed. Full return to full activities of daily living started 3 months and gradual return to sports started 9 months.

Statistical analysis

Calculation of the sample size was based on an expected difference of two points on the NRS score between the groups. With a power of 0.80 and $\alpha = 0.05$, a sample size of at least 25 patients per group was obtained. SPSS 26.0 software was used for statistical analysis of the data. Measures were tested for normality using the D'Agostino test, and normally distributed indicators are expressed as the mean ± standard deviation (SD) and compared between groups using the independent samples *t*-test; nonnormally distributed indicators are expressed as the median and interquartile range (IQR) and compared between groups using the Mann–Whitney *U* test. Multifactorial logistic regression analysis was performed to assess the correlation between NRS scores and local anesthesia or not within 48 h preoperatively and postoperatively after adjusting for confounders. Statistical data are expressed as percentages (%), and comparisons between groups were made by the chi-square test or Fisher's exact probability method. $P < 0.05$ was considered a statistically significant difference.

Results

From 2020 to 2022, 73 patients were included in this study. The baseline characteristics were similar between the two groups concerning gender, age, BMI, time from injury to hospital admission, pain tolerance, and intraoperative tourniquet application time (Table 1). However, the pain threshold was higher in the LIA group (55.87 ± 6.18 vs. 50.85 ± 4.42, $P < 0.001$). Within the first 12 h after surgery, pain level was significantly lower in Group A than in Group B ($P < 0.05$). There was no difference in pain scores preoperatively and at the time point greater than or equal to 24 h postoperatively (Table 2), but the consumption of opioids during the patient's hospitalization showed a significant difference between groups ($P < 0.05$) (Table 3). Since we collected

TABLE 1 Patient characteristics ($n = 73$).

	Group A ($n = 47$)	Group B ($n = 26$)	$T/U/c^2$	*P* value
Gender			1.780	0.182
Male	31 (66.0%)	13 (50.0%)		
Female	16 (34.0%)	13 (50.0%)		
Age (years)	23.00 (20.00–25.00)	24.50 (20.75–26.25)	737.000	0.145
Time from injury to hospital admission (days)	30.00 (7.00–150.00)	30.99 (11.75–157.50)	670.500	0.492
Pain threshold (seconds)	55.87 ± 6.18	50.85 ± 4.42	3.656	<0.001
Pain tolerance (seconds)	107.72 ± 6.53	109.19 ± 7.40	−0.877	0.383
BMI (kg/m^2)	22.40 (21.30–23.90)	23.50 (21.27–25.02)	733.500	0.158
Tourniquet time (minutes)	82.00 (79.00–86.00)	83.00 (79.00–87.00)	655.000	0.610

TABLE 2 Patient-reported NRS.

	Group A	Group B	*T* value	*P* value
NRS (preoperatively)	3.06 ± 1.90	3.15 ± 1.22	−0.245	0.807
NRS (2 h postoperatively)	2.62 ± 1.69	3.77 ± 1.86	−2.692	0.009
NRS (4 h postoperatively)	2.98 ± 1.46	4.23 ± 1.82	−3.203	0.002
NRS (6 h postoperatively)	3.87 ± 1.20	4.96 ± 1.54	−3.343	0.001
NRS (12 h postoperatively)	5.55 ± 1.21	6.54 ± 1.27	−3.222	0.002
NRS (24 h postoperatively)	3.89 ± 1.31	4.12 ± 1.18	−0.719	0.475
NRS (48 h postoperatively)	3.04 ± 1.08	3.12 ± 1.07	−0.276	0.783

TABLE 3 Opioids consumption.

	Group A ($n = 47$)	Group B ($n = 26$)	*U*	*P* value
Opioids consumption (mg)	50.00 (40.00–60.00)	60.00 (47.50–72.50)	905.500	0.001

TABLE 4 Regression analysis of postoperative NRS.

NRS	β	SE	t	P	β	95% CI
2 h	−0.930	0.465	−2.000	0.049	−0.246	−1.858 to −0.003
4 h	−0.965	0.420	−2.296	0.025	−0.274	−1.804 to −0.127
6 h	−0.915	0.354	−2.585	0.012	−0.310	−1.621 to −0.209
12 h	−0.798	0.326	−2.447	0.017	−0.293	−1.449 to −0.148
24 h	−0.085	0.336	−0.253	0.801	−0.033	−0.755 to 0.586
48 h	0.055	0.287	0.193	0.848	0.025	−0.517 to 0.627

TABLE 5 NRS, IKDC, lysholm, KOOS, and KNEELAX evaluation preoperatively.

	Group A	Group B	T/U	P value
NRS	3.06 ± 1.90	3.15 ± 1.22	−0.245	0.807
IKDC	51.68 ± 12.65	50.77 ± 13.03	0.292	0.771
Lysholm	54.47 ± 21.31	50.27 ± 14.49	0.895	0.374
KOOS				
Symptoms	61.96 ± 18.64	63.96 ± 12.58	−0.489	0.626
Pain	69.91 ± 13.77	70.27 ± 10.09	−0.115	0.909
Function in daily living	79.81 ± 10.30	80.27 ± 7.61	−0.200	0.842
Sports/recreation	47.55 ± 25.72	48.46 ± 26.06	−0.144	0.886
Quality of life	31.79 ± 10.68	33.08 ± 12.55	−0.464	0.644
KNEELAX (mm)				
Affected side	6.69 ± 1.19	6.55 ± 1.41	0.432	0.667
Healthy side	1.80 ± 0.50	1.79 ± 0.51	0.113	0.910

objective data on pain perception (CPT), so standardizing the scores of the NRS based on pain perception could be considered. After regression analysis, there was no change in the conclusion in terms of pain (Table 4). This study showed no differences in functional outcomes between groups at all follow-up time points (Tables 5–7). No complications related to the anesthesia or nerve block were observed.

Discussion

The most important finding of this study was a statistically significant reduction in postoperative pain scores with the additional use of donor-site block. The significant complications of ACLR consist of infection, hematoma or hemarthrosis, failure of the surgery, etc. (27). However, based on our experience in clinical practice, cases most commonly seen contain quadriceps weakness, restriction of knee flexion or extension, and donor-site or incision pain. Pain can often lead to the exacerbation of the first two issues. Not only is pain subjectively troubling for the patient, but it can also objectively hinder rehabilitation efforts, lead to a decreased range of motion, and have an overall negative effect on surgical outcomes (14).

To date, few studies have been conducted on the effect of LIA at the donor site combined with FNB on short-term postoperative pain and functional outcomes after arthroscopic hamstring tendon autograft ACLR. The reduction of pain level was obvious within 12 hours after ACLR but this effect was no longer working beyond

TABLE 6 NRS, IKDC, lysholm, KOOS, and KNEELAX evaluation 1 month postoperatively.

	Group A	Group B	T/U	P value
NRS	2.17 ± 1.47	2.58 ± 1.77	−1.048	0.298
IKDC	81.02 ± 12.56	81.42 ± 14.70	−0.123	0.902
Lysholm	81.02 ± 5.82	81.88 ± 5.53	−0.626	0.534
KOOS				
Symptoms	81.70 ± 7.61	83.38 ± 5.86	−0.977	0.332
Pain	82.28 ± 6.56	83.50 ± 7.30	−0.733	0.466
Function in daily living	83.85 ± 9.16	85.69 ± 7.10	−0.886	0.378
Sports/recreation	81.91 ± 10.19	83.85 ± 6.67	−0.867	0.389
Quality of life	81.26 ± 8.67	81.81 ± 9.18	−0.255	0.799
Pain improvement (cm)	8.00 (7.50–8.40)	7.70 (7.50–8.20)	533.500	0.371
Quality of life improvement (cm)	7.70 (7.20–8.20)	7.50 (7.37–7.70)	496.500	0.186
KNEELAX (mm)				
Affected side	1.74 ± 0.49	1.84 ± 0.48	−0.845	0.401
Healthy side	1.81 ± 0.50	1.78 ± 0.50	0.247	0.806

TABLE 7 NRS, IKDC, lysholm, KOOS, and KNEELAX evaluation 3 months postoperatively.

	Group A	Group B	T/U	P value
NRS	1.68 ± 1.23	1.69 ± 1.56	−0.034	0.973
IKDC	83.89 ± 11.08	85.69 ± 13.30	−0.618	0.539
Lysholm	83.68 ± 5.17	85.81 ± 5.72	−1.619	0.110
KOOS				
Symptoms	84.89 ± 6.67	86.58 ± 5.42	−1.100	0.275
Pain	86.19 ± 7.45	87.42 ± 6.28	−0.713	0.478
Function in daily living	89.74 ± 5.59	90.38 ± 5.36	−0.475	0.636
Sports/recreation	87.77 ± 6.74	88.85 ± 4.75	−0.723	0.472
Quality of life	86.60 ± 7.51	87.92 ± 5.00	−0.806	0.423
Pain improvement (cm)	8.30 (8.00–8.60)	8.10 (7.90–8.50)	471.500	0.106
Quality of life improvement (cm)	8.00 (7.60–8.40)	8.05 (7.47–8.40)	550.000	0.481
KNEELAX (mm)				
Affected side	1.79 ± 0.49	1.63 ± 0.51	1.330	0.188
Healthy side	1.84 ± 0.48	1.75 ± 0.50	0.740	0.462

the period. In addition, the additional donor site block after FNB did not affect any other subjective or objective outcomes. However, an assumption should not be made arbitrarily that donor-site LIA did not have any positive effects on functional recovery since the first assessment of function was at 1 month postoperatively. Less pain is often accompanied by a greater range of motion. Additional block could provide comfort to the affected region and a greater range of motion during the immediate postoperative course.

The study we conducted was similar to Bushnell et al. (14) in 2010, and they found a remarkable decrease in VAS score among patients treated with both LIA and FNB compared with FNB alone. Our study makes the same conclusions. However, their study may be associated with some bias because of the absence of opioid consumption records, an insufficient follow-up period, and a lack of baseline pain scores preoperatively. Therefore, we assessed preoperative pain scores as well as the pain threshold and pain tolerance, extended the follow-up time, recorded opioid consumption, and further took into consideration subjective and objective functional outcomes to improve the study design to eventually make a more comprehensive evaluation of the effect of a donor site block. Another highlight of our study is the utilization of the novel tendon retriever that we invented, which ensures precise anesthesia at the donor site. As the core variable in this study, it deserves to be made as accurate as possible. The tools and methods for implementing LIA have not been harmonized between different studies, which may have an impact on the correctness of the trial conclusions. Previous similar studies have always ignored this point.

Considering that gender is one of the confounders of pain (28), the baseline characteristics of the subjects were analyzed. The slight baseline difference between the two groups probably did not bias our results.

The best choice of anesthetic for local infiltration has not yet been determined, with bupivacaine and ropivacaine being commonly used. Bupivacaine has a half-life of 3.5 h, whereas ropivacaine is a long-acting local anesthetic with a similar structure to bupivacaine and a half-life of 4.2 h. Ropivacaine has the advantage of being less toxic, and its blockade of sensation is stronger than its block against movement (29), which is why we selected it.

It was expected that the range of motion would be highly associated with pain intensity. Based on our observations of postoperative patients, patients with less pain did have a greater knee range of motion and were more comfortable moving their knees. Therefore, range of motion was not specifically described in this study.

Less early postoperative pain could be observed without the use of a tourniquet during routine knee arthroscopy (30), suggesting the potential impact of the application of a tourniquet intraoperatively on postoperative rehabilitation, but some studies have noted that a tourniquet use of less than approximately 2 h had no effect on the strength of the lower extremity and pain scores (31, 32). There was no significant difference in the mean tourniquet times between the two groups in this study, so this potential interfering factor was eliminated. It is worth noting that Guler et al. (33) showed that a local anesthetic injection is more beneficial after tourniquet release. Thus, future studies may consider investigating the timing of the injection as a factor in pain control.

Several papers previously reported an abnormal sensation in the lower extremities after surgery. This complication often occurs because of injury to the lateral sural cutaneous or saphenous nerve due to the incision or intraoperative retraction (14). In our study, there were no neurological problems related to the use of the donor-site injection technique.

There are some limitations of this study. There was no intentional blinding of patients, doctors, or nurses in the postanesthesia care unit. Moreover, patient satisfaction during the whole course, speed of recovery, and the immediate postoperative condition of the body and knee could not be presented merely according to our study data.

Conclusion

The simplicity of the donor-site block technique warrants its extensive application. It could effectively improve the early postoperative pain of patients after ACLR and reduce the use of opioids, without affecting follow-up functional outcomes. Future related studies with larger samples may help confirm its beneficial effect.

Data availability statement

The data supporting the findings of this study are available from the corresponding author, upon reasonable request.

Ethics statement

The studies involving human participants were reviewed and approved by the institutional ethics committee of Xiangya Hospital of Central South University (approval number: 202110105).

Author contributions

ZC: design, manuscript writing. YY: provision of study material, collection, and assembly of data. WX (Wenqing Xie), MH, DL, and DY were responsible for revising the article and data acquisition. WL and HL: provision of relevant references. LP and HJ: data analysis and interpretation. WX (Wenfeng Xiao) and YL: conception, financial support, administrative support. All authors contributed to the article and approved the submitted version.

Funding

This work was supported by the National Natural Science Foundation of China (No. 82272611, 82072506, 81874030), National Clinical Research Center for Geriatric Disorders

(Xiangya Hospital, No. 2021KFJJ02), National Clinical Research Center for Orthopedics, Sports Medicine and Rehabilitation (No. 2021-NCRC-CXJJ-PY-40), Provincial Clinical Medical Technology Innovation Project of Hunan (No. 2020SK53709), Innovation-Driven Project of Central South University (No. 2020CX045), the Independent Exploration, Innovation Project for Postgraduate Students of Central South University (No. 2021zzts1030, 2021zzts1037, 2021zzts1024) and the Hunan Provincial Innovation Foundation for Postgraduate (CX20210360).

Acknowledgments

Everyone who contributed significantly to this study has been listed.

Conflict of interest

The authors declare that the research was conducted in the absence of any commercial or financial relationships that could be construed as a potential conflict of interest.

Publisher's note

All claims expressed in this article are solely those of the authors and do not necessarily represent those of their affiliated organizations, or those of the publisher, the editors and the reviewers. Any product that may be evaluated in this article, or claim that may be made by its manufacturer, is not guaranteed or endorsed by the publisher.

References

1. Kaeding CC, Léger-St-Jean B, Magnussen RA. Epidemiology and diagnosis of anterior cruciate ligament injuries. *Clin Sports Med*. (2017) 36(1):1–8. doi: 10.1016/j.csm.2016.08.001

2. Nordenvall R, Bahmanyar S, Adami J, Stenros C, Wredmark T, Felländer-Tsai L. A population-based nationwide study of cruciate ligament injury in Sweden, 2001–2009: incidence, treatment, and sex differences. *Am J Sports Med*. (2012) 40 (8):1808–13. doi: 10.1177/0363546512449306

3. Weitz FK, Sillanpää PJ, Mattila VM. The incidence of paediatric acl injury is increasing in Finland. *Knee Surg Sports Traumatol Arthrosc*. (2020) 28(2):363–8. doi: 10.1007/s00167-019-05553-9

4. Yang YT, Cai ZJ, He M, Liu D, Xie WQ, Li YS, et al. All-inside anterior cruciate ligament reconstruction: a review of advance and trends. *Front Biosci*. (2022) 27(3):91. doi: 10.31083/j.fbl2703091

5. Rogers MP, Kuo PC. Pain as the fifth vital sign. *J Am Coll Surg*. (2020) 231(5):601–2. doi: 10.1016/j.jamcollsurg.2020.07.508

6. Marques FDS, Barbosa PHB, Alves PR, Zelada S, Nunes R, de Souza MR, et al. Anterior knee pain after anterior cruciate ligament reconstruction. *Orthop J Sports Med*. (2020) 8(10):2325967120961082. doi: 10.1177/2325967120961082

7. Tichonova A, Rimdeikienė I, Petruševičienė D, Lendraitienė E. The relationship between pain catastrophizing, kinesiophobia and subjective knee function during rehabilitation following anterior cruciate ligament reconstruction and meniscectomy: a pilot study. *Medicina*. (2016) 52(4):229–37. doi: 10.1016/j.medici.2016.07.005

8. Sayegh ET, Otto TS, Garvey KD, Martin A, Lowenstein NA, Matzkin EG. Defining the opioid requirement in anterior cruciate ligament reconstruction. *J Am Acad Orthop Surg Glob Res Rev*. (2022) 6(1). doi: 10.5435/JAAOSGlobal-D-21-00298

9. Maiese BA, Pham AT, Shah MV, Eaddy MT, Lunacsek OE, Wan GJ. Hospitalization costs for patients undergoing orthopedic surgery treated with intravenous Acetaminophen (iv-apap) plus other iv analgesics or iv opioid monotherapy for postoperative pain. *Adv Ther*. (2017) 34(2):421–35. doi: 10.1007/s12325-016-0449-8

10. Blendon RJ, Benson JM. The public and the opioid-abuse epidemic. *N Engl J Med*. (2018) 378(5):407–11. doi: 10.1056/NEJMp1714529

11. Behera SK, Gunupuru B, Sahu L, Das S. Peripheral nerve stimulator versus ultrasound-guided femoral nerve block for knee arthroscopy procedures: a randomized controlled trial. *Cureus*. (2022) 14(11):e32043. doi: 10.7759/cureus.32043

12. Kristensen PK, Pfeiffer-Jensen M, Storm JO, Thillemann TM. Local infiltration analgesia is comparable to femoral nerve block after anterior cruciate ligament reconstruction with hamstring tendon graft: a randomised controlled trial. *Knee Surg Sports Traumatol Arthrosc*. (2014) 22(2):317–23. doi: 10.1007/s00167-013-2399-x

13. Faunø P, Lund B, Christiansen SE, Gjøderum O, Lind M. Analgesic effect of hamstring block after anterior cruciate ligament reconstruction compared with placebo: a prospective randomized trial. *Arthroscopy*. (2015) 31(1):63–8. doi: 10.1016/j.arthro.2014.07.024

14. Bushnell BD, Sakryd G, Noonan TJ. Hamstring donor-site block: evaluation of pain control after anterior cruciate ligament reconstruction. *Arthroscopy*. (2010) 26 (7):894–900. doi: 10.1016/j.arthro.2009.11.022

15. Yung EM, Brull R, Albrecht E, Joshi GP, Abdallah FW. Evidence basis for regional anesthesia in ambulatory anterior cruciate ligament reconstruction: part iii: local instillation analgesia-a systematic review and meta-analysis. *Anesth Analg*. (2019) 128 (3):426–37. doi: 10.1213/ane.0000000000002599

16. Karos K, Alleva JM, Peters ML. Pain, please: an investigation of sampling bias in pain research. *J Pain*. (2018) 19(7):787–96. doi: 10.1016/j.jpain.2018.02.011

17. Lamotte G, Boes CJ, Low PA, Coon EA. The expanding role of the cold pressor test: a brief history. *Clin Auton Res*. (2021) 31(2):153–5. doi: 10.1007/s10286-021-00796-4

18. Li B, Wang GB, Wang YF, Zhou BZ. Effects of pre-operative knee laxity on clinical outcomes after partial anterior cruciate ligament reconstruction. *Knee*. (2018) 25 (3):445–52. doi: 10.1016/j.knee.2018.02.012

19. Taketomi S, Inui H, Yamagami R, Kawaguchi K, Nakazato K, Kono K, et al. Length of the tendon within the tibial tunnel affects tibial tunnel widening following anatomic anterior cruciate ligament reconstruction using a bone-patellar tendon-bone graft. *J Knee Surg*. (2020) 33(5):445–51. doi: 10.1055/s-0039-1681064

20. Taketomi S, Inui H, Yamagami R, Shirakawa N, Kawaguchi K, Nakagawa T, et al. Bone-patellar tendon-bone autograft versus hamstring tendon autograft for anatomical anterior cruciate ligament reconstruction with three-dimensional validation of femoral and tibial tunnel positions. *J Knee Surg*. (2018) 31(9):866–74. doi: 10.1055/s-0037-1615813

21. Tada M, Yamada N, Matsumoto T, Takeda C, Furukawa TA, Watanabe N. Ultrasound guidance versus landmark method for peripheral venous cannulation in adults. *Cochrane Database Syst Rev*. (2022) 12(12):Cd013434. doi: 10.1002/14651858.CD013434.pub2

22. Williamson A, Hoggart B. Pain: a review of three commonly used pain rating scales. *J Clin Nurs*. (2005) 14(7):798–804. doi: 10.1111/j.1365-2702.2005.01121.x

23. Wilson AJ, Yasen SK, Nancoo T, Stannard R, Smith JO, Logan JS. Anatomic all-inside anterior cruciate ligament reconstruction using the translateral technique. *Arthrosc Tech*. (2013) 2(2):e99–e104. doi: 10.1016/j.eats.2012.12.002

24. Schurz M, Tiefenboeck TM, Winnisch M, Syre S, Plachel F, Steiner G, et al. Clinical and functional outcome of all-inside anterior cruciate ligament reconstruction at a minimum of 2 years' follow-up. *Arthroscopy*. (2016) 32(2):332–7. doi: 10.1016/j.arthro.2015.08.014

25. MacLachlan C, Shipton EA, Wells JE. The cold pressor test as a predictor of prolonged postoperative pain, a prospective cohort study. *Pain Ther*. (2016) 5 (2):203–13. doi: 10.1007/s40122-016-0056-z

26. Birnie KA, Petter M, Boerner KE, Noel M, Chambers CT. Contemporary use of the cold pressor task in pediatric pain research: a systematic review of methods. *J Pain*. (2012) 13(9):817–26. doi: 10.1016/j.jpain.2012.06.005

27. de Sa D, Shanmugaraj A, Weidman M, Peterson DC, Simunovic N, Musahl V, et al. All-inside anterior cruciate ligament reconstruction-a systematic review of techniques, outcomes, and complications. *J Knee Surg*. (2018) 31(9):895–904. doi: 10.1055/s-0038-1627446

28. Schindler M, Schmitz S, Reinhard J, Jansen P, Grifka J, Benditz A. Pain course after total knee arthroplasty within a standardized pain management concept: a prospective observational study. *J Clin Med*. (2022) 11(23). doi: 10.3390/jcm11237204

29. Winnie L, Kao YH, Liao CC, Tamura T, Chang ML, Hsieh KY. Comparative analgesic efficacies of ropivacaine and bupivacaine for postoperative Rectus sheath block in paediatric abdominal surgery: a meta-analysis of randomized controlled trial and retrospective cohort studies. *Pain Res Manag*. (2021) 2021:5535730. doi: 10.1155/2021/5535730

30. Kirkley A, Rampersaud R, Griffin S, Amendola A, Litchfield R, Fowler P. Tourniquet versus no tourniquet use in routine knee arthroscopy: a prospective, double-blind, randomized clinical trial. *Arthroscopy*. (2000) 16(2):121–6. doi: 10.1016/s0749-8063(00)90024-0

31. Nicholas SJ, Tyler TF, McHugh MP, Gleim GW. The effect on leg strength of tourniquet use during anterior cruciate ligament reconstruction: a prospective randomized study. *Arthroscopy*. (2001) 17(6):603–7. doi: 10.1053/jars.2001.24854

32. Johnson DS, Stewart H, Hirst P, Harper NJ. Is tourniquet use necessary for knee arthroscopy? *Arthroscopy*. (2000) 16(6):648–51. doi: 10.1053/jars.2000.4826

33. Guler G, Karaoglu S, Akin A, Dogru K, Demir L, Madenoglu H, et al. When to inject analgesic agents intra-articularly in anterior cruciate ligament reconstruction: before or after tourniquet releasing. *Arthroscopy*. (2004) 20(9):918–21. doi: 10.1016/j.arthro.2004.08.019

frontiers | Frontiers in Surgery

TYPE Original Research
PUBLISHED 23 February 2023
DOI 10.3389/fsurg.2023.961188

Check for updates

OPEN ACCESS

EDITED BY
Paphon Sa-ngasoongsong,
Mahidol University, Thailand

REVIEWED BY
Angelo Vasiliadis,
Aristotle University of Thessaloniki, Greece
Osvaldo Mazza,
Bambino Gesù Children's Hospital (IRCCS), Italy

*CORRESPONDENCE
Weili Fu
✉ foxwin2008@163.com

†These authors have contributed equally to this work

SPECIALTY SECTION
This article was submitted to Orthopedic Surgery, a section of the journal Frontiers in Surgery

RECEIVED 04 June 2022
ACCEPTED 08 February 2023
PUBLISHED 23 February 2023

CITATION
Wu S, Wang H, Zhu Y and Fu W (2023) A retrospective case series of the treatment of spontaneous quadriceps tendon rupture in patients with uremia and secondary hyperparathyroidism.
Front. Surg. 10:961188.
doi: 10.3389/fsurg.2023.961188

COPYRIGHT
© 2023 Wu, Wang, Zhu and Fu. This is an open-access article distributed under the terms of the Creative Commons Attribution License (CC BY). The use, distribution or reproduction in other forums is permitted, provided the original author(s) and the copyright owner(s) are credited and that the original publication in this journal is cited, in accordance with accepted academic practice. No use, distribution or reproduction is permitted which does not comply with these terms.

A retrospective case series of the treatment of spontaneous quadriceps tendon rupture in patients with uremia and secondary hyperparathyroidism

Shuang Wu[1†], Huihui Wang[2†], Yanlin Zhu[1] and Weili Fu[1*]

[1]Department of Orthopedics, West China Hospital, Sichuan University, Chengdu, China, [2]Department of Orthopedics, Provincial Orthopaedics Hospital, Chengdu, China

Background: Spontaneous quadriceps tendon rupture (QTR) is a rare complication of uremia. Secondary hyperparathyroidism (SHPT) is considered the leading cause of QTR in uremia patients. QTR in patients with uremia and SHPT are treated with active surgical repair along with the treatment of SHPT using medication or parathyroidectomy (PTX). The impact of PTX for SHPT on tendon healing remains unclear. The purpose of this study was to introduce surgical procedures for QTR and to determine the functional recovery of the repaired quadriceps tendon (QT) after PTX.

Methods: Between Jan 2014 and Dec 2018, eight uremia patients underwent PTX after a ruptured QT was repaired by figure-of-eight trans-osseous sutures with an overlapping tightening suture technique. Biochemical indices were measured before and one year after PTX to evaluate the control of SHPT. The changes in bone mineral density (BMD) were determined by comparing x-ray images at pre-PTX and during follow-up. The assessment of the functional recovery of the repaired QT was conducted at the last follow-up using multiple functional parameters.

Results: Eight patients (fourteen tendons) were retrospectively evaluated at an average follow-up of 3.46 ± 1.37 years after PTX. ALP and iPTH levels one year after PTX were significantly lower than at pre-PTX ($P = 0.017$, $P < 0.001$, respectively). Although there was no statistical differences compared to pre-PTX, serum phosphorus levels decreased and returned to normal one year after PTX ($P = 0.101$). BMD significantly increased at the last follow-up compared to pre-PTX. The average Lysholm score was 73.5 ± 11.07 and the average Tegner activity score was 2.63 ± 1.06. The active knee ROM after repair averaged an extension of $2.85 \pm 3.78°$ to a flexion angle of $113.21 \pm 10.12°$. The quadriceps muscle strength was grade IV and the mean Insall-Salvati index was 0.93 ± 0.10 in all of the knees with tendon ruptures. All patients were able to walk without external help.

Conclusions: Figure-of-eight trans-osseous sutures with an overlapping tightening suture technique is an economical and effective treatment for spontaneous QTR in patients with uremia and SHPT. PTX may promote tendon-bone healing in patients with uremia and SHPT.

KEYWORDS

Spontaneous quadriceps tendon rupture, Secondary hyperparathyroidism, uremia quadriceps tendon rupture, uremia, secondary hyperparathyroidism, parathyroidectomy, ligament reconstruction

Introduction

A spontaneous tendon rupture may be defined as a rupture that occurs during movement activities that should not usually damage the involved musculo-tendinous units (1). In the absence of a significant history of trauma, spontaneous quadriceps tendon rupture (QTR) is often misdiagnosed or delayed in patients with chronic renal failure (CRF) where the tendons have become weakened, predisposing them to ruptures (2). According to previous reports, spontaneous QTR is a rare complication in hemodialysis patients with uremia. Since the first description by Steiner and Plamer (3), only over 100 cases have been documented. Complete QTR must be treated surgically to regain full function recovery, however, the underlying cause should be quickly diagnosed to allow the prompt commencement of treatment.

In uremic patients, the mechanisms of QTR is controversial and include secondary hyperparathyroidism (SHPT), corticosteroid treatment, metabolic acidosis, post-dialysis amyloidosis, malnutrition, and the accumulation of uremic toxins (4, 5). Of these factors, SHPT is considered the leading cause of tendon rupture in uremia patients (6–8).

The management of patients with SHPT is predominantly medical. Despite advances in medical therapy for SHPT, parathyroidectomy (PTX) remains the definitive therapy for refractory SHPT (9). However, there are currently only a few reports on the comprehensive treatment of spontaneous QTR in patients with uremia and SHPT. Also, the influence of PTX for SHPT after tendon repair on tendon healing remains unclear.

In this study, we report a case series of 8 patients with uremia and SHPT who suffered from spontaneous QTR. All patients had undergone quadriceps tendon (QT) repair at our Institution followed by PTX for SHPT. We aimed to determine the functional recovery of the repaired QT after PTX.

Methods

Participants

This retrospective study was approved by our Institutional review board and patients were recruited under informed consent. Between Jan 2014 and Dec 2018, ten uremia patients with SHPT suffered from complete QRTs at our Institution. Of these patients, two patients were lost at follow-up and so eight patients were included in this study. None of the patients had a history of steroid and fluoroquinolone administration.

Table 1 summarizes the patient characteristics of those included in this study. The median age of the patients was 38 ± 9.93 years. Males were more often affected than females (7:1). The average BMI was 21.95 ± 2.11 kg/m^{2,} and the average period of hemodialysis was 5.38 ± 2.07 years. The mean time from the injury to QT repair was 14.13 ± 14.35 weeks. Six patients presented with simultaneous bilateral QTRs and one patient showed a unilateral QTR. One patient presented a QT and contralateral patellar tendon rupture but had a four-month interval between the lesions. The mechanism of injury in both bilateral and unilateral QTR was most commonly a slip or fall on a flat surface (four patients). This was followed by falls on stairs (two patients) and injuries resulting from falling from a bicycle (one patient). Also one patient was injured by sudden exertion whilst trying to stand up from squatting (Table 1).

Laboratory findings showed increased intact parathyroid hormone (iPTH), serum phosphorus, and alkaline phosphatase (ALP) in all patients (Table 2). x-ray imaging revealed severe and generalized osteoporosis and showed patella baja. Calcifications were observed in the ruptured ends of the tendon in all patients. MRI revealed the quadricep tendons presented an avulsion-like rupture at their osteotendinous junction.

Surgical techniques

All ruptured QTs were repaired using figure-of-eight trans-osseous sutures with an overlapping tightening suture technique *via* an anterior median longitudinal approach. A longitudinal incision of 8 cm is made from the proximal part of the QT tear site to the upper pole of the patella. Non-viable tendon extremities were debrided and any grossly degenerative tissue was excised. The end of the tendon was freshened and the surface of the upper pole of the patella roughened using a spherical burr. Five parallel longitudinal trans-osseous tunnels with diameters of 2.0 mm were made in the upper pole of the patella using a drill (Figure 1A). A non-absorbable number 5 Ethibond suture

TABLE 1 Summary of the patient characteristics.

Patient	Age (years)	Gender (M/F)	BMI (kg/m^2)	Rupture side	Mechanism of injury	Dialysis Time (years)	Rupture to surgery interval (weeks)
1	32	M	21.1	Bilateral	d	4	21
2	28	M	21.6	Bilateral	a	3	40
3	24	F	18.8	Right	c	4	1
4	50	M	22.1	Bilateral	a	7	5
5	48	M	23.8	Bilateral	b	9	2
6	33	M	25.9	Bilateral	b	5	26
7	46	M	21.1	Bilateral	a	7	17
8	43	M	21.2	Left	a	4	1

a = slip and fall on a flat surface; b = a fall down the stairs; c = a fall from a bicycle; d = sudden exertion whilst trying to stand up from squatting.

TABLE 2 Summary of the laboratory findings for the patients recruited to the study.

Patient	Ca	*P*	AG	ALP	iPTH	UREA	CREA	25-OH-VD
	(mmol/L)	(mmol/L)	(mmol/L)	(IU/L)	(pmol/L)	(mmol/L)	(umol/L)	(nmol/L)
	[2.1–2.7]	[0.67–1.04]	[12.0–20.0]	[51–160]	[1.60–6.90]	[3.30–8.22]	[53.0–140.0]	[47.7–144]
1	2.3	2.94	30.5	827	370.1	21.8	935	54.24
2	2.43	2.38	23.2	307	175.3	17.5	906	72.33
3	2.39	2.51	28.6	1088	146	30.2	868	63.1
4	2.2	2.06	21.7	358	183.5	27.7	811	57.86
5	2.06	2.76	27.8	362	243.7	23.6	1042	41.62
6	2.03	1.72	17.9	401	190.8	13.2	551	32.61
7	2.07	2.48	26.7	374	218.4	22.79	763	35.72
8	2.25	1.87	19.9	1794	333.2	13.9	644	56.95

Ca, calcium; P, phosphorus; AG, anion gap; ALP, alkaline phosphatase; iPTH, intact parathyroid hormone; CREA, creatinine; 25-OH-VD, 25- hydroxyvitamin D.

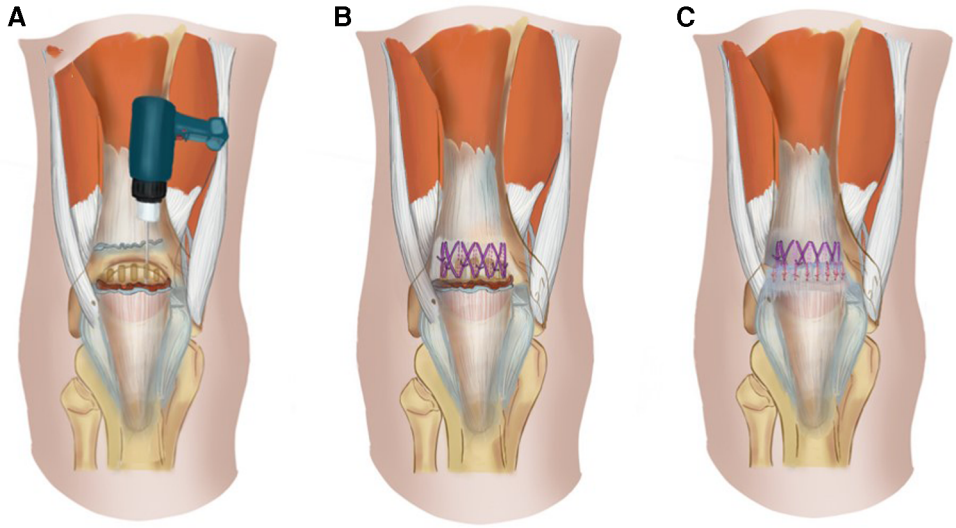

FIGURE 1
Diagram of the QT repair surgery. (**A**). Five parallel longitudinal trans-osseous tunnels with diameters of 2.0 mm were made in the upper pole of the patella using a drill. (**B**). A figure-of-eight suture was performed through each of the adjacent bone tunnels and simple trans-osseous sutures were achieved through the bone tunnels on both sides. (**C**). Tears in the retinaculum and deep fascia on the surface of the patella were repaired using an overlapping tightening suture with absorbable suture material.

material was used for trans-osseous sutures. A figure-of-eight suture was performed through each of the adjacent bone tunnels and simple trans-osseous sutures placed on the bone tunnels on both sides (Figure 1B). The suture was tied with the knee in full extension. Tears in the retinaculum and deep fascia on the surface of the patella were repaired using an overlapping tightening suture with absorbable No. 1-0 sutures (Ethicon) (Figure 1C). No additional reinforcing systems were used.

Post-operative rehabilitation

The knee was locked in full extension with a cylinder cast or a range-of-motion brace for a minimum of 6 weeks post-operatively. Patients were allowed partial weight-bearing with their cylinder cast or brace locked in extension immediately after surgery(10). Electrical stimulation was performed routinely. At seven weeks after the operation, patients were permitted to undertake full weight-bearing activities and progressive range of motion (ROM) exercise was maintained (10 days at 0°, 30°, 60°, and 90°) aiming for full flexion by six weeks.

PTX for SHPT

After consulting the multiple disciplinary teams (MDT) including the departments of nephrology, endocrinology and thyroid surgery, all patients underwent PTX (11) after repairing the ruptured tendon.

Clinical and functional assessment

The serum levels of calcium, phosphorus, ALP and iPTH before and one year after PTX were measured to evaluate the

control of SHPT. Changes in bone mineral density (BMD) was determined by comparing x-ray images at pre-PTX and the final follow-up.

We attempted to have all patients return to assess the functional outcomes of the knee. Patients who returned fulfilled a Lysholm score and Tegner activity score. The results of QT repair were evaluated with particular attention to the knee ROMs measured using a goniometer (0°corresponding to full extension). The quadriceps muscle strength was reported based on the Kendall scale (12). In cases where the patient agreed, isokinetic muscle strength (IMS) tests were performed (IsoMed-2000; D&R Ferstl, Hemau, Germany). Also, the ability to walk without crutches and the occurrence of new ruptures after the procedure were recorded.

Anteroposterior (AP) and lateral radiographs with the knee flexed at 30° were taken. The patella height was measured according to Insall and Salvati index (the ratio of the longest patellar diagonal length to tendon length with the knee in 30° of flexion. A value of ≤0.8 indicated that the patella baja was present.

Statistics analysis

Continuous variables were expressed as the mean ± standard deviation, and categorical variables were expressed as frequencies. Differences in the serum levels of calcium, phosphorus, ALP, and iPTH at pre-PTX and one year after PTX were compared using a paired-samples T-test. Probability values of P less than 0.05 were considered significant. All statistical analyses were performed using SPSS 18.0.

Results

Eight patients (fourteen tendons) were included in this study. The mean time from the injury to QT repair was 14.13 ± 14.35 weeks. The average time from QT repair to PTX was 10.33 ± 1.53 weeks. The average follow-up after PTX was 3.46 ± 1.37 years. Intra-operative observations confirmed all QTs presented an avulsion-like rupture at the osteotendinous junction.

Table 3 shows SHPT was well controlled in all patients one year after PTX. ALP and iPTH levels one year after PTX were significantly lower than that the levels at pre-PTX ($P < 0.05$). Serum phosphorus levels decreased and returned to normal one year after PTX. No statistical differences in serum phosphorus levels were detected one year after PTX compared to pre-PTX levels. Serum calcium levels were not significantly different at pre-PTX and one year after PTX. BMD was shown to significantly increase at the last follow-up compare to pre-PTX measurements.

TABLE 3 Changes in the biochemical indices of patients before and one year after PTX.

Variable	Pre PTX	Post PTX 1 year	*P*-value
Ca (2.1-2.7 mmol/L)	2.43 ± 0.25	2.31 ± 0.31	0.408
P (0.67–1.04 mmol/L)	2.15 ± 0.55	1.68 ± 0.52	0.101
ALP (51-160IU/L)	732.83 ± 634.21	117.43 ± 112.64	0.017*
iPTH (1.60–6.90 pmol/L)	232.47 ± 86.35	4.65 ± 4.21	<0.001*

Ca, calcium; P, phosphorus; ALP, alkaline phosphatase; iPTH, intact parathyroid hormone; 25-OH-VD, 25-hydroxyvitamin D; NA, not available; PTX, parathyroidectomy.
*$P < 0.05$.

The outcome scores at the last follow-up are summarized in Table 4. The patients were satisfied with the treatment results. The average Lysholm score was 73.5 ± 11.07 and the average Tegner activity score was 2.63 ± 1.06. Active knee ROM after repair averaged an extension of 2.85 ± 3.78° to flexion of 113.21 ± 10.12°. Quadriceps muscle strength in all knees was grade IV according to the Kendall scale. Only one patient performed IMS tests (Table 5) and the results are shown in the subsequent case report. All patients were able to walk without external help. Post-operative x-rays showed good positioning of the patella. The mean Insall-Salvati index was 0.93 ± 0.10 in all the knees with tendon ruptures (Table 4).

Complications

Complications associated with quadriceps tendon repair included delayed wound healing in one patient and skin breakdown from casting in another patient. Both of these complications were resolved. No deep infections and no new ruptures occurred during the follow-up periods.

Illustrative case (case 3)

A 24-year-old woman who had been receiving hemodialysis for four years for CRF suffered acute pain and swelling in her right knee after a trivial fall from a bicycle at low speed. The patient could not stand or walk after the fall and could not actively extend the right knee. A palpable depression was present in the suprapatellar region. The medical treatment of the patient consisted of amlodipine (10 mg/day), Bisoprolol (10 mg/day), Irbesartan (300 mg/day), Calcitriol (0.5 μg/day) and calcium supplements (500 mg/day). The patient was lean with a body mass index of 18.8 kg/m^2.

Preoperative examination showed that serum levels of phosphorus, anion clearance, ALP, iPTH, urea, and creatinine were higher than normal. Levels of 25-OH-VD were lower than normal and blood calcium was normal suggesting SHPT (Table 2, Patient 3). A lateral radiograph revealed an abnormal patella baja and calcification at the end of the ruptured tendon. The patient was also seen to have severe osteoporosis (Figures 2A,B). MRI revealed a complete disruption of the quadriceps tendon at the patellar insertion sites (Figure 2C).

The patient was diagnosed with a unilateral spontaneous QTR and SHPT with secondary osteoporosis. Surgical intervention was recommended. The MDT consultation recommended PTX after QT repair.

One week after the injury, the patient underwent surgery during which an avulsion-like rupture at the osteotendinous

TABLE 4 Functional evaluation at the last follow-up.

Patient	ROM (°)	Insall-Salvati ratio			The quadriceps muscle strength		Tegner activity score	Lysholm score	Complications
	R	L	R	L	R	L			
1	0–120	5–115	0.93	1.01	IV	IV	3	75	-
2	0–125	0–115	0.81	0.84	IV	IV	4	86	skin breakdown
3	0–130	0–140	O.91	NA	IV	V	4	94	-
4	10–105	0–115	0.86	0.82	IV	IV	2	65	-
5	0–95	5–100	1.07	0.96	IV	IV	1	63	delayed healing
6	0–120	10–115	0.92	0.87	IV	IV	3	70	-
7	5–110	0–120	1.02	0.89	IV	IV	2	65	-
8	0–130	5–100	NA	1.13	V	IV	2	70	-

ROM, Range of motion; NA, not available.

TABLE 5 Changes in biochemical indices and BMD before and after PTX and the IMS test results at one year after PTX.

Variable	Pre PTX	Post PTX 2 week	Post PTX 1 year	Variable	R	
Ca (2.1–2.7 mmol/L)	2.47	1.78	2.12	IMS testing result		
P (0.67–1.04 mmol/L)	1.99	0.64	0.72	FTW (J)	359	485
ALP (51–160IU/L)	2005	3157	365	ETW (J)	599	695
iPTH (1.60–6.90 pmol/L)	352.6	4.79	7.82	FPT (N·m)	33	48
26-OH-VD (47.7–144 nmol/L)	39.1	NA	174.6	EPT (N·m)	71	80
BMD value (g/cm^2)/ T score				The relative FPT(N·m/kg)	0.66	0.96
L1-4 lumbar spine	0.689/−3.5	NA	1.156/0.4	The relative EPT (N·m/kg)	1.42	1.6
Left femoral neck	0.691/−2.0	NA	1.064/1.1			
Left total hip	0.726/−1.9	NA	1.008/0.3			

Ca, calcium; P, phosphorus; ALP, alkaline phosphatase; iPTH, intact parathyroid hormone; 25-OH-VD, 25-hydroxyvitamin D; NA, not available; PTX, preparathyroidectomy. T score > −1.0 equals normal BMD, −2.5 < T value < −1.0 denotes osteopenia/low bone mass, and T value < −2.5 indicates osteoporosis. IMS, Isokinetic Muscle Strength; FTW, total work of flexion; ETW, total work of extension; FPT, Peak Torque of flexion; EPT, The peak torque of extension; relative FPT:FPT/BW; relative EPT:EPT/BW.

junction was found (Figure 2D). The tendon was repaired using a trans-osseous suture with a figure-of-eight stitch *via* an anterior knee approach as described above.

Postoperative radiography showed that the patella height had returned to normal (Figures 2E,F). After a six-week immobilization period, the patient was allowed full weight-bearing and continuous passive-active movements to exercise the extensor mechanism and improve flexion range. Three months after surgery, the patient regained 130° flexions without an extension lag. Walking was possible without external help and the monopodial standing position in flexion was stable.

Twelve weeks after the QT repair, the patient found that her height had decreased significantly from normal 162 to 151 cm, and she felt pain in her heel when walking. Examinations showed an abnormal increase of 352.60 pg/ml in iPTH. 99mTc-MIBI dual-phase planar imaging showed MIBI uptake in the inferior pole of the right thyroid lobe in the early phase (15 min) (Figure 3A), and the inferior and upper pole of the bilateral thyroid lobes in the delayed phase (2 h) (Figure 3B). 99mTc-MIBI SPECT/CT imaging showed small soft-tissue masses with MIBI uptake in the back of the inferior poles of both bilateral thyroid lobes (Figure 3C). DXA BMD examination showed that the patient had severe osteoporosis (Table 5). The patient was diagnosed with tertiary hyperparathyroidism (THPT) (13) and shrinking man syndrome (14). She underwent total PTX and autografting of the brachioradialis muscle in the right forearm of the upper left parathyroid gland. Postoperative histopathology confirmed that the mass was hyperplastic parathyroid tissue. After the operation, the patient presented with hungry bone syndrome (HBS) (15).

One year after PTX, the patient was back to normal life and the iPTH had returned to normal. ALP had decreased significantly (Table 5). The right quadriceps muscle strength based on the Kendall scale was IV/V. IMS tests (Figure 2K) showed the strength of extension and flexion on the operated side had decreased compared to the normal side (Table 5). The height of the patient increased by 4 cm without obvious bone pain and movement dysfunction. x-ray imaging of the knee (Figures 2G, H) and BMD examination revealed a significant increase in BMD compared to pre-PTX levels (Table 5).

Discussion

In this retrospective study, we investigated the injury characteristics, surgical procedures and outcomes of spontaneous QTR in patients with uremia and SHPT. Also, we investigated PTX for the treatment of SHPT and determined its effects on tendon-bone healing. All QTs presented an avulsion-like rupture at the osteotendinous junction and were repaired using figure-of-eight trans-osseous sutures with an overlapping tightening suture technique. All patients underwent PTX after QT repair and parathyroid function was well controlled. The knee joint function recovered satisfactorily at the last follow-up. After repair of the

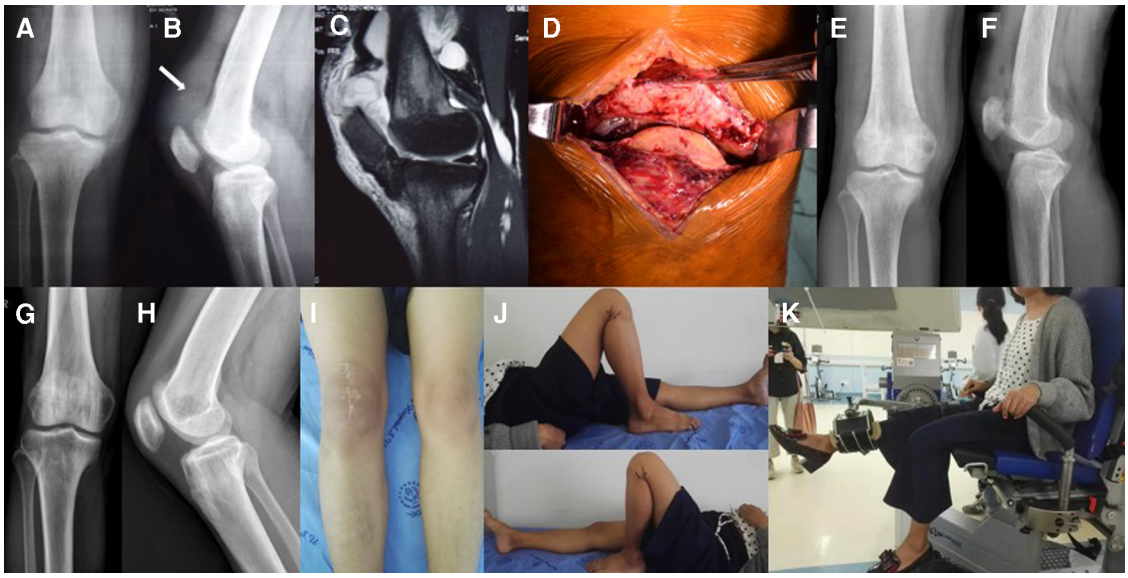

FIGURE 2
(A) x-ray of the right knee taken at the initial consultation showing severe osteoporosis. (B) Lateral radiograph showing the patella baja and calcification in the ruptured end of the QT (arrow). (C) Lateral T2-weighted MRI of the right knee showing a complete disruption of the QT at the patellar insertion sites. (D) The QT peel off from the upper pole of the patella. (E,F) Radiography after QT repair showing the regular positioning of the patella. (G,H) Radiography one year after PTX showed BMD had significantly increase compared to pre-PTX levels. (I,J) One year after PTX, the ROM of the right knee was 0–130° and in the left knee was 0–140°. (K) The patient undergoing IMS tests.



FIGURE 3
(A) 99mTc-MIBI dual-phase planar imaging. The early phase (15 min) planar images showed MIBI uptake in the inferior pole of the right thyroid lobe. (B) The delayed phase (2 h) planar images showed MIBI uptake in the inferior and upper pole of the bilateral thyroid lobes. (C) 99mTc-MIBI SPECT/CT imaging showing small soft-tissue masses with MIBI uptake in the back of the inferior Poles of both bilateral thyroid lobes.

QT in patients with uremia and SHPT, PTX may promote tendon-bone healing.

The mechanisms of QTR in patients with uremia remain controversial. They include malnutrition, β-2- amyloidosis, chronic acidosis, vitamin D deficiency, accumulation of uremia toxins, and SHPT (5, 16–19). In uremia patients undergoing maintenance hemodialysis, chronic acidosis can cause tendon degeneration (20). The accumulation of uremic toxins affects collagen structure and metabolism (21) as well as the soft tissue deposition of amyloid (22) that can weaken tendons. These pathological changes may lead to tendon rupture in the tendon or at the musculotendinous junction, rather than at the tendon-bone junction (23). Subperiosteal bone resorption and dystrophic calcifications due to SHPT may lead to tendon rupture with minor trauma.

The high level of parathyroid hormone (PTH) stimulates osteoclast activity which induces subtendinous bone reabsorption. This results in structural entheseal modifications that lead to the avulsion of the tendinous insertion. Finally, repeated minor avulsion fractures result in total tendon ruptures with minor trauma (23). SHPT also leads to dystrophic calcification which reduces the elasticity of the tendon and causes fragility of the bone tendon junction (24).

In this study, all patients presented with SHPT as determined by the laboratory and based on radiologic findings. The ruptured site was just at the tendon attachment to the bone, which was

smooth and completely free from tendon tissue. All quadricep tendons presented a calcification in the ruptured end of the tendon. They were consistent with the findings reported by Shiota et al. (23) who studied five long-term dialysis patients with seven spontaneous ruptures of major tendons and found that the ruptured site was at the osteotendinous junction. These data suggest that the most likely cause of tendon rupture in hemodialysis patients is SHPT.

When the QTR occurs in patients with uremia and SHPT, in addition to the active surgical repair of the ruptured tendon, the treatment of the main risk factors leading to tendon rupture should also be carried out as soon as possible. Consistent with most reports (3, 25) for the surgical treatment of QTR, we used non-absorbable no. 5 Ethibond suture to attach the ruptured tendons onto the patella which prevented late failure due to hardware fatigue and avoided the need to later remove hardware. The two most common techniques used for rupture closure to the patellar insertion are trans-osseous sutures (gold standard) or suture anchors, both of which have yielded excellent outcomes (26–28).

In our study, considering bone resorption, osteoporosis, and health economics, we opted for trans-osseous sutures. In most case reports, trans-osseous sutures are commonly used in combination with Bunnel or Krakow sutures and a suture-bone tunnel technique (23, 25). In the current cases, the proximal tendon was sutured using a figure-of-eight suture to improve tissue grip and avoid tight sutures that affect the blood supply of the tendon and can impact tendon-bone healing. Furthermore, the torn retinaculum and deep fascia on the surface of the patella was sutured to the QT using an overlapping tightening suture technique to strengthen the ruptured tendon. All of our patients achieved excellent results and no re-rupture occurred at the last follow-up. Figure-of-eight trans-osseous sutures with an overlapping tightening suture technique was an economical and highly effective treatment for this avulsion-like rupture.

Some authors hypothesize that a missed diagnosis may lead to delayed repair, which could be problematic due to the significant retraction of the quadriceps. Treatment would therefore require more complex surgical techniques to fix the consequent defect and restore the extensor system of the knee (29). In contrast, the current study found that patients with delayed surgery could have their quadriceps tendon directly stitched together, without the no need for lengthening plasty and tendon grafting to compensate for retraction. These findings were consistent with the previous results from Malta et al. (12). We found that there was no apparent defect in the length of the quadriceps tendon for this avulsion-like rupture. The uremia patients were complicated with muscle atrophy and decreased muscle tone and so it was easy to pull the ruptured QT back to the upper pole of the patella. Komaba et al. (9) also reported that many patients with CRF exhibit signs of wasting and muscle atrophy. Also, some studies have shown that SHPT may be involved in the pathogenesis of wasting and muscle weakness (30–33).

During treatment, uremia patients should be identified as soon as possible to ensure that patients complicated with SHPT are given timely treatment to prevent and control SHPT (34). The strict control of SHPT is crucial to avoid tendon rupture or re-rupture (23). In our study, one patient presented QTR four months after contralateral patellar tendon rupture due to delayed diagnosis and treatment of SHPT. If SHPT had been diagnosed and treated at the time of the initial tendon rupture in this patient, the second episode of the tendon rupture could likely have been prevented. In addition to tendon ruptures, SHPT can also lead to severe complications such as pathological fractures, shrinking man syndrome and vascular calcification (34, 35). The longer SHPT patients are exposed to high serum iPTH, the more likely they are to have serious complications (36). Moreover, patients with long-standing SHPT can experience parathyroid hyperplasia and develop THPT (36). In addition, studies have shown that electrical stimulation during the postoperative rehabilitation phase can delay muscle disuse atrophy after knee ligament injury to some extent (37).

Currently, there are no clear criteria to aid in the treatment decisions for SHPT in patients with uremia and spontaneous QTR. Various treatment options are available including drug treatment and surgery. Although pharmacologic treatments for SHPT are generally successful in reducing PTH levels, results vary by drug class and are frequently limited by several factors including medication adherence, adverse events associated with medications and high pill burden (38, 39). Despite advances in the treatment of SHPT, PTX remains the definitive therapy for refractory SHPT (9).

PTX is more effective than drug therapy in controlling the symptoms of patients, the associated biochemical indices (40) and significantly improves patient quality of life (41). Furthermore, circulating PTH levels drastically decreases after PTX followed by progressive reductions in serum calcium and phosphorus levels. This condition is known as a hungry bone syndrome and is characterized by massive deposition of calcium and phosphate in the bone resulting from a transient increase in bone formation and a sustained decrease in bone resorption (9). Following the rapid accumulation of calcium and phosphate by the skeleton, several observational studies have consistently demonstrated an increase in BMD after PTX (42). The increase in BMD at the tendon attachment site may promote tendon-bone healing leading to improved biomechanical properties. In our patients, it was observed that after PTX, osteoporosis was gradually reversed and BMD began to increase. We assume that after PTX, a massive flow of ions to demineralized bones replenished the calcium deficit and normalized bone turnover which may promote tendon-bone healing. We recommend that once the uremia patient was diagnosed with SHPT, the surgical treatment of PTX is suggested as early as possible after repairing the ruptured tendon.

The current study had several limitations. Firstly, it was a retrospective case series study and the number of cases was relatively small. We did not observe changes in bone metabolism markers after PTX. Secondly, only one patient underwent BMD and IMS examination after PTX, so the recovery of BMD and quadriceps muscle strength could not be quantitatively assessed. Thirdly, all uremia patients with QTR were combined with SHPT and received PTX after QT repair. Further studies are

needed to determine the optimal timing of PTX. Finally, we failed to collect the data of uremia patients with SHPT but did not perform PTX which made it impossible to obtain direct evidence of PTX in promoting tendon-bone healing after repair of QT in patients with uremia and SHPT.

Conclusions

Figure-of-eight trans-osseous sutures with an overlapping tightening suture technique is an economical and effective treatment for spontaneous QTR in patients with uremia and SHPT. PTX may promote tendon-bone healing in patients with uremia and SHPT.

Data availability statement

The datasets presented in this study can be found in online repositories. The names of the repository/repositories and accession number(s) can be found in the article/Supplementary Material.

Ethics statement

The studies involving human participants were reviewed and approved by http://www.chictr.org.cn/index.aspx (ChiCTR-OIC-16008306) chinese clinical trail registry. The patients/participants provided their written informed consent to participate in this study. Written informed consent was obtained from the individual(s) for the publication of any potentially identifiable images or data included in this article.

Author contributions

All authors contributed to the study conception and design. Material preparation, data collection and analysis were performed by SW and HW. The first draft of the manuscript was written by SW and YZ, and all authors commented on previous versions of the manuscript. SW made major contributions to the revision of the manuscript. All authors contributed to the article and approved the submitted version.

Conflict of interest

The authors declare that the research was conducted in the absence of any commercial or financial relationships that could be construed as a potential conflict of interest.

Publisher's note

All claims expressed in this article are solely those of the authors and do not necessarily represent those of their affiliated organizations, or those of the publisher, the editors and the reviewers. Any product that may be evaluated in this article, or claim that may be made by its manufacturer, is not guaranteed or endorsed by the publisher.

References

1. Józsa L, Kannus P. Histopathological findings in spontaneous tendon ruptures. *Scand J Med Sci Sports*. (1997) 7(2):113–8. doi: 10.1111/j.1600-0838.1997.tb00127.x

2. Neubauer T, Wagner M, Potschka T, Bilateral RM. Simultaneous rupture of the quadriceps tendon: a diagnostic pitfall? Report of three cases and meta-analysis of the literature. *Knee Surg Sports Traumatol Arthrosc*. (2007) 15(1):43–53. doi: 10.1007/s00167-006-0133-7

3. Steiner CA, Palmer LH. Simultaneous bilateral rupture of the quadriceps tendon. *Am J Surg*. (1949) 78(5):752–5. doi: 10.1016/0002-9610(49)90317-7

4. Shah MK. Outcomes in bilateral and simultaneous quadriceps tendon rupture. *Orthopedics*. (2003) 26(8):797–98. doi: 10.3928/0147-7447-20030801-18

5. Shah MK. Simultaneous bilateral rupture of quadriceps tendons: analysis of risk factors and associations. *South Med J*. (2002) 95(8):860–6. doi: 10.1097/00007611-200295080-00016

6. Serino J, Mohamadi A, Orman S, McCormick B, Hanna P, Weaver MJ. Comparison of adverse events and postoperative mobilization following knee extensor mechanism rupture repair: a systematic review and network meta-analysis. *Injury*. (2017) 48(12):2793–9. doi: 10.1016/j.injury.2017.10.013

7. Camarda L, D'Arienzo A, Morello S, Guarneri M, Balistreri F, D'Arienzo M. Bilateral ruptures of the extensor mechanism of the knee: a systematic review. *J Orthop*. (2017) 14(4):445–53. doi: 10.1016/j.jor.2017.07.008

8. Lim CH, Landon KJ, Chan GM. Bilateral Quadriceps Femoris Tendon Rupture in a Patient With Chronic Renal Insufficiency: A Case Report. *J Emerg Med*. (2016) 51(4):e85–e87. doi: 10.1016/j.jemermed.2016.05.063

9. Komaba H, Kakuta T, Fukagawa M. Management of secondary hyperparathyroidism: how and why? *Clin Exp Nephrol*. (2017) 21(Suppl 1):37–45. doi: 10.1007/s10157-016-1369-2

10. Vasiliadis AV, Maris A, Tsoupli A, Saridis A. Rehabilitation exercise program after surgical treatment of quadriceps tendon rupture: a case report. *Phys Ther Sport*. (2019) 39:82–9. doi: https://doi.org/10.1016/j.ptsp.2019.07.001

11. Wang M, Chen B, Zou X, Wei T, Gong R, Zhu J. A nomogram to predict hungry bone syndrome after parathyroidectomy in patients with secondary hyperparathyroidism. *J Surg Res*. (2020) 255:33–41. doi: 10.1016/j.jss.2020.05.036

12. Malta LM, Gameiro VS, Sampaio EA, Gouveia ME, Lugon JR. Quadriceps tendon rupture in maintenance haemodialysis patients: results of surgical treatment and analysis of risk factors. *Injury*. (2014) 45(12):1970–3. doi: 10.1016/j.injury.2014.09.008

13. Martin KJ, González EA, Gellens M, Hamm LL, Abboud H, Lindberg J. 19-Nor-1-alpha-25-dihydroxyvitamin D2 (paricalcitol) safely and effectively reduces the levels of intact parathyroid hormone in patients on hemodialysis. *J Am Soc Nephrol*. (1998) 9(8):1427–32. doi: 10.1681/ASN.V981427

14. Horensten ML, Boner G, Rosenfeld JB. The shrinking man. A manifestation of severe renal osteodystrophy. *JAMA*. (1980) 244(3):267–8. doi: 10.1001/jama.244.3.267

15. Yang G, Zha X, Mao H, Yu X, Wang N, Xing C. Hypocalcemia-based prediction of hungry bone syndrome after parathyroidectomy in hemodialysis patients with refractory secondary hyperparathyroidism. *J Int Med Res*. (2018) 46(12):4985–94. doi: 10.1177/0300060518788744

16. Jones N, Kjellstrand CM. Spontaneous tendon ruptures in patients on chronic dialysis. *Am J Kidney Dis*. (1996) 28(6):861–6. doi: 10.1016/s0272-6386(96)90386-8

17. Ribbans WJ, Angus PD. Simultaneous bilateral rupture of the quadriceps tendon. *Br J Clin Pract*. (1989) 43(3):122–5. PMID: 2692688.

18. Mahlfeld K, Kayser R, Franke J, Grasshoff H. Die beidseitige und simultane quadrizepssehnenruptur bei sekundärem hyperparathyreoidismus. Eine falldarstellung [bilateral and simultaneous quadriceps tendon rupture in secondary

hyperparathyroidism. A case report]. *Zentralbl Chir*. (1999) 124(11):1045–8. PMID: 10612212

19. Dougherty KA, Dilisio MF, Agrawal DK. Vitamin D and the immunomodulation of rotator cuff injury. *J Inflamm Res*. (2016) 9:123–31, Published. doi: 10.2147/JIR.S106206

20. Finlayson GR, Smith G Jr, Moore MJ. Effects of chronic acidosis on connective tissue. *JAMA*. (1964) 187:659–62. doi: 10.1001/jama.1964.03060220033010

21. Hofmann GO, Weber T, Lob G. Sehnenrupturen bei chronischer niereninsuffizienz–"urämische insertionstendopathie"? eine literaturgestützte dokumentation dreier fälle [tendon rupture in chronic kidney insufficiency–"uremic tendonopathy"? A literature-supported documentation of 3 cases]. *Chirurg*. (1990) 61(6):434–7. PMID: 2194758.

22. Masonis JL, Frick SL. Bilateral quadriceps tendon rupture as the initial presentation of amyloidosis. *Orthopedics*. (2001) 24(10):995–6. doi: 10.3928/0147-7447-20011001-23

23. Shiota E, Tsuchiya K, Yamaoka K, Kawano O. Spontaneous major tendon ruptures in patients receiving long-term hemodialysis. *Clin Orthop Relat Res*. (2002) 394:236–42. doi: 10.1097/00003086-200201000-00028

24. De Franco P, Varghese J, Brown WW, Bastani B. Secondary hyperparathyroidism, and not beta 2-microglobulin amyloid, as a cause of spontaneous tendon rupture in patients on chronic hemodialysis. *Am J Kidney Dis*. (1994) 24(6):951–5. doi: 10.1016/s0272-6386(12)81067-5

25. Richards DP, Barber FA. Repair of quadriceps tendon ruptures using suture anchors. *Arthroscopy*. (2002) 18(5):556–9. doi: 10.1053/jars.2002.30729

26. Plesser S, Keilani M, Vekszler G, Hasenoehrl T, Palma S, Reschl M. Clinical outcomes after treatment of quadriceps tendon ruptures show equal results independent of suture anchor or transosseus repair technique used - A pilot study. *PLoS One*. (2018) 13(3):e0194376. Published 2018 Mar 19. doi: 10.1371/journal.pone.0194376

27. Brossard P, Le Roux G, Vasse B. Orthopedics, traumatology society of western France (SOO). acute quadriceps tendon rupture repaired by suture anchors: outcomes at 7 years' follow-up in 25 cases. *Orthop Traumatol Surg Res*. (2017) 103 (4):597–601. doi: 10.1016/j.otsr.2017.02.013

28. Sherman SL, Copeland ME, Milles JL, Flood DA, Pfeiffer FM. Biomechanical evaluation of suture anchor versus transosseous tunnel quadriceps tendon repair techniques. *Arthroscopy*. (2016) 32(6):1117–24. doi: 10.1016/j.arthro.2015.11.038

29. Zribi W, Zribi M, Guidara AR, Ben Jemaa M, Abid A, Krid N. Spontaneous and simultaneous complete bilateral rupture of the quadriceps tendon in a patient receiving hemodialysis: a case report and literature review. *World J Orthop*. (2018) 9 (9):180–4. Published 2018 Sep 18. doi: 10.5312/wjo.v9.i9.180

30. Cuppari L, de Carvalho AB, Avesani CM, Kamimura MA, Dos Santos Lobão RR, Draibe SA. Increased resting energy expenditure in hemodialysis patients with severe hyperparathyroidism. *J Am Soc Nephrol*. (2004) 15(11):2933–9. doi: 10.1097/01.ASN.0000141961.49723.BC

31. Chou FF, Lee CH, Chen JB. General weakness as an indication for parathyroid surgery in patients with secondary hyperparathyroidism. *Arch Surg*. (1999) 134 (10):1108–11. doi: 10.1001/archsurg.134.10.1108

32. Kir S, Komaba H, Garcia AP, Economopoulos KP, Liu W, Lanske B. PTH/PTHrP receptor mediates cachexia in models of kidney failure and cancer. *Cell Metab*. (2016) 23(2):315–23. doi: 10.1016/j.cmet.2015.11.003

33. Kir S, White JP, Kleiner S, Kazak L, Cohen P, Baracos VE. Tumour-derived PTH-related protein triggers adipose tissue browning and cancer cachexia. *Nature*. (2014) 513(7516):100–4. doi: 10.1038/nature13528

34. Chen CM, Chu P, Huang GS, Wang SJ, Wu SS. Spontaneous rupture of the patellar and contralateral quadriceps tendons associated with secondary hyperparathyroidism in a patient receiving long-term dialysis. *J Formos Med Assoc*. (2006) 105(11):941–5. doi: 10.1016/S0929-6646(09)60180-7

35. Pitt SC, Sippel RS, Chen H. Secondary and tertiary hyperparathyroidism, state of the art surgical management. *Surg Clin North Am*. (2009) 89(5):1227–39. doi: 10.1016/j.suc.2009.06.011

36. Komaba H, Kakuta T, Fukagawa M. Diseases of the parathyroid gland in chronic kidney disease. *Clin Exp Nephrol*. (2011) 15(6):797–809. doi: 10.1007/s10157-011-0502-5

37. Kannus P, Järvinen M. Nonoperative treatment of acute knee ligament injuries. A review with special reference to indications and methods. *Sports Med (Auckland, N.Z.)*. (1990) 9(4):244–60. doi: https://doi.org/10.2165/00007256-199009040-00005

38. Fissell RB, Karaboyas A, Bieber BA, Sen A, Li Y, Lopes AA. Phosphate binder pill burden, patient-reported non-adherence, and mineral bone disorder markers: findings from the DOPPS. *Hemodial Int*. (2016) 20(1):38–49. doi: 10.1111/hdi.12315

39. Beto J, Bhatt N, Gerbeling T, Patel C, Drayer D. Overview of the 2017 KDIGO CKD-MBD update: practice implications for adult hemodialysis patients. *J Ren Nutr*. (2019) 29(1):2–15. doi: 10.1053/j.jrn.2018.05.006

40. Ghani A, Baxter P. Surgical parathyroidectomy versus cinacalcet therapy: in the management of secondary hyperparathyroidism. *Otolaryngol Head Neck Surg*. (2012) 146(2):220–5. doi: 10.1177/0194599811428272

41. Cheng SP, Lee JJ, Liu TP, Yang TL, Chen HH, Wu CJ. Parathyroidectomy improves symptomatology and quality of life in patients with secondary hyperparathyroidism. *Surgery*. (2014) 155(2):320–8. doi: 10.1016/j.surg.2013.08.013

42. Abdelhadi M, Nordenström J. Bone mineral recovery after parathyroidectomy in patients with primary and renal hyperparathyroidism. *J Clin Endocrinol Metab*. (1998) 83(11):3845–51. doi: 10.1210/jcem.83.11.5249

frontiers | Frontiers in Surgery

TYPE Original Research
PUBLISHED 02 March 2023
DOI 10.3389/fsurg.2023.1047558

Check for updates

OPEN ACCESS

EDITED BY
Paphon Sa-ngasoongsong,
Mahidol University, Thailand

REVIEWED BY
Wanbo Zhu,
Shanghai Jiao Tong University, China
Sien Lin,
The Chinese University of Hong Kong, China

*CORRESPONDENCE
Guozhi Jiang
jianggzh5@mail.sysu.edu.cn
jgz02865@hotmail.com
Deqing Wang
deqingw@vip.sina.com

†These authors have contributed equally to this work and share first authorship.

‡These authors share last authorship.

SPECIALTY SECTION
This article was submitted to Orthopedic Surgery, a section of the journal Frontiers in Surgery

RECEIVED 13 October 2022
ACCEPTED 13 February 2023
PUBLISHED 02 March 2023

CITATION
Chen Y, Cai X, Cao Z, Lin J, Huang W, Zhuang Y, Xiao L, Guan X, Wang Y, Xia X, Jiao F, Du X, Jiang G and Wang D (2023) Prediction of red blood cell transfusion after orthopedic surgery using an interpretable machine learning framework.
Front. Surg. 10:1047558.
doi: 10.3389/fsurg.2023.1047558

COPYRIGHT
© 2023 Chen, Cai, Cao, Lin, Huang, Zhuang, Xiao, Guan, Wang, Xia, Jiao, Du, Jiang and Wang. This is an open-access article distributed under the terms of the Creative Commons Attribution License (CC BY). The use, distribution or reproduction in other forums is permitted, provided the original author(s) and the copyright owner(s) are credited and that the original publication in this journal is cited, in accordance with accepted academic practice. No use, distribution or reproduction is permitted which does not comply with these terms.

Prediction of red blood cell transfusion after orthopedic surgery using an interpretable machine learning framework

Yifeng Chen[1†], Xiaoyu Cai[2†], Zicheng Cao[1], Jie Lin[2], Wenyu Huang[1], Yuan Zhuang[2], Lehan Xiao[1], Xiaozhen Guan[2], Ying Wang[3], Xingqiu Xia[4], Feng Jiao[5], Xiangjun Du[1], Guozhi Jiang[1,6*‡] and Deqing Wang[2*‡]

[1]School of Public Health (Shenzhen), Shenzhen Campus of Sun Yat-sen University, Shenzhen, China, [2]Department of Transfusion Medicine, The First Medical Center of Chinese PLA General Hospital, Beijing, China, [3]The Second School of Clinical Medicine, Guangdong Medical University, Dongguan, China, [4]HealSci Technology Co., Ltd, Beijing, China, [5]Guangzhou Centre for Applied Mathematics, Guangzhou University, Guangzhou, China, [6]School of Public Health (Shenzhen), Sun Yat-sen University, Guangzhou, China

Objective: Postoperative red blood cell (RBC) transfusion is widely used during the perioperative period but is often associated with a high risk of infection and complications. However, prediction models for RBC transfusion in patients with orthopedic surgery have not yet been developed. We aimed to identify predictors and constructed prediction models for RBC transfusion after orthopedic surgery using interpretable machine learning algorithms.

Methods: This retrospective cohort study reviewed a total of 59,605 patients undergoing orthopedic surgery from June 2013 to January 2019 across 7 tertiary hospitals in China. Patients were randomly split into training (80%) and test subsets (20%). The feature selection method of recursive feature elimination (RFE) was used to identify an optimal feature subset from thirty preoperative variables, and six machine learning algorithms were applied to develop prediction models. The Shapley Additive exPlanations (SHAP) value was employed to evaluate the contribution of each predictor towards the prediction of postoperative RBC transfusion. For simplicity of the clinical utility, a risk score system was further established using the top risk factors identified by machine learning models.

Results: Of the 59,605 patients with orthopedic surgery, 19,921 (33.40%) underwent postoperative RBC transfusion. The CatBoost model exhibited an AUC of 0.831 (95% CI: 0.824–0.836) on the test subset, which significantly outperformed five other prediction models. The risk of RBC transfusion was associated with old age (>60 years) and low RBC count (<4.0×10^{12}/L) with clear threshold effects. Extremes of BMI, low albumin, prolonged activated partial thromboplastin time, repair and plastic operations on joint structures were additional top predictors for RBC transfusion. The risk score system derived from six risk factors performed well with an AUC of 0.801 (95% CI: 0.794–0.807) on the test subset.

Conclusion: By applying an interpretable machine learning framework in a large-scale multicenter retrospective cohort, we identified novel modifiable risk factors and developed prediction models with good performance for postoperative RBC transfusion in patients undergoing orthopedic surgery. Our findings may allow more precise identification of high-risk patients for optimal control of risk factors and achieve personalized RBC transfusion for orthopedic patients.

KEYWORDS

orthopedic surgery, RBC transfusion, prediction model, machine learning, interpretability

1. Introduction

Orthopedic surgery is usually related to complicated operations and deep cuts, which results in orthopedic patients having a high risk of intraoperative bleeding and difficulty in stopping the bleeding (1, 2), whilst allogeneic blood transfusion (ABT) is often administered to patients undergoing orthopedic surgery (3, 4). Red blood cell (RBC) is most commonly used when surgical patients need ABT. Although allogeneic RBC transfusion can improve the health of patients (5), it might be accompanied by many side effects, such as surgical site infections and multiple complications, thus adversely leading to physical deterioration (6, 7). Previous studies have also shown that receiving an allogeneic blood transfusion is associated with a decrease in survival rate in the short or long term (8).

Identification of risk factors and accurate predictions of RBC transfusion before patients undergo surgical treatment is of great importance in clinical practice. Typically, physicians make decisions of blood transfusion primarily based on their clinical experience and the hemoglobin (Hb) level of the patient (9). However, this strategy often ignores other potential preoperative indicators and may lead to one-sided and inappropriate transfusion. Recent studies have identified other risk factors including BMI, age, blood pressure, or use of medications, and showed that Hb might not be the most critical risk factor in postoperative RBC transfusion (10, 11). Therefore, more modifiable factors should be considered before the RBC transfusion decision is made. Furthermore, most studies on the prediction of postoperative RBC transfusion have been based on traditional statistical models, which are often required to meet a series of strict assumptions, such as additive and linearity. However, these assumptions may not always hold in the real world. In addition, traditional regression analyses examine the associations of predictors one-by-one or a specific subset based on prior knowledge and neglect the interactive or modifying effects among predictors, which might lead to the omission of significant predictors and loss of prediction performance (12).

Machine learning methods, which use data-driven mathematical models to perform predictions, are widely employed to deal with complicated medical problems, and often exhibit better prediction performance compared with traditional statistical methods, especially in handling enormous numbers of predictors (13, 14). Traditional machine learning methods focus on the accuracy of prediction and are black-box in nature, thus it is difficult to be interpreted biologically. Therefore, an interpretable machine learning framework was developed to explain the output of prediction models (15). If the outcome of RBC transfusion is accurately predicted before surgery, interventions can be taken to prevent complications for patients at high risk of postoperative transfusion, whereas inappropriate transfusion of RBC would increase the risk of surgical errors and deficient blood supply, or lead to waste of blood resources (16). Different machine learning models have been applied to the prediction of blood transfusion, such as XGBoost and tree-based models (17, 18). However, to the best of our knowledge, there is no study to predict postoperative RBC transfusion in patients with orthopedic surgery using machine learning approaches.

In this study, we aimed to identify the risk factors of postoperative RBC transfusion in orthopedic patients and further establish prediction models of RBC transfusion after orthopedic surgery based on an interpretable machine learning framework.

2. Materials and methods

2.1. Study population

Data were retrieved from the National Preoperative Anemia Database, which was initiated by The First Medical Center of People's Liberation Army (PLA) General Hospital. From June 2013 to January 2019, electronic medical records of 65,044 patients with orthopedic surgery were collected at 7 tertiary hospitals located in China. Variables were gathered retrospectively, including demographics of patients, and clinical and hematology information. The recruitment methods, definitions, and biochemical investigations have been described in detail elsewhere (19). After excluding 5,432 patients with missing values of BMI and 7 patients who did not complete surgery, 59,605 individuals were included in our study (**Figure 1**). This study was approved by the Medical Ethics Committee of the Chinese PLA General Hospital (approval number, S2018–245–01), and followed RECORD guidelines for data collection.

2.2. Clinical and laboratory measurements

All variables were collected from the medical record systems of the seven hospitals. A total of thirty preoperative variables were incorporated into our study. The information of sex, age, and other demographics was recorded at hospital admission. BMI was calculated from the weight and height of patients. Hematology parameters including RBC count, Hb, and albumin (ALB) level were also measured before orthopedic surgery. For preoperative laboratory indicators which were measured more than once, we used the values closest to the start time of surgery. To make laboratory indicators comparable among different hospitals, all the data were required to pass internal quality control and external quality control evaluation organized by the National Health Commission of the People's Republic of China (19). The surgery procedures were classified into ten categories by the criterion of ICD-9-CM-3, according to the top two codes.

The designated physician of each member hospital extracted the qualified data of inpatient surgical procedures from the Hospital Information System, and then uploaded the data to the platform annually after de-identification. Data quality is ensured through comprehensive training of the physicians, an audit of the participating hospital, regular conference calls, and an annual training meeting. Contribution to the National Preoperative Anemia Database is voluntary.

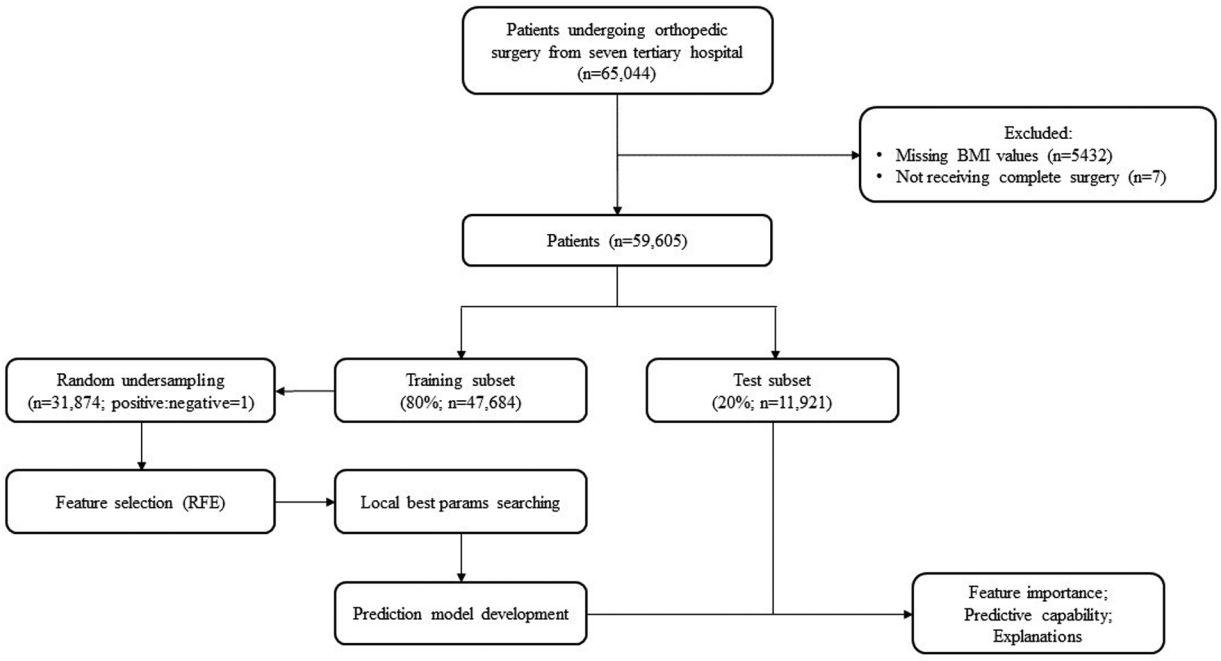

FIGURE 1
Flowchart of the study design.

2.3. Definition of clinical outcomes

According to the transfusion information of the status and time of RBC transfusion and the surgical information, the primary outcome in this study was defined as the reception of postoperative RBC transfusion. The RBC transfusion group was defined as patients receiving at least 1 unit RBC transfusion from postoperation to discharge.

2.4. Machine learning and statistical analysis

The data were randomly split into a training subset and a test subset, and the ratios of cases and controls were maintained across the two subsets. 80% data of patients were used to develop prediction models, whilst the other 20% of patients were used as validation. Recursive feature elimination (RFE), a feature selection method, was used to identify an optimal subset of predictors. RFE algorithm cyclically eliminates features with the lowest importance in the training set until they reached a specified termination criterion, such as the maximized accuracy or a preset AUC threshold (20). The subset which had the largest AUC would be assigned to the built prediction model. The resampling method of random undersampling was employed to balance the disproportion of outcome distribution. Six commonly used machine learning algorithms, including Logistic Regression (LR), K-Nearest Neighbors (KNN), Support Vector Machine (SVM), Random Forest (RF), eXtreme Gradient Boosting (XGBoost), and Gradient Boosting with Categorical Features Support (CatBoost) were employed to develop prediction models. The prediction performance was quantified by calculating the accuracy, precision, recall, f1-score, AUC, and Matthews correlation coefficient (MCC) of models.

An interpretable machine learning framework was used to explain the outputs of the prediction models. The SHapley Additive exPlanations (SHAP) method was used to provide consistent and locally accurate attribution values for each predictor in the prediction model (21). A higher SHAP value represents a larger contribution of a predictor toward the prediction. SHAP approach provided a partial dependence plot to graphically present the linear or nonlinear relationship between each predictor and the outcome.

Although the interpretable approach was applied to explain the output of the machine learning model, a relatively large number of predictors and the complexity of the model limited its application. For simplicity of the clinical utility, therefore, a risk score system was further established. To quantify the risk effect of predictors, a multivariable logistic regression model was created. Those variables, which were selected by the RFE algorithm but had a relatively minor contribution to the prediction model (accounting for <5% of total feature importance), were excluded to simplify the risk score system. Moreover, continuous variables were discretized before model establishment. The discretization thresholds were determined by clinical reference ranges or the results of partial dependence plots. Each variable was assigned a score according to the effect size derived from the logistic model, and the sum of scores reflected the magnitude of risk of postoperative RBC transfusion. The prediction performance of the risk score model was also evaluated on both training and test sets.

All data were expressed as percentages, means, and SDs, or medians and interquartile ranges (IQRs) as appropriate. Pearson chi-squared test or Fisher's exact test for categorical variables,

TABLE 1 Main preoperative characteristics of the study population of two groups (receiving postoperative RBC transfusion or not).

Variates	No RBC Transfusion Group	RBC Transfusion Group	*P*-value
Age (yrs), mean ± SD	47.28 ± 17.36	56.91 ± 17.76	<0.001
BMI (kg/m^2), mean ± SD	23.87 ± 3.50	24.60 ± 4.13	<0.001
Albumin (g/L), mean ± SD	42.05 ± 3.93	39.82 ± 4.30	<0.001
Alanine Aminotransferase (U/L), median (IQR)	17.60 (12.20–27.37)	15.80 (11.30–24.20)	<0.001
Activated Partial Thromboplastin Time(sec), mean ± SD	33.84 ± 5.77	36.01 ± 6.07	<0.001
Aspartate Aminotransferase (U/L), median (IQR)	17.10 (14.10–21.80)	16.70 (13.80–21.30)	<0.001
Creatinine(μmol/L), median (IQR)	67.40 (57.00–79.40)	63.40 (54.20–74.70)	<0.001
Hemoglobin(g/L), mean ± SD	136.96 ± 18.67	126.71 ± 18.70	<0.001
Hematocrit (%), mean ± SD	40.45 ± 5.07	37.78 ± 5.18	<0.001
Mean Corpuscular Hemoglobin (pg), mean ± SD	30.25 ± 2.07	29.97 ± 2.28	<0.001
Mean Corpuscular Hemoglobin Concentration (g/L), mean ± SD	338.18 ± 12.29	335.19 ± 12.36	<0.001
Mean Corpusular Volume (fl), mean ± SD	89.45 ± 5.24	89.37 ± 5.67	0.373
Platelet (10^9/L), median (IQR)	224.00 (187.00–267.00)	227.00 (186.00–274.25)	<0.001
Prothrombin Time(sec), mean ± SD	12.70 ± 1.72	13.13 ± 1.31	<0.001
Red Blood Cell Count (10^{12}/L), mean ± SD	4.59 ± 0.53	4.25 ± 0.60	<0.001
Total Bilirubin (μmol/L), median (IQR)	10.70 (8.00–14.30)	10.30 (7.80–13.70)	<0.001
White Blood Cell Count (10^9/L), median (IQR)	6.63 (5.47–8.22)	6.26 (5.18–7.77)	<0.001
Sex, *N* (%)			<0.001
Male	22,560 (37.85%)	8,108 (13.60%)	
Female	17,124 (28.73%)	11,813 (19.82%)	
Iron Supplements Use, *N* (%)			<0.001
No	38,581 (64.73%)	17,787 (29.84%)	
Yes	1,103 (1.85%)	2,134 (3.58%)	
Erythropoietin Use, *N* (%)			<0.001
No	31,641 (53.08%)	14,724 (24.70%)	
Yes	1,609 (2.70%)	3,472 (5.83%)	
Folic Acid Use, *N* (%)			<0.001
No	33,229 (55.75%)	18,160 (30.47%)	
Yes	21 (0.04%)	36 (0.06%)	
Vitamin B12 Use, *N* (%)			<0.001
No	33,240 (55.77%)	18,193 (30.52%)	
Yes	10 (0.02%)	3 (0.01%)	
In-hospital Times, *N* (%)			<0.001
1	31,410 (52.70%)	15,144 (25.41%)	
>1	4,845 (8.13%)	3,901 (6.54%)	
Operation Type, *N* (%)			<0.001
Incision, excision, and division of other bones	2,684 (4.50%)	1,483 (2.49%)	
Other operations on bones, except facial bones	2,616 (4.39%)	304 (0.51%)	
Reduction of fracture and dislocation	9,092 (15.25%)	2,756 (4.62%)	
Incision and excision of joint structures	7,590 (12.73%)	1,921 (3.22%)	
Repair and plastic operations on joint structures	9,101 (15.27%)	10,663 (17.89%)	
Operations on muscle, tendon, and fascia of hand	423 (0.71%)	1 (0.00%)	
Operations on muscle, tendon, fascia, and bursa, except hand	2,231 (3.74%)	308 (0.52%)	
Other procedures on musculoskeletal system	260 (0.44%)	218 (0.37%)	
Operations and procedures on other systems	5,687 (9.54%)	2,267 (3.80%)	

SD = standard deviation; IQR = Interquartile range.

and Student t-test or Mann-Whitney *U* test for continuous variables were used as appropriate. All statistical tests were 2-sided, and a *P*-value < 0.05 was considered to be significant. All the analysis was completed using Python 3.8.

3. Results

3.1. Baseline characteristics of the study cohort

The study cohort consisted of 59,605 patients (mean age 50.50 ± 18.08 years, 51.45% males, mean BMI 24.11 ± 3.74 kg/m^2), 47,684 (80%) allocated to the training subset, and 11,921 (20%) to the test subset (Figure 1). Of the 59,605 patients, 19,921 (33.40%) underwent RBC transfusion after orthopedic surgery. The most common operation was arthrosis repair and plastics (33.16%). Compared with patients without RBC transfusion, those with transfusion were more likely to be older, had a lower RBC count, Hb level, ALB level, and longer activated partial thromboplastin time (APTT) (Table 1).

3.2. Interpretable machine learning model

Seventeen variables were identified as important predictors by the RFE algorithm based on the criterion of AUC (Supplementary Figure S1), including age, sex, BMI, type of operation, ALB, alanine aminotransferase (ALT), APTT, aspartate aminotransferase (AST), creatinine (CR), Hb, hematocrit (HCT), mean corpuscular hemoglobin concentration (MCHC), platelet (PLT), prothrombin time (PT), RBC count, white blood cell (WBC) count, and use of erythropoietin. A series of prediction models were established using different machine learning algorithms. As shown in Figure 2, the model derived from the CatBoost algorithm had the best prediction performance compared with the other five models, with an AUC of 0.864 (95% CI: 0.861–0.867) and 0.831 (95% CI: 0.824–0.836) on the training

and test subsets, respectively (Table 2). The accuracy and precision of the CatBoost model on the test subset were 0.766 and 0.656, respectively, which were higher than other prediction models.

With respect to the feature importance of the CatBoost model, there were seven predictors, including the type of operation, age, RBC count, preoperative erythropoietin, ALB level, APTT, and BMI, accounted for >5% of total feature importance (Figure 3). The impact of different indicators on the risk of postoperative RBC transfusion was evaluated by the SHAP approach. As shown in Figure 4A, the risk of postoperative RBC transfusion varied in different orthopedic operations. Patients who underwent repair and plastic operations on joint structures had the highest risk of postoperative RBC transfusion. Among the operations in the orthopedic department, the operations on muscle, tendon, and fascia of hand were associated with the lowest risk of postoperative RBC transfusion. There were non-linear relationships between the risk of postoperative RBC transfusion and age, RBC count, or BMI (Figure 4B,C, G), whereas the relationships for levels of ALB and Hb were approximately linear with a negative slope (Figure 4E, Supplementary Figure S2). Patients with age under 60 years old, RBC count over 4.0×10^{12}/L, higher ALB level, and BMI between about 18 and 25 had a lower risk of postoperative RBC transfusion. Also, other variables in the model may partly contribute to the outcomes.

3.3. Risk score system

For simplicity of clinical application, we further constructed a risk score system using the coefficients of predictors in the logistic regression model. The top six risk factors, including the operation type, age, RBC count, ALB, APTT, and BMI, were incorporated into the risk score model (Table 3), The total score ranged from 0 to 56 theoretically, and patients with a score greater than 28 (mean value of the risk score) would be considered as high-risk individuals. Even with fewer variables compared with the machine learning model, the risk score model still performed relatively well, whose AUCs on the training subset and test subset were 0.776 (95% CI: 0.772–0.781) and 0.778 (95% CI: 0.771–0.785), respectively (Table 4).

4. Discussion

In this multicenter retrospective cohort study, we developed prediction models for the postoperative RBC transfusion of orthopedic patients in the Chinese population based on the interpretable machine learning framework. Our main findings were 3-fold. First, we established a prediction model derived from the CatBoost algorithm, which presented better prediction performance when compared with the other five machine learning models. Second, besides the low level of Hb, we identified old age of orthopedic surgery, low ALB and RBC count, extremes of BMI, prolonged APTT, repair and plastic operations on joint structures, and use of erythropoietin as significant predictors for postoperative RBC transfusion in orthopedic patients. Third, we developed a simple risk score system with fewer predictors but similar prediction performance as machine learning models, which was intuitive and could be used more easily in clinical settings. These findings would enable the identification of high-risk patients for optimal control of risk factors and achieve personalized RBC transfusion for orthopedic patients.

In this analysis, we developed a prediction model for RBC transfusion in orthopedic patients using the machine learning algorithm of CatBoost, which showed a higher AUC of 0.831 when compared with the other five models (LR, KNN, SVM, RF, XGBoost). Compared with the previous prediction model which included perioperative variables, our prediction model only used preoperative indicator, so preventive measures could be taken when clinicians planned operations for patients (22). Moreover, most previous studies on postoperative blood transfusion in orthopedic patients only focusing on a specific type of surgery, rather than incorporating all types of surgery in a clinical department, which limits the application of the prediction model. In addition, some other studies only identify the risk factors of postoperative transfusion but without individual prediction (23, 24). In our prediction model, different types of orthopedic surgery were incorporated, which could be applied in the whole department to help clinicians identify high-risk patients, and further improve the management of postoperative RBC transfusion for patients. Hence, the potentially unnecessary repeat preoperative testing, such as the testing of hematological and biochemical indexes, could be avoided. With consideration of the large number of patients undergoing orthopedic surgery, the saving in medical tests and transfusions would be of benefit to the individual, family, and society to reduce the medical burdens.

The old age of orthopedic surgery, low ALB and RBC count, extremes of BMI, high APTT, operation of repair and plastic operations on joint structures, and use of erythropoietin were identified as important risk factors in our study. The relative feature importance suggested that there were several predictors that contributed more to the prediction of the postoperative RBC transfusion in orthopedic patients compared with that of Hb. Similar findings were reported in previous studies. Raman et al. (10) developed a decision tree-based machine learning model to predict the transfusion units after adult spinal deformity surgery and found that the number of levels fused was the most significant risk factor, whilst the preoperative Hb was not included in the model. In another study on total shoulder arthroplasty, Gowd et al. (25) identified preoperative hematocrit, BMI, and operative time as the most important risk factors of postoperative transfusion and other short-term complications. These results suggest that it may be not appropriate to simply speculate the requirement of postoperative transfusion only based on the levels of Hb, but more risk factors need to be considered, such as age, BMI, and RBC count (26, 27). Even if the preoperative Hb level of the patient is high, other risk factors might significantly contribute to the postoperative transfusion (18). Interestingly, we identified low ALB and high APTT as important risk factors of postoperative RBC transfusion. ALB plasma concentrations is an indicator of nutritional status and hepatic function (28), and low preoperative ALB level reflects the

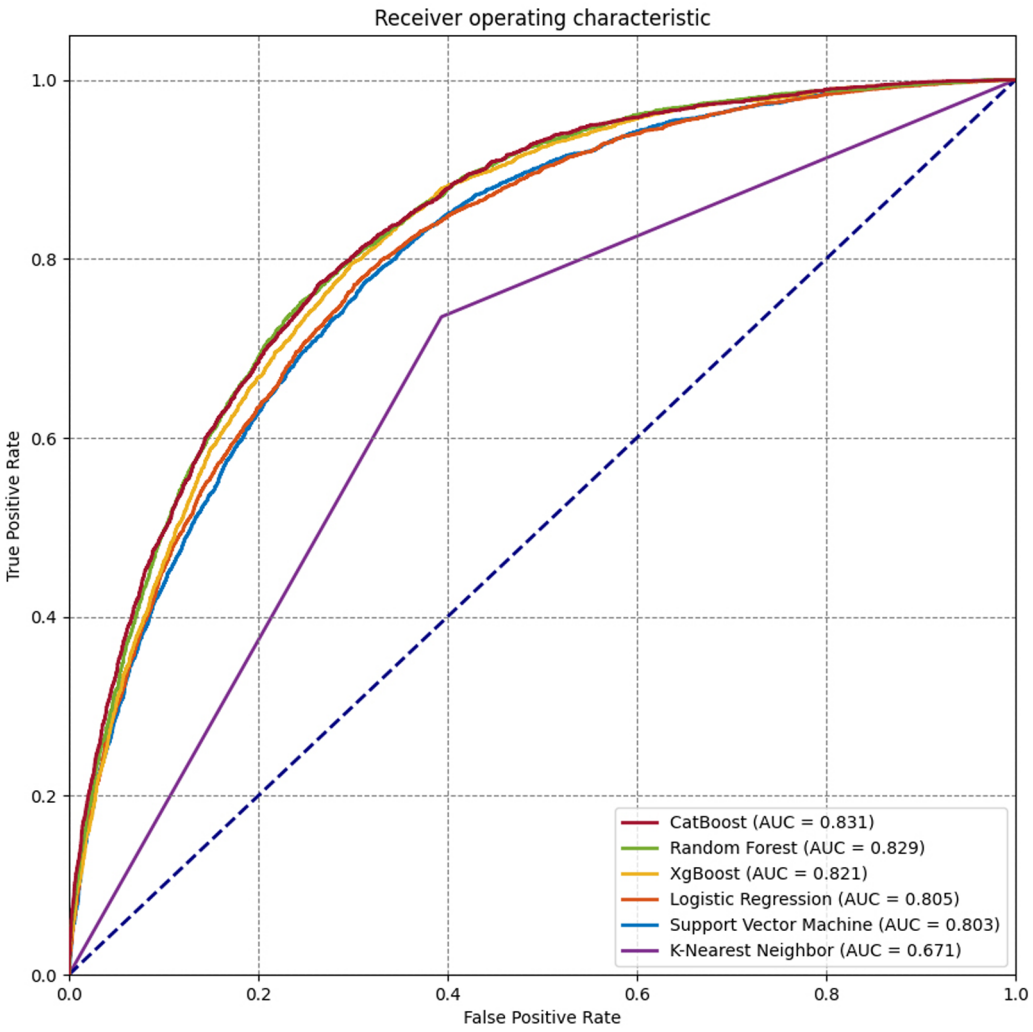

FIGURE 2
Receiver operating characteristic (ROC) curves for the machine learning and logistic regression prediction models.

TABLE 2 The prediction performance of different machine learning models in the training subset and test subset.

	Model	Accuracy	Precision	Recall	F1 score	AUC (95% CI)	MCC
Training Subset	CatBoost	0.763	0.824	0.670	0.739	0.864 (0.861–0.867)	0.536
	XGBoost	0.766	0.752	0.792	0.771	0.840 (0.837–0.844)	0.532
	RF	0.821	0.807	0.844	0.825	0.821 (0.817–0.824)	0.643
	LR	0.731	0.733	0.728	0.730	0.731 (0.727–0.735)	0.462
	SVM	0.728	0.731	0.721	0.726	0.728 (0.724–0.732)	0.456
	KNN	0.669	0.650	0.735	0.690	0.669 (0.665–0.674)	0.342
Test Subset	CatBoost	0.766	0.656	0.633	0.644	0.831 (0.824–0.836)	0.471
	XGBoost	0.737	0.580	0.774	0.663	0.821 (0.814–0.827)	0.467
	RF	0.741	0.584	0.782	0.669	0.830 (0.823–0.835)	0.477
	LR	0.721	0.560	0.773	0.649	0.805 (0.798–0.812)	0.443
	SVM	0.721	0.563	0.742	0.640	0.803 (0.796–0.809)	0.430
	KNN	0.650	0.484	0.735	0.584	0.671 (0.663–0.678)	0.322

RF, random forest; LR, logistic regression; SVM, support vector machine; KNN, k-nearest neighbor; AUC, the area under the operating characteristic curve; CI, confidence interval; MCC, Matthews correlation coefficient.

malnutrition and anemia of patients before surgery (29), which might increase the risk of postoperative RBC transfusion. A prolonged preoperative APTT, which indicates the coagulation functions of patients (30), may be correlated to a high risk of intraoperative and postoperative bleeding, which leads to the requirement for RBC transfusion.

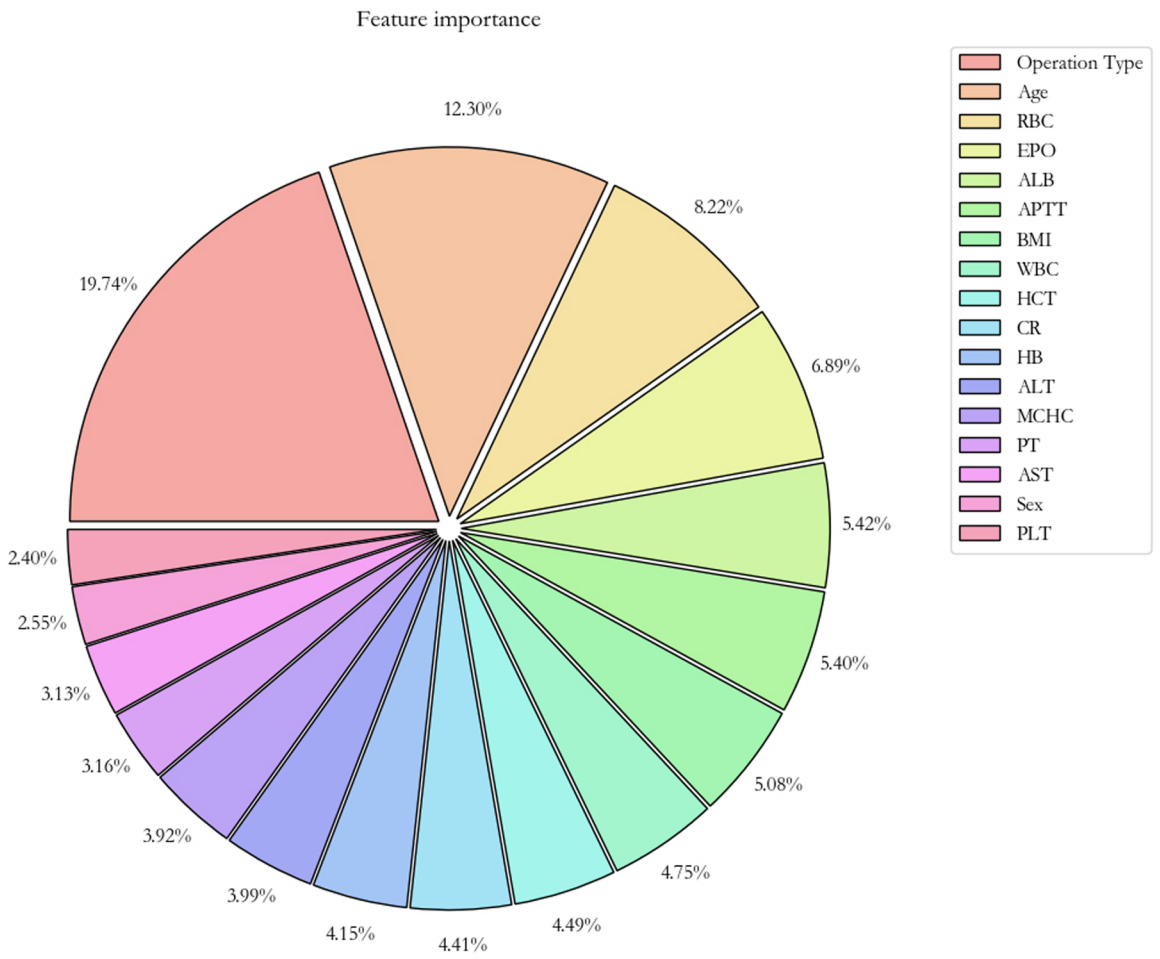

FIGURE 3
Importance of the features in the catBoost prediction model. The pie plot shows the relative importance of features for predicting the risk of postoperative RBC transfusion, sorted by importance from high to low. RBC, red blood cell count; EPO, erythropoietin use; ALB, albumin; APTT, activated partial thromboplastin time; WBC, white blood cell count; HCT, hematocrit; CR, creatinine; Hb, hemoglobin; ALT, alanine aminotransferase; MCHC, mean corpuscular hemoglobin concentration; PT, prothrombin time; AST, aspartate aminotransferase; PLT, platelet.

The type of operation and increased age were strongly associated with a higher risk of RBC transfusion after orthopedic surgery. Interestingly, a threshold effect was identified for the age of patients. Orthopedic patients aged over 60 years had a markedly increased risk of postoperative RBC transfusion compared with those under 60 years. Lenoir et al. (31) reported that age was the independent preoperative predictor of homologous RBC transfusion in patients undergoing elective spine surgery of France population. Patients aged over 50 years old had nearly 5-fold higher risk of transfusion compared with those with age under 50 years old. Moreover, Torres-Claramunt et al. (32) found that age over 60 years was a risk factor for postoperative transfusion in patients who underwent surgeries for degenerative conditions of the lumbar spine in the Spain population. These findings suggested that clinicians and surgeons might need to pay extra attention to the requirement of postoperative transfusion for elderly patients with orthopedic surgery. The threshold effect of RBC count was also identified. Orthopedic patients with RBC count under 4.0×10^{12}/L had a growing risk of postoperative transfusion. And as expected, the relationship between the preoperative Hb level and the postoperative RBC transfusion was approximately linear. Patients with higher preoperative Hb level had a lower risk of postoperative RBC transfusion.

The correlation between BMI and the postoperative RBC transfusion showed a bimodal effect. Both underweight and overweight orthopedic patients had a higher risk of postoperative RBC transfusion. This finding is consistent with previous work. For example, Durand et al. (17) used a machine learning model to predict blood transfusion after adult spinal deformity surgery in the US population, and reported a bimodal risk profile. Patients with both low and high BMI were associated with an increased risk of transfusion. One potential explanation is that greater surgical exposure and complexity operation among patients with large BMI intensify the risk of intraoperative bleeding, thus predisposing the postoperative RBC transfusion, whereas patients with low BMI may have low blood volume, indicating that the blood loss threshold at RBC transfusion requirement would be lower than patients of greater size. However, Frisch et al. (33) reported that patients with increased BMI have lower rates of blood transfusion following total hip

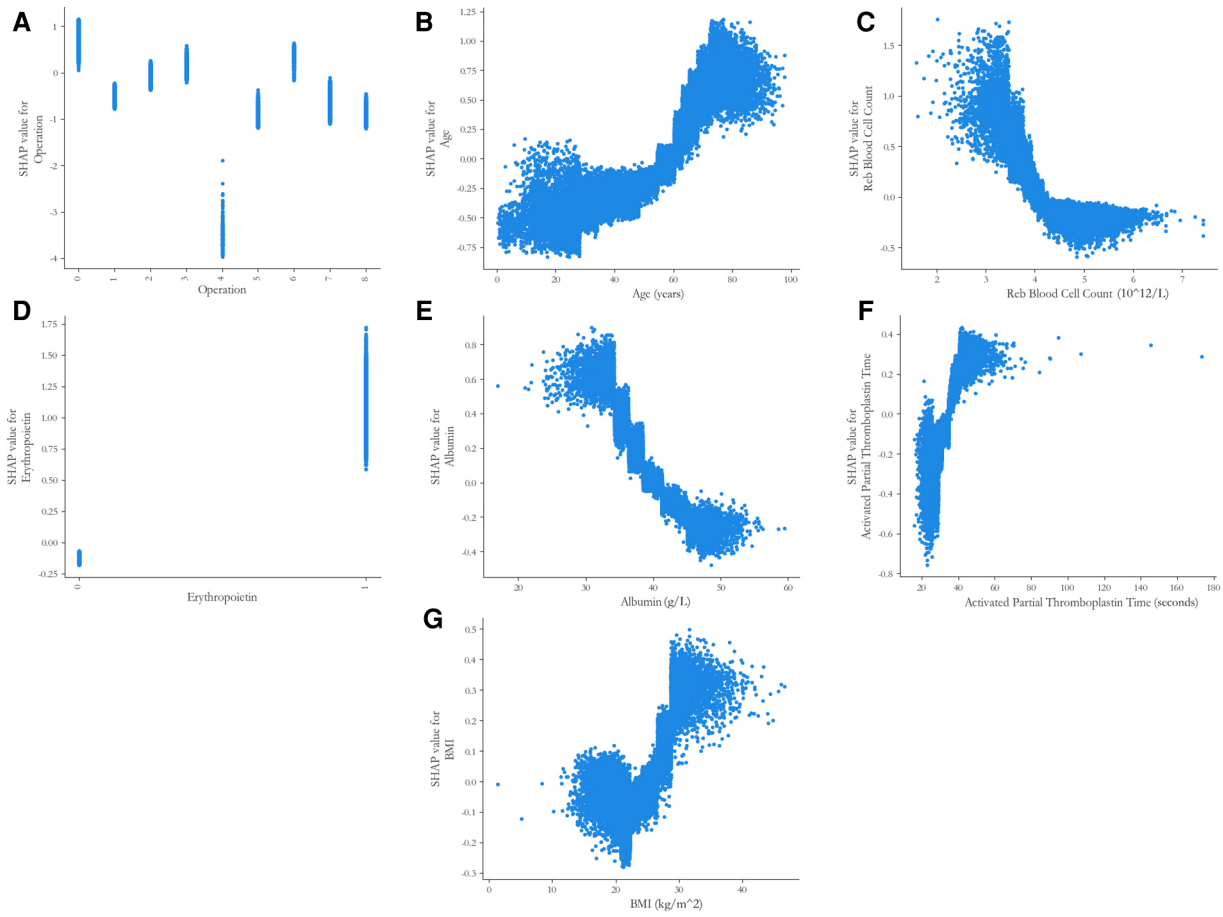

FIGURE 4
SHAP partial dependence plots of the five predictors in the catBoost model. Each plot shows how a single risk factor affects the outcome of the prediction model. SHAP values for specific factors exceed zero, representing an increased risk of postoperative RBC transfusion in orthopedic surgery patients. SHAP, SHapley Additive exPlanations. (**A**) Code on the x-axis: 0 = Repair and plastic operations on joint structures; 1 = Incision and excision of joint structures; 2 = Operations and procedures on other systems; 3 = Incision, excision, and division of other bones; 4 = Operations on muscle, tendon, and fascia of hand; 5 = Operations on muscle, tendon, fascia, and Bursa, except hand; 6 = Other procedures on musculoskeletal system; 7 = Reduction of fracture and dislocation 8 = Other operations on bones, except facial bones; (**D**) Code on the x-axis: 0 = no use, 1 = use.

(THA) and knee (TKA) arthroplasty. Erben et al. (34) also concluded that patients with a higher BMI were potentially at lower risk for blood transfusion in the THA and TKA. These discrepancies could be attributed to the type of surgery or the different surgical plans among institutions. Further investigation with prospectively designed is warranted to clarify this issue.

The use of erythropoietin is usually proposed preoperatively to reduce blood transfusion in orthopedic surgery (35). However, in our study, the use of erythropoietin is correlated with the increased risk of postoperative RBC transfusion, indicating that medication intervention did not seem to achieve the desired effect or reflect a worse health state of patients. This result may be due to the fact that only a small proportion of patients with preoperative anemia (14.6%) were treated with medication, and erythropoietin was mostly prescribed to patients with severe anemia. Moreover, the treatment of erythropoietin was not early enough to take effect before surgery. Generally, erythropoietin should be initiated at least 1 month before surgery in patients at high risk of transfusion (36). However, the mean duration from

TABLE 3 The risk score model based on the β-coefficient of logistic regression analysis.

Variables	Beta	Score
Albumin ≤ 40 g/L	0.516	5
Activated Partial Thromboplastin Time > 36 seconds	0.442	4
Red Blood Cell Count ≤ $4.0*10^{12}$/L	1.035	10
Age > 60 years	0.747	7
BMI (kg/m^2)		
BMI > 23.0	0.247	2
18.5 < BMI ≤ 23.0	–	0
BMI ≤ 18.5	0.433	4
Operation		
Repair and plastic operations on joint structures	2.625	26
Incision and excision of joint structures	1.142	11
Operations and procedures on other systems	1.653	17
Operations on muscle, tendon, fascia, and bursa, except hand	2.050	21
Other procedures on musculoskeletal system	0.676	7
Operations on facial bones and joints	2.271	23
Reduction of fracture and dislocation	1.187	12
Other operations on bones, except facial bones	0.792	8
Operations on muscle, tendon, and fascia of hand	–	0

TABLE 4 The prediction performance of the risk score model in the training subset and test subset.

	Accuracy	Precision	Recall	F1 score	AUC (95% CI)	MCC
Training Subset	0.709	0.725	0.674	0.698	0.776 (0.772–0.781)	0.419
Test Subset	0.719	0.567	0.679	0.618	0.778 (0.771–0.785)	0.403

AUC, the area under the operating characteristic curve; CI, confidence interval; MCC, Matthews correlation coefficient.

admission to surgery was only 4.7 days in our cohort, much shorter than 1 month. Another retrospective cross-sectional study in Chinese adults reported that there was no significant association between preoperative erythropoietin and postoperative RBC transfusion (19). More studies are needed to clarify the relationship between erythropoietin and postoperative RBC transfusion.

Although the model derived from the machine learning algorithm presented good prediction performance, the inclusion of relatively too many numbers of predictors increased the complexity the of model and may limit their application. For the expedient application of the prediction model in clinical settings, we further developed a simpler risk score model with fewer variables (six variables) but similar prediction performance. All the continuous variables were categorized in the risk score system to conveniently perform prediction of postoperative RBC transfusion in orthopedic patients. The risk score model could be quickly deployed in most routine clinical situations or among outpatients without the need for a web-based platform or programming into the electronic health record system (37). In contrast, the machine learning prediction model may be more suitable for the requirement of accurate prediction.

This study has several strengths. First, our study included plentiful data consisting of multi-center datasets, which improved the generalization and reliability of the models. Second, different types of orthopedic operations were all included in the analysis. Thus, the machine learning prediction model had a wider range of applications, compared with those models only focusing on a specific type of surgery. Third, we used a novel interpretable machine learning approach to explain the output of the prediction model, which revealed the relationships between the identified risk factors and the outcome. Additionally, variables used in our risk score systems were only demographic characteristics, preoperative laboratory outcomes, and operation type, all of which could be easily obtained before surgery.

Several limitations of this study should be discussed. First, the exclusion of patients with missing critical data might induce some bias. However, the sample size of our study was large and the exclusion only accounted for a small fraction (<10%). Second, the surgeons at each hospital had different surgical plans, which might affect the results. However, the regular training of participating physicians and hospitals was implemented, which might reduce these differences. Third, although the test subset was divided for internal validation, the performance of our prediction model still needed further validation on the independent external dataset. Ultimately, our prediction model was focused on the orthopedic surgery patients of the Chinese population, so it might not applicable to other populations or patients of other surgeries.

5. Conclusion

On the basis of the interpretable machine learning framework, this large-scale multicenter retrospective cohort study identified novel modifiable risk factors and developed prediction models with good performance for RBC transfusion in patients undergoing orthopedic surgery. These findings may allow more precise identification of high-risk patients for optimal control of risk factors and achieve personalized RBC transfusion for orthopedic patients.

Data availability statement

The raw data supporting the conclusions of this article will be made available by the authors, without undue reservation.

Ethics statement

The studies involving human participants were reviewed and approved by The Medical Ethics Committee of the Chinese PLA General Hospital (approval number, S2018-245-01). Written informed consent to participate in this study was provided by the participants' legal guardian/next of kin.

Author contributions

YFC carried out the literature review and conceptualized the study. All authors contributed to methodology development. YFC, XYC, JL, YZ, LHX, and DQW contributed to the data curation. YFC, XYC, and GZJ interpreted the results and wrote the original draft of the manuscript. XYC, ZCC, JL, WYH, YZ, LHX, XZG, YW, XQX, FJ, XJD, DQW, and GZJ helped review and edit the final draft of the manuscript. YFC and XYC contributed equally to the study. GZJ and DQW are responsible for the decision to submit the manuscript. All authors contributed to the article and approved the submitted version.

Funding

This work was supported by the Bethune Charitable Foundation of China (BQE-2018-SX-01), Fundamental Research Funds for the Central Universities, Sun Yat-sen University (22QNTD4310), the Shenzhen Science and Technology Program under Grant No. JCYJ20220530145210024, and the

Guangdong Basic and Applied Basic Research Foundation under Grant No. 2023A1515012624.

Acknowledgments

We thank all medical and nursing staff of the First Medical Center of Chinese PLA General Hospital and all other six hospitals, for their commitment and professionalism.

Conflict of interest

XQX was employed by HealSci Technology Co., Ltd. The remaining authors declare that the research was conducted in the absence of any commercial or financial relationships that could be construed as a potential conflict of interest.

Publisher's note

All claims expressed in this article are solely those of the authors and do not necessarily represent those of their affiliated organizations, or those of the publisher, the editors and the reviewers. Any product that may be evaluated in this article, or claim that may be made by its manufacturer, is not guaranteed or endorsed by the publisher.

Supplementary material

The Supplementary Material for this article can be found online at: https://www.frontiersin.org/articles/10.3389/fsurg.2023.1047558/full#supplementary-material.

References

1. Sculco TP. Global blood management in orthopaedic surgery. *Clin Orthop Relat Res*. (1998) 357:43–9. doi: 10.1097/00003086-199812000-00007

2. Rankin D, Zuleta-Alarcon A, Soghomonyan S, Abdel-Rasoul M, Castellon-Larios K, Bergese SD. Massive blood loss in elective spinal and orthopedic surgery: retrospective review of intraoperative transfusion strategy. *J Clin Anesth*. (2017) 37:69–73. doi: 10.1016/j.jclinane.2016.10.017

3. Carson JL, Stanworth SJ, Dennis JA, Trivella M, Roubinian N, Fergusson DA, et al. Transfusion thresholds for guiding red blood cell transfusion. *Cochrane Database Syst Rev*. (2021) 12:CD002042. doi: 10.1002/14651858.CD002042.pub5

4. Mitchell MD, Betesh JS, Ahn J, Hume EL, Mehta S, Umscheid CA. Transfusion thresholds for Major orthopedic surgery: a systematic review and meta-analysis. *J Arthroplasty*. (2017) 32(12):3815–21. doi: 10.1016/j.arth.2017.06.054

5. Takei T, Amin NA, Schmid G, Dhingra-Kumar N, Rugg D. Progress in global blood safety for hiv. *J Acquir Immune Defic Syndr*. (2009) 52(Suppl 2):S127–S31. doi: 10.1097/QAI.0b013e3181baf0ac

6. Fisahn C, Schmidt C, Schroeder JE, Vialle E, Lieberman IH, Dettori JR, et al. Blood transfusion and postoperative infection in spine surgery: a systematic review. *Global Spine J*. (2018) 8(2):198–207. doi: 10.1177/2192568217747572

7. Gu W-J, Gu X-P, Wu X-D, Chen H, Kwong JSW, Zhou L-Y, et al. Restrictive versus liberal strategy for red blood-cell transfusion: a systematic review and meta-analysis in orthopaedic patients. *J Bone Joint Surg Am*. (2018) 100(8):686–95. doi: 10.2106/JBJS.17.00375

8. Carson JL, Sieber F, Cook DR, Hoover DR, Noveck H, Chaitman BR, et al. Liberal versus restrictive blood transfusion strategy: 3-year survival and cause of death results from the focus randomised controlled trial. *Lancet*. (2015) 385(9974):1183–9. doi: 10.1016/S0140-6736(14)62286-8

9. Napolitano LM, Kurek S, Luchette FA, Corwin HL, Barie PS, Tisherman SA, et al. Clinical practice guideline: red blood cell transfusion in adult trauma and critical care. *Crit Care Med*. (2009) 37(12):3124–57. doi: 10.1097/CCM.0b013e3181b39f1b

10. Raman T, Vasquez-Montes D, Varlotta C, Passias PG, Errico TJ. Decision tree-based modelling for identification of predictors of blood loss and transfusion requirement after adult spinal deformity surgery. *Int J Spine Surg*. (2020) 14(1):87–95. doi: 10.14444/7012

11. Jalali A, Lonsdale H, Zamora LV, Ahumada L, Nguyen ATH, Rehman M, et al. Machine learning applied to registry data: development of a patient-specific prediction model for blood transfusion requirements during craniofacial surgery using the pediatric craniofacial perioperative registry dataset. *Anesth Analg*. (2021) 132(1):160–71. doi: 10.1213/ANE.0000000000004988

12. Waljee AK, Higgins PDR. Machine learning in medicine: a primer for physicians. *Am J Gastroenterol*. (2010) 105(6):1224–6. doi: 10.1038/ajg.2010.173

13. Beam AL, Kohane IS. Big data and machine learning in health care. *JAMA*. (2018) 319(13):1317–8. doi: 10.1001/jama.2017.18391

14. Obermeyer Z, Emanuel EJ. Predicting the future - big data, machine learning, and clinical medicine. *N Engl J Med*. (2016) 375(13):1216–9. doi: 10.1056/NEJMp1606181

15. Lundberg SM, Erion G, Chen H, DeGrave A, Prutkin JM, Nair B, et al. From local explanations to global understanding with explainable ai for trees. *Nat Mach Intell*. (2020) 2(1):56–67. doi: 10.1038/s42256-019-0138-9

16. Feng Y, Xu Z, Sun X, Wang D, Yu Y. Machine learning for predicting preoperative red blood cell demand. *Transfus Med*. (2021) 31(4):262–70. doi: 10.1111/tme.12794

17. Durand WM, DePasse JM, Daniels AH. Predictive modeling for blood transfusion after adult spinal deformity surgery: a tree-based machine learning approach. *Spine (Phila Pa 1976)*. (2018) 43(15):1058–66. doi: 10.1097/BRS.0000000000002515

18. Huang X, Wang Y, Chen B, Huang Y, Wang X, Chen L, et al. Ability of a machine learning algorithm to predict the need for perioperative red blood cells transfusion in pelvic fracture patients: a multicenter cohort study in China. *Front Med (Lausanne)*. (2021) 8:694733. doi: 10.3389/fmed.2021.694733

19. Lin J, Wang C, Liu J, Yu Y, Wang S, Wen A, et al. Prevalence and intervention of preoperative Anemia in Chinese adults: a retrospective cross-sectional study based on national preoperative Anemia database. *EClinicalMedicine*. (2021) 36:100894. doi: 10.1016/j.eclinm.2021.100894

20. Liu L-P, Zhao Q-Y, Wu J, Luo Y-W, Dong H, Chen Z-W, et al. Machine learning for the prediction of red blood cell transfusion in patients during or after liver transplantation surgery. *Front Med (Lausanne)*. (2021) 8:632210. doi: 10.3389/fmed.2021.632210

21. Lundberg S, Lee S-I. Consistent feature attribution for tree ensembles. *arXiv e-prints*. (2017). doi: 10.48550/arXiv.1706.06060

22. Jo C, Ko S, Shin WC, Han H-S, Lee MC, Ko T, et al. Transfusion after total knee arthroplasty can be predicted using the machine learning algorithm. *Knee Surg Sports Traumatol Arthrosc*. (2020) 28(6):1757–64. doi: 10.1007/s00167-019-05602-3

23. Grandone E, Mastroianno M, De Laurenzo A, di Mauro L, Carella M, Gorgoglione F, et al. Mortality and clinical outcome of Italian patients undergoing orthopaedic surgery: effect of peri-operative blood transfusion. *Blood Transfus*. (2021) 19(4):284–91. doi: 10.2450/2020.0059-20

24. Hart A, Khalil JA, Carli A, Huk O, Zukor D, Antoniou J. Blood transfusion in primary total hip and knee arthroplasty. Incidence, risk factors, and thirty-day complication rates. *J Bone Joint Surg Am*. (2014) 96(23):1945–51. doi: 10.2106/JBJS.N.00077

25. Gowd AK, Agarwalla A, Amin NH, Romeo AA, Nicholson GP, Verma NN, et al. Construct validation of machine learning in the prediction of short-term postoperative complications following total shoulder arthroplasty. *J Shoulder Elbow Surg*. (2019) 28(12):e410–e21. doi: 10.1016/j.jse.2019.05.017

26. Frisch NB, Wessell NM, Charters MA, Yu S, Jeffries JJ, Silverton CD. Predictors and complications of blood transfusion in total hip and knee arthroplasty. *J Arthroplasty*. (2014) 29(9 Suppl):189–92. doi: 10.1016/j.arth.2014.03.048

27. Park JH, Rasouli MR, Mortazavi SMJ, Tokarski AT, Maltenfort MG, Parvizi J. Predictors of perioperative blood loss in total joint arthroplasty. *J Bone Joint Surg Am*. (2013) 95(19):1777–83. doi: 10.2106/JBJS.L.01335

28. Hülshoff A, Schricker T, Elgendy H, Hatzakorzian R, Lattermann R. Albumin synthesis in surgical patients. *Nutrition*. (2013) 29(5):703–7. doi: 10.1016/j.nut.2012.10.014

29. Jesus S, Alves BP, Golin A, Mairin S, Dachi L, Marques A, et al. Association of Anemia and malnutrition in hospitalized patients with exclusive enteral nutrition. *Nutr Hosp*. (2018) 35(4):753–60. doi: 10.20960/nh.1628

30. Loizou E, Mayhew DJ, Martlew V, Murthy BVS. Implications of deranged activated partial thromboplastin time for anaesthesia and surgery. *Anaesthesia*. (2018) 73(12):1557–63. doi: 10.1111/anae.14344

31. Lenoir B, Merckx P, Paugam-Burtz C, Dauzac C, Agostini M-M, Guigui P, et al. Individual probability of allogeneic erythrocyte transfusion in elective spine surgery: the predictive model of transfusion in spine surgery. *Anesthesiology*. (2009) 110 (5):1050–60. doi: 10.1097/ALN.0b013e31819df9e0

32. Torres-Claramunt R, Ramírez M, López-Soques M, Saló G, Molina-Ros A, Lladó A, et al. Predictors of blood transfusion in patients undergoing elective surgery for degenerative conditions of the spine. *Arch Orthop Trauma Surg*. (2012) 132 (10):1393–8. doi: 10.1007/s00402-012-1563-y

33. Frisch N, Wessell NM, Charters M, Peterson E, Cann B, Greenstein A, et al. Effect of body mass Index on blood transfusion in total hip and knee arthroplasty. *Orthopedics*. (2016) 39(5):e844–e9. doi: 10.3928/01477447-20160509-04

34. Erben H-C, Hess F, Welter J, Graf N, Steurer MP, Neff TA, et al. Perioperative blood transfusions in hip and knee arthroplasty: a retrospective assessment of combined risk factors. *Arch Orthop Trauma Surg*. (2022) 142 (8):1817–22. doi: 10.1007/s00402-021-03763-w

35. Heschl M, Gombotz H, Haslinger-Eisterer B, Hofmann A, Böhler N, Meier J. The efficacy of Pre-operative preparation with intravenous iron and/or erythropoietin in anaemic patients undergoing orthopaedic surgery: an observational study. *Eur J Anaesthesiol*. (2018) 35(4):289–97. doi: 10.1097/EJA.0000000000000752

36. Rineau E, Stoyanov A, Samson E, Hubert L, Lasocki S. Patient blood management in Major orthopedic surgery: less erythropoietin and more iron? *Anesth Analg*. (2017) 125(5):1597–9. doi: 10.1213/ANE.0000000000002086

37. Rudin C. Stop explaining black box machine learning models for high stakes decisions and use interpretable models instead. *Nat Mach Intell*. (2019) 1 (5):206–15. doi: 10.1038/s42256-019-0048-x

frontiers | Frontiers in Surgery

TYPE Original Research
PUBLISHED 16 March 2023
DOI 10.3389/fsurg.2023.1132569

Check for updates

OPEN ACCESS

EDITED BY
Paphon Sa-ngasoongsong,
Mahidol University, Thailand

REVIEWED BY
Delia Cannizzaro,
Humanitas Research Hospital, Italy
George Fotakopoulos,
University Hospital of Larissa, Greece

*CORRESPONDENCE
Lei Lu
lulei9377@126.com

SPECIALTY SECTION
This article was submitted to Orthopedic Surgery, a section of the journal Frontiers in Surgery

RECEIVED 27 December 2022
ACCEPTED 23 February 2023
PUBLISHED 16 March 2023

CITATION
Jingcheng L and Lei L (2023) Clinical effect of limited posterior decompression and 13-mm titanium mesh implantation on severe thoracolumbar burst fractures: A case series. Front. Surg. 10:1132569.
doi: 10.3389/fsurg.2023.1132569

COPYRIGHT
© 2023 Jingcheng and Lei. This is an open-access article distributed under the terms of the Creative Commons Attribution License (CC BY). The use, distribution or reproduction in other forums is permitted, provided the original author(s) and the copyright owner(s) are credited and that the original publication in this journal is cited, in accordance with accepted academic practice. No use, distribution or reproduction is permitted which does not comply with these terms.

Clinical effect of limited posterior decompression and 13-mm titanium mesh implantation on severe thoracolumbar burst fractures: A case series

Liu Jingcheng and Lu Lei*

Spinal Surgery, China Medical University Shaoxing Hospital, Shaoxing, China

Background: Posterior incision with 270° spinal canal decompression and reconstruction surgery is a treatment option for thoracolumbar burst fractures (TLBF), but the large diameter titanium mesh placement is difficult. This study evaluated the characteristics and clinical effects of limited posterior decompression and 13-mm titanium mesh implantation to treat TLBF.
Hypothesis: 13-mm titanium meshes could be used to fix thoracolumbar burst fractures.
Patients and methods: This case series included patients who underwent limited posterior decompression and 13-mm titanium mesh implantation at China Medical University Shaoxing Hospital (01/2015–12/2019). The Cobb angle, injury vertebral anterior edge height loss percentage, and spinal canal occupancy rate were analyzed. The degree of spinal cord injury was evaluated according to the ASIA grade.
Results: Fifteen patients were included (eight males and seven females). The patients were 32.2 ± 4.6 years of age. The American Association of Spinal Injury improved after surgery (A/B/C/D/E: from 2/6/5/2/0 to 0/0/2/8/5, $P < 0.001$). The Cobb angle decreased after surgery (from 20.1 ± 4.8° to 7.1 ± 1.4°, $P < 0.001$) but increased to 8.2 ± 0.9° at 1 year ($P = 0.003$). The percentage of loss of the anterior edge height of the injured vertebrae decreased after surgery (from 40.9% ± 6.1% to 7.5% ± 1.8%, $P < 0.001$) and decreased at 1 year (7.0% ± 1.5%, $P = 0.044$). The spinal canal occupancy rate decreased after surgery (from 64.8% ± 7.8% to 20.1% ± 4.2%, $P < 0.001$) but did not decrease further at 1 year (19.4% ± 3.4%, $P = 0.166$).
Discussion: Spinal canal limited posterior decompression, and 13-mm titanium mesh implantation in the treatment of TLBF can achieve one-stage spinal canal decompression and three-column reconstruction. The curative effect was satisfying.
Level of evidence: Level IV; case series.

KEYWORDS

thoracolumbar fracture, titanium mesh implantation, spinal canal decompression, case series, thoracolumbar burst fractures

Introduction

Thoracolumbar burst fracture usually results from high-energy (younger patients) or low-energy (older patients) vertebral injury (1). The burst bone fragments can squeeze into the spinal canal, leading to spinal cord compression and impaired nerve function (1, 2).

Abbreviations
TLBF, thoracolumbar burst fractures; LSC, load sharing classification; TLICS, thoracolumbar injury classification and severity score; CT, computed tomography; MRI, magnetic resonance imaging.

The proper management of such fractures is crucial since they can easily cause chronic pain (3–6). The treatment goals are to prevent neurological damage, establish stability and fusion of the injured spine, preserve sagittal balance, and initiate early rehabilitation and return to normal activities (1, 2, 7), but how to achieve these goals remains controversial (3–6). The surgical methods for treating thoracolumbar burst fractures include the anterior spinal approach, combined approach, and posterior approach (1, 2, 7). Although the anterior approach can treat fractures of the anterior and middle column of the vertebral body, it cannot treat all injuries to the posterior longitudinal ligament complex and column (1, 2, 7). The anteroposterior combined approach is used to reconstruct the injured vertebra and repair the posterior longitudinal ligament complex. Still, the operation is difficult and time-consuming (1, 2, 7). Therefore, the posterior short-segment pedicle internal fixation is a commonly used treatment method (8), but the posterior approach alone cannot effectively treat anterior and middle column fractures (1, 2, 7).

Many authors advocated a new surgical method for thoracolumbar burst fracture, namely the three-column reconstruction of the vertebral body with the implantation of titanium mesh for one-stage spinal canal decompression (9, 10). In 2008, Huazi et al. (11) described an innovative treatment method for thoracolumbar burst fractures through a posterior incision with 270° spinal canal decompression and reconstruction surgery.

Nevertheless, most of the surgical methods reported in China use titanium meshes with a diameter of 18 or 20 mm, but large-diameter titanium mesh needs to remove more injured vertebrae, with large blood loss during operation, long operation time, and difficulty to place. Small-diameter titanium mesh may have more advantages. From January 2015 to December 2019, many patients with thoracolumbar burst fractures were treated successfully by limited posterior decompression and 13-mm titanium mesh implantation at China Medical University Shaoxing Hospital. To the best of the authors' knowledge, no previous study reported using 13-mm titanium meshes for thoracolumbar burst fractures. Therefore, this retrospective study aimed to evaluate the characteristics and clinical effect of limited posterior decompression and 13-mm titanium mesh implantation to treat thoracolumbar burst fractures.

Methods

Study design and patients

This case series included consecutive patients who underwent limited posterior decompression and 13-mm titanium mesh implantation to treat thoracolumbar burst fractures at the Department of Spinal Surgery of China Medical University Shaoxing Hospital from January 2015 to December 2019. This study was approved by the Ethics Committee of China Medical University Shaoxing Hospital. The requirement for individual informed consent was waived by the committee.

The inclusion criteria were (1) thoracolumbar burst fractures with single-segment vertebral body injury [according to the Three-Column Theory of Denis (6)], (2) Thoracolumbar Injury Classification and Severity Score (TLICS) (12) ≥7 points, (3) Load Sharing Classification (LSC) score (13) ≥7 points, (4) a 13-mm titanium mesh was implanted through the posterior spinal approach, and (5) follow-up time ≥1 year with complete data. The exclusion criteria were (1) multi-segment spinal injury, (2) spinal deformity, (3) autoimmune diseases or any underlying diseases affecting neurological function, (4) very severe osteoporosis, or (5) concomitant cranial nerves or severe thoracic and abdominal joint organ injury.

Data collection

The routine procedures are presented in the **Supplementary Material**. The patients' general characteristics were collected. The patients were re-examined at 1, 3, 6, and 12 months after surgery. Three senior clinicians evaluated the spinal canal occupancy area of the injured vertebra, the percentage of loss of the anterior edge height of the injured vertebra, the Cobb angle, and the American Association of Spinal Injury (ASIA) grade.

Statistical analysis

SPSS 22.0 (IBM, Armonk, NY, United States) was used for data analysis. Categorical data were presented as *n* (%) and analyzed using Fisher's exact test. Quantitative data were presented as means ± standard deviation and analyzed using repeated-measures analysis of variance with the Bonferroni *post hoc* method. The ASIA grades were analyzed as ordinal data. The Stata/SE 15.1 data analysis package (StataCorp LP, College Station, TX, United States) was used to perform two independent sample *t*-tests on the mean ± standard deviation data of the results of two independent studies, analyzing whether the results of the two independent studies were statistically significant. *P*-value <0.05 indicated statistically significant differences.

Results

Characteristics of the patients

Fifteen patients were included. All patients had thoracolumbar burst fractures due to high-energy trauma. At admission, the Cobb angle of the injured vertebra was 20.1 ± 4.7°, the percentage of loss of the anterior edge of the vertebra height was 40.9% ± 5.9%, and the spinal canal occupancy area was 64.8% ± 7.5% (**Table 1**).

All patients were followed up after surgery, and their postoperative recovery was good. The spinal sequence and physiological curvature were restored, and the injured spinal canal was fully decompressed (**Table 1**).

TABLE 1 Characteristics of 15 patients before, after surgery, and at 1-year after surgery.

General information	Patient ($n = 15$)
Sex	
Male (n)	8
Female (n)	7
Age (year, mean ± SD)	32.2 ± 4.6
Types of high-energy injuries	
Car accidents (n)	8
High-altitude falling accidents (n)	3
Falling objects injury (n)	4
TLBF location	
T12 (n)	2
L1 (n)	6
L2 (n)	6
L3 (n)	1
TLICS score (mean ± SD)	7.53 ± 0.71
LSC score (mean ± SD)	7.73 ± 0.77
ASIA grade	
A (n)	2
B (n)	6
C (n)	5
D (n)	2
Operation time (min, mean ± SD)	208 ± 21
Intraoperative bleeding (ml, mean ± SD)	900 ± 359
Postoperative negative pressure drainage flow (ml, mean ± SD)	361 ± 122
Inpatient days (day, mean ± SD)	25.7 ± 4.1

TLBF, thoracolumbar burst fracture; TLICS, thoracolumbar injury classification and severity score; LSC, load sharing classification; ASIA, American Association of Spinal Injury.

The radiological data 1 year after surgery showed fusion of the bone graft in the 13-mm titanium mesh in all patients. There were no space-occupying lesions in the spinal canal of the injured vertebrae and no signs of loosening and falling off of screws and connecting rods during follow-up. The imaging results of typical cases are shown in Figures 1, 2.

ASIA grade of patients before surgery and 1 year after surgery

The 13 patients performed better than they were at admission ($P < 0.001$) (Table 2). The two grade A patients improved to grade D. In grade B patients, one improved to grade C, three to grade D, and two to grade E. Of the grade C patients, one remained grade C, two improved to grade D, and two improved to grade E. In the two grade D patients, one remained unchanged, and the other improved to grade E (Table 2). One patient with a thoracolumbar burst fracture underwent another surgery 1 year later to remove four pedicle screws and thus freed the range of motion of two vertebral body segments. The postoperative recovery was good. One patient with a thoracolumbar burst fracture was evaluated, and all internal fixation devices were removed 1 year after surgery with good postoperative recovery.

Comparison of imaging outcomes

The Cobb angle decreased after surgery (from 20.1 ± 4.8° to 7.1 ± 1.4°, $P < 0.001$) but increased a little to 8.2 ± 0.9° at 1 year ($P = 0.003$). The percentage of loss of the anterior edge height of the injured vertebrae decreased after surgery (from 40.9% ± 6.1% to 7.5% ± 1.8%, $P < 0.001$) and decreased a little more at 1 year (7.0% ± 1.5%, $P = 0.044$). The spinal canal occupancy rate decreased after surgery (from 64.8% ± 7.8% to 20.1% ± 4.2%, $P < 0.001$) and did not decrease further at 1 year (19.4% ± 3.4%, $P = 0.166$) (Table 3).

Discussion

The goals of surgical treatment for patients with a thoracolumbar fracture are to rebuild the biological stability of the injured vertebral body and decompress the spinal canal and avoid neurological dysfunction fully, and eventually improve the patient's quality of life (1, 2, 7). In 1968, thoracolumbar posterior three-column reconstruction was first described to treat a giant cell tumor of the lumbar spine. In 2003, implantation of titanium mesh and posterior spinal canal decompression was performed to treat thoracolumbar burst fractures and achieved satisfactory clinical effects (1, 2, 7). In China, one-stage three-column reconstruction and spinal canal decompression for patients with severe thoracolumbar burst fractures accompanied by spinal cord damage was first carried out by Huazi et al. in 2005 (11).

Burst fractures are caused by an axial plane compression force of the vertebral body (1). The nucleus pulposus of the intervertebral disc protrudes into the spinal canal from the superior endplates, which accounts for 21%–58% of thoracolumbar fractures (14). The objective of one-stage spinal canal surgical treatment is to decompress the dural sac to avoid aggravating the compression of the spinal cord. Based on the three-column theory of Denis (6), the corresponding anterior, middle, and posterior spine columns are reconstructed to ensure the stability of the spine.

For severe thoracolumbar burst fractures, the anterior or posterior approach through the injured vertebra alone cannot completely decompress the injured spinal canal while achieving a three-column reconstruction of the injured vertebral body. The classic surgical methods include posterior spinal approach decompression and pedicle screw fixation (15). It is undeniable that such a surgical method can achieve the reconstruction of the posterior column; however, when the anterior, middle, and posterior columns are all injured, the cancellous bone of the anterior and middle columns cannot be repositioned in one stage, that is, the "eggshell vertebral body". With the loss of height between the upper and lower endplates of the anterior edge of the injured vertebral after surgery, the physiological curvature of the spine is destroyed, and the internal fixation device of the injured vertebral body fails. Compared with the anterior or posterior approach alone, the combined

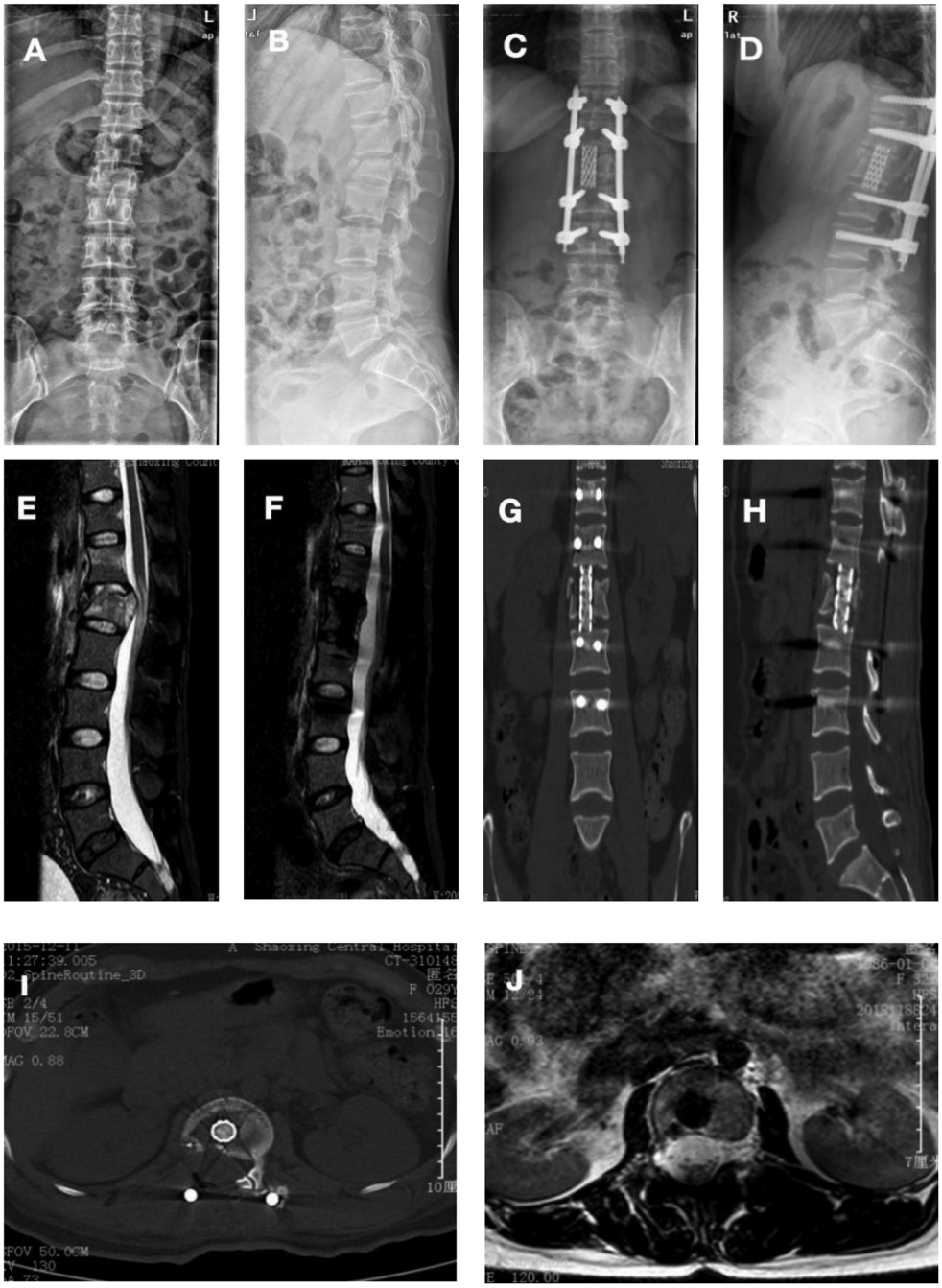

FIGURE 1
Typical preoperative, postoperative, and follow-up images of severe thoracolumbar burst fractures with posterior midline spinal approach for spinal canal limited decompression and 13-mm titanium mesh implantation (case #1). (**A**,**B**) True lateral x-rays of the patient's thoracolumbar spine before the operation shows the L1 fracture. (**C**,**D**) True lateral x-rays of the thoracolumbar vertebrae after the operation showing good fixation and recovery of the height of the anterior edge of the L1 vertebra itself. (**E**) Preoperative magnetic resonance imaging (MRI) shows L1 burst fracture, spinal cord compression, and obvious spinal canal occupancy. (**F**–**J**) Postoperative MRI indicates no spinal cord compression and no spinal canal occupancy. (**G**–**I**) Postoperative computed tomography (CT) indicates a good position of the titanium mesh, screws, and titanium rods and good bone graft fusion. (**H**) Thoracolumbar CT after the removal of titanium rods and screws.

anteroposterior approach results in increased operation time, intraoperative bleeding, and trauma and thus lead to complex perioperative management (15). Although the anterior approach alone can achieve the operation under direct vision, the spinal canal cannot be decompressed completely, and the posterior column of the injured vertebra cannot be reconstructed. Furthermore, it is difficult to reposition the intervertebral joints. Besides, there are many organs in the thorax and abdomen, leading to serious consequences of postoperative infections.

In order to solve the problems of traditional surgical treatment of thoracolumbar burst fractures and maximize the risk-benefit ratio, Huazi et al. (11). proposed an innovative surgical method:

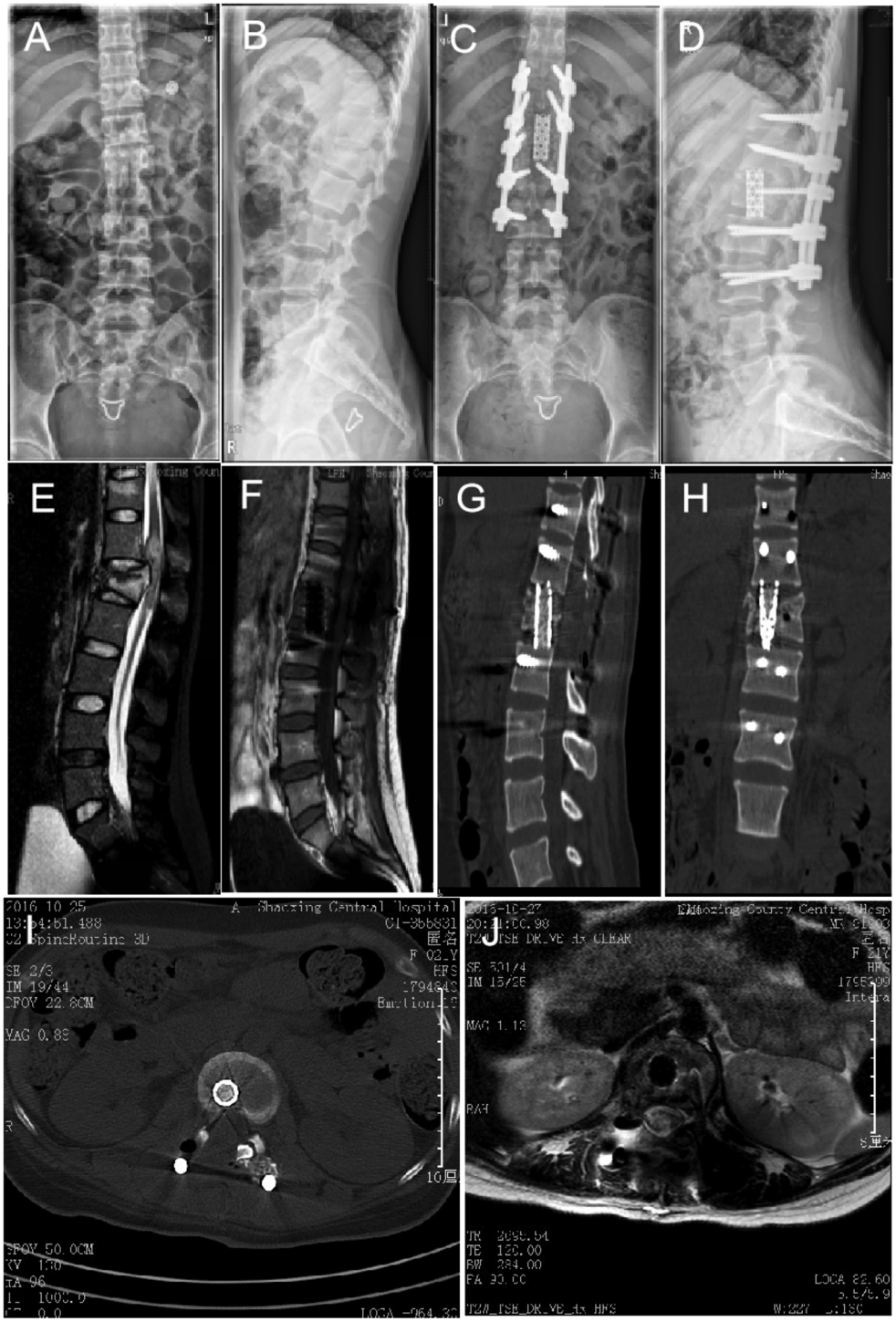

FIGURE 2
Typical preoperative, postoperative, and follow-up images of severe thoracolumbar burst fractures with posterior midline spinal approach for spinal canal limited decompression and 13-mm titanium mesh implantation (case #2). (**A**,**B**) True lateral digital x-rays of the patient's thoracolumbar spine before the operation showing the L1 fracture. (**C**,**D**) True lateral digital x-rays of the thoracolumbar vertebrae after the operation showing good fixation and recovery of the height of the anterior edge of the L1 vertebra. (**E**,**F**) Preoperative magnetic resonance imaging (MRI) showing L1 burst fracture, spinal cord compression, and obvious spinal canal occupancy. (**G**–**J**) Postoperative MRI indicates no spinal cord compression and no spinal canal occupancy. (**I**) Postoperative computed tomography (CT) indicates a good position of the titanium mesh, screws, and titanium rods.

270° spinal canal decompression and reconstruction surgery through a posterior incision. The potential damage of the operation itself is reduced, and the three columns of the vertebral body are effectively reconstructed. The indications for this operation are severe thoracolumbar burst fractures, three-column integrity destruction, LSC ≥7 points, and good general

conditions. In this study, all 15 patients met these surgical indications. The 270° spinal canal decompression and 18-mm large-diameter titanium mesh surgery were used for implementation. The advantages of this surgical method are that the spinal canal of the injured spinal canal was fully relieved from the one-stage operation, and the anterior and middle column was reconstructed with titanium mesh implantation. Secondly, the titanium mesh implantation ensures the stability of the anterior and middle columns of the vertebral body, while the pedicle screw fixation repairs the posterior column. Moreover, titanium mesh implantation distributes the stress of the pedicle screw during the movement of the vertebral body and thus avoids internal fixation failure. Thirdly, after filling and fusion with a fragment of autogenous bone, the intervertebral height is not easily lost and thus reduces the incidence of secondary kyphosis. Fourthly, the patients have a good long-term prognosis. At the same time, the disadvantages of the surgical method are that the 270° lateral anterior curettage of the injured vertebral cancellous bone might lead to massive bleeding. Secondly, it is difficult to measure the intervertebral height during the operation accurately. The larger the diameter of the titanium mesh, the more difficult the implantation is. Meanwhile, there is a risk of nerve root traction, and accordingly, the operation time is prolonged (16). Thirdly, since the operation is complicated, the doctors need to have rich clinical experience and skills. Fourthly, it is difficult to clean the bone fragment completely because of the potential blind spot. Because of the disadvantages described above, such a surgical method has not been widely promoted in China to treat severe thoracolumbar burst fractures.

The published data by Dun et al. (17) (mesh of 18 or 20 mm) were used for comparison. The analysis showed that the operation time was significantly shortened with the 13-mm mesh ($t = 10.11$; $P < 0.001$) and that the volume of bleeding during the operation was significantly reduced ($t = 2.32$; $P < 0.05$), but without difference for the negative pressure drainage volume after surgery ($t = -0.18$; $P = 0.86$). The three-column reconstruction of 270° spinal decompression is usually performed with large-diameter 18- and 20-mm titanium mesh. Given the difficulty in implantation of large titanium mesh during the operation, the long operation time, and the excision of more vertebral cancellous bone in the use of large titanium mesh, the authors' hospital adopted limited spinal canal decompression with a 13-mm small diameter titanium mesh implanted, and the vertebral body was fixed in long segments. The advantages of the surgical method are that the titanium mesh with a small diameter of 13 mm is easier to implant, requires less resection of the injured vertebra, leads to a faster postoperative recovery of the patients, and significantly reduces operation time and blood loss. Second, although the titanium mesh with a diameter of 13 mm was small, the posterior column of the injured vertebra was fixed with a long fixation rod, which reduced the compression stress of the anterior column. Besides, imaging results showed no incision settlement of the vertebral body caused by the titanium mesh. Third, when a titanium mesh with a smaller diameter is used, the upper nerve roots are loose, thereby avoiding excessive traction of the nerve roots by the implanted titanium mesh. Some domestic scholars pointed out that the posterior internal fixation methods for thoracolumbar burst fractures include long and short vertebral segment fixation. The short vertebral segment internal fixation is more effective in reducing stress concentration in adjacent segments, while the long one is superior in fracture reduction, restoration of kyphosis, and reconstruction stability (18). According to the imaging results of the patient's follow-up, the anterior edge height of the injured vertebra was not lost, the vertebral morphology was complete, and the physiological curvature was good. There was no fracture of screws or titanium rods, and the fusion of the titanium mesh bone graft was good. After successful bone graft fusion for thoracolumbar burst fractures, removing pedicle screw rods is of great help to improve the patients' low back pain and dysfunction, which might be related to the recovery of inter-segmental mobility (19). In the present study, not all patients had their screws removed. Generally, the screws of the anterior fusion segment cannot be removed but can be removed in some patients for psychological reasons. Depending on the level of injury to the posterior column of the spine, especially the extent and extent of injury to the ligamentous complex, the decision to remove the screws across the anterior fixation segment can be made. For some patients with posterior ligament injury, interlaminar bone grafting was performed across the fusion segment in consideration of long-term stability. The scope of screw fixation across the fusion level and whether to remove the screw has not

TABLE 2 Comparison of patients' ASIA grade between pre-operation and 1-year after surgery.

ASIA grade ($n = 15$)				
Index	Pre-operation	One-year after surgery	Statistical value	P
ASIA grade (A/B/C/D/E)	2/6/5/2/0	0/0/2/8/5	$X^2 = 17.269$	0.001

ASIA, American Association of Spinal Injury.

TABLE 3 Comparison of Cobb angle, loss percentage of anterior vertebral height, and spinal canal occupancy rate of 15 patients before operation, after the operation, and at 1-year after surgery.

Variable	Before operation	After operation	1-year after surgery	$P_{\text{Postoperation}}$ vs. $P_{\text{Preoperation}}$	$P_{\text{1-year after surgery}}$ vs. $P_{\text{Postoperation}}$	$P_{\text{1-year after surgery}}$ vs. $P_{\text{Postoperation}}$
Cobb angle (degree, mean ± SD)	20.1 ± 4.8	7.1 ± 1.4	8.2 ± 0.9	<0.001	<0.001	0.003
Loss percentage of anterior vertebral height (%, mean ± SD)	40.9 ± 6.1	7.5 ± 1.8	7.0 ± 1.5	<0.001	<0.001	0.044
Spinal canal occupancy rate (%, mean ± SD)	64.8 ± 7.8	20.1 ± 4.2	19.4 ± 3.4	<0.001	<0.001	0.166

been reported in domestic and foreign literature, and we were relatively cautious in removing the screw. This issue should be addressed in future studies.

This study has limitations. The sample size was small and from a single center, severely limiting the generalizability of the results. Bias due to local perioperative management cannot be excluded. Even though consecutive patients were selected, the inclusion/exclusion criteria might lead to a selection bias. As a retrospective study, the analyzable data were limited to those in the patient charts. No control group could be included.

In conclusion, spinal canal decompression and 13-mm titanium mesh implantation in the treatment of TLBF can achieve one-stage spinal canal decompression and three-column reconstruction. The curative effect is satisfying. This smaller mesh could be appropriate for younger patients with healthy bone structures. Additional studies are necessary to determine the patients who might benefit the most from using the 13-mm mesh.

Data availability statement

The original contributions presented in the study are included in the article/**Supplementary Material**, further inquiries can be directed to the corresponding author.

Ethics statement

The studies involving human participants were reviewed and approved by the Ethics Committee of China Medical University Shaoxing Hospital. Written informed consent for participation was not required for this study in accordance with the national legislation and the institutional requirements.

Author contributions

LL and JL carried out the studies, participated in collecting data, and drafted the manuscript. JL performed the statistical analysis and participated in its design. LL and JL participated in the acquisition, analysis, or interpretation of data. All authors contributed to the article and approved the submitted version.

Conflict of interest

The authors declare that the research was conducted in the absence of any commercial or financial relationships that could be construed as a potential conflict of interest.

Publisher's note

All claims expressed in this article are solely those of the authors and do not necessarily represent those of their affiliated organizations, or those of the publisher, the editors and the reviewers. Any product that may be evaluated in this article, or claim that may be made by its manufacturer, is not guaranteed or endorsed by the publisher.

Supplementary material

The Supplementary Material for this article can be found online at: https://www.frontiersin.org/articles/10.3389/fsurg.2023.1132569/full#supplementary-material.

References

1. Cahueque M, Cobar A, Zuñiga C, Caldera G. Management of burst fractures in the thoracolumbar spine. *J Orthop*. (2016) 13:278–81. doi: 10.1016/j.jor.2016.06.007

2. Rosenthal BD, Boody BS, Jenkins TJ, Hsu WK, Patel AA, Savage JW. Thoracolumbar burst fractures. *Clin Spine Surg*. (2018) 31:143–51. doi: 10.1097/BSD.0000000000000634

3. Kim BG, Dan JM, Shin DE. Treatment of thoracolumbar fracture. *Asian Spine J*. (2015) 9:133–46. doi: 10.4184/asj.2015.9.1.133

4. Schroeder GD, Kepler CK, Koerner JD, Chapman JR, Bellabarba C, Oner FC, et al. Is there a regional difference in morphology interpretation of A3 and A4 fractures among different cultures? *J Neurosurg Spine*. (2016) 24:332–39. doi: 10.3171/2015.4.SPINE1584

5. N'Da HA, Chenin L, Capel C, Havet E, Le Gars D, Peltier J. Microsurgical anatomy of the adamkiewicz artery-anterior spinal artery junction. *Surg Radiol Anat*. (2016) 38:563–7. doi: 10.1007/s00276-015-1596-3

6. Denis F. The three column spine and its significance in the classification of acute thoracolumbar spinal injuries. *Spine*. (1983) 8:817–31. doi: 10.1097/00007632-198311000-00003

7. Yuan L, Yang S, Luo Y, Song D, Yan Q, Wu C, et al. Surgical consideration for thoracolumbar burst fractures with spinal canal compromise without neurological deficit. *J Orthop Translat*. (2020) 21:8–12. doi: 10.1016/j.jot.2019.12.003

8. Korovessis P, Baikousis A, Zacharatos S, Petsinis G, Koureas G, Iliopoulos P. Combined anterior plus posterior stabilization versus posterior short-segment instrumentation and fusion for mid-lumbar (L2-L4) burst fractures. *Spine*. (2006) 31:859–68. doi: 10.1097/01.brs.0000209251.65417.16

9. Jo DJ, Kim KT, Kim SM, Lee SH, Cho MG, Seo EM. Single-stage posterior subtotal corpectomy and circumferential reconstruction for the treatment of unstable thoracolumbar burst fractures. *J Korean Neurosurg Soc*. (2016) 59:122–8. doi: 10.3340/jkns.2016.59.2.122

10. Liu Y, Li G, Dong T, Zhang Y, Li H. One-stage partial vertebrectomy, titanium mesh implantation and pedicle screw fixation in the treatment of thoracolumbar burst fractures through a posterior approach. *Clinics*. (2014) 69:804–8. doi: 10.6061/clinics/2014(12)03

11. Huazi X, Wenferi N, Qishan H, YongLong C, XiangYang W, Yuanming OY, et al. The treatment of severe thoracolumbar injury with 270° decompression and reconstruction through a small posterior incision. *Chin J Spine Spinal Cord*. (2008) 05:368–72.

12. Lee JY, Vaccaro AR, Lim MR, Oner FC, Hulbert RJ, Hedlund R, et al. Thoracolumbar injury classification and severity score: a new paradigm for the treatment of thoracolumbar spine trauma. *J Orthop Sci*. (2005) 10:671–5. doi: 10.1007/s00776-005-0956-y

13. McCormack T, Karaikovic E, Gaines RW. The load sharing classification of spine fractures. *Spine*. (1994) 19:1741–4. doi: 10.1097/00007632-199408000-00014

14. Alanay A, Acaroglu E, Yazici M, Oznur A, Surat A. Short-segment pedicle instrumentation of thoracolumbar burst fractures: does transpedicular intracorporeal grafting prevent early failure? *Spine*. (2001) 26:213–7. doi: 10.1097/00007632-200101150-00017

15. Suk SI, Kim JH, Lee SM, Chung ER, Lee JH. Anterior-posterior surgery versus posterior closing wedge osteotomy in posttraumatic kyphosis with neurologic

compromised osteoporotic fracture. *Spine*. (2003) 28:2170–5. doi: 10.1097/01.BRS.0000090889.45158.5A

16. Xiaohong W, Jiandong L. One-stage posterior subtotal resection of the injured vertebrae with three-column reconstruction for the treatment of severe thoracolumbar fracture and dislocation. *J Clin Orthop*. (2018) 21:274–77.

17. Dun W, Xiaoming X, Yuliang S, Xuangeng D, Huagang S, Simao S, et al. 270° Spinal canal decompression and reconstruction of the anterior and middle column of the vertebral body for the treatment of severe thoracolumbar fractures. *Orthop J China*. (2019) 27:1657–62.

18. Xuehai D, Xuewen W. Comparison of short-term curative effects of posterior pedicle screw fixation with different fixed segments for the treatment of thoracolumbar fractures. *Chin J Bone Joint Surg*. (2018) 11:812–15.

19. Hong P. The effect of posterior bone graft fusion and removal of internal fixation on surgical efficacy of thoracolumbar burst fractures. *J Cervicodynia Lumbodynia*. (2021) 42:94–6.

frontiers | Frontiers in Surgery

TYPE Original Research
PUBLISHED 17 March 2023
DOI 10.3389/fsurg.2023.1133744

Check for updates

OPEN ACCESS

EDITED BY
Paphon Sa-ngasoongsong,
Mahidol University, Thailand

REVIEWED BY
Mitchell K. Ng,
Maimonides Medical Center, United States
Shuisheng Yu,
Second Hospital of Anhui Medical University, China

*CORRESPONDENCE
Zhiyong Hou
✉ drzyhou@gmail.com

SPECIALTY SECTION
This article was submitted to Orthopedic Surgery, a section of the journal Frontiers in Surgery

RECEIVED 29 December 2022
ACCEPTED 23 February 2023
PUBLISHED 17 March 2023

CITATION
Jin L, Wang Z, Zhao K, Lian X, Chen W, Zhang Y and Hou Z (2023) Drain vs. no-drain for acetabular fractures after treatment *via* a modified stoppa approach: A retrospective study.
Front. Surg. 10:1133744.
doi: 10.3389/fsurg.2023.1133744

COPYRIGHT
© 2023 Jin, Wang, Zhao, Lian, Chen, Zhang and Hou. This is an open-access article distributed under the terms of the Creative Commons Attribution License (CC BY). The use, distribution or reproduction in other forums is permitted, provided the original author(s) and the copyright owner(s) are credited and that the original publication in this journal is cited, in accordance with accepted academic practice. No use, distribution or reproduction is permitted which does not comply with these terms.

Drain vs. no-drain for acetabular fractures after treatment *via* a modified stoppa approach: A retrospective study

Lin Jin[1,2], Zhongzheng Wang[1,2], Kuo Zhao[1,2], Xiaodong Lian[1,2], Wei Chen[1,2,3], Yingze Zhang[1,2,3,4] and Zhiyong Hou[1,2,3]

[1]Department of Orthopaedic Surgery, Third Hospital of Hebei Medical University, Shijiazhuang, China, [2]Key Laboratory of Biomechanics of Hebei Province, Third Hospital of Hebei Medical University, Shijiazhuang, China, [3]NHC Key Laboratory of Intelligent Orthopaedic Equipment, Third Hospital of Hebei Medical University, Shijiazhuang, China, [4]Chinese Academy of Engineering, Beijing, China

Objective: The aim of this study was to compare the clinical efficacy of close suction drainage (CSD) and no-CSD after a modified Stoppa approach for the surgical fixation of acetabular fractures.
Methods: This retrospective study included 49 consecutive acetabular fracture patients, who presented to a single level I trauma center for surgical fixation, using a modified Stoppa approach from January 2018 to January 2021. All surgeries were performed by a senior surgeon using the same approach, and the patients were divided into two groups based on whether CSD was used after the operation. Details of the patient demographics, fracture characteristics, intraoperative indicators, reduction quality, intra and postoperative blood transfusion, clinical outcomes, and incision-related complications were collected.
Results: No significant differences were found in the demographics, fracture characteristics, intraoperative indicators, reduction quality, clinical outcomes, and incision-related complications between the two groups ($P > 0.05$). The use of CSD was associated with a significantly higher postoperative blood transfusion volume ($P = 0.034$) and postoperative blood transfusion rate ($P = 0.027$). In addition, there was a significant difference in postoperative temperatures, especially on postoperative Day 2 (no-CSD 36.97 ± 0.51°C vs. CSD 37.34 ± 0.69°C, $P = 0.035$), and higher visual analogue scale (VAS) scores, especially on postoperative Day 1 (no-CSD 3.00 ± 0.93 vs. CSD 4.14 ± 1.43, $P = 0.002$) and 3 (no-CSD 1.73 ± 0.94 vs. CSD 2.48 ± 1.08, $P = 0.013$).
Conclusion: The results of this study suggest that routine use of CSD should not be recommended for patients with acetabular fractures after surgical fixation using a modified Stoppa approach.

KEYWORDS
acetabular fracture, close suction drainage, modified stoppa approach, surgical method, treatment

1. Introduction

Acetabular fractures are usually caused by high-energy trauma, have an incidence of ~3 out of every 100,000 patients per year, and are one of the most difficult fractures to manage in orthopedic surgery (1, 2). Because it is an intraarticular fracture, displaced acetabular fracture patients usually need surgical treatment (3). Many surgical approaches have been used to treat acetabular fractures, such as the iliofemoral, ilioinguinal, Kocher–

Langenbeck, combined anterior/posterior, modified Stoppa, and extended iliofemoral approaches (4–6). The modified Stoppa approach was proposed by Cole and Bolhofner in 1994 and has been widely used in recent years (7). It is an ideal surgical fixation method for the majority of acetabular fractures, because it not only results in good exposure of the fracture area but also achieves a good reduction of fracture fragments, especially those involving the anterior column, anterior wall, and posterior hemitransverse, transverse, T-type, and both columns with predominately anterior displacement (2, 4, 8, 9).

In clinical applications, closed suction drainage (CSD) is often used as a preventive strategy to eliminate dead space and reduce the occurrence of postoperative wound complications, including hematoma formation, redness, infection, pain, and incisional hernia (10, 11). The application of CSD in open wound or infectious surgeries can play a role in draining pus and necrotic tissue debris, and its use in these cases was previously beyond doubt (11). However, there is little published evidence to support its routine use after surgery. Some literature suggests that the use of CSD may be associated with increased postoperative blood transfusion rates, days in hospital, and incision pain (10, 12). In addition, some have argued that CSD, as a foreign body, may become a potential source of infection, allowing external pathogens to enter deep wounds and increasing the chances of infection (13–15). Similar debates have been reported in the orthopedic spine and trauma literature (16, 17).

To prevent the formation of wound hematomas and enhance postoperative recovery, many orthopedic surgeons still routinely use CSD after using a modified Stoppa approach to treat acetabular fractures. However, we have found that the use of CSD will not provide any benefit to patients with acetabular fractures repaired using a modified Stoppa approach. Therefore, the aim of this study was to compare the clinical efficacy of CSD with no-CSD after a modified Stoppa approach in the surgical fixation of acetabular fractures.

2. Patients and methods

2.1. Patients

Between January 2018 and January 2021, a total of 127 skeletally mature patients with acetabular fractures were surgically treated in our level I trauma center. The inclusion criteria included the following: (1) adult patients aged 18 years or older; (2) diagnosis of an acute and closed acetabular fracture; (3) patients who underwent open reduction and internal fixation *via* a modified Stoppa approach; and (4) complete and available imaging and hospitalization data. The exclusion criteria were as follows: (1) open acetabular fractures; (2) previous history of acetabular fracture or bone tumor; (3) patients who underwent surgical treatment *via* another approach; and (4) patients with incomplete hospitalization and operation records. A total of 49 patients with acetabular fractures who underwent surgical treatment through a modified Stoppa approach were enrolled in our study for analysis. All 49 patients were divided into two groups according to whether CSD was used after surgery (in Group 1, 22 patients underwent no-CSD after surgery; in Group 2, 27 patients underwent CSD after surgery). Figure 1 shows a chart of the study design.

This study was approved by the Ethics Committee of Third Hospital of Hebei Medical University (Theoretical No. K2015-001-12) and conformed to the ethical standards of the Declaration of Helsinki, adopted in 1964, and its subsequent amendments. Signed informed consent was obtained from all patients.

2.2. Preoperative management

All patients were hemodynamically stable before the operation. When available, radiography and CT scans of the injured hip were performed in all patients to assess the extent of displacement. According to the imaging data results, these fractures were graded by the Judet–Letournel classification system (18). If no contraindication was present, low-molecular-weight heparin was given to the patients before the operation. For unstable fractures, bone traction or skin traction was used to facilitate intraoperative reduction.

2.3. Surgical techniques

All patients underwent general anesthesia in the supine position during the operation. A vertical midline incision was made from approximately 2 cm below the umbilicus to 1 cm above the pubic symphysis joint. After making an incision along the alba line of the rectus abdominis muscle, blunt finger dissection was performed to detach the superior ramus of the pubis, releasing the periosteum and iliopectineal fascia, extending to the pelvic brim and the internal iliac fossa, and continuing to emerge laterally. During exposure, the anastomotic branches (corona mortis) between the internal and external iliac vessels were identified for protection. Tying or cauterization was performed to avoid bleeding if the corona mortis was damaged. Subperiosteal dissection was performed along the pelvic brim, exposing the fracture fragments. Attention was paid to identify and protect the obturator nerves and blood vessels during the further operation. Once the fracture site was exposed, reduction tools were used to attempt reduction and internal fixation. After confirmation by fluoroscopy, the wounds were closed in layers for the patients in Group 1. For the patients in Group 2, all surgical procedures were same as those in Group 1, except that a drain for CSD was placed before closing the wound (Figure 2).

2.4. Postoperative care

Patients in both groups received the same postoperative rehabilitation program. Low-molecular-weight sodium heparin was given to prevent deep vein thrombosis from 6 h to 4 weeks after surgery. The drain CSD was removed 48 h after surgery if the drainage did not exceed 50 ml/day. After surgery, the patients were encouraged to perform passive hip mobility as soon as

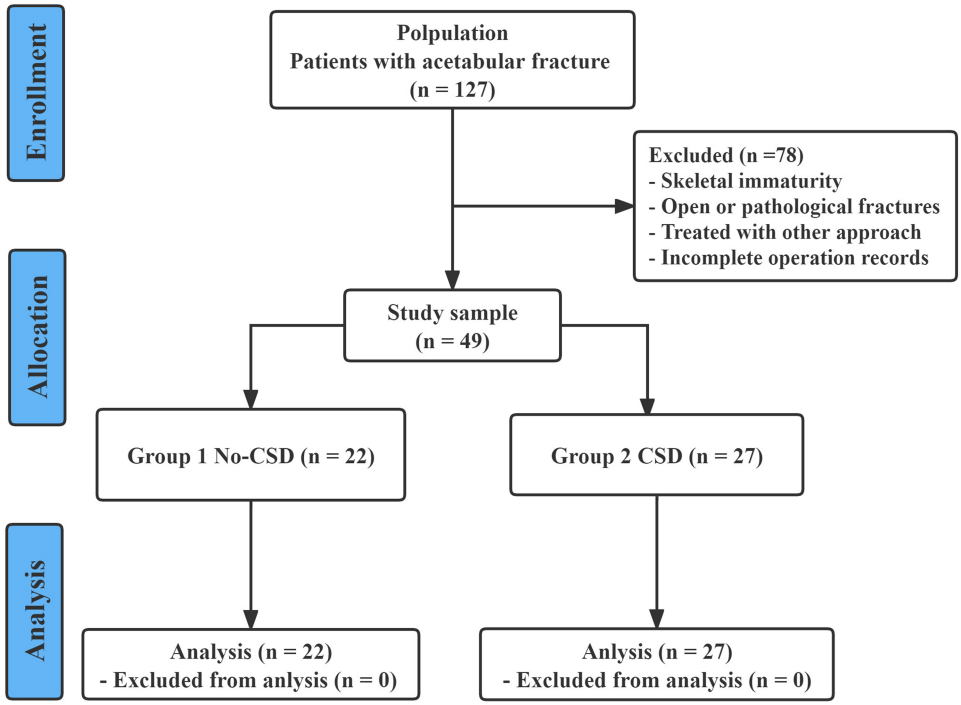

FIGURE 1
The flowchart of the patient screening process.

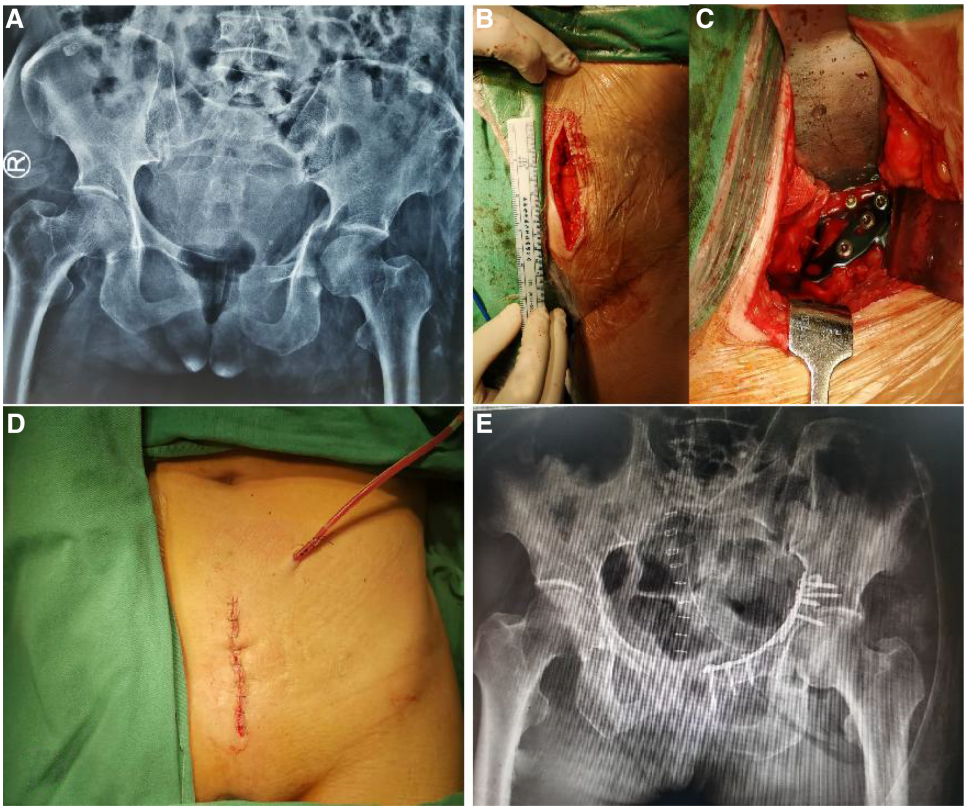

FIGURE 2
A female patient, 57 years old, with a T-type acetabular fracture who underwent surgical treatment *via* a modified stoppa approach. (A) preoperative anteroposterior pelvic radiograph; (B), picture of the incision of the modified Stoppa approach; (C), internal fixation was placed after fracture reduction; (D), a CSD was used after surgery; (E), postoperative anteroposterior pelvic radiograph.

possible. According to the general condition of the patient, the severity of the injury, and the quality of the reduction and fixation, the patients were guided to perform gradual rehabilitation exercises.

2.5. Observation index

In the present study, demographic characteristics, fracture characteristics, and medical records, including operative reports and inpatient progress notes, were collected retrospectively and compared between the two groups. The primary outcome measures were perioperative hemoglobin changes, postoperative blood transfusion volume and rate, and postoperative clinical outcomes. The secondary outcome measures included changes in body temperature from before surgery and on postoperative Day 1, 2, 3, and 7, as well as incision-related complications. Data on the duration of operation, intraoperative blood loss, and corona mortis ligation were obtained from the operation records. Data on the preoperative hemoglobin (Hgb) and intra and postoperative blood transfusion volume and rate were obtained from the inpatient progress notes. ΔHgb was expressed as the Hgb change from immediately before to after surgery. The Harris hip score (HHS) was used to evaluate the function of the hip after surgery. Visual analogue scale (VAS) scores were used to evaluate the degree of pain before surgery and on postoperative Day 1, 3, and 7. Incision-related complications mainly included wound infections, wound dehiscence, hematomas, and non-union. Wound-related complications and other perioperative issues were followed up for at least one year.

2.6. Statistical analysis

The analyses were performed using SPSS 23.0 software (IBM, Armonk, New York). Measurement data were expressed as the mean ± SD or numbers and percentages (%). The Kolmogorov–Smirnov test was used to confirm a normal distribution. Potential explanatory variables were evaluated using a chi-square test or Fisher's test for categorical variables and independent-samples *t* tests or Mann–Whitney U tests for continuous variables. The level of significance was set at $P < 0.05$.

3. Results

3.1. Patient and fracture characteristics

In the present study, 49 patients with acetabular fractures who met our screening criteria were enrolled in the analysis, of whom 37 were male and 12 were female (mean age: 49.06 ± 15.28; range: 21–80 years). Among them, 22 patients (44.9%) did not use CSD after surgery *via* a modified Stoppa approach and were enrolled in Group 1. According to the Judet–Letournel classification, there were six fracture types managed by a single modified Stoppa approach, including column fractures (16/49, 32.7%), anterior column fractures (12/49, 24.5%), anterior wall fractures (3/49, 6.1%), anterior column and posterior hemitransverse fractures (5/49, 10.2%), transverse fractures (7/49, 14.3%), and T-type fractures (6/49, 12.2%). All fracture types were identified by the same senior orthopedic surgeon according to the preoperative radiographs and CT scans. There were no significant differences in demographics or fracture classifications between the two groups (Table 1).

3.2. Perioperative-related indicators

Perioperative variables are shown in Table 2. There were no significant differences observed in intraoperative indicators between the two groups, including the duration of operation, intraoperative blood loss, reduction quality, corona mortis ligation, preoperative Hgb, changes in Hgb from immediately before to after surgery (ΔHgb), and intraoperative blood transfusion volume and rate. While the postoperative blood transfusion volume and rate tended to be higher in the CSD group than in the no-CSD group, the differences were statistically significant ($P = 0.034$ and $P = 0.027$, respectively). There were no significant intergroup differences in incision exudation time ($P = 0.789$) or HHS ($P = 0.869$). Preoperatively, no significant differences were found in body temperature or VAS pain score between the two groups. Postoperatively, there were significant intergroup differences in body temperature on

TABLE 1 Patient demographic data and fracture characteristics ($n = 49$).

Variable	No-drain Group ($n = 22$)	Drain Group ($n = 27$)	*P* value
Mean age (mean ± SD, years)	18.82 ± 17.19	49.26 ± 13.86	0.921
Sex (male), *n* (%)	17 (77.27)	20 (74.07)	0.796
BMI (mean ± SD, Kg/m^2)	25.20 ± 2.63	25.87 ± 3.31	0.441
Tobacco smoker (yes), *n* (%)	4 (18.18)	7 (25.93)	0.518
Alcohol use (yes), *n* (%)	3 (13.64)	5 (18.52)	0.646
Comorbidities (yes), *n* (%)			
Diabetes mellitus	5 (22.73)	3 (11.11)	0.274
Hypertension	6 (27.27)	7 (25.93)	0.915
Coronary heart disease	2 (0.90)	3 (11.11)	0.816
Affected side (left), *n* (%)			0.757
Left	9 (40.91)	13 (48.15)	
Right	12 (54.55)	12 (44.44)	
Bilateral	1 (4.54)	2 (7.41)	
Injury to surgery (mean ± SD, days)	5.00 ± 2.51	5.18 ± 2.82	0.762
Days in hospital (mean ± SD, days)	16.09 ± 3.89	16.48 ± 4.73	0.757
Follow-up (mean ± SD, months)	26.91 ± 17.20	26.22 ± 16.31	0.840
Fracture classification (Judet–Letournel), *n* (%)			0.947
Both columns	8 (36.36)	8 (29.64)	
Anterior column	5 (22.73)	7 (25.93)	
Anterior wall	2 (9.09)	1 (3.70)	
Anterior column and posterior hemitransverse	2 (9.09)	3 (11.11)	
Transverse	3 (13.64)	4 (14.81)	
T-type	2 (9.09)	4 (14.81)	

TABLE 2 Comparison of perioperative-related indicators between the two groups.

Variable	No-drain Group ($n = 22$)	Drain Group ($n = 27$)	P value
ASA score, *n* (%)			0.639
I	2 (9.09)	5 (18.52)	
II	14 (63.64)	15 (55.55)	
III or above	6 (27.27)	7 (25.93)	
Duration of operation (minutes), *n* (%)			0.518
1–120	4 (18.18)	7 (25.93)	
>120	18 (82.82)	20 (74.07)	
Intraoperative blood loss (ml), *n* (%)			0.612
1–200	3 (13.64)	6 (22.22)	
201–400	10 (45.45)	9 (33.33)	
>400	9 (40.91)	12 (44.45)	
Reduction quality, *n* (%)			0.983
Excellent	4 (18.18)	5 (18.52)	
Good	11 (50.00)	14 (51.84)	
Fair	5 (22.73)	5 (18.52)	
Poor	2 (9.09)	3 (11.11)	
Crown of death ligate, *n* (%)	6 (27.27)	6 (22.22)	0.683
Preoperative Hgb (mean ± SD, g/L)	117.28 ± 15.87	112.68 ± 15.06	0.305
ΔHgb (mean ± SD, g/L)	21.34 ± 11.15	17.31 ± 12.46	0.244
Intraoperative blood transfusion volume (mean ± SD, ml)	284.54 ± 200.73	303.70 ± 228.41	0.723
Intraoperative blood transfusion rate, *n* (%)	14 (63.64)	16 (59.26)	0.754
Postoperative blood transfusion volume (mean ± SD, ml)	127.27 ± 169.54	259.25 ± 246.92	0.034
Postoperative blood transfusion rate, *n* (%)	6 (27.27)	15 (55.55)	0.027
Postoperative drainage volume (mean ± SD, ml)	–	153.70 ± 107.56	–
Incision exudation time (mean ± SD, days)	3.27 ± 1.35	3.37 ± 1.18	0.789
HHS (mean ± SD)	83.56 ± 9.81	84.41 ± 6.61	0.869
Body temperature (mean ± SD, °C)			
Preoperative	36.82 ± 0.43	36.91 ± 0.40	0.460
Postoperative day 1	37.01 ± 0.55	37.26 ± 0.48	0.107
Postoperative day 2	36.97 ± 0.51	37.34 ± 0.69	0.035
Postoperative day 3	36.92 ± 0.58	37.12 ± 0.41	0.234
Postoperative day 7	36.75 ± 0.33	36.66 ± 0.31	0.488
VAS pain score (mean ± SD)			
Preoperative	3.77 ± 1.48	3.93 ± 1.66	0.738
Postoperative day 1	3.00 ± 0.93	4.14 ± 1.43	0.002
Postoperative day 3	1.73 ± 0.94	2.48 ± 1.08	0.013
Postoperative day 7	1.04 ± 0.95	1.48 ± 1.01	0.117
Time to remove stitches (mean ± SD, days)	14.41 ± 0.89	14.07 ± 0.96	0.832

postoperative Day 2 (no-CSD group, 36.97 ± 0.51°C vs. CSD group, 37.34 ± 0.69°C; $P = 0.035$) and VAS pain score on postoperative Day 1 (no-CSD group, 3.00 ± 0.93 vs. CSD group,4.14 ± 1.43; $P = 0.002$) and 3 (no-CSD group,1.73 ± 0.94 vs. CSD group, 2.48 ± 1.08; $P = 0.013$).

3.3. Postoperative incision-related complications

There were no significant differences in postoperative incision-related complications between the two groups ($P > 0.05$). Three patients (3/22) in the no-CSD group and five patients (5/27) in the CSD group suffered superficial wound infections that were completely improved by effective antibiotics. Two patients (2/22) in the no-CSD group and three patients (3/27) in the CSD group developed a hematoma, which was absorbed after one week of local physiotherapy. All specific data on incision-related complications are summarized in Table 3.

TABLE 3 Detailed presentation of postoperative incision-related complications between the two groups.

Variable	No-drain Group ($n = 22$)	Drain Group ($n = 27$)	P value
Wound infections, *n* (%)			
Superficial infections	3 (13.64)	5 (18.52)	0.715
Deep infections	0 (0.00)	0 (0.00)	1.000
Wound dehiscence, *n* (%)	0 (0.00)	0 (0.00)	1.000
Hematoma, *n* (%)	2 (9.09)	3 (11.11)	0.816
Nonunion, *n* (%)	0 (0.00)	0 (0.00)	1.000

4. Discussion

To our knowledge, our study is the first to evaluate whether using CSD has an impact on the clinical outcome of acetabular fractures treated by a modified Stoppa approach. Previous studies have suggested that CSD could be used as a preventive treatment to decrease the likelihood of surgical site infection and incision-related complications in high-risk patients after orthopedic surgery (10, 19). However, according to our study results, compared to the patients in the no-CSD group, the patients with CSD for acetabular fractures repaired by a modified Stoppa approach were associated with a higher risk of postoperative blood transfusion and pain, with no impact on clinical outcomes and incision-related complications.

Acetabular fracture is one of the most difficult fractures to manage in orthopedic surgery. An ideal surgical approach for acetabular fractures is invaluable. It not only facilitates good exposure of the surgical field and effective reduction of the fracture but also causes as few complications as possible (2). The modified Stoppa approach is only appropriate in specific surgical indications and does not often allow for posterior column access if needed. This approach has many advantages, including large areas of visualization, less chance of damaging major nerves and vessels, short operation time, and less trauma (4, 20).

Traditionally, CSD has been successfully used in the management of acute and chronic open wounds to decrease the incidence of hematomas and infection by reducing the accumulation of blood and exudate in the incision cavity (10, 21, 22). In recent years, researchers have tried to apply CSD to closed incisions for acetabular fractures to prevent surgical site infection and wound complications after surgery (19). A retrospective study by Reddix et al. (23) showed that the use of CSD in patients with acetabular fracture may significantly reduce the incidence of deep infections. Although certain high-risk patients with acetabular fractures, such as obese patients, may benefit from treatment with CSD, the use of CSD remains

controversial. For example, the results published by Boissonneault et al. (24) show that, in their study, the use of CSD after the surgical fixation of acetabular fractures *via* the Kocher–Langenbeck approach significantly increased postoperative blood transfusion rates and days in hospital, but wound complications and incision infection rates did not differ.

Similarly, in the current study, the patients in the CSD group showed higher postoperative transfusion volumes (259.25 ml vs. 127.27 ml, $P = 0.034$) and transfusion rates (55.55% vs. 27.27%, $P = 0.027$) than those in the no-CSD group. Some scholars believe that 24–48 h after surgery is the stage of maximum bleeding and seepage of surgical sites (25). Negative pressure suction caused the exudate to continue to drain outside the body and disrupted the self-coagulation mechanism, which were the main reasons for the increase in postoperative blood transfusion (25). In fact, prophylactic CSD after acetabular fractures remains controversial. The use of CSD is almost always determined by the surgeon after surgery based on the quality of intraoperative hemostasis, magnitude of the surgical procedure, and experience (17, 26).

Several authors have reported that the advantages of using CSD after acetabular fracture surgery were controlling postoperative wound drainage and preventing local accumulation of hematomas (27). However, Kim et al. (28) found that routine use of CSD not only failed to prevent or reduce postoperative morbidities but also may have led to prolonged postoperative pain. Some published studies confirmed that the application of CSD may produce undesired results, such as an increased risk of infection and pain and an increased length of hospital stay after surgery. In addition, some studies suggested that compared with the CSD group, the VAS scores of the patients in the no-CSD group decreased by 50%, especially on postoperative Day 2 (26).

In our study, we found that there was no increase in the frequency of incision-related complications in the no-CSD group. A total of three patients (11.11%) developed hematomas and five (18.52%) developed superficial infections in the CSD group, which were no significant difference from those in the no-CSD group. Theoretically, the use of CSD is beneficial to reduce the incidence of pain and fever. However, our findings were the opposite, with the patients in the CSD group having higher VAS scores on postoperative Day 1 (CSD group, 4.14 ± 1.43 vs. no-CSD group, 3.00 ± 0.93; $P = 0.002$) and 3 (CSD group, 2.48 ± 1.08 vs. no-CSD group, 1.73 ± 0.94; $P = 0.013$) and higher temperatures on postoperative Day 2 (CSD group, 37.34 ± 0.69°C vs. no-CSD group, 36.97 ± 0.51°C; $P = 0.035$) than the patients in the no-CSD group. We believed that the drain itself, similar to a foreign body, increased discomfort and anxiety. In addition, active pulling and removal can also increase patient pain, and the absorption of residual exudate in the cavity after removal of the drain can cause fever.

This study has several potential limitations, including the retrospective design with the associated bias. The small sample size from a single institution was also a main limitation. In addition, the retrospective evaluation of intra and postoperative blood loss from medical records may lead to concerns about the reliability of this study. We only compared and analyzed a few perioperative laboratory indicators, while other indicators, such as white blood cell count and platelet count, were not addressed. Furthermore, we only compared the placement of drains after treating acetabular fractures *via* a modified Stoppa approach and did not include other approaches or the number of drains. Finally, although it is an important evaluation indicator in the perioperative period of hip fracture, the incidence of deep vein thrombosis was not included due to incomplete data. We will conduct further research in the future.

5. Conclusions

It is unnecessary to use CSD routinely after treating acetabular fractures *via* a modified Stoppa approach, because the application of CSD will not effectively reduce the incidence of postoperative incision-related complications and will increase the risk of increased postoperative blood transfusion rate and pain.

Data availability statement

The original contributions presented in the study are included in the article/Supplementary Material, further inquiries can be directed to the corresponding author/s.

Author contributions

LJ and ZW: interpreted the data and wrote the manuscript; KZ and XL: collected and analyzed the data; WC and YZ: revised the manuscript; ZH: designed and revised the final manuscript. All authors contributed to the article and approved the submitted version.

Funding

This study was supported by the Natural Science Foundation of Hebei (grant number: H2020206193).

Conflict of interest

The authors declare that the research was conducted in the absence of any commercial or financial relationships that could be construed as a potential conflict of interest.

Publisher's note

All claims expressed in this article are solely those of the authors and do not necessarily represent those of their affiliated organizations, or those of the publisher, the editors and the reviewers. Any product that may be evaluated in this article, or claim that may be made by its manufacturer, is not guaranteed or endorsed by the publisher.

References

1. Laird A, Keating JF. Acetabular fractures: a 16-year prospective epidemiological study. *J Bone Joint Surg Br*. (2005) 87(7):969–73. doi: 10.1302/0301-620X.87B7.16017

2. Meena S, Sharma PK, Mittal S, Sharma J, Chowdhury B. Modified stoppa approach versus ilioinguinal approach for anterior acetabular fractures; A systematic review and meta-analysis. *Bull Emerg Trauma*. (2017) 5(1):6–12.

3. Matta JM, Merritt PO. Displaced acetabular fractures. *Clin Orthop Relat Res*. (1988) (230):83–97.

4. Kilinc CY, Acan AE, Gultac E, Kilinc RM, Hapa O, Aydogan NH. Treatment results for acetabulum fractures using the modified stoppa approach. *Acta Orthop Traumatol Turc*. (2019) 53(1):6–14. doi: 10.1016/j.aott.2018.11.003

5. Bray TJ, Esser M, Fulkerson L. Osteotomy of the trochanter in open reduction and internal fixation of acetabular fractures. *J Bone Joint Surg Am*. (1987) 69 (5):711–7. doi: 10.2106/00004623-198769050-00012

6. Kloen P, Siebenrock KA, Ganz R. Modification of the ilioinguinal approach. *J Orthop Trauma*. (2002) 16(8):586–93. doi: 10.1097/00005131-200209000-00008

7. Cole JD, Bolhofner BR. Acetabular fracture fixation via a modified stoppa limited intrapelvic approach. Description of operative technique and preliminary treatment results. *Clin Orthop Relat Res*. (1994) 305:112–23. doi: 10.1097/00003086-199408000-00015

8. Zou R, Wu M, Guan J, Xiao Y, Chen X. Clinical results of acetabular fracture via the pararectus versus ilioinguinal approach. *Orthop Surg*. (2021) 13(4):1191–5. doi: 10.1111/os.12970

9. Al Adawy AS, Aziz AHA, El Sherief FA, Mahmoud WS, Mabrook M, Hassan YE. Modified stoppa as an alternative surgical approach for fixation of anterior fracture acetabulum: a randomized control clinical trial. *J Orthop Surg Res*. (2020) 15(1):154. doi: 10.1186/s13018-020-01660-3

10. Crist BD, Oladeji LO, Khazzam M, Della Rocca GJ, Murtha YM, Stannard JP. Role of acute negative pressure wound therapy over primarily closed surgical incisions in acetabular fracture ORIF: a prospective randomized trial. *Injury*. (2017) 48(7):1518–21. doi: 10.1016/j.injury.2017.04.055

11. Zhang JZ, Zhao K, Li JY, Meng HY, Zhu YB, Zhang YZ. Prophylactic closed suction drainage is irrelevant to accelerated rehabilitation after open reduction and internal fixation for closed distal femur fractures. *Orthop Surg*. (2020) 12 (6):1768–75. doi: 10.1111/os.12812

12. Parker MJ, Livingstone V, Clifton R, McKee A. Closed suction surgical wound drainage after orthopaedic surgery. *Cochrane Database Syst Rev*. (2007) 2007(3): Cd001825.

13. Sankar B, Ray P, Rai J. Suction drain tip culture in orthopaedic surgery: a prospective study of 214 clean operations. *Int Orthop*. (2004) 28(5):311–4. doi: 10.1007/s00264-004-0561-2

14. Gurusamy KS, Allen VB. Wound drains after incisional hernia repair. *Cochrane Database Syst Rev*. (2013) (12):Cd005570. doi: 10.1002/14651858.CD005570.pub4

15. Arbadoro P, Marmorale C, Recanatini C, Mazzarini G, Pellegrini I, D'Errico MM, et al. May the drain be a way in for microbes in surgical infections? *Am J Infect Control*. (2016) 44(3):283–8. doi: 10.1016/j.ajic.2015.10.012

16. Magnussen RA, Tressler MA, Obremskey WT, Kregor PJ. Predicting blood loss in isolated pelvic and acetabular high-energy trauma. *J Orthop Trauma*. (2007) 21 (9):603–7. doi: 10.1097/BOT.0b013e3181599c27

17. Andrew Glennie R, Dea N, Street JT. Dressings and drains in posterior spine surgery and their effect on wound complications. *J Clin Neurosci*. (2015) 22 (7):1081–7. doi: 10.1016/j.jocn.2015.01.009

18. Zhang R, Yin Y, Li A, Wang Z, Hou Z, Zhuang Y, et al. Three-column classification for acetabular fractures: introduction and reproducibility assessment. *J Bone Joint SurgAm*. (2019) 101(22):2015–25. doi: 10.2106/JBJS.19.00284

19. Stannard JP, Volgas DA, McGwin G, Rena LS, William O, Thomas M, et al. Incisional negative pressure wound therapy after high-risk lower extremity fractures. *J Orthop Trauma*. (2012) 26(1):37–42. doi: 10.1097/BOT.0b013e318216b1e5

20. Kim HY, Yang DS, Park CK, Choy WS. Modified stoppa approach for surgical treatment of acetabular fracture. *Clin Orthop Surg*. (2015) 7(1):29–38. doi: 10.4055/cios.2015.7.1.29

21. Suzuki T, Minehara A, Matsuura T, Kawamura T, Soma K. Negative-pressure wound therapy over surgically closed wounds in open fractures. *J Orthop Surg*. (2014) 22(1):30–4. doi: 10.1177/230949901402200109

22. Morykwas MJ, Argenta LC, Shelton-Brown EI, McGuirt W. Vacuum-assisted closure: a new method for wound control and treatment: animal studies and basic foundation. *Ann Plast Surg*. (1997) 38(6):553–62. doi: 10.1097/00000637-199706000-00001

23. Reddix RN, Leng XI Jr, Woodall J, Jackson B, Dedmond B, Webb LX. The effect of incisional negative pressure therapy on wound complications after acetabular fracture surgery. *J Surg Orthop Adv*. (2010) 19(2):91–7.

24. Boissonneault AR, Schenker M, Staley C, Roorbach M, Erwood AA, Grabel ZJ, et al. Impact of closed suction drainage after surgical fixation of acetabular fractures. *Arch Orthop Trauma Surg*. (2019) 139(7):907–12. doi: 10.1007/s00402-019-03110-0

25. Reddix RN, Tyler HK Jr, Kulp B, Webb LX. Incisional vacuum-assisted wound closure in morbidly obese patients undergoing acetabular fracture surgery. *Am J Orthop*. (2009) 38(9):446–9.

26. Schietroma M, Pessia B, Bianchi Z, De Vita F, Carlei F, Guadagni S, et al. Thyroid surgery: to drain or not to drain, that is the problem—a randomized clinical trial. *ORL J Otorhinolaryngol Relat Spec*. (2017) 79(4):202–11. doi: 10.1159/000464137

27. Sen O, Kizilkilic O, Aydin MV, Yalcin O, Erdogan B, Cekinmez M, et al. The role of closed-suction drainage in preventing epidural fibrosis and its correlation with a new grading system of epidural fibrosis on the basis of MRI. *Eur Spine J*. (2005) 14(4):409–14. doi: 10.1007/s00586-004-0801-6

28. Kim EY, Lee SH, Lee JS, Yoon YC, Park SK, Choi HJ, et al. Is routine drain insertion after laparoscopic cholecystectomy for acute cholecystitis beneficial? A multicenter, prospective randomized controlled trial. *J Hepatobiliary Pancreat Sci*. (2015) 22(7):551–7. doi: 10.1002/jhbp.244

frontiers | Frontiers in Surgery

TYPE Brief Research Report
PUBLISHED 21 March 2023
DOI 10.3389/fsurg.2023.1123375

Check for updates

OPEN ACCESS

EDITED BY
Paphon Sa-ngasoongsong,
Mahidol University, Thailand

REVIEWED BY
Fatih Zor,
Wake Forest University, United States
Sanja Lepić,
Institute of Hygiene, Serbia

*CORRESPONDENCE
Harvey Chim
✉ harveychim@yahoo.com

SPECIALTY SECTION
This article was submitted to Orthopedic Surgery, a section of the journal Frontiers in Surgery

RECEIVED 14 December 2022
ACCEPTED 06 March 2023
PUBLISHED 21 March 2023

CITATION
Hones KM, Nichols DS, Barker H, Cox E, Hones JA and Chim H (2023) Outcomes following use of VersaWrap nerve protector in treatment of patients with recurrent compressive neuropathies.
Front. Surg. 10:1123375.
doi: 10.3389/fsurg.2023.1123375

COPYRIGHT
© 2023 Hones, Nichols, Barker, Cox, Hones and Chim. This is an open-access article distributed under the terms of the Creative Commons Attribution License (CC BY). The use, distribution or reproduction in other forums is permitted, provided the original author(s) and the copyright owner(s) are credited and that the original publication in this journal is cited, in accordance with accepted academic practice. No use, distribution or reproduction is permitted which does not comply with these terms.

Outcomes following use of VersaWrap nerve protector in treatment of patients with recurrent compressive neuropathies

Keegan M. Hones[1], David Spencer Nichols[1], Haley Barker[2], Elizabeth Cox[1], Jaime A. Hones[2] and Harvey Chim[2,3]*

[1]University of Florida Collage of Medicine, Gainesville, FL, United States, [2]Department of Plastic and Reconstructive Surgery, University of Florida, Gainesville, FL, United States, [3]Department of Neurosurgery, University of Florida, Gainesville, FL, United States

Epineural scarring following previous carpal or cubital tunnel release can lead to pain and permanent dysfunction. To prevent this cascade, nerve wraps are an option. The purpose of this study was to evaluate outcomes following use of VersaWrap nerve protector during surgical decompression and neurolysis in patients with recurrent compressive neuropathies in the upper extremity. Twenty patients comprised the patient cohort, with a mean postoperative follow-up time of 139 days (range: 42–356 days). There were 13 females and 7 males, with a mean age of 43.4 years. Fourteen surgeries were performed for revision cubital tunnel, 5 for revision carpal tunnel, and 1 for revision radial tunnel syndrome. Average duration of symptoms prior to revision surgery with VersaWrap was 2 years (range 9 months to 6 years). Postoperatively, the mean DASH score was 57.7 and VAS 3.1. Mean s2PD median distribution was 7.3, s2PD ulnar distribution 8.9, m2PD median distribution 6.9 and m2PD ulnar distribution 7.3. All patients had subjective improvement of symptoms and were satisfied with their result. No patients in our cohort required further revisional surgery. In conclusion, the use of VersaWrap as a nerve protector following revision surgery for recurrent compressive neuropathies in the upper extremity was safe and effective.
Level of Evidence: IV; retrospective case series

KEYWORDS
nerve wrap, nerve protector, peripheral nerve, carpal tunnel, cubital tunnel, radial tunnel

Introduction

Epineural scarring following previous carpal or cubital tunnel release can result in symptomatic recurrence, with pain, numbness, and weakness. Recurrent formation of scar tissue around a peripheral nerve is a particular issue in revision surgery. To reduce scarring around the nerve, many surgeons use nerve wraps or conduits. The efficacy of nerve protectors for treatment of different nerve pathologies has been demonstrated in both animal and human models (1–7). Absorbable nerve wraps are favored, with the benefit conferred by these implants likely related to the separation of soft tissue and nerve, allowing gliding and thus preventing tethering, and providing an optimized environment for nerve healing. However, disadvantages of some commercially available wraps or conduits include unfavorable handling characteristics, stiffness, and added bulk which can result in nerve constriction. In some cases where a nerve wrap is sutured in

place around a peripheral nerve, postoperative swelling can result in a localized constriction point which results in persistent neuropathic pain and resultant disability.

VersaWrap (Alafair Biosciences, Austin, Texas, USA) is a bioresorbable plant-based hydrogel wrap that was recently approved in the USA for use as a nerve wrap. Originally described for use as a wrap following repair of tendon injuries, VersaWrap was subsequently also used for treatment of peripheral nerve injuries, particularly in cases where scarring was a concern. VersaWrap consists of an ultrathin hydrogel sheet composed of hyaluronic acid and alginate, which provides a pliable wrap and non-constricting interface for tendon and peripheral nerves (8). Some advantages of VersaWrap favoring its use as a nerve wrap include its ultrathin conformable nature, smooth hydrophilic surface facilitating nerve gliding, ability to be placed without sutures, lack of polarity and transparent appearance which allows visualization of the underlying wrapped nerve. In addition, Versawrap can be tailored to fit any diameter peripheral nerve. VersaWrap is bioresorbed *via* hydrolysis and metabolic activity, unlike collagen-based implants that are remodeled and thus result in added bulk over time at the nerve repair site. Finally, as VersaWrap has no animal-derived or human tissue component, there is decreased concern for immune response and disease transmission.

Here we describe the first published experience, to our knowledge, utilising VersaWrap as a peripheral nerve wrap. In our series, VersaWrap was used primarily as a nerve protector in recurrent compressive neuropathies in the upper extremity, to reduce postoperative scarring. This remains of particular relevance given that reported rates of symptom recurrence after primary carpal tunnel surgery range from 1 to 31% (6, 9, 10) and 2.4% to 25% after primary cubital tunnel surgery (11, 12). Revision peripheral nerve surgeries involve significant scar tissue, and present significant, unique challenges. In this study, we retrospectively reviewed a series of patients in whom VersaWrap was utilized for revision upper extremity peripheral nerve decompression and neurolysis, with a focus on analysis of clinical outcomes.

Materials and methods

A single institution retrospective review was performed to identify all patients who received VersaWrap as a nerve protector intraoperatively for recurrent compressive neuropathies of the upper extremity. The study was approved by our institutional review board with a unique identification number of IRB202001859. All procedures were in accordance with the ethical standards of the responsible committee on human experimentation, the Helsinki Declaration of 1964, and later versions. Informed consent was obtained from all patients for their participation in the study. From February 2020 to June 2022, a total of 41 patients had VersaWrap used following surgical treatment of recurrent carpal tunnel syndrome, cubital tunnel syndrome or other unusual compressive neuropathies. Intraoperative use of VersaWrap nerve protector is illustrated through representative examples in **Figures 1**, **2**. Twenty patients agreed to return for in-person postoperative assessment, and this comprised the patient cohort for this study. All patients had at least 6 weeks postoperative follow-up.

All surgeries were performed by the senior author. Demographic data collected included age at surgery, gender, body mass index (BMI), history of Diabetes Mellitus and smoking status. Outcome measures included static and moving two-point discrimination (s2PD and m2PD), range of motion (ROM), and power of affected muscles as assessed using the Medical Research Council (MRC) grading scale. Standardized outcome scores including the Disabilities of the Arm, Shoulder, and Hand (DASH) questionnaire and Visual Analog Scale (VAS) were assessed postoperatively. The DASH score was chosen as this is a commonly used patient reported outcome measure in hand surgery.

Results

We evaluated 20 patients treated for upper extremity peripheral nerve injuries who had VersaWrap utilized intraoperatively. The

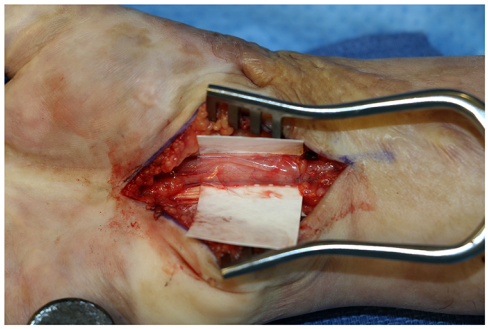

FIGURE 1
Versawrap has been placed around the median nerve following revision carpal tunnel release. The pliable and transparent nature of VersaWrap facilitates placement as a circumferential nerve wrap.

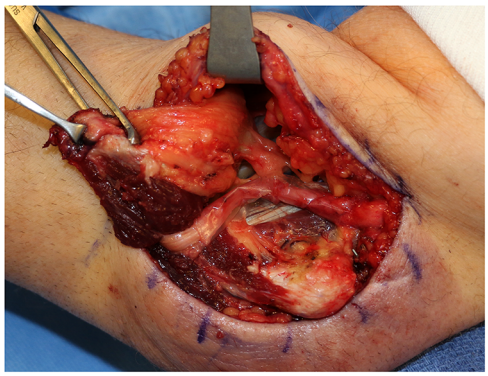

FIGURE 2
Versawrap has been placed around the ulnar nerve following revision cubital tunnel release, in preparation for submuscular transposition. The pliable and transparent nature of VersaWrap facilitates placement as a circumferential nerve wrap.

10.3389/fsurg.2023.1123375

average age of patients in our series was 43.4 years (range: 21–69). There were 13 females and 7 males. Mean follow-up time was 139 days (range: 42–356 days). All had previous surgery to the surgical site. Average duration of symptoms prior to revision surgery with VersaWrap placement was 2 years (range 9 months to 6 years). Of the 20 included, 14 surgeries were for revision cubital tunnel, 5 for revision carpal tunnel, and 1 for revision radial tunnel syndrome. Three patients were smokers, 3 former smokers, and 14 non-smokers. One patient in the cohort had diabetes mellitus. The dominant extremity was the affected side in 14/20. Mean BMI was 26.6. There were no intraoperative complications in the cohort. At the time of follow-up assessment, all patients were satisfied with the outcome and there were no further revision surgeries required.

The mean DASH score for the revision cubital tunnel group was 54.0 and mean VAS 2.7. For the revision carpal tunnel group, the mean DASH was 66.2 and mean VAS 4.2. For the revision radial tunnel patient DASH was 68.3 and VAS 3. The total mean DASH score for the cohort was 57.7 and total mean VAS was 3.1. For the entire cohort, mean s2PD in the median nerve distribution was 7.3, mean s2PD in the ulnar nerve distribution was 8.9. Mean m2PD in the median nerve distribution was 6.9, mean m2PD in the ulnar nerve distribution was 7.3.

In the revision cubital tunnel group, 14/14 patients achieved 75 degrees of wrist flexion, 13/14 achieved 70 degrees of wrist extension, 12/14 achieved full finger abduction and adduction, and 13/14 achieved full interphalangeal joint motion. Mean MRC grade for thumb opposition was 4.8, finger adduction 4.3, finger flexion 4.7, and wrist flexion 4.9. In the revision carpal tunnel group, all patients achieved 75 degrees of wrist flexion, 4/5 achieved 70 degrees of wrist extension, 5/5 achieved full finger abduction and adduction, and 3/5 achieved full interphalangeal joint motion of digits 1–5. Mean MRC grade for thumb opposition was 4.2, finger adduction 4.6, finger flexion 4.2, and wrist flexion 4.8.

For the radial tunnel patient, range of motion achieved was 75 degrees of wrist flexion, 70 degrees of wrist extension, full finger abduction and adduction, but full interphalangeal joint motion was not achieved. MRC grading for thumb opposition was 5, finger adduction 5, finger flexion 5, and wrist flexion 5. In addition, this patient presented preoperatively with weakness of finger extensors, MRC grade 2. Postoperatively, finger extension strength improved to MRC grade 3. These results are summarized in Table 1.

TABLE 1 Outcome measures in patient cohort.

	Achieved full wrist flexion	Achieved full wrist extension	Achieved full finger abduction and adduction	Achieved full interphalangeal joint motion of digits 1–5	Mean thumb opposition (MRC grade)	Mean finger adduction (MRC grade)	Mean finger flexion (MRC grade)	Mean wrist flexion (MRC grade)	DASH	VAS
Cubital tunnel	14/14	13/14	12/14	13/14	4.8	4.3	4.7	4.9	54.0	2.7
Carpal tunnel	5/5	4/5	5/5	3/5	4.2	4.6	4.2	4.8	66.2	4.2
Radial tunnel	1/1	1/1	1/1	0/1	5	5	5	5	68.3	3
Total	20/20	18/20	18/20	16/20	4.7	4.5	4.5	4.9	57.7	3.1

MRC, medical research council; DASH, disabilities of the arm, shoulder, and hand; VAS, visual analog score.

Discussion

Compressive neuropathies of the upper extremity are very common, with over 400,000 carpal tunnel releases (13, 14) and over 15,000 cubital tunnel releases (15) performed annually. Despite overall good results, some patients continue to have pain, altered sensation or weakness after surgery or experience delayed recurrence of symptoms. Revision surgery may become necessary to alleviate these symptoms, but these surgeries are not generally

as straightforward as the initial ones. Scar tissue and altered anatomy present unique challenges for the surgeon. Additionally, epineural scarring is likely more of a risk following a revision surgery. Nerve wraps or conduits may provide specific benefit in these instances. In this paper we present the first published experience, to our knowledge, describing the use of VersaWrap as a nerve protector. In our series, VersaWrap was used for patients with recurrent compressive neuropathies in the upper extremity requiring surgical intervention.

The use of nerve wraps in peripheral nerve surgery is well-established (2, 4, 5). However, as one animal study by Nicolas et al. demonstrated, the potential for over-tightening nerve wraps has detrimental effects (16). Spielman et al. reported resolution of symptoms and improved VAS scores in 30 patients with recurrent or persistent carpal tunnel syndrome who had surgery that involved the use of a nerve wrap (17). Additionally, Thakkar et al. in a systematic review reported improvements in outcomes after revision compressive nerve surgery that included the use of a nerve wrap (18). Other techniques for preventing scarring or recurrence in revision surgery may include the use of local flaps for revision carpal tunnel release of subcutaneous or submuscular transposition for revision cubital tunnel release.

Overall, while this study provides new insights, it does have limitations. This was a retrospectively collected series, with shortcomings inherent to its design. These include a smaller sample size and a single institution experience which may limit generalizability of findings. In addition, as only 20 patients agreed to return postoperatively for data collection, this introduces a source of bias. Finally, we were not able to obtain preoperative DASH and VAS scores due to resource limitations in our clinic. Nevertheless, our findings provide evidence for use of VersaWrap as a safe and effective nerve protector for revision surgery targeted at compressive neuropathies. Hopefully, this data will provide a basis for larger studies and randomized controlled trials.

In conclusion, VersaWrap is safe and effective when used as a nerve wrap. In this study, we focused on patients undergoing revision surgery for compressive neuropathies of the upper extremity. Notably, all patients in this cohort had subjective and objective improvement of symptoms, postoperative satisfaction with results and did not require revisional surgery in the post-operative period examined during this investigation.

Data availability statement

The raw data supporting the conclusions of this article will be made available by the authors, without undue reservation.

Ethics statement

The studies involving human participants were reviewed and approved by University of Florida IRB-01. The patients/participants provided their written informed consent to participate in this study.

Author contributions

KH, DN, EC, HB, JH: were involved in data procurement and management. KH and HC: were the primary manuscript writers, with editing and contribution from all others. HC: conceived the idea of the study, oversaw the study, and was the performing surgeon. All authors contributed to the article and approved the submitted version.

Conflict of interest

The authors declare that the research was conducted in the absence of any commercial or financial relationships that could be construed as a potential conflict of interest.

Publisher's note

All claims expressed in this article are solely those of the authors and do not necessarily represent those of their affiliated organizations, or those of the publisher, the editors and the reviewers. Any product that may be evaluated in this article, or claim that may be made by its manufacturer, is not guaranteed or endorsed by the publisher.

References

1. Kim PD, Hayes A, Amin F, Akelina Y, Hays AP, Rosenwasser MP. Collagen nerve protector in rat sciatic nerve repair: a morphometric and histological analysis: collagen nerve protector. *Microsurgery*. (2010) 30:392–6. doi: 10.1002/micr.20760

2. Suryavanshi JR, Cox C, Osemwengie BO, Jones HB, MacKay BJ. Sutureless repair of a partially transected median nerve using tisseel glue and axoguard nerve protector: a case report. *Microsurgery*. (2020) 40:896–900. doi: 10.1002/micr.30593

3. Kokkalis ST, Mavrogenis AF, Vottis C, Papatheodorou L, Papagelopoulos PJ, Soucacos PN, et al. Median nerve biodegradable wrapping : clinical outcome of 10 patients. *Acta Orthop Belg*. (2016) 82:351–7. PMID: 27682299

4. Papatheodorou LK, Williams BG, Sotereanos DG. Preliminary results of recurrent cubital tunnel syndrome treated with neurolysis and porcine extracellular matrix nerve wrap. *J Hand Surg*. (2015) 40:987–92. doi: 10.1016/j.jhsa.2015.02.031

5. Imran R, George S, Jose R, Shirley C, Power DM. Clinical outcomes following neurolysis and porcine collagen extracellular matrix wrapping of scarred nerves in revision carpal tunnel decompression. *J Plast Reconstr Aesthet Surg*. (2022) 75:2802–8. doi: 10.1016/j.bjps.2022.04.010

6. Soltani AM, Allan BJ, Best MJ, Mir HS, Panthaki ZJ. Revision decompression and collagen nerve wrap for recurrent and persistent compression neuropathies of the upper extremity. *Ann Plast Surg*. (2014) 72:572–8. doi: 10.1097/SAP.0b013e3182956475

7. Wolfe EM, Mathis SA, Ovadia SA, Panthaki ZJ. Comparison of collagen and human amniotic membrane nerve wraps and conduits for peripheral nerve repair in preclinical models: a systematic review of the literature. *J Reconstr Microsurg*. (2022). doi: 10.1055/s-0041-1732432. [Epub ahead of print]

8. ABOUT VERSAWRAP. Alafair Biosciences. Austin, Texas, United States. Available at: http://www.alafairbiosciences.com/vtp

9. Abzug JM, Jacoby SM, Osterman AL. Surgical options for recalcitrant carpal tunnel syndrome with perineural fibrosis. *Hand*. (2012) 7:23–9. doi: 10.1007/s11552-012-9391-7

10. Craft RO, Duncan SFM, Smith AA. Management of recurrent carpal tunnel syndrome with microneurolysis and the hypothenar fat pad flap. *HAND*. (2007) 2:85–9. doi: 10.1007/s11552-007-9025-7

11. Bartels DW, Marigi E, Sperling JW, Sanchez-Sotelo J. Revision reverse shoulder arthroplasty for anatomical glenoid component loosening was not universally successful: a detailed analysis of 127 consecutive shoulders. *J Bone Jt Surg*. (2021) 103:879–86. doi: 10.2106/JBJS.20.00555

12. Lowe JB, Mackinnon SE. Management of secondary cubital tunnel syndrome: plast. *Reconstr Surg*. (2004) 113:e1–e16. doi: 10.1097/01.PRS.0000097287.10955.CC

13. Fnais N, Gomes T, Mahoney J, Alissa S, Mamdani M. Temporal trend of carpal tunnel release surgery: a population-based time series analysis. *PLoS One*. (2014) 9: e97499. doi: 10.1371/journal.pone.0097499

14. Palmer DH, Hanrahan LP. Social and economic costs of carpal tunnel surgery. *Instr Course Lect*. (1995) 44:167–72. PMID: 7797856

15. Osei DA, Groves AP, Bommarito K, Ray WZ. Cubital tunnel syndrome: incidence and demographics in a national administrative database. *Neurosurgery*. (2017) 80:417–20. doi: 10.1093/neuros/nyw061

16. Nicolas CF, Corvi JJ, Zheng Y, Park KH, Akelina Y, Engemann A, et al. Resorbable nerve wraps: can they be overtightened? *J Reconstr Microsurg*. (2022) 38 (9):694–702. doi: 10.1055/s-0042-1744274

17. Spielman AF, Sankaranarayanan S, Skowronski P, Lessard A-S, Panthaki Z. Recurrent and persistent carpal tunnel syndrome: "triple-therapy approach". *J Orthop*. (2020) 22:431–5. doi: 10.1016/j.jor.2020.09.003

18. Thakker A, Sharma SC, Hussain NM, Devani P, Lahiri A. Nerve wrapping for recurrent compression neuropathy: a systematic review. *J Plast Reconstr Aesthet Surg*. (2021) 74:549–59. doi: 10.1016/j.bjps.2020.10.085

frontiers | Frontiers in Surgery

TYPE Original Research
PUBLISHED 24 March 2023
DOI 10.3389/fsurg.2023.1134355

Check for updates

OPEN ACCESS

EDITED BY
Jaimo Ahn,
University of Michigan, United States

REVIEWED BY
Marco Sapienza,
University of Catania, Italy
Anirejuoritse Bafor,
Nationwide Children's Hospital, United States

*CORRESPONDENCE
Chavarat Jarungvittayakon
✉ j_chavarat@hotmail.com

SPECIALTY SECTION
This article was submitted to Orthopedic Surgery, a section of the journal Frontiers in Surgery

RECEIVED 30 December 2022
ACCEPTED 13 March 2023
PUBLISHED 24 March 2023

CITATION
Wongsak S, Jarungvittayakon C, Chulsomlee K, Jaovisidha S and Sa-ngasoongsong P (2023) Abductor muscle function after anterolateral approach in patients with unilateral end-stage hip osteoarthritis undergoing total hip arthroplasty: A prospective study.
Front. Surg. 10:1134355.
doi: 10.3389/fsurg.2023.1134355

COPYRIGHT
© 2023 Wongsak, Jarungvittayakon, Chulsomlee, Jaovisidha, Sa-ngasoongsong. This is an open-access article distributed under the terms of the Creative Commons Attribution License (CC BY). The use, distribution or reproduction in other forums is permitted, provided the original author(s) and the copyright owner(s) are credited and that the original publication in this journal is cited, in accordance with accepted academic practice. No use, distribution or reproduction is permitted which does not comply with these terms.

Abductor muscle function after anterolateral approach in patients with unilateral end-stage hip osteoarthritis undergoing total hip arthroplasty: A prospective study

Siwadol Wongsak[1], Chavarat Jarungvittayakon[1]*, Kulapat Chulsomlee[2,3], Suphaneewan Jaovisidha[2] and Paphon Sa-ngasoongsong[1]

[1]Department of Orthopedics, Faculty of Medicine Ramathibodi Hospital, Mahidol University, Bangkok, Thailand, [2]Department of Diagnostic and Therapeutic Radiology, Ramathibodi Hospital, Mahidol University, Bangkok, Thailand, [3]Chakri Naruebodindra Medical Institute, Faculty of Medicine Ramathibodi Hospital, Mahidol University, Bangkok, Thailand

Background: Total hip arthroplasty (THA) is a successful procedure for treating end-stage hip osteoarthritis (OA). Regarding the surgical approach for THA, the anterolateral (AL) approach, which requires anterior hemimyotomy of the gluteus medius muscle, has shown a long-term favorable outcome. However, to date, complete information related to hip abductor muscle outcomes after the AL approach is unavailable. This study therefore aimed to evaluate the postoperative outcome of patients who undergo THA using the AL approach in terms of hip abductor muscle recovery, pain, function, and muscle healing status.
Methods: Twenty patients diagnosed with unilateral end-stage hip OA underwent cementless THA with the AL approach. All patient procedures were performed by a single surgeon. Preoperative and postoperative data were collected at 2-week, 6-week, 3-month, and 6-month follow-up periods. Hip abductor muscle power was measured *via* handheld dynamometer. The healing of the musculotendinous repair was evaluated with magnetic resonance imaging at 9 months.
Results: After THA, hip abductor muscle power in the operated hip significantly increased as early as 3 months post-procedure when compared with the preoperative value ($p < 0.05$). The other parameters—including pain score, Harris hip score, and WOMAC score—significantly improved as early as 2 weeks post-operation ($p < 0.05$). In all patients, MRI scans showed good healing of the muscle repair site without a gap in the gluteus medius muscle. However, three patients (15%) had some fibrosis and tendon swelling at the repair site.
Conclusion: This study demonstrated that patients with end-stage hip OA could experience significantly improved hip abductor motor function as early as 3 months after undergoing THA with the AL approach. Moreover, despite patients experiencing anterior hemimyotomy of the gluteus medius muscle, no significant complications emerged at the muscle repair site in the AL approach.

KEYWORDS

total hip arthroplasty, hip abductor muscle power, anterolateral approach, gluteus medius muscle, hip osteoarthritis article type: original research article

1. Introduction

Total hip arthroplasty (THA) is one of the most successful procedures in orthopedic surgery (1). THA is an effective method in young and older patients who experienced pain and dysfunction from arthritic hip joints unrelieved by conservative treatment (2, 3). Generally, THA can be performed *via* a variety of surgical approaches, such as the anterolateral (AL), direct anterior (DA), and lateral and posterior approaches (4). Among those, the anterior approach (either AL or DA) has emerged as a preferred method for achieving successful early postoperative outcomes (5, 6).

Concerning the anterior approaches, the AL approach has many advantages, such as good exposure of the acetabulum, implant positioning, leg length correction, and decreased incidence of dislocation (7–10). However, the AL approach has a drawback: the need to perform anterior hemimyotomy of the gluteus medius for better exposure, which requires muscle repair at the end of the operation. This iatrogenic muscle injury results in a concern about postoperative hip abductor weakness and possible complications related to unhealed muscle repair as hip dislocation (11, 12). On the other hand, while the DA approach has recently become a popular minimally evasive approach over the past decade, related complications—such as periprosthetic fracture in the early learning curve (13, 14), high risk of wound complications in obese patients (15), and difficulty in the dysplastic hip (16)—have been frequently reported.

Yet to the best of our knowledge, only a few previous studies have reported on the postoperative hip abductor muscle outcome after using the AL approach (17, 18), and no data is available regarding the hip abductor muscle recovery, the prognosis of abnormal hip function (e.g., Trendelenburg gait), and the status of the gluteus medius muscle healing. Addressing that information gap, we aimed to help better understand the effect of the AL approach in patients with end-stage hip OA undergoing THA in terms of the clinical outcome and the postoperative change of abductor muscles. We therefore conducted a prospective study using patients with unilateral end-stage hip disease and performed THA using the AL approach. The goals were to evaluate the postoperative hip abductor muscle power, clinical outcomes, and continuity of abductor muscles using magnetic resonance imaging (MRI).

2. Materials and methods

This study was approved by the Ethical Clearance Committee on Human Rights Related to Research Involving Human Subjects, Faculty of Medicine Ramathibodi Hospital, Mahidol University (Protocol number: ID 10-58-09).

For the study, we recruited 20 patients diagnosed with unilateral end-stage hip OA from Ramathibodi Hospital, Thailand. The patients underwent cementless THA with the AL approach from January 2016 to December 2017. Inclusion criteria were patients diagnosed with end-stage hip OA and unilateral hip disease with positive Trendelenburg gait. Exclusion criteria were patients with a previous surgery, a previous hip joint dislocation, and neuromuscular weakness.

Patients completed a preoperative interview and questionnaire administered by one investigator; the data collected included age, sex, body mass index, pain score, range of motion, gait, abductor muscle power, Harris hip score, and WOMAC score.

After giving informed consent, all patients subsequently underwent an operation performed by a single surgeon who has used the AL approach in more than 1,000 cases (SW). All patient surgeries used cementless implants for both the femoral and acetabular components. The implant position was the preoperative template for achieving the anatomical position using the contralateral side as a reference. For all patients, the AL approach was performed *via* a longitudinal split of the tensor fascia latae and iliotibial band, reflecting anteriorly the anterior one-third of the gluteus medius and gluteus minimus (**Figures 1A,B**). The acetabular cup was set as 15 ± 10 degrees anteversion and 40 ± 10 degrees inclination according to the Lewinek's safe zone (19). After implantation, the musculotendinous flap was repaired in the anatomical position for both the gluteus medius and the gluteus minimus (**Figures 1C,D**).

All patients underwent the same rehabilitation protocol starting the day after surgery and then followed the same outpatient protocol. The physiotherapy protocol included gait training, abductor muscle strengthening exercise, and instructions on safe self-administered exercise protocols. Patients were assessed postoperatively at 2-week, 6-week, 3-month, and 6-month intervals. For each patient, we collected the following data at all intervals: pain score (VAS score), range of motion, gait, abductor muscle power, Harris hip score, and WOMAC score. Abductor muscle power was evaluated by a single evaluator based on the newton unit, as measured with the MicroFET 2 (12-0381W) digital handheld dynamometer.

An MRI was performed postoperatively for all patients at the 9-month interval to evaluate the degeneration of muscle and the continuity of muscle or musculotendinous junction, as described in previous studies (20, 21); all MRIs were performed by an experienced senior musculoskeletal radiologist (SJ). The continuity of the musculotendinous flaps was collected to evaluate the healing of the musculotendinous flap of the gluteus medius after the anterior hemimyotomy was performed and X was repaired intraoperatively (**Figure 2**).

All statistical analyses were calculated using MedCalc Statistical Software version 15.8 (MedCalc Software bvbv, Ostend, Belgium). A Kolmogorov–Smirnov test was used to determine the normality of the data. Continuous data were calculated as mean ± standard deviation, and categorical variables were presented as the number of specimens and percentages. To compare the outcomes between the preoperative value and postoperative follow-up visits, one-way repeated measures ANOVA with a post-hoc test and the chi-square test were used. A p-value of < 0.05 was considered statistically significant.

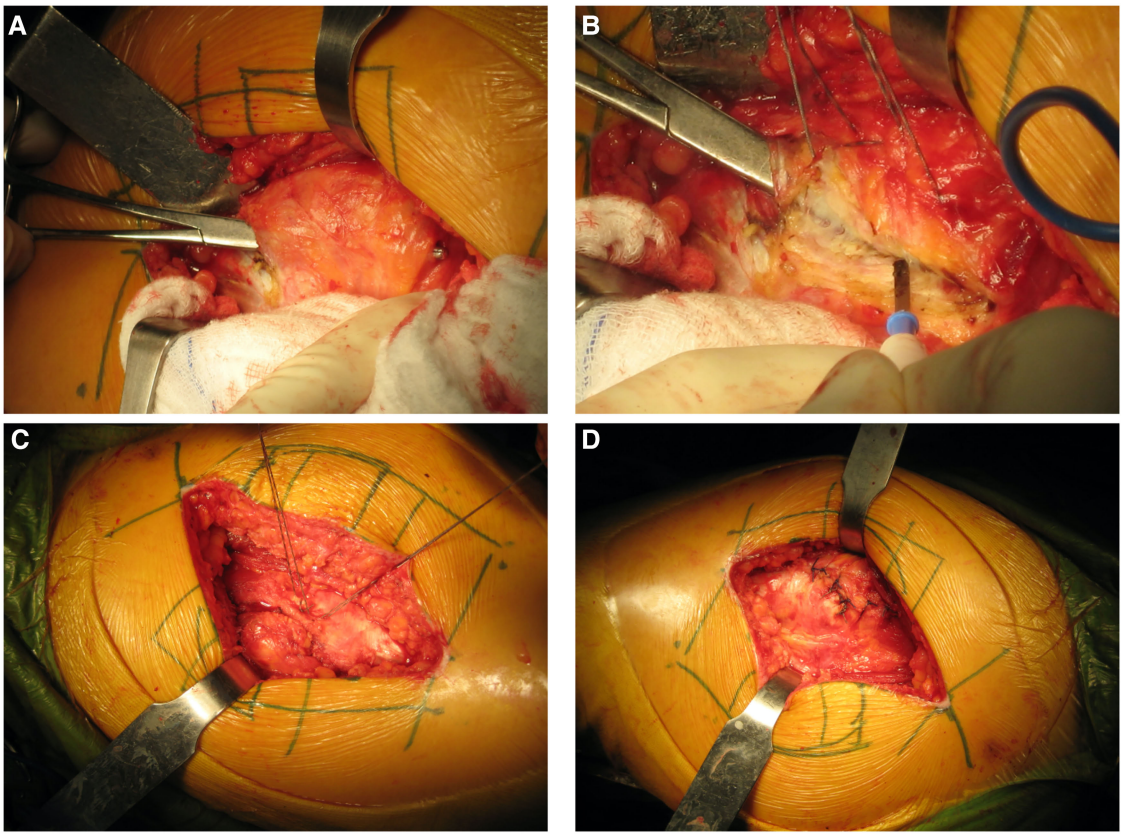

FIGURE 1
Surgical technique for the AL approach. Following splitting tensor fascia lata, the anterior one-third of the gluteus medius was identified (**A**) and cut (**B**). When the prosthesis was inserted and finally checked for stability, the musculotendinous flap of the gluteus medius and minimus were sutured (**C**) and anatomically repaired (**D**).

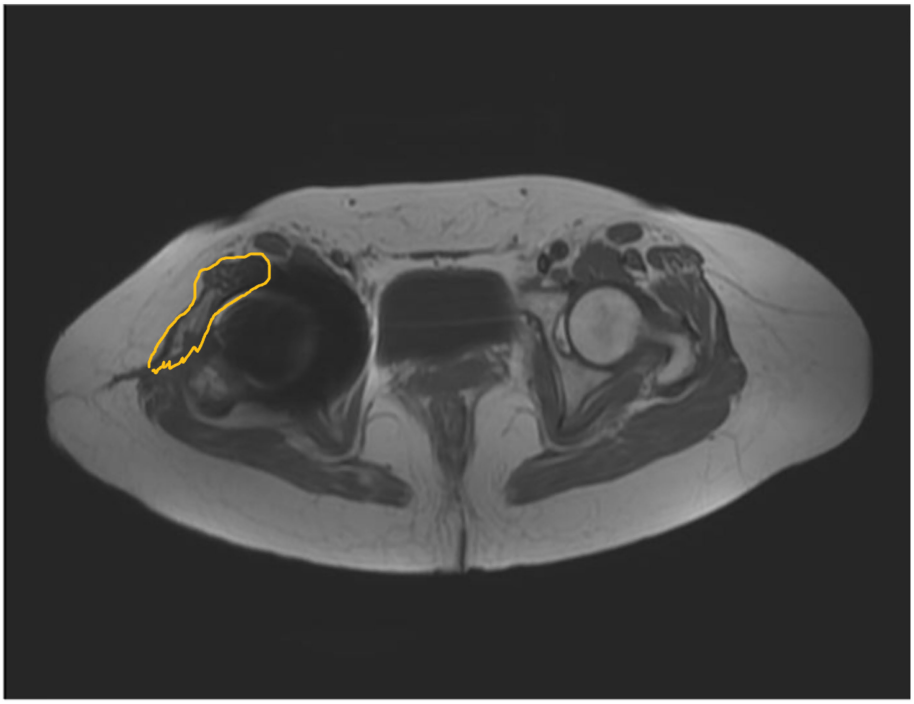

FIGURE 2
Continuity of the musculotendinous flap (yellow line) was evaluated by magnetic resonance imaging (MRI) at 9-month interval postoperatively.

3. Results

3.1. General characteristics and demographic data

A total of 20 patients diagnosed with unilateral hip disease were recruited in this study. Demographic data are presented in Table 1. The mean age of patients was 55.7 ± 15.1 years, and the mean body mass index (BMI) was 26.8 ± 4.4. Diagnostically, 12 patients (60%) had primary hip OA, 7 patients (35%) had avascular necrosis of the femoral head, and 1 patient (5%) had developmental dysplasia of the hip. All patients had a positive Trendelenburg sign (100%) with decreased hip abductor power and hip function. The mean hip abductor power and hip abductor recovery ratio were 96.3 ± 9.2 N and 50.7% ± 17.3%, respectively. The average operative time was 108 ± 14 min.

3.2. Postoperative changes in hip abductor muscle power and hip abductor recovery ratio, and postoperative MRI

Figure 3 displays the postoperative changes in hip abductor muscle power and the hip abductor strength ratio. Table 2 shows the mean difference of the hip abductor strength ratio between the preoperative and postoperative periods, and the number of patients with a positive Trendelenburg sign at each follow-up visit.

Following THA using the AL approach, a non-significant decrease occurred in both hip abductor muscle parameters at 2 weeks postoperatively. However, both parameters were then improved and significantly increased after 3 months postoperatively compared with the preoperative values ($p < 0.001$).

Regarding the change in the Trendelenburg sign, a significant decrease also occurred in the number of patients with this sign after 3 months postoperatively compared to the preoperative value ($p < 0.0001$) (Table 2).

The MRI at the 9-month postoperative follow-up interval showed good healing without a gap in the muscle repair site for all patients. However, only 3 patients demonstrated minimal fibrosis and mild swelling of the anterior gluteus muscle.

3.3. Postoperative changes in VAS, Harris hip score, and WOMOAC score

Figure 4 shows the postoperative change in the VAS, Harris hip score, and WOMAC score. Postoperatively, the pain score (VAS) and the functional scores (Harris hip score and WOMAC)

TABLE 1 Demographic data for the 20 patients with unilateral hip disease in this study.

	Value
Age, year	55.7 ± 15.1
Female gender	15 (75%)
BMI, kg/m^2	26.8 ± 4.4
Disease onset, year	2.4 ± 1.2
Positive Trendelenburg test	20 (100%)
Affected hip VAS	7.9 ± 1.4
Hip abductor power, newton	
Affected side	96.3 ± 9.2
Control side	190.2 ± 54.6
Hip abductor recovery ratio, %	50.7 ± 17.3
Harris hip score	41.3 ± 9.0
WOMAC score	48.6 ± 11.1

TABLE 2 Mean difference of hip abductor strength ratio and the number of patients with positive trendelenburg sign at each follow-up visit.

Postoperative period	Hip abductor strength ratio[a]		Positive Trendelenburg sign[b]
	Mean difference	95% CI	
2 weeks	5.5 (4.3)	−8.1 to 19.2	20 (100%)
6 weeks	−13.2 (5.8)	−31.8 to 5.3	18 (90%)
3 months	−31.9 (5.9)*	−50.6 to −13.3*	12 (60%)*
6 months	−43.2 (5.0)*	−59.1 to −27.3*	4 (20%)*

[a]Value presented as mean difference (standard error) between preoperative and postoperative values at each follow-up visit.
[b]Vvalue presented as number of patients (percentage) having positive Trendelenburg sign at each follow-up visit.
*Significant difference compared to the preoperative value, $p < 0.05$.

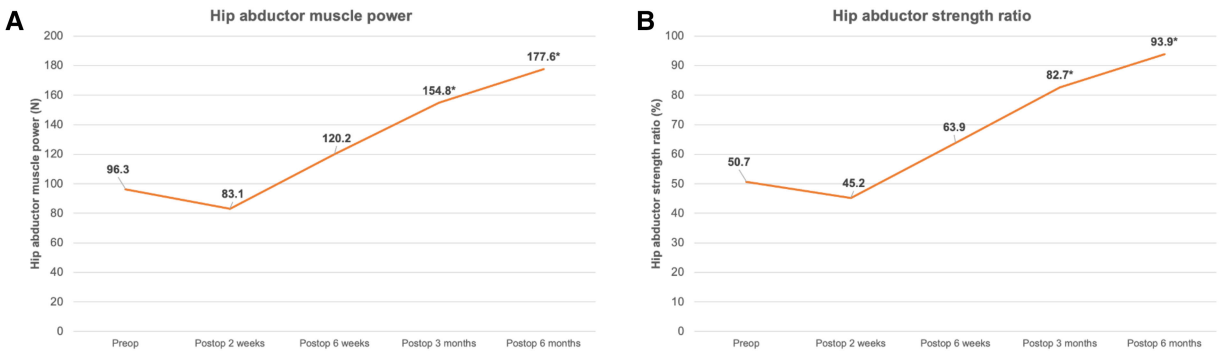

FIGURE 3
Postoperative changes in hip abductor muscle power (A) and hip abductor strength ratio (B). (*; significant difference compared with preoperative value, $p < 0.05$).

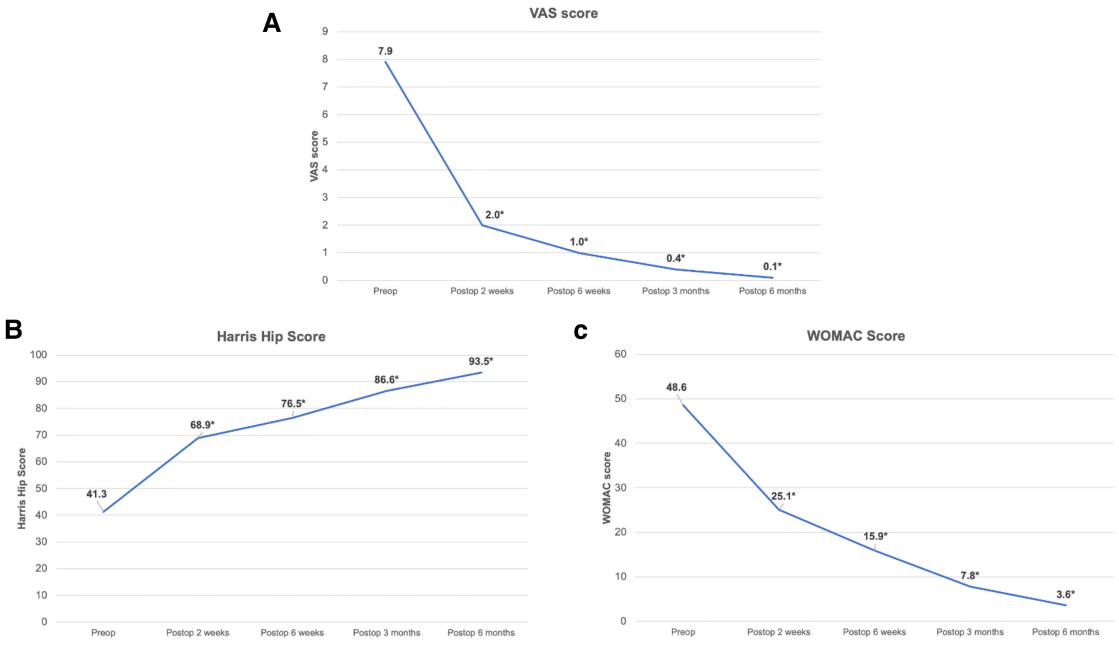

FIGURE 4
Postoperative changes in VAS (A), harris hip score (B), and WOMAC score (C). (*; significant difference compared with preoperative value with $p < 0.05$).

significantly improved as early as 2 weeks postoperatively and showed continuous improvements throughout the 6-month follow-up period ($p < 0.001$).

4. Discussion

Abductor muscles of the hip play a major role in providing stability and mobility of the hips (22). The most common mechanisms leading to abductor muscle atrophy include degenerative or traumatic rupture of the tendon attachments, and iatrogenic injury during hip arthroplasty surgery (23, 24). The resulting insufficiency of abductor muscles not only causes pain and limits movement, but also leads to a typical gait abnormality known as Trendelenburg gait (25). In the AL approach for THA, the anterior one-third of the gluteus medius and gluteus minimus tendons must be detached from the greater trochanter of the femur and later repaired to ensure adequate exposure of the hip joint and allow for femoral dislocation. The main objective in our prospective cohort study was to evaluate the hip abductor muscle recovery, hip pain and function, and the healing of anterior hemimyotomy site of the gluteus medius in patients with unilateral end-stage hip OA undergoing THA with the AL approach.

The results in this study showed the hip abductor muscle power minimally and non-significantly decreased at 2 weeks postoperatively and then gradually increased later. At 3 months postoperatively, the hip abductor muscle power and the positive Trendelenburg sign had significantly improved compared with the preoperative period (Figure 2 and Table 2). However, despite the good healing of the anterior one-third hemimyotomy of the gluteus medius muscle based on MRI assessment, the hip abductor muscle did not demonstrate full recovery, as shown by the mean hip abductor strength ratio at 6 months postoperatively, which was 93.9% ± 2.2% compared to the contralateral normal side (Figure 2 and Table 2). These findings are comparable to the results from previous studies (17, 18, 26) and a previous meta-analysis by Ismailidis et al. in 2021 (27), all of which found that hip abductor muscle strength may gradually improve during the first 24 months post-THA and possibly without complete recovery. This outcome might be explained by the muscle atrophy and lower muscle volume in the hip OA patients (28, 29). Therefore, the results in the present study might imply that, in patients with unilateral end-stage hip OA who undergo THA with the AL approach, the hip abductor muscle could significantly improve without significant complications related to the muscle repair site but might not recover to the level equal to the contralateral normal hip.

Regarding the postoperative changes in pain and hip function, the present study showed that, after THA with the AL approach, the pain score significantly decreased as early as 2 weeks postoperatively and continuously decreased during the 6-month postoperative period ($p < 0.05$). The hip functional scores (Harris hip score and WOMAC score) also significantly improved postoperatively at 2 weeks and gradually improved over the entire follow-up period (Figure 3).

While the above results are insightful, the present study has some limitations. First, the sample size in this prospective cohort study is relatively small, and the follow-up period was only 9 months postoperatively due to patients' lack of motivation and

the pandemic period of COVID-19. Nevertheless, several studies on AL approach also had the sample size estimation closed to the present study (between 16 and 26 patients) (30, 31). Also, previous studies showed that most of the cases with severe damage of nerves would still demonstrate the sign of denervation without recovery at 9 months (32–34). In addition, this study could still, however, provide the complete information related to the hip abductor muscle recovery and its related outcome through an MRI assessment in every case. Our results would therefore be helpful for encouraging surgeons to use the AL approach for THA. Second, we did not perform a comparative study to examine other approaches (e.g., direct anterior approach and posterior approach) because they were not the regular procedure at our institution. Finally, the hip abductor muscle power measurement in this study was performed using a handheld dynamometer rather than an isokinetic/isometric dynamometer as used in previous studies (17, 18). However, the handheld dynamometer has been widely accepted and used for measuring the muscle power in clinical studies, including hip arthroplasty studies (26, 35, 36). Previous studies using handheld dynamometers have also demonstrated good intra- and inter-observer reliability for isometric strength at the hip and knee, and moderate to high correlation values when compared to isometric dynamometry strength measures (37). Future studies comparing the benefits of the AL and DA approaches in patients with end-stage hip OA are needed to demonstrate the efficacy of AL approach in these specific patients.

In conclusion, the use of AL approach for THA in patients with end-stage hip OA effectively improved the hip clinical and functional outcomes as early as 2 weeks postoperatively without significant complications related to the hip abductor muscle. The hip abductor muscle recovery could be seen as early as 3 months postoperatively and then gradually increased during the 6-month postoperative period. However, based on our data, the postoperative hip abductor muscle power in these patients might not be fully recovered to match the normal side.

Data availability statement

The original contributions presented in the study are included in the article/Supplementary Material, further inquiries can be directed to the corresponding author.

Ethics statement

The studies involving human participants were reviewed and approved by Faculty of medicine Ramathibodi Hospital, Mahidol university. The patients/participants provided their written informed consent to participate in this study. Written informed consent was obtained from the individual(s) for the publication of any potentially identifiable images or data included in this article.

Author contributions

All authors conceptualized and designed the study. SW, KC, and CJ performed data collection and prepared the manuscript draft. SJ performed MRI assessment. SJ and PS helped critically revise the manuscript for important intellectual content. All authors contributed to the article and approved the submitted version.

Funding

This study was funded by Faculty of Medicine Ramathibodi Hospital, Mahidol University.

Acknowledgments

The authors wish to thank the Department of Orthopedics and the Department of Diagnostic and Therapeutic Radiology, Mahidol University for all the kind assistance and the permission to conduct this study.

Conflict of interest

The authors declare that the research was conducted in the absence of any commercial or financial relationships that could be construed as a potential conflict of interest.

Publisher's note

All claims expressed in this article are solely those of the authors and do not necessarily represent those of their affiliated organizations, or those of the publisher, the editors and the reviewers. Any product that may be evaluated in this article, or claim that may be made by its manufacturer, is not guaranteed or endorsed by the publisher.

References

1. Varacallo M, Chakravarty R, Denehy K, Star A. Joint perception and patient perceived satisfaction after total hip and knee arthroplasty in the American population. *J Orthop*. (2018) 15(2):495–9. doi: 10.1016/j.jor.2018.03.018

2. Daras M, Macaulay W. Total hip arthroplasty in young patients with osteoarthritis. *Am J Orthop (Belle Mead NJ)*. (2009) 38(3):125–9.

3. Karachalios T, Komnos G, Koutalos A. Total hip arthroplasty: survival and modes of failure. *EFORT Open Rev*. (2018) 3(5):232–9. doi: 10.1302/2058-5241.3.170068

4. Aggarwal VK, Iorio R, Zuckerman JD, Long WJ. Surgical approaches for primary total hip arthroplasty from charnley to now: the quest for the best approach. *JBJS Rev*. (2020) 8(1):e0058. doi: 10.2106/JBJS.RVW.19.00058

5. Liu H, Yin L, Li J, Liu S, Tao Q, Xu J. Minimally invasive anterolateral approach versus direct anterior approach total hip arthroplasty in the supine position: a prospective study based on early postoperative outcomes. *J Orthop Surg Res*. (2022) 17(1):230. doi: 10.1186/s13018-022-03126-0

6. Herndon CL, Drummond N, Sarpong NO, Cooper HJ, Shah RP, Geller JA. Direct anterior versus mini-anterolateral approach for primary total hip arthroplasty: early postoperative outcomes and complications. *Arthroplast Today*. (2020) 6(2):257–61. doi: 10.1016/j.artd.2020.02.009

7. Masonis JL, Bourne RB. Surgical approach, abductor function, and total hip arthroplasty dislocation. *Clin Orthop Relat Res*. (2002) 405:46–53. doi: 10.1097/00003086-200212000-00006

8. Woo RY, Morrey BF. Dislocations after total hip arthroplasty. *J Bone Joint Surg Am*. (1982) 64(9):1295–306. doi: 10.2106/00004623-198264090-00004

9. Siguier T, Siguier M, Brumpt B. Mini-incision anterior approach does not increase dislocation rate: a study of 1037 total hip replacements. *Clin Orthop Relat Res*. (2004) 426:164–73. doi: 10.1097/01.blo.0000136651.21191.9f

10. Ritter MA, Harty LD, Keating ME, Faris PM, Meding JB. A clinical comparison of the anterolateral and posterolateral approaches to the hip. *Clin Orthop Relat Res*. (2001) 385:95–9. doi: 10.1097/00003086-200104000-00016

11. Odak S, Ivory J. Management of abductor mechanism deficiency following total hip replacement. *Bone Joint J*. (2013) 95-B(3):343–7. doi: 10.1302/0301-620X.95B3.31098

12. Elbuluk AM, Coxe FR, Schimizzi GV, Ranawat AS, Bostrom MP, Sierra RJ, et al. Abductor deficiency-induced recurrent instability after total hip arthroplasty. *JBJS Rev*. (2020) 8(1):e0164. doi: 10.2106/JBJS.RVW.18.00164

13. Berend KR, Mirza AJ, Morris MJ, Lombardi AV Jr. Risk of periprosthetic fractures with direct anterior primary total hip arthroplasty. *J Arthroplasty*. (2016) 31(10):2295–8. doi: 10.1016/j.arth.2016.03.007

14. Chulsomlee K, Sa-Ngasoongsong P, Kulachote N, Sirisreetreerux N, Tuntiyatorn P, Vasaruchapong S, et al. Hip muscle power recovery after hip replacement using anterior-based muscle-sparing approach in elderly femoral neck fracture: a prospective study in 40 patients. *Orthop Res Rev*. (2018) 10:31–9. doi: 10.2147/ORR.S153451

15. Watts CD, Houdek MT, Wagner ER, Sculco PK, Chalmers BP, Taunton MJ. High risk of wound complications following direct anterior total hip arthroplasty in obese patients. *J Arthroplasty*. (2015) 30(12):2296–8. doi: 10.1016/j.arth.2015.06.016

16. Tamaki T, Nakakita Y, Miura Y, Higashi H, Oinuma K, Shiratsuchi H. Radiographic factors to predict operation time of direct anterior total hip arthroplasty for dysplastic hips. *Hip Int*. (2021) 31(1):90–6. doi: 10.1177/1120700019873877

17. Asayama I, Chamnongkich S, Simpson KJ, Kinsey TL, Mahoney OM. Reconstructed hip joint position and abductor muscle strength after total hip arthroplasty. *J Arthroplasty*. (2005) 20(4):414–20. doi: 10.1016/j.arth.2004.01.016

18. Klausmeier V, Lugade V, Jewett BA, Collis DK, Chou LS. Is there faster recovery with an anterior or anterolateral THA? A pilot study. *Clin Orthop Relat Res*. (2010) 468(2):533–41. doi: 10.1007/s11999-009-1075-4

19. Lewinnek GE, Lewis JL, Tarr R, Compere CL, Zimmerman JR. Dislocations after total hip-replacement arthroplasties. *J Bone Joint Surg Am*. (1978) 60(2):217–20. doi: 10.2106/00004623-197860020-00014

20. Engelken F, Wassilew GI, Kohlitz T, Brockhaus S, Hamm B, Perka C, et al. Assessment of fatty degeneration of the gluteal muscles in patients with THA using MRI: reliability and accuracy of the goutallier and quartile classification systems. *J Arthroplasty*. (2014) 29(1):149–53. doi: 10.1016/j.arth.2013.04.045

21. Klemt C, Simeone FJ, Melnic CM, Tirumala V, Xiong L, Kwon YM. MARS MRI assessment of fatty degeneration of the gluteal muscles in patients with THA: reliability and accuracy of commonly used classification systems. *Skeletal Radiol*. (2021) 50(4):665–72. doi: 10.1007/s00256-020-03611-9

22. Gottschalk F, Kourosh S, Leveau B. The functional anatomy of tensor fasciae latae and gluteus medius and minimus. *J Anat*. (1989) 166:179–89.

23. Lachiewicz PF. Abductor tendon tears of the hip: evaluation and management. *J Am Acad Orthop Surg*. (2011) 19(7):385–91. doi: 10.5435/00124635-201107000-00001

24. Muller M, Tohtz S, Dewey M, Springer I, Perka C. Evidence of reduced muscle trauma through a minimally invasive anterolateral approach by means of MRI. *Clin Orthop Relat Res*. (2010) 468(12):3192–200. doi: 10.1007/s11999-010-1378-5

25. Kingzett-Taylor A, Tirman PF, Feller J, McGann W, Prieto V, Wischer T, et al. Tendinosis and tears of gluteus medius and minimus muscles as a cause of hip pain: mR imaging findings. *AJR Am J Roentgenol*. (1999) 173(4):1123–6. doi: 10.2214/ajr.173.4.10511191

26. Ikeda T, Jinno T, Aizawa J, Masuda T, Hirakawa K, Ninomiya K, et al. Effects of perioperative factors and hip geometry on hip abductor muscle strength during the first 6 months after anterolateral total hip arthroplasty. *J Phys Ther Sci*. (2017) 29(2):295–300. doi: 10.1589/jpts.29.295

27. Ismailidis P, Kvarda P, Vach W, Cadosch D, Appenzeller-Herzog C, Mundermann A. Abductor muscle strength deficit in patients after total hip arthroplasty: a systematic review and meta-analysis. *J Arthroplasty*. (2021) 36(8):3015–27. doi: 10.1016/j.arth.2021.03.042

28. Loureiro A, Constantinou M, Diamond LE, Beck B, Barrett R. Individuals with mild-to-moderate hip osteoarthritis have lower limb muscle strength and volume deficits. *BMC Musculoskelet Disord*. (2018) 19(1):303. doi: 10.1186/s12891-018-2230-4

29. Zacharias A, Green RA, Semciw A, English DJ, Kapakoulakis T, Pizzari T. Atrophy of hip abductor muscles is related to clinical severity in a hip osteoarthritis population. *Clin Anat*. (2018) 31(4):507–13. doi: 10.1002/ca.23064

30. Muller M, Tohtz S, Dewey M, Springer I, Perka C. Age-related appearance of muscle trauma in primary total hip arthroplasty and the benefit of a minimally invasive approach for patients older than 70 years. *Int Orthop*. (2011) 35(2):165–71. doi: 10.1007/s00264-010-1166-6

31. Tan J, Chen H, Chen C, Liang X, Huang W. The strength and function of hip abductors following anterolateral minimally invasive total hip arthroplasty. *Chin J Traumatol*. (2014) 17(2):73–8. doi: 10.3760/cma.j.issn.1008-1275.2014.02.003

32. Chomiak J, Huracek J, Dvorak J, Dungl P, Kubes R, Schwarz O, et al. Lesion of gluteal nerves and muscles in total hip arthroplasty through 3 surgical approaches. An electromyographically controlled study. *Hip Int*. (2015) 25(2):176–83. doi: 10.5301/hipint.5000199

33. Abitbol JJ, Gendron D, Laurin CA, Beaulieu MA. Gluteal nerve damage following total hip arthroplasty. A prospective analysis. *J Arthroplasty*. (1990) 5(4):319–22. doi: 10.1016/s0883-5403(08)80090-3

34. Ramesh M, O'Byrne JM, McCarthy N, Jarvis A, Mahalingham K, Cashman WF. Damage to the superior gluteal nerve after the hardinge approach to the hip. *J Bone Joint Surg Br*. (1996) 78(6):903–6. doi: 10.1302/0301-620X78b6.1289

35. Schache MB, McClelland JA, Webster KE. Reliability of measuring hip abductor strength following total knee arthroplasty using a hand-held dynamometer. *Disabil Rehabil*. (2016) 38(6):597–600. doi: 10.3109/09638288.2015.1046565

36. Awwad DH, Buckley JD, Thomson RL, O'Connor M, Carbone TA, Chehade MJ. Testing the hip abductor muscle strength of older persons using a handheld dynamometer. *Geriatr Orthop Surg Rehabil*. (2017) 8(3):166–72. doi: 10.1177/2151458517722608

37. Arnold CM, Warkentin KD, Chilibeck PD, Magnus CR. The reliability and validity of handheld dynamometry for the measurement of lower-extremity muscle strength in older adults. *J Strength Cond Res*. (2010) 24(3):815–24. doi: 10.1519/JSC.0b013e3181aa36b8

frontiers | Frontiers in Surgery

TYPE Original Research
PUBLISHED 29 March 2023
DOI 10.3389/fsurg.2023.1127827

Check for updates

OPEN ACCESS

EDITED BY
Paphon Sa-ngasoongsong,
Mahidol University, Thailand

REVIEWED BY
Gergo Jozsa,
University of Pécs, Hungary
Jason Wink,
University of Pennsylvania, United States

*CORRESPONDENCE
Yanghua Tang
✉ tangyanghua168@163.com

SPECIALTY SECTION
This article was submitted to Orthopedic Surgery, a section of the journal Frontiers in Surgery

RECEIVED 20 December 2022
ACCEPTED 14 March 2023
PUBLISHED 29 March 2023

CITATION
Yue Z, Mo Y, Xiong Z and Tang Y (2023) New technique for the treatment of fresh bony mallet finger: A retrospective case series study. Front. Surg. 10:1127827.
doi: 10.3389/fsurg.2023.1127827

COPYRIGHT
© 2023 Yue, Mo, Xiong and Tang. This is an open-access article distributed under the terms of the Creative Commons Attribution License (CC BY). The use, distribution or reproduction in other forums is permitted, provided the original author(s) and the copyright owner(s) are credited and that the original publication in this journal is cited, in accordance with accepted academic practice. No use, distribution or reproduction is permitted which does not comply with these terms.

New technique for the treatment of fresh bony mallet finger: A retrospective case series study

Zhenshuang Yue[1†], Yafeng Mo[2†], Zhenfei Xiong[1] and Yanghua Tang[1*]

[1]Department of Orthopedics, Hospital of Traditional Chinese Medicine of Xiaoshan District, Hangzhou, China, [2]Zhejiang Rehabilitation Medical Center, Hangzhou, China

Background: The bony mallet finger is a tear fracture of the extensor tendon, resulting in a flexion deformity of the finger, which affects both the function of the finger. The classical Ishiguro's method is associated with damage to the cartilage of the distal interphalangeal (DIP) joint and always lead to the joint stiffness. This paper explores a new technique to overcome the shortcomings of the classical Ishiguro's method and achieve better clinical efficacy.
Methods: We examined 15 patients with bony mallet fingers, 9 males and 6 females, from February 2020 to June 2022, ranged from 23 to 58 years, including 1 case of index finger, 5 cases of middle finger, 3 cases of ring finger and 6 cases of little finger. The median course of the injury to surgery was 2 days (range, 1~7 days). All had fresh closed injuries, according to the Wehbe and Schneider classification: 4 cases of type IA, 6 cases of type IB, 3 cases of type IIA and 2 cases of type IIB. All patients were treated surgically by the new technique. Post-operative follow-up was conducted to record the healing of the fracture, the pain of the affected finger and the function of joint movement.
Results: The 15 cases were followed up after surgery. The median active range of motion was 65° (range, 55~75°). The median extension deficit of DIP joint was 0° (range, 0~11°). The median clinical healing time of the fracture was 6 weeks (range, 6~10 weeks). None of the patients experienced significant pain. The patients were assessed according to the Crawford criteria at the final follow-up: 11 cases were assessed as excellent, 3 cases were assessed as good and 1 case was assessed as fair. No loss of fracture repositioning, loosening of internal fixation, skin necrosis or infection was observed.
Conclusion: The application of the new technique for the treatment of bony mallet fingers has the advantages of good stability, fracture healing and functional recovery of the DIP joint, making it an ideal surgical procedure for the treatment of fresh bony mallet fingers.

KEYWORDS

bony mallet finger, kirschner wire, tendon, fracture, phalanx

Introduction

Bony mallet finger is a common hand trauma, which is characterized by swelling and pain in the distal interphalangeal (DIP) joint of the affected finger. Without the follow-up treatment, it may lead to a flexion deformity, and even a swan-neck deformity of the finger. The treatment of the bony mallet finger currently consists of conservative and surgical treatment. Because of the high failure rate of conservative treatment, more and more surgeons are advocating early surgical intervention after injury. The most classic form of the procedure is the Ishiguro's method, which has been reported to be effective,

but there are still some shortcomings, such as stiffness of joints and cartilage damage (1, 2). So we modified the design of the method. From February 2018 to June 2019, this study successfully repaired bony mallet finger using the new technique in 15 patients. After the patient's fracture had healed and then Kirschner wires (*K*-wires) were removed, the DIP joint function was noted on follow-up.

Methods

Patients

15 patients (9 males and 6 females) were recruited for the study, whose ages ranged from 23 to 58 years, with a median age of 39 years, including 1 case presented on the index finger, 5 on the middle finger, 3 on the ring finger and 6 on the little finger. The course of injury to surgery ranged from 1 to 7 days, with a median course of 2 days. All were fresh closed injuries, according to the Wehbe-Schneider classification (**Table 1**) (3): 4 cases of type IA, 6 cases of type IB, 3 cases of type IIA and 2 cases of type IIB.

Treatment method

The operation of surgery

After anaesthesia, disinfection, draping, the DIP joint of the affected finger was hyperextended to reposition the avulsed bone under C-arm fluoroscopy, with the aid of a 0.8 mm diameter *K*-wire if necessary. To determine keeping the maximum flexion of the DIP joint after repositioning, a *K*-wire with a diameter of 1.0 mm or 1.2 mm was used to drill into the middle phalanx from the dorsal side of the distal fracture block (without penetrating into the fracture block) at an angle of 35°∼45° with the axis of the middle phalanx. It was appropriate to drill the wire just through the middle phalanx cortex. In order to avoid damage to the articular cartilage of the middle phalanx and the skin of the finger caused by repeated drilling, the drilling point of the *K*-wire was determined by fluoroscopic positioning of a syringe needle before insertion of the *K*-wire. The end of the *K*-wire was cut off and folded into a curved hook. The end of the *K*-wire should not exceed 1/4 of the distal finger. The *K*-wire was used as a "blocking wire". The distal phalanx was pulled distally and the DIP joint was straightened to reposition the torn bone block. After confirming that the fracture was well repositioned and the position of the blocking wire was appropriate, another 0.8 mm *K*-wire was penetrated perpendicularly from the side of the distal phalanx to the contralateral side. Bend both ends of the *K*-wire at 3 mm from the skin, and fold the two ends of the wire respectively into a curved hook for use. Connect the bend hook of blocking wire and the transverse *K*-wire with the rubber band (made by polyisoprene), adjust the tension of the rubber band, and make the DIP joint fixed at the dorsiflexion position of 5°∼10°. The surgery was completed after fluoroscopy again, which confirmed

TABLE 1 Demographics of 15 patients.

Patient No.	Age	Gender	Hand	Finger	Mechanism of injury	Wehbe and Schneider's calssification	Injury to surgery (days)	Follow-up (weeks)	VAS	Extension Deficit (*n*°)	AROM (*n*°)	Crawford Criteria	Complication	Healing time of fracture (weeks)
1	23	Male	R	2	Basketball	IA	2	14	0	0	70	Excellent	No	6
2	25	Male	L	5	Basketball	IB	5	12	0	0	62	Excellent	No	6
3	45	Female	R	3	Traffic accident	IIA	2	18	0	0	65	Excellent	No	8
4	34	Male	L	4	Basketball	IA	5	22	0	0	60	Excellent	No	6
5	37	Female	L	5	Work	IA	1	16	0	0	75	Excellent	No	6
6	45	Male	R	4	Fight	IIA	2	16	0	0	68	Excellent	No	6
7	50	Female	R	3	Work	IB	2	24	0	11	60	Fair	No	8
8	37	Male	R	5	Fall	IB	3	16	0	6	65	Good	No	6
9	25	Male	L	3	Basketball	IA	3	18	0	10	55	Good	No	6
10	39	Female	R	5	Traffic accident	IIB	7	24	0	0	68	Excellent	No	8
11	42	Male	L	3	Work	IB	6	28	0	0	65	Excellent	No	8
12	43	Female	R	5	Work	IB	3	30	0	8	65	Good	No	6
13	32	Male	L	5	Basketball	IIB	1	26	0	0	70	Excellent	No	8
14	55	Male	R	3	Traffic accident	IB	2	28	0	0	60	Excellent	No	10
15	58	Female	L	4	Fall	IIA	1	16	0	0	70	Excellent	No	8

that the fracture block was in good position. A schematic diagram of the new technique is shown in the Figure 1.

Postoperative management

After operation, the patient was instructed to disinfect the wire-hole with alcohol to prevent infection. X-rays were reviewed to observe fracture repositioning and healing every 2 weeks. The patients were instructed to perform DIP joint active functional exercise in a small range 2 weeks after operation. The elasticity of the rubber band was adjusted every 2 weeks after surgery to fix the DIP joint in the straight position. In the 6th~10th week after surgery, the decision to remove the *K*-wire was made according to the stability of fixation and fracture healing. Then active and passive functional exercises of the DIP joint were performed under the guidance of the physician.

Efficacy evaluation index

Follow-up examinations were arranged every 2 weeks to evaluate complications including malunion, skin necrosis, and infection based on physical examination and imaging. The main indexes collected were the pain of the finger, appearance of the finger and the function of the joint. The final follow-up evaluation indexes were assessed according to the Crawford criteria (Table 1) (4).

Results

The 15 cases were followed up for 12 to 30 weeks after surgery, with a median time of 18 weeks. The median active range of motion (AROM) was 65° (range, 55~75°). The median extension deficit of the DIP joint was 0° (range, 0~11°). The median clinical healing time of the fracture was 6 weeks (range, 6~10 weeks). None of the patients experienced significant pain. The patients were assessed according to the Crawford criteria at the final follow-up: 11 cases were assessed as excellent, 3 cases were assessed as good and 1 case was assessed as fair. No loss of fracture repositioning, loosening of internal fixation, skin necrosis or infection was observed. The results of the new technique can be seen in the Table 1.

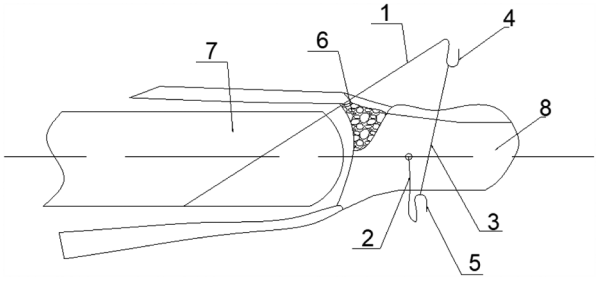

FIGURE 1
A schematic diagram of the new technique (1. Blocking wire; 2. *K*-wire; 3. Rubber band; 4. Hook; 5. Hook; 6. Avulsion fracture; 7. Middle phalanx; 8. Distal phalanx).

Typical case

A 34-year-old male came to our hospital for 4 days due to limited extension of his left ring finger after playing basketball. The affected finger was temporarily fixed by splint. X-ray examination was performed to confirm the diagnosis of bony mallet finger (Figures 2A,B). The next day, the patient was treated with the new technique under fluoroscopy (Figures 2C,D). Postoperative X-ray examination was performed (Figures 2E,F). After discharge, the patient was informed to review the X-ray at the outpatient clinic every 2 weeks. X-ray examination 6 weeks later showed that the fracture had healed and the *K*-wires were removed (Figures 3A,B). Then the patient was informed to review every 4 weeks. The recovery of finger function was evaluated at the last follow-up (Table 1 Patient No. 4, Figures 3C–F).

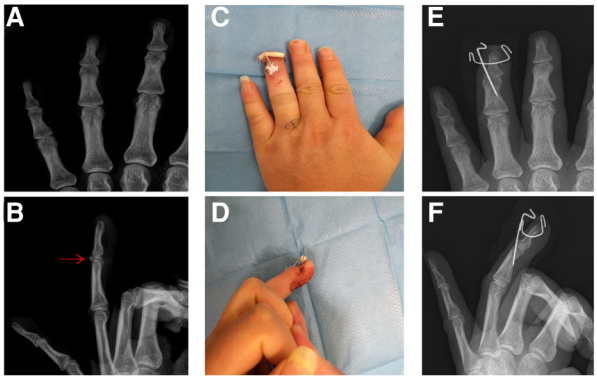

FIGURE 2
Preoperative and postoperative data of patient No.4. (A,B). Preoperative X-ray; the avulsion fracture (red arrow). (C,D). Postoperative X-ray. (E,F). Postoperative appearance.

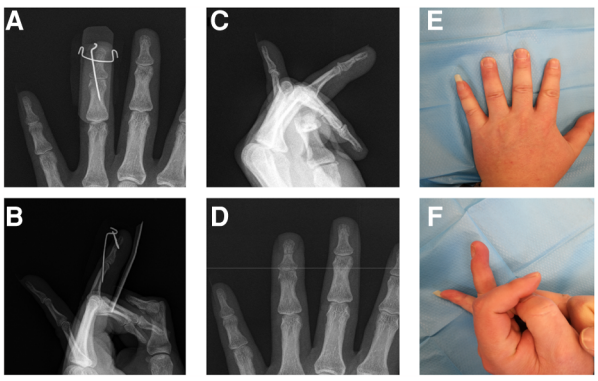

FIGURE 3
Follow-up of patient No. 4. (A,B). X-ray at 6 weeks postoperatively. (C, D). X-ray at 22 weeks postoperatively. (E,F). Finger appearance at 22 weeks.

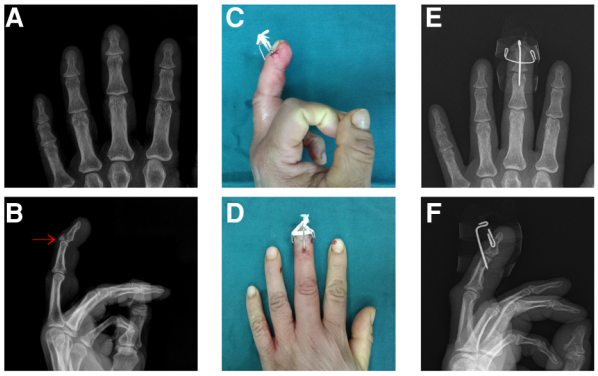

FIGURE 4
Preoperative and postoperative data of patient No.7. (A,B). Preoperative X-ray. (C,D). Postoperative X-ray. (E,F). Postoperative appearance.

Failure case

A 50-year-old female came to our hospital for 1 day due to limited extension of her right middle finger after agricultural work. The affected finger was temporarily fixed by splint. X-ray examination was performed to confirm the diagnosis of bony mallet finger (Figures 4A,B). The next day, the patient was treated with the new technique under fluoroscopy (Figures 4C,D). Postoperative X-ray examination was performed (Figures 4E,F). After discharge, the patient was informed to review the X-ray at the outpatient clinic every 2 weeks. The patient was absent for 6 weeks due to family reasons after 1 review. When she returned to the hospital, X-ray examination showed that the fracture had healed, but the rubber band was relaxed (Figures 5A,B). And then the *K*-wires were removed. Then the patient was informed to review every 4 weeks. The recovery of finger function was evaluated at the last follow-up (Table 1 Patient No. 7). The distal phalanx of the patient had a malunion and the finger of the patient had an extension deficit (Figures 5C–F).

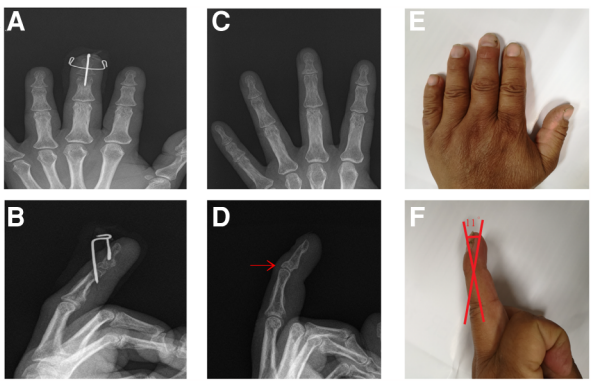

FIGURE 5
Follow-up of patient No.7. (A,B). X-ray at 8 weeks postoperatively. (C,D). X-ray at 24 weeks postoperatively;malunion (red arrow). (E,F). Finger appearance at 24 weeks; extension deficit (red angle).

Discussion

If not effectively treated in a timely manner, bony mallet finger can eventually lead to instability of the DIP joint, osteoarthritis and degenerative arthritis, or even a "swan-neck" deformity, which can seriously affect the function and appearance of the finger and cause great inconvenience to the patient's life and work (5, 6). The early treatment of the bony mallet finger is of great importance in promoting functional rehabilitation and reducing complications, which is also in line with the demands of modern medical technology.

The principles of treatment are aimed at reestablishing the stability of the DIP joint, repairing the fracture, restoring the function of the extensor tendon to balance the forces of flexion and extension (7, 8). The treatment of the bony mallet finger should restore the anatomy of the DIP joint by repositioning and fixing the avulsion fracture firstly, and secondly maintain the stability of the DIP joint by resisting the strong finger flexion forces (9, 10). The "Ishiguro method" requires fixation of the DIP joint with a wire, which can cause damage to the articular surface and complications such as nail deformity and joint stiffness (11, 12). We have modified the "Ishiguro method" and designed it. The procedure consists of 2 *K*-wires and 1 rubber band, in which the wires don't need to be fixed the DIP joint to avoid damage to the articular surface and to allow early active and passive functional exercise of the finger.

The advantages of this new technique include: (i) No damage to the epiphyseal plate and articular surface, which can avoid secondary damage such as articular cartilage degeneration and joint capsule contracture; (ii) Antagonism of the finger flexor tendon force can balance the flexion and extension forces of the distal phalanx to facilitate the healing of the fracture; (iii) Early functional exercise of the DIP joint under the protection of the elastic external fixation to avoid joint stiffness.

The following should be noted when using the new technique for the treatment of fresh bony mallet finger: (i) Before placing the blocking wire, the point of entry should be determined by syringe needle to avoid repeated damage to the articular cartilage surface of the middle phalanx and the skin of the finger. (ii) The entry angle of the blocking wire should be controlled at 35°~45°, a small angle can cause skin compression and nail bed damage easily, and a large angle will weaken the blocking and fixation effect of the avulsed fracture conversely. (iii) The blocking wire should be inserted just above the volar cortex, a long wire can damage the flexor tendon and affect its movement, which is not conducive to finger rehabilitation. (iv) An appropriate amount of cotton balls can be placed at the point of contact between the blocking wire and the dorsal skin of the finger to avoid skin compression by the blocking wire. (v) Patients must be required for strict needle tract care to prevent infection. (vi) Regular outpatient review to observe fracture repositioning and healing, and adjustment should be made in the event of loss of fracture repositioning and loosening of the wires or rubber band.

Limitations

The limitations of this technique are: (i) It is not suitable for those with a disease duration of more than 3 week, as reposition

is difficult. (ii) The blocking wire is a point blocking fixation, which is only suitable for single avulsion fractures (Wehbe-Schneider types Ia, Ib, IIa and IIb) with relatively large and intact bones, but cannot be effectively fixed for comminuted fractures; (iii) The patient must have good compliance, otherwise it is prone to tract infection, loosening of the blocking wire and loss of bone repositioning.

The sample size of this study is small and the follow-up period is short. We will also include a control group in subsequent studies to further clarify the advantages of the new technique.

Data availability statement

The original contributions presented in the study are included in the article/Supplementary Material, further inquiries can be directed to the corresponding author.

Ethics statement

Written informed consent was obtained from the individual (s) for the publication of any potentially identifiable images or data included in this article.

Author contributions

ZSY and YFM collected the patient's data. ZSY and ZFX analyzed the data and performed reference search. YFM and ZSY drafted and revised the manuscript. YFM, this author contributed equally to this work and should be considered co-first authors. YHT provided the subject support, he should be considered co-corresponding authors. All authors contributed toward data analysis, drafting and revision of the manuscript, and read and approved the final manuscript. All authors contributed to the article and approved the submitted version.

Conflict of interest

The authors declare that the research was conducted in the absence of any commercial or financial relationships that could be construed as a potential conflict of interest.

Publisher's note

All claims expressed in this article are solely those of the authors and do not necessarily represent those of their affiliated organizations, or those of the publisher, the editors and the reviewers. Any product that may be evaluated in this article, or claim that may be made by its manufacturer, is not guaranteed or endorsed by the publisher.

References

1. Ishiguro T, Itoh Y, Yabe Y, Hashizume N. Extension block with kirschner wire for fracture dislocation of the distal interphalangeal joint. *Tech Hand Up Extrem Surg.* (1997) 1(2):95–102. doi: 10.1097/00130911-199706000-00005

2. Nordback PH, Westman M, Waris E. Long-term outcomes after extension block pinning for fracture-dislocations of the proximal interphalangeal joint. *J Hand Surg Eur Vol.* (2022) 47(9):927–34. doi: 10.1177/17531934221102251

3. Wehbé MA, Schneider LH. Mallet fractures. *J Bone Joint Surg Am.* (1984) 6 (5):658–69. doi: 10.2106/00004623-198466050-00003

4. Crawford GP. The molded polythene splint for mallet finger deformities. *J Hand Surg Am.* (1984) 9(2):231–7. doi: 10.1016/s0363-5023(84)80148-3

5. Vester H, Schul L, von Matthey F, Beirer M, van Griensven M, Deiler S. Patient satisfaction after hook plate treatment of bony avulsion fracture of the distal phalanges. *Eur J Med Res.* (2018) 23(1):35. doi: 10.1186/s40001-018-0332-y

6. Giddins G. Tendinous and bony mallet finger: mechanisms of injury. *J Hand Surg Eur Vol.* (2021) 46(6):682–4. doi: 10.1177/1753193421997272

7. Wada T, Oda T. Mallet fingers with bone avulsion and DIP joint subluxation. *J Hand Surg Eur Vol.* (2015) 40(1):8–15. doi: 10.1177/1753193414554772

8. Rigot SK, Diaz-Garcia R, Debski RE, Fowler J. Biomechanical analysis of internal fixation methods for distal interphalangeal joint arthrodesis. *Hand (N Y).* (2016) 11 (2):221–6. doi: 10.1177/1558944715627211

9. Lee SK, Kim YH, Moon KH, Choy WS. Correlation between extension-block *K*-wire insertion angle and postoperative extension loss in mallet finger fracture. *Orthop Traumatol Surg Res.* (2018) 104(1):127–32. doi: 10.1016/j.otsr.2017.08.018

10. Alla SR, Deal ND, Dempsey IJ. Current concepts: mallet finger. *Hand (N Y).* (2014) 9(2):138–44. doi: 10.1007/s11552-014-9609-y

11. Lee JK, Lee S, Choi S, Han DH, Oh J, Kil M, et al. Distal interphalangeal joint arthrodesis using only kirschner wires in small distal phalanges. *Handchir Mikrochir Plast Chir.* (2021) 53(5):462–6. doi: 10.1055/a-1559-2684

12. Wang D, Sun K, Jiang W. Mini-plate versus kirschner wire internal fixation for treatment of metacarpal and phalangeal fractures. *J Int Med Res.* (2020) 48 (3):300060519887264. doi: 10.1177/0300060519887264

frontiers | Frontiers in Surgery

TYPE Original Research
PUBLISHED 30 March 2023
DOI 10.3389/fsurg.2023.1003796

Check for updates

OPEN ACCESS

EDITED BY
Paphon Sa-ngasoongsong,
Mahidol University, Thailand

REVIEWED BY
Lin Guo,
Army Medical University, China
Ziji Zhang,
The First Affiliated Hospital of Sun Yat-sen University, China

*CORRESPONDENCE
Yusheng Li
✉ liyusheng@csu.edu.cn
Wenfeng Xiao
✉ xiaowenfeng@csu.edu.cn

†These authors have contributed equally to this work

SPECIALTY SECTION
This article was submitted to Orthopedic Surgery, a section of the journal Frontiers in Surgery

RECEIVED 26 July 2022
ACCEPTED 15 March 2023
PUBLISHED 30 March 2023

CITATION
Fang M, Cai Z, Pan L, Ding Y, Zhang Y, Cheng S, Wang Y, Gao J, Li Y and Xiao W (2023) Surgical treatment of patellar dislocation: A network meta-analysis of randomized control trials and cohort studies.
Front. Surg. 10:1003796.
doi: 10.3389/fsurg.2023.1003796

COPYRIGHT
© 2023 Fang, Cai, Pan, Ding, Zhang, Cheng, Wang, Gao, Li and Xiao. This is an open-access article distributed under the terms of the Creative Commons Attribution License (CC BY). The use, distribution or reproduction in other forums is permitted, provided the original author(s) and the copyright owner(s) are credited and that the original publication in this journal is cited, in accordance with accepted academic practice. No use, distribution or reproduction is permitted which does not comply with these terms.

Surgical treatment of patellar dislocation: A network meta-analysis of randomized control trials and cohort studies

Mingqing Fang[1,3†], Zijun Cai[1,2†], Linyuan Pan[1,2†], Yilan Ding[3], Yueyao Zhang[3], Siyuan Cheng[3], Yifan Wang[3], Jialin Gao[3], Yusheng Li[1,2*] and Wenfeng Xiao[1,2*]

[1]Department of Orthopedics, Xiangya Hospital, Central South University, Changsha, China, [2]National Clinical Research Center for Geriatric Disorders, Xiangya Hospital, Central South University, Changsha, China, [3]Xiangya School of Medicine, Central South University, Changsha, China

Background: Currently, there are many surgical options for patellar dislocation. The purpose of this study is to perform a network meta-analysis of the randomized controlled trials (RCTs) and cohort studies to determine the better treatment.

Method: We searched the Pubmed, Embase, Cochrane Central Register of Controlled Trials, Web of Science, clinicaltrials.gov and who.int/trialsearch. Clinical outcomes included Kujala score, Lysholm score, International Knee Documentation Committee (IKDC) score, redislocation or recurrent instability. We conducted pairwise meta-analysis and network meta-analysis respectively using the frequentist model to compare the clinical outcomes.

Results: There were 10 RCTs and 2 cohort studies with a total of 774 patients included in our study. In network meta-analysis, double-bundle medial patellofemoral ligament reconstruction (DB-MPFLR) achieved good results on functional scores. According to the surface under the cumulative ranking (SUCRA), DB-MPFLR had the highest probabilities of their protective effects on outcomes of Kujala score (SUCRA 96.5 %), IKDC score (SUCRA 100.0%) and redislocation (SUCRA 67.8%). However, DB-MPFLR (SUCRA 84.6%) comes second to SB-MPFLR (SUCRA 90.4%) in Lyshlom score. It is (SUCRA 70%) also inferior to vastus medialis plasty (VM-plasty) (SUCRA 81.9%) in preventing Recurrent instability. The results of subgroup analysis were similar.

Conclusion: Our study demonstrated that MPFLR showed better functional scores than other surgical options.

KEYWORDS

network meta-analysis, medial patellofemoral ligament reconstruction, medial soft tissue surgery, single bundle, double bundle, patellar dislocation

Introduction

Patellar dislocation is a serious injury, accounting for 3.3% of all knee injuries, and females aged 10–17 are at the highest risk (1, 2). Failure or suboptimal treatment may result in serious problems, such as recurrent instability, keen pain, and even osteoarthritis. Those with a history of dislocation were seven times more likely to have an unstable episode during follow-up than those with a first dislocation (3). Therefore, appropriate and effective treatments are urgently needed.

A meta-analysis has reported that conservative treatments can be used for patients with lower risk, while surgery should be considered for patients with higher risk (1). However, there are different surgical options, such as medial retinaculum plication (MR-plication), medial retinaculum plasty (MR-plasty), VM-plasty, medial capsule reefing (MC-reefing), medial patellofemoral ligament reconstruction (MPFLR) and so on. In addition, a study has shown that approximately from the femoral origination point, the medial patellofemoral ligament (MPFL) consists of two relatively concentrated fiber bundles: the inferior-straight bundle and the superior-oblique bundle (4). Thus, two different methods of reconstructing the medial patellar ligament were proposed, single-bundle MPFLR (SB-MPFLR) and DB-MPFLR respectively. However, there is no standard consensus on surgical options for the treatment of patellar dislocation.

This study aimed to perform a network meta-analysis of RCTs and cohort studies in the literature to clarify differences in surgical options and provide evidence for the better treatment. The hypothesis is that DB-MPFLR would repair the medial soft tissue structure better compared with other options.

Materials and methods

Study selection

This study was according to Cochrane Review methods, and reported based on the Preferred Reporting Items for Systematic Reviews and Meta-Analyses (PRISMA) guidelines. Two reviewers independently performed a literature search, reviewing the titles and abstracts of all results, and then conducting a full-text review. We manually screened all references in the study and all literature reviews found in the search results to find articles that met the inclusion criteria. We used some combined text and MeSH terms ("patellar dislocation", "medial patellofemoral ligament reconstruction", "plication", "plasty", and "reefing") to search the Cochrane Central Register of Controlled Trials, Pubmed, Embase, Web of Science, clinicaltrials.gov and who.int/trialsearch. The complete search used for electronic databases was listed in **Supplementary Appendix A**. This search was carried out in December 2021.

Inclusion criteria

(1) Human studies; (2) Studies that evaluated clinical outcomes of MPFLR or other soft tissue surgeries (plication, plasty, reefing etc.); (3) RCTs or cohort studies; (4) Published in English language; (5) Studies reporting at least one of the following data: Kujala score, Lysholm score, IKDC score, redislocation or recurrent instability.

Exclusion criteria

(1) Subjects with knee disease or previous knee surgery; (2) Studies that only reported preoperative or intraoperative outcomes.

Data collection and analysis

The studies were independently evaluated by two authors, followed by full-text readings of potentially eligible articles for eventual inclusion. The uncertainties included in the study were resolved through discussion and negotiation. Eligible data were extracted independently by one author into a pre-defined format and then extracted by another author for a second time to ensure accuracy. We collected information concerning (1) study characteristics including journal, authors, year of publication, study design, and level of evidence; (2) demographics of patients including the number of subjects, gender, age, surgical techniques, postoperative rehabilitation, and duration of follow-up. (3) the outcomes of studies including the Kujala score, Lysholm score, IKDC score, redislocation, or recurrent instability.

Assessment of risk of bias and quality of evidence

The assessment is done independently by two investigators using the Cochrane Risk of Bias Tool for RCTs, while the cohort studies were assessed using the modified Newcastle-Ottawa Scale (NOS) (5, 6). Any disagreement between the two authors was resolved through discussion and, if no agreement could be reached after discussion, it was left to the judgment of the third author.

Statistical analysis

We conducted a pairwise meta-analysis and a network meta-analysis in a frequentist model (7). In addition, we performed a subgroup analysis of recurrent patellar dislocation in network meta-analysis. The relative effect sizes of continuous outcomes in data analysis were mean difference (MD) with confidence interval (CI) of 95% and odds ratios (ORs) and 95% CIs were calculated to evaluate the dichotomous outcomes. The level of statistical significance was set as $p < 0.05$. All statistical analyses were performed using R 4.1.1. The I-Squared (I^2) test was used to estimate heterogeneity among studies for pairwise meta-analyse and network meta-analysis (8). According to the Cochrane Collaboration Handbook, only if $I^2 < 25\%$, the heterogeneity between studies is low. Therefore, in the heterogeneity test, if $I^2 < 25\%$, fixed-effects model was adopted; otherwise, we conducted the random-effects model. For the network meta-analysis, the analysis was performed in a frequentist model employing the "netmeta" packages. For each outcome, we used a trail network plot to show the comparison of all interventions. SUCRA was used to represent the overall ranking of an intervention; that was, the higher the value of SUCRA, the higher the probability of this surgical option being the best intervention (9). We calculated the value of SUCRA to rank each intervention. Publication bias of the studies was

assessed by observing the symmetry of comparison-adjusted funnel plots.

CINeMA assessment

The confidence in network meta-analysis (CINeMA) framework was used to assessed the certainty of the evidence (10). The CINeMA evaluation consists of six evaluable items: within-study bias, reporting bias, indirectness, imprecision, heterogeneity, and incoherence. There are four levels of evidence: high, medium, low, and very low. The grade of RCT is high and The grade of cohort studies is low before evaluation.

Results

Results of the search

A total of 208 articles were queried from the databases with additional 4 records identified through other sources. Of these, 102 were duplicates in the databases and were subsequently excluded. The remaining 110 papers were carefully screened for titles and abstracts, and only 22 remained, excluding all others as irrelevant to the purpose of the study. We reviewed the full text of the remaining 22 articles and subsequently excluded 10 due to the lack of necessary data. Ultimately, a total of 10 RCTs and 2 cohort studies were included for data extraction and meta-analysis. Figure 1 illustrates the process of systematic literature retrieval and research selection.

Characteristics of the included studies

This review includes 12 trials involving 774 patients. These studies were published between 2011 and 2020. A total of 6 different surgical methods were introduced for the 10 RCTs and 2 cohort studies. Of the included 12 studies, 12 studies provided Kujala scores, 6 provided Lysholm scores, 5 provided IKDC scores and 9 provided redislocation and 8 provided recurrent instability respectively. The sample sizes of the included trials ranged from 45 to 88 patients, with the mean ages ranging from 13 to 29 years and the duration of follow-up ranging from 24 to 87 months. The basic characteristics of the included studies are summarized in Table 1.

Quality assessment of included studies

We adopted the Cochrane Risk of Bias Tool for RCTs (RoB2.0) (the score for each bias domain was graded as representing a low, high, or unclear risk of bias) and modified Newcastle-Ottawa Scale (NOS) for cohort studies (Studies with scores of 7, 5 to 7, 3 to 5, and 0 to 2 were considered of good, fair, poor-fair, and poor quality, respectively) for methodological quality evaluation. Among 10 RCTs, 6 studies utilized sufficient random sequence generation methods. Appropriate methods of allocation concealment were described in 3 studies. None of the studies applied blindness to patients and researchers because of practical and ethical issues, which resulted in a high risk of bias. In 3 studies, the outcome measures were blinded. Other bias of five included RCTs was unclear. NOS indicated that the two cohort studies were of good quality. The risk of bias assessment for RCTs is shown in Supplementary Appendix B(a-b), and the risk of bias assessment for cohort studies is shown in Supplementary Appendix B(C).

Clinical outcomes: quantitative analysis

Pairwise meta-analysis

For redislocation and recurrent instability, no pairwise meta-analysis was performed because the number of events in many studies was 0. All detailed results of pair-wise meta-analysis are shown in Table 2A–C.

Network meta-analysis

Kujala score

Twelve included studies reported Kujala scores as one of the study outcomes. $I^2 = 94.1\%$, so we chosen the random effects model. Figure 2A shows the MD and 95% CI of each surgery compared with DB-MPFLR. MC-reefing (MD −10.12, 95% CI, −18.43, −1.81), MR-plasty (MD −6.63,95% CI, −18.43, −0.68), MR-plication (MD −12.66,95% CI, −18.67, −6.66), SB-MPFLR (MD −5.83,95% CI, −10.31, −1.34) and VM-plasty (MD −6.36,95% CI, −16.77, −4.04) were inferior to DB-MPFLR. The effects of all surgeries were ranked with SUCRA probabilities in Table 3, and DB-MPFLR had the greatest probability (SUCRA 96.5%) for being the best treatment option on Kujala score, followed by the SB-MPFLR (SUCRA 57.4%), VM-plasty(SUCRA 55.5%)and MR-plasty (SUCRA 42.0%), MC-reefing ranked in the sixth position (SUCRA 28.5%) and MR-plication ranked the last (SUCRA 9.9%).

Lysholm score

Six studies reported Lysholm scores as one of the study outcomes. $I^2 = 42.1\%$, so we chosen the random effects model. Figure 2B shows the MD and 95% CI, of each surgery compared with DB-MPFLR. MR-plasty (MD −9.6,95% CI, −11.08, −8.12), MR-plication (MD −16.68,95% CI, −19.55, −13.81), and VM-plasty (MD −7.98,95% CI, −12.89, −3.07) were inferior to DB-MPFLR. DB-MPFLR was not superior to SB-MPFR (MD 0.94, 95% CI, −1.87, 3.76). As shown Table 3, SB-MPFLR had the highest probability of being the best treatment option (SUCRA 90.4%) followed by DB-MPFLR (SUCRA 84.6%). MR-plasty (SUCRA 30.3%) and MPR-plication(SUCRA 0.0%) ranked in the fourth and fifth positions behind the and VM-reefing(SUCRA 44.0%).

IKDC score

Five studies reported IKDC scores as one of the study outcomes. $I^2 = 24.4\%$, so we chosen the fixed effects model. Figure 2C show the MD and 95% CI of each surgery compared with DB-MPFLR. MR-plication (MD −18.01,95% CI, −20.05, −15.97), SB-MPFLR

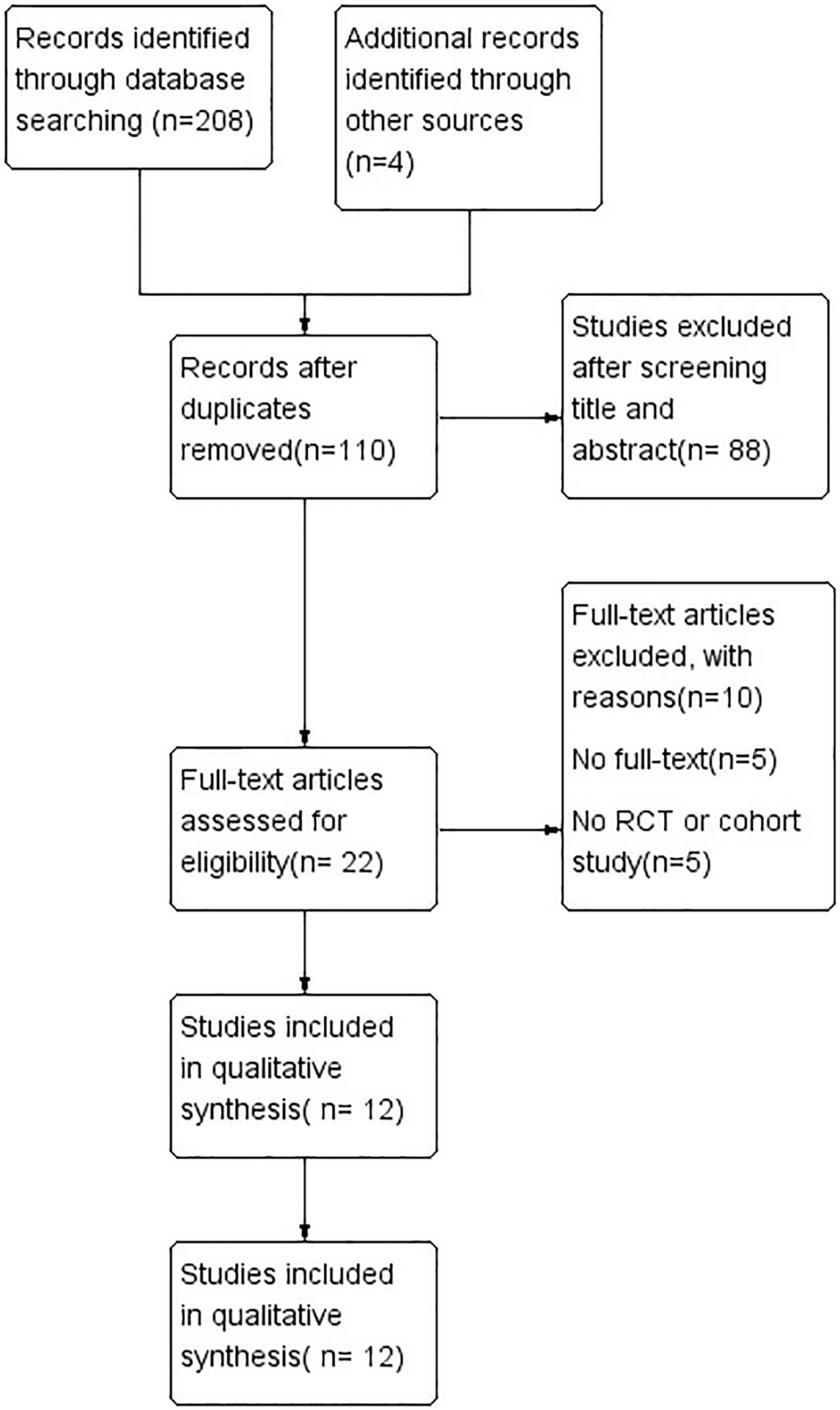

FIGURE 1
Search flow diagram. The search flow diagram summarizes the search, screening, retrieval, and appraisal of articles finally included in the network meta-analysis.

TABLE 1 Characteristics of the included studies.

Author	G 1	G 2	Patients (knees)		Sex (M/F)		Age in years mean (SD)		Follow-up (month)	Disease types	Additional surgeries	Postoperative Rehabilitation
			Included (G1/G2)	Assessed (G1/G2)	G1	G2	G1	G2				
Du et al. 2017 (31)	MR-plication	DB-MPFLR	22 (22)/ 23 (23)	22 (22)/ 23 (23)	NR		19.3 ± 6.5		24	RPD	LRR was performed in all patients	NR
Zhao et al.(1) 2012 (32)	MR-plication	DB-MPFLR	50(50)/50(50)	43(43)/45 (45)	7/ 36	8/ 37	23.9 ± 5.8	25.0 ± 6.6	24/ 60	RPD	Tibial tubercle anteromedialization or distalization was performed as indicated, and LRR was performed in all patients	The 2 groups followed the same rehabilitation protocol. A hinged brace was used for 6 weeks and locked in extension while walking.Partial to full weightbearing was allowed immediately after the operation. Range-of-motion exercises began immediately, but the knee flexion angle was restricted to 45°, 90°, and 120°in the first, second, and third 2-week periods after the operation, respectively. Straight-leg raising, vastus medialis exercises, and proprioception training began 6 weeks after the operation; running and agility training began after the fourth month.
Ma et al.(1) 2013 (33)	DB-MPFLR	MR-plasty	36 (36) / 34 (34)	32 (32) / 31 (31)	10/ 22	12/ 19	28.4 ± 4.2	28 ± 4	40	RPD	LRR was performed in all patients	The 2 groups followed the same rehabilitation protocol. Postoperatively, a hinged brace was used for 6 weeks and locked in extension during walking. Quadriceps-setting exercises and straight leg raising were encouraged from the first day after surgery. A hinged brace with a patellofemoral stabilizing component was used for 6 weeks after surgery, and it was locked in extension during walking. Walking with partial weight bearing on 2 crutches was also permitted as tolerated and gradually progressed until, after 4 weeks, full weight bearing was allowed and knee flexion up to 90° was obtained. After 6 weeks, with the removal of the brace, patients were advised to wear a knee pad to stabilize the patella during sports or rehabilitation exercises. Patients who achieved sufficient quadriceps strength and stability of the patella and sufficient range of motion were allowed to begin normal activities of daily living and jogging 2 months after surgery and to start to do athletic exercises 3 months after surgery.
Niu et al. 2016 (34)	DB-MPFLR	MR-plasty	26 (26) / 28 (28)	22 (22) / 22 (22)	10/ 12	9/ 13	27.46 ± 4.84	25.64 ± 3.35	12/24/48	RPD	LRR was performed on request.	The rehabilitation programme was similar in the two groups. There was a need to make the affected limb immobilized postoperatively. The first day after operation, the patients started moderate exercises, such as isometric contraction of the quadriceps, the affected limb straight rising, etc. Two days later, a slight knee flexion was admitted. And the degree of the knee flexion was gradually increasing from 0 to 90 during one month. At the third day afteroperation, the patients could walk on crutches. Three weeks later, the affected limb was allowed partially weight-bearing and full weightbearing five weeks or later after operation. And the immobilizer was removed three months later. Then, the patients participated in normal sports six months after operation.

(*continued*)

10.3389/fsurg.2023.1003796

TABLE 1 Continued

Author	G 1	G 2	Patients (knees)		Sex (M/F)		Age in years mean (SD)		Follow-up (month)	Disease types	Additional surgeries	Postoperative Rehabilitation
			Included (G1/G2)	Assessed (G1/G2)	G1	G2	G1	G2				
Li et al. 2018 (35)	DB-MPFLR	SB-MPFLR	46 (46) / 45 (45)	45 (45) / 43 (43)	15/30	17/26	26.9 ± 5.36	27.3 ± 5.59	40.92 ± 7.22/ 41.32 ± 7.59	RPD	NO	The 2 groups followed the same rehabilitation protocol. The involved knee was placed in a hinged knee brace with a patellofemoral stabilizing component and locked in full extension, and weight bearing was avoided for the first 3 weeks postoperatively. The brace was then adjusted to allow a motion range from 0 to 90, and the patient was allowed touchdown weight bearing with crutches for the next 3 weeks. Full weight bearing and full range of motion with the brace unlocked were allowed at 6 weeks postoperatively. Isometric quadriceps exercises were suggested after surgery and throughout the whole immobilization period to prevent disuse atrophy. After 8 weeks, with the removal of the brace, patients were advised to wear a knee pad to stabilize the patella during sports or rehabilitation exercises. Patients were allowed to begin normal activities of daily living and some light sports at 2 months postoperatively. Functional activities including walking, jogging, and running were introduced at 3 months, and 6 months were needed for patients to return to normal sports activities.
Ercan et al. 2020 (36)	DB-MPFLR	SB-MPFLR	40 (40) / 40 (40)	40 (40) / 40 (40)	20/20	18/22	19 (14–29)	15 (10–28)	40 (24–74) / 46.5 (24–74)	RPD	NO	Following MPFL reconstruction, the same physical therapy and rehabilitation protocol was applied to all patients by the same team. Active and passive assisted full range of kneemotion was started the day after MPFL reconstruction.Weight bearing was gradually increased to full at 3 weeks postoperatively. Jogging was permitted 3 months after reconstruction. Return to sports was allowed 6 months postoperatively, following an evaluation of muscle strength.
Astur et al. 2015 (37)	DB-MPFLR	SB-MPFLR	62	28 (28)/30 (30)	30/28		28.32 (18–45)	31.06 (18–45)	NR	PD	NO	Within first two-postoperative weeks, physical therapy consisted of pain and swelling control as well as active assist range of motion without weight bearing. Quadriceps muscle strengthening started in the third postoperative week with partial weight bearing until fourth week. Full weight bearing was allowed from week four onward. Full activitiy including participation in sports was allowed 12 weeks after surgery.
Zhao et al.(2) 2011 (38)	MR plication	VM plasty	60	28 (28) / 26 (26)	5/23	4/22	14.7 ± 1.3	15.2 ± 1.6	56.8 ± 21.5 / 59.1 ± 24.7	RPD	LRR was performed on request.	The 2 groups followed the same rehabilitation protocol. A hinged brace was used for 6 weeks and locked in extension while walking. Partial to full weightbearing was allowed immediately after operation. Range of motion exercise began immediately, but knee flexion anglewas restricted to 45°, 90°, and 120°, respectively, in the second, fourth, and sixth weeks after operation. Straight-leg raising, vastus medialis exercises, and proprioception training started 6 weeks after operation; running and agility training began from the fourth mont.

(*continued*)

10.3389/fsurg.2023.1003796

TABLE 1 Continued

Author	G 1	G 2	Patients (knees)		Sex (M/F)		Age in years mean (SD)		Follow-up (month)	Disease types	Additional surgeries	Postoperative Rehabilitation
			Included (G1/G2)	Assessed (G1/G2)	G1	G2	G1	G2				
Ma et al.(2) 2012 (39)	MC reefing and(LPR release)	MR plasty and(LPR release)	40 (40) / 38 (38)	40 (40) / 38 (38)	16/24	15/23	28 (21–35)	29 (21–37)	60 (33–87)	PD	15 cases had the combination of lateral retinacular release (G 1) and 12 cases had the combination of LRR (G 2)	Quadriceps setting exercises and straight leg raising exercises were encouraged from the first day following surgery. Walking with partial weight bearing on two crutches andknee flex activities were also permitted within tolerance and gradually progressed from the day following surgery. After 1 week, knee flexion up to 30° was obtained. After 2 weeks knee flexion up to 90°was obtained. After 4 weeks, full weight bearing was allowed. Patients who achieved enough quadriceps strength, stability of patella, and sufficient range of motion were allowed to begin normal daily living and jogging 2 months after surgery and athletic exercises 3 months after surgery.
Ma et al.(3) 2012 (40)	MC reefing	MR plasty	33 (33) / 35 (35)	29 (29) / 32 (32)	13/16	12/20	13 (10–16)	14 (11–17)	50 (25–75)	PD	13 patients also received LRR(G 1) and 12 patients also received LRR (G 2).	The postoperative rehabilitation program and follow-up of the two groups were basically the same. Quadriceps setting exercises and straight leg raising were encouraged from the day following surgery. Walking with partial weight bearing on two crutches and knee flex activities were also permitted as tolerated and gradually progressed from the day following surgery, until after one week, knee flexion up to 90°was obtained. After 2 weeks, full weight bearing was allowed, patients were advised to wear a knee pad to stabilize the patella during sports or rehabilitation exercises. Patients who achieved a sufficient range of motion, quadriceps strength and stability of the patella were allowed to begin normal daily living and jogging at one month and return to full sports activity at 3 months.
Wang et al. 2013 (27)	DB-MPFLR	SB-MPFLR	37 (44)/21 (26)	37 (44)/21 (26)	16/21	7/14	23 ± 10	26 ± 7	48	PD	NR	The rehabilitation program was the same for single and double bundle cases. After the MPFL reconstruction patients wore a brace for one week. The patients began moderate exercise such as isometric contraction of quadriceps femoris muscle, straight leg raising, patella traction and mild genuflection two days after the operation. Flexion of 10° was allowed from the third day after the operation and the angle was increased gradually to 90° in a month. Two weeks after operation, the patients could start CPM exercises, and active or assisted kneejoint ROM exercises; three weeks after operation, the affected limb could withstand partial weight-bearing and full weight-bearing five weeks after operation or later. The patient could jog three months after operation and participate in normal sports activities six months after operation.
Fenget al. 2020 (14)	DB-MPFLR	MR-plasty	32 (32)/25 (25)	32 (32)/25 (25)	7/25	6/17	23.8 ± 5.4	23.9 ± 5.8	41	RPD	tibial tubercle Transfer was performed in all patients.	NR

Data are presented as mean, mean standard deviation, or mean (range) unless otherwise indicated.

NR, not reported;G1, Group1;G2, Group2; F, female; M, male; IKDC score, International Knee Documentation Committee subjective scores; DB-MPFLR, double bundle medial patellofemoral ligament; SB-MPFLR, single bundle medial patellofemoral ligament; MR-plication, medial retinaculum plication; MR-plasty, Medial retinaculum plasty; VM-plasty, vastus medialis plasty; MC-reefing, Medial Capsule Reefing. LRR, lateral retinacular release; patellar dislocation, PD; recurrent patellar dislocation, RPD.

10.3389/fsurg.2023.1003796

TABLE 2 Results from pair-wise meta-analysis.

A: Kujala score				
Intervention	*n*	I^2	*p*-value	MDs (95% CI)
DB-MPFLR vs. MR-plication	2	6%	0	12.79 (10.95, 14.63)
DB-MPFLR vs. MR-plasty	2	94.5%	0.059	6.60 (−0.26, 13.45)
DB-MPFLR vs. SB-MPFLR	4	96%	0	5.75 (0.57, 10.91)
MR-plasty vs. MC-reefing	2	36.1%	0	3.21 (2.18, 4.24)
MR-plication vs. VM-plasty	1	–	0	−6.30 (−8.86, −3.74)
B: Lysholm score				
Intervention	*n*	I^2	*p*-value	MDs (95% CI)
DB-MPFLR vs. MR-plication	2	0%	0	16.75 (14.68, 18.83)
DB-MPFLR vs. MR-plasty	1	–	0	9.60 (8.12, 11.08)
DB-MPFLR vs. SB-MPFLR	2	61.1%	0.5	−1.38 (−5.38, 2.62)
MR-plication vs. VM-plasty	1	–	0	−8.70 (−11.54, −5.86)
C: IKDC score				
Intervention	*n*	I^2	*p*-value	MDs (95% CI)
DB-MPFLR vs. MR-plication	2	0%	0	18.01 (15.97, 20.05)
DB-MPFLR vs. SB-MPFLR	2	61.7%	0.232	3.30 (−2.11, 8.70)
MR-plication vs. VM-plasty	1	–	0	−9.30 (−12.87, −5.73)

(MD −4.98, 95% CI, −6.34, −3.62) and VM-plasty (MD −8.71,95% CI, −12.82, −4.60) were inferior to DB-MPFLR. DB-MPFLR was at the top-ranking position (SUCRA 100.0%) shown in Table 3 followed by SB-MPFLR (SUCRA 65.8%). Two of the least effective treatments for IKDC Score were VM-plasty (SUCRA 34.2%) and MPR-plication (SUCRA 0.0%).

Redislocation

Nine studies reported redislocation as one of the study outcomes. $I^2 = 0.0\%$, so we chosen the fixed effects model. Figure 2D shows the OR and 95% CI of each surgery compared with DB-MPFLR. DB-MPFLR has no significant advantage over other surgical procedures in preventing redislocation, although it is the most likely intervention to be the best (SUCRA 67.8% shown in Table 3).

Recurrent instability

Eight studies reported recurrent instability as one of the study outcomes. $I^2 = 0.0\%$, so we chosen the fixed effects model. Figure 2E shows the OR and 95% CI of each surgery compared with DB-MPFLR. All the methods are not obviously inferior to DB-MPFLR. Even DB-MPFLR(SUCRA 70%) is less likely than VM-plasty(SUCRA 81.9%) to be the best intervention shown in shown in Table 3.

Subgroup

Since the clinical studies which reported Lyshlom and IKDC scores were all about recurrent patellar dislocation, we only conducted a subgroup analysis of Kujala score, redislocation, and recurrent instability. The results of the subgroup analysis were similar to those of the previous analysis. Detailed results are shown in Supplementary Appendix C and Table 3.

Publication bias

The comparison-adjusted funnel plots are displayed in Figures 3A–E. For the funnel plot of Kujala score, the outcomes showed obvious asymmetry, indicating a certain publication bias. The existence of points at the bottom of all funnel plots indicates that these outcomes all have small-study effects in the included studies.

Network plots

Trial network plots are shown in Figures 4A–E. The width of the line indicates the number of studies in which the two interventions are connected, and the size of the node indicates the number of patients receiving the intervention. Since there is no closed loop in each trial network plot, there is no inconsistency in NMA, and we only choose the consistency model.

CINeMA assessment

For the vast majority of interventions, the quality of evidence was "low" across the five outcome indicators. The comparisons of MC-reefing with DB-MPFLR and MR-plasty achieved very low

quality of evidence for the outcome of Kujala scores; the comparison of MR-plication with VM plasty achieved very low quality of evidence for the outcome of Recurrent instability (details were shown in Supplementary Appendix D).

Comparison of pair-wise meta-analysis and network meta-analysis

The comparison of pair-wise meta-analysis and network meta-analysis revealed that the results were generally consistent. This comparison between pair-wise meta-analysis and network meta-analysis confirmed the accuracy of the results.

Discussion

The most important finding of this study was that DB-MPFLR is a fairly good method, which greatly improves function scores. In pairwise meta-analysis, DB-MPFLR shows great advantages in three outcomes. However, this conclusion requires careful consideration as it is highly heterogeneous, which may lead to the serious risk of bias. Also, we found the source of heterogeneity through meta-analysis: studies that compare DB-MPFLR and MR-plasty. For network meta-analysis, DB-MPFLR achieves the highest SURCA not only for patellar dislocation but also in recurrent patellar dislocation subgroup, except Lysholm score and recurrent instability. DB-MPFLR ranked second only to SB-MPFLR In Lysholm score and VM-plasty in recurrent instability. However, no significant difference was achieved in the prevention of dislocation and recurrent instability compared with other treatments.

A study has shown elevated TT-TG distance, trochlear dysplasia, patella alta and so that 92% of 175 patients had MPFL injury after a first time acute patellar dislocation (11). Injured sites include the femoral attachment and the patellar attachment (12). Moreover, a biomechanical study showed that MPFL provides approximately 60% of the inward binding resistance against lateral patella displacement (13). There is good reason to suspect that MPFLR, which can directly repair the medial patellar ligament, may yield higher functional outcomes. Based

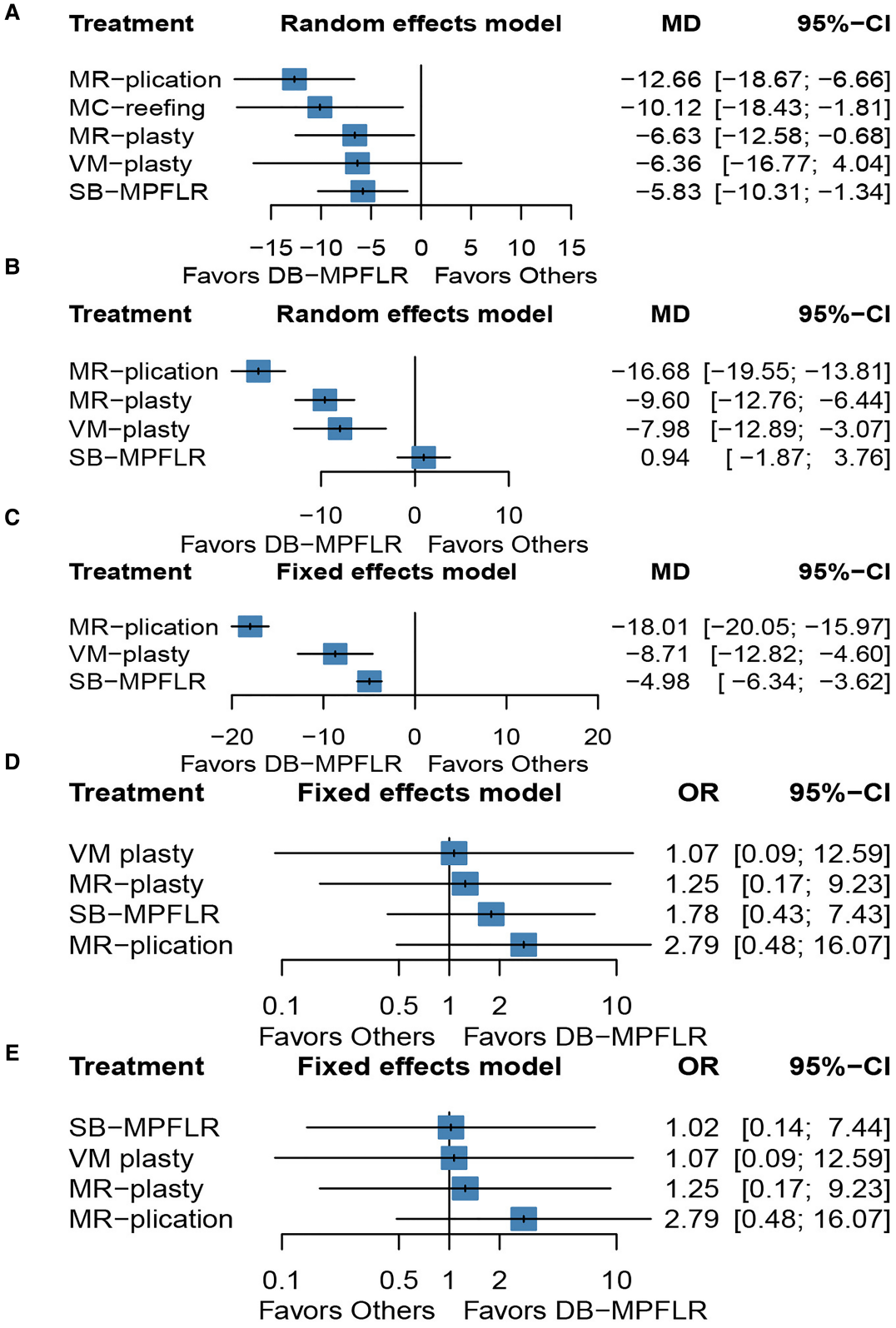

FIGURE 2
Forest plot of different surgeries: (A) kujala score; (B) lysholm score; (C) IKDC score; (D): redislocation; (E) recurrent instability.

on this, there are many clinical studies of MPFLR for patellar dislocation to verify whether this is an appropriate method. In many studies, some have found that MPFLR is not superior to other soft tissue surgeries, but others have concluded that MPFLR does result in better functional scores than other surgeries (14–16). Therefore, our study collected high-quality

TABLE 3 Ranking of surgeries based on probability of their protective effects on all outcomes according to the SUCRA. Larger probability, stronger protective effects.

Kujala score	Lysholm score	IKDC score	Redislocation	Recurrent instability	Subgroup of Kujala score	Subgroup of Redislocation	Subgroup of Recurrent instability	
96.5	84.6	100.0	67.8	70	95.3	65.6	67.5	DB-MPLFR
28.6	NA	NA	NA	NA	NA	NA	NA	MC-reefing
52.1	30.3	NA	55.2	56.5	38.3	55.1	56	MR-plasty
9.9	0.0	0.0	22.5	26.3	1.3	17.2	26	MR-plication
57.4	90.4	65.8	40.4	15.2	71.0	60.8	20.6	SB-MPFLR
55.5	44.6	34.2	64.2	81.9	43.9	51.3	80	VM-plasty

RCTs and finally confirmed that MPFLR can obtain higher functional scores.

In adults, MPFLR has shown promising results, however, alternative MPFLR techniques are urgently needed for the treatment of recurrent patellar dislocation in children and adolescents with open growth plates. Several studies have developed a minimally invasive reconstruction of the MPFL through the insertion of the medial patellofemoral growth plate (17, 18).

For recurrent patellar dislocation, MPFL also achieved good results compared to other procedures in this study. However, other studies have found that risk factors for recurrent patellar dislocation include many bony structural abnormalities, such as elevated TT-TG distance, trochlear dysplasia, patella alta and so on (19). This means that simply repairing the inner soft tissue may not be enough. A clinical study reported that MPFLR combined with Tibial Tubercle Osteotomy obtained patellar kinematics and better functional scores compared with isolated MPFLR in the surgical treatment of recurrent patellar instability in patients with a TT-TG distance of 17–20 mm (20). Another study reported that the use of arthroscopic deepening tracheoplasty combined with MPFLR is a safe, reliable and reproducible surgical option, considering the stability of surgical results, knee function scores and patient satisfaction (21). However, a study showed that MPFLR combined with tuberosities transposition is not superior to isolated MPFLR on Kujala score and KOOS score (22). Moreover, A SurveyMonkey survey of 50 active surgeons in the International Patella Femur Study Group (IPSG) revealed inconsistent results on whether to perform bone surgeries for patients with recurrent patellar dislocation with bone abnormalities (23). So the jury is still out on whether bony surgery is needed.

The type of bundle reconstructed (SB or DB) is also a critical issue worth considering when surgeons conduct MPFLR on patients with patellar dislocation to restore normal patellar function. As previously mentioned, the MPFL is located in the second layer of soft tissue on the medial side of the knee joint and consists of two bundles, the inferior-straight bundle and the superior-oblique bundle respectively (4). A cadaver study reported that the attachment point of the patellofemoral ligament on the side of the patella is flexible and extends from the upper pole of the patella to the midpoint of the patella in a fan shape (24). As mentioned in the literature, the static constraint of medial soft tissue mainly depends on the inferior-straight bundle, while the dynamic constraint mainly depends on the superior-oblique bundle (4). SB-MPFLR which is reconstructed with only one bundle lost the normal patella-femoral ligament anatomy shape and thus lost binding to a larger area, while DB-MPFLR which is reconstructed with two bundles maximally mimicked the fan-shaped structure of the original patellofemoral ligament and thus gaining better constraint on the patella and being able to produce better clinical results. There have been many clinical trials of DB-MPFLR or SB-MPFLR, and the result is that DB-MPFLR is superior to SB-MPFLR on function scores or complications (25–27). This is exactly consistent with the results of our meta-analysis. A RCT of DB-MPFLR was conducted for graft morphology (28). One group was Y-shaped graft, and the other group was C-shaped graft (28). The result is that Y-graft technique was superior to C-graft technique in knee function scores for double bundle anatomic MPFL reconstruction, at a follow-up of at least 2 years (28). Although we have addressed many issues regarding MPFLR, including indications and bundle selection. But there are also many problems left for us, such as graft selection, fixation selection and so on. Therefore, more, larger scale and higher quality clinical studies are needed to find a better way to conduct DB-MPFLR.

Patella dislocation is not only a problem with the medial ligament, but also with the lateral ligament. Many studies have explored DBMPFLR in combination with other procedures. Chang Liu et al. compared the efficacy of different lateral ligament treatments combined with DB-MPFLR, and concluded that lateral retinaculum plasty would achieve better efficacy than lateral retinacular release (29).

The included clinical studies compared the outcomes of different types of surgeries for patellar dislocation (30). We also performed a subgroup analysis of recurrent patellar dislocation. There have been previous meta-analyses comparing MPFLR with other soft tissue surgeries, but either the quality of the included studies was low or there were few studies included. Of course, there are also studies comparing DB-MPFLR and SB-MPFLR, but they are only qualitative analyses. Therefore, this study conducted a meta-analysis of RCTs and provided high-quality evidence for the selection of the most effective methods of surgery.

There are some limitations. The validity of meta-analysis is closely related to the quality of the included studies and the number of studies between each direct comparison. In our study, the number of original studies between each comparison is small,

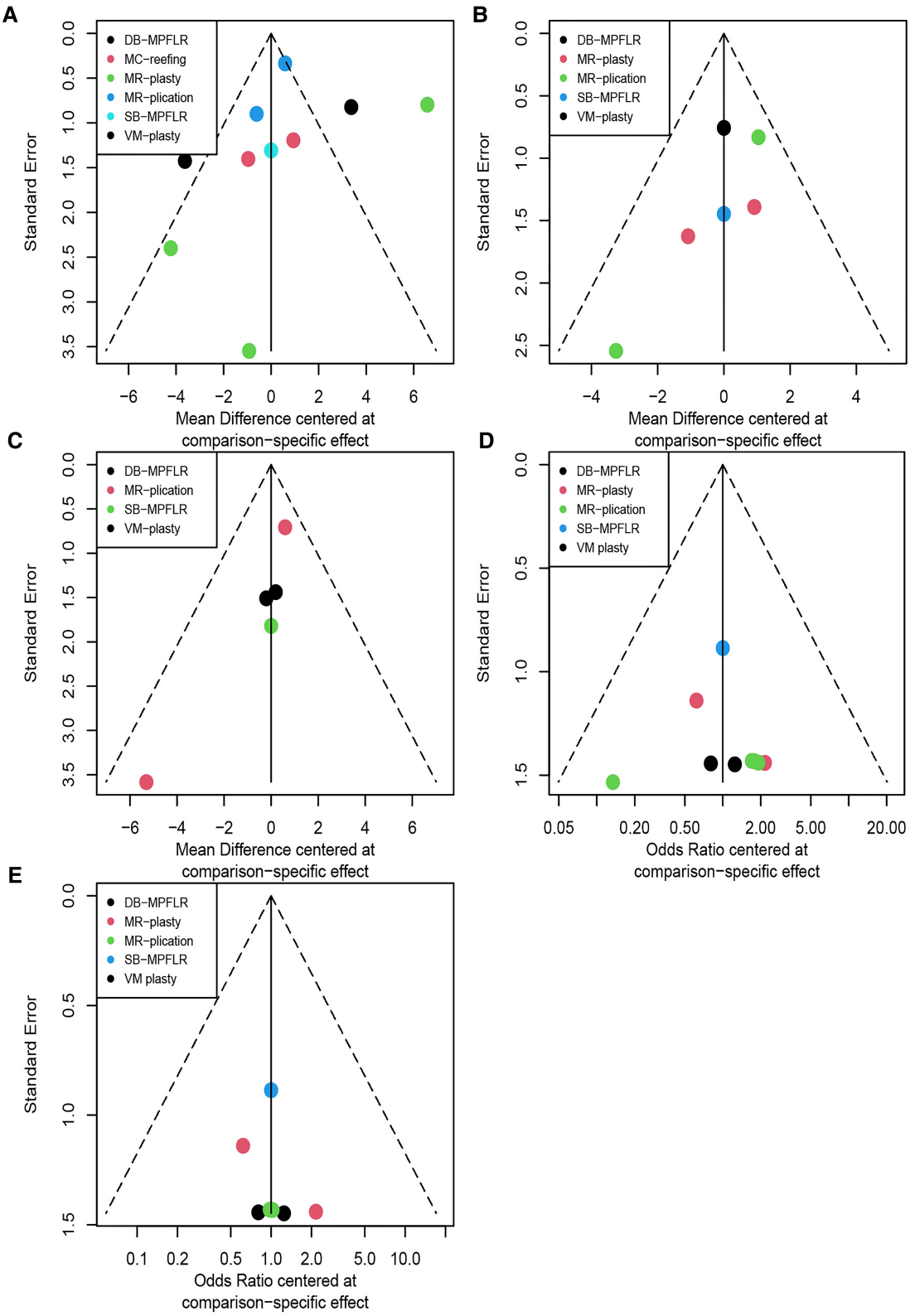

FIGURE 3
Adjusted funnel plot of different surgeries: (A) kujala score; (B) lysholm score; (C) IKDC score; (D) redislocation; (E) recurrent instability.

and a comparison between MR-plication and VM-plasty contains only one original study. Many studies also had few outcome measures, with only the kujala score reported in all studies. Although RCTs are all included in our studies, the randomization methods and whether to allocate hidden are not described in some studies. And the level of evidence in this study

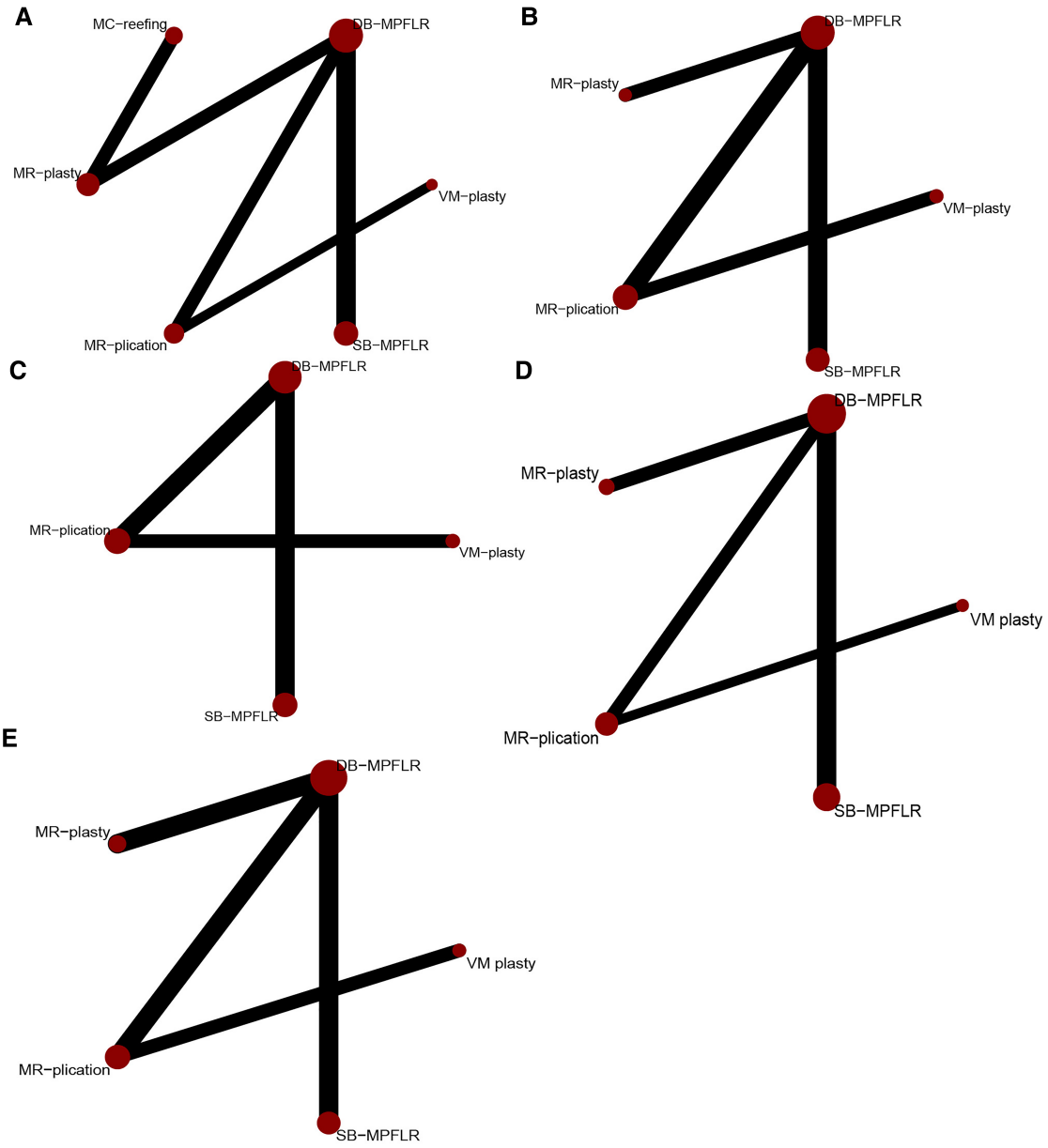

FIGURE 4
Network plot of treatment comparisons: (A) kujala score; (B) lysholm score; (C) IKDC score; (D) redislocation; (E) recurrent instability.

is low or very low. In this study, we only discussed soft tissue surgery for patellar dislocation, while bone surgery was not included, which reduced the source of heterogeneity to a certain extent but also reduced the clinical applicability of this study.

Conclusions

Our study demonstrates that MPFLR results in better functional scores than other soft tissue surgeries. Compared with SB-MPFLR, DB-MPFLR achieved higher scores in Kujala score and IKDC score, and lower scores only in Lysholm score.

Data availability statement

The raw data supporting the conclusions of this article will be made available by the authors, without undue reservation.

Author contributions

MF: design and manuscript writing. ZC: provision of study material, data analysis, and provision of relevant references. YD, YZ and SC were responsible for revising the article and for data acquisition. YW, JG and LP: data analysis and

interpretation. WX: conception, financial support, administrative support. YL: conception, financial support, administrative support. All authors approved the final version for publication.

Funding

This work was supported by the National Clinical Research Center for Geriatric Disorders (Xiangya Hospital, Grant No. 2021KFJJ02 and 2021LNJJ05), National Clinical Research Center for Orthopedics, Sports Medicine and Rehabilitation (2021-NCRC-CXJJ-PY-40), Science and Technology Innovation Program of Hunan Province (No. 2021RC3025), Innovation-Driven Project of Central University South (No. 2020CX045), the Independent Exploration, Innovation Project for Postgraduate Students of Central South University (No. 2021zzts1030), Exploration and Innovation Project for Undergraduate Students South University of Central (No. XCX2021046).

Conflict of interest

The authors declare that the research was conducted in the absence of any commercial or financial relationships that could be construed as a potential conflict of interest.

Publisher's note

All claims expressed in this article are solely those of the authors and do not necessarily represent those of their affiliated organizations, or those of the publisher, the editors and the reviewers. Any product that may be evaluated in this article, or claim that may be made by its manufacturer, is not guaranteed or endorsed by the publisher.

Supplementary material

The Supplementary Material for this article can be found online at: https://www.frontiersin.org/articles/10.3389/fsurg.2023.1003796/full#supplementary-material.

References

1. Majewski M, Susanne H, Klaus S. Epidemiology of athletic knee injuries: a 10-year study. *Knee*. (2006) 13(3):184–8. doi: 10.1016/j.knee.2006.01.005

2. Gravesen KS, Kallemose T, Blønd L, Troelsen A, Barfod KW. High incidence of acute and recurrent patellar dislocations: a retrospective nationwide epidemiological study involving 24.154 primary dislocations. *Knee Surg Sports Traumatol Arthrosc*. (2018) 26(4):1204–9. doi: 10.1007/s00167-017-4594-7

3. Fithian DC, Paxton EW, Stone ML, Silva P, Davis DK, Elias DA, et al. Epidemiology and natural history of acute patellar dislocation. *Am J Sports Med*. (2004) 32(5):1114–21. doi: 10.1177/0363546503260788

4. Kang HJ, Wang F, Chen BC, Su YL, Zhang ZC, Yan CB. Functional bundles of the medial patellofemoral ligament. *Knee Surg Sports Traumatol Arthrosc*. (2010) 18 (11):1511–6. doi: 10.1007/s00167-010-1090-8

5. Sterne JAC, Savović J, Page MJ, Elbers RG, Blencowe NS, Boutron I, et al. Rob 2: A Revised Tool for Assessing Risk of Bias in Randomised Trials. *BMJ (Clinical research ed)*. (2019) 366:l4898. doi: 10.1136/bmj.l4898

6. Zhang Y, Huang L, Wang D, Ren P, Hong Q, Kang D. The Robins-I and the Nos Had Similar Reliability but Differed in Applicability: A Random Sampling Observational Studies of Systematic Reviews/Meta-Analysis. *Journal of Evidence-Based Medicine*. (2021) 14(2):112–22. doi: 10.1111/jebm.12427

7. Efthimiou O, Debray TP, van Valkenhoef G, Trelle S, Panayidou K, Moons KG, et al. Getreal in network meta-analysis: a review of the methodology. *Res Synth Methods*. (2016) 7(3):236–63. doi: 10.1002/jrsm.1195

8. Higgins JP, Thompson SG. Quantifying heterogeneity in a meta-analysis. *Stat Med*. (2002) 21(11):1539–58. doi: 10.1002/sim.1186

9. Salanti G, Ades A, Ioannidis JP. Graphical methods and numerical summaries for presenting results from multiple-treatment meta-analysis: an overview and tutorial. *J Clin Epidemiol*. (2011) 64(2):163–71. doi: 10.1016/j.jclinepi.2010.03.016

10. Nikolakopoulou A, Higgins JP, Papakonstantinou T, Chaimani A, Del Giovane C, Egger M, et al. Cinema: an approach for assessing confidence in the results of a network meta-analysis. *PLoS Med*. (2020) 17(4):e1003082. doi: 10.1371/journal.pmed.1003082

11. Migliorini F, Pilone M, Eschweiler J, Marsilio E, Hildebrand F, Maffulli N. High Rates of Damage to the Medial Patellofemoral Ligament, Lateral Trochlea, and Patellar Crest after Acute Patellar Dislocation: Magnetic Resonance Imaging Analysis. *Arthroscopy: the Journal of Arthroscopic & Related Surgery: Official Publication of the Arthroscopy Association of North America and the International Arthroscopy Association*. (2022) 38(8):2472–9. doi: 10.1016/j.arthro.2022.01.044

12. Jiang B, Qiao C, Shi Y, Ren Y, Han C, Zhu Y, et al. Evaluation of risk correlation between recurrence of patellar dislocation and damage to the medial patellofemoral ligament in different sites caused by primary patellar dislocation by mri: a meta-analysis. *J Orthop Surg Res*. (2020) 15(1):461. doi: 10.1186/s13018-020-01984-0

13. Desio SM, Burks RT, Bachus KN. Soft Tissue Restraints to Lateral Patellar Translation in the Human Knee. *The American Journal of Sports Medicine* (1998) 26(1):59–65. doi: 10.1177/0363546598026001270l

14. Feng X, Wang F. Clinical outcomes of medial retinaculum plasty versus mpfl reconstruction with concomitant tibial tubercle transfer: a retrospective study. *Arch Orthop Trauma Surg*. (2020) 140(11):1759–66. doi: 10.1007/s00402-020-03556-7

15. Wang XL, Wang XL, Peng C, Yang JJ, Hua GJ, Liu YP. Comparative study of three different combination surgical methods for recurrent Patella dislocation. *J Orthop Sci*. (2020) 25(6):1067–71. doi: 10.1016/j.jos.2020.01.008

16. Yeung M, Leblanc MC, Ayeni OR, Khan M, Hiemstra LA, Kerslake S, et al. Indications for Medial Patellofemoral Ligament Reconstruction: A Systematic Review. *The Journal of Knee Surgery* (2016) 29(7):543–54. doi: 10.1055/s-0035-1564730

17. Nelitz M, Dreyhaupt J, Reichel H, Woelfle J, Lippacher S. Anatomic reconstruction of the medial patellofemoral ligament in children and adolescents with open growth plates: surgical technique and clinical outcome. *Am J Sports Med*. (2013) 41(1):58–63. doi: 10.1177/0363546512463683

18. Nelitz M, Dreyhaupt J, Williams SRM. Anatomic reconstruction of the medial patellofemoral ligament in children and adolescents using a pedicled quadriceps tendon graft shows favourable results at a Minimum of 2-year follow-up. *Knee Surg Sports Traumatol Arthrosc*. (2018) 26(4):1210–5. doi: 10.1007/s00167-017-4597-4

19. Christensen TC, Sanders TL, Pareek A, Mohan R, Dahm DL, Krych AJ. Risk factors and time to recurrent ipsilateral and contralateral patellar dislocations. *Am J Sports Med*. (2017) 45(9):2105–10. doi: 10.1177/0363546517704178

20. Franciozi CE, Ambra LF, Albertoni LJB, Debieux P, Granata GSM Jr., Kubota MS, et al. Anteromedial tibial tubercle osteotomy improves results of medial patellofemoral ligament reconstruction for recurrent patellar instability in patients with tibial tuberosity-trochlear groove distance of 17 to 20 mm. *Arthroscopy*. (2019) 35(2):566–74. doi: 10.1016/j.arthro.2018.10.109

21. Blønd L, Haugegaard M. Combined arthroscopic deepening trochleoplasty and reconstruction of the medial patellofemoral ligament for patients with recurrent Patella dislocation and trochlear dysplasia. *Knee Surg Sports Traumatol Arthrosc*. (2014) 22(10):2484–90. doi: 10.1007/s00167-013-2422-2

22. Mulliez A, Lambrecht D, Verbruggen D, Van Der Straeten C, Verdonk P, Victor J. Clinical outcome in mpfl reconstruction with and without tuberositas transposition. *Knee Surg Sports Traumatol Arthrosc*. (2017) 25(9):2708–14. doi: 10.1007/s00167-015-3654-0

23. Liu JN, Steinhaus ME, Kalbian IL, Post WR, Green DW, Strickland SM, et al. Patellar instability management: a survey of the international patellofemoral study group. *Am J Sports Med*. (2018) 46(13):3299–306. doi: 10.1177/0363546517732045

24. Steensen RN, Dopirak RM, McDonald WG 3rd. The anatomy and isometry of the medial patellofemoral ligament: implications for reconstruction. *Am J Sports Med*. (2004) 32(6):1509–13. doi: 10.1177/0363546503261505

25. Marteau E, Burdin P, Brilhault JM. Gracilis tendon transfer associated with distal alignment for Patella Alta with recurrent dislocations: an original surgical technique. *Orthop Traumatol Surg Res*. (2011) 97(4Suppl):S5–S11. doi: 10.1016/j.otsr.2011.03.013

26. Steensen RN, Dopirak RM, Maurus PB. A simple technique for reconstruction of the medial patellofemoral ligament using a quadriceps tendon graft. *Arthroscopy*. (2005) 21(3):365–70. doi: 10.1016/j.arthro.2004.10.007

27. Wang CH, Ma LF, Zhou JW, Ji G, Wang HY, Wang F, et al. Double-Bundle anatomical versus single-bundle isometric medial patellofemoral ligament reconstruction for patellar dislocation. *Int Orthop*. (2013) 37(4):617–24. doi: 10.1007/s00264-013-1788-6

28. Kang H, Cao J, Yu D, Zheng Z, Wang F. Comparison of 2 different techniques for anatomic reconstruction of the medial patellofemoral ligament: a prospective randomized study. *Am J Sports Med*. (2013) 41(5):1013–21. doi: 10.1177/0363546513480468

29. Liu C, Duan G, Niu Y, Cao P, Fu K, Niu J, et al. Lateral retinaculum plasty instead of lateral retinacular release with concomitant medial patellofemoral ligament reconstruction can achieve better results for patellar dislocation. *Knee Surg Sports Traumatol Arthrosc*. (2018) 26:2899–905. doi: 10.1007/s00167-017-4798-x

30. Malatray M, Magnussen R, Lustig S, Servien E. Lateral retinacular release is not recommended in association to mpfl reconstruction in recurrent patellar dislocation. *Knee Surg Sports Traumatol Arthrosc*. (2019) 27:2659–64. doi: 10.1007/s00167-018-5294-7

31. Du H, Tian XX, Guo FQ, Li XM, Ji TT, Li B, et al. Evaluation of different surgical methods in treating recurrent patella dislocation after three-dimensional reconstruction. *Int Orthop*. (2017) 41(12):2517–24. doi: 10.1007/s00264-017-3552-9

32. Zhao J, Huangfu X, He Y. The role of medial retinaculum plication versus medial patellofemoral ligament reconstruction in combined procedures for recurrent patellar instability in adults. *Am J Sports Med*. (2012) 40(6):1355–64. doi: 10.1177/0363546512439193

33. Ma LF, Wang F, Chen BC, Wang CH, Zhou JW, Wang HY. Medial retinaculum plasty versus medial patellofemoral ligament reconstruction for recurrent patellar instability in adults: a randomized controlled trial. *Arthroscopy*. (2013) 29(5):891–7. doi: 10.1016/j.arthro.2013.01.030

34. Niu Y, Wang X, Liu C, Wang X, Dong Z, Niu J, et al. Double-Bundle Anatomical Medial Patellofemoral Ligament Reconstruction with Lateral Retinaculum Plasty Can Lead to Good Outcomes in Patients with Patellar Dislocation. *Knee Surgery, Sports Traumatology, Arthroscopy: Official Journal of the ESSKA* (2018) 26(9):2743–9. doi: 10.1007/s00167-017-4720-6

35. Li J, Li Z, Wang K, Liu C, Wang Y, Wang H. Medial patellofemoral ligament reconstruction: a comparison of single-bundle transpatellar tunnel and double-anchor anatomic techniques for the treatment of recurrent lateral patellar dislocation in adults. *Arthroscopy*. (2019) 35(3):845–54. doi: 10.1016/j.arthro.2018.08.050

36. Ercan N, Akmese R, Ulusoy B. Single-tunnel and double-tunnel medial patellofemoral ligament reconstructions have similar clinical. Radiological and Functional Results. *Knee Surg Sports Traumatol Arthrosc*. (2021) 29(6):1904–12. doi: 10.1007/s00167-020-06260-6

37. Astur DC, Gouveia GB, Borges JH, Astur N, Arliani GG, Kaleka CC, et al. Medial patellofemoral ligament reconstruction: a longitudinal study comparison of 2 techniques with 2 and 5-years follow-up. *Open Orthop J*. (2015) 9:198–203. doi: 10.2174/1874325001509010198

38. Zhao J, Huangfu X, He Y, Liu W. Recurrent patellar dislocation in adolescents: medial retinaculum plication versus Vastus Medialis plasty. *Am J Sports Med*. (2012) 40(1):123–32. doi: 10.1177/0363546511420551

39. Ma LF, Wang F, Chen BC, Wang CH, Zhou JW, Ji G, et al. Medial patellar retinaculum plasty versus medial capsule reefing for patellar subluxation in adult. *Orthop Surg*. (2012) 4(2):83–8. doi: 10.1111/j.1757-7861.2012.00178.x

40. Ma LF, Wang CH, Chen BC, Zhang F, Zhou JW, Dong JT, et al. Medial patellar retinaculum plasty versus medial capsule reefing for patellar dislocation in children and adolescents. *Arch Orthop Trauma Surg*. (2012) 132(12):1773–80. doi: 10.1007/s00402-012-1598-0

frontiers | Frontiers in Surgery

TYPE Original Research
PUBLISHED 03 April 2023
DOI 10.3389/fsurg.2023.1041578

Check for updates

OPEN ACCESS

EDITED BY
Marcone Lima Sobreira,
Sao Paulo State University, Brazil

REVIEWED BY
Jingxin Yan,
Qinghai University, China
Rafael De Athayde Soares,
Hospital do Servidor Público Estadual, Brazil

*CORRESPONDENCE
Patarawan Woratanarat
✉ pataraw@yahoo.com

SPECIALTY SECTION
This article was submitted to Orthopedic Surgery, a section of the journal Frontiers in Surgery

RECEIVED 11 September 2022
ACCEPTED 15 March 2023
PUBLISHED 03 April 2023

CITATION
Tongta S, Angsnuntsukh C, Saisongcroh T, Woratanarat T, Tangsopa Y and Woratanarat P (2023) Deep vein thrombosis screening in pediatric orthopedic patients.
Front. Surg. 10:1041578.
doi: 10.3389/fsurg.2023.1041578

COPYRIGHT
© 2023 Tongta, Angsanuntsukh, Saisongcroh, Woratanarat, Tangsopa and Woratanarat. This is an open-access article distributed under the terms of the Creative Commons Attribution License (CC BY). The use, distribution or reproduction in other forums is permitted, provided the original author(s) and the copyright owner(s) are credited and that the original publication in this journal is cited, in accordance with accepted academic practice. No use, distribution or reproduction is permitted which does not comply with these terms.

Deep vein thrombosis screening in pediatric orthopedic patients

Saowalak Tongta[1], Chanika Angsnuntsukh[1], Tanyawat Saisongcroh[1], Thira Woratanarat[2], Yaowaret Tangsopa[1] and Patarawan Woratanarat[1]*

[1]Department of Orthopedics, Faculty of Medicine Ramathibodi Hospital, Mahidol University, Bangkok, Thailand, [2]Department of Preventive and Social Medicine, Faculty of Medicine, Chulalongkorn University, Bangkok, Thailand

Background: Deep vein thrombosis (DVT) is an important clinical condition that leads to subsequent morbidity and mortality in children, particularly those who involved operative procedures. The preoperative assessment for DVT in children may vary among different population risk factors and types of surgery. This study aimed to evaluate the screening methods for DVT in pediatric orthopedic patients.
Method: We performed a retrospective cohort study of orthopedic patients aged <18 years at Ramathibodi Hospital, Bangkok, Thailand, from 2015 to 2019. The inclusion criteria were children scheduled for orthopedic surgery; who performed a D-dimer test, Wells score, and Caprini score; and who underwent Doppler ultrasonography for DVT screening. The exclusion criteria were incomplete data or inconclusive ultrasonographic results. Age and results of the D-dimer test, Wells score, and Caprini score were collected from all patients. The outcome assessment was ultrasound-proven DVT. The screening abilities of each test were analyzed in terms of sensitivity, specificity, positive predictive value (PPV), negative predictive value (NPV), likelihood ratio (LR) for positive and negative tests, and area under the receiver operating characteristic curve (AUC).
Results: A total of 419 children were included in the study. Five (1.19%) patients were diagnosed with DVT. The mean age was 10.16 ± 4.83 years. D-dimer ≥500 ng/mL had a sensitivity of 100% (95% CI: 47.8%–100%), a specificity of 36.7% (95% CI: 32.1%–41.6%), a PPV of 1.9% (95% CI: 0.6%–4.3%), and an NPV of 100% (95% CI: 97.6%–100%). Wells score ≥3 demonstrated a sensitivity of 0% (95% CI: 0%–52.2%), a specificity of 99.3% (95% CI: 97.9%–99.9%), and an LR for a negative test of 1.00 (95% CI: 1.00–1.01). Caprini score ≥11 had a sensitivity of 0% (95% CI: 0%–52.2%) and a specificity of 99.8% (95% CI: 98.7%–100%). The parallel test included D-dimer ≥500 ng/mL, Wells score ≥3, or Caprini score ≥11 points, generating a sensitivity of 100% (95% CI: 47.8%–100%), a specificity of 36.7% (95% CI: 32.1%–41.6%), an LR for a positive test of 1.58 (95% CI: 1.47–1.70), and an AUC of 0.68 (95% CI: 0.66–0.71).
Conclusions: The D-dimer test exhibited moderate ability in predicting the development of DVT among pediatric orthopedic patients requiring surgery. The Wells score and Caprini score had low performance in identifying hospitalized children at increased risk of DVT events.

KEYWORDS

Caprini score, D-dimer, Doppler ultrasound, Wells score, sensitivity

1. Introduction

Deep vein thrombosis (DVT) is blood clot formation caused by venous stasis, vascular damage, and hypercoagulability (1). DVT occasionally occurs in children (2), with an average incidence of 0.07 per 10,000 children and 3.9–5.1 per 10,000 hospital admissions (3, 4). It is commonly found in early infancy (20%) and adolescence (50%) (5, 6). Venous

thromboembolism (VTE) occurs in children undergoing orthopedic surgery at approximately 0.05% per hospital admission (3). Assessments of DVT are often made after having severe symptoms or life-threatening conditions (7). Therefore, a proper screening method would benefit early detection, early prevention, and treatment.

According to the American Society of Hematology guideline, noninvasive Doppler ultrasonography is a standard preoperative DVT screening technique (8). However, it is costly, operator-dependent, and requires experienced radiologists and surgeons. Alternate screening tools, such as the D-dimer test (sensitivity 78%–97%) (9), Wells score (sensitivity 67%) (10), and Caprini score (sensitivity 83%) (11), have been developed to identify high-risk patients. These parallel tests may detect proper cases for Doppler ultrasonography, minimize medical expenses, and save time. Moreover, these tools help reduce excess workload of ultrasound performers, especially in highly demanded institutes.

To prevent perioperative complications, preoperative DVT screening has been currently integrated into our routine clinical service system at Ramathibodi Hospital, a 1,100-bed university hospital in Bangkok, Thailand. All patients were registered in the Department of Orthopedics Database for 5 years (2015–2019). However, the screening abilities may be affected by the incidence rate of DVT, age, race, body mass index (BMI), underlying diseases, and operative procedures (3). To provide a safe and sound service system for pediatric orthopedic patients, it is necessary to find the appropriate screening methods and cutoff values to detect DVT in children who underwent orthopedic surgery. This study aimed to evaluate the DVT screening methods in pediatric orthopedic patients including the D-dimer test, Wells score, and Caprini score compared with the gold standard techinque, Doppler ultrasonography.

2. Methods

A retrospective cohort study was conducted by retrieving medical records and the preoperative DVT screening database from the Department of Orthopaedics, Faculty of Medicine Ramathibodi Hospital, Mahidol University, Bangkok, Thailand. All patients admitted to the orthopedic ward from 2015 to 2019 were assessed for eligibility. The inclusion criteria were children aged under 18 years; scheduled for orthopedic surgery; who performed the D-dimer test, Wells score, and Caprini score; and who underwent Doppler ultrasonography for DVT screening. The exclusion criteria were incomplete data or inconclusive ultrasonographic results. This study was approved by the Institutional Review Board (MURA2020/249).

Patient information, including age, type of surgery, DVT prophylaxis (mechanical/pharmacological methods), diagnostic tests (D-dimer test, Wells score, Caprini score), and the gold standard test (Doppler ultrasonography), was reviewed and documented. Additionally, we recorded high-risk patients with risk factors such as cancer, immobility, obesity, heart attack, congestive heart failure, infection, fracture, spinal cord injury, history of DVT, and family history of DVT. The D-dimer test, Wells score, and Caprini score were routinely evaluated for every hospitalized child before surgery. D-dimer assays were analyzed by the Clinical Laboratory Center of Ramathibodi Hospital, and cutoff level ≥500 ng/mL was set for suspected DVT. The Wells score comprises leg conditions, history of DVT/cancer, and bedridden/major surgery and is evaluated as a cumulative risk score (0–10) by orthopedic residents. Wells score ≥3 was considered a high probability of DVT. The Caprini score (0–59) was defined by baseline characteristics, surgery, history of VTE, underlying diseases, and leg conditions. Caprini score ≥11 was determined a high risk of DVT. If the D-dimer level, Wells score, or Caprini score indicated a risk of DVT, patients were brought to ultrasonographic diagnosis. Doppler ultrasound (Aplio 500; Canon Inc., Tokyo, Japan) for lower extremities was performed by well-trained radiologists or surgeons.

Statistical analysis was performed using the STATA software package, version 15.0 (Stata Corp, College Station, TX, USA). The demographic characteristics of the sample were presented as frequencies, percentages, means, and standard deviations. The association of screening was calculated using the χ^2 test. The D-dimer test, Wells score, and Caprini score were compared with the gold standard, Doppler ultrasound. The screening abilities of each test were calculated as sensitivities, specificities, positive predictive values (PPVs), negative predictive values (NPVs), likelihood ratios (LRs) of positive and negative tests, odds ratios (ORs), and 95% confidence intervals (CIs). The receiver operating characteristic curve (ROC) was plotted by referring to sensitivity vs.1 − specificity. The areas under the curve (AUCs) and cutoff values were also computed. The significant p-value was set as <0.05. The sample size was calculated based on an alpha error of 0.05, a beta error of 0.2, a sensitivity of 99%, and an error of 10%, and the incidence of DVT was 1%. The total sample size was 404.

3. Results

3.1. Participant's demographic data

From 6,201 screened cases, 419 children met the inclusion criteria. The incidence of DVT was 1.19%. The mean age of children was 10.16 ± 4.83 years. The most common operation was pediatric orthopedic surgery (56.56%), followed by tumor surgery (12.41%) and hand surgery (10.95%). None of the participants received any mechanical or pharmacological DVT prophylaxis. According to the risk of DVT, 63.72% of children had D-dimer ≥500 ng/mL, 0.72% had a Wells score ≥3, and 0.24% had a Caprini score ≥11. The characteristics of the patients are presented in **Table 1**.

3.2. Relationship with DVT

Regarding the predictive factors for developing DVT, the DVT patients showed a significant difference in the Wells score (p = 0.043) compared to the non-DVT group. However, there were

TABLE 1 Patient characteristics.

Variables	Number ($N = 419$)
Age (years), mean (SD)	10.16 (4.83)
Type of surgery (%)	
Foot and ankle	4 (0.95)
Hand	46 (10.95)
Pediatric	237 (56.56)
Trauma	29 (6.92)
Tumor	52 (12.41)
Spine	28 (6.68)
Sport	16 (3.82)
Hip and knee	7 (1.67)
D-dimer (%)	
≥500 ng/mL	267 (63.72)
<500 ng/mL	152 (36.28)
Wells score (%)	
≥3	3 (0.72)
<3	416 (99.28)
Caprini score (%)	
≥11	1 (0.24)
<11	418 (99.76)
Doppler ultrasound (%)	
DVT	5 (1.19)
No DVT	414 (98.81)

SD, standard deviation; DVT, deep vein thrombosis.

nonsignificant differences in age ($p = 0.865$), D-dimer level ($p = 0.817$), and Caprini score ($p = 0.043$) between both groups (Table 2).

3.3. Performance of screening tests

3.3.1. D-dimer test

The sensitivity of the D-dimer test to detect DVT was as high as 100% (95% CI: 47.8%–100%), and the specificity was 36.7% (95% CI: 32.1%–41.6%) (Table 3). The PPV was 1.9% (95% CI: 0.6%–4.3%), and the NPV was 100% (95% CI: 97.6%–100%). The LR of a positive test was 1.58 (95% CI: 1.47–1.70). The D-dimer test demonstrated good performance with an AUC of 0.68 (95% CI: 0.66–0.70) (Figure 1). Since DVT prophylaxis was not administered, the effects of anticoagulants on the D-dimer could not be assessed.

TABLE 2 Comparisons between DVT and non-DVT groups.

Variables, mean (SD)	Doppler ultrasound		*p*-value
	DVT ($N = 5$)	Non-DVT ($N = 414$)	
Age (years)	9.80 (4.83)	10.17 (5.59)	0.865
D-dimer (ng/mL)	2,155.20 (1,113.46)	3,739.65 (15,313.72)	0.817
Wells score	0.40 (0.89)	0.07 (0.35)	0.043*
Caprini score	2.20 (1.67)	1.07 (1.66)	0.135

DVT, deep vein thrombosis; SD, standard deviation.
*Significant *p*-value <0.05.

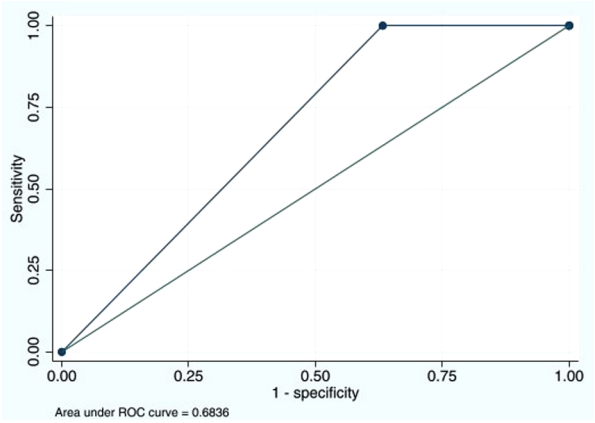

FIGURE 1
Area under the ROC curve of D-dimer cutoff ≥500 ng/mL of 0.6836. ROC, receiver operating characteristic.

3.3.2. Wells score

Wells score ≥3 could detect DVT with a sensitivity of 0% (95% CI: 0%–52.2%) and a specificity of 99.3% (95% CI: 97.9%–99.9%). The PPV was 0% (95% CI: 0%–70.8%), and the NPV was 98.8% (95% CI: 97.2%–99.6%). The LR for a negative test was 1.01 (95% CI: 1.00–1.02). The AUC was 0.49 (95% CI: 0.49–0.50) (Figure 2).

3.3.3. Caprini score

Caprini score ≥11 for DVT had a sensitivity of 0% (95% CI: 0%–52.2%), a specificity of 99.8% (95% CI: 98.7%–100%), a PPV of 0% (95% CI: 0%–97.5%), and an NPV of 98.8% (95% CI: 97.2%–99.6%). The LR for a negative test was 1.00 (95% CI: 1.00–1.01). The AUC was 0.49 (95% CI: 0.49–0.50) (Figure 3).

3.3.4. Combination of screening tests

The combination of D-dimer ≥500 ng/mL and Wells score ≥3 provided a sensitivity of 0% (95% CI: 0%–52.2%), a specificity of

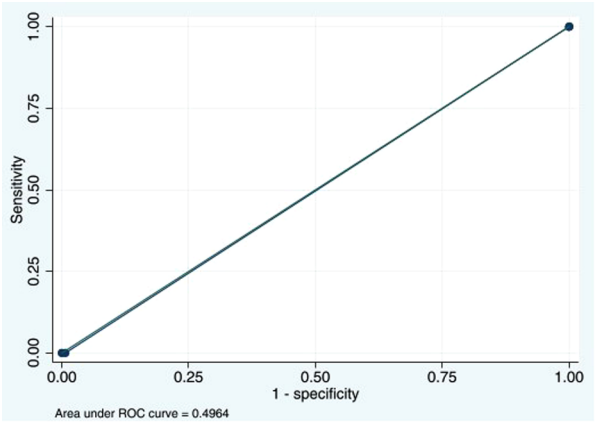

FIGURE 2
Area under the ROC curve at Wells score ≥3 cutoff point of 0.4964. ROC, receiver operating characteristic.

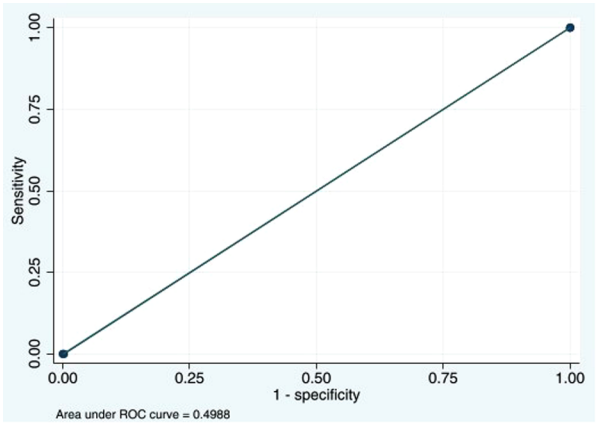

FIGURE 3
Area under the ROC curve at Caprini score ≥11 of 0.4988. ROC, receiver operating characteristic.

99.3% (95% CI: 97.9%–99.9%), a PPV of 0% (95% CI: 0%–70.8%), an NPV of 98.8% (95% CI: 97.2%–99.6%), and an LR for a negative test of 1.01 (95% CI: 1.00–1.02).

The combination of D-dimer ≥500 ng/mL and Caprini score ≥11 points had a sensitivity of 0% (95% CI: 0%–52.2%), a specificity of 99.8% (95% CI: 98.7%–100%), a PPV of 0% (95% CI: 0%–97.5%), an NPV of 98.8% (95% CI: 97.2%–99.6%), and an LR for a negative test of 1.00 (95% CI: 1.00–1.01) for DVT diagnosis.

For a combination of D-dimer ≥500 ng/mL and Wells score ≥3, the sensitivity was 100% (95% CI: 47.8%–100%), specificity was 36.7% (95% CI: 32.1%–41.6%), PPV was 1.9% (95% CI: 0.6%–4.3%), NPV was 100% (95% CI: 97.6%–100%), AUC was 0.68 (95% CI: 0.66–0.71), and LR for a positive test was 1.58 (95% CI: 1.47–1.70).

The combination of D-dimer ≥500 ng/mL and Caprini score ≥11 points and the parallel test including either D-dimer ≥500 ng/mL, Wells score ≥3, or Caprini score ≥11 points generated the same diagnostic abilities as the combination of D-dimer test ≥500 ng/mL and Wells score ≥3 (Table 3).

4. Discussion

DVT is a life-threatening condition leading to high morbidity and mortality. Identifying those who are at higher risk of developing DVT is essential to prevent fatal outcomes. This study evaluated the utility of the preoperative screening tests for DVT in children. The D-dimer test demonstrated the highest sensitivity of 100% (95% CI: 47.8%–100%) with moderate specificity of 36.7% (95% CI: 32.1%–41.6%). The Wells score, Caprini score, or combined scores provided very low sensitivity (0%–23%) with high specificity (>99%).

The development of DVT in hospitalized children is rare compared with hospitalized adults (12). Vascular endothelium in children has not deteriorated from diseases such as hypertension, diabetes, or hypercholesterolemia and other factors such as smoking or oral contraceptives (13, 14). Yen et al. estimated an incidence of 0.28% (15) among pediatric traumatic injuries and identified many risk factors to improve diagnostic sensitivity and accuracy. The incidence of DVT in our study (1.19%) was greater than the reported annual incidence (0.07–0.14 per 10,000 children) (2, 16) from other studies as well as the first report of DVT in Thai children (0.04%) in 2007 (4). The explanation for the higher incidence in this study is that we included only patients with a high risk of DVT (either D-dimer ≥500 ng/mL, Wells score ≥3, or Caprini score ≥11 points) to directly compare the utility of the screening tests used in our clinical practice and the gold standard.

The D-dimer test showed high sensitivity but relatively intermediate specificity at cutoff ≥500 ng/mL and AUC at 0.7. Our test performance was similar to that in Kanis et al. (17) and other previous studies (18, 19) that demonstrated high sensitivity of the D-dimer test for DVT. Additionally, a meta-analysis in adults by Stein et al. reported that the sensitivity and specificity of the D-dimer test at cutoff >500 ng/mL ranged from 78% to 97% and 42% to 70%, respectively (9). Nevertheless, the diagnostic ability may relate to patients' characteristics, age, underlying conditions, D-dimer assays, and the chosen cutoff values (19). The D-dimer in our study had 100% sensitivity and 100% NPV, but the specificity and PPV for DVT were quite low. From our thorough analysis, we have identified new cutoff values at 795 ng/mL to improve the diagnostic performance. This level provided a sensitivity of 100% (95% CI: 47.8%–100%), a specificity of 50.7% (95% CI: 45.8%–55.6%), and an AUC of 0.8 (95% CI: 0.7%–0.8%), as shown in Figure 4. The review of studies in children with the D-dimer test for DVT is shown in Table 4.

Although the Wells score was used to determine the probability of developing DVT in patients, its screening efficacy, specifically in children, has not been reported. Our study presented the largest sample of children and found that Wells score ≥3 had a sensitivity of 0% (95% CI: 0–52.2) and a specificity of 99.3% (95% CI: 97.9–99.9). Their results showed high specificity without sensitivity for DVT. The Wells score performed poor discrimination (AUC, 0.49) to spot the risk of DVT in pediatric orthopedic patients requiring surgery. Silveira et al. reported a low discriminatory rate of the Wells score for inpatients (AUC, 0.56) (20). Nevertheless, a high Wells score is associated with an increased probability of DVT (10, 21). Our results suggest that the Wells score risk stratification might not be applicable for pediatric orthopedic patients due to different risk factors of DVT between children and adults (14).

Patients with higher Caprini scores were correlated with an increased likelihood of VTE events. The Caprini score of 11 can identify the high-risk subgroup among patients requiring surgery. From our study, Caprini score ≥11 hardly rules out the possibility of DVT with a sensitivity of 23.9% (95% CI: 17.9%–30.8%), but it effectively rules in with a specificity of 99.1% (95% CI: 98.8%–99.3%). Contrarily, Luksameearunothai et al. reported the sensitivity and specificity of Caprini score ≥12 among the elderly of 93% and 35%, respectively (22). Hachey et al. also found that the Caprini score produced a sensitivity of 83.3% and

TABLE 3 Performance of screening in predicting DVT in pediatric orthopedic patients.

Tests	Doppler ultrasound (%)		Sensitivity (95% CI)	Specificity (95% CI)	PPV (95% CI)	NPV (95% CI)	Accuracy (95% CI)	LR+ (95% CI)	LR− (95% CI)	ROC area (95% CI)	OR (95% CI)
	DVT ($N = 5$)	No DVT ($N = 414$)									
D-dimer ≥500 ng/mL	5 (100)	262 (63.3)	100 (47.8–100)	36.7 (32.1–41.6)	1.9 (0.6–4.3)	100 (97.6–100)	37.5 (32.8–42.3)	1.6 (1.5–1.7)	0	0.7 (0.7–0.7)	–
Wells score ≥3	0 (0)	3 (0.7)	0 (0–52.2)	99.3 (97.9–99.9)	0 (0–70.8)	98.8 (97.2–99.6)	98.1 (96.3–99.2)	0	1.0 (1.0–1.0)	0.5 (0.5–0.5)	0 (0–125.2)
Caprini ≥11	0 (0)	1 (0.2)	0 (0–52.2)	99.8 (98.7–100)	0 (0–97.5)	98.8 (97.2–99.6)	98.5 (96.9–99.4)	0	1.0 (1.0–1.0)	0.5 (0.5–0.5)	0
D-dimer ≥500 ng/mL and Wells ≥3	0 (0)	3 (0.7)	0 (0–52.2)	99.3 (97.9–99.9)	0 (0–70.8)	98.8 (97.2–99.6)	98.1 (96.3–99.2)	0	1.0 (1.0–1.0)	0.5 (0.5–0.5)	0 (0–125.2)
D-dimer ≥500 ng/mL and Caprini ≥11	0 (0)	1 (0.2)	0 (0–52.2)	99.8 (98.7–100)	0 (0–97.5)	98.8 (97.2–99.6)	98.5 (96.9–99.4)	0	1.0 (1.0–1.0)	0.5 (0.5–0.5)	0
D-dimer ≥500 ng/mL or Wells > 3	5 (100)	262 (63.3)	100 (47.8–100)	36.7 (32.1–41.6)	1.9 (0.6–4.3)	100 (97.6–100)	37.5 (32.8–42.3)	1.6 (1.5–1.7)	0	0.7 (0.7–0.7)	–
D-dimer ≥500 ng/mL or Caprini ≥11	5 (100)	262 (63.3)	100 (47.8–100)	36.7 (32.1–41.6)	1.9 (0.6–4.3)	100 (97.6–100)	37.5 (32.8–42.3)	1.6 (1.5–1.7)	0	0.7 (0.7–0.7)	–
D-dimer ≥500 ng/mL or Wells score ≥3 or Caprini ≥11	5 (100)	262 (63.3)	100 (47.8–100)	36.7 (32.1–41.6)	1.9 (0.6–4.3)	100 (97.6–100)	37.5 (32.8–42.3)	1.6 (1.5–1.7)	0	0.7 (0.7–0.7)	–

DVT, deep vein thrombosis; PPV, positive predictive value; NPV, negative predictive value; LR+, likelihood ratio for a positive test; LR−, likelihood ratio for a negative test; ROC, receiver operating characteristic; OR, odds ratio; CI, confidence interval.

TABLE 4 Reviews of studies with D-dimer tests for deep vein thrombosis.

Author	Year	No. patients	Age (year)	Cutoff (ng/mL)	Sensitivity (%)	Specificity (%)
Strouse et al. (19)	2009	33	0–21	1,500	96	43
Kanis et al. (17)	2018	526	5–17	500	89	56
This study	2022	419	0–18	500	100	37
This study	2022	419	0–18	795	100	51

10.3389/fsurg.2023.1041578

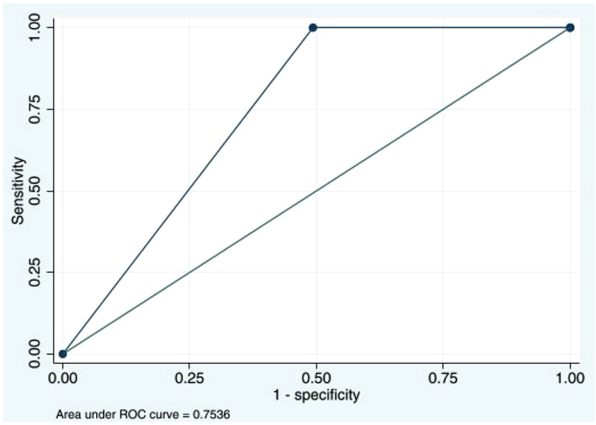

FIGURE 4
Area under the ROC curve of D-dimers with the new cutoff value at 795 ng/mL of 0.7536. ROC, receiver operating characteristic.

a specificity of 60.5% among patients who underwent lung cancer resection (11). We suggest that the preoperative Caprini score may not be used to identify DVT risk among children who underwent orthopedic surgery.

Based on the ROC analysis, the AUC of the D-dimer test has a high utility in the diagnosis of DVT. We tried to combine the scores in a serial or parallel test. The combination of the D-dimer and Wells score resulted in 0% sensitivity, 99.8% specificity, 0% PPV, and 98.8% NPV. For the parallel test, they had the same diagnostic values as those of the D-dimer test, i.e., 100% sensitivity, 36.7% specificity, 1.9% PPV, and 100% NPV, for DVT diagnosis. Therefore, combining other tests with the D-dimer test did not provide better diagnostic abilities.

Surgical procedure is one of the major risk factors, especially for those with longer operative times and longer hospital stays (23). In addition, underlying diseases or types of surgery might influence the incidence of DVT. Of five DVT cases in our study, three had undergone tumor surgery, one pediatric surgery, and one spine surgery. Our results demonstrate that 60% of DVT cases underwent tumor surgery. This reflects that the malignancy may be strongly associated with DVT (13, 24, 25). This association could be explained by several mechanisms. First, the tumor may put pressure on the vein, resulting in blood cell stasis and endothelial damage in the blood vessels. Others may include cancer-associated thrombosis due to the direct effect of the cancer cells on stimulating blood clot formation, secreting platelets and thrombin, and increasing the risk of developing deep vein thrombosis (26, 27). From our study, the average D-dimer level of orthopedic tumor cases was significantly lower than that of non-tumor patients ($p = 0.042$). However, there was no significant difference in the high D-dimer level cutoff of 500 ng/mL between the tumor (55.8%) and non-tumor (64.9%) groups with p-value = 0.202. The explanation is that conditions other than tumors, such as trauma, infection, inflammation, cardiac, and renal diseases, also contribute to D-dimer elevation, possibly by fibrin clot activation (18).

The strengths of this study are that we conducted it on the registered database with a standardized data collection form and a well-established system with integrated DVT screening tests in routine clinical services. There are still some limitations as our design is a retrospective study. First, database review may have unknown or unreported history leading to underestimating certain DVT risks. Second, the radiologists and surgeons who performed the Doppler ultrasound may be aware of the screening test results. Third, the incidence of DVT may be overestimated due to the inclusion of the cases with at least one screening test positive as a prerequisite for Doppler ultrasonography. However, this represented the real situation for DVT screening in our context. Finally, diagnostic abilities showed a wide and imprecise 95% CI of odds ratio (Table 4), reflecting the small sample size of the study. Since the incidence of DVT is very low in children, recruitment of more study populations would be of value for future research.

5. Conclusion

The D-dimer test produces moderate performance in predicting the development of DVT. However, the Wells score and Caprini score had poor performance. Even though clinical assessment tools are practical and useful for categorizing risks of DVT, we recommend the D-dimer test for preoperative DVT screening in pediatric orthopedic patients. Based on this study, a D-dimer cutoff value of 795 ng/mL is the most appropriate for DVT screening among pediatric orthopedic patients requiring surgery. A further study is needed to externally validate the new D-dimer cutoff value.

Data availability statement

The original contributions presented in the study are included in the article/Supplementary Material; further inquiries can be directed to the corresponding author.

Ethics statement

The studies involving human participants were reviewed and approved by the Human Research Ethics Committee, Faculty of Medicine Ramathibodi Hospital, Mahidol University. Written informed consent from the participants' legal guardian/next of kin was not required to participate in this study in accordance with the national legislation and institutional requirements.

Author contributions

ST, CA, TS, TW, YT, and PW contributed to the research design and data review. ST, CA, YT, and PW performed data collection and analysis. ST, TW, and PW performed data interpretation. ST, CA, TW, and PW contributed to writing and

critically revising the manuscript. All authors contributed to the article and approved the submitted version.

Conflict of interest

The authors declare that the research was conducted in the absence of any commercial or financial relationships that could be construed as a potential conflict of interest.

Publisher's note

All claims expressed in this article are solely those of the authors and do not necessarily represent those of their affiliated organizations, or those of the publisher, the editors and the reviewers. Any product that may be evaluated in this article, or claim that may be made by its manufacturer, is not guaranteed or endorsed by the publisher.

References

1. Di Nisio M, van Es N, Büller HR. Deep vein thrombosis and pulmonary embolism. *Lancet*. (2016) 388:3060–73. doi: 10.1016/S0140-6736(16)30514-1

2. Andrew M, David M, Adams M, Ali K, Anderson R, Barnard D, et al. Venous thromboembolic complications (VTE) in children: first analyses of the Canadian registry of VTE. *Blood*. (1994) 83:1251–7. doi: 10.1182/blood.V83.5.1251.1251

3. Georgopoulos G, Hotchkiss MS, McNair B, Siparsky G, Carry PM, Miller NH. Incidence of deep vein thrombosis and pulmonary embolism in the elective pediatric orthopaedic patient. *J Pediatr Orthop*. (2016) 36:101–9. doi: 10.1097/bpo.0000000000000391

4. Sirachainan N, Chuansumrit A, Angchaisuksiri P, Pakakasama S, Hongeng S, Kadegasem P. Venous thromboembolism in Thai children. *Pediatr Hematol Oncol*. (2007) 24:245–56. doi: 10.1080/08880010701360767

5. Stein PD, Kayali F, Olson RE. Incidence of venous thromboembolism in infants and children: data from the national hospital discharge survey. *J Pediatr*. (2004) 145:563–5. doi: 10.1016/j.jpeds.2004.06.021

6. Chalmers EA. Epidemiology of venous thromboembolism in neonates and children. *Thromb Res*. (2006) 118:3–12. doi: 10.1016/j.thromres.2005.01.010

7. Zhang Y, Xia H, Wang Y, Chen L, Li S, Hussein IA, et al. The rate of missed diagnosis of lower-limb DVT by ultrasound amounts to 50% or so in patients without symptoms of DVT: a meta-analysis. *Medicine (Baltimore)*. (2019) 98:e17103. doi: 10.1097/MD.0000000000017103

8. Lim W, Le Gal G, Bates SM, Righini M, Haramati LB, Lang E, et al. American Society of Hematology 2018 guidelines for management of venous thromboembolism: diagnosis of venous thromboembolism. *Blood Adv*. (2018) 2:3226–56. doi: 10.1182/bloodadvances.2018024828

9. Stein PD, Hull RD, Patel KC, Olson RE, Ghali WA, Brant R, et al. D-dimer for the exclusion of acute venous thrombosis and pulmonary embolism: a systematic review. *Ann Intern Med*. (2004) 140:589–602. doi: 10.7326/0003-4819-140-8-200404200-00005

10. Modi S, Deisler R, Gozel K, Reicks P, Irwin E, Brunsvold M, et al. Wells criteria for DVT is a reliable clinical tool to assess the risk of deep venous thrombosis in trauma patients. *World J Emerg Surg*. (2016) 11:24. doi: 10.1186/s13017-016-0078-1

11. Hachey KJ, Hewes PD, Porter LP, Ridyard DG, Rosenkranz P, McAneny D, et al. Caprini venous thromboembolism risk assessment permits selection for postdischarge prophylactic anticoagulation in patients with resectable lung cancer. *J Thorac Cardiovasc Surg*. (2016) 151:37–44.e1. doi: 10.1016/j.jtcvs.2015.08.039

12. Greene LA, Goldenberg NA. Deep vein thrombosis: thrombolysis in the pediatric population. *Semin Intervent Radiol*. (2012) 29:36–43. doi: 10.1055/s-0032-1302450

13. Branchford BR, Mourani P, Bajaj L, Manco-Johnson M, Wang M, Goldenberg NA. Risk factors for in-hospital venous thromboembolism in children: a case-control study employing diagnostic validation. *Haematologica*. (2012) 97:509–15. doi: 10.3324/haematol.2011.054775

14. Spentzouris G, Scriven RJ, Lee TK, Labropoulos N. Pediatric venous thromboembolism in relation to adults. *J Vasc Surg*. (2012) 55:1785–93. doi: 10.1016/j.jvs.2011.07.047

15. Yen J, Van Arendonk KJ, Streiff MB, McNamara L, Stewart FD, Conner KG, et al. Risk factors for venous thromboembolism in pediatric trauma patients and validation of a novel scoring system: the risk of clots in kids with trauma score. *Pediatr Crit Care Med*. (2016) 17:391–9. doi: 10.1097/PCC.0000000000000699

16. van Ommen CH, Heijboer H, Büller HR, Hirasing RA, Heijmans HS, Peters M. Venous thromboembolism in childhood: a prospective two-year registry in the Netherlands. *J Pediatr*. (2001) 139:676–81. doi: 10.1067/mpd.2001.118192

17. Kanis J, Hall CL, Pike J, Kline JA. Diagnostic accuracy of the D-dimer in children. *Arch Dis Child*. (2018) 103:832–4. doi: 10.1136/archdischild-2017-313315

18. Avila L, Amiri N, Pullenayegum E, Sealey VA, De R, Williams S, et al. Diagnostic value of D-dimers for limb deep vein thrombosis in children: a prospective study. *Am J Hematol*. (2021) 96:954–60. doi: 10.1002/ajh.26212

19. Strouse JJ, Tamma P, Kickler TS, Takemoto CM. D-dimer for the diagnosis of venous thromboembolism in children. *Am J Hematol*. (2009) 84:62–3. doi: 10.1002/ajh.21311

20. Silveira PC, Ip IK, Goldhaber SZ, Piazza G, Benson CB, Khorasani R. Performance of wells score for deep vein thrombosis in the inpatient setting. *JAMA Intern Med*. (2015) 175:1112–7. doi: 10.1001/jamainternmed.2015.1687

21. Wells P, Hirsh J, Anderson D, Lensing AA, Foster G, Kearon C, et al. Accuracy of clinical assessment of deep-vein thrombosis. *Lancet*. (1995) 345:1326–30. doi: 10.1016/S0140-6736(95)92535-X

22. Luksameearunothai K, Sa-Ngasoongsong P, Kulachote N, Thamyongkit S, Fuangfa P, Chanplakorn P, et al. Usefulness of clinical predictors for preoperative screening of deep vein thrombosis in hip fractures. *BMC Musculoskelet Disord*. (2017) 18:208. doi: 10.1186/s12891-017-1582-5

23. Mets EJ, McLynn RP, Grauer JN. Venous thromboembolism in children undergoing surgery: incidence, risk factors and related adverse events. *World J Ped Surg*. (2020) 3:e000084. doi: 10.1136/wjps-2019-000084

24. Gerotziafas GT. Risk factors for venous thromboembolism in children. *Int Angiol*. (2004) 23:195–205. PMID: 15765033.

25. Rohrer MJ, Cutler BS, MacDougall E, Herrmann JB, Anderson FA Jr., Wheeler HB. A prospective study of the incidence of deep venous thrombosis in hospitalized children. *J Vasc Surg*. (1996) 24:46–9, discussion 50. doi: 10.1016/s0741-5214(96)70143-x

26. Razak NB A, Jones G, Bhandari M, Berndt MC, Metharom P. Cancer-associated thrombosis: an overview of mechanisms, risk factors, and treatment. *Cancers (Basel)*. (2018) 10:1–21. doi: 10.3390/cancers10100380

27. Khorana AA, Mackman N, Falanga A, Pabinger I, Noble S, Ageno W, et al. Cancer-associated venous thromboembolism. *Nat Rev Dis Primers*. (2022) 8:11. doi: 10.1038/s41572-022-00336-y

frontiers | Frontiers in Surgery

TYPE Original Research
PUBLISHED 11 April 2023
DOI 10.3389/fsurg.2023.1120069

Check for updates

OPEN ACCESS

EDITED BY
Kei Ando,
Japanese Red Cross Nagoya Daini Hospital, Japan

REVIEWED BY
Vadim Byvaltsev,
Irkutsk State Medical University, Russia
Adam James Wells,
University of Adelaide, Australia
Brian Dalm,
The Ohio State University, United States

*CORRESPONDENCE
Kohei Takahashi
kohei.takahashi.c1@tohoku.ac.jp

SPECIALTY SECTION
This article was submitted to Orthopedic Surgery, a section of the journal Frontiers in Surgery

RECEIVED 09 December 2022
ACCEPTED 23 March 2023
PUBLISHED 11 April 2023

CITATION
Takahashi K, Hashimoto K, Onoki T, Kanno H, Ozawa H and Aizawa T (2023) Anterior shift of the ventral dura mater: A novel concept of the posterior surgery for ossification of the posterior longitudinal ligament in thoracic spine.
Front. Surg. 10:1120069.
doi: 10.3389/fsurg.2023.1120069

COPYRIGHT
© 2023 Takahashi, Hashimoto, Onoki, Kanno, Ozawa and Aizawa. This is an open-access article distributed under the terms of the Creative Commons Attribution License (CC BY). The use, distribution or reproduction in other forums is permitted, provided the original author(s) and the copyright owner(s) are credited and that the original publication in this journal is cited, in accordance with accepted academic practice. No use, distribution or reproduction is permitted which does not comply with these terms.

Anterior shift of the ventral dura mater: A novel concept of the posterior surgery for ossification of the posterior longitudinal ligament in thoracic spine

Kohei Takahashi[1]*, Ko Hashimoto[1], Takahiro Onoki[1], Haruo Kanno[2], Hiroshi Ozawa[2] and Toshimi Aizawa[1]

[1]Department of Orthopaedic Surgery, School of Medicine, Tohoku University, Sendai, Japan, [2]Department of Orthopaedic Surgery, School of Medicine, Tohoku Medical and Pharmaceutical University, Sendai, Japan

Background: Thoracic myelopathy caused by ossification of the posterior longitudinal ligament (OPLL) remains one of the most difficult disorders to treat. The Ohtsuka procedure, extirpation, or anterior floating of the OPLL through a posterior approach, has shown great surgical outcomes after several modifications. However, these procedures are technically demanding and pose a significant risk of neurological deterioration. We have developed a novel modified Ohtsuka procedure in which removal or minimization of the OPLL mass is unnecessary; instead, the ventral dura mater is shifted anteriorly with the posterior part of the vertebral bodies and targeted OPLL.
Surgical Procedure: First, pedicle screws were inserted at more than three spinal levels above and below the spinal level where pediculectomies were performed. After laminectomies and total pediculectomies, partial osteotomy of the posterior vertebra adjacent to the targeted OPLL was performed by using a curved air drill. Then, the PLL is completely resected at the cranial and caudal sites of the OPLL using special rongeurs or a threadwire saw with a diameter of 0.36 mm. The nerve roots were not resected during surgery.
Methods: Eighteen patients (follow-up ≥1 year) treated with our modified Ohtsuka procedure were assessed clinically, including the Japanese Orthopaedic Association (JOA) score for thoracic myelopathy and radiographically.
Results: The average follow-up period was 3.2 years (range, 1.3–6.1 years). The preoperative JOA score was 2.7 ± 1.7, which improved to 8.2 ± 1.8 at 1 year postoperatively; therefore, the recovery rate was $65.8 \pm 19.8\%$. The CT scan at 1 year after surgery revealed the anterior shift of the OPLL averaged 3.1 ± 1.7 mm and the ossification-kyphosis angle of the anterior decompression site decreased at an average of 7.2 ± 6.8 degrees. Three patients demonstrated temporary neurological deterioration, all of whom completely recovered within 4 weeks postoperatively.
Discussion: The concept of our modified Ohtsuka procedure is 1) not OPLL extirpation or minimization but only the creation of space between the OPLL and spinal cord by an anterior shift of the ventral dura mater, which is achieved by complete resection of the PLL at the cranial and caudal sites of the OPLL; and 2) no nerve roots are sacrificed to prevent ischemic spinal cord injury. This procedure is not technically demanding and safe and provides secure decompression for thoracic OPLL. The anterior shift of the OPLL was smaller than expected, but it resulted in a relatively good surgical outcome with a recovery rate ≥65%.

Conclusion: Our modified Ohtsuka procedure is quite secure and is not technically demanding, with a recovery rate of 65.8%.

KEYWORDS

ossification of the posterior longitudinal ligament, thoracic spine, dura mater, anterior decompression, myelopathy

Introduction

In our previous epidemiological study in the Japanese population, 21% of thoracic myelopathy is caused by ossification of the posterior longitudinal ligament (OPLL) with or without ossification of the ligamentum flavum (1), which remains one of the most difficult-to-treat disorders for spinal surgeons. The difficulty of surgery depends on two reasons: anatomical features and perioperative complications. Anatomically, the spinal cord has a particularly vulnerable region, usually between T4 and T9, called the "watershed zone" with poor blood supply (2, 3). In addition, the thoracic spine is naturally kyphotic, and decompressive laminectomy is less effective because of the restricted postoperative backward shift of the spinal cord (4). From the viewpoint of perioperative complications, the multi-center studies from the Japanese Society for Spine Surgery and Related Research reported complication rates were 40.8–51.3%, including 11.7–26.3% of postoperative neurological deterioration (5–8).

Many surgical procedures have been developed for patients with thoracic OPLL to ensure more stable and effective outcomes. Since the report by Yamazaki et al. in (4), posterior decompression with instrumented spinal fusion (PDF) has been the gold standard, and approximately 75% of patients in Japan are now treated using it because of its safety and effectiveness (7). PDF has shown relatively good surgical outcomes (4–7). Meanwhile, theoretically, extirpation or anterior floating of the OPLL should allow for a more effective decompression of the spinal cord than PDF. However, those anterior decompression have a certain risk of postoperative paralysis despite their approaches, through a thoracotomy or a posterior approach (5, 9). We have produced a modified procedure of anterior decompression through a posterior approach based on a novel concept, in which extirpation or minimization of the OPLL mass is not necessary; instead, an anterior shift of the ventral dura mater (not anterior shift of the spinal cord) is achieved by complete resection of the PLL at the cranial and caudal sites of the targeted OPLL (10–12). In the present study, we introduced our surgical technique and demonstrated the surgical outcomes in 18 patients treated with this procedure.

Patients and methods

Our surgical procedure

The detailed surgical procedure can be found in our previous article, with a video presentation (12). A summary of the surgical procedure is presented here. This procedure was performed using spinal cord monitoring. Under general anesthesia, the patient was placed in the prone position. First, pedicle screws were inserted at more than three levels above and three below the spinal levels where pediculectomies were performed. After laminectomies and total pediculectomies, partial osteotomy of the posterior vertebra adjacent to the targeted OPLL was performed by using a curved air drill. Then, the PLL was completely resected at the cranial and caudal sites of the OPLL using special rongeurs or a threadwire saw with a diameter of 0.36 mm (13). In order to resect the PLL safely and surely, we determined the extension of pediculectomies so that no OPLL was confirmed on preoperative computed tomography (CT) at the site of PLL resection. This manipulation shifted the ventral dura mater anteriorly, together with the OPLL and the posterior part of the vertebral bodies. Finally, the final rods were connected to the pedicle screws. The intraoperative photographs, ultrasonography, and pre- and postoperative imaging findings are shown in **Figures 1–3**.

Patients

From 2015 to 2021, we performed our modified Ohtsuka procedure in 21 patients with thoracic myelopathy caused by OPLL. Among them, two patients with a history of previous spinal surgery, one patient with intellectual disability were excluded from the analysis. Subsequently, 18 patients who were followed up for ≥1 year were included in this study.

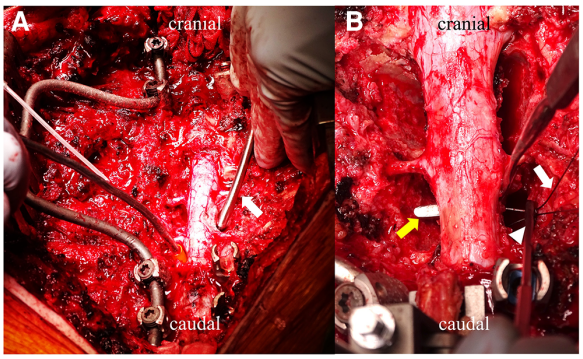

FIGURE 1
Intraoperative photographs of our modified ohtsuka procedure. (A) Using a curved air drill (white arrow), partial osteotomy of the vertebral bodies adjacent to the targeted ossification of the posterior longitudinal ligament (OPLL) is performed to make a "bone tunnel" at the posterior part of the vertebral bodies. (B) The posterior longitudinal ligament is cut at the cranial side of the OPLL by a threadedwire saw (white arrow) with a knot pusher (arrowhead) used under an angled spatula (yellow arrow).

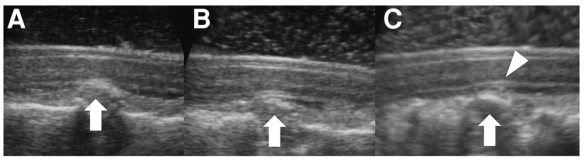

FIGURE 2
Intraoperative ultrasonography. After laminectomy. (**A**) The spinal cord is compressed anteriorly by ossification of the posterior longitudinal ligament (OPLL) (arrow). (**B**) Before resection of the PLL. After partial osteotomy of the posterior vertebra adjacent to the targeted OPLL and before PLL resection, the OPLL decreased (arrow). (**C**) After PLL resection. The OPLL further moves anteriorly (**arrow**), and a space between the spinal cord and dura mater is clearly detected (**arrowhead**).

Clinical evaluations

From the operative records, the total number of vertebrae where pediculectomies were performed was counted (e.g., when pediculectomies were performed in T7, T8 and T9, "the total number of vertebrae where pediculectomies were performed" was recorded as 3). In addition, the operative duration, intraoperative blood loss, and changes in intraoperative spinal cord monitoring results were confirmed. Each patient's neurological condition was evaluated using the modified Japanese Orthopaedic Association (JOA) score, an 11-point scale measuring lower motor function, sensory function in the lower extremities and trunk, and bladder function (14). The modified Frankel scale was used to assess walking ability (15, 16). On this scale, Grade A is defined as "complete motor and sensory loss," Grade B is defined as "preserved sensory only," Grade C is defined as "preserved motor loss less than fair grade," and Grade E is defined as "normal." Grade D was classified into three subgrades: D1, D2, and D3. D1 is defined as "preserved motor ability at the lowest functional grade and ability to walk 10 to 100 m." Patients usually use a wheelchair. D2 is defined as "preserved motor ability at midfunctional grade and ability to walk stably with a cane, handrail, and/or lower leg brace." D3 is defined as "preserved motor ability at high functional grade and ability to walk without any support." The neurological condition and walking abilities were evaluated preoperatively and one year after surgery because at one year postoperatively, the condition of patients became stable. Perioperative complications were also noted. Neurological data and complications were collected from the medical records.

Radiographical evaluations

Spinal levels and length of the OPLL were confirmed. The type of OPLL was classified as linear, beaked, continuous waveform, continuous cylindrical, or mixed (composed of at least two of these types) according to the annual report of the taskforce of research for ossification of spinal ligaments sponsored by the Japanese Ministry of Health and Welfare in 1994 (17). Using sagittal reconstructed CT before and one year after surgery, the distance between the prominence of the OPLL and the anterior margin of the vertebral body (OPLL distance) was measured. In addition, the anterior shift of the prominence of the OPLL was defined as the difference between the pre- and postoperative OPLL distances (**Figure 4A**). The ossification-kyphosis angle at the anterior decompression site was gauged. This angle was based on Tokuhashi's definition: the angle from the superior margin at the cranial vertebral body of the decompression site and from the lower posterior margin at the caudal vertebral body of the decompression site to the prominence of the maximum OPLL (**Figure 4B**) (18). The difference between the pre- and postoperative ossification-kyphosis angles was also calculated.

Statistical analysis

Statistical analysis was performed using the unpaired t-test for the JOA score, OPLL distance, and ossification-kyphosis angle compared to preoperative data with those one year after surgery. All collected data were analyzed using commercially available software (JMP Pro®. (SAS Institute Inc., Cary, NC, USA). Statistical significance was set at $P < 0.05$.

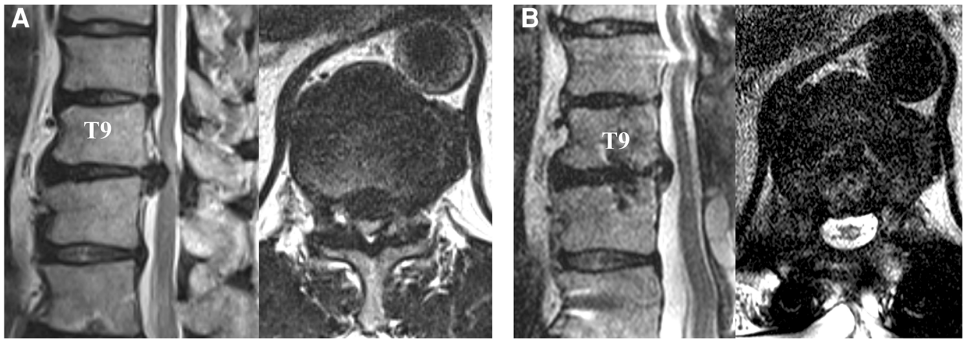

FIGURE 3
Pre- (**A**) and postoperative MRI (**B**) of the patient, a 45-year-old male, with ossification of the posterior longitudinal ligament (OPLL) at T9–10. (**A**) The spinal cord is severely compressed from anteriorly by OPLL at T9–10 with significant T2 high signal intensity. (**B**) After our modified Ohtsuka procedure, the spinal cord was completely decompressed, and cerebrospinal fluid was confirmed at the ventral side of the spinal cord.

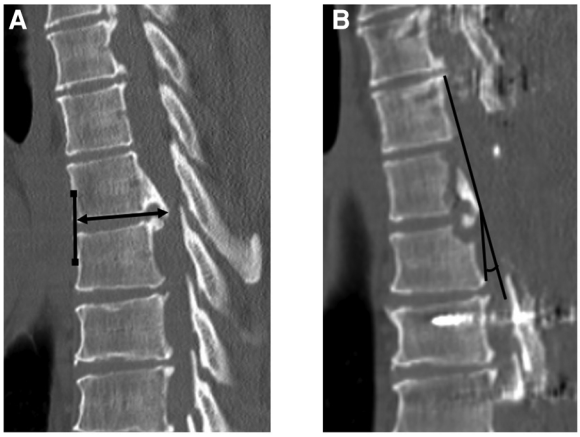

FIGURE 4
Definition of measurements of ossification of the posterior longitudinal ligament (OPLL) distance (A) and ossification-kyphosis angle (B). (A) The OPLL distance was defined as the distance between the prominence of the OPLL and the anterior margin of the vertebral bodies. The anterior margin was defined as the line connecting the midpoints of the upper and lower vertebral bodies of the corresponding OPLL. (B) The ossification-kyphosis angle was defined according to Tokuhashi et al. (18). This is the angle from the superior margin at the cranial vertebral body of the decompression site and from the lower posterior margin at the caudal vertebral body of the decompression site to the prominence of the maximum OPLL.

Results

Eight males and ten females were included in the study, and the average age at surgery was 50 years (range, 36–74 years). The average follow-up period was 3.2 years (range, 1.3–6.1 years). The demographic data of each patient are presented in Table 1. All the patients had thoracic myelopathy. The average total number of vertebrae where pediculectomies were performed was 2.9 (range, 2–5). Fifteen patients underwent fewer than three vertebral pediculectomies, while three patients underwent more than four levels of pediculectomy. Operative duration and intraoperative blood loss are presented in Table 2.

The changes in the intraoperative spinal cord monitoring results are shown in Table 2. Intraoperative neurophysiological monitoring was performed on 17 patients. Motor evoked potentials (MEPs) were detected in 9 patients before surgery. During surgery, MEPs of one patient disappeared, and those of 4 patients showed a ≥70% decrease.

Neurological evaluation results are shown in Table 3. The preoperative JOA score was 2.7 ± 1.7 (mean ± standard deviation), which significantly improved to 8.2 ± 1.8 one year after surgery.

TABLE 1 Demographic data of the patients.

Age at surgery (years)	50 ± 11
Sex	Male : female = 8 : 10
Body Mass Index (kg/m^2)	30.6 ± 6.3
Diabetes mellites	4/18
Follow-up period (years)	3.2 ± 1.5

The numeric values are shown as mean ± standard deviation.

TABLE 2 Intraoperative data of our modified ohtsuka procedure.

Number of vertebrae with pediculectomies	2.9 ± 0.8
Operative duration (min)	577 ± 131
Intraoperative blood loss (ml)	1184 ± 707
Motor evoked potentials (MEPs)	17/18
Detected preoperatively	9/17
Disappeared intraoperatively	1/9
≥70% decrease intraoperatively	4/9

The numeric values are shown as mean ± standard deviation.

The recovery rate was 65.8 ± 19.8% (14). Using the modified Frankel scale before surgery, non-ambulatory patients accounted for 55.6% before surgery. One year postoperatively, one patient showed four grade-ups, five patients showed three grade-ups, four patients showed two grade-ups, and eight patients showed one grade-up in walking ability. All preoperative non-ambulatory patients could at least walk using support such as crutches and a cane one year after surgery. Three patients demonstrated temporary neurological deterioration, all of whom completely recovered within 4 weeks postoperatively.

The radiographic evaluation results are shown in Table 4. The OPLL distance and ossification-kyphosis angle were significantly smaller postoperatively ($P < 0.001$). The anterior shift of the prominence of OPLL was 3.1 ± 1.7 mm, and the change of the ossification-kyphosis angle was 7.2 ± 6.8 degrees.

Discussions

Thoracic OPLL was first reported by Forcier et al. in (19). A 68-year-old male underwent laminectomy and achieved slight improvement. Thereafter, many spine surgeons have challenged

TABLE 3 Pre- and postoperative neurological evaluation of the patients.

Preop. JOA score	2.7 ± 1.7
Postop. JOA score	8.2 ± 1.8
Recovery rate (%)	65.8 ± 19.8
Change of modified Frankel scale	
B to D2	1
C to D1	1
C to D2	4
C to D3	3
C to E	1
D1 to D2	2
D1 to E	1
D2 to D3	4
D3 to E	1

The numeric values are shown as mean ± standard deviation.
JOA score: Japanese Orthopaedic Association score for thoracic myelopathy (full mark: 11) [16].
Recovery rate (%) = (Postop. JOA score-Preop. JOA score)/11-Preop. JOA score × 100.
Modified Frankel scale.
B: preserved sensory only.
C: preserved motor loss less than fair grade.
D1: preserved motor ability at lowest functional grade. Usually uses a wheelchair.
D2: preserved motor ability at midfunctional grade. Usually uses a cane.
D3: Preserved motor ability at a high functional grade. No support was required for walking.
E: normal.

TABLE 4 Radiographic evaluation of the patients.

Levels of OPLL	
Upper	7
Middle	9
Lower	2
Length of OPLL (number of vertebrae)	2.9 ± 1.0
Type of OPLL (17)	
Linear	0
Beaked	4
Continuous waveform	1
Continuous cylindrical	2
Mixed	11
Including beaked type	15
OLF at the narrowest segment	13
Preoperative OPLL distance	31.7 ± 4.7
Postoperative OPLL distance	28.5 ± 5.5
Preoperative ossification-kyphosis angle	24.2 ± 6.4
Postoperative ossification-kyphosis angle	17.0 ± 5.3

The length of the OPLL, OPLL distance, and ossification-kyphosis angle are shown as the mean ± standard deviation.
Upper: T1–5, middle: T5–8, lower: T8–12.
Mixed: composed of at least two of either linear, beaked, continuous waveforms, or continuous cylindrical type.
OLF: ossification of the ligamentum flavum.
OPLL distance: the distance between the prominence of the OPLL and the anterior margin of the vertebral body.
Ossification-kyphosis angle: The angle between the line joining the superior margin of the cranial end of the laminectomized vertebral body and the maximal prominence of the OPLL and the line joining the inferior margin of the caudal end of the laminectomized vertebral body and the maximal prominence of the OPLL.

this intractable disease with many kinds of procedures, including laminectomy with or without resection of the dentate ligaments (1, 20), anterior decompression and fusion through a thoracotomy (21, 22), posterior decompression with instrumented spinal fusion (4, 23), and anterior decompression through a posterior approach, the so-called Ohtsuka procedure (24). More specific procedures include circumspinal decompression through a posterior approach with thoracotomy (25), through a single posterior approach (9) and a posterolateral approach (26), staged spinal decompression through a posterior approach (27), and single-stage mini-thoracotomy without spinal fusion (3, 28).

Since the thoracic spine is usually kyphotic and OPLL compresses the spinal cord anteriorly; theoretically, extirpation or anterior floating of the OPLL should allow for more effective decompression of the spinal cord (4, 10, 11). Two surgical approaches can be used for this purpose: thoracotomy and a single posterior or posterolateral approach. These procedures have reported good surgical outcomes but might be technically demanding (5–7, 9); Kato et al. (24). The rate of postoperative neurological deterioration is higher (4–7, 9). In addition, anterior decompression through thoracotomy has a significant risk of pulmonary complications, including cerebrospinal fluid leakage into the thoracic cavity (3, 5).

The concept of our modified Ohtsuka procedure is completely different from that of other procedures. The goal is not OPLL extirpation but only the creation of space between the OPLL and spinal cord by an anterior shift of the ventral dura mater. Minimization of the OPLL mass was not necessary. Instead, complete resection of the PLL at the cranial and caudal sites of the OPLL, where no OPLL is confirmed on preoperative CT, is required. Since the ventral dura mater severely adheres to the OPLL, occasionally, ossified dura mater is detected. While the spinal cord does not cling to the dura mater, the ventral dura should shift anteriorly, pulled by the ossified mass, after anterior decompression of the OPLL with cranial and caudal PLL resection. Therefore, the procedure is not technically demanding. Invasion to the spinal cord should be less than OPLL extirpation or minimization. Recently, a similar concept of indirect decompression surgery was reported by Ma et al. (29) as thoracic column antedisplacement and fusion, with a mean recovery rate of 42.3%.

In the present study, the anterior shift of the prominence of OPLL was small, only 3.1 mm, and the change in the ossification-kyphosis angle was less than 10 °. These values may be smaller than expected; however, the postoperative outcomes were excellent: the recovery rate was more than 65%, which was better than that of the PDF and compared favorably with the other modified Ohtsuka procedures (4, 7, 9, 30, 31). It should be led by a secure anterior shift of the targeted OPLL achieved by resecting all four sides of the OPLL from the surrounding tissues, creating a significant space between the ventral dura mater and the spinal cord.

There are two advantages of our modified Ohtsuka procedure. First, because a curved air drill was used, no nerve roots were sacrificed. Therefore, ischemic spinal cord injury should be prevented as blood supply to the spinal cord is preserved. Second, extirpation or anterior floating of the OPLL carries a potential risk of spinal cord damage because the targeted OPLL usually severely compresses the spinal cord. These manipulations may further damage the weakened spinal cord even if a surgical microscope is used. In our procedure, extirpation or minimization of the OPLL mass is not performed, and the PLL is resected where no OPLL can be detected, not at the narrowest spinal level, usually done by a very fine T-saw with a diameter of 0.36 mm (13). Invasion of the spinal cord should be reduced. Although several pathologies may be out of indication, such as continuous OPLL from the cervical to the thoracic spine and a very long OPLL from T1 to T11, this procedure is less technically demanding, safer, and offers secure decompression.

The present study confirmed the significantly good surgical outcomes of our modified Ohtsuka procedure in patients with thoracic OPLL; however, several limitations should be noted. The study population was limited because thoracic OPLL is a rare condition. The outcome could be compared with that of previous reports. A randomized prospective comparison between this procedure and other surgical methods with a sufficient number of patients is ideal, but it should be difficult because of the small number of patients, in addition to ethical reasons. We should increase the number of patients and verify the safety and effectiveness of this procedure in a larger population.

Data availability statement

The raw data supporting the conclusions of this article will be made available by the authors, without undue reservation.

Ethics statement

The studies involving human participants were reviewed and approved by Tohoku University, School of Medicine. The patients/participants provided their written informed consent to participate in this study.

Author contributions

All authors listed have made substantial, direct, and intellectual contributions to the manuscript, approved the final version to be published, and agreed to be accountable for all aspects of the work. All authors contributed to the article and approved the submitted version.

Acknowledgments

The authors would like to thank Editage for language editing.

Conflict of interest

The authors declare that the research was conducted in the absence of any commercial or financial relationships that could be construed as a potential conflict of interest.

Publisher's note

All claims expressed in this article are solely those of the authors and do not necessarily represent those of their affiliated organizations, or those of the publisher, the editors and the reviewers. Any product that may be evaluated in this article, or claim that may be made by its manufacturer, is not guaranteed or endorsed by the publisher.

References

1. Aizawa T, Sato T, Tanaka Y, Ozawa H, Hoshikawa T, Ishii Y, et al. Thoracic myelopathy in Japan: epidemiological retrospective study in miyagi prefecture during 15 years. *Tohoku J Exp Med*. (2006) 210:199–208. doi: 10.1620/tjem.210.199

2. Srivastava SK, Aggarwal RA, Bhosale SK, Roy K, Nemade PS. The versatile approach: a novel single incision combined with anterior and posterior approaches for decompression and instrumented fusion to treat tuberculosis of the thoracic spine. *Asian J Spine*. (2017) 11:294–304. doi: 10.4184/asj.2017.11.2.294

3. Kanematsu R, Hanakita J, Takahashi T, Tomita Y, Minami M. Microsurgical resection of ossification of the posterior longitudinal ligament in the thoracic spine via transthoracic approach without spinal fusion: case series and technical note. *J Neurosurg Spine*. (2019) 31:326–33. doi: 10.3171/2019.3.SPINE181388

4. Yamazaki M, Mochizuki M, Ikeda Y, Sodeyama T, Okawa A, Koda M, et al. Clinical results of surgery for thoracic myelopathy caused by ossification of the posterior longitudinal ligament: operative indication of posterior decompression with instrumented fusion. *Spine*. (2006) 31:1452–60. doi: 10.1097/01.brs.0000220834.22131.fb

5. Matsumoto M, Chiba K, Toyama Y, Takeshita K, Seichi A, Nakamura K, et al. Surgical results and related factors for ossification of posterior longitudinal ligament of the thoracic spine. A multi-institutional retrospective study. *Spine*. (2008) 33:1034–41. doi: 10.1097/BRS.0b013e31816c913b

6. Matsumoto M, Toyama Y, Chikuda H, Takeshita K, Kato T, Shindo S, et al. Outcomes of fusion surgery for ossification of the posterior longitudinal ligament of the thoracic spine. a multicenter retrospective survey. *J Neurosurg Spine*. (2011) 15:380–5. doi: 10.3171/2011.6.SPINE10816

7. Imagama S, Ando K, Takeuchi K, Kato S, Murakami H, Aizawa T, et al. Perioperative complications after surgery for thoracic ossification of posterior longitudinal ligament: a nationwide multicenter prospective study. *Spine*. (2018) 43: E1389–97. doi: 10.1097/BRS.0000000000002703

8. Eto T, Aizawa T, Kanno H, Hashimoto K, Ozawa H, Itoi E. Several pathologies cause delayed postoperative paralysis following posterior decompression and spinal fusion for thoracic myelopathy caused by ossification of the posterior longitudinal ligament. *J Orthop Sci*. (2022) 27(3):725–33. doi: 10.1016/j.jos.2019.08.004

9. Takahata M, Ito M, Abumi K, Kotani Y, Sudo H, Minami A. Clinical results and complications of circumferential spinal cord decompression through a single posterior approach for thoracic myelopathy caused by ossification of posterior longitudinal ligament. *Spine*. (2008) 33:1199–208. doi: 10.1097/BRS.0b013e3181714515

10. Aizawa T, Eto T, Hashimoto K, Kanno H, Itoi E, Ozawa H. Surgical results of patients who could not walk preoperatively caused by ossification of the posterior longitudinal ligaments in thoracic spine: retrospective comparative study between posterior decompression and instrumented spinal fusion versus anterior decompression through posterior approach. *J Neurosurg Spine*. (2020) 11:492–7.

11. Aizawa T, Hashimoto K, Kanno H, Handa K, Takahashi K, Onoki T, et al. Retrospective comparison of the surgical results for patients with thoracic myelopathy caused by OPLL: posterior decompression with instrumented spinal fusion versus anterior decompression through a posterior approach. *J Orthop Sci Feb*. (2021) 7:S0949–2658(21)00011-7. doi: 10.1016/j.jos.2021.01.001

12. Kanno H, Aizawa T, Hashimoto K, Itoi E, Ozawa H. Anterior decompression through a posterior approach for thoracic myelopathy caused by OPLL: a novel concept in anterior decompression and technical notes with the preliminary outcomes. *J Neurosurg Spine*. (2021) 24:1–11. doi: 10.3171/2021.4.SPINE213

13. Tomita K, Kawahara N. The threadwire saw: a new device for cutting bone. *J Bone Joint Surg Am*. (1996) 78:915–1917. doi: 10.2106/00004623-199612000-00017

14. Yamauchi Y, Hirabayashi K. Japanese Orthopaedic association scoring system for cervical myelopathy. *Jpn J Orthop Assoc*. (1994) 68:490–503.

15. Bradford DS, McBride GG. Surgical management of thoracolumbar spine fractures with incomplete neurologic deficits. *Clin Orthop Relat Res*. (1987) 218:201–16. doi: 10.1097/00003086-198705000-00029

16. Fukuda F, Ueta T. Prediction of prognosis using modified frankel classification in cervical spinal cord injured patients. Jpn. *J Rehabil Med*. (2001) 38:29–33. (in Japanese).

17. Sakou T, Hirabayashi K. Modified criteria of patient selection for treatment of ossification of spinal ligaments. Annual report of taskforce of research for ossification of spinal ligaments sponsored by the Japanese Ministry of Health and Welfare, 11–4 (in Japanese) (1994).

18. Tokuhashi Y, Matsuzaki H, Oda H, Uei H. Effectiveness of posterior decompression for patients with ossification of the posterior longitudinal ligament in the thoracic spine–usefulness of the ossification-kyphosis angle on MRI. *Spine*. (2006) 31:E26–30. doi: 10.1097/01.brs.0000193940.75354.e5

19. Forcier P, Horsey WJ. Calcification of the posterior longitudinal ligament at the thoracolumbar junction–case report. *J Neurosurg*. (1970) 32:684–5. doi: 10.3171/jns.1970.32.6.0684

20. Ohkaya M, Tsuruta T, Matsugu M, Shiokawa Y, Yamasaki T, Mitsui T, et al. Two cases of the ossification of posterior longitudinal ligament in the thoracic spine. *J Central Jpn Assoc Orthop Surg Traumatol*. (1971) 13:244–8. (in Japanese).

21. Ohtani K, Manzoku S, Shibasaki K, Nomachi S. Anterior decompression for the ossification of posterior longitudinal ligament in the thoracic spine. *Orthop Surg*. (1977) 12:353–9. (in Japanese).

22. Kurosa Y, Yamaura I, Nakai O, Shinomiya K. Selecting a surgical method for thoracic myelopathy caused by ossification of the posterior longitudinal ligament. *Spine*. (1996) 21:1458–66. doi: 10.1097/00007632-199606150-00012

23. Matsuyama Y, Yoshihara H, Tsuji T, Sakai Y, Yukawa Y, Nakamura H, et al. Surgical outcome of ossification of the posterior longitudinal ligament (OPLL) of the thoracic spine. Implication of the type of ossification and surgical options. *J Spinal Disord Tech*. (2005) 18:492–7. doi: 10.1097/01.bsd.0000155033.63557.9c

24. Ohtsuka K, Terayama K, Tsuchiya T, Wada K, Furukawa K, Ohkubo M. A surgical procedure of the anterior decompression of the thoracic spinal cord through the posterior approach. *Orthop Surg Traumatol*. (1983) 26:1083–90. (in Japanese).

25. Tomita K, Kawahara N, Baba H, Kikuchi Y, Nishimura H. Circumspinal decompression for thoracic myelopathy due to combined ossification of the posterior longitudinal ligament and ligamentum flavum. *Spine*. (1990) 15:1114–20. doi: 10.1097/00007632-199011010-00006

26. Kato S, Murakami H, Demura S, Yoshioka K, Hayashi H, Tsuchiya H. Novel surgical technique for ossification of posterior longitudinal ligament in the thoracic spine. *J Neurosurg Spine*. (2012) 17:525–9. doi: 10.3171/2012.9.SPINE12617

27. Tsuzuki N, Hirabayashi S, Abe R, Saiki K. Staged spinal cord decompression through posterior approach for thoracic myelopathy caused by ossification of posterior longitudinal ligament. *Spine*. (2001) 26:1623–30. doi: 10.1097/00007632-200107150-00025

28. Yoon J, Bae J, Shin S, Bae Y, Lee S. Novel simultaneous decompression through single-stage mini-thoracotomy for concurrent ossification of the posterior longitudinal ligament and ossification of the ligamentum flavum at the same thoracic level. *Spine*. (2020) 46:E190–196. doi: 10.1097/BRS.0000000000003748

29. Ma X, Wang B, Chen Y, Ge S, Zou X, Zhang S, et al. Outcome of thoracic column antedisplacement and fusion in treatment of thoracic myelopathy caused by ossification of posterior longitudinal ligament: a case series study. *Oper Neurosurg*. (2021) 21:118–25. doi: 10.1093/ons/opab193

30. Imagama S, Ando K, Ito Z, Kobayashi K, Hida T, Ito K, et al. Resection of beak-type thoracic ossification of the posterior longitudinal ligament from a posterior approach under intraoperative neurophysiological monitoring for paralysis after posterior decompression and fusion surgery. *Global Spine J*. (2016) 6:812–21. doi: 10.1055/s-0036-1579662

31. Kato S, Murakami H, Demura S, Yoshida K, Yokogawa N, Takaki S, et al. Indication for anterior spinal cord decompression via a posterolateral approach for the treatment of ossification of the posterior longitudinal ligament in the thoracic spine: a prospective cohort study. *Eur Spine J*. (2020) 29:113–21. doi: 10.1007/s00586-019-06047-5

frontiers | Frontiers in Surgery

TYPE Case Report
PUBLISHED 21 April 2023
DOI 10.3389/fsurg.2023.1128868

Check for updates

OPEN ACCESS

EDITED BY
Paphon Sa-Ngasoongsong,
Mahidol University, Thailand

REVIEWED BY
Vikash Raj,
All India Institute of Medical Sciences, Deoghar (AIIMS Deoghar), India
Gianluca Ciolli,
Agostino Gemelli University Polyclinic (IRCCS), Italy

*CORRESPONDENCE
Xin Duan
dxbaal@hotmail.com

SPECIALTY SECTION
This article was submitted to Orthopedic Surgery, a section of the journal Frontiers in Surgery

RECEIVED 21 December 2022
ACCEPTED 28 March 2023
PUBLISHED 21 April 2023

CITATION
Shakya S, Chen J, Xing F, Xiang Z and Duan X (2023) Surgical treatment and functional outcome of bilateral symmetrical hip dislocation and Pipkin type II femoral head fracture: a 5-year follow-up case report and literature review.
Front. Surg. 10:1128868.
doi: 10.3389/fsurg.2023.1128868

COPYRIGHT
© 2023 Shakya, Chen, Xing, Xiang and Duan. This is an open-access article distributed under the terms of the Creative Commons Attribution License (CC BY). The use, distribution or reproduction in other forums is permitted, provided the original author(s) and the copyright owner(s) are credited and that the original publication in this journal is cited, in accordance with accepted academic practice. No use, distribution or reproduction is permitted which does not comply with these terms.

Surgical treatment and functional outcome of bilateral symmetrical hip dislocation and Pipkin type II femoral head fracture: a 5-year follow-up case report and literature review

Sujan Shakya, Jialei Chen, Fei Xing, Zhou Xiang and Xin Duan*

Department of Orthopedic Surgery, West China Hospital, Sichuan University, Chengdu, China

Background: Bilateral posterior hip dislocation and femoral head fracture are rare injuries, which may be the earliest case report that focuses on treatment with open reduction via the direct anterior approach (DAA) for bilateral symmetrical Pipkin type II fracture within 5 years of the follow-up period.
Case report: We present a case of bilateral posterior dislocation with a femoral head fracture (Pipkin II) of the hip in 47-year-old woman caused by a high-velocity accident. The dislocation was successfully reduced under general anesthesia at a local hospital and transferred to a tertiary center for surgical management. She was surgically treated with internal fixation using three Herbert screws on the bilateral hips. The DAA was used during surgery. Follow-up for 5 years was performed, and functional outcomes were evaluated using the D'Aubigné range of motion and modified Harris hip score. The range of motion in the bilateral hip was satisfactory, with no signs of post-traumatic arthritis, heterotopic ossification, or avascular necrosis of the femoral head.
Conclusion: Surgical management of bilateral Pipkin type II fractures was performed successfully with open reduction and internal fixation using a safe and reliable direct anterior approach, with good functional outcomes at 5-year follow-up.

KEYWORDS

Pipkin fracture, femoral head fracture, posterior hip dislocation, direct anterior approach Pipkin fracture

Introduction

Femoral head fracture is a rare injury to the hip, accounting for approximately 4%–17% of the cases of traumatic hip dislocation cases (1). Only 1.25% of all hip dislocations are simultaneous bilateral (2, 3). Dislocations and fractures require significant forces, which are typically encountered in high-velocity motor vehicle accidents. The majority of them are either unrestrained drivers or front-seat passengers. Birkett described the first femoral head fracture followed by posterior hip dislocation in 1869 (4), whereas Garrett Pipkin classified the fracture pattern in 1957 based on the location of the head fracture in relation to the fovea and the associated lesion on the femoral head or acetabulum (5). Meislin and Zuckerman were the first to report the symmetrical bilateral Pipkin fracture type IV which was treated with cemented hip arthroplasties (6).

In this paper, we report a rare case of symmetrical bilateral hip dislocation with femoral head fracture (Pipkin II) treated surgically using a direct anterior approach (DAA), with a successful outcome after a 5-year follow-up.

Case reports

A 46-year-old woman presented with a history of a car accident 1 day ago. She complained of severe hip pain and difficulty in thigh movement. The patient presented to our hospital after the primary treatment of hip joint reduction. Due to bilateral hip pain and limited movement, radiographic examinations were performed in the emergency department of the local hospital. The patient was diagnosed with "hip dislocation and femoral head fracture." After 1 day of inpatient observation, the patient was transported to our hospital department. The patient had no previous medical history.

Physical examination

The patient exhibited bilateral hip tenderness and limitation of motion. No neurovascular injury was observed. She also suffered forehead collusion without loss of consciousness, lung contusion, multiple abrasions to the forehead, and lower limbs, and knee injuries. The patient was initially evaluated with advanced trauma life support protocol and stabilized hemodynamically. There was no numbness or foot drop on the bilateral leg.

Imaging examination

Anteroposterior pelvis radiographs and 3D CT scans were rescheduled with the baseline investigation. The radiological reports suggested bilateral femoral head fracture (pipkin type II) as soon in (Figure 1), bilateral hip joint soft tissue swelling, intraarticular fluid accumulation, and mini fracture fragments.

Treatment

Preoperative skeletal traction

The patient underwent skeletal traction for 4 days including 1 day in the local hospital.

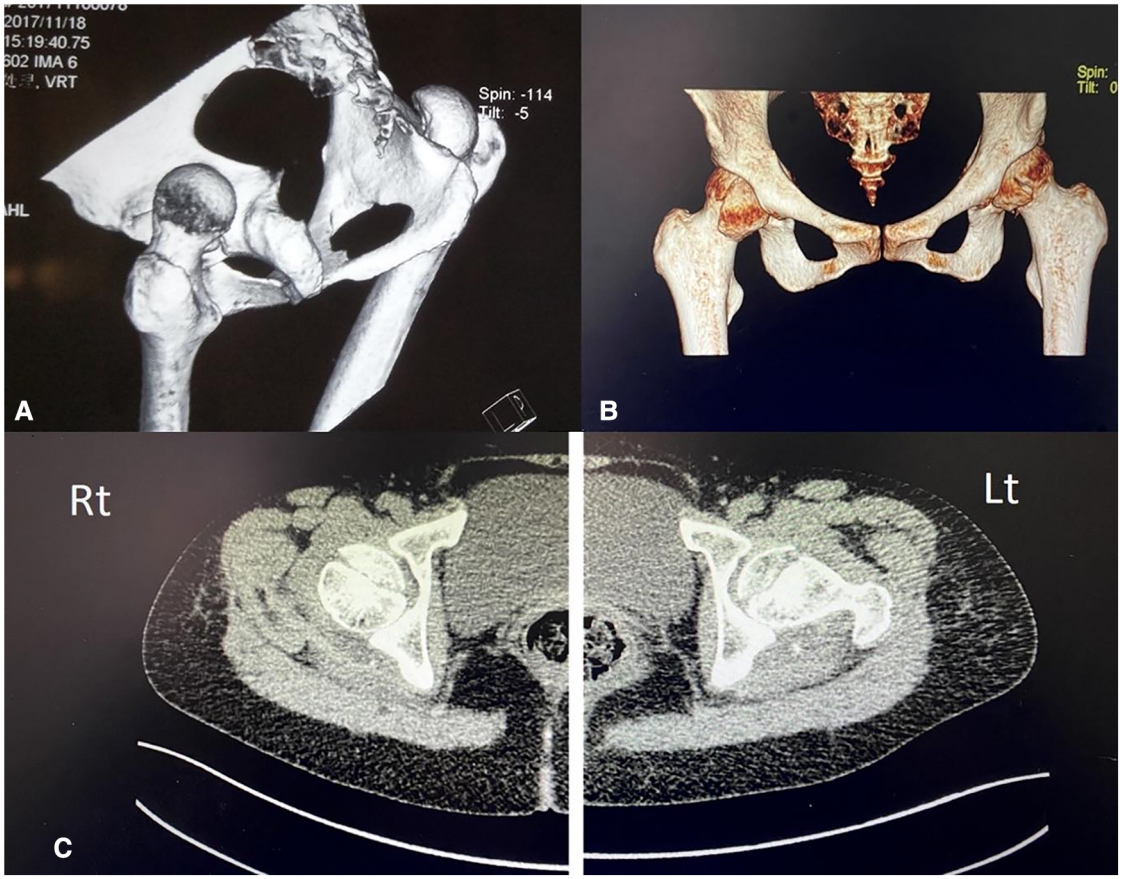

FIGURE 1
(A) 3D CT radiographs showing the bilateral posterior hip dislocation and femoral head fracture before the close reduction maneuver. (B) 3D CT radiographs showing bilateral relocated hip after reduction along with inferior part of femoral head fractures. (C) Plain CT transverse section of images showing bilateral intra-articular fractures of the femoral head.

Surgical procedures

On the fourth day following the incident, we decided to do surgery after a general physical assessment and anesthetic confirmation that the vital signs were stable.

During surgery, we chose the supine position for the DAA method to expose the hip. A surface projection of 2–3 cm lateral and distal to the anterior superior iliac spine was drawn, along with a 10-cm incision that is directed toward the ipsilateral femoral head. To avoid injury to the lateral femoral cutaneous nerve and femoral vessels, the tensor fasciae latae (TFL) was retracted laterally, and the sartorius muscle was retracted medially. T-shaped capsulotomy was performed to release the anterior capsule. The fractured area of the femoral head was fully exposed. The hip joint was then dislocated bilaterally, exposing the femoral head fracture while remaining in external rotation. The femoral head fragments were then reduced under direct vision. Following that, three compressive Herbert screws were installed perpendicular to the fracture line. All the screw heads were buried under the cartilage. Tiny fractured fragments and blood clots within the articulating surface of the hip were removed and washed with normal saline. Rubber drains were placed after closing the capsule (**Figure 2**). The total amount of bleeding for both sides was about 50 mL in 90 min. The rubber drainage was removed on the first postoperative day. On the second day, foot dorsiflexion and static quadriceps strengthening exercises were initiated immediately in bed, and postoperative radiographs were obtained (**Figure 3**). Celecoxib 200 mg BD (two times per day) was regularly used in clinical settings for 3 weeks to treat pain and avoid heterotopic ossification. One week later, joint flexion and extension exercises were performed. The patient was discharged from the hospital on oral medication and physiotherapy. She had no wound infections or lateral femoral cutaneous nerve injuries. The patient was advised to rest in the supine position.



FIGURE 2
Postoperative direct anterior surgical incision over the bilateral femoral head with suture threads and rubber drainage *in situ*.

Outcome and follow-ups

One month after the operation, the patient was advised to perform partial weight bearing with the help of a walker to get out of bed. Eight months after the operation, the patient walked normally with full weight bearing without limping and normal return to daily activity. Follow-ups in first and second years showed improved modified hip score 74 (fair) and 83 (good), respectively.

According to the D'Aubigne range of motion scale, the latest hip score in the fifth year was 86 (good). The patient had a full range of movement in both hips: flexion of 120°, internal rotation of 30°, external rotation of 50°, and abduction of extension of 40°. At five-year follow-up X-rays, there was no incidence of osteonecrosis, heterotopic ossification, or signs of post-traumatic arthritis (**Figure 4**). She resumed daily and normal activities without any disability after a severe tragic incident.

Discussion

Bilateral posterior dislocation of the hip occurs in approximately 1.25% of all hip dislocations (3, 7). Of posterior dislocations, 5–15% are associated with femoral head fractures (8). High-velocity motor accidents are the main cause of dislocations associated with femoral head fractures. Management of these cases is rare and controversial, and few cases have been reported in the literature. Previous studies have focused on the initial close reduction and conservative treatment. Authors such as Guiral et al. (9), and Treacy and Grigoris (10), advocated conservative treatment with skeletal traction with satisfactory outcomes. Whereas Zuckerman 1989 performed the surgical treatment with bilateral cemented total hip replacement (6). **Table 1** consists of a list of English language publications retrieved from PubMed, Embase, and Google Scholar databases for the oldest available case reports and abstracts from 1962 to 2022 for bilateral femoral head fractures (Pipkin fracture). Of these, only 10 were relevant after screening every article and case report, and one case report was excluded due to the unavailability of the abstract or an entire report.

Hip dislocation is an orthopedic emergency, and closed reduction must be performed within 6 h postinjury. The incidence of femoral head necrosis after fracture dislocation of the hip can be high, from 4.8% to 52.9%, depending on the time of reduction (18). Complications such as traumatic injuries to the sciatic nerve (mostly peroneal division), avascular necrosis of the femoral head (AVN), and post-traumatic osteoarthritis (PTOA) can occur after the incidence (19).

Only close reduction of this type of fracture pattern may also lead to AVN up to 5%–15% and may increase to 40%, requiring operative treatments (20). In our case, a closed reduction and conservative method for the larger fractured fragment on the inferior side could adversely influence the joint range of motion and stability. We also know that resection of the fragment in

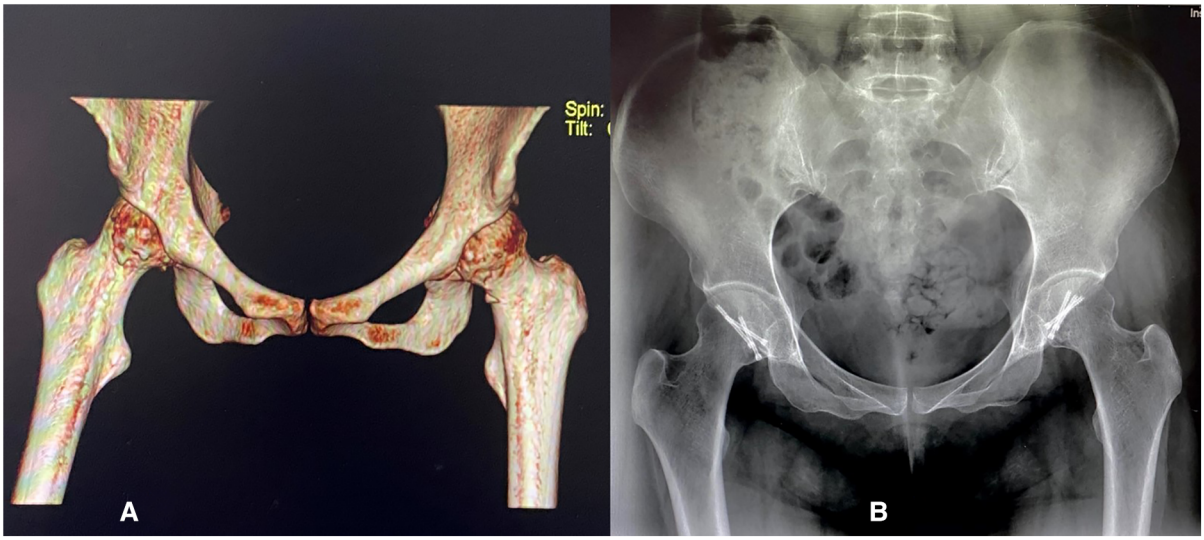

FIGURE 3
(A) Postoperative 3D CT and (B) X-ray anteroposterior (AP) images of the pelvis showing bilateral internal fixation in the femoral heads with three Herbert screws.

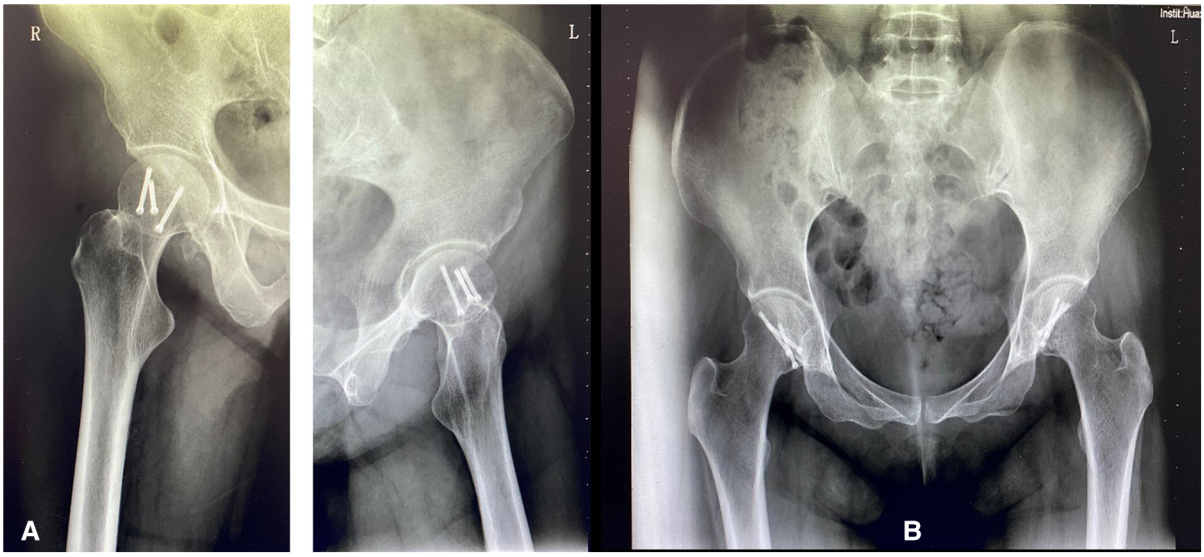

FIGURE 4
(A) X-ray, right and left lateral view (B) Plain x-ray AP view of a pelvis showing bilateral internal fixation of femoral heads during the 5-year follow-up without sign of osteonecrosis and post-traumatic osteoarthritis and heterotopic ossification.

femoral fractures might not significantly affect the loading zone of the femoral head, but long-term consequences such as pain during mobilization and heavyweight bearing leading to arthritis as an outcome should always be considered. Therefore, we took the consideration for open reduction and anatomical internal fixation on bilateral hips.

Previously, it was considered that most internal fixation was performed using the posterior approach. The posterior approach has

TABLE 1 Table showing the follow-up time period and consecutive improvement in modified Harris hip score and D'Aubigne score.

No	Follow-up period	Modified Harris hip score	D'Aubigne score
1.	1 month	50	Poor
2.	1 year	74	Fair
3.	2 years	83	Good
4.	5 years	86	Good

Study	Year	Age/sex	Injury cause	Pipkin type	Treatment type	Approach	Outcome	Follow-up year	Complications
Kuhn et al. (11)	1987	19/female	Motor accident	Lt-IV	Lt-operative IF with screws	Osbornel	Good	1 year	–
				Rt-I	Rt-osteochondral fragment removal	Posterior Approach			
Meislin et al. (6)	1989	63/female	Motor accident	B/L-IV	Cemented THA	Postero-lateral	Good	2 years	Paget's Disease HO II [O]
Guiral et al. (9)	1992	23/female	Motor accident	B/L-II	Nonoperative	–	Good	1 year	–
Treacy et al. (10)	2002	29/female	Motor Accident	B/L-I	Nonoperative	–	Good	2 years	–
Kozin et.al. (12)	1994	71/female	Motor Accident	B/L-II, 35% femoral head fracture	Operative Bipolar end prosthetic replacement	Posterior approach	Good	3 years	Mild subtalar pain
Pascarella et al. (13)	2008 Case 1	23/female	Motor accident	Rt-I Lt-II	Bilaterally remove the intra-articular fragments	Kocher-Langenbach posterior approach	Good	1.5 years	Lt side limitation of rotation, often painful
Matějka et al. (14)	2015	—	Motor accident	Lt-II Rt-I	Lt-nonoperative Rt-operative		Fair	18 months	Arthritis
Gadi et al. (15)	2020	26/male	Motor accident	Lt-IV Rt-I	–	–	–	–	–
Tripathy et al. (16)	2020	23/male	Motor accident	B/L-II	Operative with Herbert screws	Ganz's Trochanteric osteotomy	Good	2 years	–
Pathinathan et al. (17)	2021	32/male	Motor accident	Rt-I. Lt-II	Operative Lt-Herbert screws Rt-Osteochondral fragment removal	RT-K-L approach	Good	3 months	–

been associated with a greater rate of AVN than the anterior approach (21–23). Various operative approaches have been opted for Pipkin fractures depending on the femoral head fragment, the direction of the dislocation, and the associated acetabular fractures.

Several types of approaches are described in the literature: posterior (Kocher–Langenbeck), posterolateral (Moor), anterolateral (Watson Jones), trochanteric flip osteotomy, Gibson surgical hip dislocation, and direct anterior approach (Smith–Peterson) (24, 25). Our preference is for DAA, which is also interchangeably called modified Hunter's anterior surgical approach or Smith–Peterson to treat bilateral Pipkin type II justifying the minimally invasive, adequate exposure for femoral head fixation, surgical positioning in the supine position, short hospital stays and rapid recovery of incision wounds. Our method's major assets are its least invasiveness, adequate femoral head exposure, reduced intraoperative blood loss, quicker surgery time, speedy wound healing, low visual analogue scale (VAS), and practical supine surgical position. The posterior medial femoral circumflex artery, which supplies the majority of the blood to the hip and is susceptible to damage during posterior hip dislocation, is likewise preserved by the direct anterior approach. It is interesting to note that DAA has been analyzed by a multiple researchers; the learning curve is smooth, mastery of the skills can be attained with the proper guidance, and implementation problems are rare (26). The limitation of this approach can be a contradiction in high Body Mass Index (BMI) patients. Intraoperatively, damage to the lateral femoral cutaneous nerve occurs as it passes subcutaneously between the Sartorius and TFL (26, 27).

However, this approach was related to a higher rate of heterotopic ossification (HO) (28–30). According to certain studies, HO is more common in men and elderly patients, as well as those who had primary osteoarthritis, a high body mass index, a low preoperative range of motion, and longer operations (31). We thought that low disruption of the soft tissue due to less invasive surgery, such as DAA, can lead to less local tissue damage and inflammation, especially tenotomy of the gluteus fibers and hip capsule, which may contribute to the low incidence of HO. Furthermore, pharmacological prophylaxis with selective or nonselective Nonsteroidal anti-inflammatory drugs (NSAIDs) can be used to treat HO by preventing bone formation by preventing inflammation and decreasing the osteogenic differentiation of progenitor cells (31).

Pipkin fracture is accompanied by complications such as avascular necrosis, secondary arthritis, peripheral nerve damage, and heterotrophic ossification. Nevertheless, PTOA is a long-term complication and degeneration process of the hip that can manifest as pain, decreased range of motion, and change in gait. The prevalence of PTOA following traumatic hip injury is higher in the elderly, in hip fractures with posterior acetabulum

fractures, and in prolonged traumatic dislocations. Femoral head subchondral impaction or chondral injury during traumatic dislocation increases the risk of end-stage osteoarthritis leading to Total Hip Arthroplasty (THA) by 3.68 times (32). PTOA can be caused by femoral head cartilage lesions or osteochondral fragments in the joint, in addition to the quality of anatomical reduction during osteosynthesis. Even if the joint appears severely damaged on radiography, PTOA can remain silent for a long time and not manifest itself. As a result, long-term clinical monitoring and radiography are required. The radiographs of the patient was checked for signs of avascular necrosis, early sclerosis, and arthritic alterations. The clinical evaluation and radiographic assessment were correlated at the 12th week, 1-, 2-, and 5-year follow-ups.

Recently, we found many other materials, such as bioabsorbable screws, biodegradable polylactide pins, and osteochondral autografts, for the treatment of femoral head defects. Regardless, Herbert or cancellous screws are used abundantly (33). Herbert screws have the advantages of a good fixation strength and biocompatibility. It prevents the screw from protruding into the joint and has less rejection reaction that aids the fragment to part together for bone healing (34).

In summary, bilateral Pipkin fractures are rare. The key lesson to be learned from this case report is the need for immediate reduction of a dislocated hip, followed by open reduction and internal fixation using the minimally invasive direct anterior surgical technique for sufficient surgical access with a safe and effective method to treat HO, AVN, and PTOA after surgery.

Data availability statement

The raw data supporting the conclusions of this article will be made available by the authors, without undue reservation.

Ethics statement

Ethical review and approval were not required for the study on human participants in accordance with the local legislation and institutional requirements. The patients/participants provided their written informed consent to participate in this study. Written informed consent was obtained from the individual(s) for the publication of any potentially identifiable images or data included in this article.

Author contributions

SS wrote the first draft. SS, XD, and JC collects relevant information and materials. SS, XF, and ZX critically revised and edited successive drafts of the manuscript. All authors contributed to the article and approved the submitted version.

Conflict of interest

The authors declare that the research was conducted in the absence of any commercial or financial relationships that could be construed as a potential conflict of interest.

Publisher's note

All claims expressed in this article are solely those of the authors and do not necessarily represent those of their affiliated organizations, or those of the publisher, the editors and the reviewers. Any product that may be evaluated in this article, or claim that may be made by its manufacturer, is not guaranteed or endorsed by the publisher.

References

1. Kloen P, Siebenrock KA, Raaymakers ELFB, Marti RK, Ganz R. Femoral head fractures revisited. *Eur J Trauma*. (2002) 28(4):221–33. doi: 10.1007/s00068-002-1173-4

2. Epstein HC. Traumatic dislocations of the hip. *Clin Orthop Relat Res*. (1973) 92:116–42. doi: 10.1097/00003086-197305000-00011

3. Nana TC, Jules TM, Divine MM, Ndiformuche Z, Horline BT, Ngowo NM, et al. Neglected simultaneous bilateral asymmetric traumatic hip dislocation in a young male managed by closed reduction manoeuvres in a resource-limited setting: a case report. *Trauma Case Rep*. (2023) 44:100782. doi: 10.1016/j.tcr.2023.100782

4. Birkett J. Description of a dislocation of the head of the femur, complicated with its fracture; with remarks by John Birkett (1815–1904). 1869. *Clin Orthop Relat Res*. (2000) 377:4–6. doi: 10.1097/00003086-200008000-00002

5. Pipkin G. Treatment of grade IV fracture-dislocation of the hip. *J Bone Joint Surg Am*. (1957) 39-A(5):1027–42. passim. doi: 10.2106/00004623-195739050-00004

6. Meislin RJ, Zuckerman JD. Bilateral posterior hip dislocations with femoral head fractures. *J Orthop Trauma*. (1989) 3(4):358–61. doi: 10.1097/00005131-198912000-00019

7. Agarwal S, Singh GK, Jain UK, Jyoti G. Simultaneous anterior and posterior traumatic dislocation of the hip. A case report with review of the literature. *Arch Orthop Trauma Surg*. (2000) 120(3–4):236–8. doi: 10.1007/s004020050055

8. Enocson A, Wolf O. Pipkin fractures: epidemiology and outcome. *Eur J Trauma Emerg Surg*. (2022) 48(5):4113–8. doi: 10.1007/s00068-022-01951-w

9. Guiral J, Jerez J, Oliart S. Bilateral Pipkin type II fracture of the femoral head. *Injury*. (1992) 23(6):417–8. doi: 10.1016/0020-1383(92)90022-K

10. Treacy RB, Grigoris PH. Bilateral Pipkin type I fractures. *Injury*. (1992) 23 (6):415–6. doi: 10.1016/0020-1383(92)90021-J

11. Kuhn DA, Frymoyer JW. Bilateral traumatic hip dislocation. *J Trauma*. (1987) 27(4):442–4. doi: 10.1097/00005373-198704000-00019

12. Kozin SH, Kolessar DJ, Guanche CA, Marmar EC. Bilateral femoral head fracture with posterior hip dislocation. *Orthop Rev*. (1994) (Suppl):20–4. https://pubmed.ncbi.nlm.nih.gov/7854835/#linkout

13. Pascarella R, Maresca A, Cappuccio M, Reggiani LM, Boriani S. Asymmetrical bilateral traumatic fracture dislocation of the hip: a report of two cases. *Chir Organi Mov*. (2008) 92(2):109–11. doi: 10.1007/s12306-008-0045-4

14. Matějka J, Koudela K. Bilateral fractures of the femoral head (Pipkin I and Pipkin II). *Acta Chir Orthop Traumatol Cech*. (2002) 69(6):369–71. https://pubmed.ncbi.nlm.nih.gov/12587499/

15. Gadi D, Singh R, Anand V, Pathak S. Unique simultaneous dual mechanism based bilateral femoral head fracture secondary to posterior dislocation of hip: a rare case report. *Int J Med*. (2015) 3:112–4. doi: 10.14419/ijm.v3i2.5183

16. Tripathy SK, Das SS, Rana R, Jain M. Trochanteric osteotomy for safe surgical approach to bilateral hip dislocations with femoral head fractures. *J Clin Orthop Trauma*. (2020) 11(Suppl 4):S530–3. doi: 10.1016/j.jcot.2020.04.018

17. Pathinathan K, Marage N, Fernando N. Bilateral irreducible asymmetrical fracture-dislocation of the hip: a case report and literature review. *Int J Surg Case Rep*. (2021) 81:105803. doi: 10.1016/j.ijscr.2021.105803

18. Milenkovic S, Mitkovic M, Mitkovic M. Avascular necrosis of the femoral head after traumatic posterior hip dislocation with and without acetabular fracture. *Eur J Trauma Emerg Surg*. (2022) 48(1):613–9. doi: 10.1007/s00068-020-01495-x

19. Sen RK, Tripathy SK, Goyal T, Aggarwal S, Kashyap S, Purudappa PP, et al. Complications and functional outcome of femoral head fracture-dislocation in delayed and neglected cases. *Indian J Orthop*. (2021) 55(3):595–605. doi: 10.1007/s43465-020-00309-x

20. Lam F, Walczak J, Franklin A. Traumatic asymmetrical bilateral hip dislocation in an adult. *Emerg Med J*. (2001) 18(6):506–7. doi: 10.1136/emj.18.6.506

21. Del Core MA. Clinical and radiographic outcomes of femoral head fractures associated with traumatic hip dislocations. *Strategies Trauma Limb Reconstr*. (2019) 14(1):6–10. doi: 10.5005/jp-journals-10080-1416

22. Giordano V, Giordano M, Gloria RC, de Souza FS, di Tullio P, Lages MM, et al. General principles for treatment of femoral head fractures. *J Clin Orthop Trauma*. (2019) 10(1):155–60. doi: 10.1016/j.jcot.2017.07.013

23. Swiontkowski MF, Thorpe M, Seiler JG, Hansen ST. Operative management of displaced femoral head fractures: case-matched comparison of anterior versus posterior approaches for Pipkin I and Pipkin II fractures. *J Orthop Trauma*. (1992) 6(4):437–42. doi: 10.1097/00005131-199212000-00008

24. Schenker ML, Davis ME, Ahn J. Femoral head fractures. In: Nho SJ, Bedi A, Salata MJ, Mather RC III, Kelly BT, editors. *Hip arthroscopy and hip joint preservation surgery*. Cham: Springer International Publishing (2022). p. 1421–32.

25. De Mauro D, Rovere G, Smakaj A, Marino S, Ciolli G, Perna A, et al. Gibson approach and surgical hip dislocation according to Ganz in the treatment of femoral head fractures. *BMC Musculoskelet Disord*. (2021) 22(Suppl 2):961. doi: 10.1186/s12891-021-04800-w

26. Realyvasquez J, Singh V, Shah AK, Ortiz D 3rd, Robin JX, Brash A, et al. The direct anterior approach to the hip: a useful tool in experienced hands or just another approach? *Arthroplasty*. (2022) 4(1):1. doi: 10.1186/s42836-021-00104-5

27. Petis S, Howard JL, Lanting BL, Vasarhelyi EM. Surgical approach in primary total hip arthroplasty: anatomy, technique and clinical outcomes. *Can J Surg*. (2015) 58(2):128–39. doi: 10.1503/cjs.007214

28. Liu B, Zhao B, Zhang Q. Efficacy of direct anterior approach combined with direct posterior approach in Pipkin IV femoral head fractures. *J Orthop Surg Res*. (2022) 17(1):160. doi: 10.1186/s13018-022-03058-9

29. Wang C-G, Li Y-M, Zhang H-F, Li H, Li Z-J. Anterior approach versus posterior approach for Pipkin I and II femoral head fractures: a systemic review and meta-analysis. *Int J Surg*. (2016) 27:176–81. doi: 10.1016/j.ijsu.2016.02.003

30. Guo JJ, Tang N, Yang HL, Qin L, Leung KS. Impact of surgical approach on postoperative heterotopic ossification and avascular necrosis in femoral head fractures: a systematic review. *Int Orthop*. (2010) 34(3):319–22. doi: 10.1007/s00264-009-0849-3

31. Xu Y, Huang M, He W, He C, Chen K, Hou J, et al. Heterotopic ossification: clinical features, basic researches, and mechanical stimulations. *Front Cell Dev Biol*. (2022) 10:770931. doi: 10.3389/fcell.2022.770931

32. Rollmann MF, Holstein JH, Pohlemann T, Herath SC, Histing T, Braun BJ, et al. Predictors for secondary hip osteoarthritis after acetabular fractures—a pelvic registry study. *Int Orthop*. (2019) 43(9):2167–73. doi: 10.1007/s00264-018-4169-3

33. Kosashvili Y, Raz GM, Backstein D, Lulu OB, Gross AE, Safir OA. Fresh-stored osteochondral allografts for the treatment of femoral head defects: surgical technique and preliminary results. *Int Orthop*. (2013) 37:1001–6. doi: 10.1007/s00264-013-1868-7

34. Zhao B, Li H, Yan J, Han LR, Yang XF. Pipkin type III femoral head fracture-dislocation combined with complicated acetabular fracture: a rare case report and literature review. *Medicine*. (2017) 96(50):e9214. doi: 10.1097/MD.0000000000009214

frontiers | Frontiers in Surgery

TYPE Original Research
PUBLISHED 09 May 2023
DOI 10.3389/fsurg.2023.1129809

Check for updates

OPEN ACCESS

EDITED BY
Paphon Sa-ngasoongsong,
Mahidol University, Thailand

REVIEWED BY
Xiaodong Yan,
Tangdu Hospital, China
Feng Yuan,
The Affiliated Hospital of Xuzhou Medical University, China

*CORRESPONDENCE
Haisong Yang
✉ yangspine@163.com
Xuhua Lu
✉ xuhualu@hotmail.com

†These authors have contributed equally to this work and share first authorship

RECEIVED 22 December 2022
ACCEPTED 11 April 2023
PUBLISHED 09 May 2023

CITATION
Wang L, Wang H, Wang C, Zhang B, Yang H and Lu X (2023) Comparative study of halo-vest reduction and skull traction reduction in the treatment of cervical fracture dislocation in patients with ankylosing spondylitis.
Front. Surg. 10:1129809.
doi: 10.3389/fsurg.2023.1129809

COPYRIGHT
© 2023 Wang, Wang, Wang, Zhang, Yang and Lu. This is an open-access article distributed under the terms of the Creative Commons Attribution License (CC BY). The use, distribution or reproduction in other forums is permitted, provided the original author(s) and the copyright owner(s) are credited and that the original publication in this journal is cited, in accordance with accepted academic practice. No use, distribution or reproduction is permitted which does not comply with these terms.

Comparative study of halo-vest reduction and skull traction reduction in the treatment of cervical fracture dislocation in patients with ankylosing spondylitis

Liang Wang[1,2†], Haibin Wang[2†], Can Wang[3†], Bangke Zhang[2], Haisong Yang[2*] and Xuhua Lu[1,2*]

[1]School of Health Science and Engineering, University of Shanghai for Science and Technology, Shanghai, China, [2]Department of Orthopaedics, Second Affiliated Hospital of Naval Medical University, Shanghai, China, [3]Department of Orthopaedics, Affiliated Hospital of North Sichuan Medical College, Sichuan, China

Background: This study aimed to investigate the safety and efficacy of the halo-vest in the treatment of cervical fracture in patients with ankylosing spondylitis (AS) and kyphosis.
Methods: From May 2017 to May 2021, 36 patients with cervical fractures with AS and thoracic kyphosis were included in this study. The patients with cervical spine fractures with AS underwent preoperative reduction by halo-vest or skull tractions. Instrumentation internal fixation and fusion surgery were then performed. The level of cervical fractures, the operative duration, blood loss, and treatment outcomes were investigated preoperatively and postoperatively.
Results: A total of 25 cases were included in the halo-vest group and 11 cases were included in the skull tractions group. The intraoperative blood loss and the surgery duration were significantly less in the halo-vest group than in the skull traction group. A comparison of American Spinal Injury Association scores at admission and final follow-up showed that the neurological function of patients improved in both groups. All patients had reached solid bony fusion during the follow-up.
Conclusion: This study presented a unique approach to use halo-vest treatment fixation of unstable cervical fracture in patients with AS. The patient should also have early surgical stabilization with a halo-vest to correct spinal deformity and avoid worsening of neurological status.

KEYWORDS

ankylosing spondylitis (AS), halo-vest immobilization, skull traction, cervical spine trauma, American Spinal Injury Association (ASIA) impairment scale, cervical traction

Introduction

Ankylosing spondylitis (AS) is a chronic autoimmune disease involving axial joints, peripheral joints, and even extra-articular organs. Compared with the general population, patients with AS are about four times more likely to experience cervical spine fractures (1, 2). Due to the ossification of paravertebral ligaments and intervertebral discs, osteopenia, osteoporosis, and joint erosion, the patient's activities are limited, the spine may be rigid and deformed, and the stability function is poor (3). Therefore, the risk of spinal fracture is high, especially in the C5–7 segment of the cervical spine, which is

prone to low-energy fractures (4, 5). Even a low-energy accident can result in a serious neurological injury (6). Most neurological injuries accompany mechanical injury or prior to stabilization (halo-vest or skull traction), and the long lever arm is extremely unstable compared to cervical spine fractures in healthy individuals (7–9). Neurological deficits may accompany vertebral fractures or displacements (especially in hyperextension injuries) (10). In addition, AS patients with highly unstable mechanical injuries are at higher risk for secondary neurological injury. Morbidity and mortality are higher in older AS patients than younger AS patients with similar or more severe injuries (11).

When vertebral fractures occur in AS patients, the spine becomes very unstable, and primary and secondary nerve damage and progressive deformity are avoided (12). Skull traction is a widely used for reduction and immobilization in patients with cervical fracture dislocation (13). However, skull traction therapy is challenging because patients with AS may have kyphosis, primarily when the kyphosis is located in the thoracic spine (14). Due to unstable fractures and dislocation of cervical spine in AS, skull traction has the risk of aggravating neurological symptoms (15). A halo-vest is an effective adjuvant tool for correcting spinal deformities (16, 17). After reducing supine or prone fractures, the halo-vest is used to externally fix the patient, providing the most potent external fixation for the upper cervical spine.

However, the optimal preoperative traction approach for cervical spine fractures in AS patients remains controversial. This study reports on our experience in treating patients with AS cervical spine fractures to stabilize the fracture to prevent neurological deterioration and partially correct the deformity from restoring the preinjury state.

Material and methods

From May 2017 to May 2021, 36 AS and kyphosis patients with cervical spine fractures received halo-vest or skull traction to assist closed preoperative reduction. This study utilized a retrospective chart review and radiology follow-up study, including plain radiographs and magnetic resonance imaging (MRI) (**Figures 1A–C**). The fractures of all AS patients involved the anterior column to the posterior column, along with the fractures of ossified anterior and posterior ligamentous complexes and the surrounding tissue. All 36 patients were diagnosed with AS preoperatively, and 24 received AS medication. The reduction was assessed by x-ray examination of lateral cervical vertebrae beside bed. Anatomical reduction was defined as a <1 mm distance between two surgically restored vertebral bodies; reduction success was defined as a 1- to 3-mm distance, and reduction failure was defined as a >3 mm distance (18).

Halo-vest procedure

Halo-vest reduced the fracture, and the patient underwent x-ray examination after reduction. Halo-vest devices are applied in a standardized manner based on usual clinical methods. First, the patient's head is supported by a cervical collar and placed in a supine position. Next, the surgeon lifted the behind of the head ring upward, and simultaneously the assistant moved down the front of the head ring. The steps were repeated until the patient restored the preinjury status. The surgeon and assistant then tightened each pin using a torque screwdriver. Finally, plain

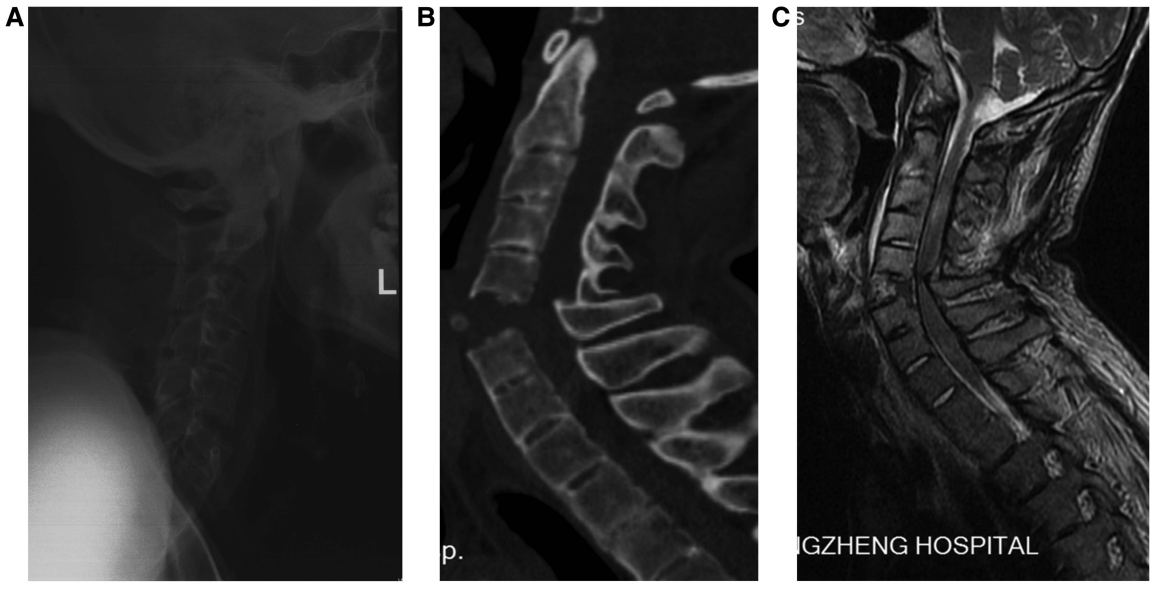

FIGURE 1
A 57-year-old man with AS and thoracic kyphosis and was diagnosed as fracture dislocation at C5/6. (A) Lateral radiography reveal a severe dislocated fracture at C5–6 levels with significant widen at C5–6 intervertebral space and so-called bamboo spine resulting from ankylosing spondylitis. (B) Sagittal CT showing fracture dislocation at C5/6. (C) MRI demonstrating increased signal segmentally at the level of the fracture indicate total segmental disruption. AS, ankylosing spondylitis; MRI, magnetic resonance imaging.

lateral x-rays were taken to evaluate the cervical spine under conditions of halo-vest fixation (Figure 2). Halo-vest immobilization lasted for a mean period of 2 ± 1 days before operative stabilization.

Surgical treatment slows or stabilizes a patient's neurological deficit and instability. With the patient kept awake, nasotracheal intubation was used, followed by general anesthesia, and the patient was carefully placed in a sitting position using a halo-vest (Figure 3). To avoid displacement of the patient's fracture site, the surgeon needs to hold the halo-vest and transfer the patient from the stretcher to the operating table. If preoperative reduction failed, it was repeated after repositioning via regulation of the length of the anterior and posterior bars of the halo-vest under neurophysiologic monitoring until satisfactory restoration was achieved.

Skull tractions

Skull tractions with a traction weight of 4–6 kg were performed on patients with fracture dislocations after admission. The traction direction was in line with the neck to reduce dislocation or fracture dislocation. Immobilization in flexion by placing sandbags under occiput reduces the fracture and prevents cord damage. The patients received x-ray examination of lateral cervical vertebrae beside bed before nasoendotracheal intubation and induction of general anesthesia. The skull tractions lasted for a mean period of 2 ± 1 days before operative stabilization.

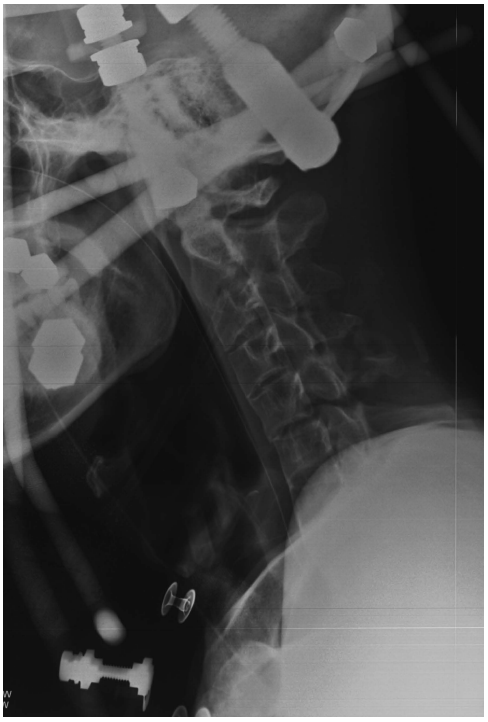

FIGURE 2
Reduction of cervical fractures in patients with AS from the perspective of a C-arm radiograph system. AS, ankylosing spondylitis.

Operative approach

The posterior approach as the first choice was operated to restore the spinous process and performed with at least two segments fixed both upper and lower. If the fracture dislocations were reduced, the patients were treated with the simple posterior instrumentation internal fixation and fusion surgery. For those patients with excessive separation in anterior fractures or apparent anterior compression, anterior–posterior instrumentation internal fixation and fusion surgery were adopted. Intraoperative neurophysiologic monitoring was performed. Finally, x-ray films were used to check the patient's fracture reduction and fixation maintenance (Figures 4A,B). Patients were treated with corresponding surgeries.

Follow-up

One day post-operation, the patients were allowed to sit with a Philadelphia collar. The Philadelphia collar was used for 2 months. Patients were monitored for radiographic and neurological outcomes. Complications were also recorded, such as infection, dysphagia, death, screw loosening and breaking, fusion cage subsidence, and rod breakage. The American Spinal Injury Association (ASIA) impairment scale was used to evaluate the neurological status pre-and post-operation. All patients received an x-ray of the whole cervical spine or an MRI of the cervical spine if required.

Statistical analysis

SPSS 21.0 software (IBM Corp., Armonk, NY, United States) was used for statistical analysis. The *t* test was used for



FIGURE 3
Nasotracheal intubation and sitting position with halo-vest.

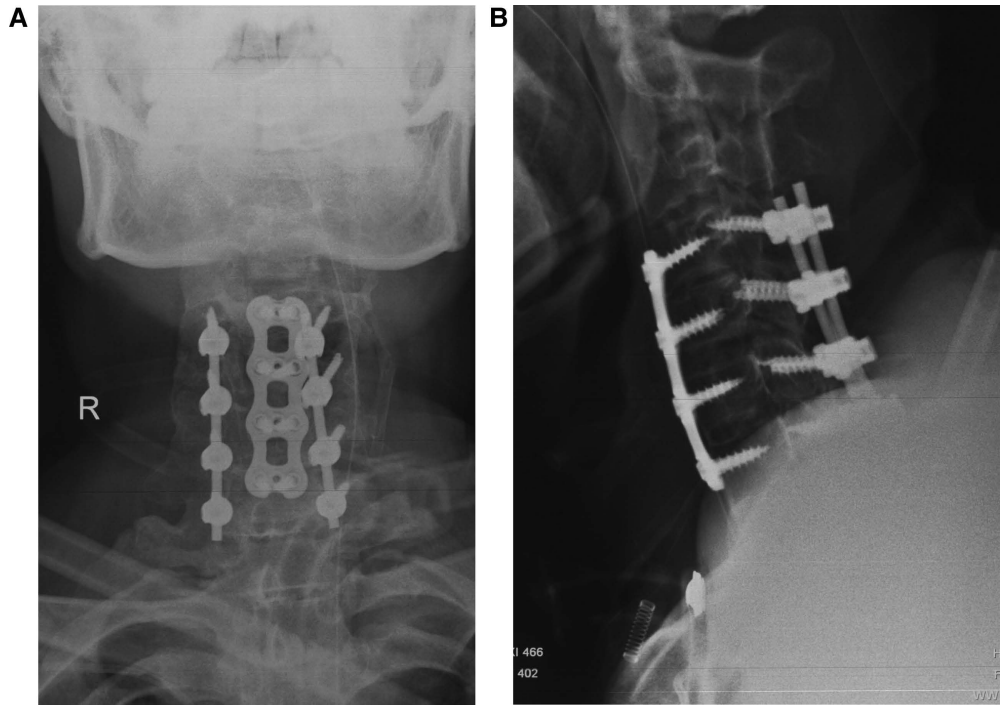

FIGURE 4
Postoperative plain radiography (A,B).

comparison of the mean between the two groups, and the Chi-square test was used for comparison of the ratio between the two groups. P <0.05 was considered statistically significant.

Results

The demographic characteristics of the 36 patients in the two groups are listed in Table 1. From May 2017 to May 2021, 25 cases were in included in the halo-vest group and 11 cases were included in the skull tractions group. A single spinal segment was involved in each patient. The mean age was 58.5 ± 6.1 years, range 49–68 years. Thirty-five AS patients with fracture dislocation of the cervical spine received posterior or combined anterior–posterior approach within 3 days after injury. In the halo-vest group, the fracture levels were odontoid in 2 patients, C2/3 in 3 patients, C4/5 in 5 patients, C5/6 in 13 patients, and C6/7 in 2 patients. Among the skull traction group, 1 patient was diagnosed with odontoid fractures, 2 patients were diagnosed with C2–3 fractures, 1 patient was diagnosed with C3–C4 fractures, 3 patients were diagnosed with C4–C5 fractures, 3 patients were diagnosed with C5–C6 fractures, and 1 patient was diagnosed with C6–C7 fractures (Table 1).

In the present study, satisfactory preoperative reductions occurred in 25 patients in the halo-vest group and in 5 patients in the skull traction group, and no further neurological decline occurred in the follow-up. In the halo-vest group, 16 patients were treated by combined anterior and posterior approach and the others by posterior approach alone. In the skull traction group, 7 patients were treated by a combined anterior and posterior approach and 4 patients by simple posterior approach. The mean surgical duration for patients with halo-vest was 180.36 ± 55.74 min, while it was 238.63 ± 56.78 min for patients with skull traction ($P < 0.05$). The skull traction group had more blood loss (415.45 ± 59.05 ml vs. 310.40 ± 16.19 ml, $P < 0.05$) than the halo-vest group. The present study showed no statistical difference in the operative approach between the halo-vest group and the skull traction group ($P > 0.05$).

All patients were followed up postoperatively: average follow-up period was 12–36 months. Bone fusions were observed in 9 of 11 patients (81%) in the skull traction group and 24 of 25 patients (96%) in the halo-vest group. The differences in ASIA score between groups were not statistically significant before surgery. In the halo-vest group, 1 case was grade A, 2 cases were grade B, 8 cases were grade C, 12 cases were grade D, and 2 cases were grade E. In the skull traction group, two cases were grade A, three cases were grade B, one case was grade C, three cases were grade D, and one case was grade E. Over follow-up, neural function was recovered in all patients. In the halo-vest group, one improved grades from B to C, one improved grades from B to D, eight improved grades from C to D, and six improved grades from D to E. In the skull traction group, one patient with grade A showed no significant neurological recovery, but one with grade A became grade B, one of two grade A became grade B postoperatively, two of three grade B became grade C postoperatively, one of three grade B became grade D postoperatively, one with grade C became grade D postoperatively, and four with grade D became grade E postoperatively (Table 1).

TABLE 1 Baseline characteristics of patients in the two groups.

Characteristics	Halo-vest	Skull traction	*P*
Age (years)	54.56 ± 9.19	48.00 ± 7.14	
Gender			0.913
Male	23 (92.0%)	10 (90.9%)	
Female	2 (8.0%)	1 (9.1%)	
Preoperative ASIA grade			0.220
A	1 (4.0%)	2 (18.2%)	
B	2 (8.0%)	3 (27.3%)	
C	8 (32.0%)	1 (9.10%)	
D	12 (48.0%)	4 (36.4%)	
E	2 (8.0%)	1 (9.10%)	
Postoperative ASIA grade			0.051
A	–	1 (9.1%)	
B	–	1 (9.1%)	
C	1 (4.2%)	2 (18.2%)	
D	15 (62.5%)	2 (18.2%)	
E	8 (33.3%)	5 (45.5%)	
Damaged segment			0.588
OF	2 (8.0%)	1 (9.1%)	
C2/3	3 (12.0%)	2 (18.2%)	
C3/4	−(0.0%)	1 (9.1%)	
C4/5	5 (20.0%)	3 (27.3%)	
C5/6	13 (52.0%)	3 (27.3%)	
C6/7	2 (8.0%)	1 (9.1%)	
Complication	1	2	0.001*
Surgery duration (min)	180.36 ± 55.74	238.63 ± 56.78	0.007*
Blood loss (ml)	310.40 ± 16.19	415.45 ± 59.05	0.001*
Type of reduction			0.356
Successful	2 (8.0%)	1 (9.1%)	
Anatomical	22 (88.0%)	4 (72.7%)	
Failed	1 (4.0%)	6 (18.2%)	
Bone fusions	24	9	0.310
Operative approach			0.861
Combined anterior and posterior approach	16	7	
Posterior approach alone	8	4	

ASIA, American Spinal Injury Association; OF, odontoid fracture.
*$P < 0.05$.

Complications

Complications occurred in one case with the halo-vest. However, lung pneumonia was diagnosed in one case with halo-vest-assisted closed reduction (ASIA grade A) before surgery. He was unable to undergo surgery and died 9 days after the injury. Surgery-related complications were not observed. In the skull traction group, postoperative complications occurred in two patients (18.2%), including implant failure ($n = 1$) and pneumonia ($n = 1$) (Table 1). The one patient with the AS fracture dislocation experienced early implant failure (screw loosening) 10 days postoperatively due to great local stresses which was related to skull traction treatment that could not completely reduce the AS cervical spine fractures during the operation; this patient required revision surgery and anterior–posterior fixation. Pneumonia in the patient was related to skull traction treatment for a long time in bed.

Discussion

Compared with the general population, patients with AS are more likely to develop spinal fractures and spinal cord injuries (19). However, the incidence of AS is low, and it is difficult to count such patients; there is a lack of treatment and clinical information for patients with fractures. Therefore, correcting fracture deformities in AS patients is challenging. The closed reduction of the cervical fracture dislocation in patients with AS has been previously described and is now a recognized procedure (20). However, the safety of closed reduction has been the focus of debate for some time. This study compared halo-vest reduction and skull traction for AS cervical spine fractures.

Recently, some studies reported the treatment of spinal fractures in AS patients (21, 22). Longo et al. reported that more than 80% of the patients' injuries were low-energy cervical spine injuries, which led to the dislocation of the cervical spine structure in AS patients and unstable cervical spine fracture morphology (23). Due to the high risk of fracture and dislocation in AS patients, secondary neurological deterioration and progressive deformity may occur, resulting in a poor clinical prognosis. Therefore, patients with AS cervical spine fractures require close monitoring and early rehabilitation.

The utility of the skull traction is widespread, and they have proven useful for cervical fracture dislocation and temporary stabilization (24). While it can make subsequent operation easier, failure rates are reported to be high. Excessive skull traction could aggravate vertebral artery and neurological injuries. If the patient with AS had cervical kyphosis, skull traction should not be used for neck traction (25). However, skull traction could not completely reduce the AS cervical spine fractures in the absence of general anesthesia. Although skull traction has been believed to be safe under general anesthesia, Sornatosensoryevokedpotentials (SEPs) should be used to monitor neurologic signals (26).

In this research and our clinical work, our data proposed that the halo-vest could be the optimal solution for early therapy of cervical spine fracture in AS patients. In this study, 25 patients with AS cervical spine fracture were treated with the halo-vest, and all patients successfully reduced the fracture site. Short-term use of the halo-vest can instantly stabilize the patient's neurological state, relieve spinal cord compression, and improve the cervical spine sequence. The advantages of the halo-vest include more precise cervical spine positioning, success in maintaining reduction, effective immobilization, and the ability to allow early mobilization of the patient (27). Through halo-vest, patients can receive safer and more effective surgical treatment after cervical spine reduction. Because of the effective reduction before operation that cloud shorten the time of surgical reduction, patients with halo-vest reduction have less bleeding and shorter operation time than patients with skull traction reduction. Therefore, surgeons should pay more attention to the type of cervical fracture to comprehensively consider the selection of appropriate surgical methods.

Although the halo-vest offers the best stabilization than other external immobilizers, it does not rigidly immobilize the cervical

spine. Lee et al. reported that the halo device caused spinal instability, and increased range of motion was not conducive to bone fusion and self-healing (28). The halo-vest increased the cervical spine range of motion at the C2/C3 segment in the general population by 42%. The lower the cervical spine segment, the greater the range of motion, accompanied by a poorer fixation effect (29). Not only that, but in elderly patients, external fixation also carries risks. Prolonged external fixation is associated with a high risk of detachment or reduction, skin ulceration, and lung problems (30, 31). Some studies reported that surgical treatment in the early stage of the disease has a lower incidence of pseudarthrosis and neurologic deficits and a better prognosis (15, 32). Therefore, to avoid complications related to conservative treatment, especially the needle site infection and the deterioration of the nervous system, the patient should still undergo surgical treatment as soon as possible to stabilize the condition. Therefore, the authors believe that the main purpose of preoperative halo-vests is temporary external stabilization of the injured cervical spine and that early surgical intervention should be performed regardless of the results of preoperative halo-vests. However, patients with AS may experience postural deterioration and iatrogenic spinal fractures during surgery. Halo-vest reduction should be used to avoid movement in patients with AS fractures and correct spinal flexion deformity after AS trauma. It is easier to remove bone fragments and complete decompression after cervical spine reduction with halo-vests (33, 34). This study found that the adjustment and control of the halo-vest stent can complete the three-dimensional adjustment of the cervical spine, improve the success rate of reduction, and effectively avoid secondary nerve damage.

The current study also has limitations. First, the sample size is relatively small, and the follow-up was relatively short in this study. Second, as with any retrospective study, selection and measurement can be biased. The retrospective results from a single-center should be prospectively verified by multicenter and randomized controlled studies. Therefore, future studies should be prospective, randomized, controlled, and longer.

Conclusion

In summary, skull traction is advocated because of its ease of use, whereas a halo-vest can be preferred in AS patients with cervical spine fractures. Successful reduction and satisfactory neurological recovery can be achieved by halo-vest for cervical fracture dislocation in patients with AS. It provides safe, simple, and accurate cervical traction and cervical fixation for AS patients after fracture. After cervical spine reduction, patients can receive safer and more effective surgical treatment.

Data availability statement

The datasets presented in this study can be found in online repositories. The names of the repository/repositories and accession number(s) can be found in the article.

Ethics statement

The studies involving human participants were reviewed and approved by Helsinki Declaration of 1975. The patients/participants provided their written informed consent to participate in this study. Written informed consent was obtained from the individual(s) for the publication of any potentially identifiable images or data included in this article.

Author contributions

LW: conceptualization, roles/writing—original draft, and methodology. HW: data curation, software, and investigation. CW: data curation and formal analysis. BZ: writing—review and editing. HY: supervision and visualization. XL: conceptualization, funding acquisition, and supervision. All authors contributed to the article and approved the submitted version.

Funding

This work was supported by the National Natural Science Foundation of China (No. 81572201) and the Project of Shanghai Municipal Commission of Health and Family Planning (No. 201540379).

Conflict of interest

The authors declare that the research was conducted in the absence of any commercial or financial relationships that could be construed as a potential conflict of interest.

Publisher's note

All claims expressed in this article are solely those of the authors and do not necessarily represent those of their affiliated organizations, or those of the publisher, the editors and the reviewers. Any product that may be evaluated in this article, or claim that may be made by its manufacturer, is not guaranteed or endorsed by the publisher.

References

1. Colterjohn NR, Bednar DA. Identifiable risk factors for secondary neurologic deterioration in the cervical spine-injured patient. *Spine*. (1995) 20(21):2293–7. doi: 10.1097/00007632-199511000-00006

2. Boonen A, van der Linden SM. The burden of ankylosing spondylitis. *J Rheumatol Suppl*. (2006) 78:4–11.

3. Yang B, Lu T, Li H. Single-session combined anterior-posterior approach for treatment of ankylosing spondylitis with obvious displaced lower cervical spine fractures and dislocations. *Biomed Res Int*. (2017) 2017:9205834. doi: 10.1155/2017/9205834

4. Einsiedel T, Schmelz A, Arand M, Wilke HJ, Gebhard F, Hartwig E, et al. Injuries of the cervical spine in patients with ankylosing spondylitis: experience at two trauma centers. *J Neurosurg Spine*. (2006) 5(1):33–45. doi: 10.3171/spi.2006.5.1.33

5. An SB, Kim KN, Chin DK, Kim KS, Cho YE, Kuh SU. Surgical outcomes after traumatic vertebral fractures in patients with ankylosing spondylitis. *J Korean Neurosurg Soc*. (2014) 56(2):108–13. doi: 10.3340/jkns.2014.56.2.108

6. Kouyoumdjian P, Guerin P, Schaelderle C, Asencio G, Gille O. Fracture of the lower cervical spine in patients with ankylosing spondylitis: retrospective study of 19 cases. *Orthop Traumatol Surg Res*. (2012) 98(5):543–51. doi: 10.1016/j.otsr.2012.03.011

7. Feldtkeller E, Vosse D, Geusens P, van der Linden S. Prevalence and annual incidence of vertebral fractures in patients with ankylosing spondylitis. *Rheumatol Int*. (2006) 26(3):234–9. doi: 10.1007/s00296-004-0556-8

8. Argenson C, Lovet J, Sanouiller JL, de Peretti F. Traumatic rotatory displacement of the lower cervical spine. *Spine*. (1988) 13(7):767–73. doi: 10.1097/00007632-198807000-00010

9. Foo D, Sarkarati M, Marcelino V. Cervical spinal cord injury complicating ankylosing spondylitis. *Paraplegia*. (1985) 23(6):358–63. doi: 10.3969/j.issn.1003-0034.2018.06.001

10. Whang PG, Goldberg G, Lawrence JP, Hong J, Harrop JS, Anderson DG, et al. The management of spinal injuries in patients with ankylosing spondylitis or diffuse idiopathic skeletal hyperostosis: a comparison of treatment methods and clinical outcomes. *J Spinal Disord Tech*. (2009) 22(2):77–85. doi: 10.1097/BSD.0b013e3181679bcb

11. Werner BC, Samartzis D, Shen FH. Spinal fractures in patients with ankylosing spondylitis: etiology, diagnosis, and management. *J Am Acad Orthop Surg*. (2016) 24(4):241–9. doi: 10.5435/JAAOS-D-14-00149

12. Einsiedel T, Kleimann M, Nothofer W, Neugebauer R. Special considerations in therapy of injuries of the cervical spine in ankylosing spondylitis (Bechterew disease). *Unfallchirurg*. (2001) 104(12):1129–33. doi: 10.1007/s001130170003

13. Uche EO, Nwankwo OE, Okorie E, Muobike A. Skull traction for cervical spinal injury in Enugu: a 5-year retrospective multicenter analysis of the clinical outcomes of patients treated with two common devices. *Niger J Clin Pract*. (2016) 19(5):580–4. doi: 10.4103/1119-3077.188713

14. Kurucan E, Bernstein DN, Mesfin A. Surgical management of spinal fractures in ankylosing spondylitis. *J Spine Surg*. (2018) 4(3):501–8. doi: 10.21037/jss.2018.06.15

15. Schneider PS, Bouchard J, Moghadam K, Swamy G. Acute cervical fractures in ankylosing spondylitis: an opportunity to correct preexisting deformity. *Spine*. (2010) 35(7):E248–52. doi: 10.1097/BRS.0b013e3181c7c8d2

16. Mattei TA, Rehman AA, Issawi A, Fassett DR. Surgical challenges in the management of cervical kyphotic deformity in patients with severe osteoporosis: an illustrative case of a patient with Hajdu-Cheney syndrome. *Eur Spine J*. (2015) 24(12):2746–53. doi: 10.1007/s00586-015-4092-x

17. Xia L, Li P, Wang D, Bao D, Xu J. Spinal osteotomy techniques in management of severe pediatric spinal deformity and analysis of postoperative complications. *Spine*. (2015) 40(5):E286–92. doi: 10.1097/BRS.0000000000000728

18. He A, Xie D, Cai X, Qu B, Kong Q, Xu C, et al. One-stage surgical treatment of cervical spine fracture-dislocation in patients with ankylosing spondylitis via the combined anterior-posterior approach. *Medicine*. (2017) 96(27):e7432. doi: 10.1097/MD.0000000000007432

19. Lukasiewicz AM, Bohl DD, Varthi AG, Basques BA, Webb ML, Samuel AM, et al. Spinal fracture in patients with ankylosing spondylitis: cohort definition, distribution of injuries, and hospital outcomes. *Spine*. (2016) 41(3):191–6. doi: 10.1097/BRS.0000000000001190

20. Lv GH, Wang B, Kang YJ, Lu C, Ma ZM, Deng YW. Combined anterior and posterior surgery for treatment of cervical fracture-dislocation in patients with ankylosing spondylitis. *Chin J Traumatol*. (2009) 12(3):148–52.

21. Tecle NE E, Abode-Iyamah KO, Hitchon PW, Dahdaleh NS. Management of spinal fractures in patients with ankylosing spondylitis. *Clin Neurol Neurosurg*. (2015) 139:177–82. doi: 10.1016/j.clineuro.2015.10.014

22. Ma J, Wang C, Zhou X, Zhou S, Jia L. Surgical therapy of cervical spine fracture in patients with ankylosing spondylitis. *Medicine*. (2015) 94(44):e1663. doi: 10.1097/MD.0000000000001663

23. Longo UG, Loppini M, Petrillo S, Berton A, Maffulli N, Denaro V. Management of cervical fractures in ankylosing spondylitis: anterior, posterior or combined approach? *Br Med Bull*. (2015) 115(1):57–66. doi: 10.1093/bmb/ldv010

24. Yu ZS, Yue JJ, Wei F, Liu ZJ, Chen ZQ, Dang GT. Treatment of cervical dislocation with locked facets. *Chin Med J*. (2007) 120(3):216–8. doi: 10.1097/00029330-200702010-00008

25. Meena RK, Dhandapani SJSJ. Chance fracture in ankylosing spondylitis—not merely by chance! Danger of injudicious use of skull traction. *J. Spine*. (2015) 15(11):e47–8. doi: 10.1016/j.spinee.2015.06.065

26. Ma F, Kang M, Liao YH, Lee GZ, Tang Q, Tang C, et al. The use of intraoperative traction for achieving reduction of irreducible atlantoaxial dislocation caused by different craniovertebral junction pathologies. *Clin Neurol Neurosurg*. (2018) 175:98–105. doi: 10.1016/j.clineuro.2018.10.016

27. Yang H, Wang H, Zhang B, Sun Y, Wang L, Lu X. Cervical spine fracture-dislocation in patients with ankylosing spondylitis and severe thoracic kyphosis: application of halo vest before and during surgical management. *Clin Neurol Neurosurg*. (2021) 207:106744. doi: 10.1016/j.clineuro.2021.106744

28. Lee D, Adeoye AL, Dahdaleh NS. Indications and complications of crown halo vest placement: a review. *J Clin Neurosci*. (2017) 40:27–33. doi: 10.1016/j.jocn.2017.01.002

29. Glaser JA, Whitehill R, Stamp WG, Jane JA. Complications associated with the halo-vest. A review of 245 cases. *J Neurosurg*. (1986) 65(6):762–9. doi: 10.3171/jns.1986.65.6.0762

30. Kamal Y, Ortho MS, Khan HA, Gani N, Haq AU, Gul S, et al. Atlas and axis injuries role of Halovest. *Int J Health Sci*. (2014) 8(4):335–45.

31. Alaranta H, Luoto S, Konttinen YT. Traumatic spinal cord injury as a complication to ankylosing spondylitis. An extended report. *Clin Exp Rheumatol*. (2002) 20(1):66–8.

32. Caron T, Bransford R, Nguyen Q, Agel J, Chapman J, Bellabarba C. Spine fractures in patients with ankylosing spinal disorders. *Spine*. (2010) 35(11):E458–64. doi: 10.1097/BRS.0b013e3181cc764f

33. Hartmann S, Tschugg A, Wipplinger C, Thome C. Analysis of the literature on cervical spine fractures in ankylosing spinal disorders. *Global Spine J*. (2017) 7(5):469–81. doi: 10.1177/2192568217700108

34. Britto NMF, Renor BS, Ghizoni E, Tedeschi H, Joaquim AF. Spine surgery in patients with ankylosing spondylitis. *Rev Assoc Med Bras (1992)*. (2018) 64(4):379–83. doi: 10.1590/1806-9282.64.04.379

frontiers | Frontiers in Surgery

TYPE Original Research
PUBLISHED 14 July 2023
DOI 10.3389/fsurg.2023.1113577

Check for updates

OPEN ACCESS

EDITED BY
Paphon Sa-Ngasoongsong,
Mahidol University, Thailand

REVIEWED BY
Yang Wang,
University of Maryland, United States
Xisheng Weng,
Peking Union Medical College Hospital (CAMS), China

*CORRESPONDENCE
Li Lingli
lilingli2000@126.com

RECEIVED 01 December 2022
ACCEPTED 14 June 2023
PUBLISHED 14 July 2023

CITATION
Jing W, Chunlin Z, Xue Y, Tingting H, Linyan Y, Xiao C and Lingli L (2023) A randomized controlled study of a psycho-behavioral intervention combined with a non-benzodiazepine to improve perioperative sleep quality in patients undergoing knee arthroplasty.
Front. Surg. 10:1113577.
doi: 10.3389/fsurg.2023.1113577

COPYRIGHT
© 2023 Jing, Chunlin, Xue, Tingting, Linyan, Xiao and Lingli. This is an open-access article distributed under the terms of the Creative Commons Attribution License (CC BY). The use, distribution or reproduction in other forums is permitted, provided the original author(s) and the copyright owner(s) are credited and that the original publication in this journal is cited, in accordance with accepted academic practice. No use, distribution or reproduction is permitted which does not comply with these terms.

A randomized controlled study of a psycho-behavioral intervention combined with a non-benzodiazepine to improve perioperative sleep quality in patients undergoing knee arthroplasty

Wang Jing, Zhao Chunlin, Yang Xue, He Tingting, Yuan Linyan, Chen Xiao and Li Lingli*

West China Hospital, Sichuan University/West China School of Nursing, Sichuan University, Chengdu, China

Objective: To clarify the effectiveness and safety of psycho-behavioral intervention combined with a non-benzodiazepine to improve perioperative sleep quality in patients undergoing knee arthroplasty, and also to explore the optimal dosage of non-benzodiazepine (oral zolpidem tartrate) to form a standardized sleep quality management process to promote accelerated recovery of patients.
Methods: 240 patients undergoing initial unilateral total knee arthroplasty between January and December 2016 were prospectively included and randomly divided into blank control group (group A), psycho-behavioral intervention group (group B), zolpidem tartrate 10 mg group (group C), and psycho-behavioral intervention + zolpidem tartrate 5 mg group (group D). Sleep, pain, psychological, and knee function scores were compared.
Results: There were significant differences between the four groups with respect to Pittsburgh sleep quality index scores, sleep efficiency, Epworth Sleepiness Scale scores, inflammatory indices, pain, and enhanced recovery after surgery indices during hospitalization ($P < 0.05$).
Conclusion: Psychological behavioral intervention combined with non-benzodiazepine can improve the perioperative quality of sleep. Compared with drug intervention alone, it reduces the dosage of non-benzodiazepine, alleviates anxiety, improves patient satisfaction, and enhances the quality of life.

KEYWORDS

psycho-behavioral interventions, zolpidem tartrate, knee arthroplasty, sleep quality, randomized controlled trial

1. Introduction

With the modernization of society, widespread use of modern transportation, and the global trend of population aging, the incidence of joint injuries and orthopedic trauma has shown a progressive increase worldwide (1–3). The number of patients undergoing hip and knee replacement surgery worldwide exceeds one million annually, and the number is increasing every year placing a heavy burden on health care systems (4). The

development of Enhanced Recovery After Surgery (ERAS) has brought a solution to this challenge. Due to the traumatic nature of orthopedic surgery, forced postoperative positions, and significant pain, perioperative sleep quality issues are a key impediment to the patients' accelerated recovery after surgery, with a prevalence of up to 50% (5). Poor sleep quality affects immunity, increases infection rates, causes poor hospital experience, delays rehabilitation function, prolongs hospital stay, and increases hospital costs (6). Therefore, in-depth characterization of the perioperative sleep quality problems and its determinants in patients undergoing hip/knee replacement patients, and exploration of effective interventions to promote accelerated recovery of patients are key imperatives. The purpose of this study was to determine the efficacy and safety of psycho-behavioral interventions administered in combination with a non-benzodiazepine in improving perioperative sleep quality in patients undergoing knee replacement. We explored the effects of different intervention programs on sleep, inflammatory indices, and pain scores in patients undergoing knee replacement and explored the relationship between sleep, pain, and accelerated rehabilitation. Our findings may help inform a standardized protocol for sleep quality management and promote accelerated rehabilitation of patients.

2. Objects and methods

2.1. Study objects

2.1.1. Sample size calculation

The sample size was estimated using the following formula:

$$N = (1 + 1/k)(u_\alpha/2 + u_\beta)^2\sigma^2/\delta^2$$

$\alpha = 0.05$, $\beta = 0.10$, $\delta = 1.4$, $\sigma = 2.5$ were obtained by referring to the literature. $u_{\alpha/2}$ and u_β are the u values of the first-class error and the second-class error probability, respectively (1.96 and 1.28, respectively). Based on the formula, a sample size of 45 was required for each group. Factoring a drop-out rate of 20%, the number was 54 cases, which was rounded to 60 cases in each group. Finally, 240 patients who were admitted in the orthopedic joint ward of a tertiary care hospital for undergoing unilateral knee arthroplasty between January and December 2016 were included. Inclusion criteria: (1) patients aged ≥18 years undergoing first unilateral knee arthroplasty; (2) written informed consent obtained from patients/families; (4) Pittsburgh sleep quality index (PSQI) ≤7 at admission. Exclusion criteria: (1) patients who were unwilling to cooperate; (2) patients with severe anxiety at admission. Subjects who had a change in condition and could not continue to participate in the trial were also excluded.

2.2. Groups

A randomized single-blind control method was used, with blinding of the patient. Patients were divided into 4 groups using a computer-generated random number sequence. Blank control group (group A): only the routine process of accelerated rehabilitation in the perioperative period of total knee arthroplasty was performed according to the routine process; psycho-behavioral intervention group (group B): centrally arranged to Ward B nursing group, using psycho-behavioral intervention of sleep education and relaxation therapy. Psycho-behavioral interventions were implemented by trained charge nurses on patients three times a day at 10:00, 16:00 and 21:00 for 20 min each time; Zolpidem Tartrate 10 mg group (group C): Zolpidem tartrate tablet 10 mg was administered 30 min before bedtime every night; psycho-behavioral intervention + zolpidem tartrate 5 mg group (Group D): centrally arranged to Ward D care group. Psycho-behavioral intervention was started on the day of admission by a uniformly trained charge nurse, three times a day for 20 min each time. 5 mg of Synthroid was administered from 2 d before to 5 d after surgery at 30 min before bedtime under the guidance of the charge nurse. Patients were randomly grouped upon admission and assigned to 4 different wards without seeing each other to avoid contamination.

2.3. Conventional treatment and care

All patients were operated by the same surgical team using the same perioperative procedure (6–8 h preoperative fasting, 2 h abstinence from drinking, combined intravenous inhalation anesthesia, and postoperative routine administration of cefuroxime 1,500 mg 2 times/day intravenously). If patients showed signs of infection such as pulmonary infection and incisional cellulitis, the antibiotic was changed to levofloxacin hydrochloride injection 500 mg 1 time/day intravenously. All patients were given peri-incisional ice for 24 h upon return to the ward and a sequential intravenous drip of tranexamic acid 1 g three hours after surgery. If plasma drainage is placed, the drainage tube should be removed as soon as the bleeding tends to stop (no obvious bleeding in the drainage tube or serum in the drainage tube). The drainage tube can be removed on the day of surgery or on the first postoperative day, and the drainage volume should be recorded. Analgesic medications were applied using a three-tiered principle, with primary medications started 3 d before surgery and continued postoperatively; secondary and tertiary analgesics were used as needed. Patients were instructed to passively extend and flex the knee in bed on the day of surgery for functional exercise and walk without limp using a walker. The environment in the ward was maintained quiet, with the lights dimmed at lunchtime and night, and focus on treatment and early extubation.

2.4. Data collection and observation indicators

1.4.1 Baseline information The table includes basic information such as age, gender, height, weight, operation time, anesthesia classification, number of rooms, operation site, diagnosis, and comorbidities. It was collected after the study subjects signed the informed consent form, and the information was mainly obtained from the medical records, nursing records and the study subjects themselves, and recorded by the uniformly trained data collectors.

1.4.2 Sleep quality evaluation index PSQI scale (Pittsburgh Sleep Quality Index) was investigated and assessed by the data collector at 15:00 on the day of patient admission and 9:00 on the day of discharge. Sleep efficiency was assessed by the data collector who instructed the patients to wear sleep monitors and exported the data at 9:00 every day to record the patients' sleep efficiency 1 d before and 1 d, 3 d and 5 d after surgery.ESS (Epworth sleep scale) scale was investigated and assessed by the data collector at 15:00 before and 1 d, 3 d and 5 d after surgery.

1.4.3 Hematological indexes were ordered by the supervising physician, and the responsible nurse drew blood on an empty stomach before and 1 d, 3 d, and 5 d after surgery in the morning and sent it immediately for testing ESR (Erythrocyte Sedimentation Rate), CRP (C-reaction protein), and IL-6 (Interleukin-6). The data collector uniformly extracts the data from the test report.

1.4.4 VAS pain scores (Visual Analogue Scale) were collected by the data collector at 15:00 each day before and 1 d, 3 d, and 5 d after surgery for walking, resting, and knee flexion, and at 20:30 for nighttime VAS scores.

1.4.5 Knee circumference The circumference of the affected knee was measured with a soft ruler at the midpoint line of the patella. The measurements were collected by the data collector with a soft ruler before and 1 d, 3 d and 5 d after surgery starting at 15:00.

1.4.6 GAD-7 score (Generalized Anxiety Disorder-7) The GAD-7 score was assessed by the data collector at 15:00 on the day of admission and at 9:00 on the day of discharge.

1.4.7 Patient satisfaction scores were collected by the data collector at 15:00 on 1 d, 3 d, and 5 d postoperatively.

1.4.8 Knee mobility, AKS score (the American Knee Society) The normal knee joint is generally flexed at 0–130°. The AKS score of the knee contains two parts: the clinical score of the knee and the functional score. The clinical score includes pain, mobility and stability; the functional score includes evaluation of walking ability and the ability to walk up and down stairs. It was completed by the data collector at 15:00 on the day of admission, and the knee mobility was retested at 15:00 from 1 d, 3 d and 5 d after surgery, and the AKS score was retested in the outpatient clinic at 3 w after discharge.

1.4.9 Quality of life SF-12 score (the 12-Item Short Form Health Survey) Completed by the data collector at 15:00 on the day of admission and retested at the outpatient clinic 3 w after discharge.

1.4.10 Perioperative Adverse Reactions A dedicated data collector will collect and record the patient's possible perioperative adverse reactions while measuring the data: difficulty concentrating, exhaustion, memory difficulties, dry mouth, sweating, headache, diarrhea, gastrointestinal reactions, rebound insomnia, early awakening, hangover effects, etc.

2.5. Statistical methods

SPSS 21.0 software was used for data analysis. Data are presented as mean ± standard deviation or as frequency (percentage). Between-group differences were assessed using the chi-squared, rank sum test, ANOVA or two independent samples t test.

2.6. Quality control

Strict inclusion and exclusion criteria were used to select the study subjects. Patients were divided into four different ward care groups to avoid cross-contamination. All relevant personnel underwent standardized training and the operations were consistent as much as possible, except for the interventions, to reduce confounding bias. The same calibrated measuring instruments were used throughout the trial to avoid operational interference as much as possible and to reduce bias due to confounding factors.

3. Results

3.1. Baseline information

A total of 247 patients qualified the inclusion and exclusion criteria and were enrolled; of these, 5 patients were lost to follow-up and 2 patients had missing data. Therefore, 240 patients completed the trial in the end. The baseline indicators of the study population are shown in Table 1. There were no significant differences between the four groups with respect to age, sex, height, weight, body mass index (BMI), or time to surgery at baseline ($P > 0.05$).

3.2. Sleep

The percentage of patients with sleep quality PSQI scores >7 during hospitalization was 58.33%, 31.67%, 18.33%, and 11.67% ($P < 0.05$). Sleep efficiency and ESS scores at 1 d, 3 d, and 5 d postoperatively were better in groups B, C, and D than in the blank control group; groups C and D were significantly better than groups A and B ($P < 0.05$). Sleep efficiency at 1 d postoperatively was the lowest and ESS score was the highest (Table 2).

3.3. Inflammatory indicators and pain scores

3.3.1. Inflammatory indicators: ESR, CRP and IL-6

There were significant differences between the four groups with respect to the ESR, CRP, and IL-6 levels at 1 d, 3 d and 5 d

TABLE 1 Comparison of baseline information.

Type	A	B	C	D	*P*-value
Number of cases	60	60	60	60	
Age	68.08 ± 9.4	66.31 ± 8.3	64.9 ± 7.3	65.3 ± 7.3	0.15
Sex					0.93
Male	23	26	25	23	
Women	37	34	35	37	
BMI	25.50 ± 3.80	26.00 ± 3.70	26.50 ± 3.50	25.90 ± 3.80	0.54
Surgery time	61.15 ± 6.40	63.36 ± 5.90	62.50 ± 6.30	61.40 ± 7.10	0.27
Anesthesia grading	2.12 ± 0.58	2.25 ± 0.65	2.15 ± 0.60	2.30 ± 0.50	0.34
Patients in the ward					0.27
Single room	1	2	2	3	
Double room	7	8	6	9	
Six-person room	22	24	28	24	
Seven-person room	30	26	24	24	
Operation site					0.77
Right knee	33	28	32	33	
Left knee	27	32	28	27	
Diagnosis					0.88
Osteoarthritis	46	51	46	49	
Endorheumatoid arthritis	11	8	12	9	
Other	3	1	2	2	
Complication (medicine)					0.94
Hypertensive	5	2	5	5	
Diabetes	2	3	2	2	
Osteoporosis	4	2	2	4	
Chronic obstructive pulmonary disease	3	4	4	3	
Other	1	3	1	1	

postoperatively, respectively ($P < 0.05$). Groups B, C, and D were superior to the blank control group, and groups C and D were superior to groups A and B. The differences were statistically significant ($P < 0.05$) (Table 3).

3.3.2. Pain scores: walking, resting, nocturnal, flexed knee VAS scores

Patients in the four groups showed significant differences ($P < 0.05$) with respect to postoperative walking, resting, nocturnal, and hip flexion VAS pain scores at 1 d, 3 d, and 5 d. Patients in groups B, C, and D had significantly lower walking and resting pain than the blank control group, and groups C and D were superior to group B. The results were statistically significant ($P < 0.05$). Nocturnal, flexion pain was significantly lower in patients in groups B, C, and D than in the blank control group ($P < 0.05$). Pain scores were highest at 1 d postoperatively and gradually decreased thereafter (Table 4).

TABLE 2 Comparison of sleep efficiency (%) and ESS score results.

Categories	PRE-OP	POD1	POD3	POD5
Sleep efficiency				
A	80.89 ± 3.96	52.86 ± 7.28	64.79 ± 7.07	71.46 ± 5.12
B	81.01 ± 3.56	56.53 ± 6.40	68.66 ± 6.85	75.67 ± 4.55
C	80.48 ± 3.20	61.33 ± 6.40	72.96 ± 6.85	79.77 ± 4.55
D	81.04 ± 2.66	62.47 ± 5.28	74.07 ± 5.17	80.68 ± 3.93
P	0.7904	**<0.05**	**<0.05**	**<0.05**
ESS				
A	4.40 ± 0.89	8.20 ± 1.12	6.80 ± 1.05	5.73 ± 1.30
B	4.47 ± 0.72	7.20 ± 1.12	5.90 ± 1.05	4.83 ± 1.26
C	4.53 ± 0.89	6.00 ± 1.12	4.90 ± 1.05	4.53 ± 1.26
D	4.67 ± 0.88	5.84 ± 1.04	4.85 ± 1.03	4.27 ± 1.18
P	0.3573	**<0.0001**	**<0.0001**	**<0.0001**

The bold values represent the statistically significant difference in P-values (i.e., $p \leq 0.05$).

TABLE 3 Comparison of inflammatory indicators.

Categories	PRE-OP	POD1	POD3	POD5
ESR				
A	26.53 ± 7.97	35.53 ± 6.96	58.00 ± 8.28	55.33 ± 9.59
B	25.53 ± 8.83	29.33 ± 10.25	53.43 ± 7.30	48.57 ± 9.21
C	25.4 ± 7.77	25.93 ± 7.62	49.07 ± 8.48	42.07 ± 7.07
D	25 ± 7.96	25.23 ± 8.47	47.25 ± 9.64	40.8 ± 8.30
P	>0.05	**<0.0001**	**<0.0001**	**<0.0001**
CRP				
A	3.69 ± 2.76	53.26 ± 11.82	91.84 ± 11.81	43.78 ± 12.07
B	3.67 ± 2.24	45.80 ± 13.61	80.49 ± 13.63	33.49 ± 8.03
C	3.63 ± 2.68	34.98 ± 8.25	75.46 ± 11.83	30.85 ± 8.30
D	3.51 ± 1.79	33.43 ± 8.83	73.69 ± 13.11	28.16 ± 12.17
P	0.9767	**<0.0001**	**<0.0001**	**<0.0001**
IL-6				
A	3.38 ± 1.48	96.44 ± 21.25	37.75 ± 12.03	21.24 ± 8.12
B	3.40 ± 1.29	78.76 ± 10.84	26.45 ± 9.53	13.83 ± 3.77
C	3.50 ± 1.39	70.02 ± 10.56	23.11 ± 5.66	9.57 ± 4.09
D	3.50 ± 1.39	71.49 ± 8.79	23.25 ± 7.22	9.83 ± 3.40
P	0.9404	**<0.0001**	**<0.0001**	**<0.0001**

The bold values represent the statistically significant difference in P-values (i.e., $p \leq 0.05$).

TABLE 4 Comparison of VAS scores.

Categories	Point in time	Score				*P*-value
		Group A	Group B	Group C	Group D	
Walking pain	PRE-OP	55.53 ± 16.94	55.00 ± 13.61	54.60 ± 13.46	54.53 ± 13.43	0.9803
	POD1	65.27 ± 10.62	58.07 ± 13.74	50.47 ± 11.28	50.60 ± 9.72	**<0.0001**
	POD3	47.40 ± 9.69	42.53 ± 9.45	37.53 ± 9.45	37.73 ± 7.48	**<0.0001**
	POD5	33.27 ± 6.56	28.33 ± 6.92	24.33 ± 6.92	24.47 ± 5.75	**<0.0001**
Resting pain	PRE-OP	34.07 ± 7.21	35.13 ± 6.93	35.27 ± 7.13	35.40 ± 7.09	0.722
	POD1	41.60 ± 2.35	35.47 ± 4.95	31.00 ± 4.60	28.00 ± 4.60	**<0.0001**
	POD3	28.73 ± 3.97	24.87 ± 5.51	21.33 ± 5.34	21.25 ± 5.49	**<0.0001**
	POD5	23.53 ± 3.41	22.73 ± 6.30	19.73 ± 6.30	18.73 ± 5.91	**<0.0001**
Nocturnal pain	PRE-OP	42.27 ± 11.64	41.93 ± 8.77	41.63 ± 8.88	41.30 ± 8.38	Total *P*
	POD1	57.33 ± 13.00	52.27 ± 14.42	49.53 ± 14.72	48.27 ± 15.07	**0.0032**
	POD3	38.80 ± 10.23	32.87 ± 8.89	29.60 ± 8.67	28.73 ± 8.50	**<0.0001**
	POD5	29.73 ± 5.29	22.67 ± 6.39	19.27 ± 6.17	18.53 ± 5.55	**<0.0001**
Painful flexion of the knee	PRE-OP	61.13 ± 15.97	60.20 ± 13.53	60.00 ± 12.18	60.27 ± 11.54	0.9687
	POD1	72.40 ± 9.13	65.20 ± 12.12	62.20 ± 12.12	61.93 ± 11.92	**<0.0001**
	POD3	49.47 ± 11.60	42.67 ± 10.07	39.20 ± 9.89	38.93 ± 9.62	**<0.0001**
	POD5	35.87 ± 7.96	30.40 ± 8.28	26.93 ± 8.08	25.60 ± 7.06	**<0.0001**

The bold values represent the statistically significant difference in P-values (i.e., $p \leq 0.05$).

3.4. ERAS indicators

3.4.1. Knee joint circumference

The circumference of the knee joint in the four groups was not significantly different ($P > 0.05$) at 1 d and 5 d postoperatively. At 3 d postoperatively, the mean knee joint circumference in groups B, C, and D were significantly lower than that in the blank control group ($P < 0.05$).

3.4.2. Knee mobility and AKS scores

The degree of motion of knees on the first postoperative day in group C and D was significantly superior to that in the blank control group ($P < 0.05$); at 3 d postoperatively, patients in groups B, C and D were significantly better than the blank control group in this respect ($P < 0.05$); at 5 d postoperatively, patients in groups C and D were significantly better than those in groups A and B in this respect ($P < 0.05$). With respect to knee AKS clinical and functional scores at 3 weeks follow-up, patients in groups B, C, and D were better than the blank control group, and patients in groups C and D were significantly better than patients in groups A and B ($P < 0.05$) (Table 5).

TABLE 5 Comparison of the AKS.

Categories	Preclinical		Functionalities	
	Pre-operative	3 weeks after surgery	Pre-operative	3 weeks after surgery
A	43.67 ± 10.90	75.87 ± 6.72	41.33 ± 12.27	68.00 ± 8.08
B	44.13 ± 11.82	78.33 ± 3.41	41.00 ± 10.32	74.80 ± 7.47
C	43.80 ± 11.85	82.33 ± 3.41	41.13 ± 7.30	78.80 ± 7.47
D	43.60 ± 10.85	82.73 ± 3.41	41.20 ± 6.51	78.40 ± 7.61
P	0.9943	**<0.0001**	0.9979	**<0.0001**

The bold values represent the statistically significant difference in P-values (i.e., $p \leq 0.05$).

3.4.3. Generalized anxiety scale (GAD-7) scores

Gad-7 scores at discharge in groups B, C, and D were significantly lower than those in the blank control group ($P < 0.05$). Groups C and D were significantly superior to groups A and B ($P < 0.05$), while there was no significant difference ($P > 0.05$) between groups C and D in this respect.

3.4.4. Satisfaction scores

In groups B, C, and D, the satisfaction scores at 1 d, 3 d, and 5 d postoperatively were significantly higher than that in the blank control group ($P < 0.05$). Group D had the highest scores, which were significantly different from those in group B ($P < 0.05$) but not significantly different compared with group C ($P > 0.05$).

3.4.5. Quality of life SF-12 scores

The mean postoperative 3 W physical function, somatic pain, mental health, energy and social function scores in groups B, C, and D were significantly higher than that in the blank control group ($P < 0.05$); patients in group D had higher scores than in group C, but the differences were not statistically significant ($P > 0.05$). Postoperative 3 W physical function, overall health score comparison was not statistically significant ($P > 0.05$), emotional function in group D was significantly higher than that in groups A and B ($P < 0.05$).

3.5. Length of stay, hospital costs and perioperative adverse effects

The length of stay and cost of hospitalization in groups B, C, and D were significantly lesser than that in the blank control group ($P < 0.05$); there were no significant differences among the three intervention groups in this respect ($P > 0.05$). There were no significant differences among the four groups in terms of adverse

effects such as dizziness or headache ($P > 0.05$). However, the incidence of rebound insomnia and hangover effects were significantly higher in group C than in the other three groups ($P < 0.05$); early awakening was significantly more frequent in groups A and B than in groups C and D, and the difference between the four groups was statistically significant ($P < 0.05$) (Table 6).

4. Discussion

4.1. Problems with sleep quality in knee arthroplasty

Total knee arthroplasty (TKA) is the primary treatment option for advanced degenerative knee disease or rheumatoid arthritis for the relief of knee pain and improvement of joint deformity and to improve the quality of life of patients (5). Fear of complications associated with TKA and the ambivalence of desperately wanting surgery to improve quality of life can cause preoperative anxiety, which can affect the quality of preoperative sleep of patients. At the same time, TKA is a very traumatic procedure, causing increased pain at night and affecting the quality of sleep (7). In this study, we found that patients generally had poor postoperative sleep, with a 53.3% incidence of sleep disturbance in the blank control group. This is largely consistent with the results of a previous study [5]. The study showed that TKA patients were in a state of high psychological stress and sympathetic excitement after surgery. The consequent elevated concentration of catecholamines in the blood leaves patients in an excited and irritable state, which along with nocturnal knee pain, greatly affects the quality of perioperative sleep after TKA.

4.2. Relationship between sleep quality and pain and recovery in knee arthroplasty

Studies have shown a positive correlation between pain and blood levels of inflammatory markers (ESR, CRP, IL-6). Elevated inflammatory factors cause severe postoperative nocturnal pain in patients and greatly affect the quality of postoperative sleep after major orthopedic surgery (7). Postoperative pain necessitates increase in the dosage of NSAIDs and opioids. Since opioids affect the activity of opioid receptors through the same binding sites as endogenous opioid peptides, the consequent increase in opioid concentrations in the patient's blood, and decrease in endogenous enkephalin production, significantly reduces rapid eye movement sleep (REM), increasing the number of awakenings during sleep, decreasing sleep efficiency, and prolonging REM latency (8–11).

TABLE 6 Comparison of perioperative adverse outcomes .

Indicators	A	B	C	D	*P*
Dry mouth	11	10	8	6	0.578
Sweating	5	3	2	2	0.551
Dizzy	9	5	4	3	0.228
Headache	5	3	2	2	0.551
Diarrhea	1	0	1	0	0.569
Gastrointestinal reactions	6	4	2	1	0.161
Bounce-back insomnia	0	0	8	2	**<0.001**
Sleepiness	0	0	1	0	0.390
Wake up early.	35	20	9	5	**<0.001**
Hangover effect	0	0	6	1	**0.002**

The bold values represent the statistically significant difference in P-values (i.e., $p \leq 0.05$).

Under accelerated rehabilitation hip and knee arthroplasty management, a full range of multimodal analgesic protocols are often required for perioperative patients. Prior to TKA, an over-the-top analgesia program was adopted to reduce perioperative pain. In a study by Mammoto et al., 120 knee arthroplasty patients were prospectively randomized into two groups (test group: celecoxib analgesia; control group: placebo); the results showed that effective postoperative analgesia reduces pain, improves sleep quality, and promotes accelerated recovery (12). In a domestic study, 86 patients with knee joint replacement were randomly divided into two groups (test group: full pain care; control group: conventional analgesia). The results showed that effective preoperative nursing guidance and regular analgesic treatment can effectively reduce postoperative pain, improve sleep quality, and promote accelerated recovery of postoperative joint function. Pain affects sleep, and poor sleep quality in turn affects pain. Both these factors affect early functional exercises and generate anxiety; anxiety in turn affects sleep, and the three factors form a vicious circle (13, 14). Improving perioperative sleep quality can increase the threshold of pain response and reduce daytime fatigue, improve patient satisfaction, and accelerate functional recovery (15, 16).

In the present study, compared with the blank control group, patients in the intervention group (perioperative psycho-behavioral and zolpidem tartrate) showed improved sleep quality in the postoperative period at d1, d3, and d5, and the differences were statistically significant. Among these, the psycho-behavioral intervention + zolpidem tartrate 5 mg group and zolpidem tartrate 10 mg group showed the best results. This may be related to the strong sedative-hypnotic effect of zolpidem tartrate; the mechanism of action is through selective action on γ-aminobutyric acid (GABA) α receptor, after a series of binding and interaction, resulting in opening of chloride channels, causing cell membrane hyperpolarization, and inhibiting neuronal excitation. It does not change the sleep structure, but can prolong the overall sleep time, reduce the time to fall asleep and the number of night awakenings, with no hangover effect on the next day (17). Zolpidem tartrate has several advantages: (1) rebound insomnia is less likely to occur at therapeutic doses; (2) sequential administration of zolpidem with benzodiazepine sleeping pills does not cause rebound; (3) no addictive and withdrawal effects (18). Studies have shown that the perioperative application of oral zolpidem tartrate during joint replacement surgery improves the quality of perioperative sleep, relieves daytime fatigue and drowsiness, accelerates early functional exercise, reduces pain, and promotes early and accelerated recovery (19, 20). Behavioral cognitive therapy showed significant improvement in patients' anxiety and depression indices, and could improve patients' sleep quality (21, 22).

Numerous studies have shown that nighttime sleep deprivation lowers the threshold for walking pain during the day and aggravates pain. Nocturnal pain directly causes sleep disturbance and even sleep deprivation; low-quality sleep in turn increases pain sensitivity, creating a vicious cycle of pain - low quality sleep - aggravated pain - even lower quality sleep, greatly affecting the patient's early rehabilitation exercise (23, 24). In the present study, psycho-behavioral intervention + zolpidem tartrate 5 mg and zolpidem tartrate 10 mg significantly reduced pain in TKA patients at 1st d, 3rd d and 5th d postoperatively during walking, resting, nocturnal and flexed knee states. In a previous study, nocturnal pain was shown to positively correlate with joint swelling and blood concentrations of CRP, ESR, and interleukin 6, which are closely related to local and systemic trauma response after TKA (25). In the present study, blood CRP, ESR, and interleukin 6 levels were not significantly different in the psycho-behavioral intervention + zolpidem tartrate 5 mg and zolpidem tartrate 10 mg groups, but their blood concentrations were greatly reduced compared to the blank control group; in addition, the opioid use was relatively reduced, reducing the effect of opioids on patients' perioperative sleep quality and adjusting the vicious cycle to a virtuous one. The possible mechanisms of action are: psycho-behavioral intervention and zolpidem tartrate can improve the perioperative sleep quality of patients, thus reducing the secretion of inflammatory factors and alleviating the postoperative traumatic inflammatory response; the reduction of inflammatory response can reduce the blood concentration of inflammatory factors in the blood, thus alleviating local and systemic pain, reducing the application of related opioids and realizing the improvement of sleep quality. However, the effect of psycho-behavioral interventions alone is limited; psycho-behavioral interventions + zolpidem tartrate 5 mg can achieve the same effect as zolpidem tartrate 10 mg, reducing the risk of zolpidem tartrate-related complications. Improving sleep quality in TKA patients by means of physical and pharmacological interventions can effectively reduce the inflammatory response, enhance the degree of pain tolerance, reduce the amount of application of sleep-influencing analgesic drugs (opioids), and pain relief in turn improves sleep quality, turning a vicious cycle into a virtuous one and promoting accelerated recovery (26, 27).

4.3. Relationship between postoperative sleep quality and postoperative functional recovery, improved quality of life, reduced anxiety and increased satisfaction

Low-quality nocturnal sleep due to postoperative environmental changes and pain results in daytime drowsiness and fatigue, which affects the patient's ability to mobilize early on (28). Robert et al. prospectively included 68 patients who underwent arthroscopic surgery to study the relationship between sleep quality and pain, fatigue index, and analgesic medication dosage. They found that postoperative sleep quality and fatigue index were important factors affecting postoperative pain and early recovery, and that low-quality sleep increased daytime fatigue (29, 30). In this study, postoperative knee mobility of patients in groups C and D was significantly greater than that in the other two groups. This may be related to the fact that combination of pharmacological plus non-pharmacological interventions can significantly improve the quality of perioperative sleep, reducing the patients' daytime sleepiness index. Thus they have more time and energy to perform flexion and extension functional exercises in bed or get out of bed early for walking functional exercises, and increase the confidence in postoperative rehabilitation (25). In this study, the satisfaction of patients in groups C and D was also significantly higher than that in the other two groups at 1 d, 3 d, and 5 d postoperatively; this was inextricably linked to good perioperative functional exercises, early time to get out of bed, and a good sense of experience (26).

A range of factors such as pre-operative concerns about the risks of surgery and anesthesia, unfamiliar surroundings and adaptation to the ward, the extent of post-operative rehabilitation exercises and the speed of recovery induce pre- and post-operative anxiety in patients. Studies have shown that anxiety and pain are independent risk factors for the quality of patients' postoperative sleep; low-quality sleep in turn increases the level of postoperative anxiety and depression. In this study, we also found that both zolpidem tartrate and psycho-behavioral interventions significantly improved patients' anxiety and depression during hospitalization, with zolpidem tartrate 5 mg + psycho-behavioral intervention showing comparable effect as zolpidem tartrate10 mg. This may be related to good perioperative functional exercise, high satisfaction and mild pain levels in patients, leading to early and accelerated recovery, and eliminating some of the factors that contribute to postoperative anxiety.

This study confirmed that psycho-behavioral intervention, psycho-behavioral intervention + oral zolpidem tartrate 5 mg and oral zolpidem tartrate 10 mg can improve the sleep quality-related problems, relieve postoperative pain, inflammatory response, and anxiety, improve patient satisfaction, promote functional recovery, and improve the quality of life of patients undergoing knee replacement surgery. The length of hospital stay and hospitalization cost of the psychopharmacology intervention + zolpidem tartrate 5 mg group were similar to those of the zolpidem tartrate 10 mg group. However, the former group had a lower incidence of perioperative adverse reactions and less severe anxiety; therefore, it was safer and more effective for patients undergoing knee replacement and accelerated recovery. Thus, we recommend psychopharmacology intervention in combination with zolpidem tartrate 5 mg as the optimal intervention for these patients.

Data availability statement

The original contributions presented in the study are included in the article, further inquiries can be directed to the corresponding author.

Ethics statement

The studies involving human participants were reviewed and approved by Ethics approval was granted by the West China School of Medicine, Si Chuan University (2016 (202)). Written informed consent was obtained at baseline from the participant. The patients/participants provided their written informed consent to participate in this study.

Author contributions

WJ and YX: wrote protocol. ZC, HT, LL and YL: data entry, checking, analysis, commented on and revised the manuscript draft for critical content, and approved the final version. LL: statistical guidance. WJ and LL: interpretation of statistical findings. WJ: wrote first draft of manuscript. All authors contributed to the article and approved the submitted version.

Funding

The Key Science and Technology R&D Project of Sichuan Province (No2020YFS0153) among the fund projects was corrected as the Natural Science Foundation of Sichuan Province (No.2023NSFSC0541).

Acknowledgment

All the researchers express their gratitude to the medical staff of Sichuan University Orthopedics and all the patients who participated in the study.

Conflict of interest

The authors declare that the research was conducted in the absence of any commercial or financial relationships that could be construed as a potential conflict of interest.

Publisher's note

All claims expressed in this article are solely those of the authors and do not necessarily represent those of their affiliated organizations, or those of the publisher, the editors and the reviewers. Any product that may be evaluated in this article, or claim that may be made by its manufacturer, is not guaranteed or endorsed by the publisher.

References

1. Schwartz AM, Farley KX, Guild GN, Bradbury TL Jr. Projections and epidemiology of revision hip and knee arthroplasty in the United States to 2030. *J Arthroplasty*. (2020) 35(6s):s79–85. doi: 10.1016/j.arth.2020.02.030

2. Ackerman IN, Bohensky MA, Zomer E, Tacey M, Gorelik A, Brand CA, et al. The projected burden of primary total knee and hip replacement for osteoarthritis in Australia to the year 2030. *BMC Musculoskelet Disord*. (2019) 20(1):90. doi: 10.1186/s12891-019-2411-9

3. Sloan M, Premkumar A, Sheth NP. Projected volume of primary total joint arthroplasty in the U.S., 2014–2030. *J Bone Joint Surg Am*. (2018) 100(17):1455–60. doi: 10.2106/JBJS.17.01617

4. Wang SJ, Zhang SL. Current status and hot spots of artificial hip arthroplasty. *Chinese J Joint Surg*. (2015) 9(06):718–24. doi: 10.3877/cma.j.issn.1674-134X.2015.06.007

5. Fatah RMN, Abdulrahman BB. A sleep disturbance after total knee arthroplasty. *J Family Med Prim Care*. (2020) 9(1):119–24. doi: 10.4103/jfmpc.jfmpc_595_19

6. Chenhui W, Jinli G, Hong C, Cuiping W, Shi J, Jiahui L. Analysis of perioperative sleep quality and factors influencing different categories of orthopaedic surgery patients. *J Nurs Res*. (2020) 34(12):2120–5. doi: 10.12102/j.issn.1009-6493.2020.12.012

7. Hu R, Wang WH, He CY, Liu YH, Xiong Y. Current status of sleep quality and its influencing factors in 104 knee replacement patients. *J Nurs*. (2016) 23(14):12–5. doi: 10.16460/j.issn1008-9969.2016.14.012

8. Zhang S, Kong XP, Chai W. Opioids in total joint arthroplasty: interpretation of the 2020 AAHKS/ASRA/AAOS/THS/TKS clinical practice guidelines. *Chinese J Restorative Reconstr Surg*. (2020) 1–7.

9. Gruen ME, Samson DR, Lascelles BDX. Functional linear modeling of activity data shows analgesic-mediated improved sleep in dogs with spontaneous osteoarthritis pain. *Sci Rep*. (2019) 9(1):14192. doi: 10.1038/s41598-019-50623-0

10. Wang YX, Mao XF, Li TF, Gong N, Zhang MZ. Dezocine exhibits antihypersensitivity activities in neuropathy through spinal μ-opioid receptor activation and norepinephrine reuptake inhibition. *Sci Rep*. (2017) 7:43137. doi: 10.1038/srep43137

11. Ghomrawi HM, Mancuso CA, Westrich GH, Marx RG, Mushlin AI; Expectations Discordance Study Group. Discordance in TKA expectations between patients and surgeons. *J Clinical Orthop Related Res*. (2013) 471(1):175–80. doi: 10.1007/s11999-012-2484-3

12. Zhan YJ, Li JX, Jin TL, Zhu H. Effect of pain management on sleep quality in patients with total knee arthroplasty. *J Nurs Res*. (2012) 26(29):2747–8. doi: 10.3969/j.issn.1006-9852.2012.06.015

13. Liu J, Ren YF, Li M, et al. Mechanisms and therapeutic advances of sleep deprivation-induced nociceptive hypersensitivity. *J West China Med*. (2020) 35(03):352–6. doi: 10.7507/1002-0179.201911071

14. Wang L, Wang Y, Pei L. Current status of research on sleep disorders and postoperative pain. *Chinese J Pain Med*. (2012) 18(06):372–4. doi: 10.3969/j.issn.1006-9852.2012.06.015

15. Xiuying B, Xijun X. Observation of the effect of pain care on the improvement of postoperative sleep in patients with knee arthroplasty. *World J Sleep Med*. (2020) 7(03):488–9. doi: 10.3969/j.issn.2095-7130.2020.03.047

16. Tang W, Chen JK, Zhang SJ. Pain care to improve postoperative sleep in knee replacement patients. *World J Sleep Med*. (2021) 8(01):107–8. doi: 10.3969/j.issn.2095-7130.2021.01.043

17. Schroeck JL, Ford J, Conway EL, Kurtzhalts KE, Gee ME, Vollmer KA, et al. Review of safety and efficacy of sleep medicines in older adults. *Clin Ther*. (2016) 37(11):2340–72. doi: 10.1016/j.clinthera.2016.09.010

18. Shen B, Xisheng W, Blade L, Tiebin Q, Xianlong Z, Li C, et al. Accelerated rehabilitation of hip and knee arthroplasty in China - expert consensus on perioperative pain and sleep management. *Chinese J Bone Joint Surg*. (2016) 9(02):91–7.

19. Akbaba YA, Yeldan I, Guney N, Ozdincler AR. Intensive supervision of rehabilitation programme improves balance and functionality in the short term after bilateral total knee arthroplasty. *Knee Surg Sports Traumatol Arthrosc*. (2016) 24(1):26–33. doi: 10.1007/s00167-014-3179-y

20. Dolores Herrero-Sanchez M, del Carmen Garcia-Inigo M, Soledad Nuno-Beato-Redondo B, Fernandez-de-las-Penas C, Alburquerque-Sendin F. Association between ongoing pain intensity, health-related quality of life, disability and quality of sleep in elderly people with total knee arthroplasty. *Cien Saude Colet*. (2014) 19(6):1881–8. doi: 10.1590/1413-81232014196.04632013

21. Ren CH, Xie F, Yu HL, Su WL, Chen LJ, Zhao LB. A meta-analysis of self-help cognitive-behavioral therapy for insomnia:efficacy, influencing factors, and evidence evaluation. *J Adv Psychol Sci*. (2016) 24(02):173–95. doi: 10.3724/SP.J.1042.2016.00173

22. Shao XY, Zhao M, An RL, Guo J, Qu N, Li D. Systematic evaluation and meta-analysis of clinical efficacy of cognitive behavioral therapy for chronic insomnia. *J Clinical Meta-Analysis*. (2019) 34(05):447–54. doi: 10.3969/j.issn.1004-583X.2019.05.014

23. Stocks J, Tang NK, Walsh DA, Warner SC, Harvey HL, Jenkins W, et al. Bidirectional association between disturbed sleep and neuropathic pain symptoms: a prospective cohort study in post-total joint replacement participants. *J Pain Res*. (2018) 11:1087–93. doi: 10.2147/JPR.S149830

24. Roehrs TA, Roth T. Increasing presurgery sleep reduces postsurgery pain and analgesic use following joint replacement: a feasibility study. *Sleep Med*. (2017) 33:109–13. doi: 10.1016/j.sleep.2017.01.012

25. Giordano NA, Kent M, Andersen SG, Scott-Richardson M, Highland KB. Postoperative pain mediates the association between peripheral nerve blocks and postoperative sleep following lower extremity arthroplasty. *Clinical J Pain*. (2021) 37 (7):487–93. doi: 10.1097/AJP.0000000000000942

26. Shakya H, Wang D, Zhou K, Luo ZY, Dahal S, Zhou ZK. Prospective randomized controlled study on improving sleep quality and impact of zolpidem after total hip arthroplasty. *J Orthop Surg Res*. (2019) 14(1):289. doi: 10.1186/s13018-019-1327-2

27. Lerman SF, Finan PH, Smith MT, Haythornthwaite JA. Psychological interventions that target sleep reduce pain catastrophizing in knee osteoarthritis. *Pain*. (2017) 158(11):2189–95. doi: 10.1097/j.pain.0000000000001023

28. Gong L, Wang Z, Fan D. Sleep quality effects recovery after total knee arthroplasty (TKA) - A randomized, double-blind, controlled study. *J Arthroplasty*. (2015) 30(11):1897–901. doi: 10.1016/j.arth.2015.02.020

29. Tashjian RZ, Banerjee R, Bradley MP, Alford W, Fadale PD. Zolpidem reduces postoperative pain, fatigue, and narcotic consumption following knee arthroscopy: a prospective randomized placebo-controlled double-blinded study. *J Knee Surg*. (2006) 19(2):105–11. doi: 10.1055/s-0030-1248088

30. Jove M, Griffin DW, Minkowitz HS, Ben-David B, Evashenk MA, Palmer PP. Sufentanil sublingual tablet system for the management of postoperative pain after knee or hip arthroplasty A randomized, placebo-controlled study. *Anesthesiology*. (2015) 123(2):434–43. doi: 10.1097/ALN.0000000000000746

frontiers | Frontiers in Surgery

TYPE Original Research
PUBLISHED 29 September 2023
DOI 10.3389/fsurg.2023.1134986

Check for updates

OPEN ACCESS

EDITED BY
Elif Nedret Keskinöz,
Acıbadem University, Türkiye

REVIEWED BY
Mazhar Özkan,
Namik Kemal University, Türkiye
Suvranshu Pattanayak,
National Institute of Technology Rourkela, India

*CORRESPONDENCE
Eakkachai Warinsiriruk
✉ eakkachai.war@mahidol.ac.th

RECEIVED 31 December 2022
ACCEPTED 18 September 2023
PUBLISHED 29 September 2023

CITATION
Pengrung N, Sa-ngasoongsong P, Sabsuantang K, Thongchuea N and Warinsiriruk E (2023) Effectiveness of laser welding in cerclage wiring fixation: a biomechanical study.
Front. Surg. 10:1134986.
doi: 10.3389/fsurg.2023.1134986

COPYRIGHT
© 2023 Pengrung, Sa-ngasoongsong, Sabsuantang, Thongchuea and Warinsiriruk. This is an open-access article distributed under the terms of the Creative Commons Attribution License (CC BY). The use, distribution or reproduction in other forums is permitted, provided the original author(s) and the copyright owner(s) are credited and that the original publication in this journal is cited, in accordance with accepted academic practice. No use, distribution or reproduction is permitted which does not comply with these terms.

Effectiveness of laser welding in cerclage wiring fixation: a biomechanical study

Nachapan Pengrung[1], Paphon Sa-ngasoongsong[1], Konlawat Sabsuantang[2], Nutchanat Thongchuea[3] and Eakkachai Warinsiriruk[3]*

[1]Department of Orthopedics, Faculty of Medicine Ramathibodi Hospital, Mahidol University, Bangkok, Thailand, [2]Chakri Naruebodindra Medical Institute (CNMI), Faculty of Medicine Ramathibodi Hospital, Mahidol University, Samut Prakan, Thailand, [3]Department of Industrial Engineering, Faculty of Engineering, Mahidol University, Nakhon Pathom, Thailand

Introduction: Cerclage wiring is a common orthopedic procedure for fracture fixation. However, previous studies reported wiring-related perioperative complications, such as wire loosening or breakage, with an incidence rate of up to 77%. Recently, the use of laser welding on medical implants was introduced to connect biomedical materials. This study used laser technology to weld between wires after conventional cerclage fixation. We hypothesized that the laser welding could significantly increase the biomechanical properties of cerclage wiring fixation.

Materials and methods: Twenty-five wiring models underwent biomechanical tests in five cerclage wiring configurations (five models per group), namely, (1) single loop, (2) single loop with laser welding, (3) double loop, (4) double loop with one-side laser welding, and (5) double loop with two-side laser welding. Characteristics such as load to failure, mode of failure, and wiring failure were compared between groups. The biocompatibility for a 316L stainless steel wire with laser welding was evaluated via an *in vitro* hemolysis test.

Results: Mean load to failure of the double loop with one-side and two-side laser welding groups were 3,596 ± 346 N and 3,667 ± 240 N, which were significantly higher than for the double-loop group (2,919 ± 717 N) ($p = 0.012$ and $p = 0.044$, respectively). Conversely, no significant difference was shown in the comparison of the mean load to failure between the single loop and the single loop with laser-welded cerclage wire (1,251 ± 72 N, 1,352 ± 122 N, and $p = 0.12$). Untwisted wire and wire breakage were the most common mode of failure. All welding specimens revealed non-hemolytic effects from *in vitro* hemolysis test.

Conclusion: Laser welding on cerclage wiring significantly increases the biomechanical property of double cerclage wire fixation. However, further biocompatibility tests and clinical studies are still recommended.

KEYWORDS

laser welding, cerclage wiring fixation, single loop, double loop, tensile testing

1. Introduction

Cerclage wiring fixation is a common orthopedic procedure, which was first proposed over 200 years ago (1), and nowadays remains popular in the fracture fixation procedure such as periprosthetic fracture, femoral fracture, or patellar fracture (2). In general, the cerclage wiring fixation was performed by using the standard stainless steel wire. However, regarding the cerclage materials, these options could be categorized into

metallic materials (as stainless steel wire and cable) and non-metallic materials (as fiber tape and heavy suture). Recent studies showed that the newer cerclage materials have some advantages over the standard stainless steel wire. For example, Förch et al. reported the superior biomechanics of cable cerclage in addition to a plate osteosynthesis of distal tibia fracture (3). Hägerich et al. reported that the non-metallic cerclage provides similar stability to metal cerclage and reduces metallic risk profile (4). Nevertheless, the stainless steel wire remains the most common cerclage material because of surgeon familiarity, cost-effectiveness, and reliable biomechanical property.

Regarding the use of stainless steel wire in cerclage wiring fixation, previous studies also demonstrated many different surgical techniques, such as novel instruments, tightening methods, and wiring configurations that could be used for improving the fixation stability by stainless steel wire (5–9). Schultz et al. reported that two single-loop wires were stronger than a continuous double-loop wire (7). Lenz et al. reported that the double-looped technique provided better fixation stability compared to a single-looped technique (8). Wähnert reported that increasing the wire diameter and cerclage handling techniques—such as twisting under traction, cutting the wire outside the twist, and forward-bending the twist—affected the quality of a cerclage fixation (9). However, postoperative complications with fixation failure caused by wire breakage or loosening still occur in 2%–77% of cases (10). From the literature review, the two most common scenarios of fixation failure are the following: first, overtightened wire twisting creates plastic deformation at the initial turning point of the twisted wire to make the weakest point the cause of wire breakage (9, 10), and, second, inadequately tightened wire twisting causes untwisting or wire loosening (6, 7). Recently, laser welding technology had been used as a biomedical engineering tool due to the ability to join and seal the implanted biomedical materials, such as titanium alloys, cobalt–chromium alloys, stainless steel, and polymer-based materials (11). The laser beam was designed to deliver thermal energy to the focal point of different material surfaces, such as metal, and creating a fusion between them—and therefore—could be used for strengthening, repairing, or refurbishing medical devices and lead to the long-term durability of implants, especially in the dental procedure (11, 12). In 2020, we successfully developed the experimental protocol of using the laser welding for creating the fusion between the stainless steel cerclage wires. To the best of our knowledge, no previous study had investigated the biomechanical property of laser welding for cerclage wiring fixation in orthopedic surgery.

Therefore, this study aims to compare the biomechanical property between cerclage wire fixation with and without laser welding and evaluates the clinical safety with blood for the 316L stainless steel wire with laser welding via an *in vitro* hemolysis test. We hypothesized that laser welding is effective and safe for cerclage wire fixation.

2. Materials and methods

This study has been reviewed and approved by the Institutional Review Board at Mahidol University, based on the Declaration of Helsinki (COA. No. MURA2018/618, Protocol number 08-61-61).

2.1. Specimen preparation

In this study, a synthetic bone [fourth generation (SKU: 3403-31), Sawbones, Vashon, WA, USA] with an external diameter of 40 mm and wall thickness of 8.9 mm was used. Twenty-five bone models were prepared using the same method, each model cut with a length of 30 mm; each model was then horizontally cut in half, as presented in Figure 1.

2.2. Study groups

The 316L stainless steel wire (Synthes GmbH, Solothurn, Switzerland) that consists of 18% Cr, 13% Ni, 2.7% Mo, 1.7% Mn, and 0.3% C (13) with a diameter of 1.5 mm was used for the cerclage wiring techniques. The cerclage wiring was all prepared by one of the authors (NP), an orthopedic trauma expert, for five different cerclage configurations (five groups, Figure 2) with five models per cerclage configuration. In laser welding groups, the process was performed on the laser welding machine AHL-Laser (model XBW-400). The beam source is Nd: YAG (wavelength 1,064 nm). The laser welding parameters were set up using literature references from our previous study (Table 1) (14). Because of the tiny location for welding which limits the transfer of the energy from the laser to the wire in the single-loop group, we set a higher voltage and pulse width to create a higher heat input compared with the double-loop group:

(1) Single loop (Figure 2A).
(2) Single loop with laser welding (Figure 2B). Cerclage wire with one single loop was welded at the innermost turn of the twisted knot. The laser parameter for welding on the single



FIGURE 1
Synthetic bone preparation.



FIGURE 2
Cerclage wiring fixation method.

TABLE 1 Laser parameters for the experiment.

Parameters	Level	
Cerclage wire	Single	Double
Charge voltage (V)	90	80
Pulse width (ms)	2.5	1.5
Multi-frequency (Hz)	6	
Ar gas shielding (L/min)	10	
Defocused length (mm)	56	
Beam diameter (mm)	1.76	
Length of welding (mm)	5	

loop was fixed at a charge voltage of 90 V, a pulse width of 2.5 ms, and a multi-frequency of 6 Hz (Table 1).

(3) Double loop (Figure 2C).

(4) Double loop with laser welding for one side (Figure 2D). Cerclage wire with one double loop was welded on wire to wire with 5 mm length of welding at one side of the twisted knot. The laser parameter for welding a double loop was fixed at a charge voltage of 80 V, a pulse width of 1.5 ms, and a multi-frequency of 6 Hz (Table 1).

5) Double loop with laser welding for two sides (Figure 2E). Cerclage wire with one double loop was welded on wire to wire with 5 mm length of welding at two sides across the twisted knot. The laser parameter for welding a double loop was fixed at a charge voltage of 80 V, a pulse width of 1.5 ms, and a multi-frequency of 6 Hz (Table 1).

2.3. Tensile testing

The experimental setup in this biomechanical study was performed using a servo-hydraulic testing machine (Jinan Testing Equipment IE Corporation) with a 20 kN load cell. The jig was designed as two metallic half cylinders with a radius of 10.6 mm forming a full cylinder with a cylinder bar length of 50 mm (Figure 3). The upper and lower half-cylinder parts were affixed



FIGURE 3
The tensile testing.

with the testing machine, and the tensile load was applied to the specimens at a rate of 50 mm/min (15). All cerclage wiring specimens were tested until the wire breaks. The load of failure for the cerclage wire was measured.

2.4. *In vitro* hemolysis test

The biocompatibility with blood for the 316L stainless steel wire with laser welding was evaluated via an *in vitro* hemolysis test. The test was performed according to ASTM F756-13, ISO 10993-4, and ISO 10993-12 protocols (16). Three random specimens from low (80 V) to high (90 V) laser parameters were

chosen for the test and then sterilized for 30 min by UV, and blood sampling was collected from at least three people. Human blood cells were treated with the calcium and magnesium-free phosphate-buffered saline (CMF-PBS) extracts to determine whether they caused an *in vitro* hemolysis effect. CMF-PBS and high-density polyethylene (HDPE) of 10 ml were used as the negative control, including positive controls using CMF-PBS and 18 MΩ of 10 ml. The human blood cells using these specimens were maintained in a tube for 3 h at 37 ± 2°C; each tube was gently inverted twice approximately every 30 min to maintain contact with the blood and material. Each supernatant was added by Drabkin's solution to define the hemoglobin concentration. The absorbance of the solution was measured with a spectrophotometer at a wavelength of 540 nm. According to the Standard Practices for Assessment of Hemolytic Properties of Materials, a hemolytic grade can be classified into three levels: hemolytic, defined as consisting of more than 5%; slightly hemolytic, defined as a percentage between 2% and 5%; and non-hemolytic, defined as a percentage between 0% and 2%.

2.5. Statistical analysis

Statistical analysis was performed using Minitab® 19 Statistical Software. The Kolmogorov–Smirnov test was used to determine the normality of the data. The data were presented as mean ± standard deviation and were used to compare the groups with ANOVA test and unpaired *t*-test. A *p*-value of <0.05 was considered statistically significant.

3. Results

Table 2 and Figure 4 present the result of the tensile test in five cerclage wiring groups and the mode of cerclage wire failure in each group. The mean load to failure was significantly different between the groups ($p < 0.05$). For the single-loop configurations, no significant difference was found between the conventional single-loop cerclage wire group and the single-loop cerclage wire with laser welding group (1,251 ± 72 N vs. 1,352 ± 122 N, $p = 0.12$). The average welding length in this single loop with the laser welding group is 0.74 mm. Meanwhile, among the double-loop cerclage wiring configurations, the double-loop cerclage wiring with both one-sided and two-sided laser welding groups (3,596 ± 346 N and 3,667 ± 240 N, respectively) had a significantly higher mean load to failure compared with the conventional double-loop cerclage wiring group (2,919 ± 717 N, $p = 0.012$ and 0.044, respectively).

Regarding the mode of failure, the single-loop cerclage wiring with and without laser welding and double-loop cerclage wiring groups were failed by the untwisting of the knot. Conversely, the double-loop cerclage wiring with

TABLE 2 Mean load to failure and mode of failure at different wire fixation methods.

Study groups	Load to failure (*N* ± SD)	Mode of failure	
1. Single loop	1,251 ± 72	Untwist	
2. Laser welding on single loop	1,352 ± 122	Untwist	
3. Double loop	2,919 ± 717	Untwist	
4. Laser welding on double loop (weld one side)	3,596 ± 346	Wire breakage between twisted knot and welded area	
5. Laser welding on double loop (weld two sides)	3,667 ± 240	Wire breakage between twisted knot and welded area	

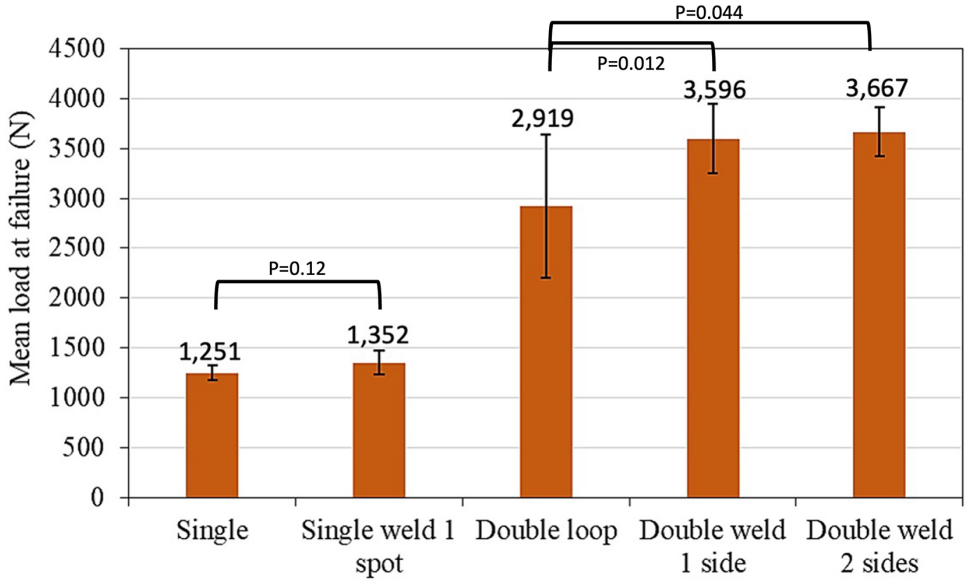

FIGURE 4
Mean load to failure (*N*).

laser-welded groups failed via a wire breakage between the knot and welded area (Table 2). The average breakage location was 1.49 ± 1.19 mm (range 0.18–3.43 mm) in the laser welding for the one-sided group and 2.27 ± 0.75 mm (range 1.6–3.49 mm) and 5.36 ± 1.63 mm (range 3.82–7.73 mm) in laser welding for the two-sided group compared with the welded area (Table 3).

The result of the hemolysis test is reported in Table 4. The mean percentage of hemolysis is below 2%, which is 0.355 (±0.11) at low laser parameters and 0.246 (±0.09) at high laser parameters. These results show that the hemolysis effect on the laser-welded surface of the 316L stainless steel wire is non-hemolytic (non-blood toxic), according to the Standard Practices for Assessment of Hemolytic Properties of Materials.

TABLE 3 Average breakage distance.

Study groups	Average breakage distance	
1. Laser welding on double loop (weld one side)		X_1 = 1.49 ± 1.19 mm (range 0.18–3.43 mm)
2. Laser welding on double loop (weld two sides)		X_1 = 2.27 ± 0.75 mm (range 1.6–3.49 mm) X_2 = 5.36 ± 1.63 mm (range 3.82–7.73 mm)

TABLE 4 Effect of hemolysis on 316l stainless steel with laser welding.

Sample	Hemoglobin of supernatant from extract (mg/ml)	% Hemolysis	Mean % hemolysis	SD	Hemolytic index	Hemolytic grade
Laser parameter: 80 V, 1.5 ms, 6 Hz						
Test item extract (A)—100%	0.003	0.266	0.355	0.107	0	Non-hemolytic
Test item extract (B)—100%	0.004	0.325				
Test item extract (C)—100%	0.006	0.473				
Laser parameter: 90 V, 2.5 ms, 6 Hz						
Test item extract (A)—100%	0.002	0.192	0.246	0.094	0	Non-hemolytic
Test item extract (B)—100%	0.004	0.355				
Test item extract (C)—100%	0.002	0.192				

4. Discussion

The current study aims to evaluate the biomechanical property of laser welding technology in a common orthopedic procedure, that is, cerclage wire fixation. Our results showed that the double-loop cerclage wiring with laser welding (either in one-sided or two-sided welded groups) provided significantly better biomechanical strength (load to failure under tensile traction) than conventional single- or double-loop cerclage wire fixation and single loop with laser welding (at the knot). However, no significant difference existed in the load to failure between double loop with one-sided welding and those with two-sided welding groups. Moreover, the results from this study showed that the mode of failure from double-loop cerclage wire fixation with laser welding differs from the single- or double-loop cerclage wire fixation without welding and the single loop with welding on the twisted knot. The failure mode for double loop with one-sided or two-sided welding groups was the breakage of the wire, while that for the other groups was untwisted wire. This difference could be explained by the laser welding potentially increasing the fatigue failure of the construct by reducing the stress of the cerclage wire under tension load or distributing the tension load in the at-risk area of implant failure, such as the twisted knot (6–8), from the welding joint area between the double loop and resulting in the breakage of wire, as depicted in **Tables 2** and **3**. These results also confirmed that the fixation stability of cerclage wire fixation mainly depends on the wire tension and the twisting technique (6, 9). In addition, the findings on the single loop with welding on the twisted knot showed that the additional fixation stability from laser welding should be related to the welding area (0.74 mm in the single-loop group). Therefore, the application of laser welding in orthopedic fixation should be appropriately designed with the welding area, which is important for long-term durability.

Our hemolysis test also reported non-hemolytic results according to ASTM F756-13, ISO 10993-4, and ISO 10993-12 protocols, which represents that laser welding is not an acute *in vitro* hemolytic adverse event for use in contact with blood. However, other adverse biological effects—such as the incompetent welding process, the discontinued micro-surface of stainless steel, and the long-term release of metallic ions—are not assessed. Although the thermal effect is not evaluated in our study, Quazi et al. reported that the temperature alterations during welding are below the allowable limit of 5.5°C, encouraging the researchers to employ laser welding in *in vivo* studies, thus accounting for an immediate restoration of dental devices (11). Due to the small welding area, the surrounding tissues can be protected and cooled with saline solution during the intraoperative welding process. Moreover, this publication is the first that uses laser welding in orthopedic treatment. However, a small number of previous studies do describe laser welding applications. Hart and Wilson studied the biomechanics of using a filler wire in the laser welding of titanium prostheses to improve flexural strength and fatigue resistance (17). Ortorp and Jemt reported a 100% success rate with excellent overall long-term results of laser-welded titanium frameworks in mandible implantation (18). Fornaini et al. studied pig jaws (*ex vivo*) and found that laser welding could connect titanium implant abutments without the risk of thermal increase into the bone and with good results in terms of mechanical strength (19). Moreover, Fornaini et al. also revealed a case report of intraoral laser welding in a dental prosthesis; the results showed that it was a safe and effective procedure without any complications (20). On the basis of this study, we believe that the laser welding concept could safely be applied to cerclage wire fixation.

Our study has encountered some limitations. First, inherent to any biomechanical study is the difficulty in translation to clinical practice, which may be a combination of multi-loading directions, but we examined only one mode of loading. Consequently, while many previous clinical studies use welding materials in dentist surgery (21–23), further clinical studies and long-term results of using welding materials in orthopedic surgery are needed. Second, we emphasize only the mechanical strength and hemocompatibility of laser welding technology, an emphasis that does not purport to address all safety concerns. Nevertheless, other biocompatible testing, such as thermal necrosis and corrosion testing, should be clarified before human use. Third, the location, character, and magnitude of the welded area are created based on the feasibility and previous trial of examiners. Therefore, additional experiments should be performed for optimal outcomes. According to a different laser parameter between single- and double-loop specimens, a limited comparison between the groups is expected.

5. Conclusion

Laser welding significantly increases the biomechanical strength of double cerclage wire fixation and provides secure hemocompatibility. However, further biocompatible and clinical studies are still recommended.

Data availability statement

The original contributions presented in the study are included in the article, further inquiries can be directed to the corresponding author.

Ethics statement

This study has been reviewed and approved by the Institutional Review Board at Mahidol University, based on the Declaration of Helsinki (COA. No. MURA2018/618, Protocol number 08-61-61).

Author contributions

NP and PS designed the study and wrote the article. NP, EW, KS, and NT performed the experiment and analyzed the results. All authors contributed to the article and approved the submitted version.

Conflict of interest

The authors declare that the research was conducted in the absence of any commercial or financial relationships that could be construed as a potential conflict of interest.

Publisher's note

All claims expressed in this article are solely those of the authors and do not necessarily represent those of their affiliated organizations, or those of the publisher, the editors and the reviewers. Any product that may be evaluated in this article, or claim that may be made by its manufacturer, is not guaranteed or endorsed by the publisher.

References

1. Evans PE. Cerclage fixation of a fractured humerus in 1775. Fact or fiction? *Clin Orthop Relat Res*. (1983) 174:138–42. doi: 10.1097/00003086-198304000-00019

2. Angelini A, Battiato C. Past and present of the use of cerclage wires in orthopedics. *Eur J Orthop Surg Traumatol*. (2015) 25(4):623–35. doi: 10.1007/s00590-014-1520-2

3. Förch S, Sandriesser S, Mayr E, Schrödl F, von Rüden C, Augat P. Biomechanical comparison of different cerclage types in addition to an angle stable plate osteosynthesis of distal tibial fractures. *Injury*. (2021) 52(8):2126–30. doi: 10.1016/j.injury.2021.03.040

4. Hägerich LM, Dyrna FGE, Katthagen JC, Michel PA, Heilmann LF, Frank A, et al. Cerclage performance analysis—a biomechanical comparison of different techniques and materials. *BMC Musculoskelet Disord*. (2022) 23(1):1037. doi: 10.1186/s12891-022-05983-6

5. Bostrom MP, Asnis SE, Ernberg JJ, Wright TM, Giddings VL, Berberian WS, et al. Fatigue testing of cerclage stainless steel wire fixation. *J Orthop Trauma*. (1994) 8(5):422–8. doi: 10.1097/00005131-199410000-00009

6. Meyer DC, Ramseier LE, Lajtai G, Nötzli H. A new method for cerclage wire fixation to maximal pre-tension with minimal elongation to failure. *Clin Biomech*. (2003) 18(10):975–80. doi: 10.1016/S0268-0033(03)00181-5

7. Schultz RS, Boger JW, Dunn HK. Strength of stainless steel surgical wire in various fixation modes. *Clin Orthop Relat Res*. (1985) 198:304–7. doi: 10.1097/00003086-198509000-00045

8. Lenz M, Perren SM, Richards RG, Mückley T, Hofmann GO, Gueorguiev B, et al. Biomechanical performance of different cable and wire cerclage configurations. *Int Orthop*. (2013) 37(1):125–30. doi: 10.1007/s00264-012-1702-7

9. Wähnert D, Lenz M, Schlegel U, Perren S, Windolf M. Cerclage handling for improved fracture treatment: a biomechanical study on the twisting procedure. *Acta Chir Orthop Traumatol Cech*. (2011) 78(3):208–14. doi: 10.55095/achot2011/033

10. Jarit GJ, Sathappan SS, Panchal A, Strauss E, Di Cesare PE. Fixation systems of greater trochanteric osteotomies: biomechanical and clinical outcomes. *J Am Acad Orthop Surg*. (2007) 15(10):614–24. doi: 10.5435/00124635-200710000-00006

11. Quazi MM, Ishak M, Fazal MA, Arslan A, Rubaiee S, Aiman MH, et al. A comprehensive assessment of laser welding of biomedical devices and implant materials: recent research, development and applications. *Crit Rev Solid State Mater Sci*. (2021) 46(2):109–51. doi: 10.1080/10408436.2019.1708701

12. Perveen A, Molardi C, Fornaini C. Applications of laser welding in dentistry: a state-of-the-art review. *Micromachines*. (2018) 9(5):23. doi: 10.3390/mi9050209

13. Nouri A, Wen C. Chapter 3: stainless steels in orthopedics. In: Wen C, editor. *Structural biomaterials*. Cambridge, United Kingdom: Woodhead Publishing (2021). p. 67–101.

14. Thongchuea N, Warinsiriruk E, Wang Y-T. Laser welding on cerclage wire joining in femur surgery. *Appl Sci*. (2020) 10:2407. doi: 10.3390/app10072407

15. McCartney W, Ober C, Benito M, MacDonald B. Comparison of tension band wiring and other tibial tuberosity advancement techniques for cranial cruciate ligament repair: an experimental study. *Acta Vet Scand*. (2019) 61(1):44. doi: 10.1186/s13028-019-0481-1

16. Esmaeili A, Ghaffari SA, Nikkhah M, Malek Ghaini F, Farzan F, Mohammadi S. Biocompatibility assessments of 316L stainless steel substrates coated by Fe-based bulk metallic glass through electro-spark deposition method. *Colloids Surf B Biointerfaces*. (2021) 198:111469. doi: 10.1016/j.colsurfb.2020.111469

17. Hart CN, Wilson PR. Evaluation of welded titanium joints used with cantilevered implant-supported prostheses. *J Prosthet Dent*. (2006) 96(1):25–32. doi: 10.1016/j.prosdent.2006.05.003

18. Ortorp A, Jemt T. Clinical experiences with laser-welded titanium frameworks supported by implants in the edentulous mandible: a 10-year follow-up study. *Clin Implant Dent Relat Res*. (2006) 8(4):198–209. doi: 10.1111/j.1708-8208.2006.00020.x

19. Fornaini C, Meleti M, Bonanini M, Lagori G, Vescovi P, Merigo E, et al. Laser welded versus resistance spot welded bone implants: analysis of the thermal increase and strength. *Sci World J*. (2014) 2014:357074. doi: 10.1155/2014/357074

20. Fornaini C, Merigo E, Cernavin I, de Castro GL, Vescovi P. Intraoral laser welding (ILW) in implant prosthetic dentistry: case report. *Case Rep Dent*. (2012) 2012:839141. doi: 10.1155/2012/839141

21. Jemt T, Henry P, Linden B, Naert I, Weber H, Bergstrom C. A comparison of laser-welded titanium and conventional cast frameworks supported by implants in the partially edentulous jaw: a 3-year prospective multicenter study. *Int J Prosthodont*. (2000) 13(4):282–8.

22. Ortorp A, Jemt T. Early laser-welded titanium frameworks supported by implants in the edentulous mandible: a 15-year comparative follow-up study. *Clin Implant Dent Relat Res*. (2009) 11(4):311–22. doi: 10.1111/j.1708-8208.2008.00119.x

23. Bozini T, Petridis H, Garefis K, Garefis P. A meta-analysis of prosthodontic complication rates of implant-supported fixed dental prostheses in edentulous patients after an observation period of at least 5 years. *Int J Oral Maxillofac Implants*. (2011) 26(2):304–18.

frontiers | Frontiers in Surgery

TYPE Original Research
PUBLISHED 11 October 2023
DOI 10.3389/fsurg.2023.1122379

Check for updates

OPEN ACCESS

EDITED BY
Paphon Sa-ngasoongsong,
Mahidol University, Thailand

REVIEWED BY
Qichang Mei,
Ningbo University, China
Soroush Baghdadi,
Children's Hospital of Philadelphia,
United States

*CORRESPONDENCE
Farid Amirouche
✉ amirouch@uic.edu

RECEIVED 12 December 2022
ACCEPTED 12 September 2023
PUBLISHED 11 October 2023

CITATION
Amirouche F, Solitro GF, Gligor BZ, Hutchinson M and Koh J (2023) Investigating the effect of autograft diameter for quadriceps and patellar tendons use in anterior cruciate ligament reconstruction: a biomechanical analysis using a simulated Lachman test. Front. Surg. 10:1122379. doi: 10.3389/fsurg.2023.1122379

COPYRIGHT
© 2023 Amirouche, Solitro, Gligor, Hutchinson and Koh. This is an open-access article distributed under the terms of the Creative Commons Attribution License (CC BY). The use, distribution or reproduction in other forums is permitted, provided the original author(s) and the copyright owner(s) are credited and that the original publication in this journal is cited, in accordance with accepted academic practice. No use, distribution or reproduction is permitted which does not comply with these terms.

Investigating the effect of autograft diameter for quadriceps and patellar tendons use in anterior cruciate ligament reconstruction: a biomechanical analysis using a simulated Lachman test

Farid Amirouche[1,2]*, Giovanni Francesco Solitro[3], Brandon Zachary Gligor[1], Mark Hutchinson[1] and Jason Koh[2]

[1]Department of Orthopaedics, University of Illinois at Chicago College of Medicine, Chicago, IL, United States, [2]Department of Orthopaedics, Northshore University Health System, Evanston, IL, United States, [3]Department of Orthopaedics, Louisiana State University College of Medicine, Shreveport, LA, United States

Introduction: Current clinical practice suggests using patellar and quadriceps tendon autografts with a 10 mm diameter for ACL reconstruction. This can be problematic for patients with smaller body frames. Our study objective was to determine the minimum diameter required for these grafts. We hypothesize that given the strength and stiffness of these respective tissues, they can withstand a significant decrease in diameter before demonstrating mechanical strength unviable for recreating the knee's stability.

Methods: We created a finite element model of the human knee with boundary conditions characteristic of the Lachman test, a passive accessory movement test of the knee performed to identify the integrity of the anterior cruciate ligament (ACL). The Mechanical properties of the model's grafts were directly obtained from cadaveric testing and the literature. Our model estimated the forces required to displace the tibia from the femur with varying graft diameters.

Results: The 7 mm diameter patellar and quadriceps tendon grafts could withstand 55–60 N of force before induced tibial displacement. However, grafts of 5.34- and 3.76-mm diameters could only withstand upwards of 47 N and 40 N, respectively. Additionally, at a graft diameter of 3.76 mm, the patellar tendon experienced 234% greater stiffness than the quadriceps tendon, with similar excesses of stiffness demonstrated for the 5.34- and 7-mm diameter grafts.

Conclusions: The patellar tendon provided a stronger graft for knee reconstruction at all diameter sizes. Additionally, it experienced higher maximum stress, meaning it dissociates force better across the graft than the quadriceps tendon. Significantly lower amounts of force were required to displace the tibia for the patellar and quadriceps tendon grafts at 3.76- and 5.34-mm graft diameters. Based on this point, we conclude that grafts below the 7 mm diameter have a higher chance of failure regardless of graft selection.

KEYWORDS

ACL, autograft, patellar tendon, quadriceps tendon, diameter, finite element modeling, Lachman test

Introduction

The ACL originates at the medial side of the lateral femoral condyle and runs an oblique course through the intercondylar fossa. It is the primary restraint to anterior tibial translation and secondary restraint to internal rotation of the weight-bearing and non-weight-bearing knee (1). An anterior cruciate ligament (ACL) injury can result in significant impairment, especially in highly active individuals. Numerous graft sources have been described during the evolution of ACL reconstruction surgery (2, 3). Traditionally, the surgical approach to ACL reconstruction favored the use of allografts or autografts from the patellar tendon, although the hamstrings, and to a lesser degree, the quadriceps tendon have become popular grafts amongst many surgeons and institutions throughout the years (4). Many studies have been conducted to investigate the biomechanical properties of these grafts to guide surgeons in choosing the graft most suitable for their patients (5, 6). More specifically, these studies define biomechanical properties such as tensile strength, elasticity, stiffness, stress and strain responses, and the anatomical measures of these individual grafts. These measures were simulated by the model employed in the study to adequately predict, based on graft selection, how the reconstructed joint functions in consideration of the geometric dimensions employed when designing these individual grafts.

One main limitation of the literature regarding this topic is the need for more data for the quadriceps tendon graft compared to the other graft sources. Additionally, a 2022 systematic review noted a need for studies investigating the effects of diameter on graft selection (4). Considering this second point, two studies investigating this question found that smaller diameter patellar and hamstring tendon autografts are associated with weaker tensile strength and a greater risk of failure (7). However, neither of these studies investigated how the diameters of these grafts would affect the knee mechanics in its working environment. More importantly, no studies have been conducted to determine how diameter affects the strength of the quadriceps tendon. This can be attributed to the fact that the quadriceps were the latest grafts to be popularized by Orthopaedic surgeons (4). Therefore, this study aimed to investigate how diameter affects the biomechanical properties of the quadriceps graft while also comparing it to the "gold standard" patellar tendon graft (8, 9). We hypothesize that when changing the diameters of the quadriceps and patellar grafts, these grafts will tolerate a significant decrease in diameter before they become too weak to meet mechanical requirements for ACL reconstruction, with the patellar tendon capable of withstanding a more substantial reduction in diameter when compared to the quadriceps. Furthermore, we introduced a controlled Lachman test as a measure of knee stability similar to the passive accessory movement test of the knee performed to identify the integrity of the anterior cruciate ligament (ACL). Finally, we aimed to determine how changes in the dimensions of the grafts affect their interaction with various bony and ligamentous features of the reconstructed joint, with an emphasis placed on the graft-epicondylar interface.

Methods

Patellar and quadriceps autografts mechanical testing

The extensor apparatus was harvested from fresh-frozen, non-irradiated human knees from male and female donors aged 70–90 without any musculoskeletal pathology. Seven quadriceps tendon-patella-patellar ligament-tibial tuberosity complexes were obtained. Each complex was further divided into two complexes (i) a segment of the quadriceps tendon with the proximal half of the patella attached (QT-P); and (ii) the distal half of the patella, the patellar ligament, and a distal insertion of the tibia (P-PL-T) by performing a transverse cut at the midline of the patella using an oscillating saw following a methodology already used by Staubli (10). The exposed tendon and ligament were wrapped with 0.9% NS-soaked gauze throughout the harvesting and placement procedure. To ensure a proper fixation for the experimental testing, the distal ends of each complex were cemented in a metal box with polyester resin. Stabilizing wires were placed at a perpendicular angle through the longitudinal axis of the tendon complex, and the ends of the stabilizing wires were clamped securely to both sides of the box. This procedure was performed for the P-PL-T for both ends (**Figure 1A**). For the QT-P complex, a Krackow suture was placed within the free tendon end with 3–0 PDS and then secured to the stabilizing wires using multiple suture loops (**Figure 1B**). The metal boxes were clamped to the materials testing machine (Instron, Instron Corporation, Canton, MA, USA) through a wire loop and a screw. Before testing, 250 N was applied to secure the sutures. Uniaxial tensile testing was performed at an 18 mm/min extension rate.

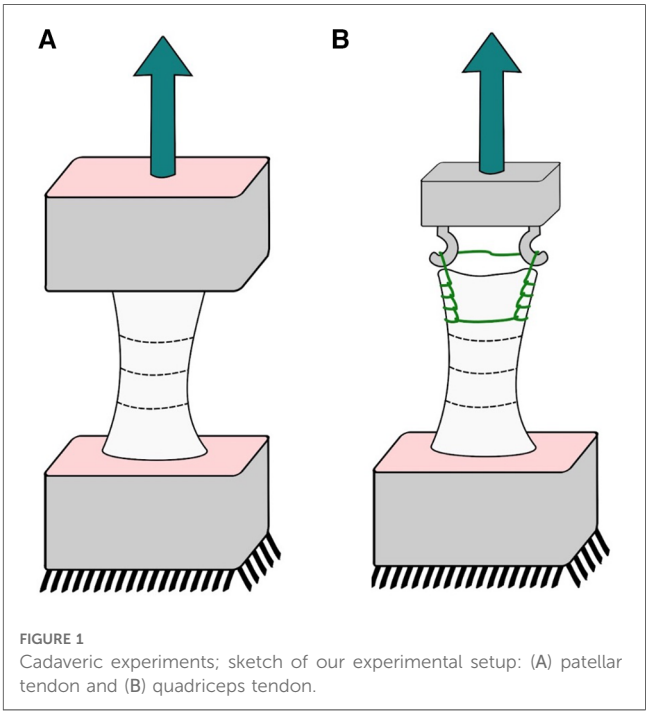

FIGURE 1
Cadaveric experiments; sketch of our experimental setup: (A) patellar tendon and (B) quadriceps tendon.

Using a digital caliper, the exposed tendons and ligaments were marked in the thinner cross-section to measure thickness and width with an initial load of 5 N. The initial length of the tendons and ligaments was an average of 38.5 mm, measured between cemented extremities for the patellar ligament and between the cemented extremity and the suture for the quadriceps tendon. The width was measured in this minor position, and the two adjacent sections were spaced along one-third of the tendon length. The thickness was measured at three equidistant points on these reference positions. The cross-sectional area was evaluated as the width multiplication and the tissue's average thickness. After testing the entire segment, lateral portions were removed to have two remaining sequential samples of two-thirds and one-third in width. On the central one-third, measurements were taken until failure was reached, defined as either separating the tendon complex from the metal housing or separating the housing container from the arm of the machine.

Stress was determined by dividing the force by the corresponding cross-sectional area measurement (see **Figure 6**). In addition, the Modulus of the tissues was evaluated using linear regression on the obtained measurements.

Finite element model for the Lachman test

The effective mechanical behavior of the graft and the composition of both material characterization and tensioning are evaluated in a computer-simulated model that best approximates the knee biomechanics. This model was based on the Lachman Test, the most widely used clinical test to determine if the ACL has been torn (11). When building our model, we needed to recreate the structural properties of these grafts by assigning them different inputs for their intrinsic and extrinsic properties according to preselected Young's Modulus values and diameters.

Given the limitations of using cadavers, many labs report various values for the biomechanical properties of the individual grafts being tested (12). To balance these variations in the literature, we chose to use a range of Young's Modulus values for both the patellar tendon and quadriceps tendon grafts to average the results generated from our model to gain a more accurate picture of the investigated effects. We chose to include Young's Modulus values from the literature for the patella tendon of 340.0 MPa (13), 507.4 MPa (14), 565.9 MPa (15), and 597.4 MPa (16), and a value of 263.4 MPa (15) for the quadriceps tendon.

In choosing diameters to test in our experiment, we followed guidelines in the literature, stating that appropriate graft sizes for ACL reconstruction need to restore up to 85%–115% of the native ACL total cross-sectional area (17). We chose our largest diameter of 7 mm based on an experiment that looked at the effect of diameter on the tensile strength of the patellar tendon at diameters of 7, 10, and 15 mm (18). In line with this past study, we further investigated by starting at the lowest data point used in prior studies and expanding to even smaller diameters. Additionally, this value matches the average diameter of the native ACL mid-substance of 7 mm (1). The next smallest diameter of 5.34 mm was chosen based on a value of 5.4 mm diameter reported for the mid substance of the ACL, based on an analysis of female and older age cadavers (average age of 74.8 years) (19). This would allow us to analyze a potential smaller graft for patients with smaller knee geometry. Finally, we chose our smallest diameter of 3.76 mm, which would still align with the required reconstructed area of the native ACL, based on a reconstruction of an ACL with a diameter of 5.4 mm (20).

The knee bone Geometry was reconstructed from CT scan data using a BrightSpeed (GE Medical Systems) scanner with a slice thickness of 0.625 mm and pixel size of 0.426 mm. The CT images were then imported to Mimics (Materialise, Leuven, Belgium). The tunnels (shown in **Figure 2**) for the ACL graft were virtually created at 90° of Flexion using a Boolean

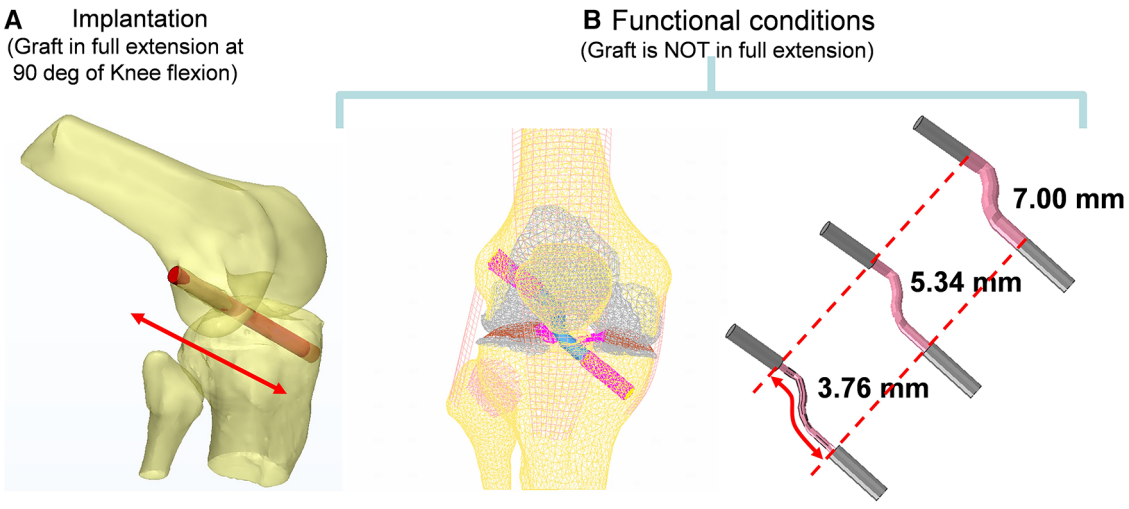

FIGURE 2
Computer reconstruction of the ACL tunnel during implantation at 90 degrees of flexion using the boolean operation of an 8 mm cylinder in diameter (A) and functional conditions (B).

subtraction with a cylinder 8 mm in diameter (21). Its femoral and tibial positions were based on the studies proposed by Bedi et al. and Gadikota et al. (20, 22). An expert surgeon evaluated the axial slices.

Main ligaments were reconstructed following anatomical landmarks on insertion footprints from the literature (23–28). The meniscus was modeled with variable thickness to match the femoral surface in the relaxed position of the CT scan. Considering the aim of this study, the ACL graft was modeled in the knee-flexed configuration as a cylinder and characterized transversely as isotropic (29). The graft in the model is kept in place by two Softsilk 1.5 fixation titanium screws (Smith & Nephew, Andover, MA) 8 mm in Diameter (**Figure 3A**). All other ligaments are modeled as membrane elements reinforced by truss elements (30–32). The meniscus was modeled as transverse isotropic with an orientation identical to the tibia axis (33). The cartilages (**Figure 3B**) are created assuming a constant thickness of 2.23 mm for the patella and 2.14 mm for the femur with modulus $E = 10$ MPa and $\nu = 0.45$ (34). The cortical bone was modeled with Young's modulus of 17 GPa (35), while the material properties of the trabecular bone were assigned from the CT data (36–38).

The model was simulated, imposing an A-P translation of 15.9 mm, equivalent to the average value reported at the anterior tibial tubercle by Christel et al. (39) for Lachman tests performed on cadaveric specimens (**Figure 3C**). In addition, six variations in ACL cross-sections from the initial 38.5 mm^2 were implemented, considering cross-section areas of 22.4 mm^2 and 11.10 mm^2 (**Figure 4**). The boundary conditions were applied to constrain the proximal end of the femur in all degrees of freedom. Additionally, a posterior-anterior displacement was applied to the distal end of the tibia along the projection of the anatomical axis of the femur on the plane sectioning the tibia.

Results

Experimental tensile properties

During mechanical testing, no specimen slippage from the fixation device occurred, and no slippage from the fixation device was observed. Patellar ligaments were generally smaller than quadriceps tendons (126.27 and 135.67 $mm^{2,}$ respectively). The cross-sectional area of the patellar tendon was reduced by 10.64% of its initial cross-sectional area at L_1 (first-third of the length) and approximately 34.61% at L_2 (second third of the length). For the quadriceps tendon, the reduction in cross-sectional area for L_1 was 9.77%.

For the young Modulus evaluated for the entire segment, the quadriceps tendon has shown a standard deviation of 76 MPa, smaller than the 115 MPa estimated for the patellar tendon. Still, as shown in **Figure 5**, the range between maximal and minimal values recorded for every strain value was more significant for the quadriceps tendon than for the patellar ligament. We have found an increasing modulus with decreasing cross-section (see **Table 1**). Specifically, the central one-third graft was a drastic 118% stiffer for the patellar ligament than the entire segment. The quadriceps tendon further demonstrates this trend (**Figure 6B**, **Table 1**).

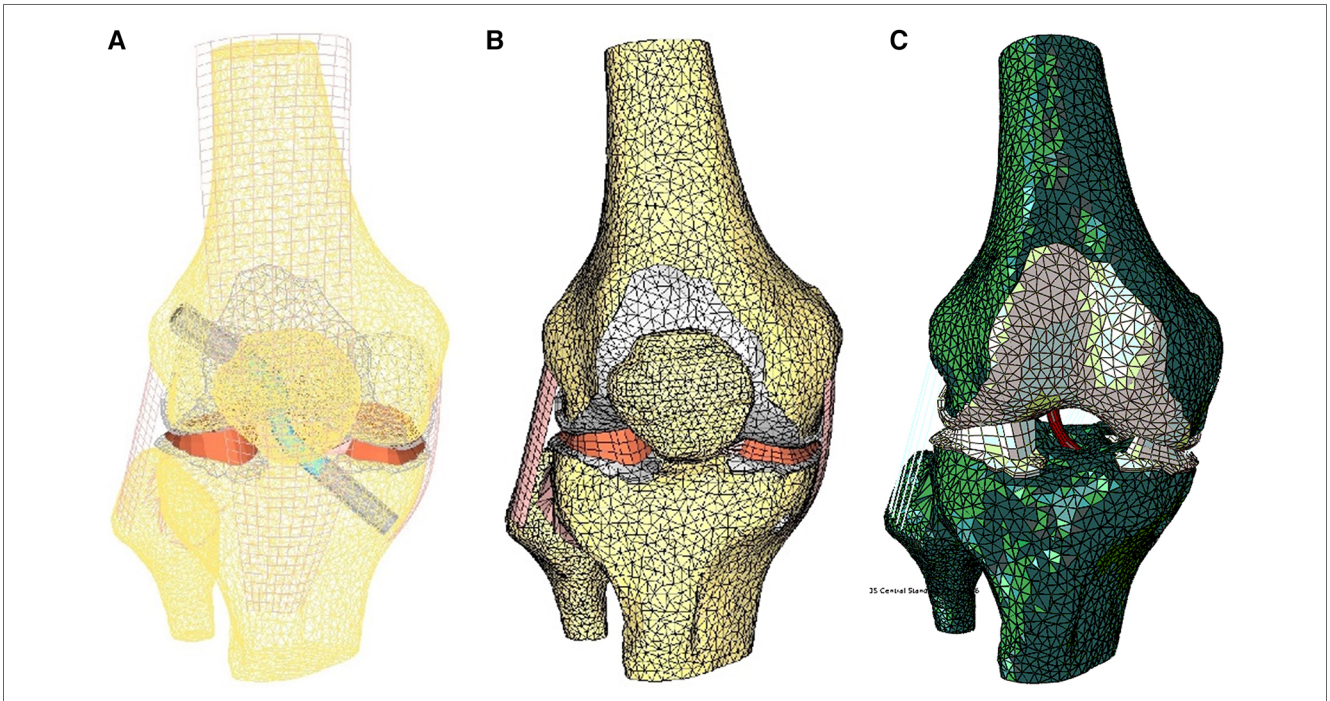

FIGURE 3
Finite element model of the knee in the unloaded configuration: (A) ACL graft simulated, (B) 3D external rotation view of cartilage and meniscus layers and collateral ligaments, and (C) initial displacement imposed.

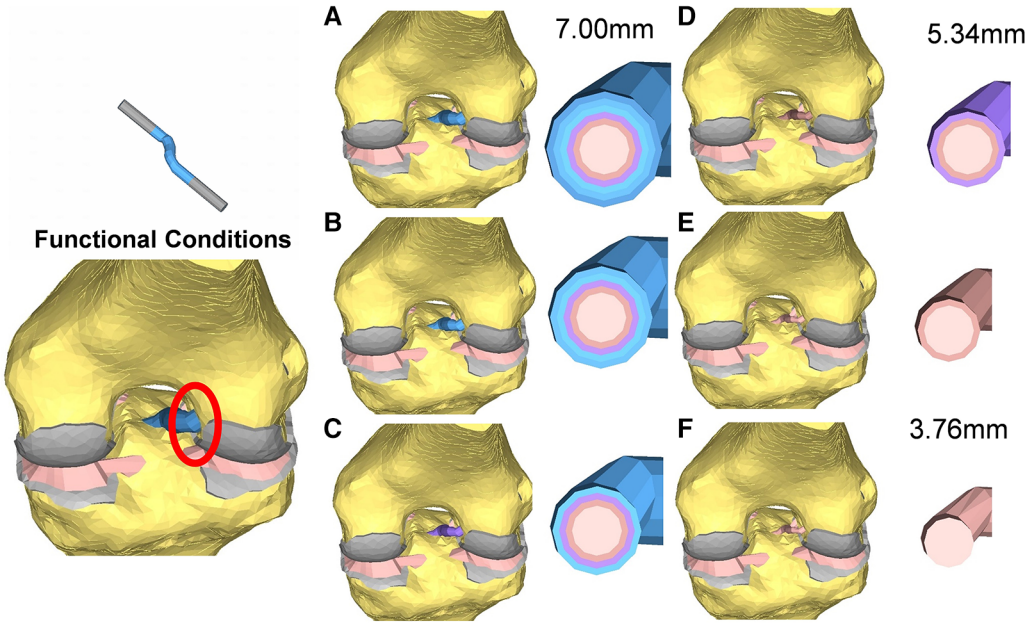

FIGURE 4
Cross-section view of the reconstructed ACL grafts: the diameters range from 7 mm (A) to 3.76 mm (F).

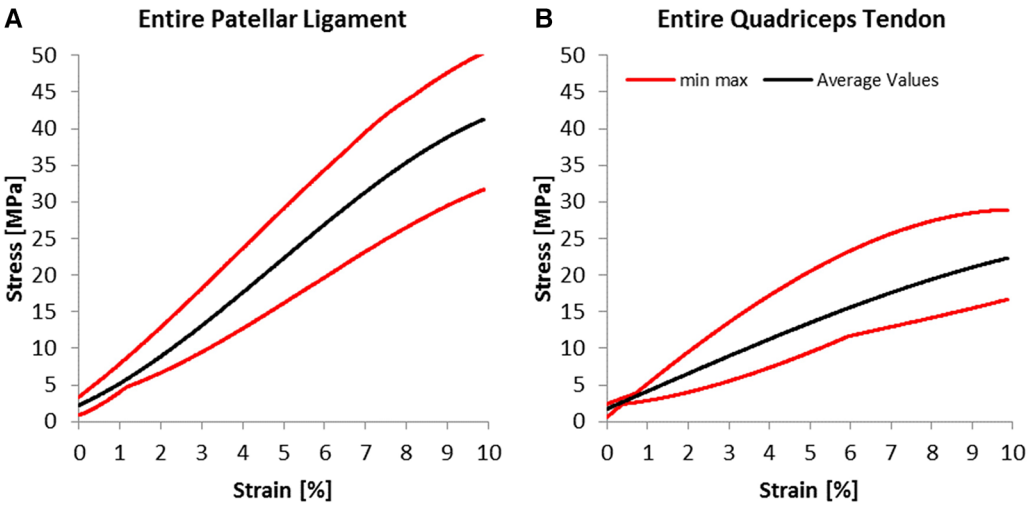

FIGURE 5
Experimental results; average stress-strain curves and ranges for (A) patellar ligaments and (B) quadriceps tendon.

TABLE 1 Young moduli from experiments conducted in the current study.

Segment	Patellar ligament			Quadriceps tendon		
Portion	Entire segment	Central two third	Central One third	Entire segment	Central Two third	Central portion
Cross Section [mm^2]	126.3	83.1	48.5	135.7	105.8	64.3
Modulus [MPa]	409.5	564.6	893.4	176.7	330.5	461.8

The Patellar ligament was stiffer than the Quadriceps tendon (Figure 6A). When comparing the central one-third portion of the tissues, the proportion commonly used for grafts, the patellar ligament was substantially stiffer, with a Modulus of 893.4 MPa, compared to 461.8 MPa for the quadriceps tendon.

Simulated Lachman test

The average force for the Lachman maneuver was 59.48 N ± 1.82 N for the patellar tendon graft with a width of 7.00 mm. For graft sizes of 5.34 mm and 3.76 mm, the force was reduced by

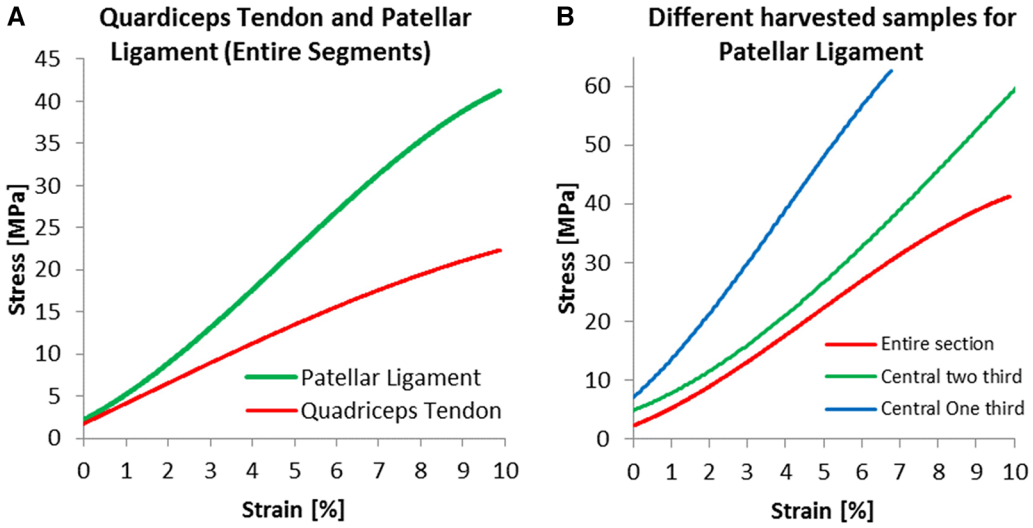

FIGURE 6
Specific results for harvested dimensions; experimental results for (A) entire segments and for (B) three harvested dimensions of the patellar ligament.

21% and 33%, respectively (Figure 7). When used as a graft, the 7 mm patellar tendon graft was 10.7% stronger than the native ACL. The force calculated using the central portion of the 7 mm quadriceps tendon as a graft was 5.1% greater than the one produced by the native ACL.

In the cases where the quadricep graft sizes were reduced to 5.34 mm and 3.76 mm, the forces were reduced by 27% and 13%. The ANOVA single factor revealed a significant difference between the three graft sizes ($p < 0.05$). In the graft size of 3.76 mm, the patellar tendon graft (893.4 MPa) was 234% stiffer than the quadriceps graft (263.4 MPa), and the force increment was limited to 5.1% ($R^2 = 0.946$). For graft sizes of 5.34 mm and 7.00 mm, the force increment was evaluated at 8.1% ($R^2 = 0.928$) and 9.8% ($R^2 = 0.909$), respectively.

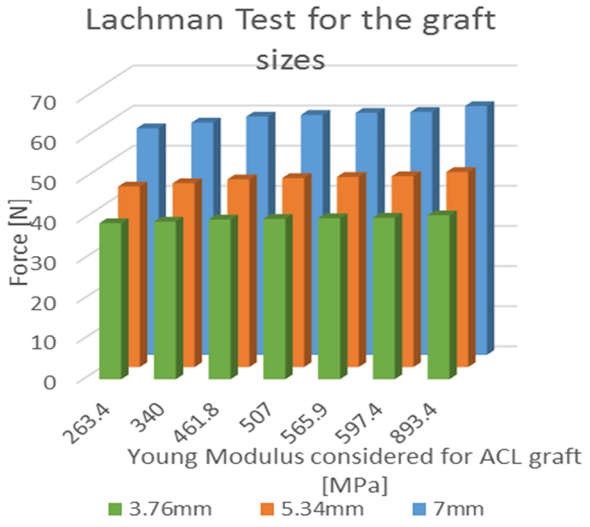

FIGURE 7
Results of the simulated Lachman test; values of force needed for the A-P displacement according to the young modulus for each of the three considered graft dimensions.

We also performed additional tests to investigate the quadriceps tendon (461.8 MPa) as an alternative to the patellar tendon. The maximum stress for the quadriceps tendon with a graft size of 3.76 mm was 43.8 MPa (Figure 8). Increasing the graft dimensions, the maximal stress was significantly reduced to 28.4 MPa and 27.5 MPa for the 5.34 mm and 7.00 mm graft sizes (Figure 8). Following the intercondylar eminence, the stress 10.88 MPa was found for the 7.0 mm graft, whereas the 3.76 mm graft resulted in 8.5 MPa maximal stress. A much more pronounced reduction in stress is seen when comparing the stress risers at the femoral condyle bonding part, where we measured 21.1 MPa and 8.8 MPa for the 7.00 mm and the 3.76 mm grafts. Similar trends in maximum stress were observed for the native ACL and the patellar tendon grafts. However, when comparing values for the maximum stress of the quadriceps tendon to those experienced by the patellar tendon at similar diameters, the patellar tendon grafts in our model showed an average of two times greater maximum stress across relative points of interest on the grafts.

Discussion

We found that within our model, the patellar tendon outperformed the quadriceps at all graft diameters. When averaging the values for graft diameter and Young's Modulus of the respective graft sources, the patellar tendon required a 10.7% greater force relative to the native ACL to induce tibial displacement compared to 5.1% for the quadriceps. This suggests that the patellar tendon yields more robust grafts for ACL reconstruction at smaller graft diameters. Additionally, the maximum stress for the patellar tendon is at least double that of

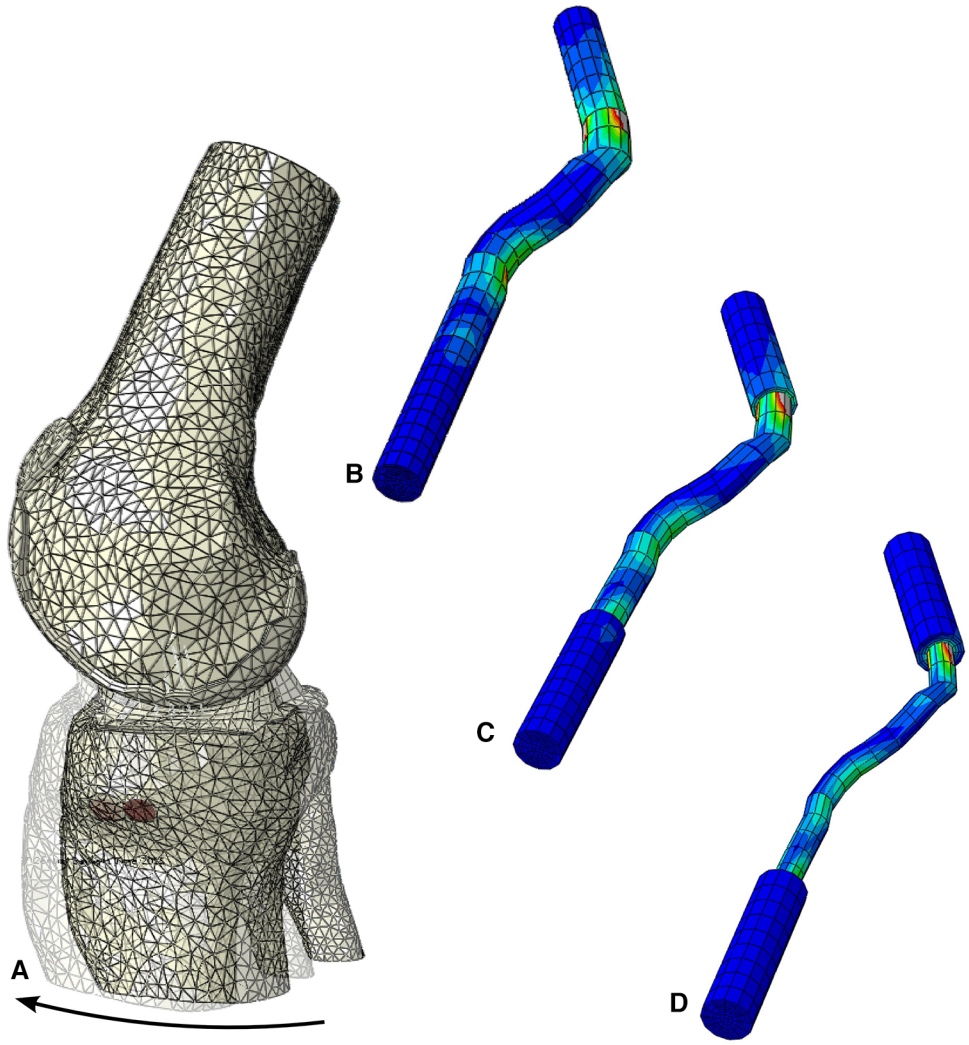

FIGURE 8
Stress distribution during the simulated Lachman test for the configuration with young modulus of 461 MPa, (A) resultant displacement with graft dimension of 7 mm, von mises stress distribution, including the screws, in (B) 7 mm, (C) 5.34 mm and (D) 3.76 mm graft sizes.

the quadriceps tendon and about 3–4 times that of the native ACL. This is visualized in Figure 8 by using our modeling results and extracting the maximum stress from the stress response heat map on the tendon. This shows that the patellar tendon better distributes force across the graft and can tolerate more significant stress before deformation.

On the other hand, the patellar tendon has its inherent flaws. The patellar tendon was 234% stiffer than the quadriceps tendon. Additionally, past research found that the Young Modulus evaluated for the patellar tendon is approximately two times greater than that of the quadriceps tendon (see Table 2) (15). This is problematic given an association of excessive stiffness and high Young's Modulus with over-constraining of the knee. A study by O'Brien et al. found that the knee experiences more significant constriction with increasing Young's Modulus. In contrast, Suggs et al. found a correlation between graft stiffness

TABLE 2 Young moduli reported in the literature compared to the current study.

Author	Stäubli et al. (10)	Flahiff et al. (13)	Current study	Hashemi et al. (14)	Stäubli et al. (10)	O'Brien et al. (16)	Current study
Segment	Quadriceps tendon	Patellar ligament	Quadriceps tendon	Patellar ligament	Patellar ligament	Patellar ligament	Patellar ligament
Portion	Central portion (CSS 64.6 mm^2)	Central portion (Width 13.2 mm)	Central portion (CSS 64.3 mm^2)	Central portion (CSS 20.7 mm^2)	Central portion (CSS 34.5 mm^2)	Entire Patellar Ligament (vivo) (CSS 114.8 mm^2)	Central portion (CSS 48.5 mm^2)
Ultimate tensile stress [MPa]	38.0	78.4 "800 to 3,000"N	62.2	58.7	69.6	–	68.17
Modulus [MPa]	263.4 (at 200 N) 462.8 (at 800 N)	340.0	461.8	507.4	565.9 (at 200 N) 811.7 (at 800 N)	597.4	893.4

and knee constraining at various flexion angles (16, 40). Additionally, it has been shown that an over-constraining effect is a common postoperative outcome of ACL reconstruction. A study by Robertson et al. that investigated postoperative knee stiffness in 100 patients undergoing primary ACL reconstruction with hamstring autografts found an incidence of postoperative knee stiffness of 12% at six months follow-up (40, 41). Even more, one study found that athletes who have undergone ACL reconstruction with quadriceps tendons experience less stiffness when compared to those who received patellar tendon autografts and performed better in specific compound movements such as squatting (42).

Westermann et al. conducted a similar study using a simulated Lachman model to test graft diameters between 5 and 9 mm (43). However, they designed a graft that restored the joint to ideal proportions in all areas of the knee joint, and that reconstructed the ACL with a graft demonstrating over 150% the strength of the native ACL. In addition, their study showed that anatomically ideal grafts of all sizes could tolerate over 75 N of force before induced tibial displacement. Based on this, we could compare the strength of the grafts within our model relative to the "gold standard" for ACL reconstruction. We found that the 7 mm diameter grafts were the only grafts in our study that showed strength comparable to these ideal grafts, with forces of over 55 N and upwards of -60 N required to induce tibial displacement. Additionally, the grafts below 7 mm failed to reach a strength of even 50 N before tibial displacement. Even more, grafts of these diameters underperformed compared to the native ACL within our model. Given our goal of restoring the native strength of the ACL, grafts below 7 mm diameters do not approximate the strength of an ideal ACL graft and should not be considered for ACL reconstruction.

Regarding the graft size of 3.76 mm, we were not surprised by the results collected. We anticipated this graft dimension would not be suitable for ACL reconstruction but chose to include it in our model to validate the diameter at which the grafts fail. Although this graft size is unsuitable for ACL reconstruction, we aimed to understand how small the graft's diameter can be before it is incompatible with ACL reconstruction, making this data point extremely valuable.

Furthermore, using smaller graft diameters within the experimental design allows the model to better estimate how the total area of the grafts affect their biomechanical properties, while maintaining core constants such as width and length. This allowed us to model smaller graft sizes in the context of understating if smaller grafts are suitable for patients with smaller body frames, while only changing a single dimensional variable, namely diameter, which was already the variable under investigation within our study. A more favorable approach to investigating total area would be to adjust the width and diameters of the grafts while keep these variables within ranges that are commonly employed in surgical practice, however this was out of the scope of the research question. We were able to still gauge the importance of area on the strength of smaller grafts by using graft diameters smaller than those commonly used within clinical practice while also using these graft diameters to formally investigate the extent of which diameter affects ACL graft selection.

Within our study, a few limitations can be identified. Foremost, the cadavers utilized were of a significant age, between 70 and 90. This may have impacted the mechanical properties of experimental characterization. Additionally, the Young's Modulus values found in our study were more significant than those reported in the literature compared to younger cadavers. This finding runs contrary to what has been established in the literature, as it has been well described that the quadriceps undergoes degeneration as the individual ages and should have yielded a weaker response to stress as compared to the quadriceps of younger cadavers tested by other laboratories (44). The different testing conditions employed, namely concerning the load ranges adopted could have impacted the preparation of the grafts, thus explaining why our tissues behaved differentially than those of other researchers. We compensated for this variance by creating a range of Young's Modulus values that would provide us with an average of values to estimate better the actual effect of Young's Modulus on the grafts. Values from the literature were chosen based on studies that followed similar methods to ours. Although we chose to include four Young's Modulus values for the patellar tendon, it is essential to note that only one literature value was used for the quadriceps, given that fewer data exists for this graft source compared to the patellar tendon in the literature.

Next, we used a finite element model to conduct our experiment. We chose to use a model for several key reasons. First, using a model rules out any errors regarding preparing the grafts at their proper diameters. Additionally, variables such as diameter can be easily manipulated within a model, and various results, such as maximum stress and strain across different elements of the reconstructed knee, can be obtained from a single test. This is not attainable when using cadavers. The limitations faced with cadavers are both a lack of accessibility to adequate quantities of cadavers and many inherent flaws that can affect the data collected. These include variables such as how the cadavers were stored, how old the cadavers are, and how the test is designed and carried out. Finally, using a model of the knee in its working environment allowed us to test how diameter affects the mechanics of the joint, something that has yet to be done in prior studies investigating the effects of diameter on ACL grafts.

Currently, no established experimental methodologies exist to validate such interactions between grafts and condyles. Consequently, the conclusions regarding the experimental testing of the tissues have been appropriately separated from the results obtained from the computer model, which overlooks the ACL-bone interaction (45, 46) entirely. The model used within the study primarily serves to investigate the interaction between graft diameter and joint stability but also functions independently to indicate the interaction between the graft and the condyles. Considering this, the measurements taken from the model focused on quantifying the forces distributed across the reconstructed joint at all the anatomical landmarks of the reconstructed joint, with particular consideration of the epicondylar eminence and femoral condyles. Although the validity of this element is limited, the model does quantify the relationship between graft dimensions and

the graft-to-condyle interface. This can be used as a preface to further research to investigate this relationship better.

While finite element modeling has its benefits, it is limited in its application and accuracy when compared to research with cadaveric models. Further testing with cadaveric models is highly recommended to conclude what has been found in this study. It would be beneficial to test the functionality of these grafts within cadavers at various diameters with 1 mm increments, starting at 7 mm and going up to 10 mm, to generate finite data to guide surgeons when considering matching functional graft sizes to their patients.

Conclusion

When designing ACL grafts of a smaller area for use with patients that require smaller than traditional grafts, we found that the patellar tendon provided a stronger graft for knee reconstruction at all diameters. This makes the patellar tendon favorable for use as a graft source in patients requiring smaller grafts. This is further corroborated by the point that the quadriceps tendon undergoes a significantly greater degree of degeneration over time as compared the patellar tendon. For traditional graft sizes, this would not be a factor causing surgeons to favor the patellar tendon over the quadriceps tendon, however when maximally confining graft dimensions in the context of our research question, this element becomes increasingly important to consider.

Assuming that a greater emphasis is placed on the utilization of smaller grafts in target populations, it will be increasingly important to choose a graft source that is stronger and retains a greater functional area as the graft ages. Even more, we conclude based on our model that grafts below 7 mm diameter are unsuitable for reconstruction of the knee. Finally, the interaction we discovered between the condyles and the graft paves the way for future investigations into how graft dimensions can be tailored to the morphometric characteristics of the knee.

Data availability statement

The original contributions presented in the study are included in the article/Supplementary Material, further inquiries can be directed to the corresponding author.

Author contributions

FA is the principal author for the proposed manuscript and was responsible for the proposal and design of the experiment. FA also conducted data analysis and helped in the process of creating the manuscript for the project. GS in coordination with FA helped with the design of the project. Additionally, GS helped in the process of drafting the manuscript. BG worked on data analysis and was most responsible for creating the manuscript for the project. MH and JK helped in the design of the project and helped with data analysis. All authors contributed to the article and approved the submitted version.

Conflict of interest

The authors declare that the research was conducted in the absence of any commercial or financial relationships that could be construed as a potential conflict of interest.

Publisher's note

All claims expressed in this article are solely those of the authors and do not necessarily represent those of their affiliated organizations, or those of the publisher, the editors and the reviewers. Any product that may be evaluated in this article, or claim that may be made by its manufacturer, is not guaranteed or endorsed by the publisher.

References

1. Duthon VB, Barea C, Abrassart S, Fasel JH, Fritschy D, Ménétrey J. Anatomy of the anterior cruciate ligament. *Knee Surg Sports Traumatol Arthrosc.* (2006) 14 (3):204–13. doi: 10.1007/s00167-005-0679-9

2. Brown CH, Steiner ME, Carson EW. The use of hamstring tendons for anterior cruciate ligament reconstruction. Technique and results. *Clin Sports Med.* (1993) 12 (4):723–56. doi: 10.1016/S0278-5919(20)30385-9

3. Jansson KA, Linko E, Sandelin J, Harilainen A. A prospective randomized study of patellar versus hamstring tendon autografts for anterior cruciate ligament reconstruction. *Am J Sports Med.* (2003) 31(1):12–8. doi: 10.1177/036354650303 10010501

4. Diermeier T, Tisherman R, Hughes J, Tulman M, Baum Coffey E, Fink C, et al. Quadriceps tendon anterior cruciate ligament reconstruction. *Knee Surg Sports Traumatol Arthrosc.* (2020) 28(8):2644–56. doi: 10.1007/s00167-020-05902-z

5. Buerba RA, Boden SA, Lesniak B. Graft selection in contemporary anterior cruciate ligament reconstruction. *JAAOS Glob Res Rev.* (2021) 5(10):e21.00230. doi: 10.5435/JAAOSGlobal-D-21-00230

6. Malige A, Baghdadi S, Hast MW, Schmidt EC, Shea KG, Ganley TJ. Biomechanical properties of common graft choices for anterior cruciate ligament reconstruction: a systematic review. *Clin Biomech.* (2022) 95:105636. doi: 10.1016/j.clinbiomech.2022.105636

7. Boniello MR, Schwingler PM, Bonner JM, Robinson SP, Cotter A, Bonner KF. Impact of hamstring graft diameter on tendon strength: a biomechanical study. *Arthrosc J Arthrosc Relat Surg.* (2015) 31(6):1084–90. doi: 10.1016/j.arthro.2014.12.023

8. *Why bone–patella tendon–bone grafts should still be considered the gold standard for anterior cruciate ligament reconstruction | British Journal of Sports Medicine.* Available at: https://bjsm.bmj.com/content/43/5/323.long (Cited July 13, 2022).

9. Woods T, Gratzer PF. Effectiveness of three extraction techniques in the development of a decellularized bone–anterior cruciate ligament–bone graft. *Biomaterials.* (2005) 26(35):7339–49. doi: 10.1016/j.biomaterials.2005.05.066

10. Stäubli HU, Schatzmann L, Brunner P, Rincón L, Nolte LP. Mechanical tensile properties of the quadriceps tendon and patellar ligament in young adults. *Am J Sports Med.* (1999) 27(1):27–34. doi: 10.1177/03635465990270011301

11. van Eck CF, van den Bekerom MPJ, Fu FH, Poolman RW, Kerkhoffs GMMJ. Methods to diagnose acute anterior cruciate ligament rupture: a meta-analysis of physical examinations with and without anaesthesia. *Knee Surg Sports Traumatol Arthrosc.* (2013) 21(8):1895–903. doi: 10.1007/s00167-012-2250-9

12. Marieswaran M, Jain I, Garg B, Sharma V, Kalyanasundaram D. A review on biomechanics of anterior cruciate ligament and materials for reconstruction. *Appl Bionics Biomech*. (2018) 2018:e4657824. doi: 10.1155/2018/4657824

13. Flahiff CM, Brooks AT, Hollis JM, Vander Schilden JL, Nicholas RW. Biomechanical analysis of patellar tendon allografts as a function of donor age. *Am J Sports Med*. (1995) 23(3):354–8. doi: 10.1177/036354659502300319

14. Hashemi J, Chandrashekar N, Slauterbeck J. The mechanical properties of the human patellar tendon are correlated to its mass density and are independent of sex. *Clin Biomech*. (2005) 20(6):645–52. doi: 10.1016/j.clinbiomech.2005.02.008

15. Staeubli HU, Adam O, Becker W, Burgkart R. Anterior cruciate ligament and intercondylar notch in the coronal oblique plane: anatomy complemented by magnetic resonance imaging in cruciate ligament–intact knees. *Arthrosc J Arthrosc Relat Surg*. (1999) 15(4):349–59. doi: 10.1016/S0749-8063(99)70051-4

16. O'Brien TD, Reeves ND, Baltzopoulos V, Jones DA, Maganaris CN. Mechanical properties of the patellar tendon in adults and children. *J Biomech*. (2010) 43 (6):1190–5. doi: 10.1016/j.jbiomech.2009.11.028

17. Offerhaus C, Albers M, Nagai K, Arner JW, Höher J, Musahl V, et al. Individualized anterior cruciate ligament graft matching: in vivo comparison of cross-sectional areas of hamstring, patellar, and quadriceps tendon grafts and ACL insertion area. *Am J Sports Med*. (2018) 46(11):2646–52. doi: 10.1177/0363546518786032

18. Cooper DE, Deng XH, Burstein AL, Warren RF. The strength of the central third patellar. Tendon graft: a biomechanical study. *Am J Sports Med*. (1993) 21(6):818–24. doi: 10.1177/036354659302100610

19. Muneta T, Takakuda K, Yamamoto H. Intercondylar notch width and its relation to the configuration and cross-sectional area of the anterior cruciate ligament: a cadaveric knee study. *Am J Sports Med*. (1997) 25(1):69–72. doi: 10.1177/036354659702500113

20. Bedi A, Altchek DW. The "footprint" anterior cruciate ligament technique: an anatomic approach to anterior cruciate ligament reconstruction. *Arthroscy*. (2009) 25(10):1128–38. doi: 10.1016/j.arthro.2009.03.008

21. Kopf S, Forsythe B, Wong AK, Tashman S, Irrgang JJ, Fu FH. Transtibial ACL reconstruction technique fails to position drill tunnels anatomically in vivo 3D CT study. *Knee Surg Sports Traumatol Arthrosc*. (2012) 20(11):2200–7. doi: 10.1007/s00167-011-1851-z

22. Gadikota HR, Sim JA, Hosseini A, Gill TJ, Li G. The relationship between femoral tunnels created by the transtibial, anteromedial portal, and outside-in techniques and the anterior cruciate ligament footprint. *Am J Sports Med*. (2012) 40 (4):882–8. doi: 10.1177/0363546511434276

23. Basso O, Johnson DP, Amis AA. The anatomy of the patellar tendon. *Knee Surg Sports Traumatol Arthrosc*. (2001) 9(1):2–5. doi: 10.1007/s001670000133

24. Espregueira-Mendes, da Silva MV. Anatomy of the lateral collateral ligament: a cadaver and histological study. *Knee Surg Sports Traumatol Arthrosc*. (2006) 14 (3):221–8. doi: 10.1007/s00167-005-0681-2

25. Feyen H, Van Opstal N, Bellemans J. Partial resection of the PCL insertion site during tibial preparation in cruciate-retaining TKA. *Knee Surg Sports Traumatol Arthrosc*. (2013) 21(12):2674–9. doi: 10.1007/s00167-012-1997-3

26. Lind M, Menhert F, Pedersen AB. Incidence and outcome after revision anterior cruciate ligament reconstruction: results from the danish registry for knee ligament reconstructions. *Am J Sports Med*. (2012) 40(7):1551–7. doi: 10.1177/0363546512446000

27. Salim R, Salzler MJ, Bergin MA, Zheng L, Carey RE, Kfuri M, et al. Fluoroscopic determination of the tibial insertion of the posterior cruciate ligament in the sagittal plane. *Am J Sports Med*. (2015) 43(5):1142–6. doi: 10.1177/0363546514568277

28. Chahla J, Moatshe G, Dean CS, LaPrade RF. Posterolateral corner of the knee: current concepts. *Arch Bone Jt Surg*. (2016) 4(2):97–103.

29. Weiss JA, Maker BN, Govindjee S. Finite element implementation of incompressible, transversely isotropic hyperelasticity. *Comput Methods Appl Mech Eng*. (1996) 135(1–2):107–28. doi: 10.1016/0045-7825(96)01035-3

30. Adouni M, Shirazi-Adl A, Shirazi R. Computational biodynamics of human knee joint in gait: from muscle forces to cartilage stresses. *J Biomech*. (2012) 45 (12):2149–56. doi: 10.1016/j.jbiomech.2012.05.040

31. Marouane H, Shirazi-Adl A, Adouni M, Hashemi J. Steeper posterior tibial slope markedly increases ACL force in both active gait and passive knee joint under compression. *J Biomech*. (2014) 47(6):1353–9. doi: 10.1016/j.jbiomech.2014.01.055

32. Mesfar W, Shirazi-Adl A. Biomechanics of the knee joint in flexion under various quadriceps forces. *Knee*. (2005) 12(6):424–34. doi: 10.1016/j.knee.2005.03.004

33. Yao J, Kuang GM, Wong DWC, Niu WX, Zhang M, Fan YB. Influence of screw length and diameter on tibial strain energy density distribution after anterior cruciate ligament reconstruction. *Acta Mech Sin*. (2014) 30:241–9. doi: 10.1007/s10409-014-0027-8

34. Łuczkiewicz P, Daszkiewicz K, Witkowski W, Chróścielewski J, Zarzycki W. Influence of meniscus shape in the cross sectional plane on the knee contact mechanics. *J Biomech*. (2015) 48(8):1356–63. doi: 10.1016/j.jbiomech.2015.03.002

35. Samitier G, Marcano AI, Alentorn-Geli E, Cugat R, Farmer KW, Moser MW. Failure of anterior cruciate ligament reconstruction. *Arch Bone Jt Surg*. (2015) 3 (4):220–40.

36. Helgason B, Taddei F, Pálsson H, Schileo E, Cristofolini L, Viceconti M, et al. A modified method for assigning material properties to FE models of bones. *Med Eng Phys*. (2008) 30(4):444–53. doi: 10.1016/j.medengphy.2007.05.006

37. Keller TS. Predicting the compressive mechanical behavior of bone. *J Biomech*. (1994) 27(9):1159–68. doi: 10.1016/0021-9290(94)90056-6

38. Schileo E, Balistreri L, Grassi L, Cristofolini L, Taddei F. To what extent can linear finite element models of human femora predict failure under stance and fall loading configurations? *J Biomech*. (2014) 47(14):3531–8. doi: 10.1016/j.jbiomech.2014.08.024

39. Christel PS, Akgun U, Yasar T, Karahan M, Demirel B. The contribution of each anterior cruciate ligament bundle to the lachman test: a cadaver investigation. *J Bone Joint Surg Br*. (2012) 94(1):68–74. doi: 10.1302/0301-620X.94B1.26562

40. Suggs J, Wang C, Li G. The effect of graft stiffness on knee joint biomechanics after ACL reconstruction––a 3D computational simulation. *Clin Biomech*. (2003) 18 (1):35–43. doi: 10.1016/S0268-0033(02)00137-7

41. Robertson GAJ, Coleman SGS, Keating JF. Knee stiffness following anterior cruciate ligament reconstruction: the incidence and associated factors of knee stiffness following anterior cruciate ligament reconstruction. *Knee*. (2009) 16 (4):245–7. doi: 10.1016/j.knee.2008.12.014

42. Wang B, Zhong JL, Xu XH, Shang J, Lin N, Lu HD. Incidence and risk factors of joint stiffness after anterior cruciate ligament reconstruction. *J Orthop Surg*. (2020) 15 (1):175. doi: 10.1186/s13018-020-01694-7

43. Westermann RW, Wolf BR, Elkins JM. Effect of acl reconstruction graft size on simulated lachman testing: a finite element analysis. *Iowa Orthop J*. (2013) 33:70–7.

44. Kannus P, Józsa L. Histopathological changes preceding spontaneous rupture of a tendon. A controlled study of 891 patients. *JBJS*. (1991) 73(10):1507. doi: 10.2106/00004623-199173100-00009

45. Mogl KE, Shirazi-Adl A. Biomechanics of passive knee joint in drawer: load transmission in intact and ACL-deficient joints. *Knee*. (2003) 10(3):265–76. doi: 10.1016/S0968-0160(02)00135-7

46. Kia M, Schafer K, Lipman J, Cross M, Mayman D, Pearle A, et al. A multibody knee model corroborates subject-specific experimental measurements of low ligament forces and kinematic coupling during passive flexion. *J Biomech Eng*. (2016) 138 (5):051010. doi: 10.1115/1.4032850

Frontiers in Surgery

Explores and improves surgical practice and clinical patient management

A multidisciplinary journal which explores surgical practices - from fundamental principles to advances in microsurgery and minimally invasive techniques. It fosters innovation and improves the clinical management of patients.

Discover the latest Research Topics

See more →



Frontiers

Avenue du Tribunal-Fédéral 34
1005 Lausanne, Switzerland
frontiersin.org

Contact us

+41 (0)21 510 17 00
frontiersin.org/about/contact